ormation on forensic medicine and toxicology books, visit our website www.ejaypee.com, for detailed information on forensic medicine and toxicology books, visit our website www.ejaypee.com

3rd Edition

Practical Guide for Forensic Medicine and Toxicology

As per the Revised Competency-based Medical Education Curriculum (NMC)

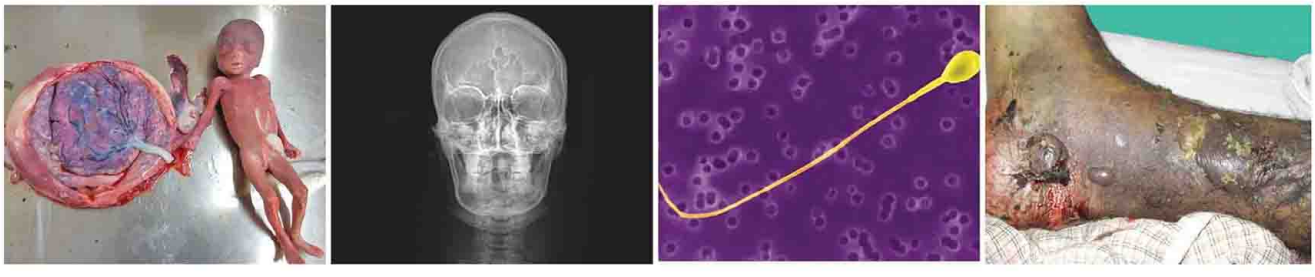

K Tamilmani

Forewords
A Edwin Joe
P Sampath Kumar
CB Jani
M Poovathi

diginerve®
A Jaypee Initiative
• Video Lectures • Dr. Wise AI Chatbot
• Question Bank • Notes
Download App

JAYPEE

Contents

Chapter 1: Age Estimation by Dentition and Physical Examination 1

- Tooth Development *1*
- Race from Teeth *1*
- Based on Development and Eruption, the Permanent Teeth are Two Types *2*
- Estimation of Age from Teeth Beyond 25 Years *5*
- Dental Numbering Systems *5*
- Color Changes in Teeth *5*
- Tooth Eruption Facts *5*
- Estimation of Age by Physical Examination *6*

Chapter 2: Age Estimation by Radiograph 9

- Ossification Centers *9*
- X-Rays *10*
- Appearance and Fusion of Ossification Centers of Bones *10*
- Stages of Skull Sutures *13*
- Age Determination from Pubic Symphysis *15*
- Radiological Examination *16*

Chapter 3: Examination of Skeletal Remains 21

- Introduction to Skeletal Remains *21*
- Handling and Examination of Skeletal Remains *21*
- Identification of Bones *21*
- Determination of Sex *21*
- Identification of Individuals *22*
- Estimation of Number of Individuals *22*
- Ossification Process of Bone and Anatomical Knowledge *22*
- Bone or Not? *22*
- Estimation of Age at Death *31*
- Determination of Race *32*
- Estimation of Stature *34*
- Nature of Injury *34*
- Time Since Death *34*
- Estimation of Age by Pubic Symphysis (Todd's Method) *35*

Chapter 4: Examination of a Case of Drunkenness 38

- Definition of Drunkenness *38*
- Medical Terminology *38*
- Phases of Alcohol Intoxication *38*
- Factors Affecting the Alcohol Absorption *39*
- Laboratory Investigations *39*
- Medicolegal and Legal Aspects of Drunkenness *40*
- Scheme of Examination for Certification of Drunkenness (British Medical Association) *41*
- Alcohol and its Properties *43*
- Certificate of Drunkenness *44*

Chapter 5: Examination of Wounds and Methods of Issuing Wound Certificate 47

- General Principles of Wound Examination *47*
- Description of Wounds *47*
- Classification of Wounds Based on Severity *48*
- Types of Wounds *49*
- Age Determination of Wounds *53*
- Medical Definition *54*
- Skull Injuries and Fractures *55*
- Examination of the Weapon Used *55*
- Legal Aspects of Wounds and Relevant Laws *56*
- Homicide *56*

Chapter 6: Examination of Sexual Offence Cases 58

- Rape *58*
- Punishment: Section 64 BNS *59*
- Sexual Offence and Medical Terminology *59*
- Natural Variants of Human Sexuality *59*
- Examination of the Rape Victim *60*
- Provisional Opinion *64*
- Final Opinion to be Formulated after Receiving Reports from the Forensic Science Lab (FSL) *66*
- Treatment Guidelines and Psychosocial Support *66*
- Examination of the Accused *67*

- Local Examination of Genitalia *69*
- Hymen *71*
- Signs of Virginity *72*
- Pseudocyesis *73*
- Acquaintance Rape *73*
- Indecent Assault *74*
- Sodomy *74*
- Examination of the Passive Agent *74*
- Findings in Passive Agent *74*
- Sexual Perversions *75*
- Hymenal Rupture/Tear *77*
- The Protection of Children From Sexual Offences Act—*2012* *77*
- The Criminal Law Act—*2013* *77*
- Examination of Case of Sexual Offences 78
- Physical Examination *78*
- Examination of Case of Sexual Offences *80*
- Physical Examination *80*

Chapter 7: Examination of Fetus 82

- Definitions and Key Terms *82*
- Live Birth, Still Birth and Signs of Life or Death in the Fetus *82*
- Examination of Fetus *84*
- Ossification Centers *84*
- Methods of Determination of Fetal Age *84*
- Fetal Growth by Lunar Months *86*
- Final Opinion Format *88*

Chapter 8: Viscera Packing.....92

- Viscera and Body Fluids to be Preserved *92*
- Preservatives *92*
- Mode of Preservation of Viscera *93*
- Reasons for Failure in Detection of Poison in Viscera *94*
- Final Opinion *94*
- Discussion *94*
- Interpretation of Toxicology Report *94*
- Putrefaction and its Effect on Chemical Analysis *94*
- Collection and Preservation of Samples for DNA Examination *94*

Chapter 9: Medicolegal Postmortem Examination 96

- Standard Procedures in Medicolegal Postmortem Examination *96*
- Laboratory Procedure *97*
- Instructions for Conducting Autopsy and Writing a Postmortem Report *97*
- Standard Reference Values in Postmortem Examination *98*
- Autopsy Procedure *99*
- Arterial Air Embolism *99*
- Technique of Removing Organs *100*
- Decomposition *100*

Chapter 10: Stature Estimation 107

- Factors Affecting Stature *107*
- Stature Estimation from Body Parts *107*
- Stature Estimation from Long Bones *107*
- Formulas Used for Stature Estimation *108*

Chapter 11: Medicolegal Importance of Age 110

- Legal Aspects of Age *110*
- Medicolegal Importance of Various Age Groups *111*

Chapter 12: Forensic Clinical Examination.....113

- Forensic Psychiatric Clinical Case Examination *113*
- History Taking *113*
- Case Examination *114*
- Examination in Poisoning Cases *115*

Chapter 13: Guidelines for Medicolegal Cases and Postmortem Examination 119

- Pre-autopsy Protocols *119*
- Autopsy/Postmortem Examination Guidelines *119*
- Medicolegal Cases *138*
- Director of Medical Education (DME) Guidelines *139*
- Role-Specific Guidelines *139*

Chapter 14: Firearm Injuries and Forensic Ballistics 142

- Ballistics *142*
- Rifling *142*
- Rifiling in Firearm *142*
- Tests for Detection of Firearm Residues *146*
- Crime Bullet *146*
- Class Characteristics or Primary Markings *146*
- Secondary Markings or Individual or Accidental Characteristics *146*
- Wounds from Firearms *146*
- Shooting Ranges and Associated Effects *146*
- Bullets *146*
- Blast Injuries *147*

Chapter 15: Objective Structured Practical Examination in Forensic Medicine 148

- OSPE Stations *148*
- Bed Side Color Test *153*

Chapter 16: Model Spotters.....155

- Weapons *155*
- Specimens *159*
- Identification Marks *162*
- Fetal Specimens *162*
- Skull Bone Injuries *163*
- Firearms and Ballistics *164*

Toxicology Spotters 165

- Poisoning and their Specific Antidotes *165*
- Treatment of Overdose *165*
- Chelating Agents in Heavy Metal Poisoning *165*
- Some Important Poisons *166*
- Characteristic Features of Some Poisonings *166*
- Key Toxicological Facts and Street Names of Commonly Abused Substances *166*
- Alcohol *166*
- Animal Irritants *167*
- Cardiac Poisons *171*
- Vegetable Organic Irritants *174*
- Spinal Poisons *177*
- Deliriant Poisons *178*
- Agricultural Poisons *181*
- Metallic Poisons *181*
- CNS Depressants *187*
- Asphyxiants and Others *189*
- Additional Poisons *192*
- Instruments and Special Spotters *194*
- Histopathological Slides *194*

Chapter 17: Model Exercises.....199

Age and Sex Estimation from Bones 199

- Examination from Skull *199*
- Examination from Mandible *201*
- Examination from Pelvis *202*
- Examination from Sacrum *203*
- Examination from Femur *204*

Radiological Age Estimation (Joint-Wise) 205

- Shoulder Joint *205*
- Elbow Joint *206*
- Wrist Joint *207*
- Hip Joint *208*
- Knee Joint *209*
- Ankle Joint *210*

Age Estimation 211

Model Certificates 213

- Age Certificate *213*
- Wound Certificate *215*

Examination of Drunkenness 216

- Physical Examination *217*
- Certificate of Drunkenness *219*
- Sexual Offence Certificate (Victim) *220*
- Potency Certificate *221*
- Viscera Forwarding Report *222*

Medical Certificate of Cause of Death 227

Stature Estimation from Various Methods 228

- From Diaphyseal Length of Fetal Long Bone *228*

Chapter 18: Standard Proformas in Forensic Medicine.....230

Identity, Consent, and General Examination Proformas 230

- Age Estimation (General) *230*

Age Certificate 232

Age Certificate for Athletic Candidate 233

Age Estimation Format 234

- Injury and Assault Proformas *236*
- Wound Certificate *237*
- Proforma for Health Screening of Prisoners on Admission to Prison *238*
- Instructions for the Recording of Marks, Scars and Other Means of Identifying Individuals (See 211 of Tamil Nadu Prison Rules) *239*
- Form A Information to Police Assent/Dissent (Medical Termination of Pregnancy in a Survivor) *240*
- Form B Communication Made to Police Regarding Medical Termination of Pregnancy without Providing any Identification of the Girl (Victim) *241*
- Consent Form: Medical Termination of Pregnancy—Form C (MTP Rules, Rule 8) *242*
- Consent Form: Medical Termination of Pregnancy—Form C (Rule 8) *243*
- Form I (MTP Rules, Regulation 3) *244*
- Form F: Form for Maintenance of Record in Case of Prenatal Diagnostic Test/Procedure by Genetic Clinic/Ultrasound Clinic/Imaging Center—(Proviso to Section 4(3), Rule 9(4) and Rule 10(1a) of PCPNDT Act) *245*
- Form G (See Rule 10): Form of Consent (for Invasive Techniques) *249*
- Certificate of Production of Electronic Evidence Part A (to be Filled by the Party) *250*

- Model Postmortem Report Form as per NHRC Guideline (Death in Police Custody/During Police Action/Jail) *251*
- Appendix – 'A': Instructions to be Followed Carefully for Detention of Torture *256*
- Weapon Examination Report *257*
- Certificate of Drunkenness *258*
- Intimation of Accidents and Injuries to Police *259*
- Death Intimation to Police *260*
- Sexual Offence Proformas *261*
- Instructions for Doctors in Sexual Offence Cases Examination *261*
- Examination of Accused in Sexual Violence *263*
- Examination of Sexual Offence Survivor *268*
- Certificate of Sexual Assault–Accused Person Examination *275*
- Certificate of Sexual Assault–Victim/Survivor Examination *276*
- Checklist of Steps of Medicolegal Examination in Sexual Assault Cases *277*
- Office of the Police Surgeon and Department of Forensic Medicine *278*
- Medical Examination for Age Estimation *279*
- Death and Postmortem Proformas *281*
- Postmortem Certificate *283*
- Furnishing Final Opinion on the Cause of Death *284*
- Letter to Tahsildar Regarding Viscera Forwarding *285*
- Letter to RFSL Deputy Director *286*
- Form to Report Postmortem Examinations, to be Used When Forwarding Viscera to the Chemical Examiner *287*
- Forensic Medicine Department *290*
- Fitness Certificate for Employment *291*
- Proforma for Recording Dying Declaration by a Medical Practitioner *292*
- Toxicological and DNA-Related Proformas *293*
- Letter to State Forensic Laboratory for DNA Analysis *293*
- Letter to Regional Forensic Laboratory for Diatoms Examination *294*
- Organ Transplant and Brain Death Certification *295*
- Medical Certification Proformas *303*
- Medical Certificate for Leave or Extension or Commutation *303*
- Certificate of Fitness to Resume Duty *304*
- Identification Form for DNA Profiling *305*

Appendix: Highlights of New Criminal Laws—2023.....307

- Highlights of New Criminal Laws—2023 *307*
- Tabular Comparison of New Clauses of Bharatiya Nyaya Sanhita (BNS) and Indian Penal Code (IPC) *309*
- Tabular Comparison of Bharatiya Sakhshya Adhiniyam (BSA) and Indian Evidence Act (IEA) *312*
- Tabular Comparison of New Clauses of Criminal Procedure Code (CrPC) and Bharatiya Nagarik Suraksha Sanhita (BNSS) *314*

Index *319*

CHAPTER

3

Examination of Skeletal Remains

JAYPEE BROTHERS

COMPETENCY

FM14.8: Demonstrate examination of and present an opinion after examination of skeletal remains in a simulated/supervised environment.

INTRODUCTION TO SKELETAL REMAINS

Bones are usually found in crematorium; unusually disposed in a jungle, in the open, in the ditch, etc. or in case of mass disasters where many persons die in the same area, at the same time from fire accidents, air crashes or so.

HANDLING AND EXAMINATION OF SKELETAL REMAINS

Bones should be arranged in anatomical skeletal chart and photographed. Skeletal remains should be first examined in the condition in which, it was found, along with whatever soft tissues and earth present. Sand, dust or earth present on the bone are removed with brushes, wooden picks and scrapes. Application of acetone may remove dirt. Note the attachment of soft tissue to bones, if any and its stage of putrefaction.

Note whether the bones are moist and humid or dry and its smell. Bones are then washed and brushed with lukewarm water and are dried slowly, if soft tissues are attached. It can be boiled in water for five to six hours in case of bones of young individuals, and for twelve hours or more in case of adult bones. Or else it can be immersed in dilute aqueous solution of trisodium phosphate and household detergent. With this, the soft parts including tendon attachment and the periosteum can be stripped of easily with an ordinary scrubbing brush.

IDENTIFICATION OF BONES

Human or Animal

The knowledge of human as well as comparative anatomy is needed to find out whether a particular bone belongs to human or not. It is easy when whole skeleton or entire bones are available. If the bone is fairly fresh and some of the blood constituents are still present, the precipitin test is useful. Anatomically, Globular skull (erect posture) with true forehead, foramen magnum at base of the skull, supraorbital ridges rather than crests suggests human origin. Primary and secondary dentition is unique for mammals. Dental formula is unique to humans. Microscopic examination (Haversian system) and chemical analysis of bone ash for inorganic constituents can also be done.

DETERMINATION OF SEX

Identification of sex comes first before age. It is because of the fact that if sex is identified, nearly half of the population can be ruled out and sex specific age and stature correction can be done accordingly. Recognizable sex differences do not appear until after puberty except in the pelvis and the accuracy is about 75–80%. Determination of sex is based mainly upon the appearance of pelvis, skull, long bones and others. Radiological thinning of the cortex and progressive rarefactions of apex of medullary cavity of head of humerus and femur are helpful. According to Krogman, the degree of accuracy in determining the sex of adult skeletal remains is mentioned in **Table 3.1**.

- ❖ Best bone for determination of sex is pelvis.
- ❖ Greater sciatic notch in the pelvis is the ideal feature to determine sex of female child.
- ❖ Corporobasal index is more in males.

Table 3.1: Krogman's table.

• Entire skeleton	100%
• Pelvis alone	95%
• Skull alone	90%
• Pelvis plus skull	98%
• Long bone alone	80%
• Long bone + pelvis	98%

IDENTIFICATION OF INDIVIDUALS

Identification may be established from teeth, disease, deformity of the bone, old healed or healing fractures, orthopedic surgical procedure, regional atrophy, spinal deformity, flat foot, supernumerary ribs, etc., and by super imposition technique using the skull. If the pre-existing X-rays are available it may be possible to make positive identification on the basis of contours and cancellous patterns of various bone.

If blood stains/red bone marrow are available, it is possible to identify the ABO group of skeletal material. Also DNA finger printing is rapidly becoming the primary method for identifying and distinguishing individual human beings. DNA finger print technique is capable of distinguishing every individual with the exception of identical twins. Other methods are X–ray comparison of trabecular patterns and neutron activation analysis to distinguish the relative mineral content.

ESTIMATION OF NUMBER OF INDIVIDUALS

Whether the bone belongs to one individual or not can be determined by reconstructing the skeleton. If there is no disproportion in size of various bones or reduplication, if the articulation is correct and if the age, sex and race of all the bones are same, it belongs to one individual.

Visual pair matching, articulation, and measurements are means of segregating bones. If mixture of bones from more than one skeleton is suspected, it can be segregated by the use of a short wave ultraviolet lamp. When surface of bones are exposed to ultraviolet radiation, it reflects variety of colors. The radiated color is the fluorescence of organic elements in the bone, inorganic substances on the surface of bones and to a lesser extent reflected light. Bones from different persons can be segregated by color emissions.

OSSIFICATION PROCESS OF BONE AND ANATOMICAL KNOWLEDGE (TABLE 3.2)

Table 3.2: Ossification process of bone formation.

Primary	*Secondary*
Diaphysis	Epiphysis
Single/multiple	Multiple
Appear simultaneously	Do not appear simultaneously
Appear before birth	Appear after birth
Exception	
Cuneiform navicular	Lower end of tibia, upper end of fibula

BONE OR NOT?

It is bone:

- ❖ Based on anatomical knowledge
- ❖ Evidence of muscles, ligaments, tendons attaches with evidence of changes after death
- ❖ On cross-section evidence of bone marrow
- ❖ Biochemical analysis for organic and inorganic constituents.
- ❖ Histology of the material.

Sex Differentiating Features in Bones (Table 3.3)

Table 3.3: Sex differentiating features in bones.

Features	*Male*	*Female*
Skull (Figs. 3.1A to F)		
Size	Large intracranial capacity 1500–1550 cc	Smaller intracranial capacity 1350–1400 cc
General appearance	Large, heavier, rugged, more marked muscular ridges	Smaller, lighter, smoother and less marked muscular impressions
Glabella	Less prominent	More prominent
Supraorbital ridge	More prominent	Less prominent
Frontonasal junction (Nasion)	Distinct angulation	Smoothly curved
Frontal eminence	Less prominent	More prominent
Parietal eminence	Less prominent	More prominent

Contd...

JAYPEE BROTHERS

Contd...

Features	*Male*	*Female*
Forehead	Steep and rather flat	Roundish, infantile
Orbit	Lower, relatively smaller, roundish margin, square shaped	Higher, relatively larger sharp margin, round in shape
Zygomatic arch	More pronounced	Less pronounced
Molar prominence	More prominent and laterally curved	Less prominent and laterally compressed
Nasal aperture	Higher and narrower	Lower and broader
Parietal eminence	Less	More
Frontal sinuses	More developed	Less developed
Palate	Larger 'U' shaped	Smaller, parabolic
Teeth	Larger	Smaller
Base	Sites of muscular insertion more marked	Less marked
Digastric groove	Deep	Shallow
Condylar facet	Long and narrow	Short and broad
Foramina	Larger	Smaller
Foremen magnum	Relatively large and long	Relatively small and round
Occipital protuberance	More prominent	Less prominent
Mandible (Fig. 3.2)		
Weight and surface	Heavier, surface rough with prominent sites of muscular attachment	Lighter with smooth surface
General appearance and size	Larger, thicker	Smaller, thinner
Anatomical angle	Everted	Inverted
Chin (symphysis menti)	Square shaped	Rounded
Shape of bone	'V' shaped	'U' Shaped
Mental tubercle	Large, prominent	Insignificant
Mylohyoid line	Prominent and deep	Less prominent, shallow
Height at symphysis menti	More	Less
Ascending ramus	Broader	Narrower
Teeth	Larger	Smaller
Condylar facets	Larger	Smaller
Hip Bone (Figs. 3.3A to I)		
General features	Heavy, surface rough with prominent sites of muscular attachment	Light with smooth surface
Ilium	High, vertical in anatomical position, anterior surface deep	Low, laterally divergent, anterior surface shallow
Obturator foramen	Large and oval	Small and triangular
Greater sciatic notch	Narrow and deep	Broad and shallow

Contd...

JAYPEE BROTHERS

Contd...

Features	*Male*	*Female*
Preauricular sulcus (attachment of anterior sacroiliac ligament, lying just lateral to sacroiliac joint)	Infrequent, when present it is narrow and shallow	Frequently present broad and deep
Obturator foramen	Large, oval	Small and triangular
Iliopectineal line	Well marked and rough	Rounded and smooth
Acetabulum	Shape more than 2/3rd of hollow sphere, directed laterally	Shape less than 2/3rd of hollow sphere, directed anterolaterally
Ischial tuberosity	Inverted	Everted
Ischiopubic rami	Slightly everted	More everted
Shape of pubis	Triangular	Square
Pubic symphysis	Higher	Lower
Sacrum (Fig. 3.4)		
General features	Larger, heavier and rough	Smaller, lighter, smoother
Breadth of the body of 1st sacral vertebrae	More than the breadth of one side ala	Less than the breadth of one side ala
Sacral promontory	More projected ventrally	Less prominent and less projected ventrally
Inner curvature	Uniformly curved anteriorly	Abruptly curved at the last two segments
No. of sacral vertebrae	May be 5 or 6	Always 5
Sacroiliac articulation	Extends up to 3rd segment	Extends up to 2½–3rd segment
Deepest point of inner curvature in anatomical position	Higher	Lower
Coccyx	Less movable	More movable
Femur (Figs. 3.5A, D, E)		
Head	Articular surface is more than 2/3 of sphere	Articular surface is less than 2/3rd of a sphere
Neck shaft angle	Obtuse angle with shaft about 125°	Less obtuse angle with shaft
Inward inclination of the shaft at lower end	Less	More
Vertical diameter of head	About 4–5 cm	About 4.15 cm
Trochanteric oblique length	About 45 cm	About 39 cm
Popliteal line	About 14 cm	About 10 cm
Bicondylar width	About 7.5 cm	About 7 cm
General features	Heavier, rough with prominent sites of muscular attachment	Light with smooth surface
Articulated Pelvis (Figs. 3.6A to D)		
Pelvic brim	Heart shaped	Circular
True pelvis	More spacious	Less spacious

Contd...

JAYPEE BROTHERS

Contd...

Features	*Male*	*Female*
Subpubic angle	Acute 'V' shaped 70°–75°	Obtuse 'U' shaped 90°–100°
Pelvic cavity	Conical, funnel shaped	Broad, round
Pelvic outlet	Smaller	Larger
Sacroiliac articulation	Large, extends to 2½–3 vertebrae	Small, extends to 2–2½ vertebrae
Distance between two anterior superior iliac spine	Less	More
Distance between highest points of iliac crests of two sides	Less	More
Thorax		
General features	Longer, narrower	Shorter, wider
Sternum	Body longer and more than twice the length of the manubrium. Upper margin is in level with lower part of the body of second thoracic vertebrae Length >breadth. Length >14 cm	Shorter and less than twice the length of the manubrium, upper margin in level with lower part of third thoracic vertebrae. Breadth >length. Length <14 cm
Ribs	Thick, less curved, and are less oblique	Thinner, greater curved, more oblique
Clavicle	Longer, broader, heavier, less curved	Smaller, narrower lighter, more curved
Tibia		
Length	>31 cm	<31 cm
Muscle marking	More prominent	Less prominent
Scapula		
Glenoid cavity diameter	>3.5 cm	<3.5 cm
Vertebrae		
Total length	>70 cm	<60 cm
Breadth of atlas	>8 cm	<7.5 cm

JAYPEE BROTHERS

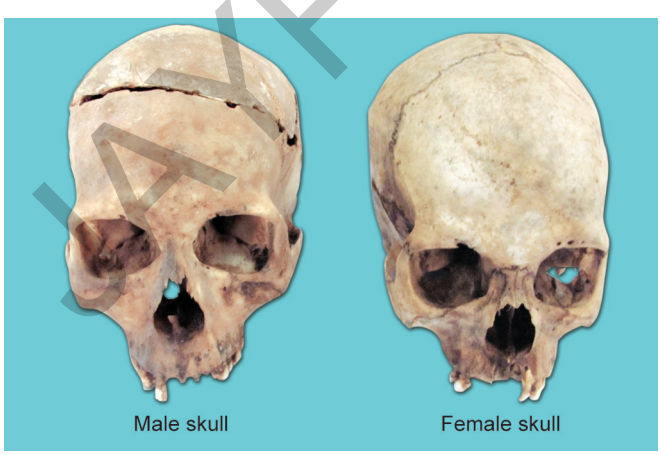

Fig. 3.1A: Male and female skull features in anterior view.

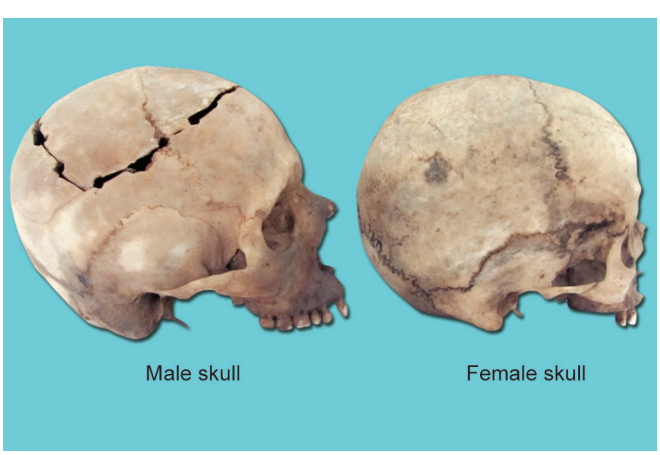

Fig. 3.1B: Male and female skull features in lateral view.

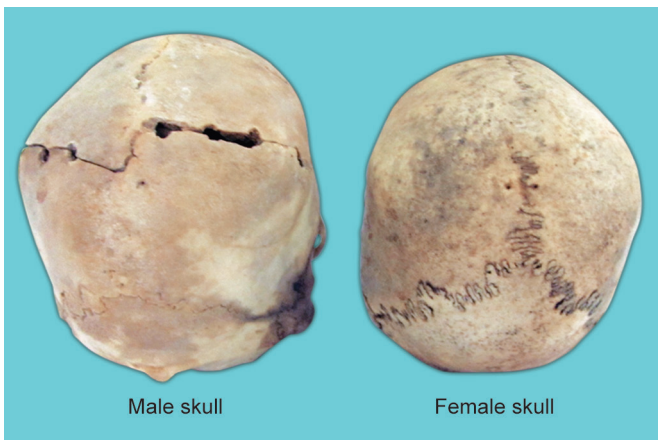

Fig. 3.1C: Male and female skull features in posterior view.



Fig. 3.1D: Male and female skull features in basal view.

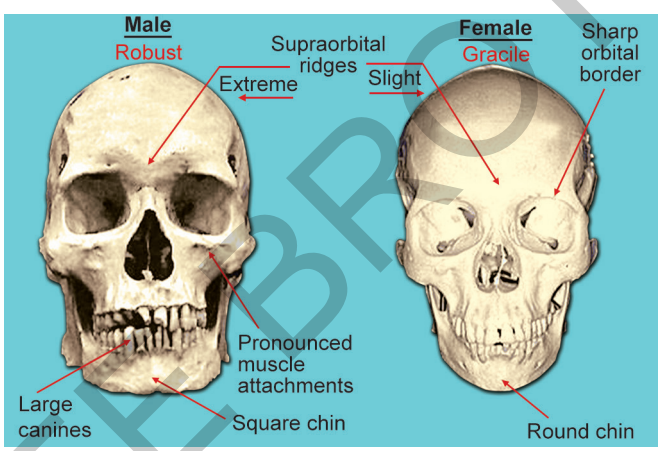

Fig. 3.1E: Male and female skull features in anterior view.

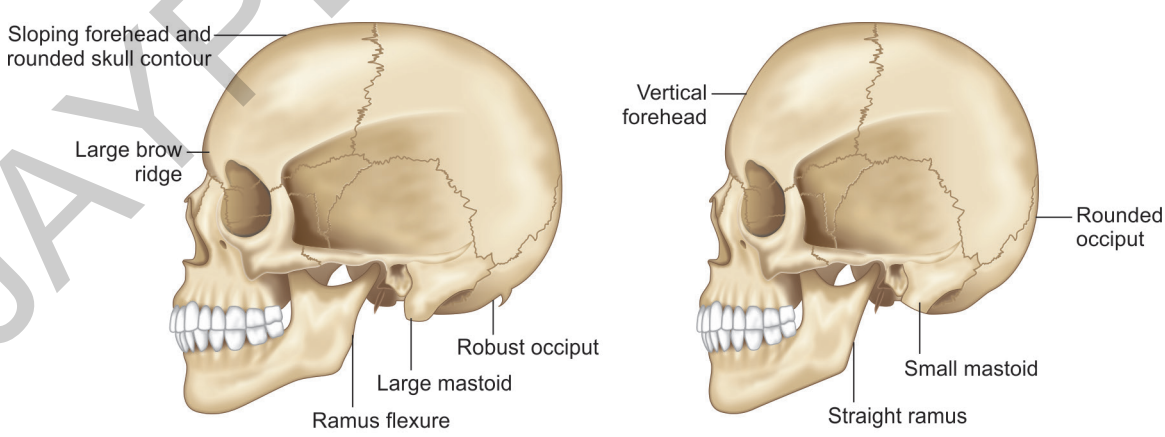

Fig. 3.1F: Male and female skull features in lateral view.

Figs. 3.1A to F: Sex differentiating features in skull.

JAYPEE BROTHERS

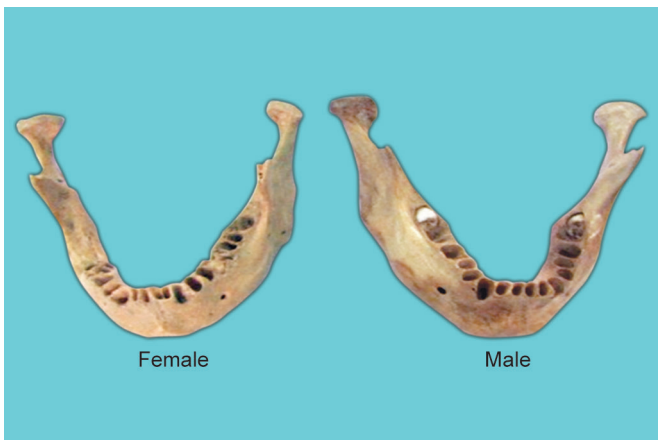

Fig. 3.2: Sex differentiating features in mandible.



Fig. 3.3A: Female hip bone shows—small contour, ilium is low, anterior surface is shallow, ischial tuberosity is evereted, body of pubis is square-shaped.



Fig. 3.3B: Female hip bone shows—small contour, ilium is low, anterior surface is shallow, ischial tuberosity is everted, body of pubis is square-shaped. Obturator foramen is small and triangular.

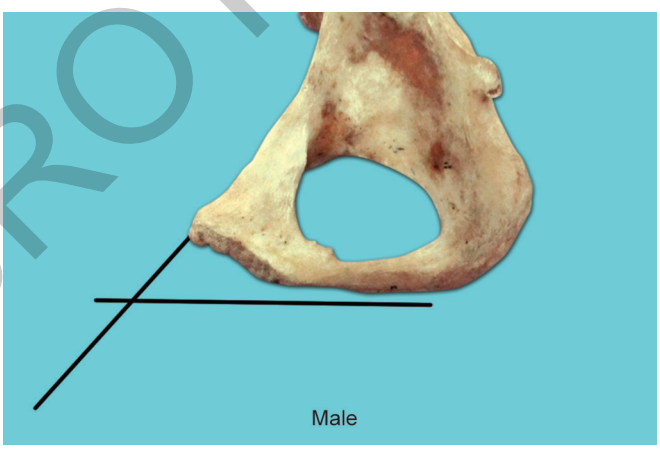

Fig. 3.3C: Male hip bone—body of pubis is triangular and depth of symphysis is more.

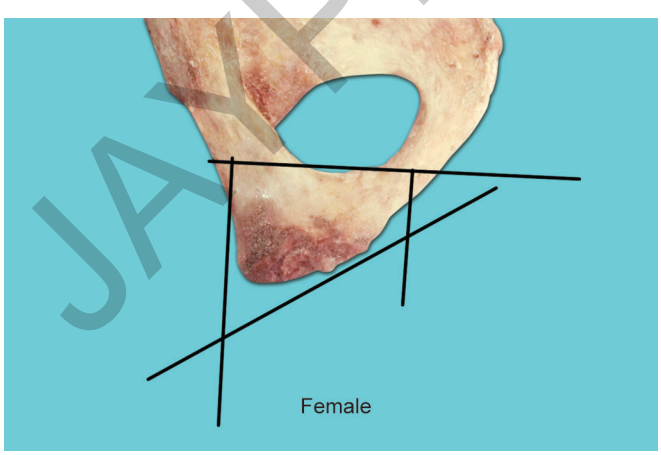

Fig. 3.3D: Female hip bone—body of pubis is square-shape and depth of symphysis is less.

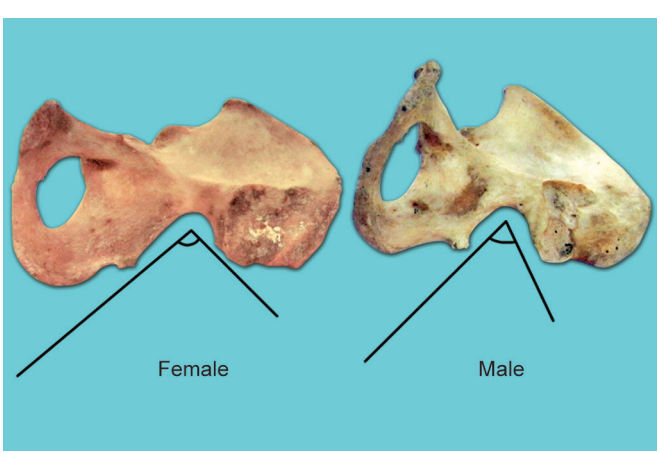

Fig. 3.3E: Greater sciatic notch—male is narrow and deep; female is broad and shallow.

JAYPEE BROTHERS

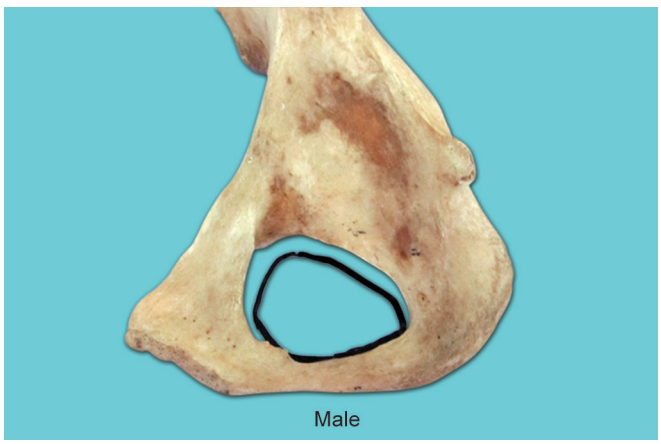

Fig. 3.3F: Obturator foramen for male is large and oval.



Fig. 3.3G: Obturator foramen for male is large and oval for female is small and triangular.

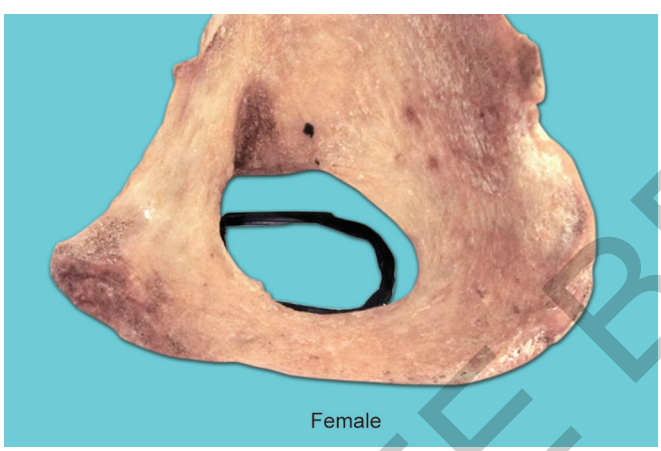

Fig. 3.3H: Obturator foramen for female is small and triangular.



Fig. 3.3I: Hip bone: Male—obturator foramen is large and oval, acetabulum is more than 2/3rd of sphere large and directed laterally, Female—obturator foramen is small triangular acetabulum is <2/3rd of sphere small and directed anterolaterally.

Figs. 3.3A to I: Sex differentiating features in hip bone.

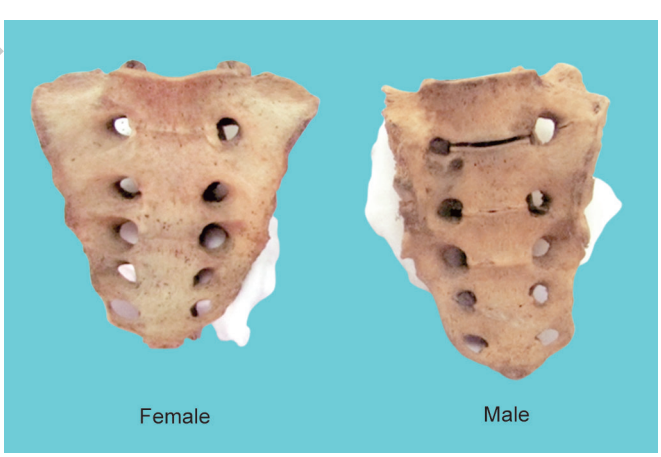

Fig. 3.4: Male sacrum: It is long and narrow with evenly distributed anterior curvature. Body of 1st sacral vertebrae is large and sacral promontory is well-defined, coccyx is less movable. Female sacrum: It is shorter and wider with anterior curvature more or less straight up to the center of the 3rd segment, then curves abruptly forward, coccyx is more movable.

JAYPEE BROTHERS

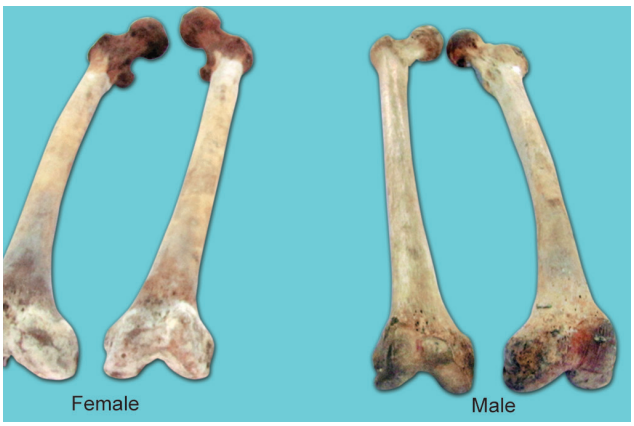

Fig. 3.5A: Femur bone: For male—articular surface is >2/3rd of sphere, massive, heavy, and muscle attachments are well-marked. For female—articular surface is <2/3rd of a sphere, lighter, and impressions for muscle attachments are less prominent.



Fig. 3.5B: Features of humerus: Male—heavy and impressions of muscular attachment are prominent, average length is 32.5 cm, vertical diameter of head is 48.7 mm and transverse diameter of head is 44.6 mm. Female—lighter and impression marks are less, average length is 30 cm, vertical diameter of head is 41.5 mm, and transverse diameter is 38.9 mm.



Fig. 3.5C: Features of ulna: Male—heavy and broad with impression for muscular marking are more prominent. Female—light and narrow with impression for muscular marking are less prominent.

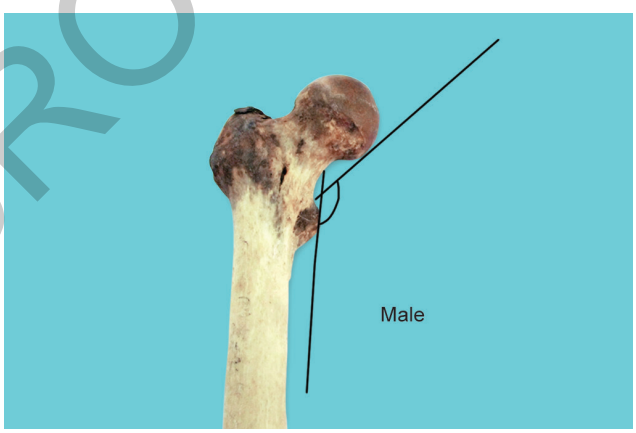

Fig. 3.5D: Femur bone male: Neck shaft angle; obtuse angle with shaft about 125°.

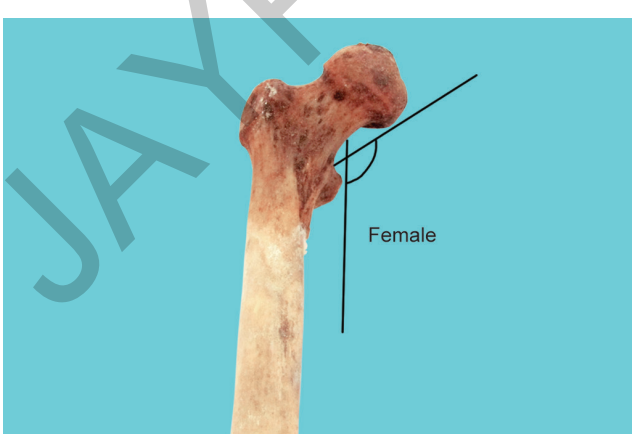

Fig. 3.5E: Femur bone: Female—neck shaft angle; less obtuse angle with shaft.

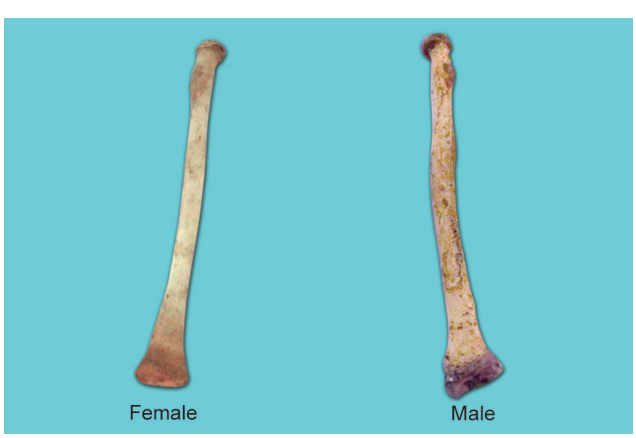

Fig. 3.5F: Features of radius bone: Male—heavy and broad with impression for muscular marking are more prominent. Female—light and narrow with impression for muscular marking are less prominent.

Figs. 3.5A to F: Sex differentiating features in femur, humerus and radius, ulna.

JAYPEE BROTHERS

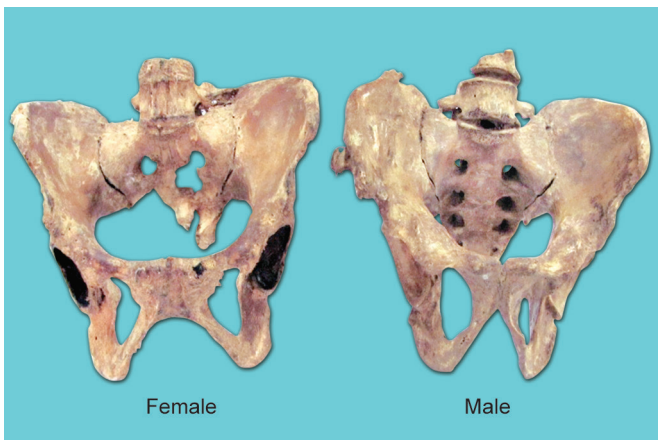

Fig. 3.6A: Male and female pelvis—anterior view.

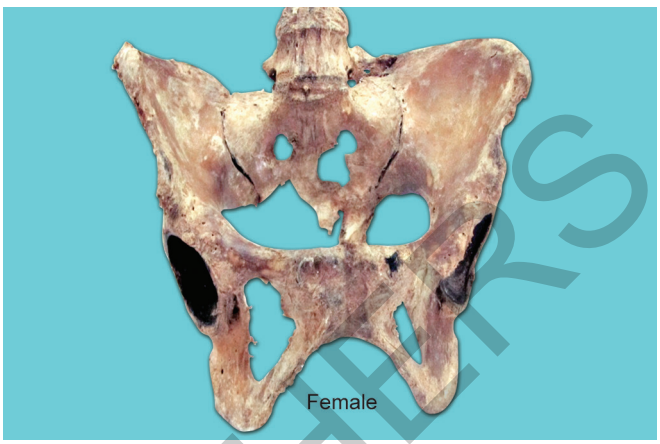

Fig. 3.6B: Female pelvis: The pelvis is wide, shallow, the brim is circular the outlet is broad and round, ilium is more expanded the sloping is more gradual and the posterior border is rounded. Anterior superior iliac spines is are widely separated, symphysis pubis is smaller and shorter the dorsal border is irregular due to childbirth. Subpubic angle is U-shaped, >90°.

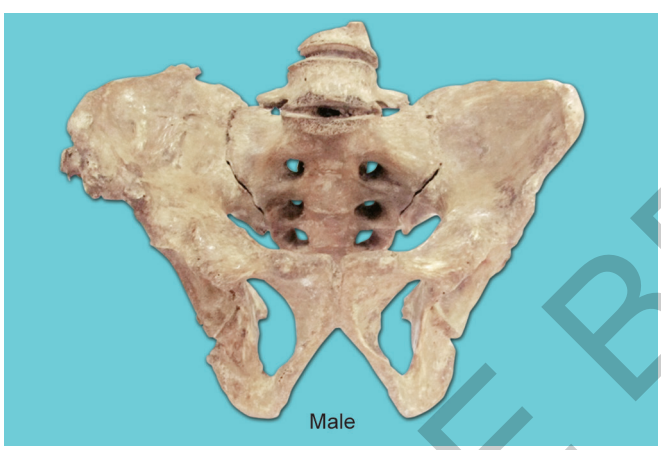

Fig. 3.6C: Male pelvis: The pelvis is deep and funnel-shaped, the brim is heart-shaped, outlet is small, ilium is less expanded sloping is abrupt, and posterior border is rough. Anterior superior iliac spine is closer. Symphysis pubis is longer and narrower, but the dorsal border is rounded, body of pubis is narrower and triangular. Subpubic angle is <90° and V-shaped. Preauricular sulcus is not prominent.

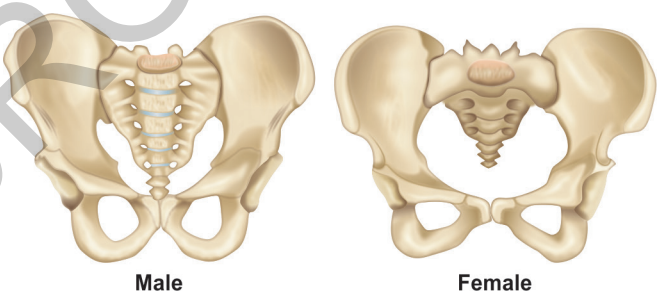

Fig. 3.6D: Features of male and female pelvis.

Figs. 3.6A to D: Sex differentiating features in pelvis.

Diagnostic Indices for Determination of Sex (Table 3.4)

Table 3.4: Diagnostic indices for determination of sex.

Index	*Formula*	*Male in CM*	*Female in CM*
Sternal index	$\frac{\text{Length of manubrium}}{\text{Length of body}} \times 100$	46.2	54.3
Ischiopubic index or wash burn index	$\frac{\text{Length of pubis}}{\text{Length of ischium}} \times 100$	73–94	91–115
Corporobasal index	$\frac{\text{Breadth of body of 1st sacral vertebrae}}{\text{Transverse diameter of base of sacrum}} \times 100$	>42	>42
Sacral index	$\frac{\text{Transverse diameter}}{\text{Anterior length of sacrum}} \times 100$	<114	<114

Contd...

JAYPEE BROTHERS

Contd...

Index	*Formula*	*Male in CM*	*Female in CM*
Sciatic notch index	$\frac{\text{Width of sciatic notch}}{\text{Depth of sciatic notch}} \times 100$	4–5	5–6
Kimura's base wing index	$\frac{\text{Width of wing (ala of sacrum)}}{\text{Width of base (transverse diameter of body of s1)}}$		
Chilotic line indices	$\frac{\text{Sacral part of chilotic line}}{\text{Pelvic part of chilotic line}}$ For male—sacral part of chiliotic line more prominent For female—pelvis part of chiliotic line is more prominent		
Medullary index	Long bone can be used for determination of sex $\text{MI} = \frac{\text{Diameter of medulla}}{\text{Diameter of whole bone}} \times 100$		
Alar index	$= \frac{\text{Length of ALA}}{\text{Transverse diameter of the first sacral vertibrae (TDS 1)}} \times 100$		
• Sternal index and Ashley's rule • [Mnemonic: I AM SACSY]	Ashley's rule states that sternal length is >149 mm in males and <149 mm in females		

ESTIMATION OF AGE AT DEATH (FIGS. 3.7 TO 3.12)

It can be determined from examination of teeth, ossification centers, and amount of wear and tear in teeth, epiphyseal union, meta-morphosis of pubic symphysis, closure of skull sutures (Refer Chapters 1 and 2: Age by X-ray and dental examination), cortical resorption, bony lipping, osteoporotic changes, calcification, osteoarthritis changes, etc. After 25 years, age cannot be stated in exact number of years.

In mandible, mental foramen is near the lower border in infancy, middle in adult, near the alveolar margin in elderly (bone resorption); angle between ramus and alveolar margin is obtuse in extremes of age, acute in adult.

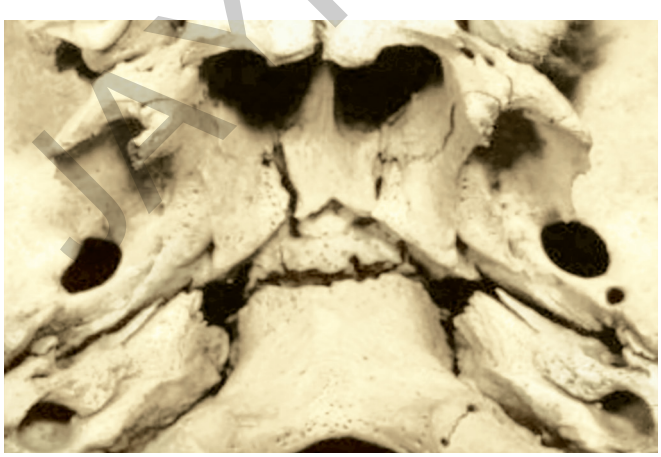

Fig. 3.7: Basiocciput and basisphenoid not fused age <21 years.



Fig. 3.8: Epiphysis line seen in upper end of (humerus shaft not united with head of humerus, so age >5 years and <18 years).

Fetal age can be determined by measuring the length of ossified portions of the long bones. In case of broken bones, rough estimate of the age can be made by measuring the external diameter of the long bones at mid shaft.

General age can also be estimated by resorption patterns in the cortex of the long bones. In infancy, most resorption activity is found in medullary end of the cortex. In childhood, it is scattered throughout the thickness of cortex and during adolescence, it is most marked just under the periosteal surface. In young adulthood, there is very little resorption. During 60 years of age in men and earlier in women, medullary end of the cortex undergoes increasing resorption with thinning of cortex. These changes are described microscopically by quantifying four cortical

JAYPEE BROTHERS

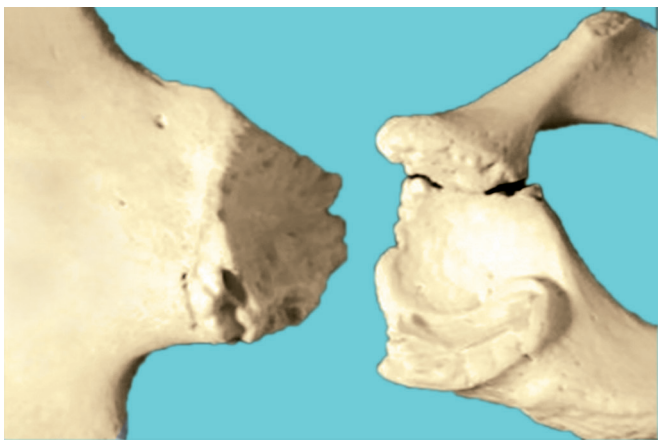

Fig. 3.9: Triradiate cartilage not obliterated less than 15 years.



Fig. 3.10: Ischial tuberosity not fused less than 21 years.



Fig. 3.11: Preauricular sulcus seen female.



Fig. 3.12: Dorsal pitting seen in female.

elements for estimating age, i.e., osteons, osteon fragments, lamellar bone, Haversian canals. With loss of cancellous tissue, the proximal end of medullary cavity of humerus or femur assumes a cone shape, the tips of which gradually ascends and reaches the surgical neck between 41 and 50 years and the epiphyseal lines between 61 to 74 years. With advancing age there is gradual fatty replacement of bone marrow.

DETERMINATION OF RACE

Skull

Cephalic index is useful for identifying race in skull. Skull can be classified into three types based up on cephalic index (CI): **(1) Dolichocephalic, (2) brachycephalic, and (3) mesaticephalic (Table 3.5 and Fig. 3.13)**. Indian skull is Caucasian with few negroid characters. Skulls of Dravidians are of Negroid characters/dolichocephalic **(Table 3.6)**. The Indices of long bones may also help in identifying race, i.e., brachial index (radiohumeral index), intermembral index, humerofemoral index and the crural index (tibiofemoral index).

$$\text{Cephalic index} = \frac{\text{Breadth of the skull (measured between two parietal eminences)}}{\text{Maximum anteroposterior length of skull (measured between external occipital protuberance and frontonasal junction)}} \times 100$$

Table 3.5: Race determination by using cephalic index.

Type of skull	*Cephalic index*	*Race*
Dolichocephalic (long headed)	70–75	Dravidians, Pure Aryans, Aborigines, Negros
Mesaticephalic (medium headed)	75–80	European and Chinese
Brachycephalic (short headed)	80–85	Pure Mongols

JAYPEE BROTHERS

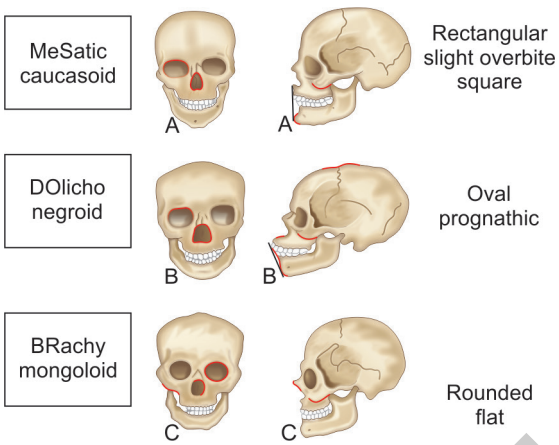

Fig. 3.13: Race identification based on skull.

Table 3.6: Race determination (Fig. 3.14).			
Features	***Caucasian***	***Mongolian***	***Negro***
Skull	Rounded	Square	Narrow and elongated
Forehead	Raised	Inclined	Small and compressed
Face	Small, proportionate	Large and flattened molar bone being prominent	Molar bones and jaws projecting, teeth set obliquely
Orbits	Triangular	Small	Square
Upper extremities	Normal	Small	Long in proportion to body, forearm large in proportion to arms, hands small
Lower extremities	Normal	Small	Legs large in proportion to thighs, feet wide and flat, heel bone projects backwards

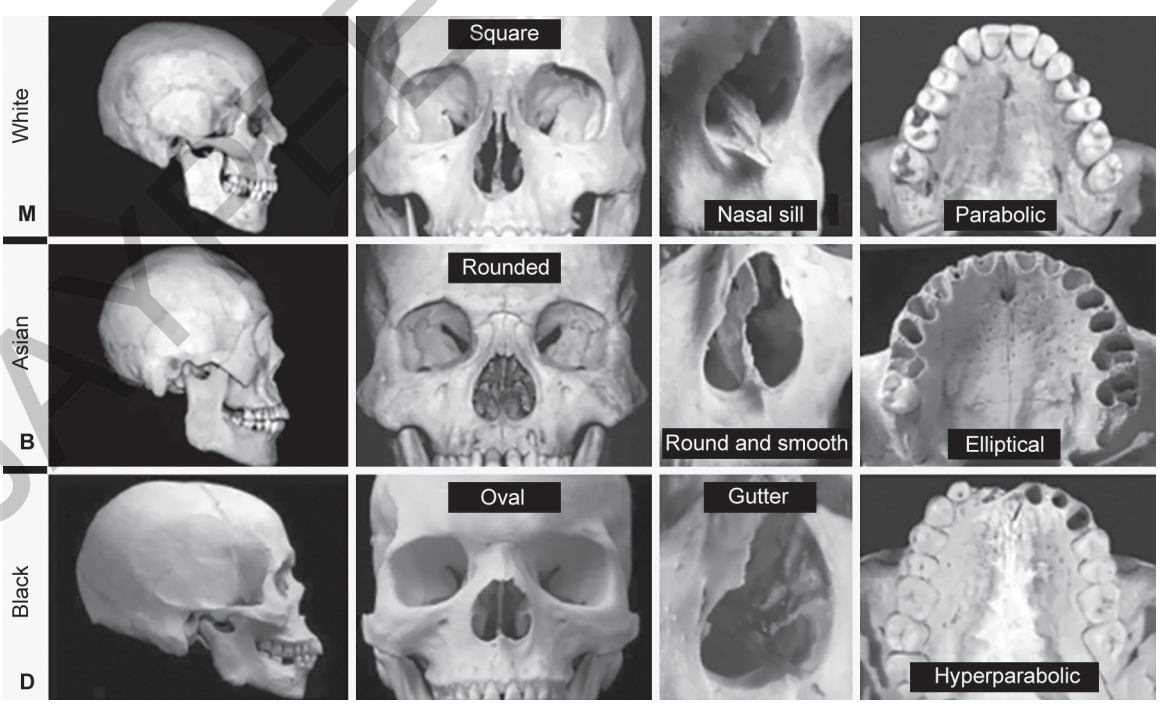

Fig. 3.14: Human skull features of various race.

JAYPEE BROTHERS

Indices Used for Determination of Race

- Cephalic index
- Standard for limb bones length ratio

$$= \frac{\text{Length of radius}}{\text{Length of humerus}} \times 100$$

(Ratio for male 0.77 and female 0.75)

- Crural index $= \frac{\text{Length of tibia}}{\text{Length of femur}} \times 100$
- Humero femoral index $= \frac{\text{Length of humerus}}{\text{Length of femur}} \times 100$
- Intermembral index

$$= \frac{\text{Length of humerus + radius}}{\text{Length of femur + tibia}} \times 100$$

ESTIMATION OF STATURE

A useful rule of thumb is that humerus is 20%, femur is 27%, tibia 22% and distance between symphysis menti to mandibular angle × 16 is individual's height in life. Multiple bones if available, average from each bone is preferred.

NATURE OF INJURY

Ends of long bones should be examined carefully to find out if they have been cut by sharp cutting instruments or sawn or gnawed by animals. Bones discarded after dissection of the body will show some stain in the nutrient canals.

Depending upon degree of heat applied, the bone changes occur; the more heat applied, the more it gets destroyed. Shape of burnt bone is preserved, but it becomes powdered when pressed between the fingers. In a burnt skull, cracking often occurs in circular pattern with sharp edges which have the appearance of cuts.

Whether the bones have been burnt with flesh covering it or in the dried state can be made out from its appearance. This is important to know whether the body was disposed off immediately after death or after the decomposition of the soft parts. Unprotected bone when burnt undergoes charring, cracking and splintering, whereas bones embedded in thick soft tissues show the molten or guttered condition characteristic of fusion by heat. Sometimes when a bone is burnt in open it turns white, whereas it turns black or ash gray when burnt in a closed fire.

TIME SINCE DEATH

Exact time of death cannot be given from examination of the bones. The answer depends upon the circumstances under which bones have been found, e.g., burying and cold weather will delay decomposition. After the soft tissues disappear, remains of cartilage and ligaments remain attached to bone for 3–4 months. Traces of marrow and periosteum may remain attached to the bones for several months. Odor is a good indication of relatively recent death. In buried dead bodies, total skeletonization may take one year. A fairly recent bone is slightly greasy to touch and is heavy due to persistence of collagen and the normal apatite matrix.

After losing the covering tissue and the odor of decay, the bones have appearance of freshness. Repeated freezing, thawing of the bones when buried superficially may cause it to expand and crack within a few years. In old burials, the cancellous bone at the metaphysis and epiphysis may erode away by weathering, ground water seepage. It may leach the normal calcium phosphate out of bone. Nonbiological distributions may deposit excess calcium carbonate which depends upon the ground water. In mineral rich areas, some parts of skeleton are heavily mineralized; whereas in other areas demineralization occurs; both depend upon the soil and ground water. This can be detected by examining histological ground section of long bones or by microradiographs of under calcified ground section of these bones. X-Ray diffraction studies can provide some identification of calcium carbonate in bone. We can estimate the age by using C14 carbon dating for bones more than 5 decades old.

Estimation of Time Since Death (Table 3.7)

Table 3.7: Estimation of time since death by postmortem changes in the body.

Greasy to touch, heavy and odor of bone	Recent bone (1–3 months)
Soft tissue remnant attached to the bones	1–3 months
Skeletonization (exposed)	1–2 months
Joint capsule and ligament attached to the bones	3–5 months
Skeletonization (buried)	2–6 months
Foul smell in bones	6–12 months
Tendons and muscles are absent in bones	>1 year
Bones lose their contour and crumble down to dust	10–15 years
Dry, light, fragile and free from bone marrow	Old bone

Cause of Death

Cause of death cannot be made out unless there is evidence of fracture or injuries which usually cause death, e.g. fracture of skull, vertebrae, hyoid bone, several ribs, and marks of deep cuts in long bones. Bone should be examined for firearm injuries or any disease. The type of the weapon can be known from type and depth of the bony injury. Metallic poisons, e.g. arsenic, antimony, lead or

JAYPEE BROTHERS

mercury can be found in bones long after death. Arsenic, thallium can be detected even in burnt bones.

ESTIMATION OF AGE BY PUBIC SYMPHYSIS (TODD'S METHOD) (FIG. 3.15)

First Post-adolescent Phase (Age 18–19 Years)

Symphyseal surface rugged, traversed by horizontal ridges separated by well-marked grooves; no ossific nodules fusing with the surfaces; no definite delimiting margin; no definition of extremities.

Second Post-adolescent Phase (Age 20–21 Years)

Symphyseal surface is still rugged, traversed by horizontal ridges, and the grooves between which are, however, becoming filled near the dorsal limit with a new formation of finely textured bone. This formation begins to obscure the hindered extremities of horizontal ridges. Ossific nodules fusing with upper symphyseal face may occur; dorsal limiting margin begins to develop; no delimitation of extremities; foreshadowing of ventral bevel.

Third Post-adolescent Phase (Age 22–24 Years)

Symphyseal face shows progressive obliteration of ridge and furrow system; commencing formation of dorsal plateau; presence of fusing ossific nodules; dorsal margin gradually becoming more defined; beveling as a result of ventral rarefaction becoming rapidly more pronounced; no delimitation of extremities.

Fourth Phase (Age 25–26 Years)

Great increase of ventral beveled area; corresponding diminution of ridge and furrow formation; complete definition of dorsal margin through the formation of dorsal plateau; commencing delimitation of lower extremity.

Fifth Phase (Age 27–30 Years)

Little or no change in the symphyseal face and dorsal plateau except that sporadic and premature attempts at the formation of a ventral rampart occur; lower extremity like the dorsal margin is increasing in clearness of definition; commencing formation of upper extremity with or without intervention of bony nodule.

Sixth Phase (Age 30–35 Years)

Increasing definition of extremities; development and practical completion of ventral rampart; retention of granular appearance of symphyseal face and ventral aspect pubis; absence of lipping of symphyseal margin.



Fig. 3.15: Todd's (1920) ten stages of pubic symphysis modification in adult white males.

JAYPEE BROTHERS

Seventh Phase (Age 35–39 Years)

Changes in symphyseal face and ventral aspect of pubic symphysis and diminishing the activities. Dorsal plateau indicates the presence or absence of texture difference between the dorsal half and the ventral half.

Eighth Phase (Age 39–44 Years)

Symphyseal face is generally smooth and inactive; ventral surface of the pubis also inactive; oval outline complete or approximately complete; extremities clearly defined; no distinct rim to symphyseal face; no marked lipping of either dorsal or ventral margin.

Ninth Phase (Age 45–50 Years)

Symphyseal face presents a more or less marked rim; dorsal margin uniformly lipped; ventral margin irregularly lipped.

Tenth Phase (Age 50 Years and Upward)

Symphyseal face eroded and showing erratic ossification; ventral border more or less broken down; disfigurement increases with age.

Quick Facts

- Best bone for determination of sex is pelvis
- Best criteria in pelvis, for determination of sex is sciatic notch index.
- Chilotic line is useful for determination of sex. In males, sacral part of it is more prominent while in females, the pelvic part is more prominent.
- Cusp of Carabelli is present at the mesiopalatal angle in Caucasoid skull.
- Ponderal index (PI) is for IUGR (PI = Fetal weight/Fetal length × 3)
- Karl Pearson's formula is used to calculate the stature of the individual from long bones.
- Trotter and Gleser formula are used for estimation of stature from long bones.
- **Barr body:** The number of Barr bodies present is correlated with the (number of barr bodies X is the number of X chromosome). Barr body is small plano-convex mass nuclear membrane. It was demonstrated by Barr and Bertram. It is present in the buccal mucosa 20–80% in females cells and 0–4% in male cells.
- **Davidsons-Smith body:** Present in neutrophils in females (8%), but it is absent in males.
- **Feulgen reaction:** This reaction give bright yellow spot in X chromosome.
- **Steel's formula:** Stature can be estimated in fragmented bones.
- **Weight of human skeleton:** 4.6 kg in male and 3 kg in female)
- Capacity of male skull is 10% more than female
- **Trigonocephaly:** Early fusion of metopic suture
- **Scaphocephly:** Early fusion of sagittal suture
- **Posterior plagiocephaly:** Early fusion of lambdoid suture
- **Anterior plagiocephaly:** Early fusion of coronal suture
- **Turica** means **multiple sutures**.
- **Alzarian red** is used for marker to stain center of ossification.
- **Risser test:** It is based on a study of iliac crest points of ossification from a frontal view of the pelvis.
- **Quetelet's rule:** Weight in kilograms of a normal adult should equal their height in centimeters minus 100.
- No two persons have same fingerprint pattern not even identical twins.
- Superimposition used by Glaister and Brash in Scotland to solve the famous Ruxton case.
- Superimposition is a presumptive test.
- A photograph of the skull is taken and a transparency is prepared. The transparency of the life-size photograph is now superimposed on the transparency of the skull.
- Useful test for exclusion of identity, rather than confirmation of identity. A negative of the skull is more reliable.
- Anthropometry is also known as Bertillon System—skeletal dimensions remain unchanged after 21 years.
- Poroscopy is an examination of pores on fingers. Also, known as Lockard method.
- Podogram is study of footprints.
- **Rugoscopy (palatoprints)** is the study of rugae patterns on the anterior part of hard palate.
- Spectrogram is helpful in trapping anonymous phone callers.
- Fingerprints can be studied by electron autoradiography, scanning electron microscopy.
- DNA fingerprinting is best to detect paternity (other methods are HLA and blood group).
- Blackening and tattooing skin/clothing can be best demonstrated by infrared photograph. Tattoo marks are permanent when dye (India ink) penetrates the dermis.
- Amino acid content of bone is detected by thin layer chromatography. Amino acids content falls gradually. Analysis of fresh bone reveals >15 amino acids while <7 amino acids in bone suggest that the age of bone after death is >100 years.

JAYPEE BROTHERS

EXERCISE

- Place, date and time of examination
- Number of bones
- For example, skull, hip bone, femur, sacrum, mandible
- Human or animal: Anatomical features, confirmation by histology or precipitin test
- Race
- Sex

For example, skull or hip bone

Sl. No.	*Features*		*Observation*
	Male	*Female*	

- Age:
- Stature:
- Any injuries:
- Cause of death:
- Time since death:
- Whether the bones belong to one individuals or more:

Note: Examination details of each bone should be written separately like above.

Opinion

For example, I am of the opinion that the examined bone (skull, pelvis, sacrum, sternum) belong(s) to human male/female individual of age between _____ years to _____ years. Stature is between_____ to_____ cm, cause of death unascertainable.
Time since death is _____ to _____

Signature of the Doctor
Professor
Department of Forensic Medicine and Toxicology
.....
Thanjavur

Station:
Date:
Original:
Duplicate:
Triplicate:

JAYPEE BROTHERS

or detailed information on forensic medicine and toxicology books, visit our website www.ejaypee.com, for detailed information on forensic medicine and toxicology books, visit our website www.

Practical Guide for
Forensic Medicine and Toxicology

Salient Features

- *CBME-aligned structure*—the content is mapped to competencies, emphasizing hands-on learning, case-based discussions, and practical applications for both UGs and PGs as per latest NMC norms
- *Recent advances*—includes the latest updates in forensic pathology, toxicology, medicolegal aspects, and new technologies like forensic DNA analysis and criminal laws
- *Clinical case scenarios*—real-life cases to enhance clinical reasoning and medicolegal decision-making
- *Integrated approach*—correlation with clinical forensic medicine, forensic pathology, and law for a holistic understanding
- *Illustrations and flowcharts*—well-structured diagrams, tables, and algorithms for quick recall
- *Important points* were discussed in nutshell, and it will be useful for preparing viva voce and preparations for competitive examinations
- *New criminal laws*—updated medicolegal guidelines and new criminal laws BNS, BNSS, and BSA wherever applicable to the book court rulings
- *Hands-on skill development*—guidance on autopsy techniques, injury assessment, and forensic documentation
- *Practical checklists*—ready reference for documentation, reporting formats, and certification procedures

K Tamilmani MD (FM) RCDM is currently working as Professor and Head, Department of Forensic Medicine and Toxicology, Thanjavur Medical College, Thanjavur, Tamil Nadu, India. He is interested in academic activities, medicolegal issues, and clinical toxicology. He has handled sensitive medicolegal cases in the country. He has given training to judicial officers, police officers, and doctor professionals. He is the Senate member of the Tamil Nadu Dr. MGR Medical University, Guindy, Chennai and also an associate editor of J-SIMLA. He is an executive committee member of IAFM, IST, and a former joint secretary in Tamil Nadu Service Forensic Medicine Experts Society. He has published research papers in various national and international publications and doing research in Virtopsy.

Buy from ejaypee

JAYPEE BROTHERS

Shelving Recommendations
FORENSIC MEDICINE AND TOXICOLOGY

ISBN 978-93-6616-949-1