formation on orthopedics books, visit our website www.ejaypee.com, for detailed information on orthopedics books, visit our website www.ejaypee.com

3rd Edition

Bedside Clinics in Orthopedics

(Beyond Cases)



OSCE HIGHLIGHTS

- Bone, Joint Model, and Specimen
- Orthopedic Radiographs
- Instruments and Implants
- Ward Round
- Orthopedic Surgical Approaches
- Review of Orthopedic Surgeries
- Review of Orthopedic Imaging
- Orthopedic Operation Theater Principles
- Orthopedic Rehabilitation
- Miscellaneous Section

Editor
Upendra Kumar

Forewords
DK Taneja
Anil K Jain
VK Sinha

JAYPEE

Contents

SECTION 1: Bone, Joint Model, and Specimen

1. Basics about Bones and Joints **3**

Bone ***3*** • Bone Formation and Growth Pattern ***6*** • Joint ***9*** • OSCE Questions (Osteon) ***10***

2. Bones and Joints of Upper Limb **11**

Clavicle ***11*** • Scapula ***12*** • Review of Shoulder Joint ***13*** • Humerus ***16*** • Review of Elbow Joint ***18*** • Radius and Ulna ***19*** • Review of Wrist Joint ***20*** • Bones of Wrist and Hand ***24*** OSCE Questions (Rib cage) ***26***

3. Bones and Joints of Lower Limb **27**

Pelvic Bone ***27*** • Review of Hip Joint ***27*** • Femur ***31*** • Patella ***35*** • Review of Knee Joint ***35*** • Tibia and Fibula ***37*** • Review of Ankle Joint ***40*** • Bones of Ankle and Foot ***41*** OSCE Questions (Pelvis) ***44***

4. Bones and Joints of Spine **46**

Spine (Bones) ***46*** • Review of Joints of Spine ***49*** OSCE Questions (Sacrum bone) ***50***

5. Specimen Section **52**

Proceeding for Specimen Section ***52*** • Dissected Specimen of Elbow ***52*** • Dissected Specimen of Wrist and Hand ***53*** • Dissected Specimen of Knee ***53*** • Dissected Specimen of Ankle and Foot ***54*** • Specimen of Bony Sequestrum ***56*** • Specimen of Pott's Spine ***56*** • Specimen of Menisci ***57*** • Specimen of Loose Bodies ***58*** • Specimen of Osteochondroma ***59*** • Specimen of Giant Cell Tumor ***59*** • Specimen of Osteosarcoma ***61*** • Specimen of Ewing's Sarcoma ***62*** • Specimen of Multiple Myeloma Spine ***62*** OSCE Questions (Madura foot) ***63***

SECTION 2: Orthopedic Radiographs

6. Radiographs of Fractures **67**

Preliminary Knowledge for Study of Fracture X-ray ***67*** • X-ray: Etiological Classification of Fracture ***67*** • X-ray: Fracture Patterns and Mechanism of Injury ***68*** • X-ray: Pediatric Fracture ***68*** • X-rays: Periarticular Fractures ***71*** • X-ray: Pathological Fractures ***71*** • X-ray: Peri-implant Fracture ***72*** OSCE Questions (Hamstring avulsion) ***74***

7. Radiographs of Bone Tumors **75**

Description of a Tumor Radiographs ***75*** • X-ray: Osteochondroma ***75*** • X-ray: Osteoid Osteoma ***77*** • X-ray: Enchondroma/Chondroma ***78*** • X-ray: Simple Bone Cyst ***78*** • X-ray: Aneurysmal Bone Cyst ***79*** • X-ray: Fibrous Dysplasia ***80*** • X-ray: Fibrous Cortical Defect (Nonossifying Fibroma) ***80*** • X-ray: Giant Cell Tumor ***81*** • X-ray: Osteosarcoma ***82*** • X-ray: Chondrosarcoma ***82*** • X-ray: Ewing Sarcoma ***83*** • X-ray: Multiple Myeloma ***83*** • OSCE Questions (Multiple exostosis) ***84***

8. Radiographs of Infective and Rheumatic Disorders **86**

X-ray: Chronic Osteomyelitis ***86*** • X-ray: Osteoarticular Tuberculosis ***87*** • X-ray: Degenerative Arthritis ***88*** • X-ray: Rheumatoid Arthritis ***88*** • X-ray: Ankylosing Spondylitis ***89*** • X-ray: Psoriatic Arthropathy ***91*** OSCE Questions (Psoriatic hand) ***92***

9. Radiographs of Metabolic Disorders **93**

X-ray: Nutritional Rickets ***93*** • X-ray: Scurvy ***94*** • X-ray: Osteomalacia ***94*** • X-ray: Osteoporosis ***95*** • X-ray: Primary Hyperparathyroidism ***96*** • X-ray: Myositis Ossificans ***96*** • X-ray: Osteogenesis Imperfecta ***97*** OSCE Questions (Ostepetrosis) ***98***

10. Radiographic Identification of Some Congenital and Developmental Disorders **100**

X-ray: Congenital Cervical Synostosis (Klippel–Feil Syndrome) ***100*** • X-ray: Scoliosis ***100*** • X-ray: Spondylolisthesis ***101*** • X-ray: Developmental Dysplasia of Hip ***102*** • X-ray: Slipped Capital Femoral Epiphysis or Adolescent Coxa Vara ***103*** • X-ray: Perthes Hip ***104*** • X-ray: Avascular Necrosis Femur Head: Kahler's Disease ***105*** • X-ray: Loose Bodies of Knee ***106*** • X-ray: Blount's Disease ***106*** • X-ray: Congenital Pseudoarthrosis of Tibia ***107*** • X-ray: Tibial Hemimelia ***108*** • X-ray: Sprengel's Shoulder ***109*** • X-ray: Superior Radioulnar Synostosis ***109*** • X-ray: Radial Club Hand ***110*** OSCE Questions (Madelung's deformity of wrist) ***111***

SECTION 3: Instruments and Implants

11. Tourniquet, Esmarch's Bandage and General Surgical Instruments **115**

Tourniquet and Esmarch Bandage ***115*** • Towel Clips ***116*** • Bard-Parker Knife Handle with Detachable Blade ***117*** • Artery (Hemostatic) Forceps ***118*** • Allis Forceps ***118*** • Rampley's Sponge Holding Forceps ***118*** • Cheatle Forceps (Sister's Forceps) ***119*** • Scissors ***119*** • Needle Holder ***120*** • Dissecting Forceps ***121*** OSCE Questions (Esmarch bandage on limb) ***122***

12. Surgical Retractors and Bone Levers **123**

Langenbeck's Right Angle Retractor ***123*** • Czerny's Retractor ***123*** • Hook Retractors ***123*** • Hohmann's Retractor ***124*** • Self-retaining Retractors ***124*** • Lane Bone Lever ***125*** • Bristow's Retractor ***126*** OSCE Questions (Fukuda retractor) ***126***

13. Bone Cutting and Related Instruments **127**

Osteotome (Stille Type) ***127*** • Bone Chisel (Stille Type) ***127*** • Bone Gouge (Stille Type) ***127*** • Bone Cutter ***128*** • Laminectomy Forceps ***128*** • Bone Nibbler (Rongeur) ***128*** • Scoop or Curette (Volkmann's Type) ***129*** • Corticotome ***129*** • Periosteal Elevator

(Farabeuf's Type) ***129*** • Gigley's Saw ***130*** • Amputation Saw ***130*** • OSCE Questions (Flush cutter) ***131***

14. Bone and Plate Holding Instruments **132**

Bone Holders ***132*** • Reduction Clamp/Forceps ***132*** • Heygroves Bone Holders ***132*** • Lane's Bone Holders ***132*** • Burns Bone Holders ***133*** • Mani's Clamp ***133*** • Lowman's Clamp ***133*** • Verbrugge's Self-centering Bone Holding Forceps ***133*** • Patella Bone Holding Clamp ***134*** • Wide-throated Periarticular Clamp ***134*** • Pelvic Reduction Clamp and Forceps ***134*** • OSCE Questions (Collinear clamp) ***135***

15. Bone Piercing Instruments and Screw-drivers **137**

Bone Awl: Kuntscher's Diamond Pointed Awl ***137*** • Bradawl (Cobbler's Awl) ***137*** • Drill Bit ***137*** • Counter Sink ***138*** • Bone Tap ***138*** • Drill Guide/Sleeve ***138*** • Intramedullary Reamers ***138*** • Guidewire ***139*** • Tissue Protector Sleeve ***140*** • Screw-drivers ***140*** • OSCE Questions (Guidewire holder) ***141***

16. SS-wire and K-wire Handling Instruments **142**

Orthopedic Pliers ***142*** • Wire and Pin Cutter ***142*** • SS-wire Tensioner ***143*** • SS-wire Sleeve (Wire-Passer) ***143*** • K-wire Bender ***143*** OSCE Questions (K-wire introducer) ***144***

17. Miscellaneous Orthopedic Instruments **146**

Mallet ***146*** • Orthopedic Drill Machine ***146*** • T-handle with Jacobs Chuck and Key ***146*** • Depth Gauge ***146*** • Bone (Kocher's) Hook ***148*** • Bone Graft Impactor ***148*** • Bone File ***148*** • Hollow Mill ***148*** • Antiskid Failed Screw Extractor ***149*** • Wrench or Spanner ***149*** • Dynamometer ***149*** • Allen Key ***150*** • Sequestrum Forceps ***150*** • Cartilage (Martin's) Holding Forceps ***150*** • Tendon Stripper ***151*** • Tendon Tunneling or Tendon Passing Forceps ***151*** • Humby's Knife ***151*** • Measuring Instruments ***151*** • Plaster Cutting Instruments ***152*** • OSCE Questions (Femoral distractor and distal radial distractor) ***154***

18. Special Instruments for Plating and Nailing **155**

Plate Bender ***155*** • Zig for Locking Plate ***155*** • Intramedullary Nail Introducer ***155*** • Zigs for Nail Insertion ***155*** • Nail Extractors ***156*** • Broken Nail Extractor ***156*** • OSCE Questions (Müller compression device) ***158***

19. Key Instruments for DHS/DCS and Hip Hemiarthroplasty **159**

Instruments for DHS and DCS Surgeries ***159***

Guidewire ***159*** • Angle Guide ***159*** • Triple Reamer ***160*** • Direct Measuring Device ***160*** • Dynamic Hip Screw Tap ***160*** • Dynamic Hip Screw Wrench ***160***

Instruments for Hip Hemiarthroplasty ***161***

• Charnley's Self-retaining Initial Retractor ***161*** • Corkscrew (Judet) ***161*** • Head Measuring Gauze ***161*** • Box Chisel ***162*** • Rasp/Broach with Tommy Bar ***162*** • Murphy Skid ***163*** • Head Impactor ***163*** • OSCE Questions (DHS assembly) ***163***

20. Key Instruments for Spine Surgery **165**

Cobb's Elevator ***165*** • Self-retaining Spinal Retractors ***165*** Rib Retractor ***166*** • Doyen's Rib Raspatory ***166*** • Rib Shear ***167*** • Kerrison's Rongeurs ***167*** • Dura and Nerve Root Retractors ***167*** • Discectomy (Codman's) Forceps ***167*** • Pedicle Awl ***168*** • Pedicle Probe ***169*** • Pedicle Sound ***169*** • OSCE Questions (Lamina spreader) ***170***

21. Key Instruments for Arthroscopy **171**

Arthroscope ***171*** • Probe ***171*** • Scissor ***171*** • Basket Forceps ***172*** • Grasp Forceps ***172*** • Arthroscopic Knives ***172*** • Shaver System ***172*** • OSCE Questions (Trocar and sheath) ***173***

22. Pins, Wires, and Tension Band Wiring **174**

Steinmann Pin ***174*** • Denham Pin ***174*** • Schanz Screw ***174*** • Kirschner's Wire (Martin Kirschner, Germany) ***175*** • Stainless Steel Wire ***175*** Tension Band Wiring ***176*** • OSCE Questions (Screw eye) ***176***

23. Orthopedic Screws **178**

Screw Description ***178*** • Comparison between AO and Machine Screw ***179*** • Cortical and Cancellous Screw ***179*** • Lag Screw ***179*** • Herbert Screw ***180*** • Dynamic Hip Screw Sliding Screw ***180*** • Malleolar Screw ***181*** • Locking Screw or Locking Head Screw ***181*** • Interlocking Bolt ***181*** • Cannulated Bolt (Proximal Femoral Nail and Recon Nail) ***182*** • Some Other Functions of Screw ***182*** • Various Screw Types and Drill Bits ***182*** • OSCE Questions (Acutrak screw) ***184***

24. Orthopedic Plating **185**

Bone Plate ***185*** • Dynamic Compression Plates (Allgower, 1960) ***188*** • Tubular Plates ***188*** • Locking Plate ***190*** • Reconstruction Plates ***191*** • Stress and Strain in Relation to Bone and Implant ***191*** • Various Regional Plates ***192*** • OSCE Questions (Plate for periprosthetic fracture femur) ***195***

25. Orthopedic Nailing **197**

Intramedullary Nail ***197*** • Rush Nail ***198*** • Talwalkar's Square Nail ***199*** • Ender's Nail and TENS Nail ***199*** • Kuntscher's Cloverleaf Nail: Gerhard Kuntscher from Germany ***200*** • Kuntscher's V-nail ***201*** • Interlocking Nail ***201*** • Regional Interlocking Nail ***202*** • OSCE Questions (TTC nail) ***204***

26. Special Implants Around Hip **205**

Identification of Some Historical Implants ***205*** • Moore's Pin and Knowles Pin (Austin Moore, USA) ***205*** • Cannulated Cancellous Hip Screw ***206*** • Dynamic Hip Screw Plate ***206*** • Dynamic Condylar Screw Plate ***208*** • Angled Blade Plate (130° and 95°) ***208*** • Proximal Femoral Nail ***209*** • Proximal Femoral Nail Antirotation ***210*** • OSCE Questions (FNS) ***211***

27. Spinal Implantation **212**

Steffee Spine Plate and Screw ***212*** • Hartshill Ring or Frame and Drummond Wire ***212*** • Harrington Rod with Hook ***212*** • Pedicular Screw and Connecting Rod ***213*** • Anterior Spinal Locking Plate and Screw ***213*** • Spinal Cage ***214*** • OSCE Questions (Stand alone cervical cage) ***214***

28. Osteotomy Fixation Implants and Special Implants for Arthrodesis **216**

Wainwright Plate, Kissel Spline, and Tupman Plate ***216*** • 90° Osteotomy Blade Plate ***216*** • 120° Double-angle Osteotomy Blade Plate ***217*** • 120° Double-angle Dynamic Hip Screw Plate ***217*** • Coventry Staple ***217*** • High Tibial Osteotomy Plate ***217*** • Blount's Epiphysiodesis Staple ***218*** • Figure 8 Plate ***218*** • Cobra Plate for Hip Arthrodesis ***219*** • Long Interlocking Nails ***219*** • Other Implants Used for Arthrodesis ***219*** • OSCE Questions (Charnley compression clamp) ***220***

29. Arthroplasty Implants **221**

Unipolar Hip Prosthesis: Austin Moore and Thompson Type (Austin Moore, USA) ***221*** • Talwalkar's Fixed Bipolar Prosthesis (AK Talwalkar, India) ***221*** • Modular Bipolar Hemiarthroplasty Prostheis ***222*** • Total Hip Arthroplasty Implant (John Charnley, England) ***222*** • Total Knee Arthroplasty System ***226*** • Shoulder Hemiathroplasty Implant ***227*** • Shoulder Total Arthroplasty Implant ***227*** • Total Elbow Arthroplasty System ***228*** • OSCE Questions (Radial head prosthesis) ***229***

30. Implants for External Fixators **231**

Components of AO External Fixator Frame (Me Muller, 1952) ***231*** • Components of Ilizarov's Ring Frame and JESS Fixator ***231*** • OSCE Questions (JESS system) 234

31. Miscellaneous Materials **236**

Suture Materials ***236*** • Suturing Methods and Knots ***236*** • Surgical Needles ***236*** • Bone Cement ***236*** • OSCE Questions (Synthetic calcium sulfate granules) ***240***

SECTION 4: Ward Round

32. Casting Materials and Orthopedic Casts **245**

Plaster of Paris Bandage ***245*** • Fiberglass Plaster/Synthetic Cast ***246*** • Stockinette ***247*** • Cotton Roll ***247*** • Cotton Roller Bandage ***247*** • Principle of Reduction and Casting ***248*** • Casting in James Position (Radial Gutter, Ulnar Gutter, and Volar Splintage with Pop) ***249*** • Scaphoid Cast and Thumb Spica ***249*** • Colles' Cast ***250*** • U-slab or Cast ***251*** • Above Elbow Cast ***251*** • Shoulder Spica ***251*** • Below Knee Cast and Boot Cast ***252*** • Cylindrical Cast ***252*** • Above Knee Cast ***252*** • Congenital Talipes Equinovarus Cast: A Special Type of Above Knee Cast ***253*** • Patellar Tendon Bearing Cast—A Functional Cast Bracing (Sarmiento A, 1963) ***254*** • Walking Heel (Rubber) ***255*** • Walking Iron ***255*** • Hip Spica ***255*** • Spica ***257*** • Wedging of Cast ***257*** • Making a Window in Cast ***257*** • Bivalving of Cast ***258*** • Slitting of Cast ***258*** • Plaster Bed: A Forgotten Technique of Immobilization ***259*** • OSCE Questions (Pin plaster) ***260***

33. Dressing Materials **261**

Objectives of Dressing ***261*** • Layers of Dressing ***261*** • Cotton Gauze Pieces ***261*** • Gamgee Roll and Dressing Pad ***262*** • Elastic Bandage (Crepe Bandage) ***262*** • Adhesive Surgical Tapes ***262*** • Tincture Benzoin ***263*** • Magnesium Sulfate Cream (Su Mag/Mag-Sulf) and Glycerin ***264*** • Paraffin Gauze ***264*** • Hydrocolloids (DuoDERM) ***264*** • Hydrogel (Megaheal) ***265*** • Alginates (Algisite M) ***265*** • Hydrogen Peroxide (H_2O_2) ***265*** • Savlon (Tartrazine Yellow Color) ***266*** • Dettol (Light Yellow Color) ***266*** • Surgical Spirit ***266*** • Povidone-iodine ***267*** • Chlorhexidine Solution ***267*** • Edinburgh University Solution of Lime ***267*** • Silver Ions Solution (Qurion) ***268*** • Placenta Extract (Placentrex) ***268***

• Collagen Granules and Collagen Sheet ***268*** • Dressing Trolley ***269*** • Cut Open Tray ***270*** • Cidex Tray ***270*** • Pus Culture Tube ***270*** • OSCE Questions (Oxoferin solution) ***271***

34. Orthopedic Strappings, Bandages, and Slings **272**

Finger and Toe Strapping (Buddy Taping) ***272*** • Arm Chest Strapping (Velpeau) ***272*** • Jones Strapping (Robert Jones, Britain) ***272*** • Chest Strapping ***273*** • Bandaging Around Ankle and Wrist ***273*** • Figure of 8 Bandage ***273*** • Ball Bandaging ***274*** • Sling in Orthopedics ***274*** • OSCE Questions (Jones bandage) ***276***

35. Orthopedic Tractions and their Equipment **278**

Splints ***278*** • Bohler–Braun Splint ***278*** • Thomas Splint (Robert Jones, Britain) ***279*** • Bohler's Stirrup ***281*** • Buck's Pulley ***281*** • Tensionizer/Tensioner/K-wire Strainer ***282*** • Traction ***282*** • Fixed Traction ***282*** • Sliding Traction ***283*** • Skin Traction ***284*** • Bryant's/Gallow's Traction ***285*** • Dunlop's Traction ***286*** • Skeleton Traction ***286*** • Lateral Upper Femoral Traction ***287*** • Distal Femoral Traction ***288*** • Upper Tibial Traction ***288*** • Distal Tibial Traction ***288*** • Calcaneal Traction ***288*** • Olecranon Traction ***289*** • Metacarpal Traction ***289*** • Axial Traction (Cervical and Pelvic) ***290*** • Special Type of Traction in Lower Limb ***291*** • Obletz, Ninety–Ninety Traction ***293*** • OSCE Questions (Pneumatic splints) ***295***

36. Patients on External Fixators **296**

Pin Fixator: AO Type ***296*** • Limb Reconstruction System ***298*** • Ilizarov System (Gavriil Abramovich Ilizarov, Russia) ***299*** • Taylor Spatial Frame ***300*** • Joshi External Stabilization System ***302*** • OSCE Questions (INFIX) ***303***

37. Miscellaneous Equipments **304**

Orthopedic Bed with Balkan Frame or Bim ***304*** • Air Mattress ***305*** • Compression Stockings ***305*** • Pneumatic Compression Device ***306*** • Triflow Incentive Spirometer ***306*** • Vacuum-assisted Closure Device: GS Kulkarni Machine for Vacuum-assisted Dressing ***306*** • Surgical Drain ***308*** • Foley's Catheter with Urobag ***309*** • Intercostal Drainage/Chest Tube ***311*** • Different Parenteral Fluids ***311*** • Blood and Blood Products ***311*** • Intravenous Drip Set ***312*** • Intravenous Cannula ***313*** • Syringe and Needle ***313*** • Three-way Stop Cock with Tubing/Three-way Extension Set ***314*** • OSCE Questions (Segregation of biomedical waste) ***315***

SECTION 5: Orthopedic Surgical Approaches

38. Pectoral Girdle, Shoulder, and Arm **319**

Shoulder: Anterior Approach (Deltopectoral Approach) ***319*** • Arm: Anterior/Anterolateral Approach of Arm ***320*** • Arm: Posterior Approach of Arm ***321*** • Other Approaches of Shoulder ***321*** • OSCE Questions (Judet approach) ***322***

39. Distal Arm, Elbow, and Proximal Forearm **323**

Elbow: Posterior Approach of Elbow ***323*** • Elbow: Lateral Approach (Modified Kocher's Approach) ***324*** • Elbow: Some Other Approaches ***325*** • OSCE Questions (Kocher's approach) ***326***

40. Forearm, Wrist, and Hand **327**

Forearm: Anterior Approach to Radius (Henry's Approach) ***327*** • Forearm: Posterior Approach to Ulna (Boyd's Approach) ***328*** • Forearm: Posterior Approach to Radius (Thompson Approach) ***328*** • Forearm: Volar Approach for Distal Radius ***329*** • Volar and Dorsal Approach for Scaphoid ***329*** • Other Approach of Wrist: Dorsal Approach ***329*** • OSCE Questions (Approach of forearm and hand in compartment syndrome) ***332***

41. Spine **333**

Cervical Spine: Anterior Approach to Cervical Spine (Southwick and Robinson Approach) ***333*** • Dorsal Spine: Costotransversectomy ***334*** • Dorsolumbar Spine: Interlaminar Approach of Spine ***335*** • Other Approaches to Spine ***335*** • OSCE Questions (Dorsal cervical approach) ***336***

42. Pelvis, Hip, and Thigh **338**

Pelvis: Anterior Approach (Ilioinguinal Approach) ***338*** • Anterior Intrapelvic Approach (Modified Stoppa's Approach) ***339*** • Pelvis: Posterior Approach (Kocher–Langenbeck) ***340*** • Hip: Anterior Approach (Smith–Peterson Approach) ***341*** • Hip: Posterior Approach (Moore's or Southern Approach) ***341*** • Hip: Lateral Approach (Hardinge Approach) ***342*** • Thigh: Lateral Approach ***343*** • Pelvis and Hip: Other Approaches ***344*** • OSCE Questions (Ileofemoral approach) ***345***

43. Distal Thigh, Knee, and Proximal Leg **346**

Distal Femur: Lateral/Posterolateral Approach ***346*** • Distal Femur: Anteromedial Approach ***347*** • Tibial Plateau: Anterolateral Approach ***347*** • Tibial Plateau: Anteromedial Approach ***348*** • Tibial Platue: Postmedial (Lobenhoffer) Approach ***349*** • Tibial Plateau: Postlateral (Frosche) Approach ***349*** • Knee: Posterior Approach ***350*** • Some Other Approaches Around Knee ***351*** • OSCE Questions (True anterior approach for patella) ***353***

44. Leg, Ankle, and Foot **355**

Leg: Anterior or Anterolateral Approach ***355*** • Leg: Posterolateral Approach (Henry) ***355*** • Ankle: Anterior Approach ***356*** • Ankle: Posterior (Posteromedial and Posterolateral) Approach ***357*** • Approach for Talus and Calcaneus ***358*** • Midfoot: Anterior Approach (Ollier's Approach) ***360*** • Other Approaches Around Ankle ***361*** • OSCE Questions (Approach of leg and foot in compartment syndrome) ***362***

SECTION 6: Review of Orthopedic Surgeries

45. Common Orthopedic Plating and Nailing **367**

Humerus Plating ***367*** • Plating for Intercondylar Humerus Fracture ***368*** • Radius/Ulnar Plating ***369*** • Radius and Ulna Square Nailing ***370*** • Tibia Interlocking Nail ***371*** • Femur Interlocking Nailing ***373*** • Suprapatellar Tibial Nailing and Supracondylar Femur Nailing ***375*** • Proximal Femoral Nailing ***375*** • OSCE Questions (Clavicle plating) ***377***

46. Miscellaneous Trauma Procedures **379**

Pediatric Supracondylar Humerus Fracture Fixation with K-wire (Through Lateral Approach) ***379*** • Tension Band Wiring for Fracture Olecranon and Patella ***380*** • Malleolar Fracture Fixation ***381*** • Dynamic Hip Screw ***382*** • Multiple Hip Screw for Fracture Neck

Femur ***384*** • Hemiarthroplasty Hip ***386*** • Cord Decompression and Pedicular Screw Fixation (Posterior Approach) ***387*** • OSCE Questions (BDSF) ***389***

47. Basic Principles of Osteotomy and Arthrodesis **391**

Valgus Osteotomy Proximal Femur ***391*** • Medial Displacement Osteotomy Proximal Femur ***391*** • Lower Limb Alignment ***392*** • Proximal Tibial Osteotomy ***392*** • Epiphysiodesis Around Knee ***394*** • Distal Humerus Osteotomy ***395*** • Osteotomy Around Wrist and Ankle ***396*** • Arthrodesis Around Joints ***396*** • OSCE Questions (Distal femur osteotomy) ***398***

48. Basic Principles of Total Arthroplasty **400**

Total Hip Arthroplasty ***400*** • Total Knee Arthroplasty ***401*** • Total Shoulder Arthroplasty ***402*** • Elbow Arthroplasty ***403*** • OSCE Questions (Unicompartmental knee arthroplasty) ***404***

SECTION 7: Review of Orthopedic Imaging

49. X-ray, Ultrasound, and CT Scanning in Orthopedics **409**

Roentgen ***409*** • Contrast Radiographs (Arthrogram) ***409*** • Ultrasonography ***411*** • Computed Tomography ***413*** • OSCE Questions (Fluoroscopy guided hip injection) ***418***

50. MRI and Nuclear Medicine in Orthopedics **419**

Magnetic Resonance Imaging ***419*** • Nuclear Medicine ***424*** • OSCE Questions (PET-CT scanning) ***427***

SECTION 8: Orthopedic Operation Theater Principles

51. Operation Theater Structure and Services **431**

Structure of a Modern Operation Theater ***431*** • Zoning Plan of Operation Theater ***432*** • Subareas of the Operation Theater Complex ***433*** • Essential Services ***434*** • Safety Hazards in Operation Theater ***436*** • OSCE Questions (OT control panel) ***437***

52. An Overview of Equipment Inside Operation Theater **438**

Operation Table ***438*** • Anesthesia Machine and Gas Connections ***439*** • Anesthesia Equipment Kit ***439*** • Multipara Monitors ***440*** • Defibrillator ***440*** • Drug Cart ***441*** • Electrical Surgical Cautery Unit ***442*** • Suction Machine ***442*** • Tourniquet ***443*** • Warming Device ***443*** • Operation Theater Trolley ***444*** • Sterilized Drums And Boxes ***444*** • Arthroscope Trolley ***444*** • Resuscitation Trolley ***444*** • Image Intensifier (C-arm) ***445*** • Waste Disposal Unit ***445*** • Miscellaneous Equipment ***446*** • OSCE Questions (Fluid compression bag or pressure infusion bag) ***447***

53. Principles of Sterilization **448**

Definitions ***448*** • Classification of Items and their Decontamination Techniques ***449*** • Cleaning ***449*** • Chemical Disinfection and Pasteurization ***449*** • Steam Sterilization (Autoclaving) ***451*** • Ethylene Oxide Sterilization ***453*** • Some Other Methods of Sterilization ***454*** • Sterilization of Operation Theater ***456*** • Sterilization of Different Materials ***457*** • OSCE Questions (Fumigation and fogging machine) ***457***

54. Before Starting Surgery **458**

Goals of Patient Care before any Procedure ***458*** • Preparation before Admitting the Patient ***458*** • On Admission to the Ward ***459*** • Principle of Operative Site Preparation ***459*** • Guidelines for Discontinuation of Drugs ***460*** • Checklist Regarding Patient Preparation ***460*** • After Taking the Patient In Operation Theater ***461*** • Patient Positioning ***462*** • Surgeon Preparation ***463*** • Surgical Site Preparation by Surgeon before Surgery ***464*** • WHO Surgical Safety Checklist ***466*** • OSCE Questions (Gloves wearing technique) ***467***

SECTION 9: Orthopedic Rehabilitation

55. Basics about Orthosis and Prosthesis **471**

Orthosis ***471*** • Prosthesis ***472*** • OSCE Questions (Immediate postoperative prosthesis) ***473***

56. Lower Limb Orthosis **475**

Foot Orthosis ***475*** • Ankle-foot Orthosis ***478*** • Knee Orthosis and Knee Joints in Lower Limb Orthosis ***479*** • Knee-ankle-foot Orthosis ***482*** • Hip-knee-ankle-foot Orthosis ***482*** • Special Orthosis for Lower Limb ***483*** • OSCE Questions (Patellar tendon bearing KAFO) ***488***

57. Upper Limb Orthosis **489**

Hand Orthosis ***489*** • Wrist-hand Orthosis ***490*** • Elbow Orthosis ***492*** • Shoulder Orthosis ***493*** • Special Orthosis in Upper Limb (Turnbuckle Splint) ***494*** • OSCE Questions (Sling and swathe immobilizer/universal shoulder immobilizer) ***494***

58. Spinal Orthosis **496**

Cervical Orthosis ***496*** • Extended Cervical Orthosis ***499*** • Thoracolumbosacral Orthosis ***500*** • Lumbosacral Orthosis ***501*** • Special Orthosis for Scoliosis: Milwaukee and Boston Brace ***502*** • OSCE Questions (Chairback orthosis) ***504***

59. Lower Limb Prosthesis **505**

Components of Lower Limb Prosthesis ***505*** • Prosthetic Foot ***505*** • Prosthetic Shank ***507*** • Prosthetic Socket and Suspension (BKP) ***507*** • Prosthetic Knee Joint (AKP) ***508*** • Prosthetic Socket and Suspension ***508*** • Stubbies and Leg Extension Prosthesis ***508*** • OSCE Questions (ITAP intraosseous transcutaneous amputation prosthesis) ***510***

60. Upper Limb Prosthesis **511**

Components of Upper Limb Prosthesis ***511*** • Power System ***511*** • Terminal Devices ***511*** • Wrist Unit ***511*** • Forearm Section ***512*** • Prosthetic Socket (Below Elbow Prosthesis) ***512*** • Elbow Joint Unit ***512*** • Prosthetic Socket (Above Elbow Prosthesis) ***513*** • OSCE Questions (Bionic upper limb/myoelectric prosthesis) ***514***

61. Mobility Aids for Patients **515**

Wheelchair (Second Home for Paraplegics) ***515*** • Standard Walking Frame (Walker) ***516*** • Rollator Walking Frame (Walker on Wheels) ***516*** • Axillary Crutches ***517*** • Elbow

Crutches (Lofstrand Crutch) ***517*** • Gutter Crutch ***518*** • Walking Sticks ***518*** • Crutch Gait ***518*** • OSCE Questions (Tripod or quadripod walking aid) ***520***

62. Physical Therapy and Traction in Rehabilitation **522**

Exercise Therapy ***522*** • Mechanics of Exercises ***523*** • Traction Machine ***524*** • Continuous Passive Machine ***525*** • Mobilization Therapy ***526*** • OSCE Questions (Hydrotherapy unit) ***526***

63. Modalities of Electrotherapy in Rehabilitation **528**

Heat and Cold Therapy ***528*** • Wax Therapy ***529*** • Electrotherapy ***530*** • Transcutaneous Electrical Nerve Stimulation ***530*** • Interferential Therapy ***531*** • Electrical Muscle Stimulation ***532*** • Ultrasonic Therapy ***532*** • Short-wave Diathermy ***533*** • Microwave-Diathermy ***534*** • Light Amplification by Stimulated Emission of Radiation ***534*** • Infrared Lamp ***535*** • OSCE Questions (Biofeedback mechanism of rehabilitation) ***536***

SECTION 10: Miscellaneous Section

64. Glorious History of World Orthopedics **541**

Ambroise Paré (1510–1590) ***541*** • Nicolas Andry (1658–1742) ***541*** • PercivaLl Pott (1714–1788) ***542*** • John Hunter (1728–1793) ***542*** • William Hey (1736–1819) ***542*** • Giovanni Battista Monteggia (1762–1815) ***543*** • Abraham Colles (1773–1843) ***543*** • Baron Guillaume Dupuytren (1777–1835) ***543*** • Sir Benjamin Brodie (1783–1862) ***543*** • Sir John Rhea Barton (1794–1871) ***544*** • James Syme (1799–1870) ***544*** • Antonius Mathijsen (1805–1878) ***544*** • Robert William Smith (1807–1873) ***545*** • William John Little (1810–1894) ***545*** • Jean–Martin Charcot (1825–1893) ***545*** • Emil Theodor Kocher (1841–1917) ***546*** • Sir James Paget (1814–1899) ***546*** • Richard Von Volkmann (1830–1889) ***546*** • Hugh Owen Thomas (1834–1891) ***547*** • Friedrich Trendelenburg (1844–1924) ***547*** • Sir Robert Jones (1857–1933) ***547*** • Martin Kirschner (1879–1942) ***548*** • Willis Campbell (1880–1941) ***548*** • Thomas Porter Mcmurray (1887–1949) ***548*** • Austin T Moore (1899–1963) ***549*** • Gerhard Küntscher (1900–1972) ***549*** • Sir Reginald Watson–Jones (1902–1972) ***549*** • Sir John Charnley (1911–1982) ***550*** • Ignacio Ponseti (1914–2009) ***550*** • Gavriil Abramovich Ilizarov (1921–1992) ***551***

65. How to Approach Objective Structured Clinical Examination in Postgraduate Orthopedic Practical Examination? **552**

Objective Structured Clinical Examination: A New System of Evaluation ***552*** • Importance of OSCE ***552*** • Types of Objective Structured Clinical Examination ***553*** • Pattern of Arrangement of Objective Structured Clinical Examination ***553*** • Tips to Crack the Objective Structured Clinical Examination ***553***

Bibliography ***555***

Index` ***557***

CHAPTER

41

Spine

JAYPEE BROTHERS

CERVICAL SPINE: ANTERIOR APPROACH TO CERVICAL SPINE (SOUTHWICK AND ROBINSON APPROACH) (FIGS. 1A AND B)

- *Position of patient on operating table (OT)?*
  - Supine position with the head in right/left lateral position.
- Line of incision?
  - Transverse incision → at appropriate vertebral pathology.
  - Vertically oblique → anterior to sternocleidomastoid prominence.
- Steps of dissection?
  - Split platysma.
  - Dissect between sternocleidomastoid muscle (accessory cranial and second and third cervical) and deep cervical fascia over strap muscles.
  - Palpate the carotid artery and make a plane between the carotid sheath and midline structures, such as the esophagus and trachea.
  - Blunt dissection to reach prevertebral fascia.
  - Sharp dissection between the longus (colli and capitis) muscle of either side reaches the body of vertebrae.
- Structures at risk in this approach?
  - Recurrent laryngeal nerve.
  - Contents of carotid sheath—common carotid artery, internal jugular vein, and vagus nerve.
  - Vertebral artery.
  - Trachea and esophagus.

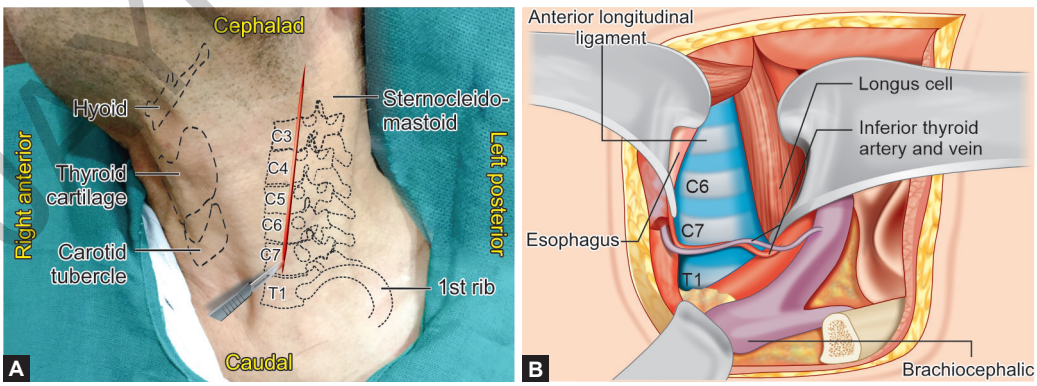

FIGS. 1A AND B: (A) Cervical spine: Anterior approach to the cervical spine (Southwick and Robinson approach) (landmarks and incision); and (B) Deep dissection.

Courtesy: Dr Mahesh Kumar, Patna.

- Common surgeries performed through this approach?
  - Spinal fracture fixation
  - Vertebral disc surgery
  - Vertebral interbody fusion
  - Spinal osteomyelitis
  - Spine tumors
- *Points of special interest*:
  - Always care for these bony landmarks during surgery.
    - Hard palate—arch of atlas
    - Lower border of mandible—C2–C3
    - Hyoid bone—C3
    - Thyroid cartilage—C4–C5
    - Cricoid cartilage—C6
    - Carotid tubercle—C6
  - *Preferred position of a patient*: Right lateral and surgery over the left side of the neck. Why so?
    - The course of the left recurrent laryngeal nerve is predictable.
    - The right recurrent laryngeal nerve is fixed to the trachea.

DORSAL SPINE: COSTOTRANSVERSECTOMY (FIGS. 2A AND B)

- Position of patient on OT table?
  - Right/left lateral position.
- Line of incision?
  - *Capener's incision*: A "C" shaped incision 8–10 cm lateral to affected spinous process—extend 5 cm above and below respectively from the concerned spinous process.
- Steps of dissection?
  - Cut through the trapezius, in the line of muscle fibers.
  - Rib resection → 6–8 cm from midline.
  - Divide the transverse process at the junction of the lamina with the pedicle.
  - Enter the retropleural space by digital dissection to reach the anterolateral part of the body.
  - Intercostal neurovascular bundle is a guide for intervertebral foramina and assesses the posterolateral part of the body.
- Structures at risk in this approach?
  - Intercostal vessels
  - Pleura of lung
- Common surgeries performed through this approach?
  - Vertebral abscess drainage
  - Vertebral body resection (partial)
  - Vertebral body biopsy
  - Anterolateral decompression of spinal canal (Pott's spine).

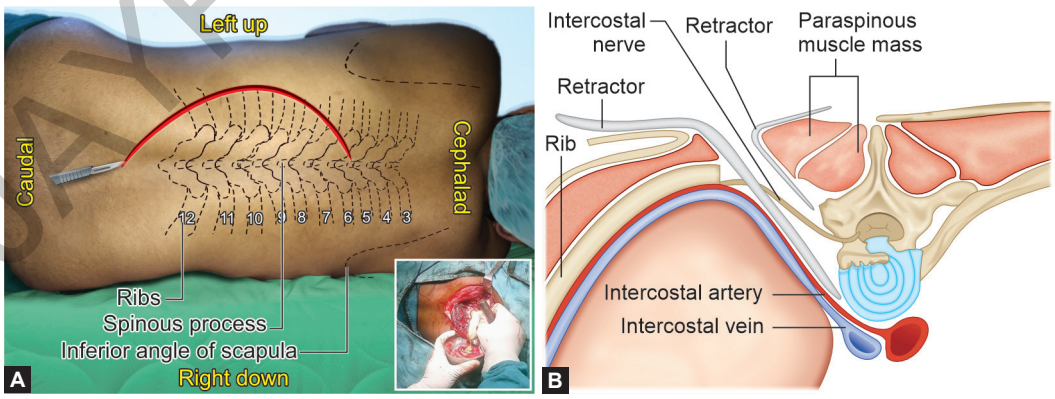

FIGS. 2A AND B: (A) Dorsal spine: Costotransversectomy (landmarks and incision); and (B) Deep dissection.
Courtesy: Dr Chandan Shekhar, Patna.

JAYPEE BROTHERS

- *Points of special interest*:
  - *Preferred position of the patient*: Right lateral and surgery over the left side of the chest. Why so?
    - The aorta is visible and has less chance of injury.
    - If an injury to the aorta occurs, it is easier to repair.
    - The left lung falls anteriorly and it decreases the chances of lung injury.

DORSOLUMBAR SPINE: INTERLAMINAR APPROACH OF SPINE (FIGS. 3A AND B)

- Position of patient on OT table?
  - Prone position or right/left lateral.
- Line of incision?
  - Midline incision in the line of the spinous process of C7 vertebrae and natal cleft according to the site of affected vertebrae.
- Steps of dissection?
  - Incision over thoracolumbar fascia in midline.
  - Cutting of paraspinal muscle by the side of a spinous process.
  - Retract the paraspinal muscle from the spinous process to the edge of the lamina.
  - Dissection for articular facet joint and transverse process.
- Structures at risk?
  - Dorsal primary rami
  - Segmental vessels
- Common surgeries performed through this approach?
  - Stabilization of fractured vertebrae
  - Posterior spinal fusion
  - Scoliosis surgery
  - Tumor removal.
- *Points of special interest*:
  - *Entry point for the lumbar pedicular screw* ***(Fig. 3B)***: The bisector of two imaginary lines, one (horizontal) in the plane of upper one-third of the transverse process and another (vertical) just lateral to facet joint; direction is caudal and medial (0–10° at L1 vertebrae and 20–30° at L5 vertebrae).

OTHER APPROACHES TO SPINE

- *Dorsal spine (transthoracic approach)*: Here incision line is centered over two

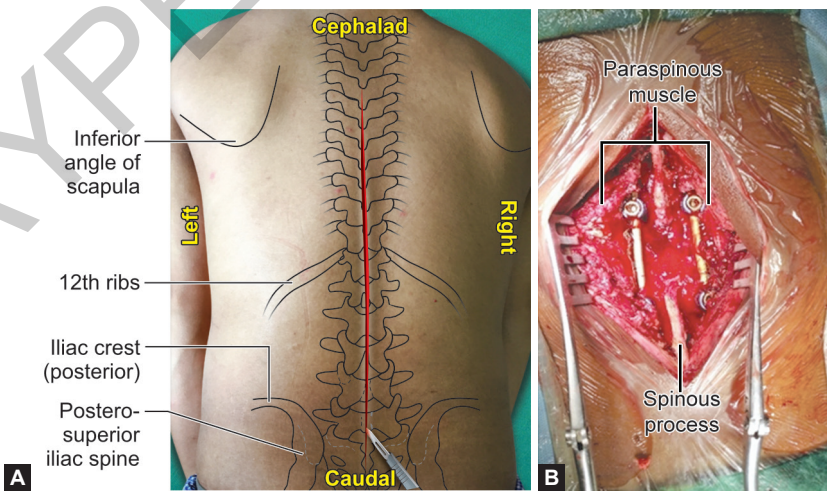

FIGS. 3A AND B: (A) Dorsolumbar spine: Interlaminar approach of the spine (landmarks and incision); and (B) Deep dissection.

JAYPEE BROTHERS

fingers breathing below the inferior angle of the scapula and extending forward toward the inframammary crease and extending backward and upward towards the thoracic spine. *Muscles are cut as follows:* (1) Serratus-anterior muscle (long thoracic nerve) anteriorly. (2) Latissimus dorsi muscle (thoracodorsal nerve) in the middle. (3) Trapezius muscle (spinal accessory cranial XI) posteriorly. Now assess through the 5th intercostal space to approach up to T8-9 vertebrae but use the sixth intercostal space for lower dorsal vertebrae. Then approach the superior border of a lower rib of the particular space and follow likewise → rib rasping done → do rib cutting → parietal pleura exposed. Structures that are in danger in this approach are intercostal vessels and lungs **(Fig. 4)**. Common surgeries performed through this approach are (1) surgery over thoracic vertebral bodies for Potts' spine, (2) vertebral interbody fusion, (3) anterior cord decompression, (4) spinal osteotomy, and (5) spinal biopsy.

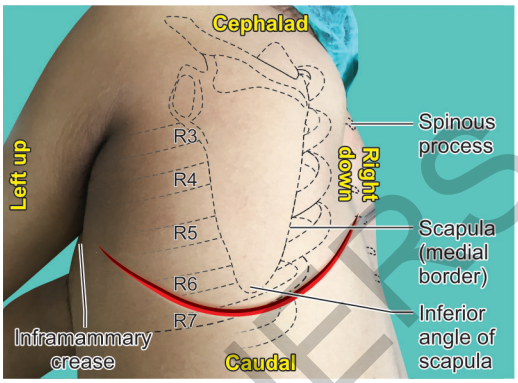

FIG. 4: Dorsolumbar spine—transthoracic approach.

- *Anterolateral retroperitoneal approach to lumbar spine*: It is something like the kidney approach used by general surgeons in a lateral position. This is an oblique incision in the loin along the 12th rib running towards the rectus abdominis muscle. After incising all three abdominal muscles (external oblique, internal oblique, and transverses abdominis) and facia transversalis; the retroperitoneal area is visible which is confirmed by retroperitoneal fat. Now the plane is made between great vessels (descending aorta and inferior vena cava) and psoas muscle to expose lumbar vertebrae. The structures in danger in this approach are great vessels itself, lumbar segmental arteries and veins, the ureter, the genitofemoral nerve, and the sympathetic chain.

OSCE Questions (Dorsal cervical approach)

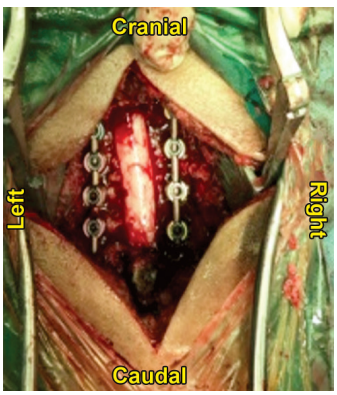

Courtesy: Dr Mahesh Kumar, Patna.

JAYPEE BROTHERS

Q1. What approach is this?

Ans. Dorsal approach for cervical spine and occipitocervical junction.

Q2. What are the incision line and dissection plane in this approach?

Ans. Midline incision in the line of cervical spinous processes. Subperiosteal dissection by the side of the spinous process to create paraspinal space.

Q3. What are the surgical indications of this approach?

Ans. Spinal cord decompression, lateral mass fixation, occipitocervical fusion, facet joint surgery, dealing with cervical stenosis and disc herniation, cervical myelopathy, and tumor surgery.

Q4. What are the structures at risk in this approach?

Ans. Dorsal primary rami, cervical nerve root, segmental vessels, vertebral artery in foramen transversarium from C1 to C6.

JAYPEE BROTHERS

for detailed information on orthopedics books, visit our website www.ejaypee.com, for detailed information on orthopedics books, visit our website www.e

Bedside Clinics in Orthopedics (Beyond Cases)

Salient Features

- It is the first book of its kind on practical orthopedic for postgraduate students and residents
- Includes over 700 self-explanatory photographs and line arts and many boxes for quick revision of important topics
- Throws brief details of bone, joints, and specimens kept in table viva-voce
- Includes a comprehensive and reproducible description of orthopedic radiographs and related facts
- Details the proper understanding of orthopedic instruments and implants and their uses
- Describes the basic understanding of orthosis and prosthesis for proper rehabilitation of an orthopedic patient
- Focuses on every corner of orthopedic ward ranging from orthopedic casts, dressing materials, traction, and equipment used for patient care
- Contains important questions and answers commonly asked by examiners in ward-round and table viva
- Highlights common surgical approaches frequently asked in viva-voce
- Covers the steps of common orthopedic surgeries
- Highlights the basic orthopedic imaging tools and their uses
- Provides a brief account of operation theater principle and sterilization
- Makes you familiar with recent advances in orthopedics that are commonly asked by examiners nowadays
- A comprehensive kit for cooling our examinees before viva-voce and OSCE for DNB
- Finally a ready reckoner before entering the examination hall



Upendra Kumar is a young Orthopedic Surgeon from Bettiah, West Champaran, Bihar, India. He has completed his postgraduate diploma from Patna Medical College, Bihar, and DNB from Deen Dayal Upadhyay Hospital, New Delhi. He also has experience in orthopedic rehabilitation from National Institute for the Orthopaedically Handicapped, Kolkata, West Bengal. He has completed his senior residency from Government Medical College, Bettiah. He is proud to work with the most famous orthopedic surgeon of India Dr John Mukhopadhyay, the son of so-called Father of Indian Orthopedics Dr B Mukhopadhyay.

He has presented many papers in various conferences in India. His students have been achieving success in prestigious DNB practical examinations at different centers of India. At present, he is serving the humanity as a private orthopedic consultant in his hospital, well known as ORTHOCARE, a dedicated institute of orthopedic and rehabilitation (IOOR) in his hometown Bettiah. In addition, he also updates the orthopedic knowledge by teaching postgraduates (DNBs and Masters) in various PG courses. He is the founder member of Minimal Invasive Orthopedic Surgeons Association, famously known as MIOS. He is also popular as "Slipperman of India" in his zone for his social activity dedicated to education, job-oriented coaching, and upliftment of unprivileged sections of society. His "Orthocare Slipperman Team" serves poor students with slippers, school-bags, notebooks, geometry boxes, slate, and other necessary stationery weekly at the village level. His life is ultimately dedicated to humanity.

Printed in India

Available at all medical bookstores or buy online at www.ejaypee.com

JAYPEE BROTHERS
Medical Publishers (P) Ltd.
EMCA House, 23/23-B, Ansari Road, Daryaganj, New Delhi - 110 002, INDIA
www.jaypeebrothers.com

Join us on facebook.com/JaypeeMedicalPublishers
Follow us on instagram.com/JaypeeMedicalPublishers

Shelving Recommendation
ORTHOPEDICS

ISBN 978-93-6616-993-4