m, for detailed information on anatomy books, visit our website www.ejaypee.com, for detailed information on anatomy books, visit our website www.ejaypee.com, for detailed information on anatomy book

7th Edition

First Ever Comprehensive Anatomy Book by Subject Specialist

Includes New Pattern NEET-PG and INI-CET Questions with explanatory Answers

SELF ASSESSMENT AND REVIEW OF ANATOMY

A Must-buy Book for NEET-PG, INI-CET, and FMG Exams

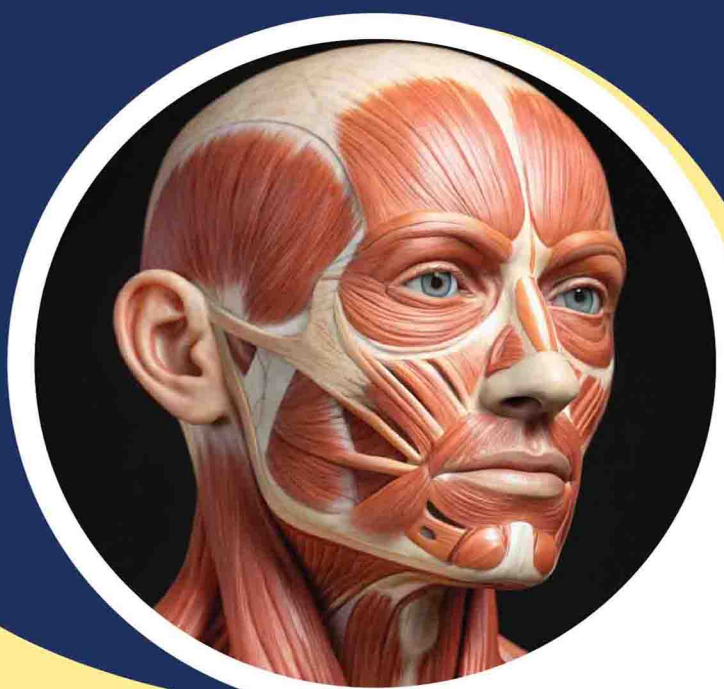

Highlights

- Comprehensive theory and latest pattern questions in all sub-sections of Anatomy: Embryology, Histology, Neuroanatomy and Gross Anatomy (including Surface and Radiological Anatomy)
- Previous years' questions with explanatory answers from the Entrance Examinations conducted by INI-CET and NEET-PG
- Reference books include Gray's Anatomy, Keith L Moore, Langman's Embryology, Ross Histology, Barr's Neuroanatomy, Dorland's Medical Dictionary.

diginerve®
A Jaypee Initiative
• Video Lectures • Dr. Wise AI Chatbot
• Question Bank • Notes
Download App

Rajesh K Kaushal

JAYPEE

Contents

Recent Questions and Answers with Explanation *p1–p124*

1. General Anatomy 1
2. Embryology 12
3. Histology 77
4. Neuroanatomy 133
5. Head and Neck 214
6. Back Region 334
7. Thorax 342
8. Upper Limb 383
9. Abdomen 442
10. Pelvis and Perineum 514
11. Lower Limb 558

CHAPTER

5



Head and Neck

PHARYNGEAL APPARATUS, THYROID DEVELOPMENT, SKULL DEVELOPMENT, VERTEBRAL LANDMARKS & LEVELS

HEAD AND NECK EMBRYOLOGY: PHARYNGEAL APPARATUS

The pharyngeal (branchial) apparatus is essential for the development of the head and neck.

- **Composition:** It consists of pharyngeal **arches, pouches, clefts (grooves), and membranes**.
- **Structural Layers:** Each arch has a mesenchymal core derived from **primary mesoderm (somites)** and **secondary mesoderm (neural crest cells)**, covered externally by *ectoderm* and internally by *endoderm*.
- **Arches:** Six pairs of U-shaped cylindrical bars develop in the lateral wall of the primitive pharynx, though the **fifth arch is rudimentary** and regresses.
- **Muscle vs. Bone Origin:** Skeletal muscles of the arches derive from **somites** (primary mesoderm), while bones and cartilages derive from **neural crest cells** (secondary mesoderm).

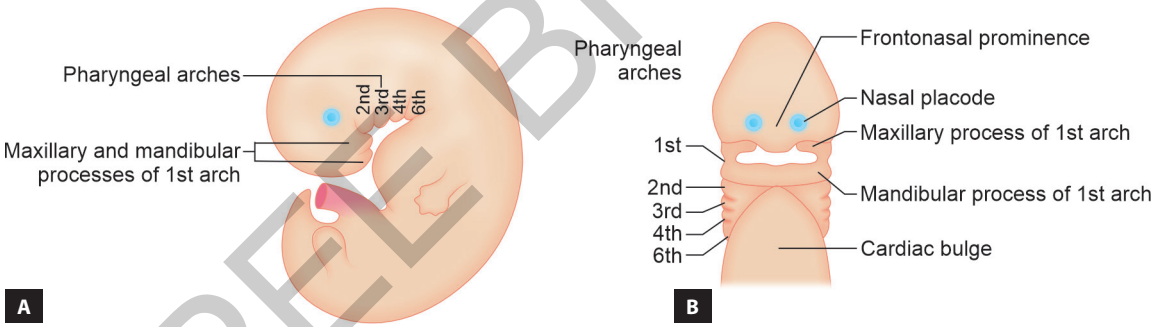

Figs. 1A and B: Formation of pharyngeal arches. (A) Lateral view; (B) Frontal view. Note that first pharyngeal arch consists of maxillary and mandibular processes.

Derivatives of the pharyngeal arches.

Arch no.	Nerve	Embryonic cartilage	NCCs/Mesoderm	Mesoderm (Muscles)	Miscellaneous	Artery
1.	CNV_3	Quadrate/ Meckel's	Maxilla Mandible (GT) Incus Malleus Anterior ligament of malleus Sphenomandibular ligament	Tensor tympani Tensor veli palatini Muscles of mastication Mylohyoid Anterior belly digastric	Anterior 2/3 of tongue	Maxillary (transitory)
2.	CN VII	Reichert's	Stapes Styloid process Stylohyoid ligament Lesser horn and upper part of body of hyoid bone	Stapedius Stylohyoid Facial muscles (incl. Buccinatory/Platysma, auricular, occipitofrontalis) Posterior belly digastric		Stapedial/Hyoid artery (transitory)

Contd…

JAYPEE BROTHERS

Contd…

Arch no.	Nerve	Embryonic cartilage	NCCs/Mesoderm	Mesoderm (Muscles)	Miscellaneous	Artery
3.	CN IX		Greater horn and lower part of body of hyoid	Stylopharyngeus	Posterior 1/3 of tongue	Common carotid artery Internal carotid artery (first part)
4.	CN X Pharyngeal branch superior laryngeal branch		NCSs: none Thyroid Cartilage Epiglottis	Palate (Levator, etc.) Pharynx Cricothyroid	Root of tongue	Right subclavian artery (proximal part) Arch of aorta (between origins of left common carotid and left subclavian arteries)
6.	CN X Recurrent laryngeal branch		NCCs: none Cricoid Arytenoid cartilages	Larynx		Pulmonary arteries D arteriosus

PHARYNGEAL ARCHES AND DERIVATIVES

Each arch contains a dedicated nerve, artery (aortic arch), and cartilaginous/skeletal component and muscles.

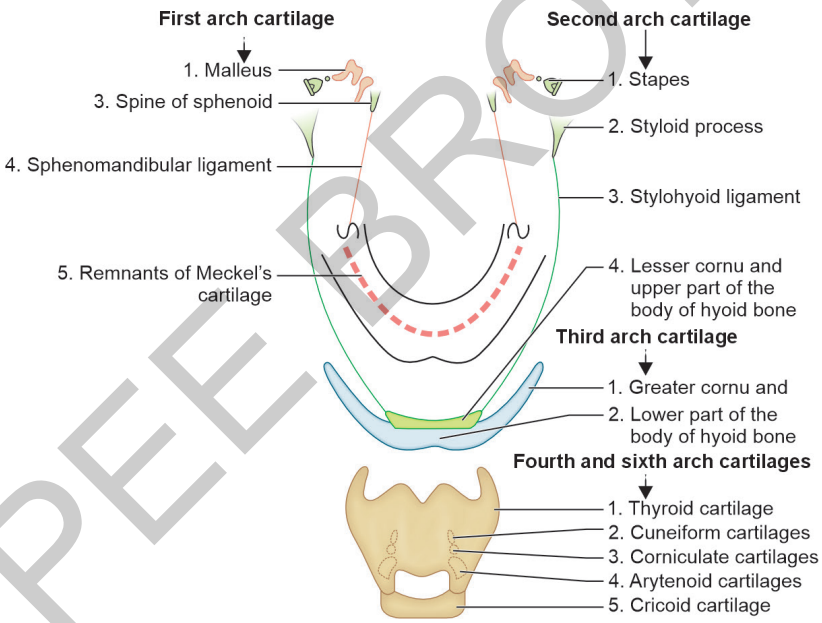

Fig. 2: Skeletal derivatives of pharyngeal arch cartilages. Bones are derived from the neural crest cells and larynx cartilages are derived from lateral plate mesoderm.

QUESTIONS

1. Which of the following muscle is derivative of 1st arch? *(NEET Pattern 2015)*

a. Stylopharyngeus
b. Tensor tympani
c. Platysma
d. Cricothyroid

2. WRONG match about the bone and cartilages in pharyngeal arches:

a. Meckel's cartilage: Mandible
b. Reichert's cartilage: Stapes
c. Second arch cartilage: Styloid process
d. Third arch: Lesser cornu of hyoid bone

3. Which of the following muscles develop from 6th pharyngeal arch?

a. Cricothyroid
b. Thyrohyoid
c. Stylopharyngeus
d. Cricoarytenoid

4. Maxillary prominence develops in:

a. 1st pharyngeal arch
b. 1st pharyngeal groove
c. 1st pharyngeal pouch
d. 1st pharyngeal membrane

JAYPEE BROTHERS

Questions

5. Pretrematic nerve of 1st pharyngeal arch is: *(DNB 2018)*

a. Mandibular nerve
b. Trigeminal nerve
c. Glossopharyngeal nerve
d. Chorda tympani

Answers

1. b. Tensor tympani
- Tensor tympani muscle develops in the first pharyngeal arch.
- Stylopharyngeus develops in 3rd arch, platysma in 2nd and cricothyroid in 4th arch, respectively.

2. d. Third arch: Lesser cornu of hyoid bone
- Third pharyngeal arch forms the lower body and greater (and not lesser) cornu of hyoid bone.

3. d. Cricoarytenoid
- Larynx muscles develop in 6th pharyngeal arch, cricoarytenoid is one among them.
- Cricothyroid is an exception in the sense that, despite being a larynx muscle it develops in fourth arch.

4. a. 1st pharyngeal arch
- Two prominences develop in 1st pharyngeal (mandibular) arch.
- Maxillary prominence, which forms maxilla, zygomatic bone, squamous part of temporal bone.
- Mandibular prominence, which has Meckel's cartilage and forms mandible.

5. d. Chorda tympani
- **Trigeminal nerve** (CNV) (maxillary and mandibular divisions) is the nerve of the **first pharyngeal arch**. The first arch is also supplied by the **chorda tympani nerve**, a pretrematic branch of the facial nerve—the nerve of second arch.
- Each pharyngeal arch is supplied by two nerves. The nerve that runs along **cranial border** of the arch is known as post-trematic nerve and nerve that runs along its **caudal border** is called pretrematic nerve.
- The pretrematic nerves disappear from all arches except first arch where it persists as **chorda tympani** nerve.
- Some authors consider the **tympanic branch of glossopharyngeal nerve** and **auricular branch of vagus nerve** as the pretrematic branches of the parent nerves.

PHARYNGEAL POUCHES

There are four well-defined pouches lined with *endoderm*.

1. **Pouch 1:** Forms the **epithelium of the middle ear (tympanic) cavity** and the **Eustachian (auditory) tube**.
2. **Pouch 2:** Forms the **epithelium and crypts of the palatine tonsils**.
3. **Pouch 3:** Has a ventral wing that forms the **thymus** and a dorsal wing that forms the **inferior parathyroid glands**.
4. **Pouch 4:** Forms the **superior parathyroid glands** (dorsal) and the **ultimobranchial body** (ventral).

- **Clinical Correlation: DiGeorge Syndrome** involves the failure of the 3rd and 4th pouches to develop, leading to an absent thymus (immunodeficiency) and absent parathyroids (hypocalcemia).

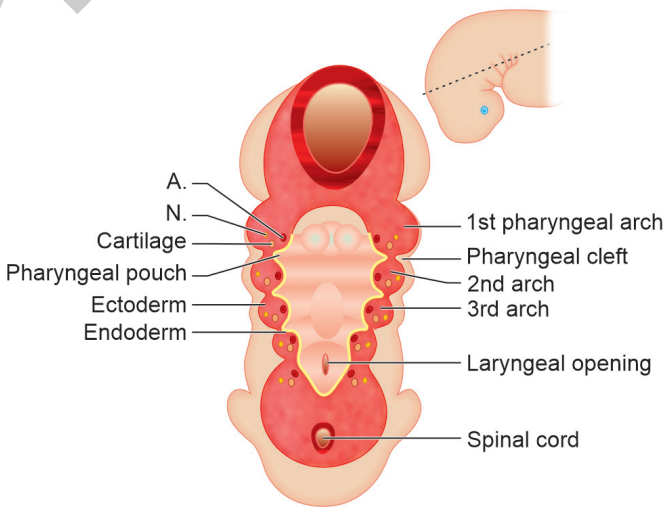

Fig. 3: Pharyngeal cleft, arch and pouches.

JAYPEE BROTHERS

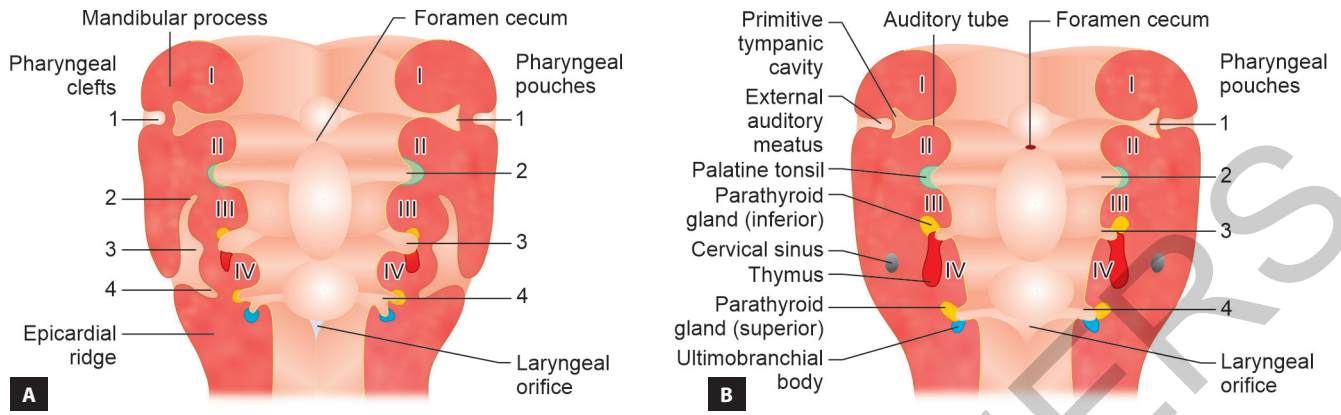

Figs. 4A and B: (A) Development of the pharyngeal clefts and pouches. The second arch grows over the third and fourth arches, burying the second, third, and fourth pharyngeal clefts. (B) Remnants of the second, third, and fourth pharyngeal clefts form the cervical sinus, which is normally obliterated.

PHARYNGEAL CLEFTS AND MEMBRANES

- **Pharyngeal Clefts (Grooves):** External *ectoderm*-lined indentations.
  - **1st Cleft:** Develops into the **external auditory meatus**.
  - **2nd, 3rd, & 4th Clefts:** Usually obliterated by the overgrowth of the 2nd arch, forming a temporary **cervical sinus**.
- **Pharyngeal Membranes:** Found between pouches and clefts.
  - The **1st membrane** is the only one to persist, forming the **tympanic membrane**. It is trilaminar: outer *ectoderm*, middle *mesoderm*, and inner *endoderm*.
- **Anomalies:** Failure of cleft obliteration results in **branchial cysts** (closed sacs), **sinuses** (one opening), or **fistulas** (two openings). These are most commonly (95%) related to the **second arch** and pass between the internal and external carotid arteries.

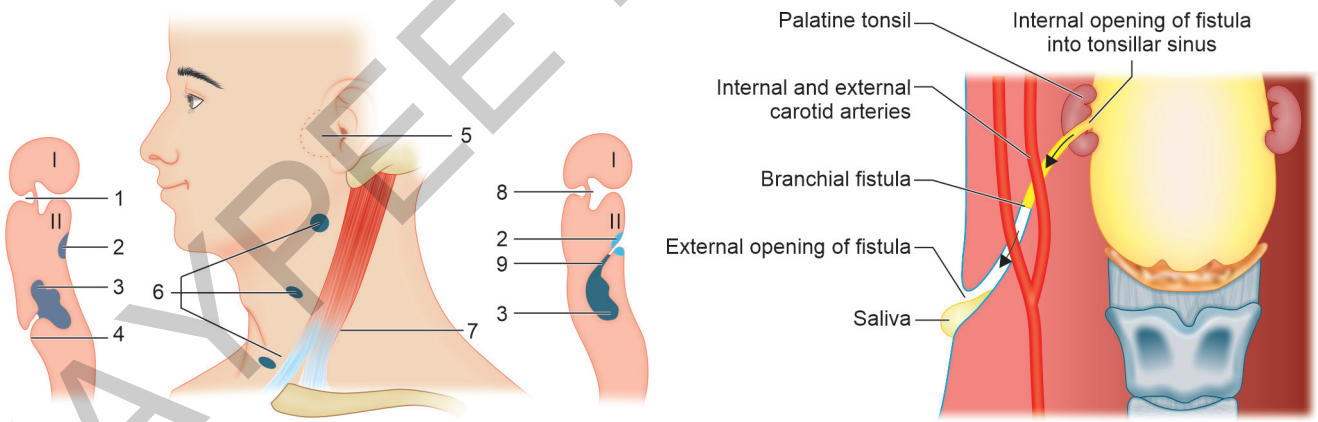

Fig. 5: 1. External auditory meatus; 2. Palatine tonsil; 3. Lateral cervical (branchial) cyst; 4. External branchial sinus; 5. Region of preauricular fistulae; 6. Region of lateral cervical cysts and fistulae; 7. Sternocleidomastoid muscle; 8. Tubotympanic recess; 9. Internal branchial sinus.

QUESTIONS

1. **Which of these is CORRECT about the development of tonsil?** *(NEET Pattern 2012)*
   a. Is a derivative of the first pharyngeal arch
   b. Develops from the second pharyngeal pouch
   c. Develops from the third pharyngeal pouch
   d. Is a derivative of the neural crest cells

2. **Thymus develops from:**
   a. Second pharyngeal pouch (ventral portion)
   b. Third pharyngeal pouch (ventral portion)
   c. Third pharyngeal pouch (dorsal portion)
   d. Fourth pharyngeal pouch (ventral portion)

JAYPEE BROTHERS

Questions

3. **During 4th week, endoderm and ectoderm approach each other in the head and neck region at:** *(AIIMS)*
   a. Pharyngeal groove
   b. Pharyngeal pouch
   c. Pharyngeal membrane
   d. Pharyngeal arch

4. **Which structure develops from all the 3 germ layers?**
   a. Tympanic membrane
   b. External acoustic meatus
   c. Auditory tube
   d. Middle ear

5. **TRUE statement regarding branchial anomalies:** *(AIIMS 2010)*
   a. Most commonly second arch is involved
   b. Cyst is more common than sinus
   c. Sinus should always be excised
   d. Cyst cause dysphagia and hoarseness

6. **A sinus is extending from the base of tongue to anterior border of sternomastoid, develop from which arch?**
   a. I
   b. II
   c. III
   d. IV

Answers

1. **d. Is a derivative of the neural crest cells > b. Develops from the second pharyngeal pouch**
   - Neural crest derived (secondary) mesenchyme, in the region of second pharyngeal pouch differentiates into connective tissue of tonsil, which later is invaded by lymphocytes migrating from bone marrow and thymus.
   - Endoderm of second pharyngeal pouch contributes to the tonsillar epithelium.

2. **b. Third pharyngeal pouch (ventral portion)**
   - Thymus gland develops in the ventral portion of third pharyngeal pouch, whereas in the dorsal region develops inferior parathyroid.

3. **c. Pharyngeal membrane**
   - During 4th week, at the lateral wall of primitive pharynx, inner endoderm (of pharyngeal pouch) and outer ectoderm (of pharyngeal cleft) approach each other and sandwich the pharyngeal membrane between the two.
   - The membrane is made up of mesenchyme (connective tissue) lined by outer ectodermal epithelium and inner endodermal epithelium.

4. **a. Tympanic membrane**
   - Tympanic membrane has an outer epithelial layer (ectodermal) and inner epithelial layer (endodermal) and sandwiched between the two is mesenchyme, forming the connective tissue.

5. **a. Most commonly second arch is involved**
   - This is a **controversial Questions**, since all the statements can be proven correct. The most appropriate option has been chosen as the answer.
   - Branchial arch anomalies are the most commonly associated with second arch, comprising more than 90% of the arch anomalies.
   - Branchial cysts are more common than the branchial sinus statistically - nearly 74% of the branchial arch anomalies present as a branchial cyst (though in paediatric age group sinuses are more common than cysts).
   - Branchial sinuses should always be excised (though some of the authors believe that excision should be done if they present with chronic inflammation, recurrent infections or have potential for malignant degeneration).
   - Pressure symptoms like dysphagia and hoarseness are rarely seen with branchial cyst (though few cases have been documented in neonates).

6. **b. II**
   - This is a case of second arch branchial fistula, with a cutaneous opening along the anterior border of the sternocleidomastoid, usually at the junction of the middle and lower thirds, and track up through the neck to run between the internal and external carotid arteries and end in the tonsillar fossa.

THYROID DEVELOPMENT

- **Origin:** The gland begins as an *endodermal* proliferation in the floor of the pharynx at the **foramen cecum**.
- **Descent:** It descends into the neck via the **thyroglossal duct**, passing ventral to the hyoid bone to reach its final position.
- **Parafollicular C Cells:** These cells produce calcitonin and originate from **neural crest cells**. They migrate into the **ultimobranchial body** (derived from the rudimentary 5th pouch or 4th pouch) before incorporating into the thyroid gland.

Questions

1. **The parafollicular C cells of thyroid develops from:**
   a. 1st and 2nd pharyngeal pouch
   b. 2nd and 3rd pharyngeal pouch
   c. 3rd and 4th pharyngeal pouch
   d. 4th and 5th pharyngeal pouch

2. **Parafollicular C cells are derived from:**
   a. Ultimobranchial body
   b. Pharyngeal pouch 4
   c. Pharyngeal pouch 5
   d. Neural crest cells

JAYPEE BROTHERS

Questions

3. **True about development of pharyngeal arches are all *EXCEPT*:** *(PGIC)*
   a. Parathyroid glands develop from 3rd and 4th pharyngeal pouch
   b. Tongue muscles develop from occipital myotome
   c. Superior parathyroid gland develops from 4th pharyngeal pouch
   d. Inferior parathyroid gland develops from 2nd pharyngeal pouch
   e. Thyroid develops from foramen cecum

Answers

1. **d. 4th and 5th pharyngeal pouch**
   - Parafollicular C cells of thyroid gland develop from the neural crest cells.
   - The fifth pharyngeal pouch is rudimentary and disappears, leaving behind ultimobranchial body, which attaches to the fourth pharyngeal pouch.
   - Neural crest cells reach the ultimobranchial body and get converted into parafollicular C cells of thyroid.

2. **d. Neural crest cells > a. Ultimobranchial body > b. Pharyngeal pouch 4 > c. Pharyngeal pouch 5**
   - Parafollicular C cells of thyroid gland develop from the neural crest cells.
   - The Fifth pharyngeal pouch is rudimentary and disappears, leaving behind ultimobranchial body, which subsequently attaches to the fourth pharyngeal pouch.
   - Neural crest cells reach the ultimobranchial body and get converted into parafollicular C cells of thyroid.

3. **d. Inferior parathyroid gland develops from 2nd pharyngeal pouch**
   - Inferior parathyroid gland develops from 3rd pharyngeal pouch.

SKULL DEVELOPMENT

Embryonic Origin of Skull Bones

The skull develops from two primary mesenchymal sources:

- **Secondary Mesenchyme (Neural Crest Cells):** Forms the **anterior and lateral** regions of the skull, including:
  - *Frontal bone*.
  - *Facial skeleton* (Nasal, zygomatic, maxilla, mandible, hyoid).
  - Parts of the *sphenoid* and *temporal* bones.
- **Primary Mesenchyme (Para-axial Mesoderm):** Forms the **posterior** and midline region of the skull, including:
  - *Occipital* and *parietal* bones.
  - *Petrous part* of the temporal bone.

Fontanelles: Development and Closure

Fontanelles are **unossified** spaces between skull bones (covered by membrane) at birth that allow for brain growth and skull overlapping during childbirth.

Fontanelle	Location	Closure timeline	Resulting suture/Landmark
Anterior	Between frontal and parietal bones; largest fontanelle	**1.5 – 2 years** (last to close)	**Bregma**
Posterior	Between parietal and occipital bones	**2 – 3 months** (first to close)	**Lambda**
Anterolateral (Sphenoid)	Junction of frontal, parietal, temporal, and greater wing of sphenoid	**2 – 3 months**	**Pterion**
Posterolateral (Mastoid)	Junction of occipital, parietal, and temporal bones	**6 – 18 months**	**Asterion**

- **Clinical Note:** In **hydrocephalus**, the anterior fontanelle may remain open past the expected time due to increased cerebrospinal fluid (CSF) pressure. In **dehydration** it appears **sunken**.

Skull Maturation and Pneumatization

Structures at Adult Size at Birth

The following ear-related structures **do not grow** postnatally:

- Middle ear (tympanic) cavity and mastoid antrum.
- Ear ossicles (**malleus, incus, stapes**).
- Tympanic membrane and inner ear.

JAYPEE BROTHERS

Postnatal Growth

Structures that continue to develop after birth include the **external ear canal, Eustachian tube, mastoid process, and the orbit** (reaches adult size around age 7).

Pneumatic Bones (Air-filled Sinuses)

Certain bones contain paranasal sinuses that connect to the nasal cavity:

- **Maxilla:** Contains the maxillary sinus (largest).
- **Frontal Bone:** Frontal sinus.
- **Ethmoid Bone:** Ethmoid air cells.
- **Sphenoid Bone:** Sphenoid sinus.
- **Temporal Bone:** Contains mastoid air cells.

SKELETAL LANDMARKS ON THE SKULL

Key landmarks identified (primarily from *norma lateralis*) include:

- **Bregma:** The junction of the coronal and sagittal sutures.
- **Vertex:** The highest point of the skull.
- **Lambda:** The junction of the sagittal and lambdoid sutures.
- **Pterion:** An **H-shaped suture** on the lateral aspect of the skull.
- **Asterion:** The junction of the occipital, parietal, and temporal bones.
- **Inion:** The most prominent point of the external occipital protuberance.
- **Glabella:** The smooth area on the frontal bone above the root of the nose.
- **Nasion:** The junction of the frontal and nasal bones.
- **Additional Landmarks:**
  - *Supramastoid crest* and *External auditory meatus*.
  - *Zygomatic arch* and *Angle of the mandible*.
  - **Reid's base line:** Extends from the infraorbital margin to the center of the external acoustic meatus.
  - **Frankfort line:** A horizontal line used for skull orientation.

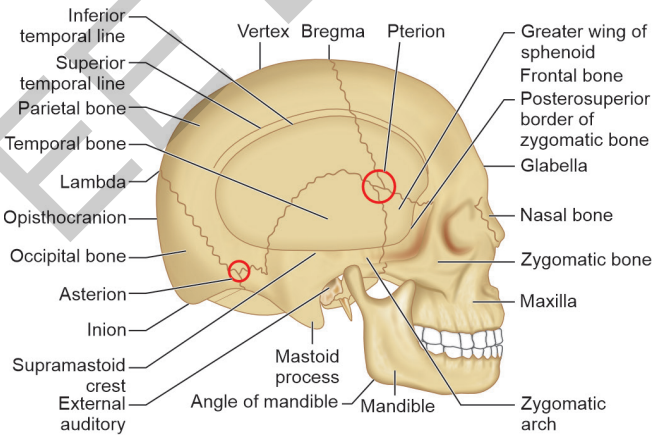

Fig. 6: Skeletal landmarks on skull (norma lateralis).

PTERION: ANATOMY AND CLINICAL SIGNIFICANCE

The **pterion** is a critical clinical and anatomical landmark on the lateral skull.

- **Composition:** An H-shaped junction where **four bones** meet: *Frontal, Parietal, Squamous part of Temporal, and Greater wing of Sphenoid.*
- **Sylvian Point:** The central point of the pterion, where the cranium is exceptionally thin.
- **Deep Relations:**
  1. **Frontal (anterior) branch of the middle meningeal artery** and its accompanying vein.
  2. Stem of the **lateral sulcus (Sylvian fissure)** of the cerebrum.

JAYPEE BROTHERS

- **Clinical Significance:**
  1. **Fractures** at this point can rupture the middle meningeal artery, leading to an **extradural hemorrhage**.
  2. It serves as a landmark for positioning **burr-holes** to evacuate hematomas.

VERTEBRAL LANDMARKS AND LEVELS

The following anatomical structures correspond to specific vertebral levels in the head and neck:

- **C3:** Level of the **hyoid bone** and its greater cornu.
- **C3–C4 Junction:** Marks the **superior border of the thyroid cartilage** and the **bifurcation of the common carotid artery**.
- **C3–C6:** Extent of adult **larynx**
- **C6:** Marks the level of the **cricoid cartilage**, the termination of the larynx and pharynx, and the beginning of the trachea and esophagus.

Structure	Vertebral level/Landmark
Thyroid Gland Isthmus	Overlies **tracheal rings 2, 3, and 4**
Common Carotid Bifurcation	Superior border of thyroid cartilage lamina; site for carotid sinus massage
Esophageal Narrowing (1st and the narrowest)	C6 level due to cricopharyngeus sphincter (15 cm from upper incisors)

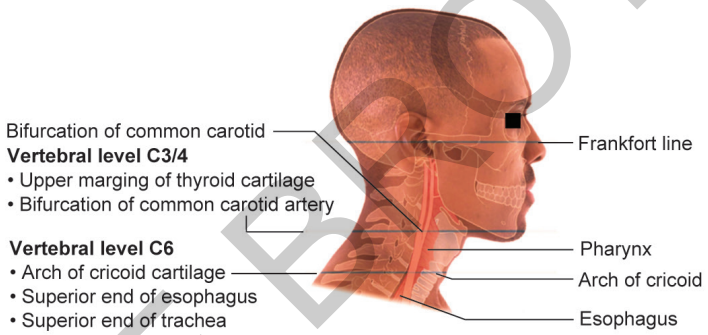

Fig. 7: Lateral view of head and neck to show structures at the C3/C4 and C6 vertebral levels.

CRANIAL CAVITY AND FOSSAE, SKULL FORAMINA, MANDIBLE

ORGANIZATION OF THE CRANIAL FOSSAE

The cranial cavity is divided into **three** distinct fossae, primarily housing different parts of the brain and providing passage for the **twelve** cranial nerves (CN I–XII).

Fossa	Primary bony contributions	Major contents/Associated nerves
Anterior	Frontal, **Ethmoid** (Cribriform plate, Crista galli), Lesser wing and body of Sphenoid	Olfactory bulb, **CN I and II**
Middle	Greater wing & Body of Sphenoid, Petrous part of Temporal bone	Pituitary gland, Cavernous sinus, **CN III–V3, CN VI**
Posterior	Occipital bone, Petrous part of Temporal bone, Body of Sphenoid	Brainstem, Cerebellum, **CN VII–XII**

DETAILED FORAMINA AND TRANSMITTING STRUCTURES

Anterior Cranial Fossa

- **Foramen Cecum:** Emissary vein from nasal mucosa to superior sagittal sinus.
- **Cribriform Plate:** Axons of the Olfactory nerve (CN I).
- **Anterior & Posterior Ethmoidal Foramina:** Respective ethmoidal nerves, arteries, and veins.

JAYPEE BROTHERS

- **Crista Galli:** Midline projection providing attachment for the *falx cerebri*.
- **Optic Canal** (at the junction of lesser wing of sphenoid with body of sphenoid): ***Optic nerve (CN II)*** and ophthalmic artery.

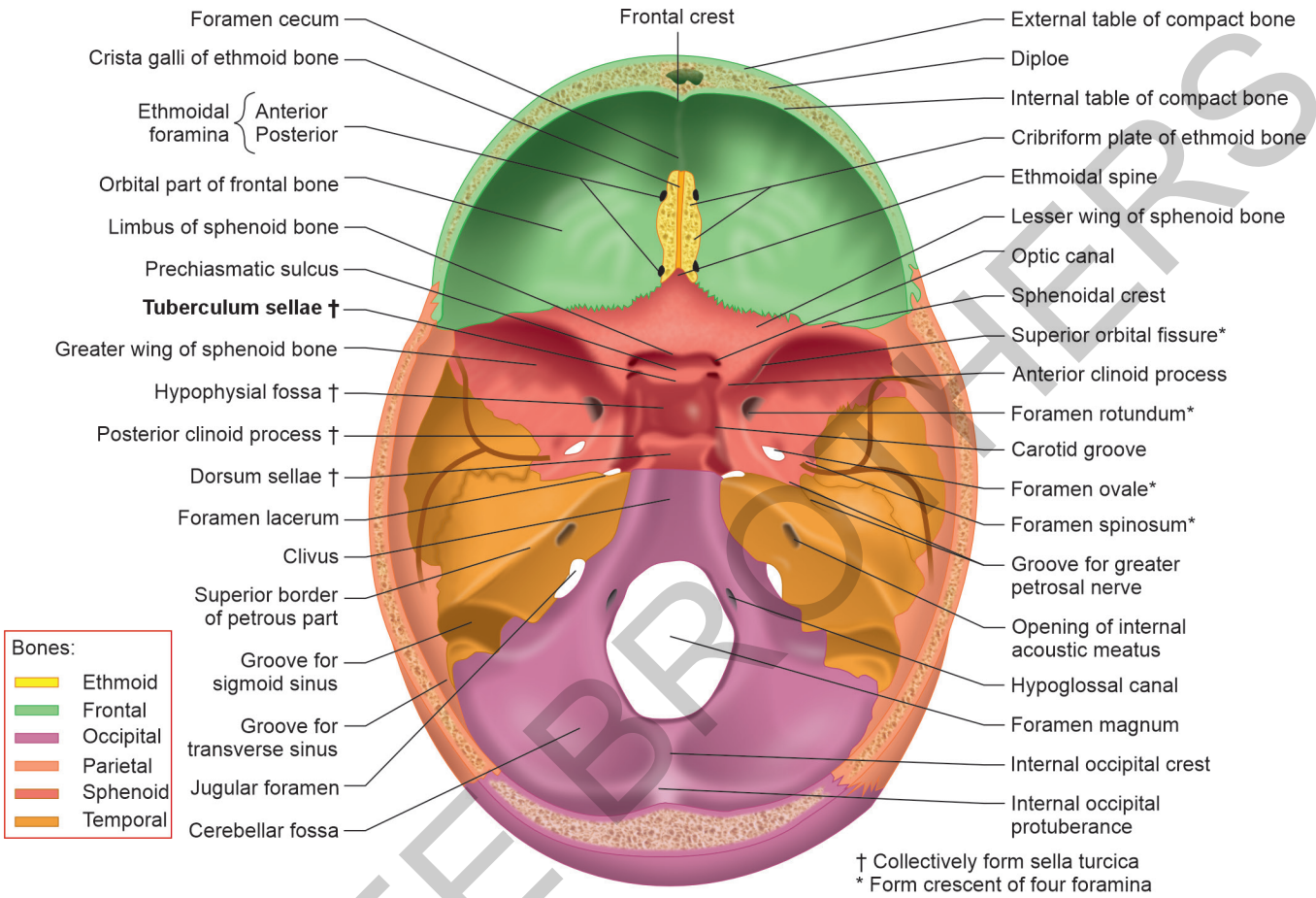

Fig. 8: Internal surface of cranial base (Superior view).

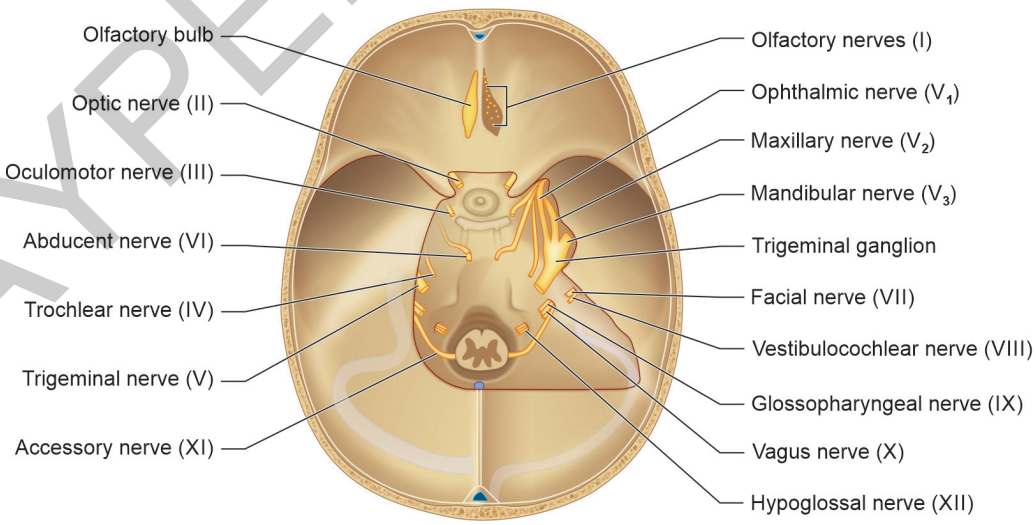

JAYPEE BROTHERS

Middle Cranial Fossa

- **Foramen Rotundum:** Maxillary nerve (CN V2).
- **Foramen Ovale:** Mnemonic '**MALE**':
  - **M**: Mandibular nerve (CN V3).
  - **A**: Accessory meningeal artery.
  - **L**: Lesser petrosal nerve.
  - **E**: Emissary vein (connects cavernous sinus to extracranial veins).
- **Foramen Spinosum:** Middle meningeal artery and ***nervus spinosus*** (meningeal branch of CN V3).
- **Foramen Lacerum:** Traversed superiorly by the internal carotid artery (and sympathetic plexus) and the vidian nerve; no structure passes directly *through* it.
- **Superior Orbital Fissure (SOF):** A gap between the greater and lesser wings of the sphenoid. Structures are divided by the **Common Tendinous Ring of Zinn (CTRZ)**:
  - **Within CTRZ:** ***CN III*** (superior/inferior divisions), ***CN VI***, ***Nasociliary nerve*** (branch of V1), Optic nerve, and Ophthalmic artery.
  - **Outside CTRZ (Mnemonic 'LFT'):** ***Lacrimal*** and ***Frontal*** nerves (V1), Trochlear nerve (CN IV), and Superior/Inferior Ophthalmic veins.

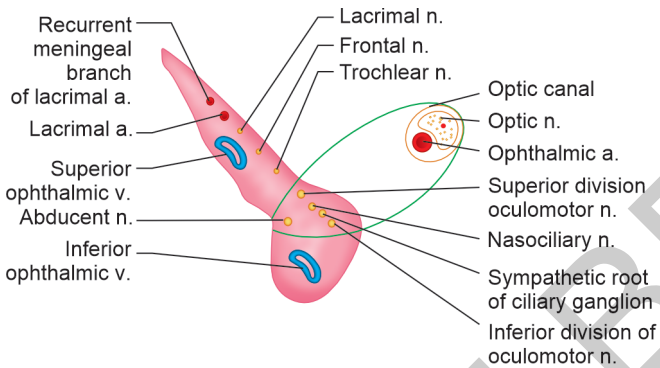

Fig. 9: Structures passing through superior orbital fissure. (a: artery; n: nerve; v: vein)

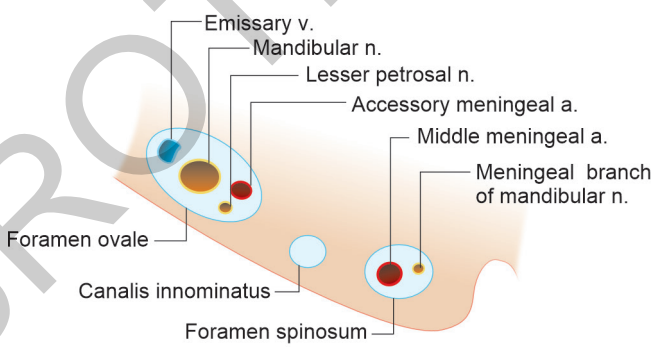

Fig. 10: Structures passing through foramen ovale and spinosum. (a: artery; n: nerve; v: vein)

Posterior Cranial Fossa

- **Internal Auditory Meatus:** Facial nerve (CN VII), Vestibulocochlear nerve (CN VIII), and labyrinthine artery.
- **Jugular Foramen:**
  - *Anterior:* Inferior petrosal sinus.
  - *Middle:* CN IX (Glossopharyngeal), CN X (Vagus), and CN XI (Accessory).
  - *Posterior:* Sigmoid sinus joining the internal jugular vein; meningeal branch of occipital artery.
- **Hypoglossal Canal:** ***Hypoglossal nerve (CN XII)*** and meningeal artery.
- **Foramen Magnum:** The largest opening.
  - *Nervous:* Lower **medulla oblongata** and meninges; **spinal roots of CN XI**.
  - *Vascular:* **Vertebral arteries**, anterior/posterior spinal arteries, and sympathetic plexus.
  - *Ligamentous:* **Membrana tectoria**, **Cruciate ligament** (vertical band), and **Apical ligament of the dens**.

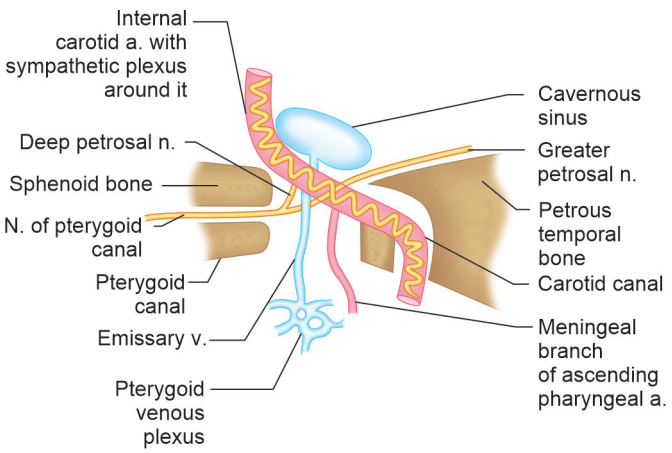

Fig. 11: Structures at the base and passing through the foramen lacerum. (a: artery; n: nerve; v: vein)

JAYPEE BROTHERS

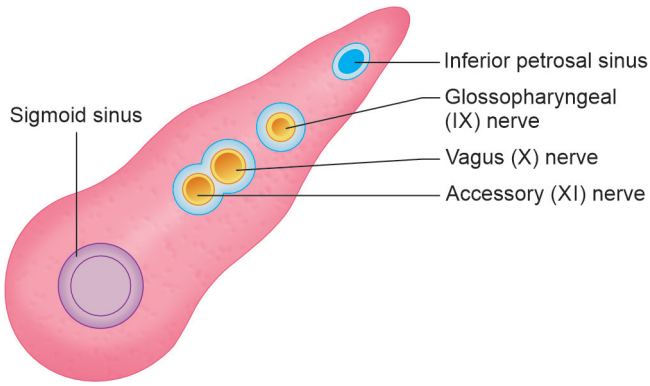

Fig. 12: Structures passing through the jugular foramen. (n: nerve)

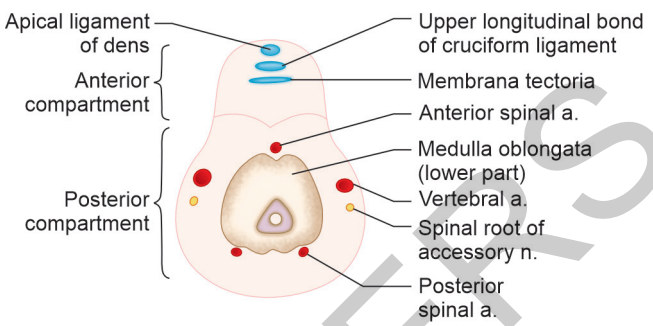

Fig. 13: Structures passing through the foramen magnum. (a: artery; n: nerve)

FORAMINA IN THE BASE OF THE SKULL

Foramen	Contents
Petrotympanic fissure	Chorda tympani and often anterior tympanic artery
Stylomastoid foramen	Facial nerve
Incisive canal	Nasopalatine nerve and terminal part of the sphenopalatine or greater palatine vessels
Greater palatine foramen	Greater palatine nerve and vessels
Lesser palatine foramen	Lesser palatine nerve and vessels
Palatine canal	Descending palatine vessels and the greater and lesser palatine nerves
Pterygoid canal	Runs from the anterior wall of the foramen lacerum to the pterygopalatine fossa and transmits the nerve of the pterygoid canal (vidian nerve)
Sphenopalatine foramen	Sphenopalatine vessels and nasopalatine nerve

SPECIALIZED ANATOMICAL REGIONS

The Orbit

- **Bony Walls:**
  - *Roof:* Frontal bone, lesser wing of sphenoid.
  - *Floor:* Maxilla, lacrimal, ethmoid, and sphenoid body.
  - *Medial Wall:* Ethmoid, lacrimal, maxilla, and sphenoid body.
  - *Lateral Wall:* Zygomatic bone and greater wing of sphenoid.

Cavernous Sinus

- **Location:** Lateral to the pituitary gland/sella turcica in the middle cranial fossa.
- **Structures Within:** Internal carotid artery and the **T1 sympathetic plexus** (controls *superior tarsal* and *dilator pupillae* muscles).
- **Nerves in Lateral Wall:** CN III, CN IV, CN V1, and CN V2.
- **Dorello's Canal:** A bow-shaped enclosure for the ***abducens nerve (CN VI)*** as it enters the cavernous sinus.

Sella Turcica (Turkish Saddle)

- A depression in the sphenoid body consisting of the **tuberculum sellae** (anterior), **hypophyseal fossa** (lodges the pituitary), and **dorsum sellae** (posterior).

JAYPEE BROTHERS

CLINICAL CORRELATES

Condition	Key anatomical involvement	Primary symptoms/Signs
Jugular Foramen Tumor	CN IX, X, XI	Dysphagia (swallowing), dysphasia (speech), difficulty shrugging shoulders (trapezius), and turning neck to the *opposite* side (sternocleidomastoid)
Extradural Hematoma	**Pterion** fracture; Anterior division of **Middle Meningeal Artery**	Young patients, road accidents, **lucid interval**, biconvex hyperdense shadow on CT (does *not* cross suture lines)
Cavernous Sinus Thrombosis	Spreads via 'dangerous area of the face' (facial/ophthalmic veins)	**Medial squint** (CN VI affected first), progressing to **external ophthalmoplegia** ('still eyeball')
Horner's Syndrome	Damage to T1 sympathetic plexus around the internal carotid	Miosis (constricted pupil) and Ptosis (drooping eyelid)
Anterior Fossa Fracture	Cribriform plate of ethmoid bone	**Anosmia** (loss of smell), **CSF rhinorrhea**, and **Raccoon eyes** (periorbital bruising)

QUESTIONS

1. All structures pass through foramen ovale *EXCEPT*:
a. Accessory meningeal artery b. Middle meningeal artery
c. Lesser petrosal nerve d. Emissary vein

2. Structure passing through the tendinous ring of Zinn:
a. Superior ophthalmic vein b. Trochlear nerve
c. Nasociliary nerve d. Lacrimal nerve

3. Mass in jugular foramen may result in all *EXCEPT*:
a. Difficulty in swallowing
b. Hoarseness
c. Difficulty in turning the neck to opposite side
d. Tongue deviates to same side

4. Incisive foramen transmits: *(NEET Pattern 2015)*
a. Greater palatine artery and greater palatine nerve
b. Greater palatine artery and lesser palatine nerve
c. Greater palatine artery and sphenopalatine nerve
d. Greater palatine artery and nasopalatine nerve

5. Choose the INCORRECT pair regarding the skull foramina and the structures passing through: *(PGIC)*
a. Maxillary nerve: Foramen rotundum
b. Vestibulocochlear nerve: Internal acoustic meatus
c. Anterior part of jugular foramen: Inferior petrosal sinus
d. Foramen spinosum: Middle meningeal artery
e. Superior orbital fissure: Optic nerve

6. Structures which passes through the internal auditory meatus are all *EXCEPT*: *(NEET Pattern 2014)*
a. Nerve of Wrisberg
b. Anterior inferior cerebellar artery
c. Superior vestibular nerve
d. Cochlear nerve

7. Cranial nerve related to apex of the petrous temporal bone:
a. IX b. VIII *(PGIC 2005)*
c. VII d. VI
e. V

8. Which structure passes through foramen magnum? *(AIPG 2010)*
a. Vertebral artery b. Internal carotid artery
c. Hypoglossal nerve d. Sympathetic chain

9. Mandibular division of trigeminal nerve passes through, which of the following marked foramen? *(AIIMS 2017)*
a. A
b. B
c. C
d. D

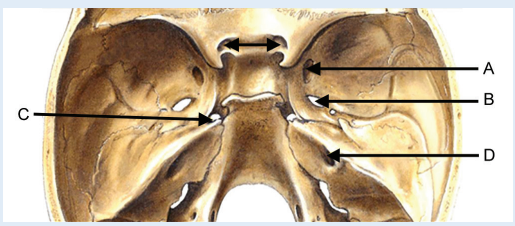

10. Which of the following structures do not pass through the marked foramen in the diagram? *(AIIMS 2014)*
a. Maxillary nerve
b. Sensory branch of mandibular nerve
c. Lesser petrosal nerve
d. Motor root of trigeminal nerve

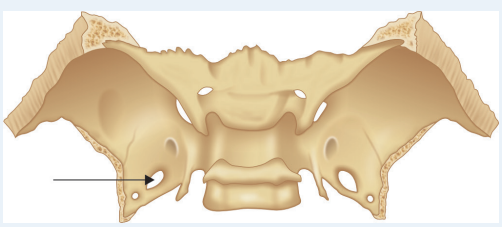

11. Maxilla doesn't articulate with: *(AIIMS 2015)*
a. Lacrimal bone b. Plate of sphenoid bone
c. Frontal bone d. Ethmoid bone

12. NOT a relation of sphenoid sinus: *(NEET Pattern 2015)*
a. Optic nerve b. Mandibular nerve
c. Maxillary nerve d. Vidian nerve

JAYPEE BROTHERS

Questions

13. Identify the structure marked with arrow: *(AIIMS 2017)*

a. Spinal accessory nerve
b. Abducent nerve
c. Vertebral artery
d. Labyrinthine artery

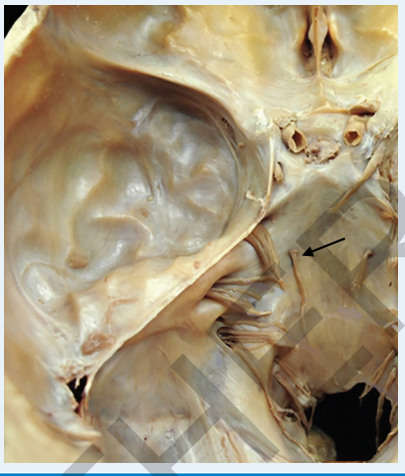

Answers

1. b. Middle meningeal artery
- 'MALE' structures pass through foramen ovale: Mandibular division of trigeminal nerve, Accessory meningeal artery, Lesser petrosal nerve, Emissary vein.
- Middle meningeal artery passes through foramen spinosum, along with nervus spinosus (branch of mandibular nerve).

2. c. Nasociliary nerve
- Nasociliary nerve passes inside (though) the common tendinous ring of Zinn.
- LFT nerves are left outside the ring (L - Lacrimal, F - Frontal, T - Trochlear).
- Superior and inferior ophthalmic veins usually remain outside the ring of Zinn, while passing through superior orbital fissure.

3. d. Tongue deviates to same side
- Hypoglossal nerve passes through hypoglossal canal (and not jugular foramen). Hence tongue doesn't show any deformity as such.
- Jugular foramen has cranial nerves 9, 10, and 11 passing through it, which supply the muscles of palate, pharynx and larynx (for speech and swallowing).
- A mass in the foramen leads to paralysis of these muscles and difficulty in speech and swallowing.
- Injury to spinal part of accessory nerve leads to paralysis of sternocleidomastoid muscle and difficulty in turning the neck to opposite side.

4. d. Greater palatine artery and nasopalatine nerve
- Incisive foramina are located behind the central incisor teeth in the incisive fossa of the maxilla (hard palate).
- It receives the nasopalatine nerves from the floor of the nasal cavity along with the greater palatine vessels supplying the mucous membrane covering the hard palate of the mouth.

5. e. Superior orbital fissure: Optic nerve
- Optic nerve passes through the optic canal.

6. b. Anterior inferior cerebellar artery
- Labyrinthine vessels passing through internal auditory meatus.
- Vestibulocochlear and facial nerves also pass through the meatus.
- Nerve of Wrisberg (nervus intermedius) is sensory component of facial nerve.

7. d. VI; e. V
- Apex of petrous temporal bone is related to cranial nerve V and VI.

8. a. Vertebral artery
- Foramen magnum has the two vertebral arteries and three spinal arteries passing through it.
- Internal carotid artery passes through the carotid canal in the petrous temporal bone at the base of the skull.
- Hypoglossal nerve passes the hypoglossal canal present in the occipital bone.
- Sympathetic chain begins at the foramen magnum and continues till the coccyx

9. b. B
- The diagram shows various foramina in the superior view of cranial cavity. Mandibular nerve (trigeminal) passes through the foramen ovale (Marker B).
- Key: Marker A: Foramen rotundum; C: Foramen lacerum; D: Internal auditory meatus

10. a. Maxillary nerve
- Maxillary nerve passes through foramen rotundum (not foramen ovale).
- The marked foramen in diagram is foramen ovale and structures passing through it are: Mandibular division of trigeminal nerve, Accessory meningeal artery, Lesser petrosal nerve, Emissary vein. (Mnemonic: MALE).

JAYPEE BROTHERS

Answers

11. b. Plate of sphenoid bone
- Maxilla bone generally do not articulate with plate (pterygoid) of sphenoid bone, though sometimes it may form an articulation with the orbital surface or lateral pterygoid plate of the sphenoid bone.
- Maxilla articulates with nine bones: Frontal, ethmoid, nasal, lacrimal, zygomatic, inferior nasal concha, vomer, palatine, and the other maxilla.

12. b. Mandibular nerve
- Structures related to sphenoid sinus are foramen rotundum (maxillary nerve), optic canal (optic nerve and ophthalmic artery), vidian canal (with nerve), internal carotid artery.
- Mandibular nerve is not related to sphenoid sinus.

13. b. Abducent nerve
- This diagram shows the cranial cavity and the marker is put at abducent nerve, piercing duramater to enter the Dorello's canal. The nerve emerges from the brainstem and runs upward between the pons and the clivus, then pierces the dura mater to run through Dorello's canal, before it enters cavernous sinus.

MANDIBLE

- **Development:** The mandible develops from the **first pharyngeal arch**.
- **Structure:** It contains **16 alveolar sockets** for teeth and is recognized as the **most mobile bone** of the skull.
- **Clinical Significance:** Local anesthesia for the inferior alveolar nerve is approached lateral to the **pterygomandibular raphe**, between the **buccinator** and **superior constrictor** muscles.

OSSIFICATION AND GROWTH

The mandible is the **second bone in the body to ossify**. Its formation involves complex processes:

Feature	Ossification type/Details	Relationship to Meckel's cartilage
Main Body	Both *intramembranous* and *endochondral*	Formed in relation to **Meckel's cartilage** (1st arch)
Secondary Processes	**Coronoid** and **condylar** processes	Ossify from secondary cartilages **not related** to Meckel's
Birth State	Consists of two halves connected by the ***symphysis menti*** (cartilaginous joint)	
Bony Union	Starts from below upward during the 1st year; completed by the end of the **2nd year**.	

NEURAL PATHWAYS AND LANDMARKS

The mandible features specific grooves and foramina that serve as conduits for several cranial nerve branches.
- **Lingual Nerve:** Passes just behind and inferior to the **third molar tooth** between the medial mandible and the gum mucosa. It is highly susceptible to injury during **tooth extraction** or local anesthetic administration.
- **Inferior Alveolar Nerve:** Enters the **mandibular foramen** and travels through the **mandibular canal**. A block of this nerve also typically anesthetizes the **mental nerve** (affecting the lower lip/chin) and the **lingual nerve** (affecting the tongue).
- **Mental Nerve and Vessels:** Exit through the **mental foramina**, located inferior to the **second premolar teeth**.
- **Additional Nerve Relations:**
  - ***Mylohyoid nerve:*** Runs in the **mylohyoid groove**.
  - ***Masseteric nerve:*** Passes through the **mandibular notch**.
  - ***Auriculotemporal nerve:*** Runs to the medial side of the neck.
  - ***Marginal mandibular nerve:*** Crosses the lower border of the mandible.

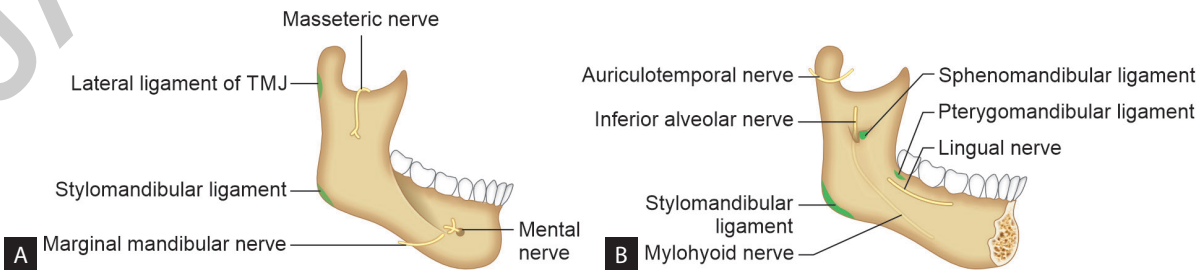

Figs. 14A and B: Attachment of ligaments and nerves related to the mandible. (A) Lateral surface of the right half of the mandible; (B) Medial surface of the left half of the mandible.

JAYPEE BROTHERS

Questions

1. **Mental foramen is located near:** *(AIIMS 2002)*
   a. First premolar of mandible
   b. Second molar of mandible
   c. Canine of mandible
   d. Canine of maxilla

2. **Which nerve is in close relation with root of the lower third molar?** *(NEET Pattern 2014)*
   a. Inferior alveolar nerve
   b. Chorda tympani nerve
   c. Lingual nerve
   d. Mylohyoid nerve

3. **To give inferior alveolar nerve block the nerve is approached lateral to pterygomandibular raphe between the buccinator and:** *(AIIMS 2002)*
   a. Temporalis
   b. Superior constrictor
   c. Middle constrictor
   d. Medial pterygoid

4. **The nerve block shown in the diagram is going to which of the following nerves:** *(AIPG Pattern 2019)*



   a. Inferior alveolar nerve
   b. Buccal nerve
   c. Lingual nerve
   d. Mental nerve

Answers

1. **a. First premolar of mandible**
   - The most frequent position (63%) of the mental foramen is in line with the longitudinal axis of the 2nd premolar tooth (not given in the choice).
   - On the medial surface of mandible is the mandibular foramen for inferior alveolar nerve and vessels.
   - The foramen leads into mandibular canal which opens on lateral surface of mandible at mental foramen, situated below the second premolar tooth.

2. **c. Lingual nerve**
   - Lingual nerve moves in a groove on the medial aspect of socket for lower third molar.

3. **b. Superior constrictor**
   - The coronoid notch is palpated with index finger and the needle is introduced 1 cm above the surface of last molar medial to finger (coronoid notch) but lateral to pterygomandibular raphe between the buccinator and superior constrictor muscle.

4. **a. Inferior alveolar nerve > c. Lingual nerve**
   - The block shown in the diagram is for **inferior alveolar nerve** (a branch of the mandibular nerve, the third division of the **trigeminal nerve**).
   - This procedure attempts to anesthetize the inferior alveolar nerve prior to it entering the mandibular foramen on the medial surface of the mandibular foramen causes blockage of the **inferior alveolar nerve** and the nearby **lingual nerve** by diffusion (includes supplying the tongue).
   - This causes patients to lose sensation in:
     - Mandibular teeth on one side (via **inferior alveolar nerve block**)
     - Lower lip and chin on one side (via **mental nerve block**)
     - Parts of their tongue and lingual gingival tissue on same side (via **lingual nerve block**);
   - An additional **buccal nerve** block is needed to anesthetize the cheek side of the mandibular molars.
   - **Note:** Buccal nerve is a branch of the mandibular (Trigeminal) nerve and transmits sensory information from skin over the buccal membrane (in general, the cheek) and from the second and third molar teeth.

TRIGEMINAL NERVE

TRIGEMINAL NERVE (CN V): OVERVIEW

- **Type:** The **thickest** and **largest** (in size) cranial nerve with the highest number of axons. It is a **mixed nerve** containing both sensory and motor components.
- **Development:** Supplies structures originating from the **first pharyngeal arch**.
- **Functional Components:**
  - **GSA (General Somatic Afferent):** Sensation from the face, scalp, teeth, and oral/nasal mucosa.
  - **SVE (Special Visceral Efferent):** Motor supply to muscles of mastication and others.

JAYPEE BROTHERS

for detailed information on anatomy books, visit our website www.ejaypee.com, for detailed information on anatomy books, visit our website www.ejaypee.com, for detailed information on anatomy books, v

SELF ASSESSMENT AND REVIEW OF ANATOMY

SARA (Self Assessment and Review of Anatomy) is a comprehensive, exam-oriented book designed to meet the demands of recent-pattern questions in INI-CET, NEET-PG, DNB, and FMGE.

Salient Features

- Human Anatomy Made Simple !
- Written by a subject expert with 22 years of teaching experience
- Includes theory, high-yield concepts, and explanatory questions
- Topics covered are Embryology, Histology, Neuroanatomy, Gross Anatomy, Surface Anatomy, and Radiological Anatomy
- Based on the latest editions of standard textbooks, including Gray's Anatomy, 43rd Edition
- Written in a simplified, student-friendly manner to improve both conceptual clarity, and exam performance
- Focuses on high-yield and frequently asked topics
- Provides detailed explanations for image-based and concept-based questions
- Covers important overlap areas between Anatomy and related subjects, taking interdisciplinary approach
- Includes simplified, fully coloured diagrams with meticulous labelling
- Handles controversial questions with standard textbook references
- Helps students revise the maximum content in the shortest possible time

Beyond the Standard Anatomy Textbook

The book also addresses topics in the grey areas, those that straddle the boundary between Anatomy and an adjacent specialty, are frequently asked in recent entrance examinations, yet remain inadequately covered in standard Anatomy textbooks. A typical example: Certain features of the nose now appearing in recent papers fall outside the scope of Gray's Anatomy, and dedicated ENT references have been integrated to bridge the gap. The same approach has been applied across Physiology, Pathology, Forensic Medicine, Surgery, Medicine, Paediatrics, Obstetrics & Gynaecology, Orthopaedics, Ophthalmology, Dermatology, Radiology, and Anaesthesia, taking interdisciplinary approach.

Reference texts consulted, to name a few, include Harrison's Principles of Internal Medicine; Schwartz's Principles of Surgery and Sabiston's Textbook of Surgery; Williams Obstetrics and Williams Gynaecology; Robbins & Cotran Pathologic Basis of Disease; Guyton & Hall Textbook of Medical Physiology and Ganong's Review of Medical Physiology; Sutton's Textbook of Radiology and Imaging; Miller's Anaesthesia; Campbell-Walsh Urology; CURRENT Medical Diagnosis & Treatment (across specialties); Scott-Brown's Otorhinolaryngology, Head and Neck Surgery; Parsons' Diseases of the Eye and Kanski's Clinical Ophthalmology; and Apley's System of Orthopaedics and Fractures.

Rajesh K Kaushal MD (Anatomy) has been teaching Anatomy to PG aspirants preparing for INI-CET, NEET-PG, DNB, and FMGE across India and abroad for the past 22 years. His teaching approach is built around the slogan HAMS - Human Anatomy Made Simple !, which is reflected in his classes, student reviews and books. He reaches over 1 lakh students annually across live and online channels, and actively interacts with students on modern online platforms for clarification of individual queries. His MD thesis: Immunogenetic Study of Autism through Flowcytometric Analysis was completed at the Department of Anatomy, All India Institute of Medical Sciences (AIIMS), New Delhi, India.

Buy from ejaypee

JAYPEE BROTHERS

Shelving Recommendation
ANATOMY

ISBN 978-93-7202-377-0

9 789372 023770