pee.com, for detailed information on obstetrics and gynecology books, visit our website www.ejaypee.com, for detailed information on obstetrics and gynecology books

Ultrasound *for* Congenital Fetal Anomalies

Editor
Sonal Panchal

Co-Editor
KV Sridevi



2nd Edition

Foreword
Chaitanya Nagori

JAYPEE

JAYPEE BROTHERS

Contents

1. **Normal and Abnormal Embryo** 1
   Chaitanya Nagori, Sonal Panchal

2. **Normal Fetal Anatomy in Second Trimester** 19
   Chaitanya Nagori, Sonal Panchal

3. **Trisomy 21 Screening in Pregnancy** 36
   Karthik Senthilvel

4. **Abnormalities of Central Nervous System** 52
   KV Sridevi, Binodini Mahendra Chauhan

5. **Ultrasound of the Fetal Face** 82
   KV Sridevi, P Madhavi Latha

6. **Basics of Fetal Echocardiography** 96
   Karthik Senthilvel

7. **Congenital Cardiac Abnormalities** 104
   BS Rama Murthy

8. **Noncardiac Thoracic Abnormalities** 137
   BS Rama Murthy, Sathiya Senthil, Swapna Gouru

9. **Gastrointestinal Tract and Abdominal Wall Abnormalities** 153
   Sathiya Senthil, Swapna Gouru, Damayanthi Y, Sankeerthy Reddy, Bhoini Preethi, Karshini Senthil, Gundra Priyanka

10. **Abnormalities of Fetal Urinary Tract** 187
    S Boopathy Vijayaraghavan

11. **Abnormalities of Placenta and Umbilical Cord** 237
    Sonal Panchal

12. **Skeletal Dysplasias and Musculoskeletal Abnormalities** 257
    Sumathi Natarajan, KV Sridevi, Sonal Panchal, Sanjay Vasoya

13. **Fetal Hydrops** 284
    KV Sridevi, Sonal Panchal

Index 301

JAYPEE BROTHERS

CHAPTER 11

Abnormalities of Placenta and Umbilical Cord

Sonal Panchal

Placenta is the chief circulatory unit that supports the growing fetus through its low resistance blood flow.

FORMATION AND DEVELOPMENT OF THE PLACENTA

With implantation of the embryo in one of the endometrial lips there are several changes occurring in the endometrium that chiefly include proteolytic and immunosuppresion mechanisms for acceptance of the foreign body—the embryo. Progesterone secretion from the corpus luteum and hCG produced by the implanting embryo, together lead to the formation and development of the chorionic tissue, which is the first step towards placentation. In the earlier stages the chorionic tissue is all around the gestational sac but as the embryo grows there is a self selection of the most vascular area expected. It is in this area of the endometrium that the chorionic tissue invades deeper and therefore appears more thick. The chorionic tissue in the rest of the area surrounding the gestational sac starts regressing. The regressing part of the chorionic tissue then is known as chorion leave, whereas the part which becomes thicker and penetrates deeper and is functionally active in allowing the uterine blood flow to reach the embryo is known as chorion frundosum **(Fig. 1)**. It is the chorion frundosum that will develop ultimately into placenta.

After 3–4 weeks of implantation, intermediate trophoblast invades maternal spiral arteries. This leads to disruption of

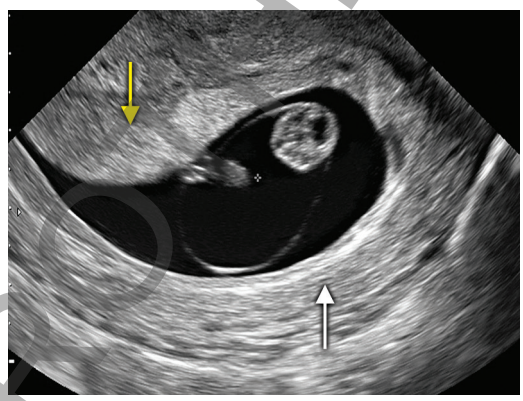

Fig. 1: B-mode image of the gestational sac showing thickened chorion frundosum (yellow arrow) and thin chorion leave (white arrow).

extracellular matrix and replacement of maternal endothelium by cells of trophoblastic origin. This leads to development of low resistance vascular bed with large capacitance.[1] There is conversion of highly muscular spiral vessels into nonmuscular placental vessels **(Fig. 2)**. Conversion of the vasculature occurs in two phases. First phase starts at around 8 weeks and the second one at around 18 weeks. The fall in resistance is fast till 12 weeks, with the initial phase of conversion in the type of vasculature and then slows down till 22 weeks. Beyond 22 weeks till term further changes in the placental vasculature in terms of lowering resistance is minimal.

Failure of this conversion of high resistance to low resistance vascular system leads to secretion of vasoactive substances from placenta and induces maternal hypertension **(Fig. 3)**. Though a complete failure

JAYPEE BROTHERS

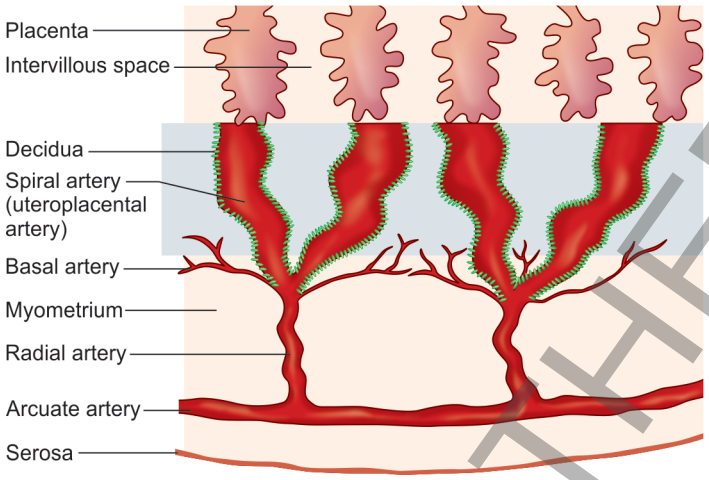

Fig. 2: Diagrammatic representation of vascular changes of normal placentation.

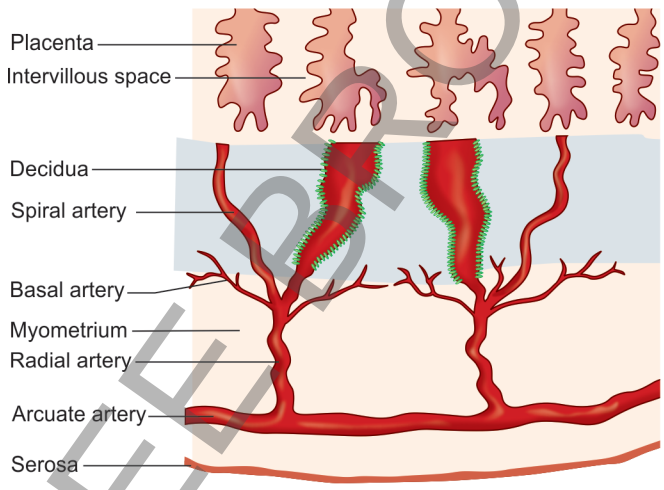

Fig. 3: Diagrammatic representation of vascular changes of abnormal placentation.

of this conversion will lead to first trimester abortions most commonly due to inability to support the vascular and nutritional needs of the growing fetus, partial failure of conversion will lead to pregnancy-induced hypertension (PIH) and fetal grwoth retardation (FGR) in late second and third trimester, depending on the severity.

It is a consequence of multiple factors:

- Primary defect in invasive trophoblasts
- Endocrine, immunological and inflammatory phenomena which regulate the interplay between maternal and fetal factors.

The pathophysiology that works in development of FGR is as follows:

Inadequate trophoblastic invasion, which leads to nondilatation of the uterine vessels as a result the placental perfusion is reduced, leading to inadequate villous circulation in turn leading to low oxygen levels in umbilical cord blood and therefore vascular changes in the fetus as a result of stimulation of chemoreceptors. This means the cause is diagnosed by high resistance in the uterine arteries and the results are shown asvascular changes in umbilical cord and fetal vessels.

JAYPEE BROTHERS

Though this chapter is dedicated to abnormalities of placenta and the umbilical cord and not on PIH and FGR, no mention about the vascular abnormalities may leave the discussion incomplete.

During pregnancy there is a persistent fall in the resistance of uterine and umbilical arteries, with increase inpeak systolic velocity, whereas there is a slow but steady rise in the resistance of middle cerebral artery (MCA) which is considered a representative of fetal circulation. A reverse trend in any of these vessels is indicative of placental insufficiency and may lead to PIH or FGR **(Figs. 4 and 5)**.

Placenta has about 50% reserve and so these changes will become evident only when there is compromise of more than 50% of placental circulation. In the initial phases, it is only dilatation of the middle cerebral arteries and reduced resistance that compensates for increased resistance of the umbilical arteries. When umbilical artery resistance increases significantly and the diastolic flow is significantly reduced the resistance index ratio of MCA to umbilical artery (CPR) becomes one or less than one. This can be taken as a cut off for prediction of bad pregnancy prognosis. An absent or reverse diastolic flow in the umbilical artery is taken as a strongly suggestive sign of fetal morbidity and a high risk of fetal mortality **(Figs. 6 to 9)**. MCA resistance persistently falls to compensate for this reduced oxygenated blood supply through the umbilical cord, but fails at a certain point. When this happens, there is lactic acidosis, cerebral edema and paradoxical reversal of MCA resistance to normal. This phase is considered to be an irreversible stage of fetal cerebral damage. There is also a circulatory paralysis and fetal or neonatal death is almost always suspected.

After that short discussion on placental vascular abnormalities now considering other abnormalities of the placenta and umbilical cord.

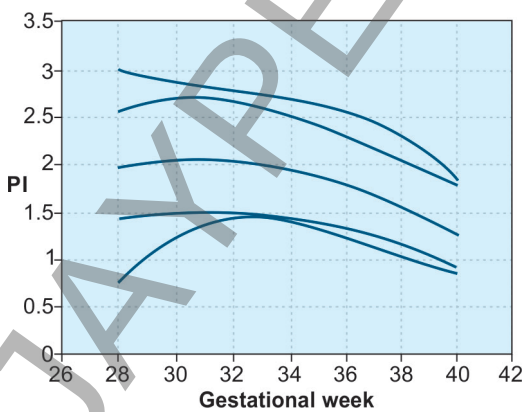

Fig. 4: Nomogram of values of middle cerebral artery pulsatility index (PI) with changing gestational age.

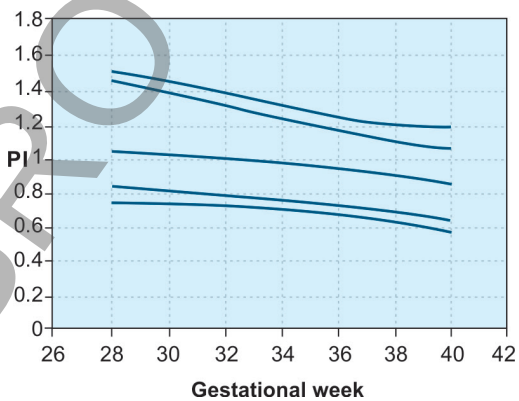

Fig. 5: Nomogram of values of umbilical artery pulsatility index (PI) with changing gestational age.

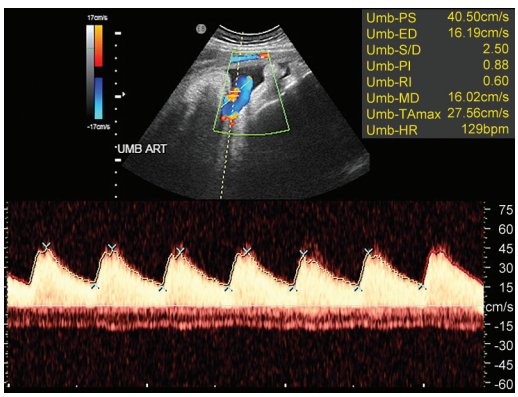

Fig. 6: Normal umbilical artery flow pattern.

JAYPEE BROTHERS

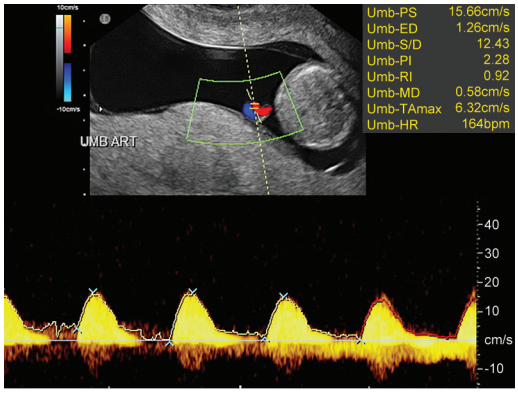

Fig. 7: Absent diastolic flow in umbilical artery.

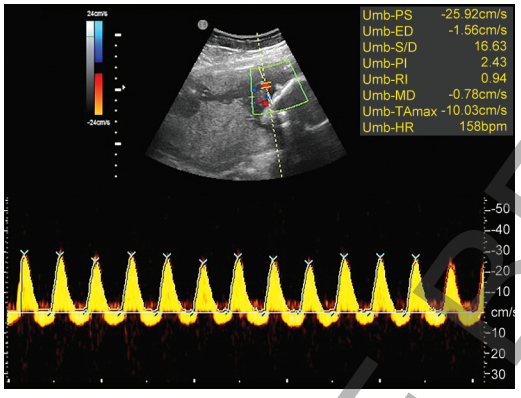

Fig. 8: Reversed diastolic flow in umbilical artery.

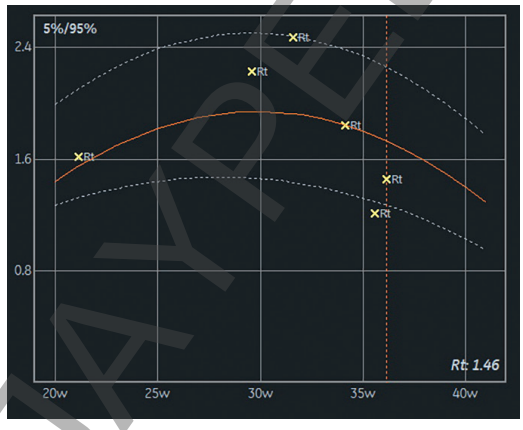

Fig. 9: Plotting of MCA PI on the nomogram shows paradoxical reversal (rise) of the MCA resistance.

Abnormalities of placenta may be divided under following heads:

- Size
- Texture
- Shape
- Location
- Penetration
- Cord attachment.

ABNORMALITIES OF PLACENTAL SIZE

The size of the placenta can be assessed as its extent or thickness. Normal placental thickness in mm is equal to gestational age in weeks +/– 10 mm at the thickest part of the placenta, which is at the point of cord insertion usually **(Fig. 10)**.[2]

There are no criteria defined on the normal or abnormal extent of the placenta, but generally narrow placenta is thick and broad placenta is thin. Ideally both parameters must be combined.

Three-dimensional (3D) ultrasound can be used to calculate placental volume.

Small Placenta

Small placenta is seen in:

- Intrauterine infections—chronic
- First trimester or preconceptional diabetes mellitus or glucose intolerance

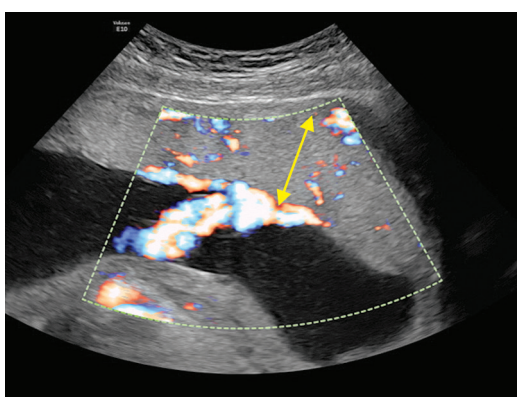

Fig. 10: Normal placenta with cord insertion. Measurement of placental thickness is shown by double sided arrow.

JAYPEE BROTHERS



Fig. 11: B-mode ultrasound image shows thin placenta.



Fig. 12: B-mode ultrasound image of thick—large placenta.

- Chromosomal abnormalities
- FGR of any cause
- Severe polyhydramnios—in these patients pacenta is not actually thin but because of abundant fluid, it gives an erroneous feel of thin placenta **(Fig. 11)**.

Large Placenta

Large placenta is seen with **(Fig. 12)**:

- Fetal hydrops
- Acute gestational infections
- Maternal anemia
- Placental mesenchymal dysplasia: These patients have a high incidence of growth restriction and fetal demise. The placenta shows anechoic areas due to cystic changes in stem villi.
- Aneuploidies
- Triploidy
- Placental hemorrhage
- Molar pregnancy
- Beckwith-Wiedemann syndrome—macrosomia, macroglossia, visceromegaly increased susceptibility to childhood tumors.

TEXTURE ABNORMALITIES OF THE PLACENTA

Normal placenta has a homogenous texture. Abnormal texture may be in the form of:

- Calcifications
- Lakes

Placental Calcification and Grading

Calcifications in the placenta was thought to be related with the circulatory status of the placenta. It is known that towards the end of the third trimester as a preparatory process for delivery of the fetus and the placenta, the placental vasculature starts regressing by calcification of the vascular walls. This means more calcification in the placenta means more mature placenta and this can be graded as **(Figs. 13A to C)**.

- *Grade 0:* Homogenous placenta
- *Grade 1:* Indentations in chorionic plate
- *Grade 2:* Basal stippling of placenta
- *Grade 3:* Calcification (is more commonly seen in smokers and in patients on aspirin or heparin prophylaxis).

Stating placental grading is not required in current scenario as calcification is no longer regarded as consistently associated with growth restriction, fetal distress in labor, PIH, diabetes or lung maturity.[3]

Placental Lakes (Fig. 14)

Placental lakes are anechoic areas in the placenta. These are almost universally seen after 25 weeks and are of no clinical significance. Lakes are formed by fibrin deposits that are a result of pooling of blood in perivillous spaces. These are more common in peripheral parts of placenta.

JAYPEE BROTHERS

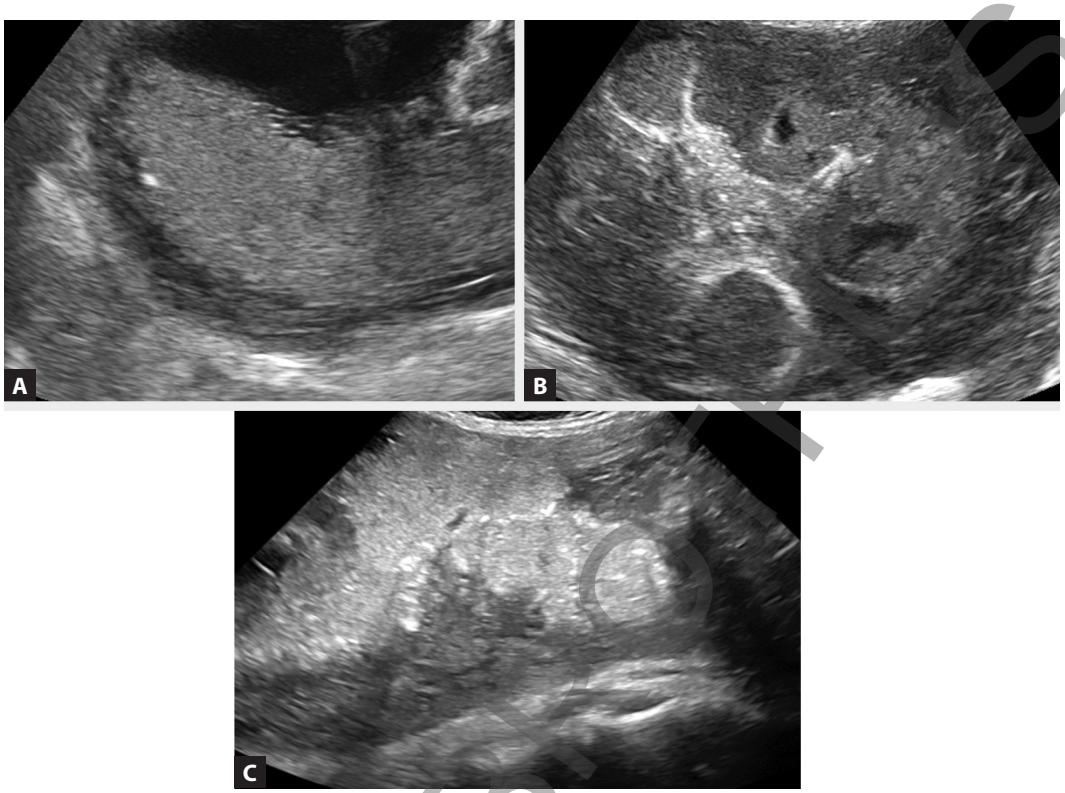

Figs. 13A to C: Placenta grade 0, 1, 2 (A through C).



Fig. 14: Anechoic areas in the placenta—known as placental lakes.

But anechoic areas in the placenta may be also due to:

- Subchorionic hematoma
- Intervillous thrombosis
- Septal cysts
- Infarcts from retroplacental hematoma

Subchorionic Fibrin Deposits

These are triangular or rectangular hypoechoic spaces with convex borders. These are of no clinical significance.[4]

Intervillous Thrombosis

This is due to fetal hemorrhage in intervillous spaces. These are of significance in fetuses with Rh incompatibility.[5]

Septal Cysts

Septal cysts are cystic areas in between cotyledons and again are of no clinical significance. Though if larger than 45 mm across, these may be associated with growth restriction.

JAYPEE BROTHERS

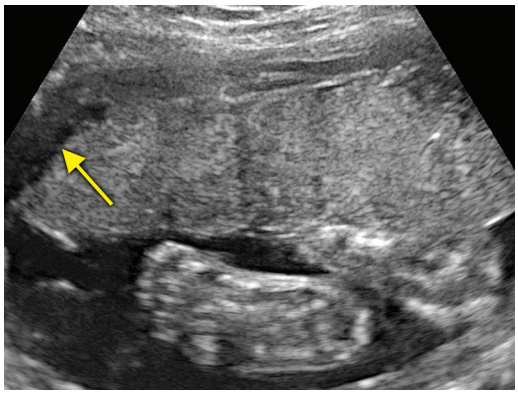

Fig. 15: Anechoic area seen between the placenta and the myometrium—retroplacental hematoma.

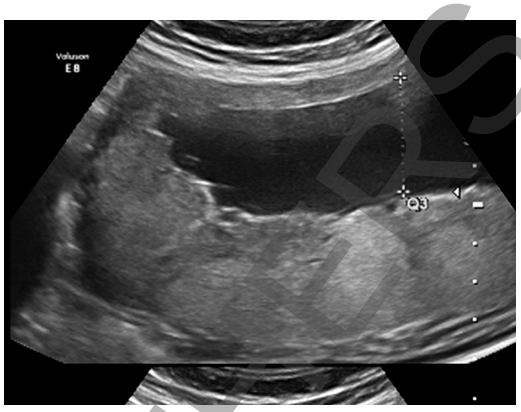

Fig. 16: Normal placenta.

Placental Infarcts

Infarcts in the placenta may result from retroplacental hematomas or thrombotic occlusion of fetal arteries.

Small ones are of no clinical significance but the larger ones may cause severe growth restriction and sometimes also fetal demise **(Fig. 15)**.[6] These are echogenic when fresh but become anechoic later. During the transition process these may be at times difficult to identify on scan. Some of these may also calcify and become densely hyperechoic.[6]

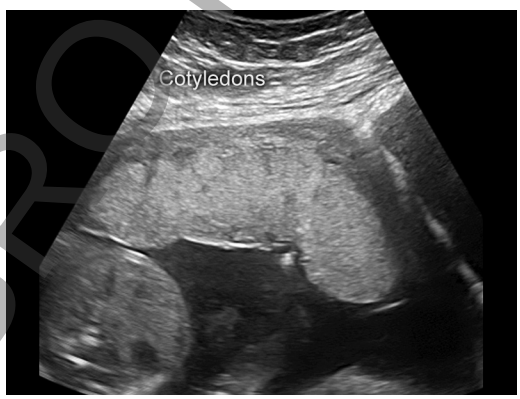

Fig. 17: Circumvallate placenta.

PLACENTAL SHAPE

Normal shape of the placenta is biconvex, with one surface attached to the uterine wall and another convex surface is its free surface **(Fig. 16)**. It is thickest in the center, which is where the umbilical cord is normally attached and thins out towards periphery.

Abnormalities of the Placental Shape

Abnormalities of the placental shape may be:

- Placenta membranacea
- Circumvallate placenta
- Horseshoe placenta
- Annular or ring-shaped placenta.

Placenta Membranacea

This is a rare entity. The entire chorion is covered by villi and large part of this placenta is dysfunctional.[7] About 1/3rd of these placentas are abnormally adherent. It often covers the internal os. Because of these two reasons, these placentas are commonly associated with recurrent antepartum heamorrhage, growth restriction and postpartum hemorrhage.[8]

Circumvallate Placenta

In this type of placenta, the chorionic plate is smaller than basal plate and therefore membranes fold over themselves and insert close to the center instead of at periphery **(Fig. 17)**. It may be complete or partial. It is difficult to diagnose antenatally. But on 3D US apprears like a tire.

Partial variety is clinically insignificant. The complete variety may lead to placental

JAYPEE BROTHERS

abruption, growth restriction, perinatal mortality and fetal growth restriction.[9]

It has thickened rolled ridge of membranes with uplifted placental shelf.[10] It often shows lucent areas in the extrachorial part of placenta due to infarcts and hematomas.

PLACENTAL LOCATION

Normally the placenta is located in the fundus or upper part of the body of the uterus. In this region of the uterus it may be located anteriorly, posteriorly or on the sides. Positions other than this are considered abnormal. When located in the lower segment of the uterus, placenta has higher risk of hemorrhagic complications. These placentas are known as placenta previa.

Depending on how low the lower edge of the placenta extends, these placentas may be graded as **(Figs. 18 and 19)**:

- *Grade I:* Lower segmental—distance from internal os <10 mm.
- Grade II: Marginal, when the lower margin of the placenta is at the margin of the internal os.
- *Grade III:* Incomplete, when the lower margin of the placenta, partially covers the internal os.
- *Grade IV:* Complete, when the internal os is fully covered by the placenta.

Risk of postpartum hemorrhage (PPH) is higher when the distance between the internal os and lower edge of placenta is <4 cm.[11]

Risk of placenta preavia is more with:

- Previous CS
- Previous surgeries on uterus
- Previous vigorous curettage
- Multiparity
- Advanced maternal age.

But approximately 90% of low lying placentas at 20 weeks have a tendency to migrate up to normal position at term. Therefore, diagnosis of placenta previa and its grade must not be made before the end of 2nd trimester.[12] Placentas with thin lower edge are less likely to migrate as compared to those with thick edge.[13]

Placental Migration

Placental migration is a consequence of:

- Formation of lower uterine segment
- Placental trophotorphism.

Placental Trophotorphism

This term is used to describe preferential proliferation of trophoblastic villi in regions of better endometrial supply and atrophy of the villi in the region of poor blood supply.[14]

This theory can explain regression of placenta previa, succenturiate placental lobes and abnormal cord insertions in placenta.

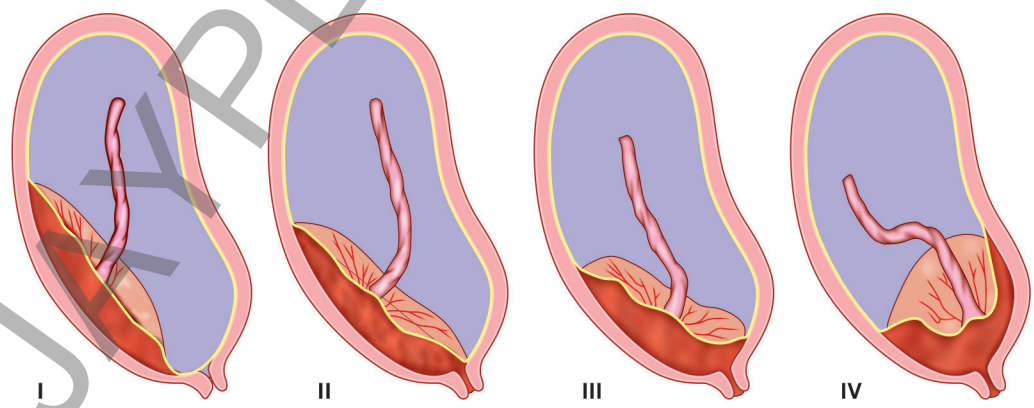

Fig. 18: Diagrammatic representation of grades of placenta previa.

JAYPEE BROTHERS

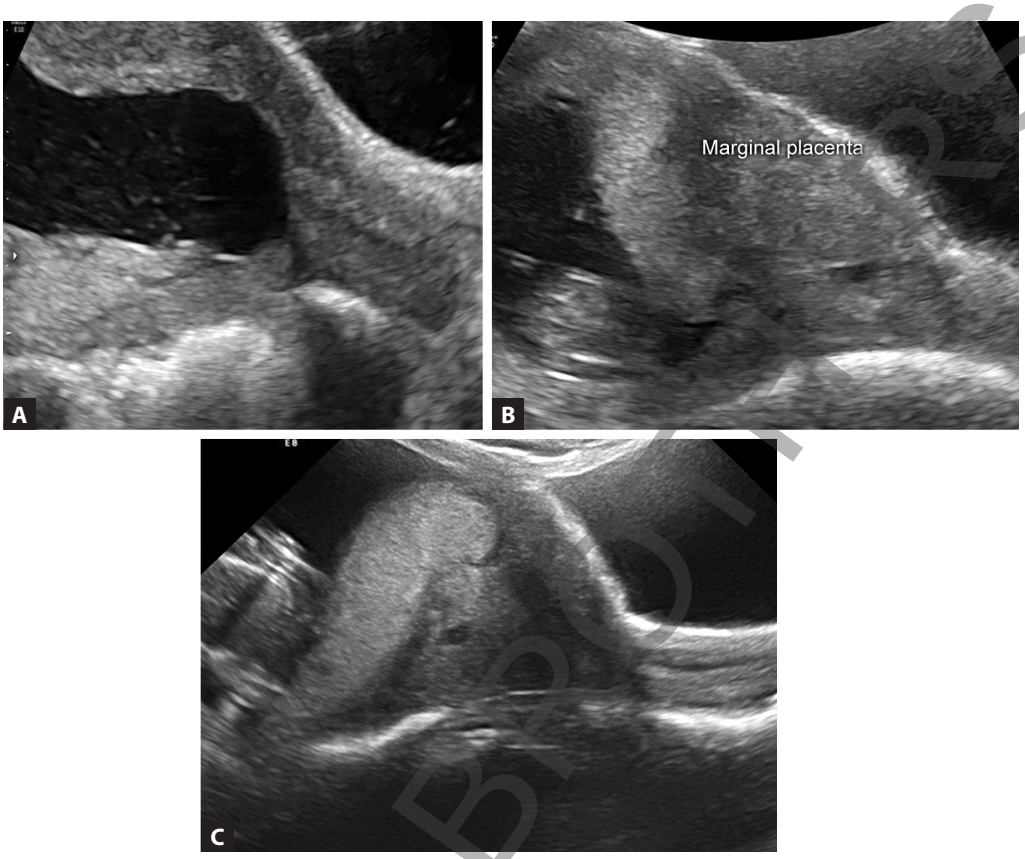

Figs. 19A to C: (A) Low lying placenta; (B) Marginal placenta previa; (C) Complete placenta previa.

When placenta migrates, the raw/just opened up surface of the uterus may bleed leading to antepartum hemorrhage. But bleeding with placental migration is not life-threatening and will not lead to the need of premature delivery usually. Antepartum bleeding can be more correlated with the cervical length and presence of echo-free space in lower edge of placenta, overlying the internal os.[15]

MANAGEMENT STRATEGY FOR PREGNANCIES WITH LOW LYING PLACENTA

- Distance between the lower edge of placenta and internal os if it is >20 mm—vaginal delivery is possible
- But if the distance is between 10 mm and 20 mm—most times vaginal delivery is possible.

Succenturiate Placental Lobe (Fig. 20)

This means a lobe of the placenta distant from main placenta. This may be a lobe with vessels not commencing out of this lobe. But at times fetal vessels may commence from these lobes to merge with main placenta to form the cord.[16] These vessels are more likely to rupture at labor or at the time of rupture of membranes and can lead to fetal demise. This is especially likely because these vessels may be close to or pass over the internal os and get damaged and also because these may

JAYPEE BROTHERS

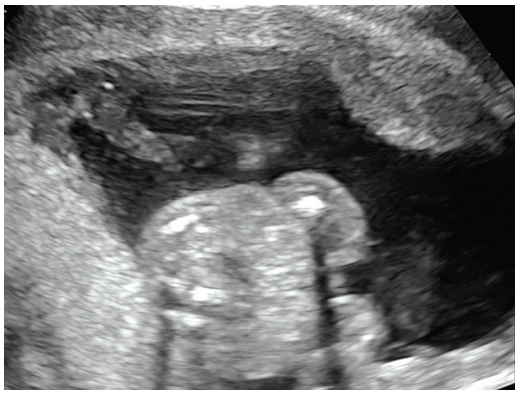

Fig. 20: Succenturiate lobe of placenta seen on the anterior wall with the main placenta on posterior wall.

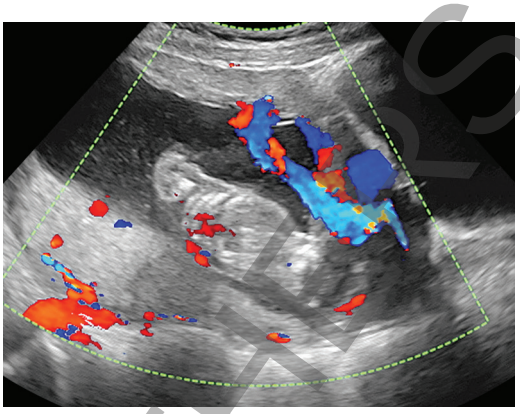

Fig. 21: Vasa previa.

not be protected by Wharton's jelly. Retained placenta and PPH are common complications with succenturiate lobe of placenta.[16]

Vasa Previa (Fig. 21)

When the cord vessels are the presenting structures it is known as vasa previa. It is different from placenta previa.

This is commonly associated with succentuariate lobe, velamentous or marginal cord insertion.

Placental Invasion (Abnormally Adherent Placenta)

Normally the placenta is attached to the myometrium of the uterus, but a clear interface is always seen between the placenta and the myometrium and this is known as retroplacental space **(Fig. 22)**. Retroplacental space is a hypoechoic space of 10–20 mm in thickness.

Retroplacental space is irregular or interrupted in conditions like retroplacental hematoma, placental abruption and placental adherence. The retroplacental space becomes irregular in placental hematomas and abruption but is obliterated in abnormal placental invasion and abrasion. Whenever this space is not consistent, assessment of the underlying myometrium



Fig. 22: Normal placenta with intact retroplacental space (hypoechoic area between placenta and myometrium).

is mandatory to exclude myomas, adenomyosis or calcifications. Myomas need to be differentiated from uterine contractions, which disappear in 20–60 minutes.

Placental Invasion Abnormalities (Fig. 23)

- Placenta accreta
- Placenta percreta
- Placenta increta **(Fig. 24)**.

Placenta Accreta

Abnormal adherence of the placenta to myometrium. The placenta is adherent to but not invading the myometrium.

JAYPEE BROTHERS

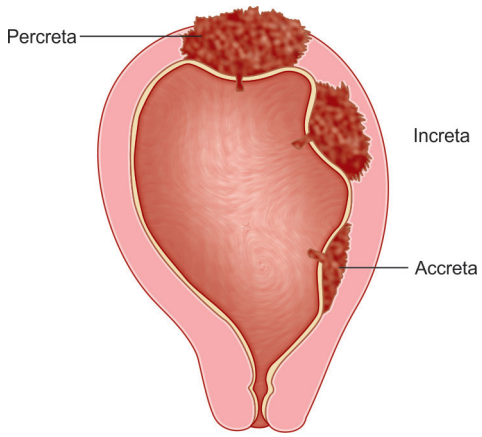

Fig. 23: Diagrammatic representation of types of placental invasion.

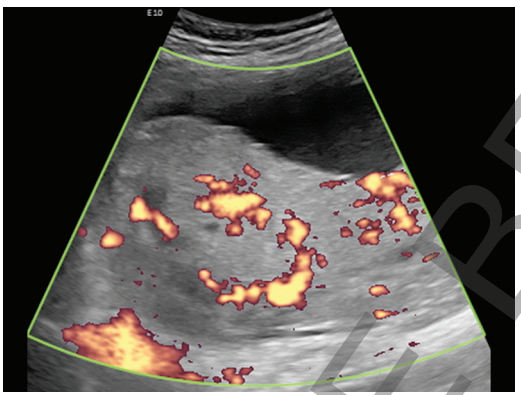

Fig. 24: Placenta increta.

It is consequential to a defect in the fibrinoid (Nitabuch's) layer of decidua underlying the placenta.[17] Placenta previa is more commonly seen in patients with placenta accreta.

Diagnosis of placenta accreta on ultrasound

- Normal retroplacental hypoechoic space is 10–20 mm thick, this reduces to <2 mm
- Interface between placenta and myometrium is lost
- Multiple anechoic lacunae are seen in the placenta
- Blood vessels running perpendicular to the myometrial vessels in a normal placenta are also seen running across into the myometrium.[18]

Placenta Increta

When the placental tissue invades into the myometrium, it is called placenta percreta. On ultrasound the retroplacental space is obliterated and on Doppler, placental vessels that are perpendicular to myometrial fibers and myometrial surace are seen penetrating into half or more thickness of the myometrium.

Placenta Percreta

When the placental tissue invades the entire thickness of the myometrium through to serosa and beyond, it is called placenta increta. Ultrasound diagnosis is by obliteration of the retroplacental space and extention of placental vessels across the myometrium, through to the serosa and may be even to the surrounding tissues.

Placenta percreta and increta are the more worse forms of an adherent placenta. These placental abnormalities may often cause uterine inversion and severe bleeding. These may almost always demand a hysterectomy at delivery of the baby.

Accuracy of ultrasound for antenatal detection of invasive placenta is fairly high and diagnosed antenatally can plan deliveries better and also save the mother from fatal complications.

The diagnostic accuracy of adherent placenta on B-mode and color Doppler studies are as follows:

B mode:

- Sensitivity 90.72%
- Specificity 96.94%
- Positive LR 11.01
- Negative LR 0.16.

Color Doppler:

- Sensitivity 90.74%
- Specificity 87.68%
- Positive LR 7.77%
- Negative LR 0.17%.

HEMATOMAS AROUND PLACENTA

- Retroplacental hematoma
- Subamniotic hematoma

JAYPEE BROTHERS

- Subchorionic hematoma
- Concealed hematoma.

Retroplacental Hematomas

Hematoma seen between basal plate of placenta and uterine wall is called a retroplacental hematoma. The fresh ones are isoechoic to placenta and difficult to identify. But the old ones are hypoechoic and cause evident widening of the retroplacental space on ultrasound. These may lead to villous infarction.

Subamniotic Hematoma (Fig. 25)

Hematoma between amnion and chorion is called a subamniotic Hematoma. The commonest location is at the placental cord insertion. It often occurs as a result of pulling of cord during delivery and therefore not an antenatal ultrasound diagnosis.

Only rarely it may be diagnosed antenatally and when large it is termed as Breus mole. This is commonly associated with growth restriction and fetal demise. On US it appears as an avascular hypoechoic lesion between chorion and amnion.[19]

Subchorionic Hematoma

Hematoma between fetal aspect of placenta and overlying chorionic membrane is termed as a subchorionic hematoma. It is more often seen in patients with cocaine abuse, smoking habits, hypertension, preeclampsia, anticardiolipin antibodies and may also occur due to blunt trauma. Its clinical presentation and significance is related to size of heamatoma and gestational age. It is associated with uterine irritation due to blood and may lead to preterm labor.[20]

Patients with subchorionic heamatoma have a higher risk of abortion, FGR, preterm labor, placental abruption or fetal distress, when associated with vaginal bleeding or uterine contractions.[20]

It can be treated with tocolytics and progesterone.



Fig. 25: Subamniotic hematoma.

PLACENTAL TUMORS

These can be divided into:

- Nontrophoblastic tumors
- Gestational trophoblastic disease
  - Complete or partial moles
  - Invasive mole
  - Choriocarcinoma.

Nontrophoblastic Placental Tumors

- Chorioangiomas
- Placental teratomas: are cystic and solid lesions, variably vascular and on surface of placenta. These may represent an unsuccesful twin pregnancy.[21]
- Metastasis from melanoma, lymphoma, leukemia and breast lesions, though very rare may be seen in the placenta.[22]

Chorioangiomas (Fig. 26)

These are the most common of nontrophoblastic placental tumors. These are benign tumours. The usually arise from close to the cord attachment on the placenta. These are well-defined tumors but variably vascular. The smaller ones are nonsignificant, but the larger ones, especially those larger than >50 mm across may lead to nonimmune hydrops, fetal cardiomegaly, polyamnios or growth restriction.[23]

JAYPEE BROTHERS

UMBILICAL CORD

Umbilical cord is the vascular and nutritional link between the mother's uterus and the fetus. It chiefly constitutes of two umbilical arteries and an umbilical vein and Wharton's jelly and all these covered in a single layer of amniotic epithelium. It has a helical structure with arteries and vein arranged as a spiral **(Figs. 27A and B)**. At term it is about 50–60 cm long and has a helical course with 10–11 coils in all.

Structure of the umbilical cord can be influenced by:

- Gestational age
- Amniotic fluid amount
- Composition of amniotic fluid
- Fetoplacental hemodynamics
- Maternal complications.



Fig. 26: Chorioangioma.

Like all other fetal parts, umbilical cord also follows a sort of a growth pattern and has a definitive consistent pattern that it follows. Its diameter progressively increases till 32 weeks and then plateaus. Its thickness is because of the caliber of arteries and the vein and also because of the amount of Wharton's jelly. The umbilical cord vessels also have an increasing caliber with the growing pregnancy **(Fig. 28 and Table 1)**.

Wharton's Jelly

Wharton's jelly consists of a collagen fibrillar network formed by canalicular structures and cavernous and perivascular spaces.[24] It is also supposed to have contractility comparable to smooth muscle cells and so participates in regulation of blood flow in the cord vessels.

It may have a role in bidirectional transfer of fluid and metabolites between amniotic fluid and cord vessels and also has metabolic functions. It protects the umbilical vessels from external pressure changes and minor injuries.

Abnormalities of the Umbilical

Abnormalities of the umbilical cord may be:

- Abnormal cord thickness
- Abnormal number of umbilical arteries
- Discordant umbilical arteries

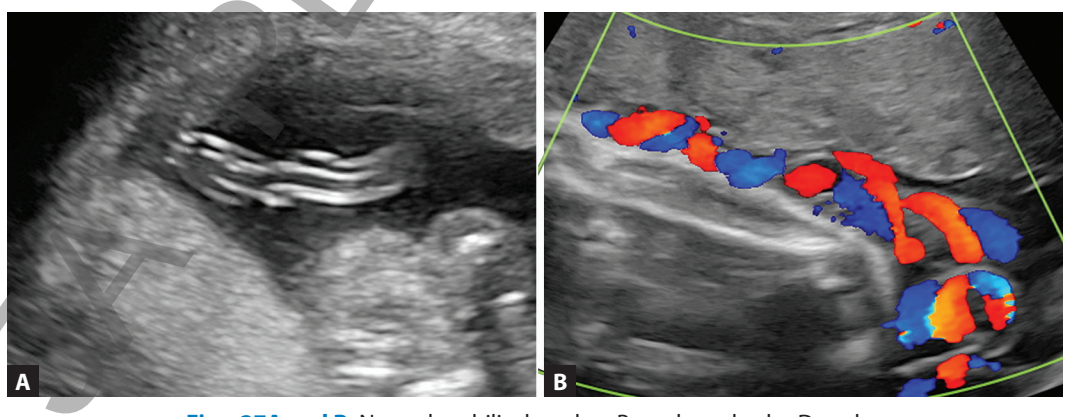

Figs. 27A and B: Normal umbilical cord on B mode and color Doppler.

JAYPEE BROTHERS

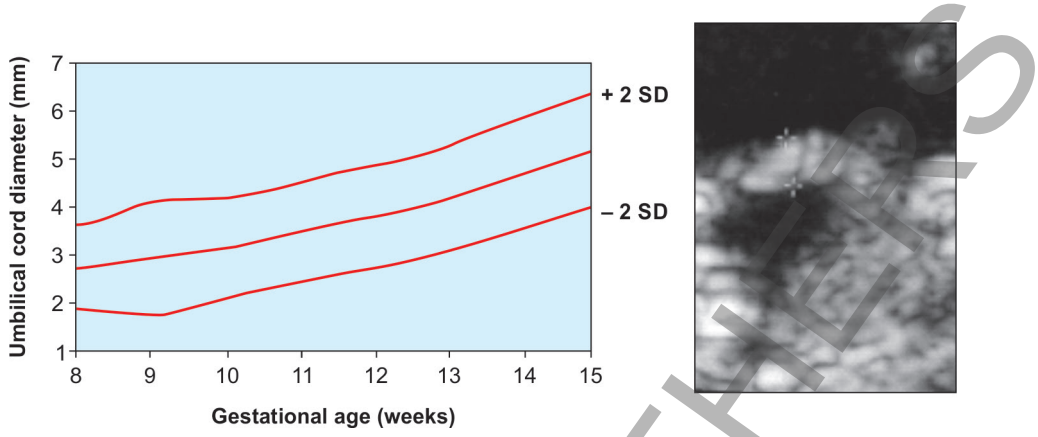

Fig. 28: Graph showing increasing umbilical cord diameter with increasing gestational age.

TABLE 1: Diameter of umbilical vessels.

Umbilical vessel	*16 weeks*	*At term*
Umbilical artery	1.2 +/–0.4 mm	4.2 +/– 0.4 mm
Umbilical vein	2.0 +/– 0.6 mm	8.2 +/– 0.8 mm



Fig. 29: Thin umbilical cord.

TABLE 2: Cord morphology in normal and thin cord.[25]

Characteristics	*Normal cord*	*Lean cord*	*p*
Cord length (cm)	57.6 ± 10.3	57.2 ± 11.5	NS
Coiling index	0.29 ± 0.09	0.18 ± 0.08	<0.001
Cord area (mm^2)	200.6 ± 34.6	87.6 ± 5.1	<0.001
Art area (mm^2)	14.3 ± 5.4	13.3 ± 5.3	NS
Vein area (mm^2)	50.5 ± 20.2	35.2 ± 11.5	<0.01
Jelly area (mm^2)	122.1 ± 33.4	25.7 ± 10.3	<0.001

- Abnormal length of the cord
- Abnormal coiling pattern of the cord

Abnormal Cord Thickness

Cord may be thin because of thin vessels and less amount of Wharton's jelly **(Fig. 29)**. It is known that thin umbilical cord vessels means less blood flow to the fetus.

Cord mophology in normal and thin cord:[25] Refer **Table 2**.

Flow parameters in normal and thin cord **(Table 3)**:[25] Lean umbilical cord after 20 weeks of gestation had **4.4 fold higher risk of having a SGA infant** than the one with normal cord (95% confidence interval, 2.16–8.85).[26] Cord thickness of **<10th centile for gestational age is an early marker of SGA infant and occurrence of intrapartum complications**.[27]

It is shown in this study by Bruch et al. that fetuses with thin cord and IUGR have significantly less amount of wharton's jelly and also smaller vessels as compared to normal fetuses **(Table 4)**.[28]

Amount of Wharton's jelly may be reduced due to reduction in extracellular fluid or

JAYPEE BROTHERS

TABLE 3: Flow parameters in normal and thin cord.

Characteristics	*Normal cord*	*Lean cord*	*p*
Artery PI	0.83 ± 0.14	0.85 ± 0.09	NS
Absolute vein blood flow	423.5 ± 93.2	293.6 ± 81.8	<0.001
Vein flow for fetal weight	126 ± 23.4	93.7 ± 17.8	<0.001
Vein flow velocity	9.0 ± 3.6	6.6 ± 2.7	<0.05

TABLE 4: Cord parameters in IUGR.

Cord parameters	*Normal*	*IUGR normal doppler*	*IUGR abnormal doppler*
Wharton's jelly	49.4 ± 2.2	40.4 ± 3.7	33.4 ± 2.6
Vessel areas	7.8 ± 0.3	6.6 ± 0.3	4.8 ± 0.3
Art wall thickness	654 ± 20	645 ± 23	525 ± 24
Vein wall thickness	465 ± 18	465 ± 18	390 ± 14

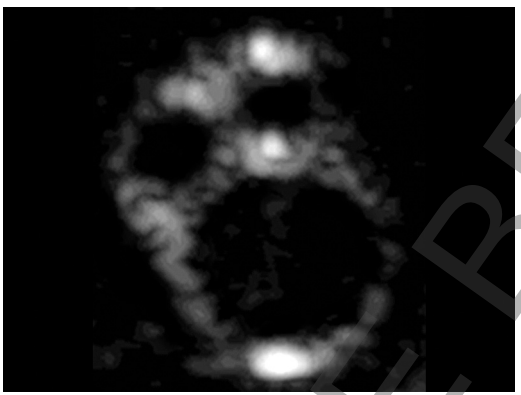

Fig. 30: Normal cord in transverse section.

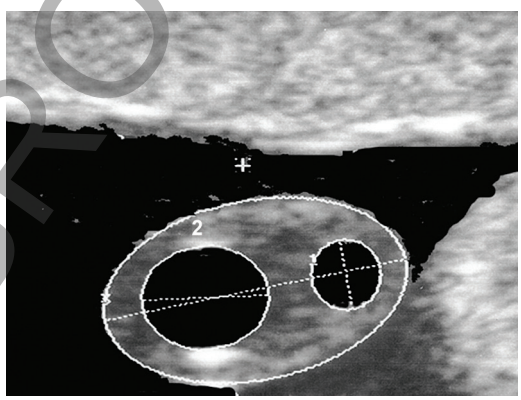

Fig. 31: Cord with single umbilical artery in transverse section.

matrix in patients with hypertensive disorders and gestational diabetes.

Thick cord may be due to:

- Cord tumor
- Urachal cysts
- Mucoid degeneration of cord
- Omphalomesenteric cyst
- It has also been used as one of the parameters to predict fetal macrosomia.[29]
- Increased amount of Wharton's jelly is seen in patients with gestational diabetes mellitus (due to increased accumulation of fluid and plasma proteins and is seen after 24 weeks of gestation).[30]

Abnormal Number of Umbilical Arteries

This is almost always a single umbilical artery. More than two umbilical arteries are not known. Single umbilical artery can be picked up on long section of the umbilical cord also, but is always better demonstrated on the transverse section of the cord. The normal cord that has two umbilical arteries and one umbilical vein shows a typical mickey mouse face appearance on transverse section **(Fig. 30)**. This is not seen in case of a single umbilical artery **(Fig. 31)**.

Incidence of single umbilical artery is:

- 0.5–2.9% in euploid fetuses

JAYPEE BROTHERS

- 1.5–7% in aborted fetuses
- 9–11% in aneuploid fetuses

There have been several studies on consequences of single umbilical artery and various studies have shown higher risk of chromosomal abnormalities and higher risk of IUGR. As for the risk of chromosomal abnormality the current concept is that as an isolated finding, this is of not much importance but when associated with other soft markers may increase the risk of chromosomal abnormalities.

Fetuses with single umbilical artery have a higher risk of:

- *IUGR (controversial):* As for the risk of IUGR, the current concept does not agree that single umbilical artery increases the risk of IUGR. Though fetuses with single umbilical artery have been shown to have a higher risk of intrapartum accidents and still births.
- Risk of congenital anomalies is calculated to be approximately 7 times higher. But unfortunately only 37% of these anomalies can be identified on prenatal scans.[31]
- Intrauterine death, the risk is more in third trimester.
- There is also an increased risk of intrapartum death.

Intrauterine death and intrapartum death may be attributed to two reasons. First is the absence of Hyrtl anastomosis, therefore no safety valve mechanism to fight sudden severe pressure changes. Second is that these cords have less Wharton's jelly, which further decreases in third trimester.

Single umbilical artery actually is thought to be an extreme form of discordant umbilical arteries.[31]

Discordant Umbilical Arteries (Fig. 32)

Difference in diameter of umbilical arteries of at least 1 mm in three different parts of cord. These arteries also show difference in impedence to blood flow.[32] But discordant umbilical arteries have not shown effect on the development of the fetus.



Fig. 32: Discordant umbilical arteries.

Discordant umbilical arteries are common with:

- Placenta bipartite (placenta divided into two parts)
- Placenta succenturiata (succenturiate lobe of placenta)
- Absent Hyrtl anatomosis
- Marginal cord insertion in placenta
- Velamentous cord insertion.

Hytrl anastomosis: Hyrtl anastomosis is the only vessel that connects the two umbilical arteries or their branches on placental surface, close to the site of cord insertion and equalizes the blood pressure between the territories of two arteries **(Figs. 33A and B)**. As it equalizes the pressure in the two umbilical arteries it actually works as a pressure release valve and protects the fetus and the cord from damages due to pressure changes. It is present in 95% of normal placentas. Absent Hyrtl anastomosisis is more frequently seen apart from fetuses with single umbilical artery, in patients with discordant umbilical arteries and in fetuses with velamentous cord insertion.

Hypothesis on the function of Hyrtl anastomosis:

1. It equalizes the pressure between the two umbilical arteries.
2. It allows uniform distribution of blood in the different regions of the placenta.
3. It acts as a safety valve for the placenta in case of compression or occlusion of one of the umbilical arteries or during uterine contractions.

JAYPEE BROTHERS

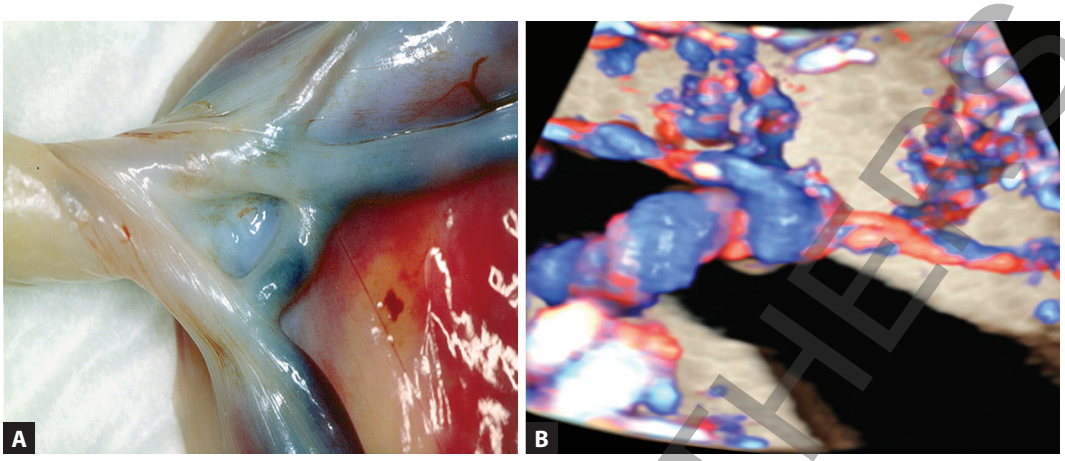

Figs. 33A and B: Normal Hyrtl anastomosis on dissection and on ultrasound.

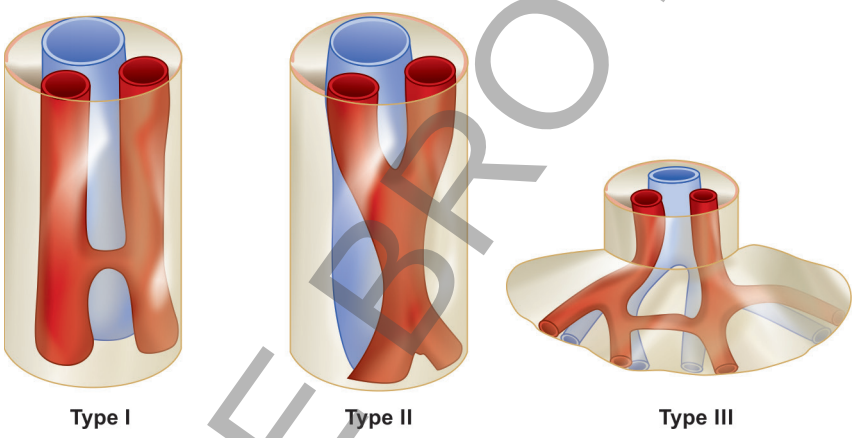

Fig. 34: Diagrammatic demonstration of three types of Hyrtl anastomosis.

Hyrtl anastomosis can be of three different types and are shown in the above **Figure 34**.

Velamentous cord insertion: Velamentous insertion of the cord is insertion of the cord in the membranes distant from placenta with vessels running in the membranes without being protected by Wharton's jelly **(Fig. 35)**.

Helical pattern of the umbilical cord: Umbilical cord starts coiling at 8 weeks. Number of coils at the end of 1st trimester are the same as at term. More cords are left twisted, though the significance of side is not yet understood.

Single coil is distance between the right outer surface of consecutive arterial coils.

Umbilical coil index (UCI) is reciprocal of this value and represents the number of coils in the cord. Umbilical coiling index is calculated as: Number of coils/cord length in cms **(Fig. 36)**.

Abnormal Coiling Pattern (Fig. 37)

- *Uncoiled:* No coils—straight umbilical arteries

  Uncoiled or hypocoiled cords are more seen in fetuses with FGR, maternal hypertensive disorders and aneuploidies.

JAYPEE BROTHERS

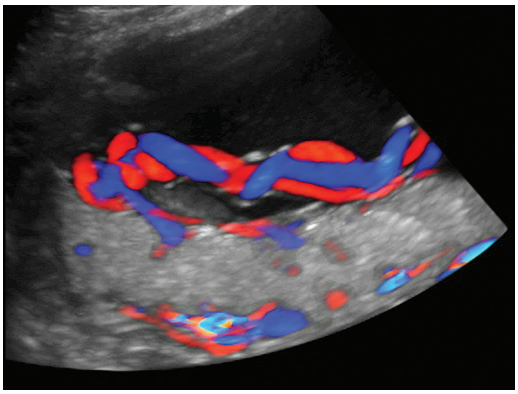

Fig. 35: Velamentous insertion of cord.

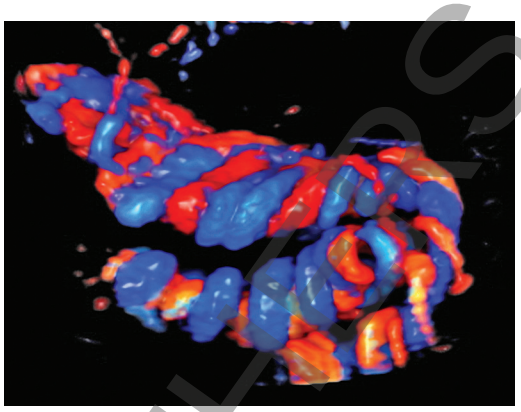

Fig. 38: Hypercoiled cord.

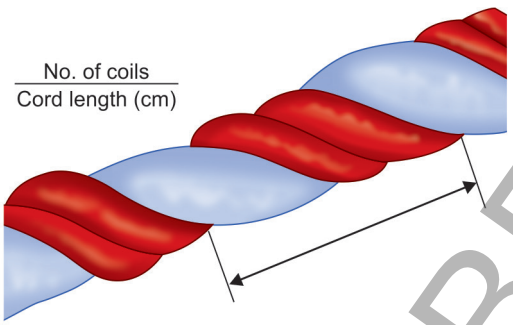

Fig. 36: Calculating umbilical cord coiling index.

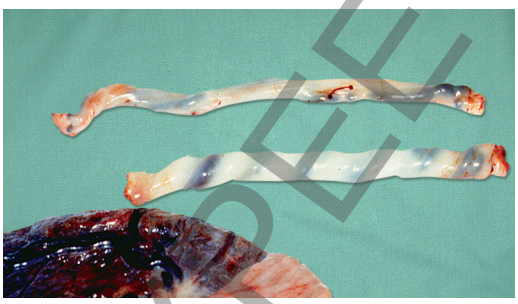

Fig. 37: Less coiled and highly coiled cord at birth.

- *Hypocoiled:* UCI <10th centile
- *Hypercoiled:* UCI >90th centile **(Fig. 38)**
- *Atypical coiling:*
  - Uncoordinated or aperiodic coiling
  - Supercoiling or spring like cord.

Though no definite correlations to pathologies have been established yet, abnormal coiling patterns are thought to influence perinatal outcome.

Supercoiled cords can be associated with pathologic intra-abdominal process leading to increase in resistance at umbilical ring and venous congestion in extra-abdominal umbilical vein.

Cord Cyst (Figs. 39A and B)

Cysts may be seen in the cord. These are of not much clinical significance, though was once thought to be a soft marker for T21.

Cord Round the Neck

This is commonly seen. Single loop is not of much importance as usually is not a complete circle. When there are two or more loops **(Fig. 40)**, it can strangulate the fetus. But at times even a single loop can cause strangulation when there is a knot **(Figs. 41A and B)**.

Knot in the cord may lead to severe fetal hypoxia and intrapartum death. This is usually difficult to identify on B-mode image. Though 3D power Doppler can be diagnostic. But it is important to remember that it must be suspected to identify. Very important sign that would suggest a possibility is intermittent fetal bradycardia.

To conclude, placenta and the cord, though most times neglected on the scan can be

JAYPEE BROTHERS

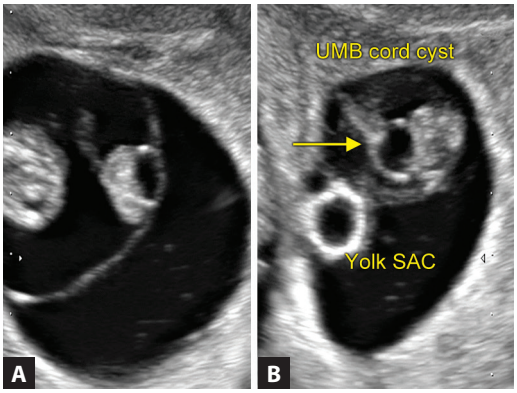

Figs. 39A and B: Umbilical cord cyst (arrow).

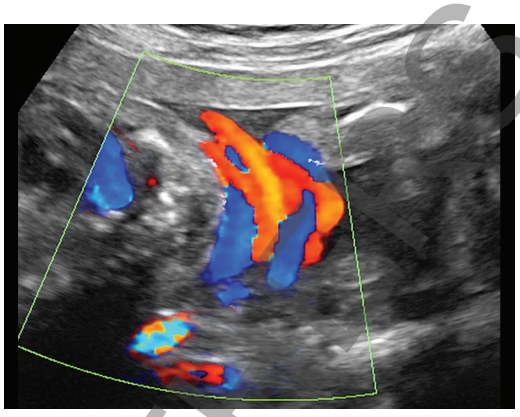

Fig. 40: Two loops of cord round the neck.

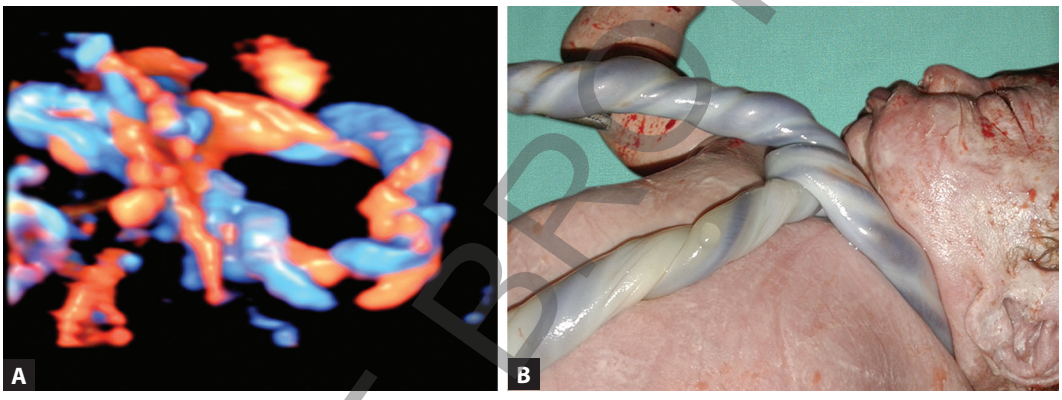

Figs. 41A and B: Single loop of cord round the neck with knot on color Doppler and in the neonate.

important indicators of fetal status and must become a part of routine anomaly scans.

REFERENCES

1. Kliman HJ. Am J Pathol. 1993;143(2):332-6.
2. Harris RD, et al. In: Ultrasound in Obstetrics and Gynecology, 4th edition. WB Saunders Co; 2000.pp.597-625.
3. McKenna D, et al. Acta Obstet Gynecol Scand. 2005;8491:7-10.
4. Spirt BA, et al. In: Diagnostic Ultrasound: a logical approach, 1st edition. Lippincott-Raven Publishers; 198. pp. 181-200.
5. Salaa Cm, et al. Am J Obstet Gynecol. 1995;17394:1049-57.
6. Jauniaux E, et al. J Clin Ultrasound. 1991;19:58-61.
7. Greenberg JA, et al. Obstet Gynecol. 1991;78(3 pt 2):512-4.
8. Wilkins BS, et al. Br J Obstet Gynecol. 1991;98(7):675-9.
9. McCarthy J, et al. J Ultrasound Med. 1995;14(1):21-6.
10. Oppenheimer L. J Obstet Gynecol Can. 2007;29(3):261-73.
11. Oyelese Y. Ultrasound Obstet Gynecol. 2009;34(2):123-6.
12. Ghourab S. Ultrasound Obstet Gynecol 2001;18(2):103-8.
13. Predanic M, et al. J Ultrasound Med. 2005;24(6):773-80.
14. Ghi T, et al. Ultrasound Obstet Gynecol 2009;33(2):209-12.
15. Saitoh M, et al. Gynecol Obstet Invest. 2002;54(1):37-42.

JAYPEE PROOF

16. Hata K, et al. Gynecol Obstet Invest. 1988; 25(4): 273-6.
17. Mazouni C, et al. Placenta. 2006;28(7):599-603.
18. Shih JC, et al. Ultrasound Obstet Gynecol. 2009; 33(2);193-203.
19. Bromley B, et al. J Ultrasound Med. 1994;13(11): 883-6.
20. Nagy S, et al. Obstet Gynecol. 2003;102:94-100.
21. Ahmed N, et al. J Clin Ultrasound. 2004;32(2): 98-101.
22. Altman JF, et al. J Am Acad Dermatol. 2003; 49(6):1150-4.
23. Prapas N, et al. Ultrasound Onstet Gynecol. 2000;16(6):559-63.
24. Vizza E, et al. Reprod Fertil Dev. 1996;8(5):885-94.
25. Di Naro, et al. Umbilical vein flow in fetuses with normal and lean umbilical cord. Ultrasound Obstet Gynecol. 2001;17:224-8.
26. Raio L, et al. Ultrasound Obstet Gynecol. 1999;13(3):176-80.
27. Ghezzi F, et al. J Clin Ultrasound. 2005;33(1): 18-23.
28. Bruch, et al. Human pathlogy. 1997;28(10): 1139-45.
29. Cromi A, et al. Ultrasound Obstet Gynecol. 2007;30(6):861-6.
30. Weissman A, et al. J Ultrasound Med. 1997;16 (10):691-4
31. Persutte WH, et al. Ultrasound Obstet Gynecol. 1995;6(3):216-29.
32. Raio L, et al. Obstet Gynecol. 1998;91(1):86-91.

JAYPEE BROTHERS

for detailed information on obstetrics and gynecology books, visit our website www.ejaypee.com, for detailed information on obstetrics and gynecology books, visit our web

Ultrasound *for* Congenital Fetal Anomalies

In this era of fetal medicine, a routine obstetrician feels very unconfident opining about the normalcy or otherwise of the fetus of their pregnant patients. But, it is not feasible to send the patients to specialists for every scan. This book is a strong guide and a supportive tool for the obstetricians to learn to do the basic antenatal scan thoroughly and systematically and differentiate between normal and abnormal. The book is made short and concise by including only the common abnormalities of their diagnostic ultrasound features with tips for close differential diagnosis also. This is a compact, precise, and to-the-point book on antenatal scan techniques and ultrasound features of common congenital fetal anomalies for an obstetrician to do antenatal scans for his or her patients.

Sonal Panchal MD PhD is an ultrasound consultant at Dr Nagori's Institute for Infertility and IVF, Ahmedabad, Gujarat, India. She is a versatile ultrasound specialist dedicated to the subject for more than 26 years. She has a high repute for her excellent scanning and teaching skills. She has a deep insight into gynecological and infertility related ultrasound. She has been one of the pioneers for the use of Doppler and 3D–4D ultrasound for infertility assessment and has several original papers and publications on the same. She is a very popular and passionate teacher in the field.

JAYPEE BROTHERS

Shelving Recommendation
OBSTETRICS & GYNECOLOGY

ISBN 978-93-7202-475-3

Buy from ejaypee

JAYPEE BROTHERS