com, for detailed information on orthopedics books, visit our website www.ejaypee.com, for detailed information on orthopedics books,

Case Based Orthopedics

A Viva and Exam Based Book



Editors
Samir Dwidmuthe
Sitanshu Barik

Forewords
Prashant Joshi
Pankaj Kandwal

JAYPEE

Contents

SECTION 1: HIP

1. **Examination of Hip Joint** 3
   Sitanshu Barik, Deepanjan Das, Priyanshu

2. **Tuberculosis of the Hip** 19
   Prashant Bhavani

3. **Nonunion Fracture Neck Femur** 33
   Ankush Mohabey

4. **Avascular Necrosis Femur Head** 46
   Mukund Madhav Ojha

5. **Perthes Disease** 56
   Varun Garg, Sharan Mallya

6. **Developmental Dysplasia of Hip** 68
   Sitanshu Barik, Saurabh Sah

7. **Slipped Capital Femoral Epiphysis** 79
   Lakshmana Das S

SECTION 2: KNEE

8. **Examination of Knee Joint** 91
   Sitanshu Barik, Deepanjan Das, Priyanshu

9. **Knee Multiligamentous Injury** 100
   Pratik Mahapatra, Arghya Kundu Choudhury

10. **Angular Deformity of the Knee** 117
    Mukund Madhav Ojha

11. **Recurrent Patellar Instability** 125
    Prashant Bhavani

12. **Osteochondroma of Knee** 138
    Amol Dubepuria

13. Congenital Dislocation of Knee **143**
Sitanshu Barik

14. Knee Arthritis **150**
Ankush Mohabey

SECTION 3: FOOT AND ANKLE

15. Examination of Foot and Ankle **165**
Sitanshu Barik, Deepanjan Das, Priyanshu

16. Clubfoot **174**
Sitanshu Barik

17. Congenital Vertical Talus **183**
Sitanshu Barik

18. Pes Planus **187**
Mukund Madhav Ojha

19. Pes Cavus: The High-arched Foot **193**
Vikash Raj

SECTION 4: SHOULDER

20. Examination of Shoulder **201**
Sitanshu Barik, Tanmay Joshi, Muhil Elvarasu

21. Shoulder Instability **214**
Prashant Bhavani

22. Rotator Cuff Injuries **225**
Aditya KS Gowda

23. Frozen Shoulder **241**
Ankush Mohabey

SECTION 5: ELBOW

24. Examination of Elbow **257**
Sitanshu Barik, Tanmay Joshi, Muhil Elvarasu

25. Angular Deformity of the Elbow **268**
Mukund Madhav Ojha

26. Elbow Arthritis **279**
Ankush Mohabey

SECTION 6: WRIST AND HAND

27. Examination of Wrist 291
Sitanshu Barik, Denish Chandrakar, Saurabh Meena

28. Radial Nerve Palsy 300
Amol Dubepuria

29. Ulnar Nerve Palsy 306
Amol Dubepuria

30. Carpal Tunnel Syndrome 312
Amol Dubepuria

31. Kienböck's Disease 316
Amey S Sadar

32. Dupuytren Contracture 322
Vikash Raj

33. Rheumatoid Arthritis Hand 326
Lakshmana Das S, Santosh Behera

SECTION 7: SPINE

34. Examination of Spine 347
Sitanshu Barik, Denish Chandrakar, Saurabh Meena

35. Tuberculosis of Spine 363
Deepankar Satapathy, Syed Ifthekar

36. Prolapsed Intervertebral Disc 384
Shubham Dakhode, Sawan I

37. Scoliosis 412
Aakash Jain

38. Torticollis 426
Aakash Jain

SECTION 8: OTHERS

39. Chronic Osteomyelitis 439
Amol Dubepuria

40. Nonunion 445
Ankush Mohabey

41. Malunion **456**
Amol Dubepuria

42. Swelling **463**
Vikash Raj

43. Gait **486**
Sitanshu Barik, Vishal Kumar

Index **493**

1 Examination of Hip Joint

Sitanshu Barik, Deepanjan Das, Priyanshu

The hip joint is the most common part of the musculoskeletal system considered for the purposes of residency exit examinations such as MS and DNB.

- Introduce yourself and get the consent of the patient or the parent of the child for examination.
- Note down the name, age, sex, race, and occupation of the patient.
- The patient should be adequately exposed while making sure that external genitalia are covered, and the patient is comfortable and relaxed. Explaining why you need to expose and the steps of examination will help in relaxing the patient and in establishing a good rapport. When examining a female patient, make sure that you have a female nurse or assistant. Examine the child with the parents by the side. Very young children may be examined in the parent's lap.
- First examine the normal or less symptomatic side first to establish the normal range of movement for the particular patient and to make the patient understand what is going to be done on the painful side.
- Steps of all procedures should be explained to the patient to ensure patient comfort and cooperation.
- Examine the patient in standing, sitting, walking, and lying down. Make sure that the patient lies on a hard surface to ensure that deformities are not concealed by a soft mattress.

HISTORY

- *Pain:*
  - Site: Pain related to the hip joint should be analyzed systematically. Discomfort localized to the groin generally indicates pathology within the hip itself, while pain felt along the anterolateral thigh is more typical of an upper lumbar origin, and pain at the back of the thigh usually suggests a lower lumbar source. If the pain gradually extends into the leg during exertion, producing the so-called "thermometer sign," lumbar canal stenosis should be suspected. In addition, pain situated laterally just above the greater trochanter in a characteristic C-shaped distribution often points toward femoroacetabular impingement. Careful attention to the exact site and radiation of pain, therefore, provides important diagnostic clues and helps in distinguishing hip pathology from referred pain arising from the spine.

JAYPEE BROTHERS

- Duration
- Onset (acute—traumatic/infective/reactive/muscular; insidious—degenerative, arthritic, osteonecrosis, and tuberculosis)
- Severity
- Progression [progressive, static, undulating course—chronic disease, undulating course with sudden increase—collapse in osteonecrosis or fracture, e.g., bone cyst or slipped capital femoral epiphysis (SCFE)]
- Character (sharp shooting pain of trauma, dull aching pain of early osteonecrosis and arthritis, and throbbing of infection)
- Temporal variation (diurnal) (night cries of tuberculosis, morning stiffness, and pain of inflammatory arthritis), pain present at first step—arthritis but pain appearing after exertion—uncommonly of hip joint origin except early osteonecrosis.

  Movement of pain (radiation of pain—pain at original site persists, referred pain—no pain at original site, shifting, and migration of pain)
- Precipitating and relieving factors:
  - Mechanical pain (e.g., osteoarthritis and impingement): Worsens with activity, improves with rest
  - Inflammatory pain (e.g., arthritis): Aggravated by rest, partially relieved on movement
- Associated features/negative history:
  - Multiple joint involvement → think of systemic arthropathy
  - Pain of spinal origin → must be differentiated based on site and pattern
  - Pregnancy-related history can be relevant.
- Limp: Note onset, association with pain, progression, and need for walking aids.
  Painless limp may indicate:
  - Congenital causes → developmental dysplasia of the hip (DDH), coxa vara, and dysplastic conditions
  - Healed disease with residual deformity → ankylosed hip after infection, ankylosing spondylitis
  - Neuromuscular disorders → poliomyelitis and cerebral palsy
- Limitation of movement: Suggests muscle spasm due to inflammation, enthesopathy, or cartilage injury, may occur after treatment of a primary disorder or following prolonged immobilization. Morning stiffness is a typical feature of inflammatory conditions.
- Deformity: Duration, onset, progression, limb length discrepancy, static or progressive
- Describe the event (usually trauma) into mode (high velocity—road traffic accident, fall from roof, low velocity—fall from standing height), site of injury, post injury mobility and ability to bear weight, injury to other regions, treatment received.

Negative history:

- Past history of infection or trauma
- Fever and constitutional symptoms—tuberculosis and neoplastic
- Night pain and night cry
- Drug intake—steroids, anticancer, antitubercular, antiretroviral, and antiseizure
- Childhood hip disorder—hip pain in childhood, surgery, hospital admission, and intravenous antibiotics
- Alcohol and tobacco intake
- Other joint involvement—pain, stiffness, and deformity

JAYPEE BROTHERS

- Bleeding disorders—easy bruise, prior blood transfusions, frequent bleeding episodes (gums commonly)
- Storage disorders—mental confusion and abdominal pain
- Shoe modification
- Small joint disease
- Pain opposite hip

Disability:
- Walking (aided or unaided)
- Side of using walking stick
- Sitting cross-legged
- Squatting
- Climbing stairs and coming down
- Ability to drive car/ride bike
- Effect on vocation
- Effect on recreation

Past history:
- Tuberculosis and its treatment
- Respiratory, renal, dermatological, neurological, or hematological illnesses
- Connective tissue disorders
- Organ transplantation and liver disease
- History of trauma and its management
- Congenital or developmental hip disorders and prior treatments
- Previous hip surgeries
- Diabetes and hypertension
- Assessment of work tolerance (important for planning treatment and anesthesia)

Personal history: Occupation, alcohol intake, diet, smoking, and menstrual history

Family history:
- Storage disorders, dysplasia, and inflammatory disorder
- Early deaths in family—genetic disorder

General physical examination:
- Orientation
- Built and nutrition
- Weight
- *Vitals:* Pulse, blood pressure, and respiratory rate
- *Hair:* Color and quality (nutrition)
- *Skin markers of tuberculosis: Lupus vulgaris* (appears as a chronic, painless, and brown-red plaque. It has a pink-red background with white structureless areas, yellow-white globules, white scale, and short and long linear vessels), *scrofuloderma* (appears as painless, ulcerated plaques with discharge, over affected lymph nodes, bones, or joints), *miliary tuberculosis* (appears as red papules and pustules in people with low immune resistance to the infection), *tuberculous chancre, erythema induratum of Bazin, and tuberculid.*
- *Neurocutaneous markers: Café-au-lait spots* (coffee-colored lesions on the skin), *neurofibromas* (soft, flat, or elevated tumors on the skin), *port-wine stain* (mark on

JAYPEE BROTHERS

the face that is characteristic of Sturge–Weber disease), *shagreen patches* (irregular, cobblestone-like plaques in the lumbosacral area), *tuft of hair* on lower back, *lipoma* in lower back, *ocular and cutaneous telangiectasias* (dilated blood vessels that occur in ataxia telangiectasia), *adenoma sebaceum* (smooth papules on the face and nasolabial folds), *white-leaf macules* (depigmentation on the trunk and lower legs), *Koenen's tumor* (an angiofibroma on the edge or surface of the nail plate)

- *Signs of hyperelasticity: Beighton score* (placing palms flat on the floor while standing with straight legs, hyperextending the knees beyond 10°, hyperextending the elbows beyond 10°, touching the thumb to the forearm, extending the fifth finger beyond 90° at the metacarpophalangeal join)—score more than 5 indicates generalized joint hypermobility **(Fig. 1)**
- Tanner staging of adolescent

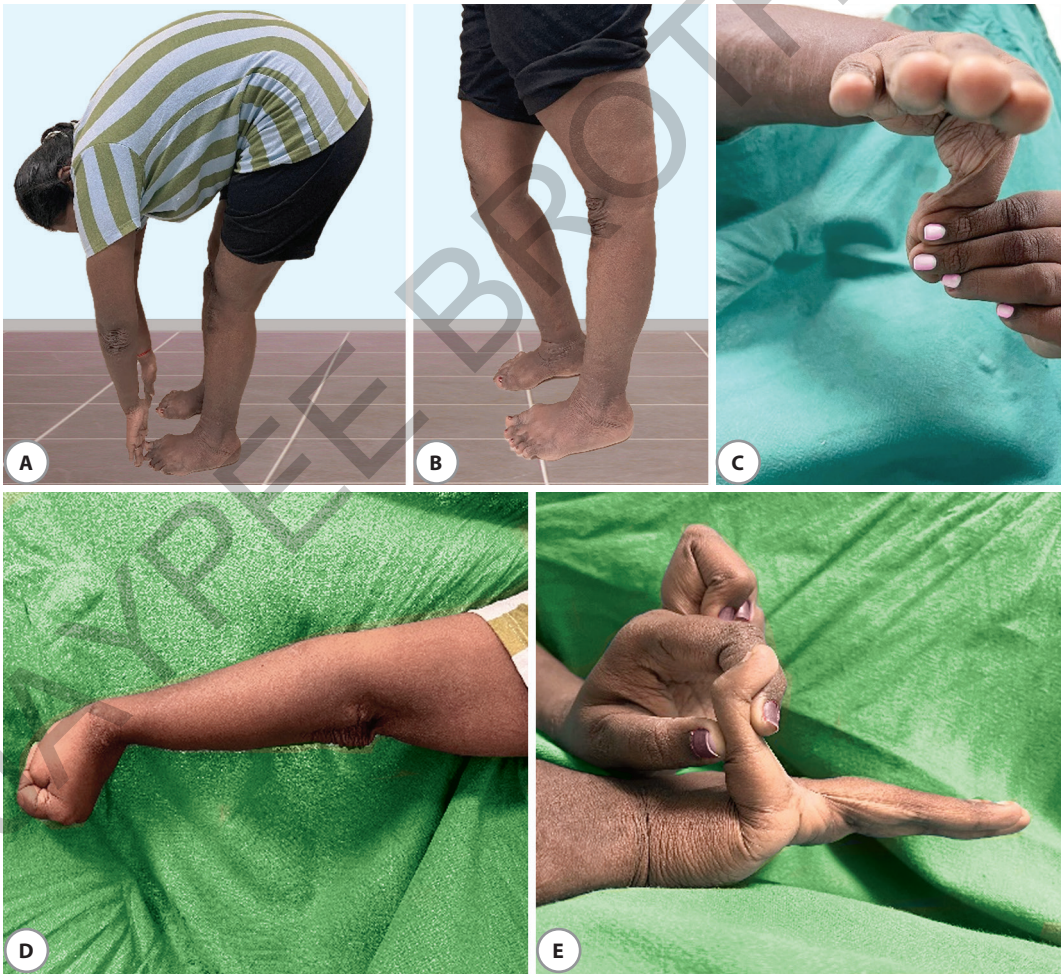

FIGS. 1A TO E: Components of Beighton score—(A) Placing palms on floor while standing with straight legs; (B) Hyperextension of knees; (C) Touching thumb to the forearm; (D) Active elbow hyperextension; (E) Extending 5th MCP beyond 90°.

JAYPEE BROTHERS

GAIT

Local Examination

Inspection

Anteriorly **(Fig. 2)**

Attitude and alignment:

- Attitude → the position in which the joint feels most comfortable.
- For the hip, the position of comfort is usually *flexion, abduction, and external rotation*, as this relaxes the capsule.
- In a correctable attitude, the hip can be brought back to neutral.
- In a true *deformity*, a fixed contracture prevents the hip from reaching neutral.
- *Fixed flexion deformity (FFD):*
  - Normally, in supine position on a hard surface, the lumbar spine touches the table without a gap.
  - In FFD, the pelvis tilts forward and lumbar lordosis increases, masking the deformity.
  - *Exaggerated lumbar lordosis* is thus a sign of FFD.
  - *Thomas test* (well-leg raising) helps unmask it.
- *Coronal plane deformities:*
  - Adduction deformity: Anterior superior iliac spine (ASIS) on affected side higher → limb appears shortened → scoliosis with convexity to opposite side.
  - Abduction deformity: ASIS on affected side lower → limb appears lengthened → scoliosis with convexity to same side.
    - Level of shoulders
    - Level of ASIS
    - Level of patella
    - Level of medial malleolus and heel
    - Scarpas triangle: Fullness, swelling, mass, pulsations, sinus, and scar
    - Thigh: Visible pulsations, engorged veins, wasting of muscles, broadened perineum, and popliteal fossa

*From side **(Fig. 3)**:*

- Kyphosis
- Lumbar lordosis
- Protuberant abdomen
- *Trochanter*: Position, fullness, and prominence—when compared to opposite side. Superior migration may be due to dislocation/subluxation, joint space destruction, fracture of neck/trochanter, and coxa vara. Excessive lateral prominence is seen in subluxation/dislocation. Reduced prominence seen with protrusio acetabuli. Scars sinuses or any abnormal prominences.
- Sinus, scar, pulsations, and engorged veins

*Posteriorly **(Fig. 4)**:*

- Scoliosis and rib hump
- Level of scapulae

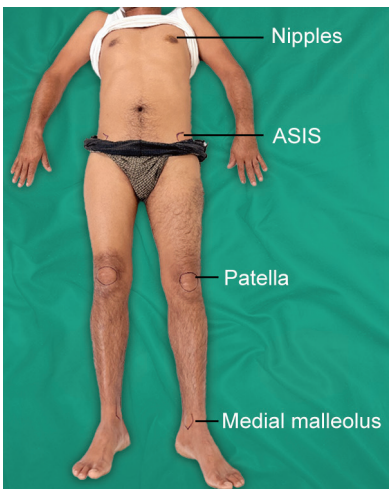

FIG. 2: Inspection from anterior aspect. (ASIS: anterior superior iliac spine)

JAYPEE BROTHERS

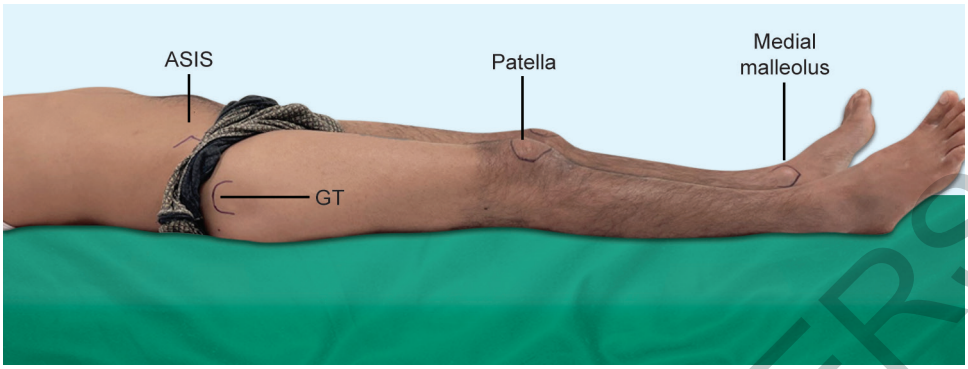

FIG. 3: Inspection from the lateral aspect.
(ASIS: anterior superior iliac spine; GT: greater trochanter)

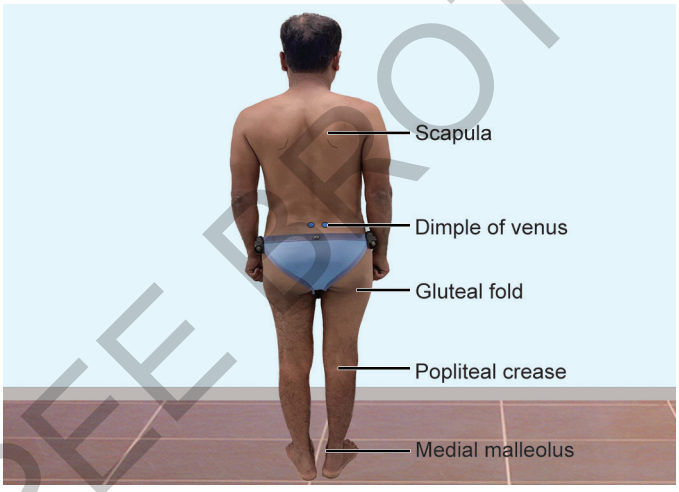

FIG. 4: Inspection from the back.

- Posterior superior iliac spine
- Gluteal folds
- Atrophy of calf muscles
- Sinus, scar, pulsations, and engorged veins

Palpation

Confirmation of inspector findings along with:

Anteriorly:

- Local rise in temperature (back of hand)
- *Anterior joint line tenderness:* 2 cm below and lateral to mid inguinal point **(Fig. 5)**

JAYPEE BROTHERS

- *Bony palpation:* Pubic tubercle, ASIS, iliac crest, greater trochanter, superior iliac spine (PSIS), and ischial tuberosity.
- Proximal femur palpation
- *Femoral pulsation:* Inferolateral to mid inguinal point—the volume of pulse when compared to opposite side will be reduced if the head is dislocated (vascular sign of Narath).
- Swelling, sinus, and scar (if any)

From side:

- *Greater trochanter:* Level, surface, thickness, and tenderness **(Fig. 6)**
- *Iliac crest:* Level and surface

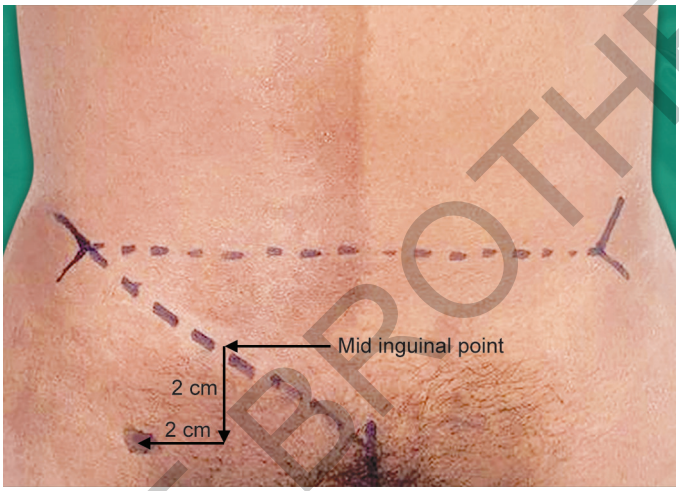

FIG. 5: Anterior hip joint line [2 cm distal and lateral to the mid inguinal point, which corresponds to mid-point of a line joining the anterior superior iliac spine (ASIS) to the pubic symphysis].

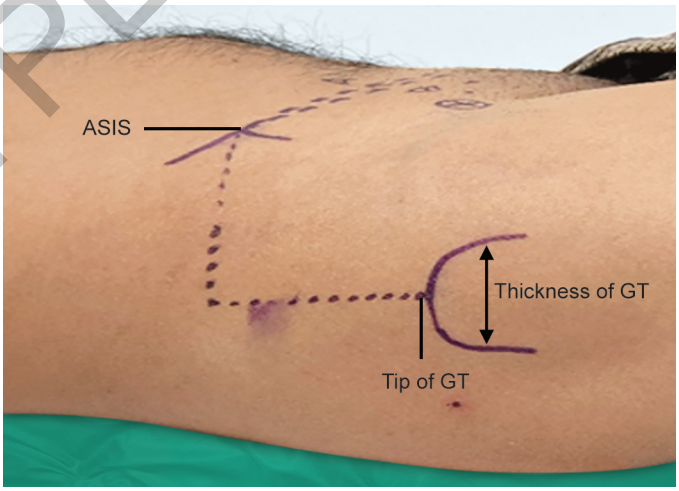

FIG. 6: The greater trochanter.
(ASIS: anterior superior iliac spine; GT: greater trochanter)

JAYPEE BROTHERS

Posteriorly:

- *Tenderness:* Located at the junction of the lateral one-third and the medial two-thirds of a line connecting the posterior PSIS and greater trochanter.
- *Any bony mass:* Globular bony mass that moves with the femur is suggestive of dislocated femoral head in presence of an unstable hip.

Movement:

- While testing hip movements, the *pelvis must be stabilized*.
- Place the *left hand on the pelvis* with the *thumb over the ASIS* and the *fingers around the greater trochanter* to detect even minimal pelvic movement.
- The *other hand supports and moves the affected limb*, ensuring that only true hip joint motion is measured.
    - *Thomas well leg flexion test:* Stand on right side of couch and explain the procedure. Pass your hand behind back volar side up. Manipulate the asymptomatic limb to flex the hip and knee to fullest obliterating lumbar lordosis. Check for ischial tuberosity movement simultaneously, and it should not rise off couch (this denotes overflexion). Ask patient to hold the knee in same position. Passively gently extend the affected limb at thigh to correct any overcorrection, correct any accidental abduction at hip, and measure the angle (couch to back of thigh) after reconfirming obliteration of lordosis. Alternate method—ask patient to flex both limbs so that knees touch chest. Then ask to release the affected limb while holding the normal knee to chest **(Fig. 7)**.
    - *Staheli prone leg extension test:* Patient position—prone with hip and knees dangling beyond the end of the examination table. Procedure—place one hand over the sacrum to stabilize the patient and to detect pelvic motion. Gently extend the tested lower limb till the pelvis starts to move. Measure the angle between the long axis of thigh and long axis of the examination couch. Interpretation—the angle between the thigh and the table is the fixed flexion deformity
    - *Squaring of pelvis:* A coronal plane deformity such as abduction or adduction is masked by compensatory coronal tilting of the pelvis, which can be identified

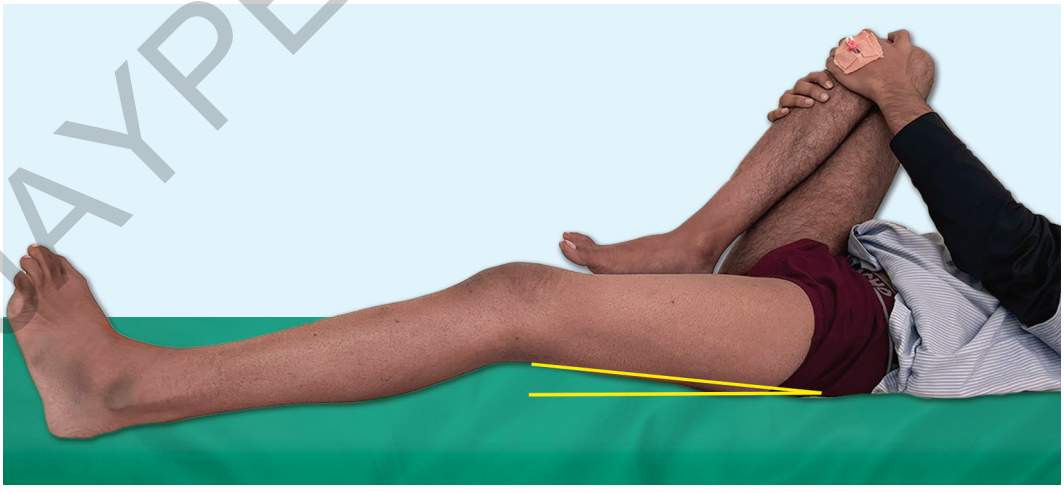

FIG. 7: Thomas Test well-leg flexion helps to unmask flexion deformity.

JAYPEE BROTHERS

by looking at the level of both ASIS. In case of an adduction deformity, the ASIS of the deformed side will be at a higher level; the affected limb will appear to be shortened and there will be lumbar scoliosis with convexity to the opposite side. In case of abduction deformity, the ASIS of the deformed side will be at a lower level, the affected limb will appear to be lengthened and there will be lumbar scoliosis with convexity to the same side. In order to assess the deformity, the coronal plane deformity is made manifest by correcting the coronal compensatory tilting of the pelvis. This is squaring of the pelvis. Squaring of the pelvis is done by making both the ASIS at the level. This is done by further adducting the affected hip in presence of an adduction deformity till both ASIS are at the same level. If there is some degree of free adduction present, then the hip has to move through that free range before the pelvis starts tilting. Hence before measuring the degree of adduction deformity, gently abduct the limb till the free range of movement is over and pelvis just starts to tilt again. Now measure the degree of adduction deformity by using a goniometer. The goniometer is placed with the hinge over the center of hip, and one arm is parallel to the midline of trunk and the other arm is parallel to the lower limb. Abduction deformity is measured by further abducting the affected hip using the same principles **(Fig. 8)**.

- *Flexion:* Unmask any *fixed flexion deformity* using the *Thomas test*. Then, move the limb passively to assess further flexion. Measure the range of motion with the *couch as the reference line* **(Fig. 9)**.
- *Extension:* Prone position **(Fig. 10)**
- *Abduction:* Begin by *squaring the pelvis* to eliminate compensatory tilt. Then move the limb passively into abduction. Measure the range of motion using the *body midline as the reference axis* **(Fig. 11)**.
- Adduction **(Fig. 12)**

JAYPEE BROTHERS



FIG. 8: Squaring of the pelvis to bring both ASIS at the same level.

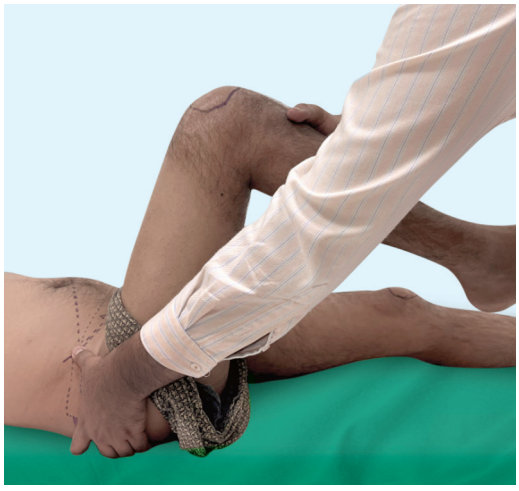

FIG. 9: Hip flexion.



FIG. 10: Hip extension in prone position.

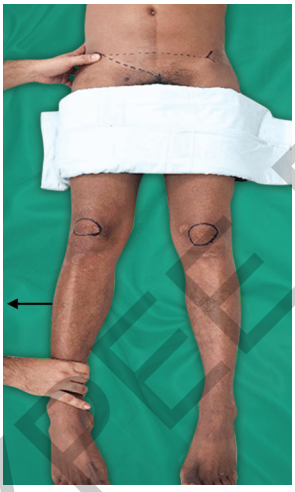

FIG. 11: Hip abduction.



FIG. 12: Hip adduction.

JAYPEE BROTHERS

- *Internal rotation:* Assess in both *extension* and *90° hip flexion* (if feasible).
  - *In extension:*
    - For the side of deformity → measure the additional movement possible from that fixed position.
    - For the opposite direction → measure starting from the zero position (patella facing straight up, horizontal to ceiling).

In flexion (hip at 90°):

- *Always measure from the* zero position *(leg parallel to midline).*
  - Internal rotation of hip **(Fig. 13)**
  - External rotation **(Fig. 14)**
  - *Associated:* Pain, spasm, and crepitus

Measurement

- *Apparent length:* Apparent limb length is measured with the patient lying comfortably supine, keeping both limbs parallel in an unsquared pelvis. The distance is taken from the xiphisternum to the medial malleolus on each side, and the values are then compared to detect any discrepancy **(Fig. 15)**.
- *True length:* Square the pelvis and put the limbs in mirror image (viz., flexion at hip, knee) and then measure from ASIS to medial malleolus **(Fig. 16)**.
- *Supratrochanteric Bryant's method:* To perform Bryant's triangle measurement, the pelvis must first be squared. A horizontal line is drawn laterally from the ASIS, keeping it perpendicular to the midline of the body. Next, a line is drawn from the ASIS to the tip of the greater trochanter, which forms the hypotenuse. Finally, a vertical line is extended upward



FIG. 13: Internal rotation of hip.



FIG. 14: External rotation of hip.

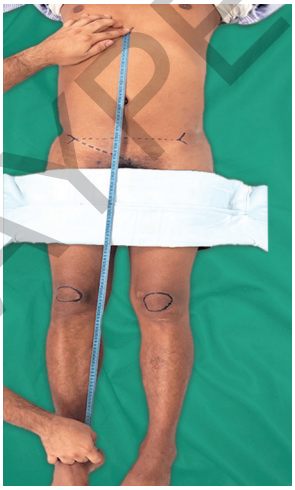

FIG. 15: Apparent length of the limb is measured between the xiphisternum and the medial malleolus. Compare with the other side.

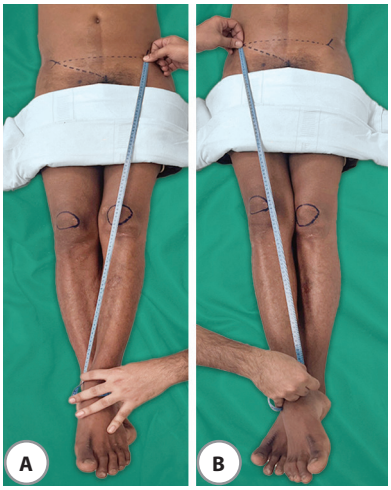

FIGS. 16A AND B: Measurement of true lengths between the ASIS and the medial malleolus (A) right side and (B) left side. Note that the limbs are in identical position.

JAYPEE BROTHERS

from the tip of the trochanter until it meets the initial horizontal line, thus completing the base of the triangle **(Fig. 17)**.

- *Kothari parallelogram:* The measurement is taken with the pelvis left unsquared. A line is drawn connecting both ASIS. From each ASIS, perpendiculars are dropped to the midline. The angle formed between these lines is then assessed, which provides an estimate of the degree of adduction or abduction deformity present in the affected hip.
- *Nelaton's line:* The patient is positioned laterally with the affected side facing upward and the hip flexed to 90°. A line is then drawn connecting the ischial tuberosity—usually the most distal and easily palpable portion—with the ASIS. If the tip of the greater trochanter lies above this line, it indicates supratrochanteric shortening. Since the comparison is not bilateral, this line is marked only on the affected side **(Fig. 18)**.

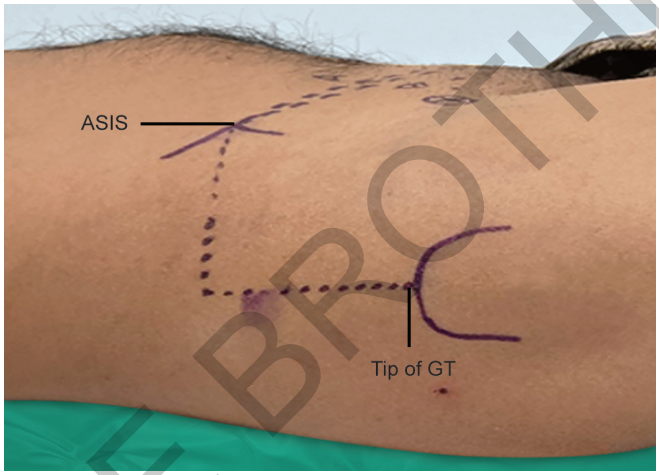

FIG. 17: Bryant's triangle. Draw a line joining the ASIS and the greater trochanter (GT), draw a perpendicular line from the ASIS to the couch, join these two lines to form the base of the triangle.

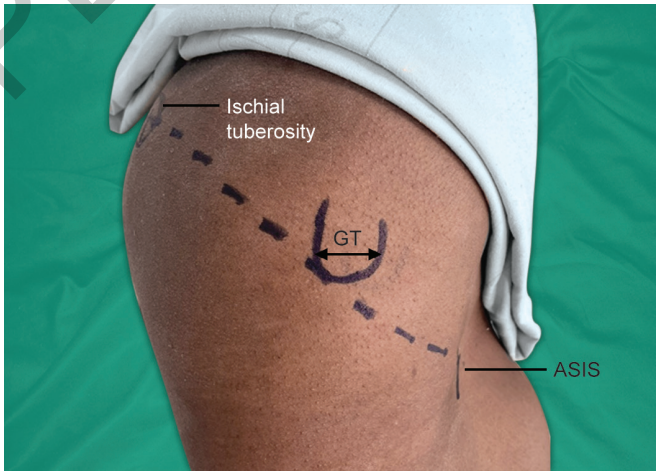

FIG. 18: Nelaton's line. Line joining the anterior superior iliac spine (ASIS) to the ischial tuberosity. The greater trochanter (GT) should normally lie at the level of this line.

JAYPEE BROTHERS

- *Shoemaker's line:* The patient is placed in the supine position. A line is drawn from the ASIS to the tip of the greater trochanter and extended across the abdomen toward the umbilicus. The same line is drawn on the opposite side. Under normal conditions, both lines intersect in the midline at or above the level of the umbilicus. In cases of unilateral supratrochanteric shortening, the lines fail to meet at the midline and instead cross on the opposite side, below the umbilicus. In bilateral symmetrical deformities, the intersection point is also below the umbilicus but remains central if the deformity is equal on both sides **(Fig. 19)**.
- Thigh girth
- Calf girth

Special Tests

- *Telescopy test:* Patient position—supine. Procedure—flex the knee and hip to 90° and 10° adduction. Stabilize the pelvis with one hand. Hold the knee and thigh with the other hand. Push and in a to and fro motion. Interpretation—relative movement of the hip is suggestive of instability **(Fig. 20)**.
- *Trendelenburg test (conventional, assisted):* Patient position—standing, examiner position—standing behind the patient. Procedure—ask the patient to do a one-legged stance on the affected limb for one minute. Note the level of gluteal fold and PSIS. Interpretation—normally the pelvis on the opposite side will move up to shift the center of gravity due to contraction of gluteus medius of weight bearing side. Up to 5° drop is considered normal. If more than 2 cm or 5°, then it is abnormal and suggests abductor insufficiency. Insufficiency may be due to abnormal fulcrum, lever or power of the abductor mechanism. Fallacies—false positive in adduction deformity of hip, quadratus lumborum paralysis, and painful lesions of sacroiliac joint. False negative in abduction deformity. Do not do if hip has fixed adduction or abduction deformity **(Fig. 21)**.

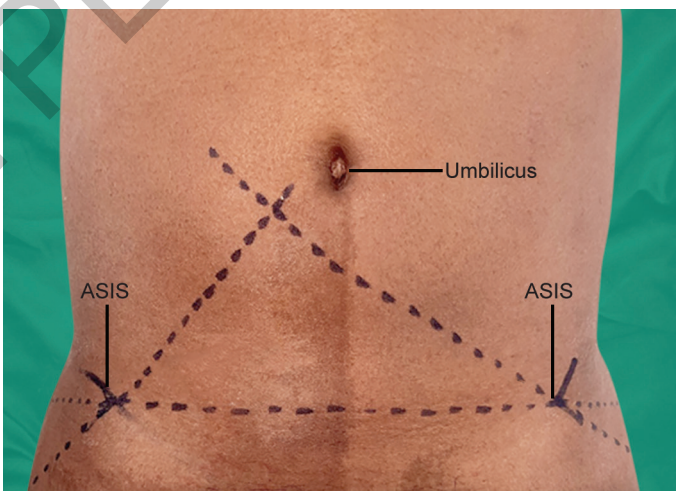

FIG. 19: Shoemaker's line—from the tip of trochanter to ASIS and extrapolate it to abdomen crossing umbilicus. Draw a similar line from other side. Normally, the lines cross at or above umbilicus in midline.

JAYPEE BROTHERS



FIG. 20: Telescopy test.
(ASIS: anterior superior iliac spine; GT: greater trochanter)



FIG. 21: Trendelenburg test—the patient is asked to stand on the affected lower limb. There is drooping of the opposite pelvis (positive test).

JAYPEE BROTHERS

- *Straight leg raising test:* The patient is asked to lift his lower limb actively. Failure to do so may suggest pathology in spine or the lower limb **(Fig. 22)**.
- *Galeazzi test:* The patient is placed in a supine position. The hip and knee of both limbs are flexed to 90°. The examiner then compares the relative height of the knees. If the knee on the affected side appears lower than the opposite side, it indicates a limb length discrepancy, commonly due to femoral shortening **(Fig. 23)**.
- Tests for sacroiliac joint (Gaenslen test—the patient is positioned at the edge of the examination table with the affected hip hanging freely. Both hips are initially flexed

together, after which the ipsilateral limb is gradually released into extension while the opposite hip remains flexed. The maneuver places stress across the sacroiliac joint, and reproduction of pain during this process is considered indicative of sacroiliac joint involvement. This test is sometimes referred to as the "pump handle" test **(Fig. 24)**.

- *Sectoral sign:* The sectoral sign is observed in conditions such as osteonecrosis, Perthes disease, and SCFE. It is characterized by a limitation of internal rotation when the hip is examined in extension, which shows noticeable improvement when the same movement is assessed with the hip in flexion.
- *Obers test:* The patient is placed in the lateral position with the affected side uppermost. The opposite hip and knee are flexed to 90° to provide stability. The examiner flexes the hip and knee of the affected limb to 90°, then stabilizes the pelvis with one hand while



FIG. 22: Active SLR test.

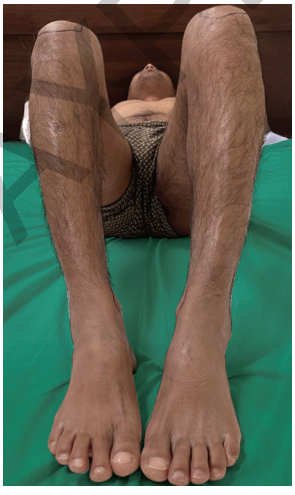

FIG. 23: Galleazi test from side.



FIG. 24: FABER/Patrick test for SI joint pathology.

JAYPEE BROTHERS

supporting the leg with the other. The hip is moved into maximum abduction and external rotation, after which the knee and hip are extended, allowing the limb to drop down under gravity. Normally, the limb falls easily to rest on the couch. If the limb remains elevated in abduction, it indicates a contracture of the iliotibial band.

Examination of Opposite Hip, Knees, and Spine

Chest Expansion

Per rectal examination: For central fracture dislocation, protrusio acetabuli

Distal neurological and vascular examination: Check for distal motor deficit, especially in sciatic nerve distribution, reflexes, and sensations. All peripheral pulses (popliteal, anterior and posterior tibial, and dorsalis pedis) to be palpated.

DIAGNOSIS

- *Anatomical:* Synovitis/arthritis/coxa vara/unstable hip/ankylosis of hip
- *Pathological:* Traumatic/inflammatory/neoplastic/infective/degenerative

JAYPEE BROTHERS

for detailed information on orthopedics books, visit our website www.ejaypee.com, for detailed information on orthopedics books, visit our w

Case Based Orthopedics

A Viva and Exam Based Book

"Case Based Orthopedics—A Viva and Exam Based Book" is designed as a practical companion for postgraduate students preparing for MS and DNB examinations. Focused on the needs of exam-going candidates, it provides step-by-step guidance on clinical examination methods, illustrated with photographs for clarity. Common long and short cases are discussed in detail, along with probable viva questions and key discussion points frequently asked by examiners. The book blends clinical knowledge with an exam-oriented approach, making it an essential resource for students to present cases systematically, build confidence, and succeed in their orthopedic examinations.

Samir Dwidmuthe MS(Orthopedics) is a Professor and Head of Department of Orthopedics at All India Institute of Medical Sciences (AIIMS), Nagpur, Maharashtra, India. A committed academician and skilled orthopedic surgeon, he has been actively involved in postgraduate training, clinical teaching, and research in musculoskeletal trauma and reconstructive surgery. His clinical interests include sports injury, arthroscopy, complex trauma, and orthopedic infections, with several publications in peer-reviewed national and international journals. Dr Dwidmuthe has contributed extensively to postgraduate teaching through lectures, workshops, and training programs across India, and has been instrumental in developing structured teaching modules for MS. He also plays a leadership role in professional bodies, including the Vidarbha Orthopedic Society, where he has helped foster academic collaboration and clinical excellence. Known for his clarity in teaching and practical approach to case discussions, Dr Dwidmuthe continues to inspire the next generation of orthopedic surgeons.

Sitanshu Barik MCh(Pediatric Orthopedics) DNB(Orthopedics) is an Associate Professor in the Department of Orthopedics at AIIMS, Nagpur, Maharashtra, India. He obtained his MBBS from Kasturba Medical College, Mangalore, Karnataka, India and completed postgraduate training in orthopedics at the Kerala Institute of Medical Sciences, Trivandrum, Kerala, India followed by an MCh in Pediatric Orthopedic Surgery at AIIMS, Rishikesh, Uttarakhand, India. He is also a DipSICOT (Belgium) and Associate Fellow of the Academy of Medical Sciences, New Delhi, India. He trained at leading centers in India and abroad, including fellowships in pediatric orthopedics and hand surgery at Orthopädisches Spital, Vienna, and in cerebral palsy care in São Paulo, Brazil. His clinical and research interests span pediatric orthopedics, deformity correction, limb reconstruction, and evidence-based orthopedics. He has authored over 100 peer-reviewed PubMed-indexed publications, numerous book chapters, and is actively involved in systematic reviews and meta-analyses, including Indian Council of Medical Research (ICMR)-funded projects on stem cell therapy in osteogenesis imperfecta. He serves as reviewer and editorial board member for several international journals. Deeply committed to orthopedic education, Dr Barik has delivered invited lectures across India, organized academic symposia, and contributed to curriculum development for undergraduate and postgraduate training.

Buy from ejaypee

JAYPEE BROTHERS

Shelving Recommendation
ORTHOPEDICS

ISBN 978-93-7202-758-7