jaypee.com, for detailed information on obstetrics and gynecology books, visit our website www.ejaypee.com, for detailed information on obstetrics and gynecology books

Complimentary Online 123 Videos (Duration 31 minutes)

2nd Edition

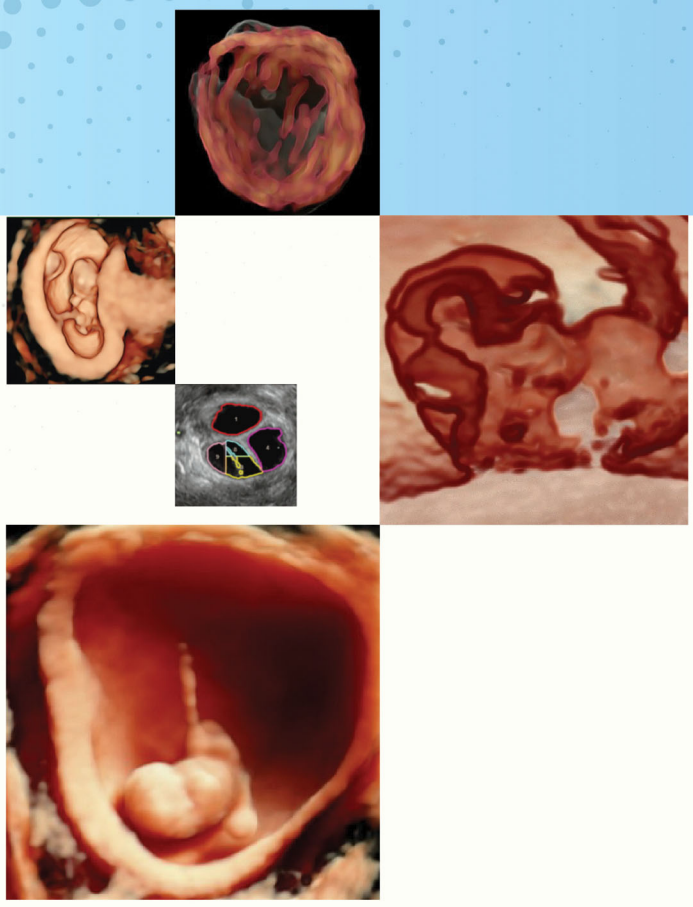

Practical Guide to
3D–4D Ultrasound in Obstetrics and Gynecology

Sonal Panchal
Chaitanya Nagori

JAYPEE

Contents

SECTION 1: 3D ULTRASOUND BASICS

1. **What is 3D Ultrasound?** **3**
2. **Acquisition and Analysis of 3D Volume** **10**
   - Acquiring A 3D Volume *10*
   - Analysis *15*
3. **Multiplanar Images: What have these Images Hidden in them?** **20**
   - Tomographic Ultrasound Imaging *20*
   - Volume Computer-aided Diagnosis *23*
   - Volume Contrast Imaging *26*
   - Omniview *28*
4. **Display of the Acquired Volume** **34**
   - Rendering *34*
   - Render Direction *34*
   - Render Line *37*
   - Cine Translation *43*
   - Magicut *44*
5. **Volume Calculation Tools** **50**

SECTION 2: CLINICAL APPLICATIONS OF VOLUME ULTRASOUND IN OBSTETRICS

6. **Role of Volume Ultrasound in First Trimester** **73**
   - Technical Aspects *74*
   - Applications of 3D and 4D Ultrasound in First Trimester *74*
   - Detection of Fetal Anomalies in First Trimester *81*
   - 3D Ultrasound in Genetic Scan *85*
   - Pregnancy with Abnormalities of the Uterus *86*
7. **3D and 4D Ultrasound for Fetal Anomalies** **91**
   - Tips for Volume Ultrasound for Second and Third Trimester Fetus *91*
   - Applications for Detection of Congenital Defects in the Fetuses *92*
   - 3D–4D Ultrasound for Fetal Echocardiography *114*
   - Conjoined Twins *117*
   - Limitations of 3D–4D Ultrasound *117*
8. **4D Ultrasound for Functional Assessment of the Fetal Brain Development** **120**
   - Functional Development of Fetal Brain *120*
   - Development of Motor Functions and 4D Ultrasound *121*
   - Movements Analyzed During First Trimester *121*
   - Movements Analyzed During Second and Third Trimesters *122*
   - Role of 4D Ultrasound *124*
   - Abnormalities of Fetal Behavior *129*

9. Sono-VCAD in Labor 137
- Process of Second Stage Labor *137*
- Understanding the Path of the Fetal Head During Labor *138*
- Angle of Progression *139*

SECTION 3: CLINICAL APPLICATIONS OF VOLUME ULTRASOUND IN GYNECOLOGY AND INFERTILITY

10. Volume Ultrasound for Uterine Abnormalities 147
- Discussion Points *147*
- How to Acquire the Volume of Uterus? *147*
- Analysis of the Acquired Uterus Volume *149*
- Rendering the Uterus and Postprocessing Tools *149*
- Using Multiplanar Tools: Tomographic Ultrasound Imaging, Omniview, and Volume Contrast Imaging *151*
- Volume Calculations *151*
- Müllerian Duct Abnormalities *151*
- Endometrial Lesions *158*
- Myometrial Lesions *165*
- Advantages of 3D Ultrasound for Imaging of Uterus *172*

11. Volume Ultrasound in Adnexal Lesions 177
- Discussion Points *177*
- How to Acquire the Volume for Adnexa and Ovaries? *177*
- Analysis of the Acquired Volume *178*
- Using Multiplanar Tools and Rendering *178*
- Volume Calculations *179*
- Adnexal Lesions *179*
- Ovarian Lesions *181*
- Cysts with Solid Components or Septae *182*

12. Volume Ultrasound in Infertility 187
- Polycystic Ovaries *187*
- Follicular Monitoring *190*

13. Role of Volume Ultrasound in Pelvic Floor Imaging 205
- Anatomy of the Pelvic Floor as seen on 3D Ultrasound *205*

Appendix 213

Index 215

Video Contents

Kindly scan the QR code below to access the online Videos.

Chapter 1: What is 3D Ultrasound?

- **Video 1:** Video showing how multiple B-mode images are taken in series to ultimately compile into a tissue block.
- **Video 2:** Acquiring the complete 3D tissue block for 3D imaging.
- **Video 3:** Video showing movement of the ultrasound beam while 3D acquisition.
- **Video 4:** Video showing x-axis rotation of the sagittal spine on A plane image making it coronal and again sagittal.
- **Video 5:** Video showing walking in and out of the volume of the cervix acquired by 3D US-cine translation.
- **Video 6:** Video showing rotation of the rendered image on y-axis cine rotation.
- **Video 7:** Video of 4D US of fetus showing eye and lip movements of the fetus.
- **Video 8:** Ultrashort video of spatiotemporal imaging correlation (STIC)-acquired volume (offline 4D) of fetal heart.
- **Video 9:** Video of live M-mode tracing of the STIC-acquired volume of fetal heart.

Chapter 2: Acquisition and Analysis of 3D Volume

- **Video 1:** Video showing how multiple B-mode images are taken in series to ultimately compile into a tissue block.
- **Video 2:** Acquiring the complete 3D tissue block for 3D imaging.
- **Video 3:** Video showing volume acquisition of the uterus. In this video at the beginning and end of the acquisition lateral most part of the uterus is seen, indicating that the volume angle of the acquired volume is inadequate.
- **Video 4:** Observe the right lower corner of this video. As the volume is being acquired, the "pie" shape or triangular shape gets gradually filled up to make a solid shape. The filling of this shape indicates the amount of acquisition done.
- **Video 5:** Video showing movement during acquisition of the volume resulting in artifact in the rendered as well as reconstruction sectional images in B and C.
- **Video 6:** Video showing walking through the A plane of the volume of the fetal spine.
- **Video 7:** Video showing x-axis rotation of the image A showing sagittal plane of fetal spine with reference dot on the spine. On rotation, the sagittal plane becoming coronal and again sagittal is observed.
- **Video 8:** Video showing y-axis rotation of the image A showing sagittal plane of fetal spine with reference dot on the spine. On rotation, the sagittal plane becoming transverse and again sagittal is observed.

- **Video 9:** Video showing z-axis rotation of the image A showing sagittal plane of fetal spine with reference dot on the spine. On rotation, the spine still remains in sagittal plane with seesaw-like movement of the spine.
- **Video 10:** Video showing x-axis rotation of the image A showing sagittal plane of fetal spine with reference dot much anterior to the spine on no anatomically identifiable land mark. On rotation, the anatomy of the resulting sections is not precisely identifiable.

Chapter 3: Multiplanar Images: What have these Images Hidden in them?

- **Video 1:** Video showing tomographic ultrasound imaging (TUI) of the 4D-acquired volume of the fetus.
- **Video 2:** Video showing 4D Omniview of the fetal head in axial view with Omniview line overlapping the falx and cavum septum pellucidum resulting in the midsagittal plane of the fetal head showing corpus callosum.

Chapter 4: Display of the Acquired Volume

- **Video 1:** Video showing curving the render line to allow its aligning to the surface to be rendered.
- **Video 2:** Video showing one side rotation 3D ultrasound rendered image of fetus with y-axis cine calculation (rotation).
- **Video 3:** Cone rotation of the HD-live rendered 3D ultrasound image of spine and rib cage, with varying speed of rotation.
- **Video 4:** Cine translation showing walking in and out of the cervical volume with cervical polyp.
- **Video 5A:** Video showing the technique of trace inside full-depth option of MagiCut.
- **Video 5B:** Video showing the technique of trace inside defined-depth option of MagiCut.
- **Video 6A:** Video showing the technique of trace outside full-depth option of MagiCut.
- **Video 6B:** Video showing the technique of trace outside defined-depth option of MagiCut.
- **Video 7A:** Video showing the technique of box inside full-depth option of MagiCut.
- **Video 7B:** Video showing the technique of box inside defined-depth option of MagiCut.
- **Video 8A:** Video showing the technique of box outside full-depth option of MagiCut.
- **Video 8B:** Video showing the technique of box outside defined-depth option of MagiCut.
- **Video 9A:** MagiCut using big eraser.
- **Video 9B:** MagiCut using small eraser.

Chapter 5: Volume Calculation Tools

- **Video 1:** Volume calculation by VOCAL (virtual organ computer-aided analysis) with “sphere” option.
- **Video 2:** Volume calculation by VOCAL with “auto-trace” option.
- **Video 3:** Volume calculation with VOCAL and “shell outside” option.
- **Video 4:** Video showing calculation of the volume histogram.
- **Video 5:** Video showing calculation of the threshold volume.
- **Video 6:** Postprocessing of sono-AVC.

Chapter 6: Role of Volume Ultrasound in First Trimester

- **Video 1:** STIC acquisition of circle of Willis at 9–10 weeks pregnancy.
- **Video 2:** 9–10-week-old fetus rendered on 4D US.
- **Video 3:** 11-week-old fetus rendered on 4D US with limb movements.
- **Video 4:** Surface-rendered 4D US clip showing movement pattern on anencephalic fetus at 11–12 weeks.
- **Video 5:** Power Doppler (HD flow) US shows normal fetoplacental circulation.
- **Video 6:** 3D cine calculation showing omphalocele.

- **Video 7:** 3D cine calculation clip showing uterus with fibroid and gestational sac and relation between the two.
- **Video 8:** First-trimester normal echocardiography with HD flow, acquired with STIC with TUI.

Chapter 7: 3D and 4D Ultrasound for Fetal Anomalies

- **Video 1:** Fetal face seen on surface rendering where multiplanar shows a sufficient fluid pocket in front of the face.
- **Video 2:** Yawning
- **Video 3:** Smiling
- **Video 4:** Swallowing
- **Video 5:** Sucking
- **Video 6:** Blinking
- **Video 7:** Grimacing
- **Video 8:** Mouthing
- **Video 9:** Tongue expulsion
- **Video 10:** Movements of fetal hand and head in a fetus of 22 weeks.
- **Video 11:** Omphalocele shown on surface rendering with cine calculation.
- **Video 12A:** 4D Omniview of the fetal leg and foot to show the sagittal plane to show normal relationship of fetal leg with fetal foot and rule out clubfoot.
- **Video 12B:** 4D Omniview of the fetal leg and foot to show the sagittal plane to diagnose clubfoot.
- **Video 13:** 3D power Doppler of normal placental vasculature on cine calculation.
- **Video 14:** Video explaining how STIC works.
- **Video 15:** Video of STIC-acquired volume of heart, displayed as multiplanar images.
- **Video 16:** Video of STIC-acquired volume of heart with color Doppler, displayed as multiplanar images.
- **Video 17:** Walk through images of the fetal heart during STIC acquisition.
- **Video 18:** Video of STIC-acquired volume of heart with HD flow on TUI.
- **Video 19:** Video of STIC-acquired volume of heart displayed as inversion mode rendered image.
- **Video 20:** Video of STIC-acquired volume of heart displayed as HD-live rendered image.
- **Video 21:** Video of volume of the two arches (aortic arch and ductal arch) acquired with power Doppler, rendered in angio mode and displayed as cine calculation.
- **Video 22:** Video of STIC-acquired volume of heart rendered to display the surgical view of the heart (relationship of two AV valves and two outflow tracts).
- **Video 23:** STIC-acquired volume of the heart rendered in up-down direction to show the structure of two AV valves.
- **Video 24:** STIC-acquired volume of the heart rendered in up-down direction to show large atrioventricular septal defect (AVSD) and single AV valve.

Chapter 8: 4D Ultrasound for Functional Assessment of the Fetal Brain Development

- **Video 1:** 7.5 weeks, head tilting and upper limb movements seen.
- **Video 2:** Rippling movement of limbs seen in 8-week-old embryo.
- **Video 3:** Twitching movement seen in 10-week-old fetus.
- **Video 4:** 14-week-old fetus showing complex limb, trunk and head movements.
- **Video 5:** General movements in the fetus seen in 14-week-old fetus.
- **Video 6:** General movements in the fetus seen in 18-week-old fetus.
- **Video 7:** 26-week-old fetus showing fine finger movements.
- **Video 8:** Stereotype movements seen in anencephalic fetus.
- **Video 9:** Goal-oriented movements of 13-week-old fetus.
- **Video 10A:** Eye and tongue movements

- **Video 10B:** Yawning
- **Video 10C:** Smiling
- **Video 10D:** Grimacing
- **Video 10E:** Finger sucking
- **Video 10F:** Eye movement and searching to suck
- **Video 11:** Hand-to-eye movement
- **Video 12:** Hand-to-face and hand-to-ear movements
- **Video 13:** Eyelid movements
- **Video 14:** Mouthing movement
- **Video 15:** Mouth opening—yawning
- **Video 16:** Tongue protrusion movement
- **Video 17:** Isolated hand movement
- **Video 18:** Eyelid and mouth movements together

Chapter 10: Volume Ultrasound for Uterine Abnormalities

- **Video 1:** Volume acquisition of uterus.
- **Video 2:** Endometrial calcification demonstrated on 3D surface-rendered image of the uterus with box inside MagiCut and cine rotation.
- **Video 3:** Virtual hysteroscopy showing fundal endometrial polyp.
- **Video 4:** Virtual hysteroscopy on uterus rendered in HD-live render mode with multiple small polyps.
- **Video 5:** VCI-A of the uterus in sagittal section showing interruption of anterior junctional zone by hyperechoic strands in adenomyosis.
- **Video 6:** Volume of the uterus rendered with a combination of surface and minimum mode showing fibroids as hypoechoic areas and endometrium seen through and through, with cine rotation.
- **Video 7:** Processing of the acquired volume of the uterus for fibroid mapping.
- **Video 8:** Intramural fibroid and its relation with endometrium demonstrated on 3D surface-rendered image of the uterus with box inside MagiCut and cine rotation.
- **Video 9:** Virtual cervicoscopy on the cervix with polyp rendered on HD-live mode.

Chapter 11: Volume Ultrasound in Adnexal Lesions

- **Video 1:** Video showing tracing the ovary from uterus transverse plane though soft tissue adnexal band.
- **Video 2:** Video showing sliding of ovary against all the soft tissue structures in its surrounding.
- **Video 3:** Video showing scrolling across the ovary.
- **Video 4:** Video showing change in the shape of the cystic lesion on rotation of the probe and appearance of partial septum-hydrosalpinx.
- **Video 5:** Video showing cine rotation of the HD-live rendered hydrosalpinx after MagiCut.
- **Video 6:** Video showing cine rotation of the hydrosalpinx. The mucosal folds of the inner surface of the tube are clearly demonstrated.
- **Video 7:** Video of cine rotation of a dermoid with floating fat lobules.
- **Video 8:** Video of cine rotation of 3D power Doppler angio mode rendered image of a malignant tumor.

Chapter 12: Volume Ultrasound in Infertility

- **Video 1:** Cine rotation of sono-AVC calculated antral follicles.
- **Video 2:** Cine rotation of polycystic ovary rendered in inversion mode showing multiple antral follicles as solid balls.

- **Video 3:** Cine rotation of angio mode rendered image of 3D power Doppler-acquired render image of polycystic ovary.
- **Video 4:** Cine rotation of inversion mode rendering of normal ovary.
- **Video 5:** Cine rotation of 3D power Doppler angio mode rendering of normal ovary.
- **Video 6:** Cine rotation of the surface rendered image of follicle showing cumulus.
- **Video 7:** Cine rotation of the glass body rendered volume of follicle for perifollicular flow assessment.
- **Video 8:** Cine rotation of the 3D HD flow VOCAL calculated volume of the endometrium.
- **Video 9:** Endometrial flow studied by STIC.

13

CHAPTER

Role of Volume Ultrasound in Pelvic Floor Imaging

INTRODUCTION

Pelvic floor imaging is especially recommended for the females presenting with urogynecological complaints such as urinary stress incontinence, urgency, frequency, cystocele, prolapse, rectocele, constipation, fecal incontinence, etc. Pelvic floor imaging is of utmost importance in patients with these complaints because these result chiefly from pelvic floor trauma and the most common cause is normal labor. Over 40% of women undergoing normal labor suffer either frank tears or irreversible overdistention of hiatus.[1] Around 10–30% of all women having delivered vaginally have some avulsion of puborectalis. But, real incidence is difficult to document because of its awareness and, therefore, seeking medical help for the same is increasing in developed countries, in many more countries, and there is still a hesitation to complain and present for the same. Diagnosis can be suspected on clinical examination, but in majority of the cases, ultrasound confirms the diagnosis. This includes B mode and volume ultrasound.

Assessing the bladder wall thickness, bladder neck funneling, hypermobility of bladder neck and urethra, urethral diverticuli, bladder tumors, rectocele, and enterocele can all be demonstrated by B-mode ultrasound, but the cause of these, extent of injury to the levator ani muscle or its attachment to pubic symphysis can only be diagnosed by assessment of the pelvic floor by 3D ultrasound. 3D/4D transperineal ultrasound (TUS) can identify specific avulsion of puborectalis muscle. It is the result of the detachment of the muscle from its insertion on the inferior pubic ramus as a consequence of overstretching of the levator during the second stage of labor and may be detected in up to 36% of women following their first vaginal delivery.

ANATOMY OF THE PELVIC FLOOR AS SEEN ON 3D ULTRASOUND

The pelvic floor can be assessed on the rendered images, tomographic ultrasound imaging (TUI) on C plane and on OmniView. Rendered image or OmniView with volume contrast imaging (VCI) on 3D ultrasound can also be used to assess the pelvic floor muscles.[2] The anatomy seen on this scan is explained and compared with the diagram in **Figures 1A and B**. At least three central slices are taken of OmniView is used. Plane of minimum hiatal dimensions and two slices 2.5 and 5 mm cranial to it. Lower most slice is just below the insertion of puborectalis muscle[3] **(Fig. 2)**. TUI is preferred for the same and is a time-saving option.

Levator hiatus is space between these various muscles and through that are the orifices, urethra, vagina, and anus[4] from anterior to posterior. Puborectalis extends from pubic symphysis till behind the anus.[5] The later is the most important muscle to maintain continence and control.

The routes of scan could be transperineal, introital, and endoanal for rectal trauma.

Transperineal Scan for Pelvic Floor (Figs. 3A and B)

Patient should be empty bladder prior to scan and take a lithotomy like position. 200–300 mL of urine for evaluation of dynamic changes

JAYPEE BROTHERS

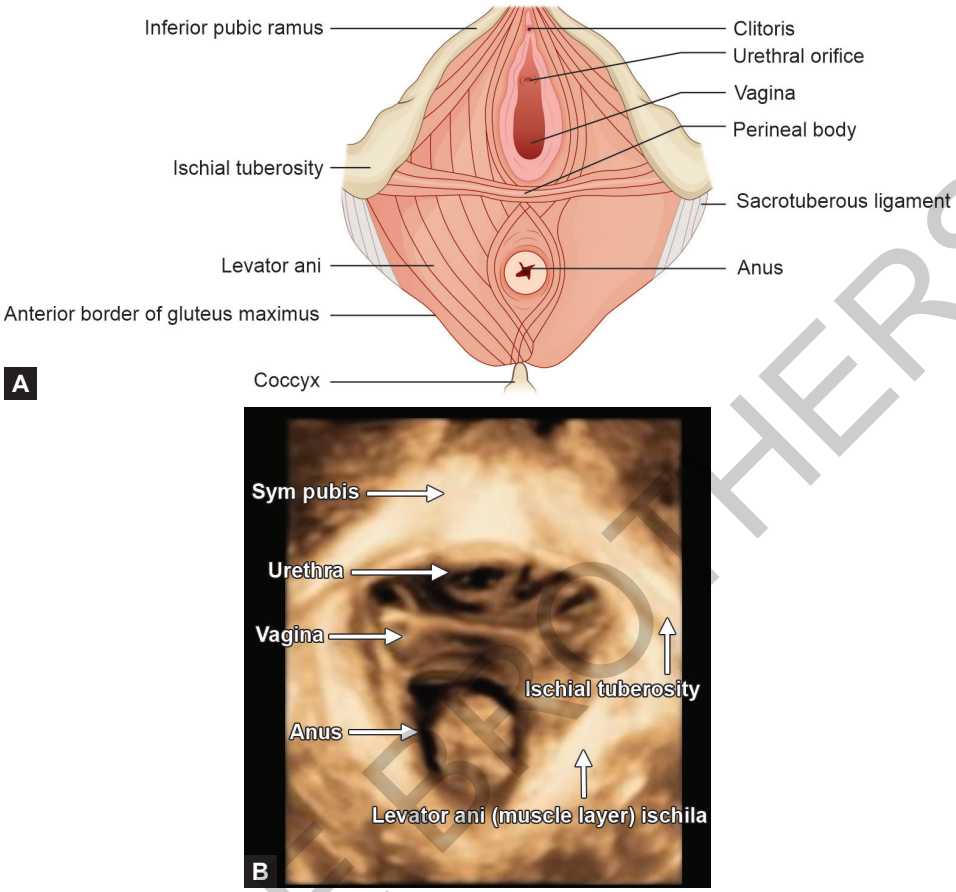

Figs. 1A and B: Anatomy of the pelvic floor on 3D ultrasound in axial plane.

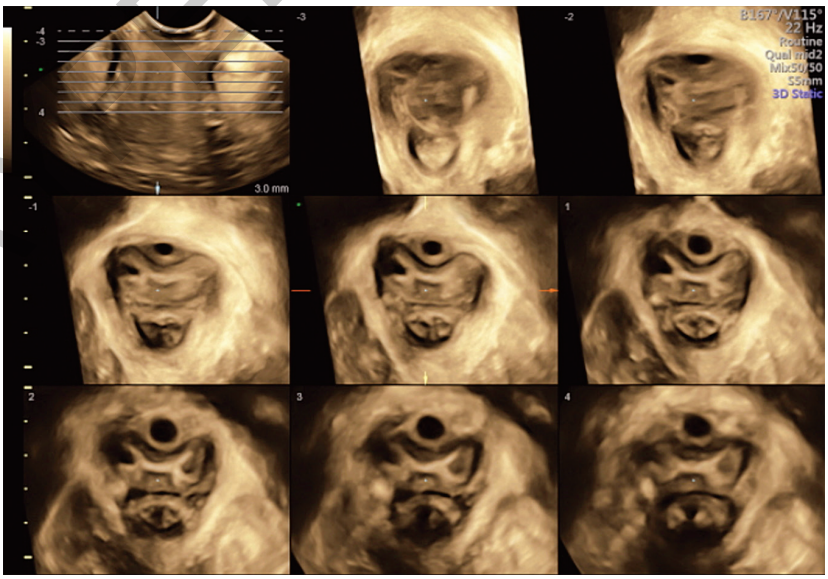

Fig. 2: Tomographic ultrasound imaging of the pelvic floor volume ultrasound.

JAYPEE BROTHERS

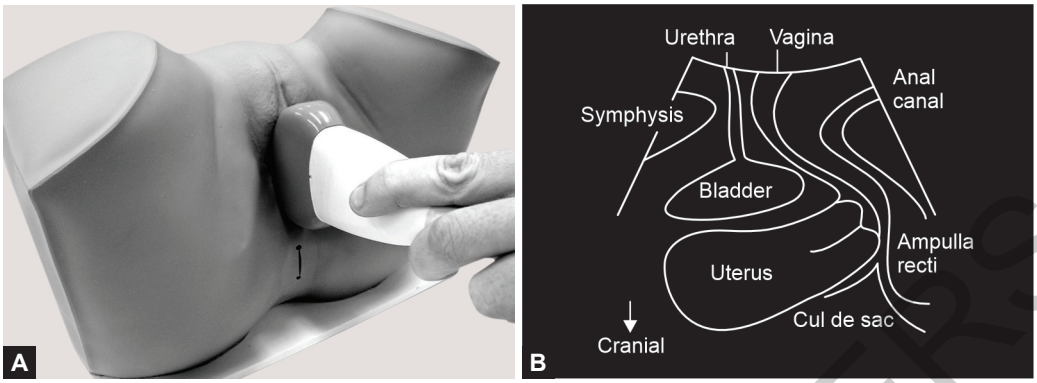

Figs. 3A and B: Position of the probe on the phantom perineum for transperineal scan.

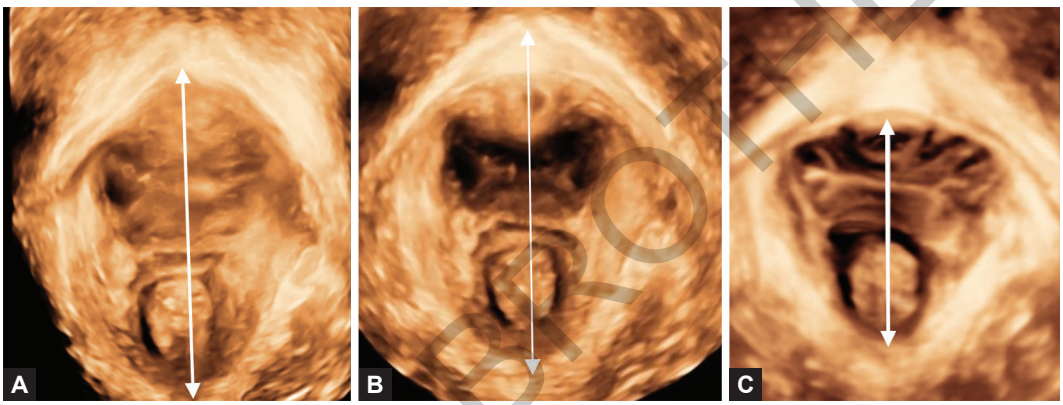

Figs. 4A to C: (A) Pelvic floor on 3D ultrasound at rest; (B) Pelvic floor on 3D ultrasound on Valsalva; (C) Pelvic floor on 3D ultrasound on levator coactivation.

of the bladder neck, but <50 mL of urine for assessment of the bladder wall thickness. Bowel preparation is always preferred.[6-8]

Select pelvic floor preset on a convex probe and adjust to widest field (maximum angle).

Though in certain special circumstances, scanning in standing position may be required, though is very inconvenient.

Transperineal ultrasound (TUS) is carried out with a 3.5–6 MHz curved array transducer. Place gel on the probe head and cover it with a dedicated probe cover. Glove can also be used instead to cover the probe. Gel is also placed above the probe cover and probe is placed on the perineum in the midsagittal line. The probe is so placed on perineum that the marker on the probe is on the anterior aspect of the patient and margin of the probe rests on the symphysis pubis **(Figs. 3A and B)**. For perineal ultrasound, probe is placed over the labia. Parting of labia may be required for better image quality. B-mode assessment is done at rest and on "Valsalva". Storing real-time clips may help a dynamic assessment. But, the first volume has to be in the resting state for evaluation of the pelvic floor in resting condition **(Fig. 4A)**.

VALSALVA

Forced expiration against closed glottis and contracted diaphragm and abdominal wall is Valsalva and it must be continued for at least 5 seconds.

This results in dorso-caudal displacement of urethra and bladder neck and downward displacement of cervix and rectal ampulla **(Fig. 4B)**.

JAYPEE BROTHERS

LEVATOR COACTIVATION

It is cranioventral shift of pelvic organs in midsagittal plane and reduction in levator hiatus diameter in midsagittal plane. Reduced anteroposterior diameter of levator hiatus **(Fig. 4C)** with elevation of anorectum and change in the angle between levator plate and symphysis pubis and displacement of internal urethral meatus in relation to inferoposterior urethral margin. This may lead to erroneous diagnosis of normalcy. It is very important to identify levator coactivation, because most commonly on explaining the patient to do the Valsalva maneuver, she ends up doing levator coactivation. Therefore, it is usually best to make her practice Valsalva before the examination.

Levator coactivation can be avoided if assessment is done in standing position.

Volume probe may be used for 3D assessment of the perineum. Volume images are acquired at rest, with full Valsalva and with levator coactivation.

Since the technique enables one to obtain tomographic or multislice scans, the whole puborectalis muscle and its attachments to the pubic rami can be visualized.[9-11]

Introital Ultrasound

The technique involves the use of front-firing endovaginal probes (5–7.5 MHz) placed on the vaginal introitus. It provides higher resolution of images but reduced penetration into the tissues. For introital scan, the probe is placed over external urethral orifice, with long axis of the probe, along the long axis of the body. This scan shows only lower end of symphysis pubis. Primarily assessment of the urethra, urinary bladder, periurethral tissues, endopelvic fascia, vagina and rectum are assessed. Excessive pressure is never exerted on the probe. This may displace the bladder neck. The assessment is done at rest, on coughing, on Valsalva and with pressure. The effect of the Valsalva maneuver on proximal urethra mobility may be evaluated along with transperineal ultrasound (TPUS) using the inferior margin of the symphysis pubis as a reference[12,13]

Measurements to be taken on B-mode ultrasound:

- Extent of posteroinferior displacement of the bladder base.
- Inferior displacement of the bladder neck **(Figs. 2A and B)**
- Pubourethral angle
- Funneling of bladder neck
- Vesicourethral angle
- Uterine descent

Volumes are especially useful for differentiating levator coactivation from true Valsalva, assessment of hiatal area, measurement of the thickness of levator ani muscle. Anteroposterior and transverse diameter of pelvic outlet at rest and on Valsalva to be measured on axial plane, on 3D ultrasound.

Plane of minimal hiatal dimensions is first identified on sectional plane **(Figs. 5A and B)**.

Maximum levator thickness ***(Figs. 6A to I)*** is determined by slowly moving the plane of minimal hiatal dimensions cranially until the plane of maximal thickness of the pubovisceral muscle is reached. This is usually located about 1–1.5 cm above the actual levator hiatus. The thickness of muscle mass does not correlate with levator function but, still it is suggested to be measured by some workers.[14] Though a bulky muscle does not suggest a better muscle power, thin muscle definitely suggests muscle atrophy and weakness, leading to descent.

In the axial view maximum diameters of the pubovisceral muscle is measured in two locations bilaterally by tracing the outline of the muscle at the level of maximal muscle thickness. Enlargement of the levator hiatus on 4D TUS is observed as "hiatus ballooning". Both levator avulsion and ballooning are associated with pelvic organ prolapse (POP)[9,10,12] **(Fig. 7)**.

JAYPEE BROTHERS

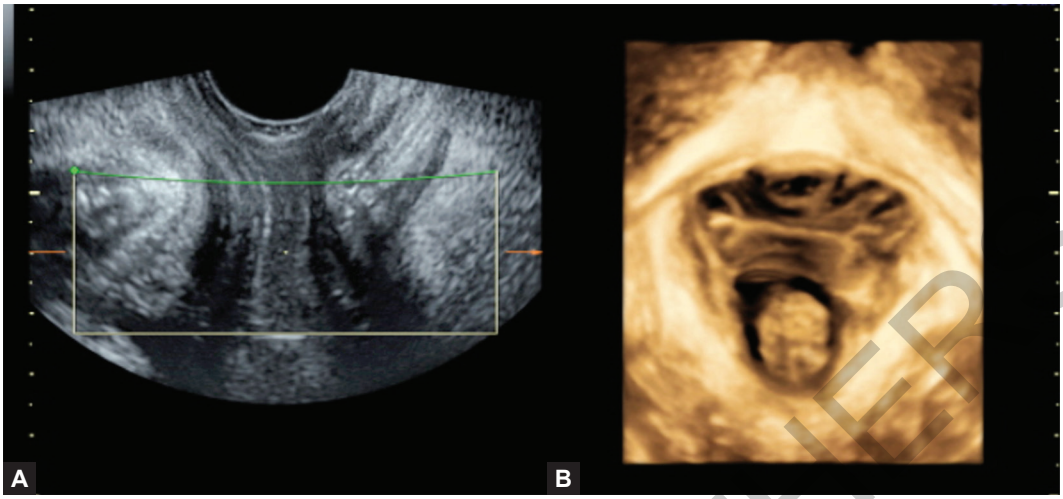

Figs. 5A and B: Plane of minimal anteroposterior (AP) diameter is marked by green viewing line on midsagittal plane of pelvis.

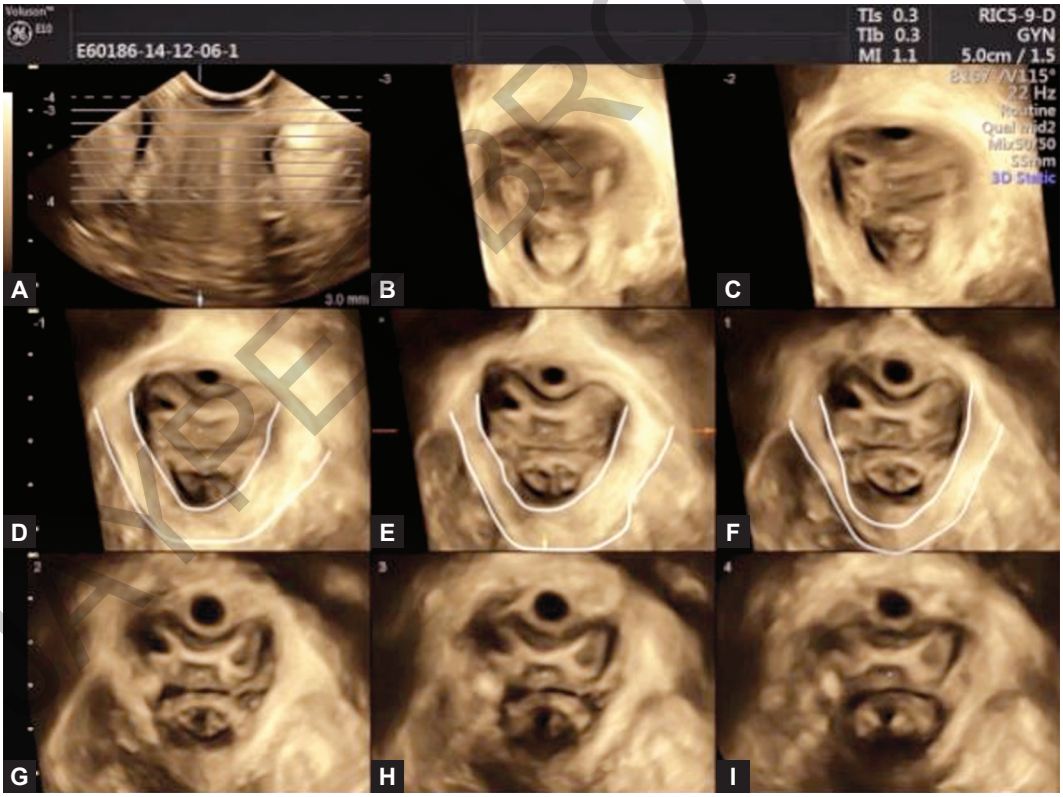

Figs. 6A to I: Identifying plane of maximum levator ani muscle on tomographic ultrasound imaging (TUI) of pelvic floor.

JAYPEE BROTHERS



Fig. 7: Ballooning of the pelvic floor, due to bilateral avulsion.

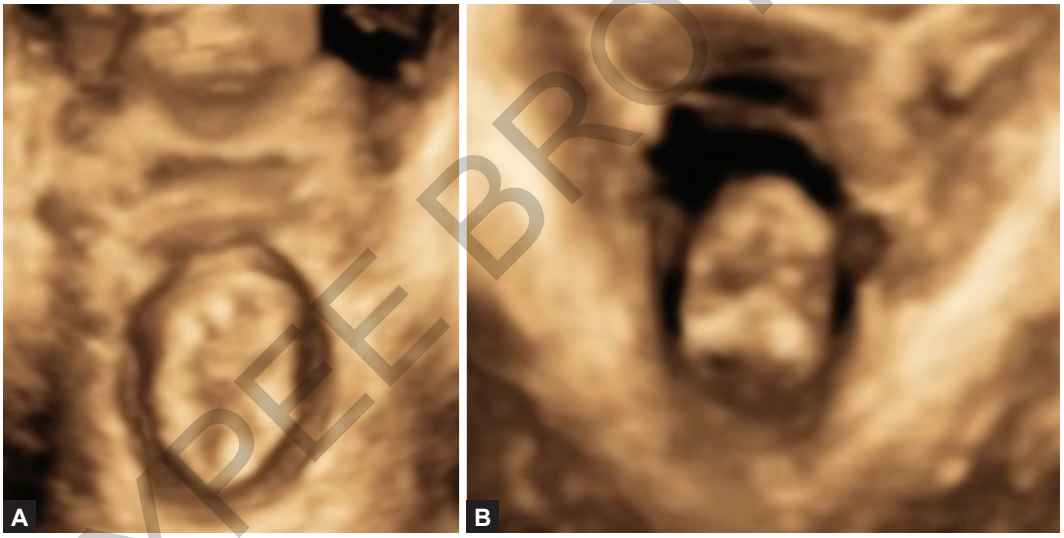

Figs. 8A and B: Endo anal scan to assess anus (A) intact anal sphincter (B) damaged external anal sphincter.

JAYPEE BROTHERS

Endoanal Route

It is selected for anal incontinence and anal tumors. It can also be used for assessment of anal sphincter **(Figs. 8A and B)**.

Ultrasound is an optional test in the evaluation of patients with complex or recurrent urinary incontinence (UI) and/or pelvic organ prolapse (POP) (Level of evidence 3, Grade of recommendation C).

Interpretation of Pelvic Floor Scan

Avulsion of the levator ani seen on the axial section of the pelvic floor is indicative of the weakening of pelvic floor and high possibility of descent **(Figs. 9A and B)**. For the prolapse or descent it has been shown that the levator hiatal size at rest closely correlates with the possibility of descent even in absence of trauma. Larger hiatal area than this indicates risk of prolapse. Hiatal overdistention may be

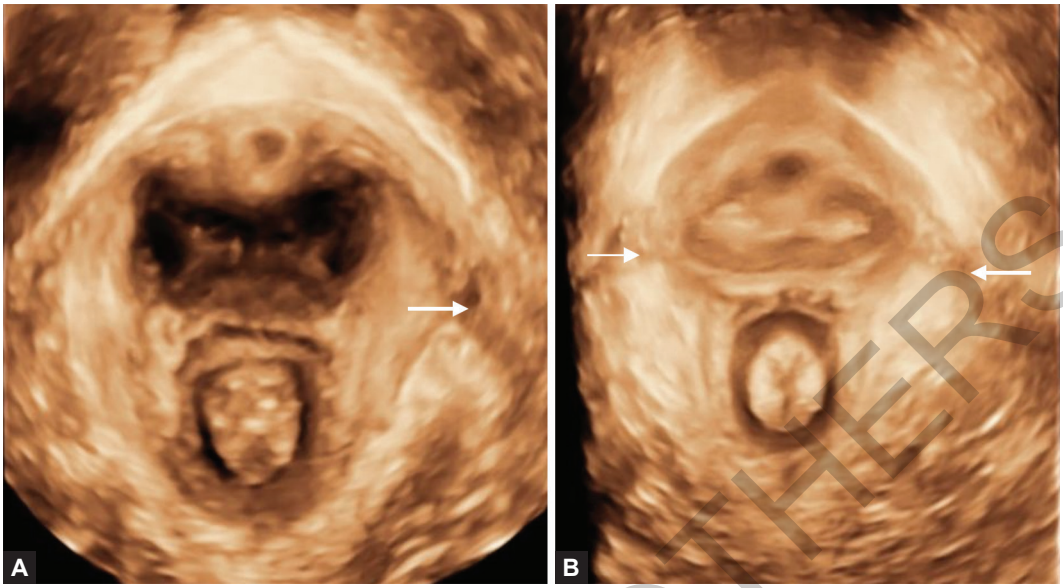

Figs. 9A and B: (A) Unilateral levator ani avulsion, shown by indicator on the image; (B) Bilateral levator ani avulsion.

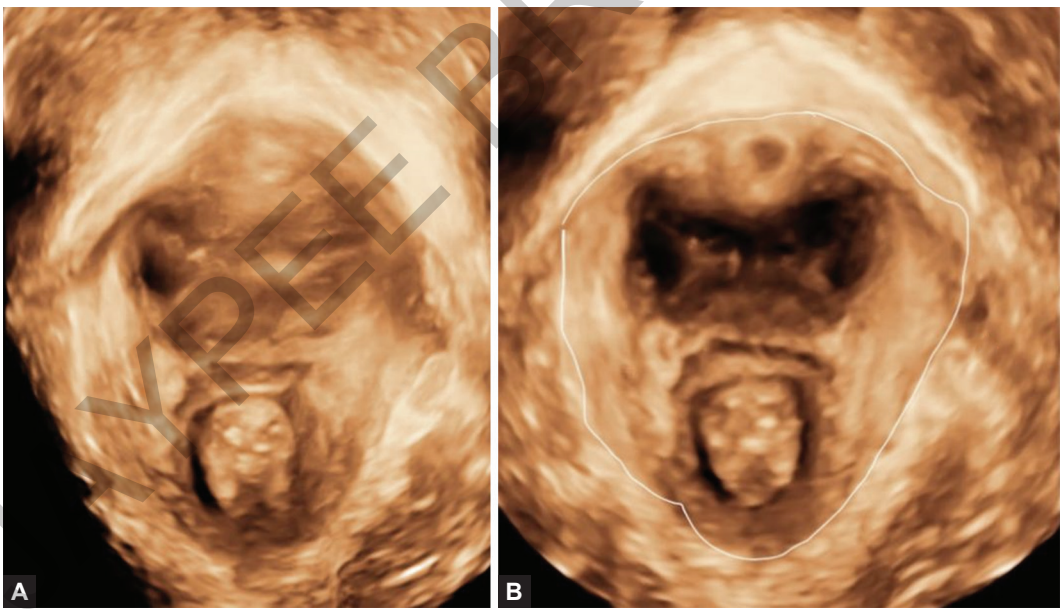

Figs. 10A and B: Measuring hiatus size. Normal in figure (A), ballooned in Figure (B).

present due to microtrauma, even in absence of avulsion. It is diagnosed by increase in >20% hiatal area (hiatus > 25 cm^2). 25 cm^2 is the upper limit of normal hiatus. The hiatal size is measured as shown in **Figures 10A and B**.

- Mild overdistention (25–29.9 cm^2)
- Moderate overdistention (30–34.9 cm^2)

JAYPEE BROTHERS

- Marked overdistention (35–39.9 cm^2)
- Severe overdistention (40+ cm^2)

CONCLUSION

Availability of pelvic floor ultrasound has revolutionized the understanding of morphological anomalies of levator ani. The cause of these abnormalities is now understood to be due to injury to the muscles of pelvic floor—traumatic avulsion of the muscles. Levator ani trauma leads to anterior and middle compartment prolapse. Abnormal puborectalis may lead to fecal incontinence. If avulsion is bilateral may lead to effect on sexual function. Ultrasound may be proposed as the initial examination of choice. Ultrasound may be used for assessment of bladder neck mobility before anti-incontinence procedures.

REFERENCES

1. Shek K, Deitz H. Intrapartum risk factors of levator trauma. Br J Obstet Gynecol. 2006;26:710-6.
2. Youssef A, Montaguti E, Sanlorenzo O, Cariello L, Salsi G, Morganelli G, et al. Reliability of new three dimensional ultrasound technique for pelvic hiatal area measurement. Ultrasound Obstet Gynecol. 2016;47:629-35.
3. Deitz H, Shek KL. Tomographic ultrasound imaging of the pelvic floor: which level matters most? Obstet Gynecol. 2009;33:698-703.
4. Kruger JA, Heap SW, Murphy BA, Dietz HP. Pelvic floor function in nulliparous women using three-dimensional ultrasound and magnetic resonance imaging. Obstet Gynecol. 2008;111(3):631-8.
5. Weinstein MM, Jung SA, Pretorius DH, Nager CW, den Boer DJ, Mittal RK. The reliability of puborectalis muscle measurement with 3-dimensional ultrasound imaging. Am J Obstet Gynecol. 2007;197: 68.e1-e6.
6. Schaer GN, Koechli OR, Schuesller B, Haller U. Perineal ultrasound: determination of reliable examination procedures. Ultrasound Obstet Gynecol. 1996;7:347-52.
7. Deitz HP, Wilson PD. Ultrasound in Urogynecology: an update on clinical application Urodyn. 1994;13:637-46.
8. Dietz HP, Wilson PD. The influence of bladder volume on the position and mobility of the urethrovesical junction. Int Urogynecol J Pelvic Floor Dysfunct. 1999;10(1):3-6.
9. Santoro GA, Wieczorek AP, Dietz HP, Mellgren A, Sultan AH, Shobeiri SA, et al. State of the art: an integrated approach to pelvic floor ultrasonography. Ultrasound Obstet Gynecol. 2011;37:381-96.
10. Dietz HP. Ultrasound imaging of the pelvic floor. Part II: three-dimensional or volume imaging. Ultrasound Obstet Gynecol. 2004;23:615-25.
11. Medina CA, Costantini E, Petri E, Mourad S, Singla A, Rodríguez-Colorado S, et al. Evaluation and surgery for stress urinary incontinence: A FIGO working group report. Neurourol Urodyn. 2017;36(2):518-28.
12. Dietz HP. Pelvic floor ultrasound: a review. Am J Obstet Gynecol. 2010;202:321-34.
13. Tunn R, Schaer G, Peschers U, Bader W, Gauruder A, Hanzal E, et al. Updated recommendations on ultrasonography in urogynecology. Int Urogynecol J Pelvic Floor Dysfunct. 2005;16: 236-41.
14. Tunn R, Paris S, Fischer W, Hamm B, Kuchinke J. Static magnetic resonance imaging of the pelvic floor muscle morphology in women with stress urinary incontinence and pelvic prolapse. Neurourol Urodyn. 1998;17:579-89.

JAYPEE BROTHERS

for detailed information on obstetrics and gynecology books, visit our website www.ejaypee.com, for detailed information on obstetrics and gynecology books, visit our we

Practical Guide to

3D–4D Ultrasound in Obstetrics and Gynecology

This book is a true practical guide to using of 3D–4D ultrasound. It narrates complete explanation of every knob, every function and every software including rendering, multiplanar images, automatized volume calculation tools, Spatio-temporal Image Correlation (STIC), etc. It also explains in detail all the options available for every software. And to follow that, is also a detailed explanation of where these functions can and softwares be applied for definite advantage of diagnosis in obstetric, gynecological and infertility patients. This book is a complete 'read and do' book for 3D–4D ultrasound in obstetrics, gynecology and infertility.

Sonal Panchal MD is an Ultrasound Consultant at Dr Nagori's Institute for Infertility and IVF, Ahmedabad, Gujarat, India. She is a versatile Ultrasound Specialist, with experience in 3D–4D ultrasound for more than 25 years. She has a thorough understanding of 3D–4D concept and has a high repute for innovative thinking in imaging. She has been one of the pioneers for the use of 3D–4D ultrasound for obstetric and gynecological applications. She is a popular Teacher in the field and an admired Trainer for 3D–4D ultrasound.

Chaitanya Nagori MD DGO is the Director of Dr Nagori's Institute for Infertility and IVF, Ahmedabad, Gujarat, India. He is a successful Infertility Consultant for more than 45 years with a very high success rate in his practice. With his highly innovative thinking, he was one of the first workers to apply 3D–4D ultrasound for monitoring of infertility treatment. He is a core Academician and a Teacher of high repute. He is a synonym for to-the-point teaching, with crisp and clear concepts. He is a Contributor and Author of several books and had several research publications.

Shelving Recommendation
OBSTETRICS AND GYNECOLOGY

ISBN 978-93-7202-815-7

9 789372 028157

Buy from ejaypee

JAYPEE BROTHERS