etailed information on orthopedic books, visit our website www.ejaypee.com, for detailed information on orthopedic books, visit our website www.ejaypee.com

Tuberculosis of the Skeletal System

Bones, Joints, Spine and Bursal Sheaths







SM Tuli

Forewords
M Shantharam Shetty
Apurv Mehra
Raj Bahadur

7th Edition

JAYPEE

Contents

Section 1: General Considerations

1. Epidemiology and Prevalence **3**
Regional Distribution 5
Incidence of Disease and Institutional Data 5
Prophylaxis Against Tuberculosis and BCG Vaccination 6

2. Pathology and Pathogenesis **8**
Experimental Tuberculosis 8
Osteoarticular Disease 9
Role of Trauma 9
The Tubercle 10
Cold Abscess 10
Tubercular Sequestra 10
Spinal Tuberculosis 11
Types of the Disease 13
Future Course of the Tubercle 13
Tuberculosis as a Late Complication of "Implant-Surgery" 13
Immunopathology of Skeletal Tuberculosis 14
Therapeutically Refractory Cases 15
Immunodeficient Stage and Looming Tuberculosis Epidemic 15
Immunomodulation 18

3. The Organism and its Sensitivity **19**
Mycobacterium tuberculosis 19
Mycobacterium Cultures 20
Sensitivity of Organism 20
Disease Caused by Atypical Mycobacteria 21

4. Evolution of Treatment of Skeletal Tuberculosis **23**
Preantitubercular Era 23
Postantitubercular Era 25

5. Diagnosis and Investigations **29**
General Clinical Picture 29
Diagnosis 29

6. Antitubercular Drugs **39**
Streptomycin(S) 39
Para-aminosalicylic Acid (PAS) 39
Isoniazid (INH-H) 40
Ethambutol(E) 40
Rifampicin(R) 42
Pyrazinamide(Z) 42
Thioacetazone with Other Drugs 42
Alternative Regimens 42
Corticosteroids and Nonsteroidal Anti-inflammatory Drugs 43
The Role of Antitubercular Drugs 43
Penetration of Antitubercular Drugs 45

7. Principles of Management of Osteoarticular Tuberculosis **47**
Prognosis and Course 47
Classification of Articular Tuberculosis 47
Principles of Management 48

Section 2: Extra-spinal Regional Tuberculosis

8. Tuberculosis of the Hip Joint **59**
Clinical Features 59
Prognosis 69
Management 69
Indications for Surgical Treatment 78
Surgical Approaches to the Hip Joint 81
Alternative Approaches 83
Relevant Surgical Anatomy of the Hip Joint 91

9. Tuberculosis of the Knee Joint **94**
Pathology 94
Clinical Features 95
Differential Diagnosis 97
Prognosis 98
Treatment 99
Surgical Techniques 101
Relevant Surgical Anatomy of the Knee Joint 107

10. Tuberculosis of the Ankle and Foot **109**
Tuberculosis of Ankle 109
Tuberculosis of Foot 112
Relevant Surgical Anatomy of the Ankle and Foot 114

11. Tuberculosis of the Shoulder **116**
Management 117
Arthrodesis of Shoulder 119
Relevant Surgical Anatomy of the Shoulder Joint 122

12. Tuberculosis of the Elbow Joint **124**
Management 125
Operative Techniques for Tuberculous Elbow 126
Relevant Surgical Anatomy of Elbow Joint 128

13. Tuberculosis of the Wrist **130**
Clinical Features 131
Management 131
Operative Treatment 132
Wrist Arthrodesis 132
Relevant Surgical Anatomy of the Wrist 132

14. Tuberculosis of Short Tubular Bones **134**
Differential Diagnosis 134
Tuberculosis of the Joints of Fingers and Toes 135

15. Tuberculosis of the Sacroiliac Joints and Sacrum **137**
Clinical Features 137
Management 138

16. Tuberculosis of Rare Sites, Girdle and Flat Bones **141**
Sternoclavicular Joint 141
Acromioclavicular Joint 141
Tuberculosis of Clavicle 141
Tuberculosis of Scapula 141
Tuberculosis of Symphysis Pubis 143
Tuberculosis of Skull and Fascial Bones 143
Tuberculosis of Sternum and Ribs 146

17. Tuberculous Osteomyelitis **148**
Tuberculous Osteomyelitis without Joint Involvement 148
Tuberculosis of Long Tubular Bones 150
Treatment 152

18. Tuberculosis of Tendon Sheaths and Bursae **154**
Tuberculous Bursitis 156

Section 3: Tuberculosis of the Spine

19. Clinical Features **159**
Age and Sex 159
Symptoms and Signs 159
Abscesses and Sinuses 160
Analysis of Clinical Material 161
Regional Distribution of Tuberculous Lesions in the Vertebral Column (In the Pre-MRI Era—Observed by Conventional X-rays) 161
Vertebral Lesion 162
Associated Extra-spinal Tubercular Lesions 163

20. X-ray Appearances and Findings on Modern Imaging **165**
Number of Vertebrae Involved 165
Kyphotic Deformity (Angulation of Spine with Convexity Posteriorly) 169
Central Type of Lesion (Tuberculosis of the Centrum of Vertebral Body) 171
Lateral Shift and Scoliosis 175
Natural Course of the Disease 175
Modern Imaging Techniques 176
Clinico-radiological Classification of Typical Tubercular-spondylitis 181

21. Differential Diagnosis **185**
Consideration of Age in Diagnosis 185
Pyogenic Infections 186

22. Neurological Complications **195**
Incidence 195
Classification of Tuberculous Paraplegia 195
Pathology of Tuberculous Paraplegia 198
Extradural Granuloma and Tuberculoma 201
Signs and Symptoms of Pott's Paraplegia Associated with Disease Proximal to Lumbar First Vertebra 204
Myelography (Now Replaced by MRIs SINCE 1987 ±) 204
Prognosis for Recovery of Cord Function 205
Treatment of Pott's Paraplegia 207
Development of Severe Kyphotic Deformity 208

23. Management and Results **209**
Evolution of Treatment 209

24. Operative Treatment **240**
Cold Abscesses 240
Surgical Approaches 241
Operative Procedures 243

Operative Complications and it's Prevention 257
Anterolateral Approach to the Lumbar Spine (Lumbovertebrotomy) 258
Surgery in Severe Kyphosis 265
Instrumentation in Tuberculous Spine 269
Re-operation for Decompression 271

25. Spinal Braces **274**

26. Relevant Surgical Anatomy **277**
Vertebral Bodies 277
Intervertebral Joint 278
Intervertebral Disc 278
Blood Supply of the Vertebral Column 279
The Bony Vertebral Canal 280
Blood Supply to the Spinal Cord 280
Cross-sectional Topography of the Spinal Cord 281

Take Home Key Points (Collated by Dr Apurv Mehra) **283**

Bibliography **295**
Section I and II: General Considerations and Extra-spinal Regional Tuberculosis 295
Section III: Tuberculosis of the Spine 309

Index ***323***

SECTION 2

Extra-spinal Regional Tuberculosis

Chapter 8: Tuberculosis of the Hip Joint

Chapter 9: Tuberculosis of the Knee Joint

Chapter 10: Tuberculosis of the Ankle and Foot

Chapter 11: Tuberculosis of the Shoulder

Chapter 12: Tuberculosis of the Elbow Joint

Chapter 13: Tuberculosis of the Wrist

Chapter 14: Tuberculosis of Short Tubular Bones

Chapter 15: Tuberculosis of the Sacroiliac Joints and Sacrum

Chapter 16: Tuberculosis of Rare Sites, Girdle and Flat Bones

Chapter 17: Tuberculous Osteomyelitis

Chapter 18: Tuberculosis of Tendon Sheaths and Bursae

JAYPEE BROTHERS

JAYPEE BROTHERS

CHAPTER 8

Tuberculosis of the Hip Joint

JAYPEE BROTHERS

Tuberculous disease of the hip is very common, the frequency of involvement is next only to spinal tuberculosis. In any long series, hip disease constitutes nearly 15% of all cases of osteoarticular tuberculosis (Martini 1988, Babhulkar 2002). The initial focus of tuberculous lesion may start in the acetabular roof, epiphysis, metaphyseal region (Babcock's triangle), or in greater trochanter **(Fig. 8.1)**. Rarely the disease may start in the synovial membrane and may remain as synovitis for a few months. Tuberculosis of the greater trochanter may involve the overlying trochanteric bursa without involving the hip joint for a very long time. As the upper end of femur is entirely intracapsular the joint gets involved rapidly from any osseous lesion situated within the capsular attachments, the disease becomes "osteoarticular", and destruction of articular surfaces of femoral head and acetabulum takes place. When the initial focus starts in the acetabular roof, the joint involvement is late and severity of symptoms mild, therefore, by the time the patient first reports to the hospital extensive destruction of the bone is already present. A cold abscess usually forms within the joint, the inferior weaker part of capsule or rarely the acetabular floor may be perforated and the cold abscess may present anywhere around the hip joint such as femoral triangle, medial, lateral or posterior aspects of thigh, ischiorectal fossa, or pelvis. The abscess tracks away from the hip joint mostly along the neighboring vessels and nerves to reach the surface. The intrapelvic abscess above the attachments of the levator ani muscle tracks upwards to point in the inguinal region; whereas those below this muscle, track into the ischiorectal fossa.

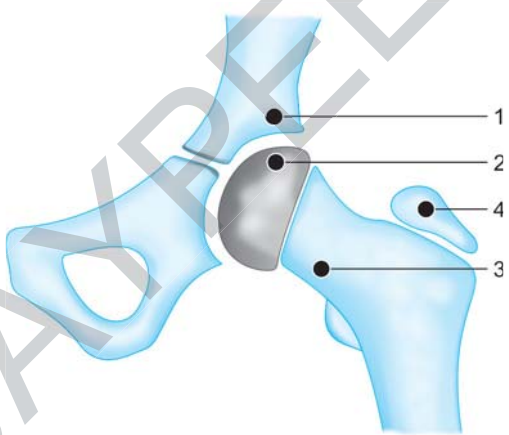

Fig. 8.1: Diagrammatic representation of the location and frequency of osseous origin of tuberculosis of the hip joint; (1) upper part of acetabulum (the commonest); (2) femoral head/epiphysis; (3) femoral neck/metaphysis; (4) greater trochanter (the least common).

CLINICAL FEATURES

Like osteoarticular tuberculosis in general commonest age of start of illness is during first 3 decades. Pain, limping, deformity and fullness around the hip are the presenting symptoms

when the disease is active. Pain is often referred to the medial aspect of the knee and is maximum toward the end of the day. A child may wake from sleep due to night cries. In developing countries, nearly 8% of patients may have clinically palpable cold abscesses with or without sinuses, and nearly 10% of patients may present with varying degrees of pathological subluxation or dislocation of the hip.

The limp is the earliest and commonest symptom. The patient while walking puts as little pressure on the diseased hip joint (for a short time) as possible (i.e., has shortest possible stance phase of the affected side) giving rise to the typical antalgic gait. To get relief from the pain of an active hip disease while changing position in the bed, the patient may support or lift the involved limb with the contralateral normal limb, or the patient may "apply traction" on the painful hip by pushing down on the dorsum of foot with the opposite foot while recumbent. So long as the disease is active, physical examination will reveal tenderness by direct pressure on the hip in the femoral triangle, or medial to the greater trochanter posteriorly or indirectly, by bitrochanteric pressure or thumping. Muscle spasm can be appreciated in the lower abdominal muscles, and in the adductors of the thigh on attempting sudden abduction-external rotation at the hip joint. In untreated cases, the disease of the hip joint passes through different stages as follows (Chapter 7, **Table 8.1** adapted from Babhulkar and Pandey 2002, **Table 8.2**).

Tubercular Synovitis (Stage I)

In synovitis, or early disease of the hip joint due to a juxta-articular osseous lesion causing "irritable hip", the joint is held in the position of maximum capacity, that is flexion, external rotation and abduction, causing apparent lengthening. There is no true/real shortening. Only extremes of movements are limited and painful. X-rays may show only soft tissue swelling, with or without rarefaction of the hip bones **(Fig. 8.2)**.

The differential diagnosis at this stage is from traumatic synovitis, rheumatic/rheumatoid disease, nonspecific transient synovitis, low-grade pyogenic infection, Perthes' disease, juxta-articular disease causing irritation of the joint, spasm of the iliopsoas muscle due to an abscess in its sheath or overlying inflamed lymph nodes/viscera, slipped capital femoral epiphysis and avascular necrosis of femoral head. Careful clinico-radiological examination and noninvasive investigations repeated at 3–6 weeks intervals usually help establish the exact diagnosis. Ultrasonography has been shown to be a useful investigation to appreciate the swelling of the soft tissues of the hip joint. MRI at this stage may show synovial effusion and varying degree of bone edema. If the pathological nature is

Table 8.1: During growing years common hip conditions that require attempt at differentiation.

	Irritable hip	***Septic hip***	***Perthes' hip***	***Tuberculosis hip***
Age	3–9 years	1–6 years	4–8 years	Any age
Pain	Mild	Severe	Mild	Severe
Weight bearing	Comfortable	Uncomfortable	Mild discomfort	Uncomfortable
Images	↑ Synovial fluid Thickened synovium	↑ Synovial fluid Thickened synovium Subperiosteal erosion	↑ Synovial fluid Thickened synovium Hyperdense femoral head	↑ Synovial fluid Thickened synovium Eroded articular margins
Synovial fluid aspirate	Sterile	Pus cells ++	Sterile	Mycobacteria ±
NSAIDs response	Favorable	Symptomatic	Temporary	Temporary

Aspirate by inserting the needle (A) proximal to the greater trochanter directing toward the femoral head; or (B) insert the needle almost vertically from anterior aspect – 1.5 cm lateral to the palpable femoral artery and 1–2 cm distal to the mid-inguinal point.

JAYPEE BROTHERS



Figs. 8.2A to C: Successive X-rays of a patient of tuberculous synovitis of right hip, treated by antitubercular drugs, traction, repetitive exercises and guarded weight bearing (for 2 years). Except moderately uncovered large femoral head and mild **coxa-valga**, there was no functional disability on healing of disease and follow-up of 17 years.

Table 8.2: Clinicoradiologic classification of tuberculosis of the hip.

Stages	*Clinical findings*	*Radiologic features*
1. Synovitis	Flexion, abduction, external rotation, apparent lengthening	Soft tissue swelling, haziness of articular margins and rarefaction
2. Early arthritis	Flexion, adduction, internal rotation, apparent shortening	Rarefaction, osteopenia, marginal bony erosions in femoral head, acetabulum or both, No gross reduction in joint space
3. Advanced arthritis	Flexion, adduction, internal rotation, true shortening	All of the above and destruction of articular surface, reduction in joint space
4. Advanced arthritis with subluxation/dislocation	Flexion, adduction, internal rotation with gross shortening	Gross destruction and reduction of joint space, wandering acetabulum

There is progressive loss of motion in various stages; least in stage of synovitis and gross in arthritis with subluxation/dislocation. For comfort from pain during long decubitus some patients may continue the position of abduction and external rotation, keeping the thigh resting on the bed.

undiagnosable, biopsy must be obtained from the representative diseased tissue for bacteriological, PCR and histological investigations.

Early Arthritis (Stage II)

As the disease advances, actual destruction or damage to the articular cartilage sets in. The local signs become more prominent and due to the spasm of adductors and flexors the hip assumes a deformity of flexion, adduction (presenting as apparent shortening) and internal rotation. There is true/real shortening of not >1 cm, appreciable muscle wasting, and restriction of movements, due to pain and muscle spasm, in all directions. X-rays show localized osteoporosis, slight diminution of the joint space due to decrease in the vertical height of the articular cartilage and localized erosions at the articular margins **(Fig. 8.6)**. MRI at this stage may show synovial effusion, synovial thickening, minimal areas of bone destruction and osseous edema.

Advanced Arthritis (Stage III)

With further advancement of destruction, clinical signs of flexion-adduction-internal rotation deformities, restriction of movements, muscle wasting **(Figs. 8.3 to 8.5, and 8.7 to 8.16)**, true and apparent shortenings are exaggerated. The tendency of the patient to sleep on the side of the uninvolved hip further contributes to the flexion, adduction and internal rotation deformity. There is gross destruction of articular cartilage and bones of the femoral head and acetabulum **(Fig. 8.5)**. The capsule is further destroyed, thickened and contracted.

Advanced Arthritis with Subluxation or Dislocation (Stage IV)

With further destruction of acetabulum, femoral head, capsule and ligaments, the upper end of femur may displace upwards and dorsally in the wandering or migrating acetabulum, leaving

JAYPEE BROTHERS

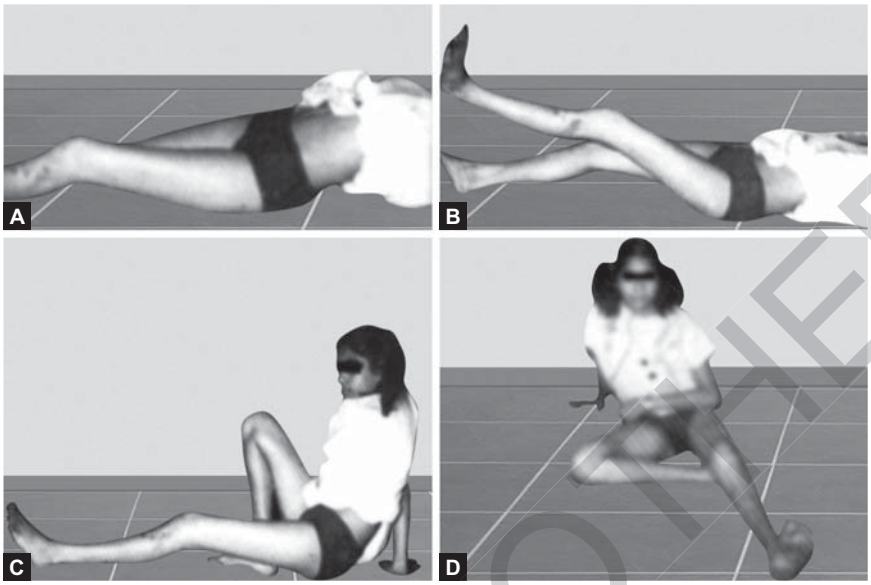

Figs. 8.3A to D: Clinical pictures of a young patient with advanced tuberculous arthritis of left hip joint. (A and B) Note fixed flexion deformity of 45 degrees; (C) Shows the position the patient adopts, to ease herself using an Indian-type of toilet; (D) Shows the posture while sitting on the floor. Being a young patient she manages these postures because of the compensatory movements at the lumbar spine; with advancing age such compensations become more difficult.

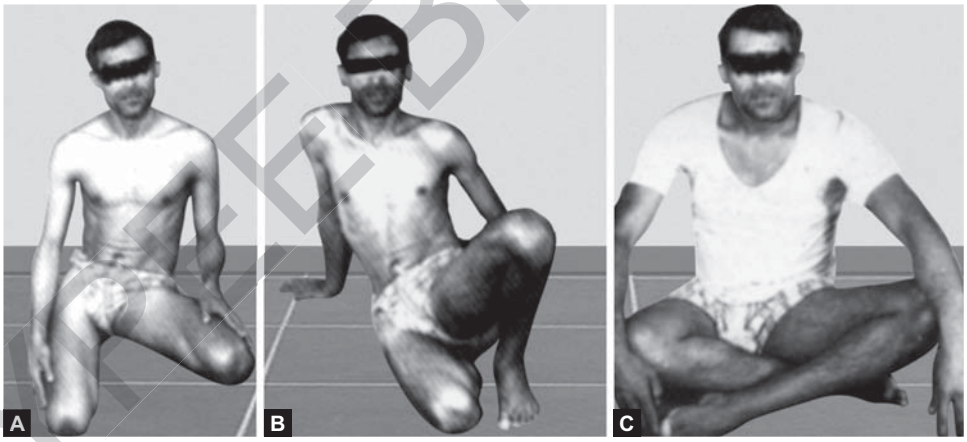

Figs. 8.4A to C: (A and B) show the method of attending to the social needs in a 35-year old man whose right hip was ankylosed at 40 degrees of flexion. (C) The same patient was able to squat and sit cross-legged after excisional arthroplasty of right hip joint.

its lower part empty and Shenton's arc broken **(Figs. 8.7, 8.8, 8.10 to 8.13, 8.19 to 8.25)**. Rarely the destruction of capsule and acetabulum may be so severe as to lead to frank pathological posterior dislocation of the femoral head **(Fig. 8.13)**. This severe variety of tuberculous infection can rarely be encountered in children. Sometimes the hip may show protrusio acetabuli **(Figs. 8.7 and 8.8)**. In some cases, the femoral head and neck are grossly destroyed, collapsed and small in size (coxa breva) **(Fig. 8.10)** contained in an enlarged acetabulum producing a mortar–pestle appearance (Shanmugasundaram 1983).

JAYPEE BROTHERS

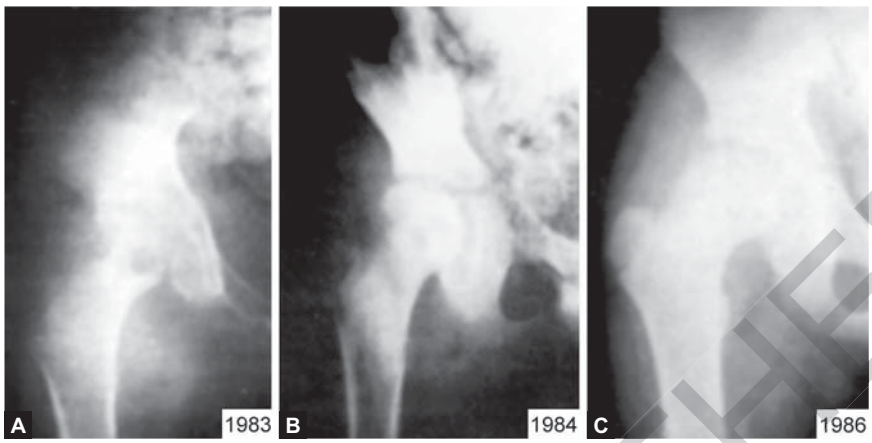

Figs. 8.5A to C: X-rays of a case of tuberculosis of the right hip joint at presentation (A) showing destructive changes in the acetabulum and the femoral head. There is wandering acetabulum, lower part of the acetabular cavity is empty and the femoral head is uncovered. The patient was treated by antitubercular drugs, skeletal traction and repetitive exercises for the right hip joint. X-rays (B) one year, (C) 3 years after the treatment show improvement of anatomy, reformation of joint margins and space, restitution of destroyed trabeculae, and coxa magna. Despite persistence of the wandering acetabulum the patient obtained a painless, 80% mobile and stable hip joint.



Fig. 8.6: A child with tuberculosis of the left hip joint, early arthritis (stage II) resembling the "normal hip" appearance. Note slight diminution of the joint space and a juxta-articular lytic lesion in the acetabular roof.

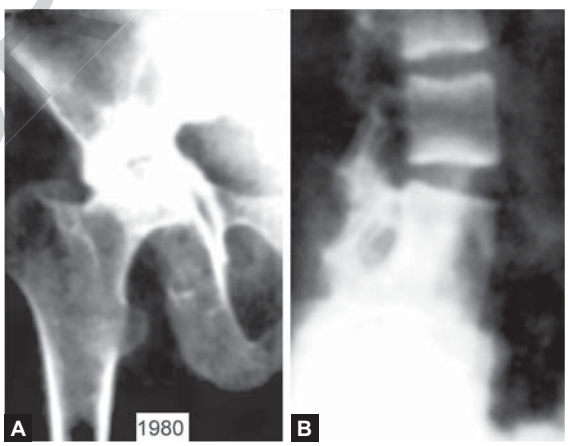

Figs. 8.7A and B: Advanced tuberculous arthritis (stage IV) of right hip joint: Note destruction and deformation of femoral head, wandering acetabulum, upward migration of femoral head, break in the Shenton's arc, empty lower part of the acetabulum, and protrusio acetabuli. The patient also had concomitant tuberculous spondylitis involving lumbar 4–5 vertebrae.

In general, the movements at this stage are grossly restricted, however, some cases with the radiological appearance of wandering acetabulum, protrusio-acetabuli, or mortar-pestle picture may retain fairly good range of movements for a long time **(Fig. 8.11)**. In some cases of aftermath of tuberculous arthritis with the disease healed in the displaced position, the femoral head may be supported by a buttress (false acetabulum) formed over its posterosuperior aspect **(Figs. 8.12 and 8.13)**.

In certain cases of tuberculous arthritis (Stages II, III and IV), the hip may not assume the classical triple deformity of flexion, adduction and internal

JAYPEE BROTHERS



Fig. 8.8A: Active tubercular arthritis of right hip joint. Note localized osteoporosis, break in the Shenton's arc, widened acetabulum, **protrusio acetabuli**, avascular capital femoral epiphysis (Perthes type) and mild coxa vara.

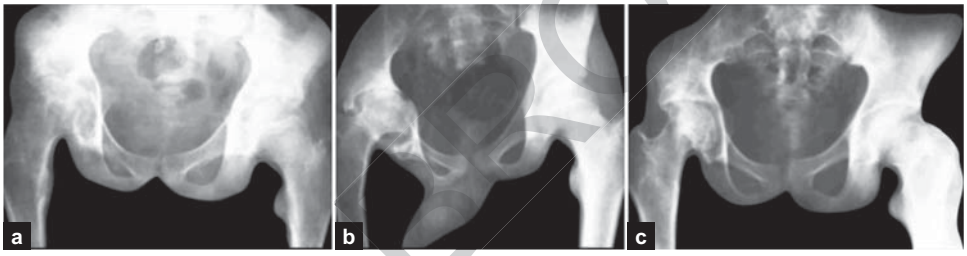

Figs. 8.8B(a to c): Another case of **protrusio acetabuli** showing the outcome of treatment with ATT and ROM exercises. TB-hip protrusio type (a) presentation = fuzzy borders, osteoporosis (b) one year after ATT (c) 3 years after treatment, improved mineralization and joint space.



Fig. 8.9A: X-ray of a child with tuberculosis of left hip joint. One can appreciate diminished joint space, indistinct joint margins, subluxation of femoral head, avascular **(Perthes type)** capital femoral epiphysis and cavities in the femoral neck (Stage IV).

JAYPEE BROTHERS

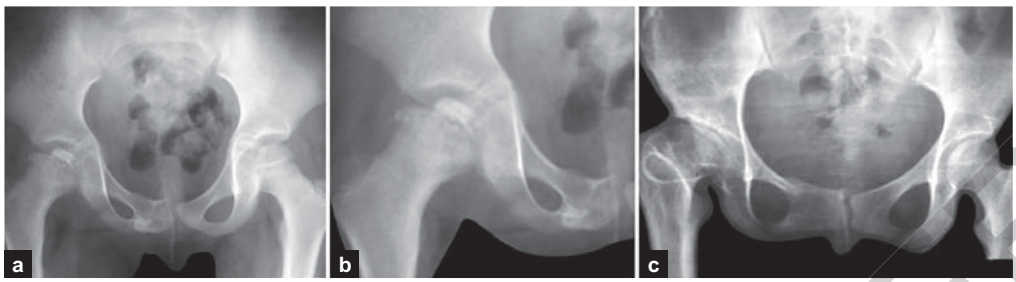

Figs. 8.9B(a to c): Another case of **Perthes-type** tuberculous infection showing the outcome of ATT and ROM exercises. (a and b) TB Hip Perthes' type: sclerotic physis, metaphyseal osteoporosis: Also note TB of right pubic bone. (c) Healed status resembles healed Perthes'–coxa-magna + short neck (coxa-breva), enlarged right pubic bone.

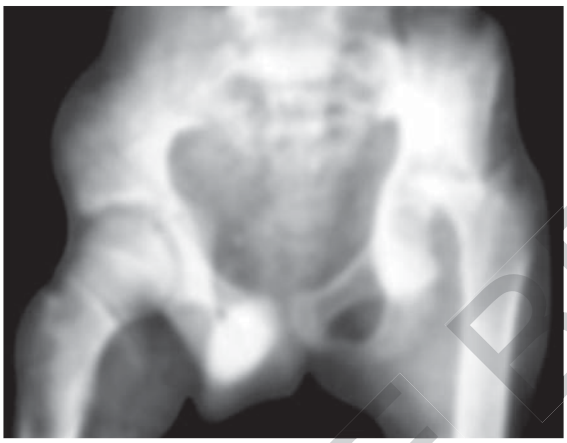

Fig. 8.10A: Tubercular arthritis of left hip joint (stage IV). Note break in the Shenton's arc, emptying of lower half of acetabulum, wandering acetabulum and grossly destroyed femoral head and neck **(mortar-pestle appearance)**.



Fig. 8.10B: Another case showing **mortar-pestle appearance** in a healed status of infection. He managed his life up to 60 years of age when he sought medical care for pain in the left joint.

rotation, instead the deformity may be that of flexion, abduction and external rotation **(Figs. 8.14 and 8.16)** with the lateral aspect of thigh of the diseased hip resting on the bed. This may be due to continuous adoption of the latter posture for relief of pain, or due to the destruction of iliofemoral Y ligament by the tuberculous process. In some cases, there is lack of correlation between the radiographic appearance of the hip disease and the range of movements possible in the joint.

If the limb has been plastered for >12 months (as was the practice in first half of 20th century), the growth plates around the knee may undergo premature fusion producing marked shortening and limitation of movements (once called "frame knee"). During growing age in some patients, hyperemia and overgrowth of the femoral head and neck may lead to coxa magna which is often associated with moderate valgus deformity and anteversion of the femoral neck, and some degree of adaptive changes in the acetabulum resembling acetabular "dysplasia". Coxa vara may also occur rarely following a destructive lesion in the femoral head and neck (leading to arrested growth of capital physis) in the presence of normal growth of the greater trochanter.

JAYPEE BROTHERS

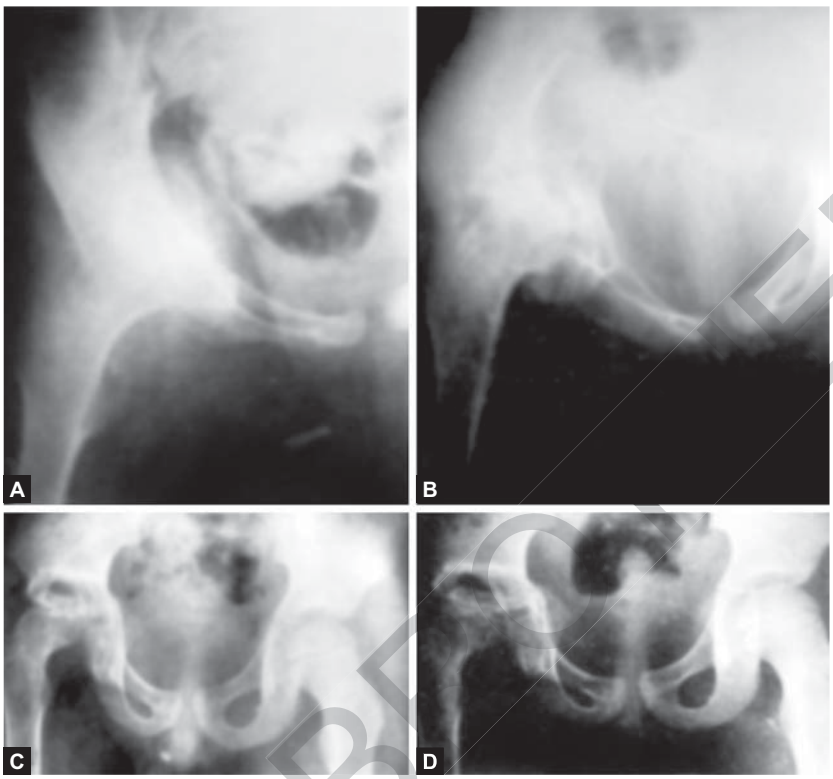

Figs. 8.11A to D: Serial X-rays of a child treated by functional method: (A) at the age of 5, (B) at the age of 6, (C) at 8 years and (D) at 9 years of age, 5 years after the onset of treatment. The patient at the last follow-up had complete healing of disease, though radiologically the femoral head was flattened and the acetabulum was irregular, and **wandering** the boy was able to squat, sit cross-legged and do normal physical activities.



Fig. 8.12: Radiograph showing aftermath of tuberculous arthritis of left hip joint. Note empty acetabulum, coxa magna with dislocation and flattening of the femoral head, and formation of a **secondary false acetabulum** superior and dorsal to the original acetabulum.

Classification of the Radiological Appearance (Figs. 8.5 to 8.17)

Shanmugasundaram (1983) suggested a radiological classification for tuberculous disease of the hip applicable for the lesions in children (C) and adults (A). Following radiological types are suggested by him: "normal" appearance (C); travelling acetabulum (C, A); dislocated hip (C); Perthes' type (C); protrusion acetabuli (C, A); atrophic type (A); "mortar and pestle" type (C, A). There is a relationship between various radiological types and the functional outcome (Campbell and Hoffman 1995). If the disease occurs during childhood (growing period), chronic hyperemia would lead to enlargement of femoral head epiphysis and metaphysis (coxa magna), thromboembolic phenomenon of selective

JAYPEE BROTHERS

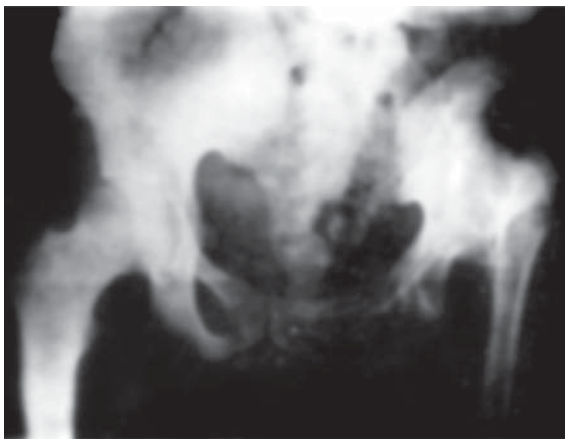

Fig. 8.13: A 26-year-old male suffered from tuberculous infection of left hip joint when he was 9-year-old. The disease healed by traction and antitubercular drugs. The patient had managed his routine activities with a shoe-raise of 6 cm. Now 17 years after the onset of disease, he has started complaining of pain in the left hip region probably due to degenerative changes in the **secondary hip joint**. Note on the left side empty acetabulum, pathological dislocation of hip joint, probable formation of a secondary acetabulum, and hypoplastic pelvis and femur.



Fig. 8.14: X-ray of tubercular arthritis of right hip joint. The limb has attained the unusual deformity of flexion, abduction and external rotation (maximal capacity of intracapsular space).

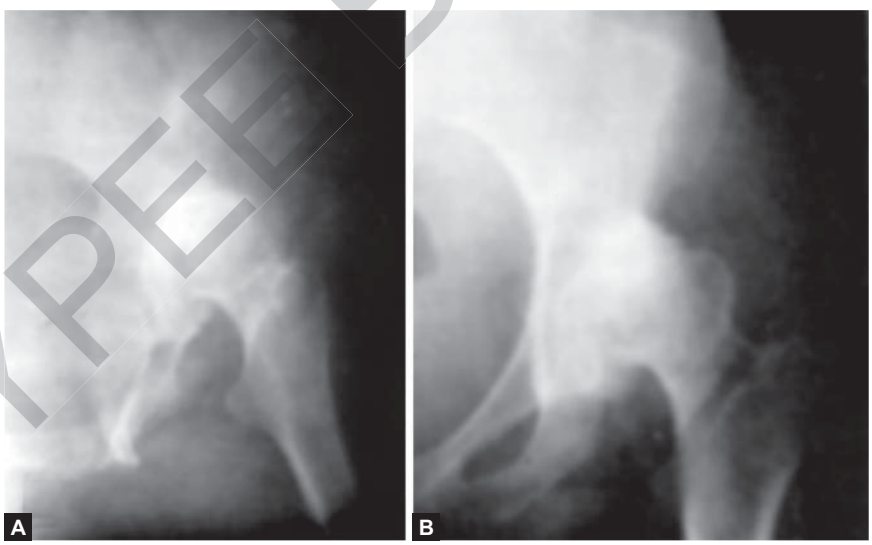

Figs. 8.15A and B: At the age of 18 years, this young lady was treated by traction, exercises, and antitubercular chemotherapy. The disease healed and she obtained a painless, stable and mobile hip joint. Having enjoyed the ability of sitting cross-legged and squatting for 22 years (A), she has now reported for pain in the hip joint due to secondary degenerative changes. The recent clinical examination revealed range of flexion of hip joint from 0 to 90 degrees, the X-rays revealed a wandering acetabulum, diminished joint space, spheroidal uncovered femoral head and **secondary degenerative** change in the left hip joint at 40 years of age (B).

JAYPEE BROTHERS



Fig. 8.16: A 6-year-old boy, presented with pain, limping and deformity of right hip joint for 2 months duration. Plain X-rays revealed an abduction deformity of right hip and moderate degree of diminution of the joint space. One can note the uncovering of the contralateral (left) femoral head due to marked fixed abduction deformity of the right hip. Tuberculous nature of pathology was confirmed from the tissue obtained while preforming arthrolysis and synovectomy on right hip joint.

terminal vasculature may create the changes resembling Perthes' disease **(Figs. 8.8 and 8.9)** gross decrease in the blood supply of the femoral head and its physis due to thromboembolic phenomenon or due to rapidly developing tense intracapsular effusion (tamponade effect) may be responsible for reduction in the size of femoral head and neck (coxa breva), restricted growth of capital femoral epiphyseal plate in the presence of normal growth of trochanteric growth-plate would lead to coxa vara, and restricted growth of trochanteric physis in the presence of normal growth of femoral head physis would result in coxa valga. Vascular changes can also occur due to destructive osseous cavities (affecting intraosseous circulation) in the upper end of femur, by a sudden pathological dislocation, or as a complication of operative intervention.

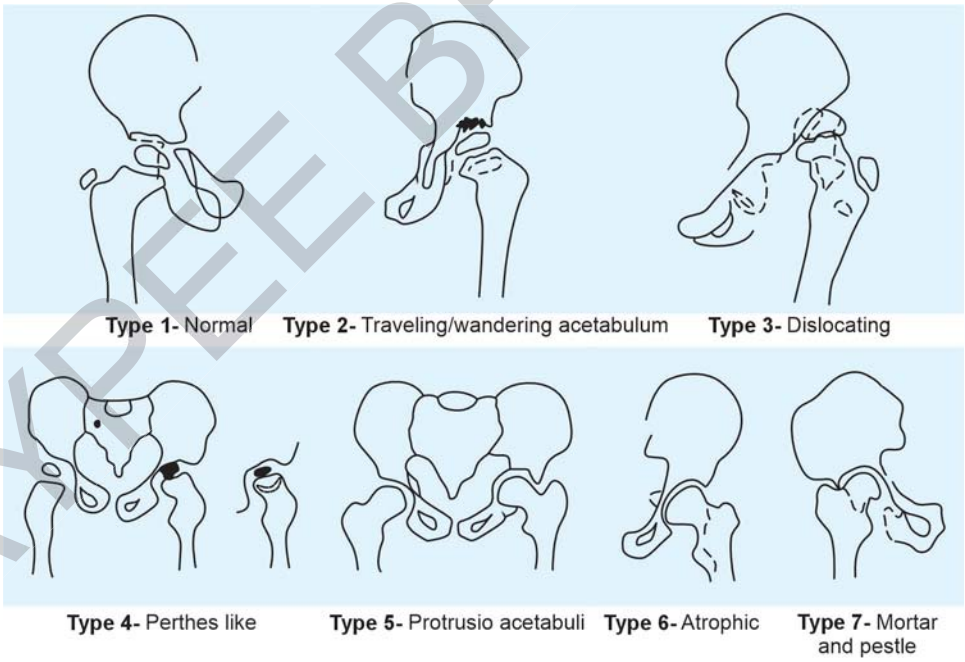

Fig. 8.17: Radiological types of tuberculosis of hip. Rarely a tuberculous hip joint may be healed with bony-ankylosis, more chances if there is concomitant pyogenic infection.

Courtesy: Shanmugasundram, 1983.

JAYPEE BROTHERS

More than one factor may be responsible for the radiological appearance in a particular case.

Rarely, simultaneous damage to the trochanteric physis and femoral head physis would result in generalized hypoplasia of upper end of femur (coxa breva). Campbell and Hoffman (1995) while treating children with tuberculosis of hip joint observed a close relationship between the radiological type and the therapeutic outcome; "good-results" were obtained in 92% of "normal type", 80% of Perthes' type, 50% of dislocating type, 29% of travelling-acetabulum and mortar-pestle type. If the radiological joint space was reduced to 3 mm or less, the outcome could be predicted as poor.

PROGNOSIS

The outcome of prognosis with modern antitubercular drugs depends essentially on the stage of the disease when the treatment is initiated (Caparros 1999, Silber 2000, Babhulkar 2002, Saraf 2014). Early disease (synovitis or early arthritis) may heal leaving a normal or nearly normal hip joint **(Figs. 8.2 and 8.20 to 8.24)** (Moon et al. 2012). Healing in the state of advanced arthritis generally results in fibrous ankylosis. If correction of deformities was not achieved by timely and appropriate treatment (traction, splintage or operation), the ankylosis is likely to occur in a non-functional position of flexion and adduction. The diseased limb may show gross shortening a few years after the treatment. This is usually the result of gross destruction of hip bones, damage to proximal femoral physis, and occasionally premature fusion of distal femoral physis if the limb has been immobilized for >1 year.

Some of these cases may be associated with a tuberculous cavity situated in the femoral neck. The femoral head then passes through the typical phases such as metaphyseal osteoporosis, diminution of the vertical height of the capital femoral epiphysis, increased density, fragmentation, collapse of the proximal segment, and development of coxa-magna with healing. Such patients require to be treated like Perthes' disease with simultaneous coverage by effective antitubercular drugs.

MANAGEMENT

All patients during active stage are treated by multidrug therapy, and traction to correct the deformity **(Figs. 8.18 and 8.34)** if present and to give rest to the part. In the presence of abduction deformity, for better control of the pelvis, bilateral traction (well leg traction) is mandatory, otherwise traction to the deformed limb alone would increase the abduction deformity further. Traction relieves the muscle spasm, prevents or corrects deformity and subluxation, maintains the joint space, minimizes the chances of development of migrating acetabulum and permits close observation of the hip region. Any palpable cold abscess may be aspirated with instillation of streptomycin with or without isoniazid.

If there is favorable clinical response the same treatment should be continued. In cases which do not have gross ankylosis, active assisted movements of the hip are started as soon as the pain has subsided. The hip mobilization exercises are gradually increased to 5–10 minutes every hour during the period the patient is awake, and within the limits of tolerable pain. With the traction applied, the patient may be progressively encouraged to sit and touch his forehead to the knee, sitting in squatting position and putting the thigh in abduction and external rotation. Usually after 4–6 months of treatment the patient may be permitted ambulation with suitable orthosis and crutches. The ambulation should be non-weight bearing for first 12 weeks and partial weight bearing for the next 12 weeks. Nearly 12 months after the onset of treatment, crutches or orthosis may be discarded. Excellent results are obtained by the above non-operative regime in majority of cases of synovial disease, in many cases with early arthritis **(Figs. 8.19 to 8.26)** and in some cases of advanced arthritis **(Figs. 8.5, 8.11, 8.15, and 8.19 to 8.26)**.

JAYPEE BROTHERS

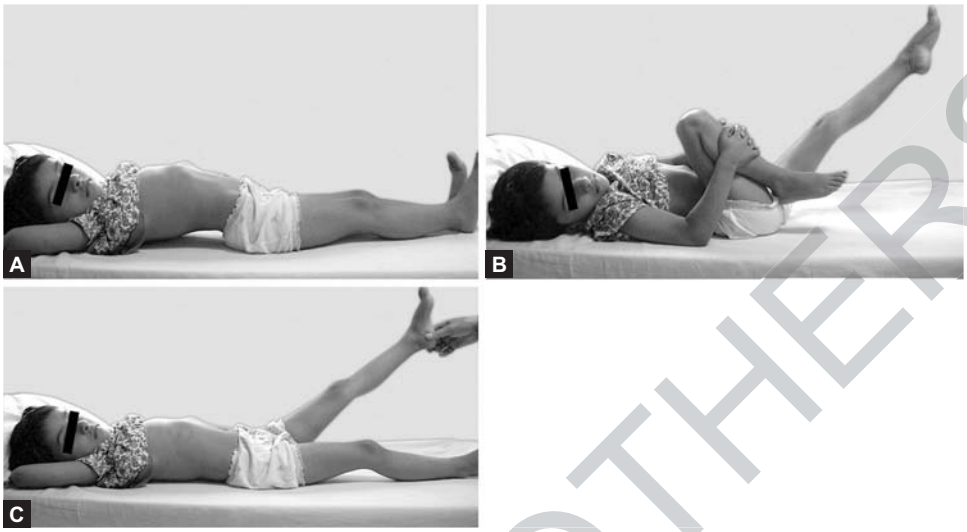

Figs. 8.18A to C: Fixed flexion deformity is the commonest deformity in an established hip infection. Flexion deformity (Left Hip) gets hidden by (A) exaggerated lumbar lordosis. Obliterate the lordosis: flexion deformity becomes manifest; (B) by performing Thomas test or (C) by holding the hip in the deformed position.

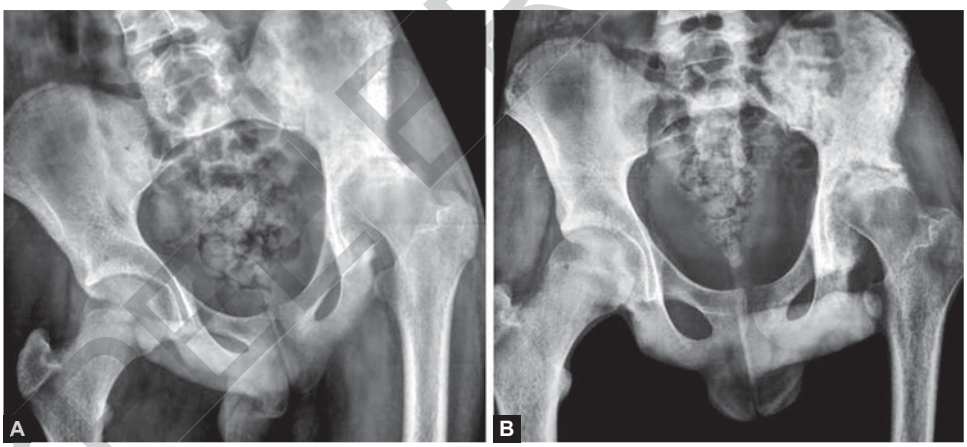

Figs. 8.19A and B: (A) X-ray of an advanced arthritis of left hip joint. Note **wandering acetabulum** and adduction deformity. (B) After 3 months of traction and the ATT-drugs, note improvement in texture of bone and deformity, and re-appearance of the joint space. Effective traction relieves spasm, pain, corrects deformities, displacements, improves joint space, permits ROM exercises.

With the employment of effective anti-tubercular drugs destruction of more than half of the articular surface is not always incompatible with a useful range of joint motion (Hodgson and Fang 1981), therefore, decision to perform excision or arthrodesis should not be made in a hurry **(Table 8.2)**. If the response to nonoperative treatment is unfavorable, one should perform synovectomy or debridement of the diseased joint as needed. Occasionally, on opening the hip joint the disease may be more advanced than anticipated. When the disease is well under control, protected ambulation is started 3–6 months after the operation.

JAYPEE BROTHERS

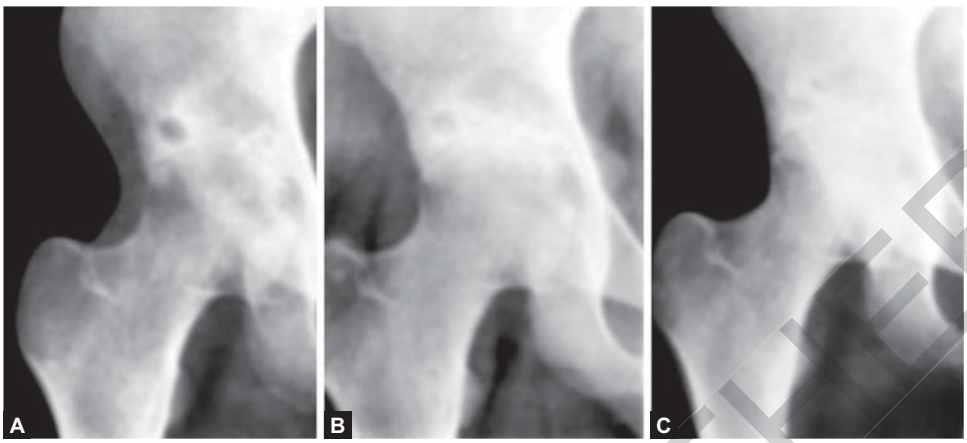

Figs. 8.20A to C: Follow-up X-rays of a young engineer who was treated by antitubercular drugs, traction and active assisted exercises, (A) for early tuberculous arthritis of right hip joint. Observe a supra-acetabular cavity at presentation (A) and its healing process (B). The patient maintained the healed status, with 70% function of the joint. The X-ray 8 years after completion of treatment (C), shows slight diminution of the articular cartilage space and almost normal texture of bones.

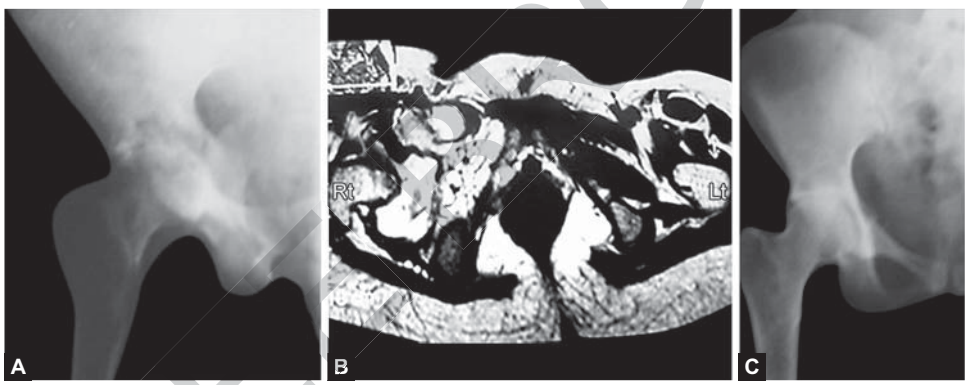

Figs. 8.21A to C: X-ray (A) and MRI (B) of right hip joint at presentation. X-ray shows eroded acetabulum, gross diminution of joint space (stage III). MRI shows collection of fluid within the joint, it also shows a suppurating lymph node anteriorly. She was treated at home by traction (for a few weeks), multidrug therapy and range of motion exercises; (C) shows the healed status by restoration of the bone architecture and the joint space one year after the start of treatment.

In *advanced arthritis,* the usual outcome is gross fibrous ankylosis. The traction regime and functional exercises in the initial stages help to overcome the deformities and permit assessment regarding the retention or return of any useful range of motion. Once gross ankylosis is anticipated and accepted, the limb should be immobilized with the help of a plaster hip spica for about 4–6 months. The **ideal position for ankylosis of hip joint** in adults is neutral between abduction and adduction, 5–10 degrees of external rotation, and flexion depending upon age (between 10 degrees in children and 30 degrees in adults). About 6 months after onset of the treatment or the application of hip spica, whichsoever is earlier, partial weight bearing should be started first in a single hip spica (for about 6 months), and later on with the help of an orthosis and crutches for nearly 2 years.

In an analysis of results of traction regime for tubercular arthritis, Sandhu (1983) reported healing of disease in 98% of cases. Of the 41 patients,

JAYPEE BROTHERS

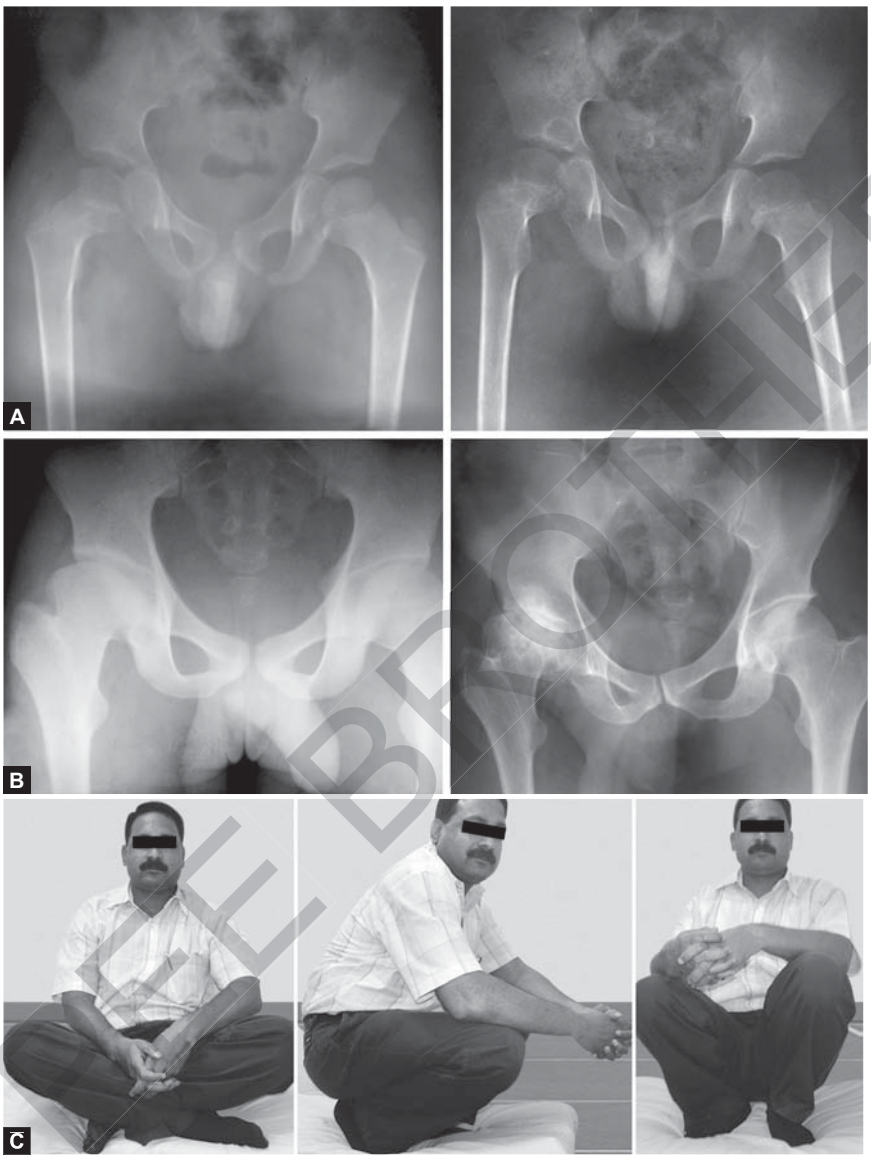

Figs. 8.22A to C: (A) Four years male presented in 1966 as TB right hip joint. Treatment was multidrug therapy, ROM exercises and traction at home. Patient followed up to 2006. (B) During growing age there is remarkable potential for recovery of disease and retention of joint movements despite coxa magna. (C) At 44 years age note the remarkable function of right hip joint. In due course he may be justifiably suitable for right hip replacement.

40 had healed with retention of appreciable range of movements; the average range was flexion 69 degrees, abduction 22 degrees, adduction 19 degrees, external rotation 22 degrees and internal rotation 24 degrees. One patient who had secondary infection ended up in bony ankylosis. In 5 patients, corrective osteotomy was indicated for unacceptable deformity.

JAYPEE BROTHERS

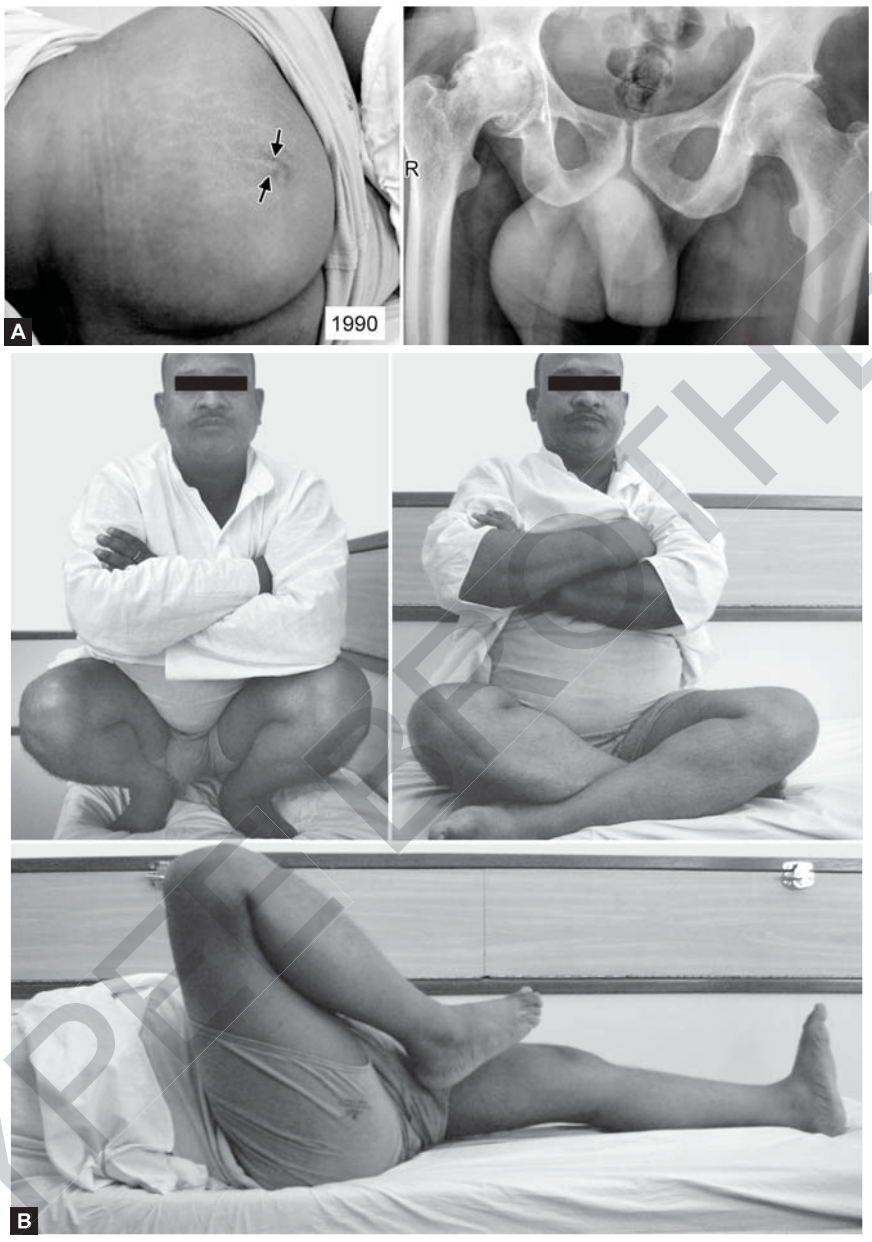

Figs. 8.23A and B: (A) A 20 years male developed right hip TB (stage II ±), treated by drugs, drainage of gluteal abscess right hip TB (Scar) and ROM exercises. At 22 years follow-up (now aged 42 years) he has very good function. X-rays show secondary osteoarthrosis. (B) At age 42 years clinical function despite osteoarthrosis in X-rays.

JAYPEE BROTHERS

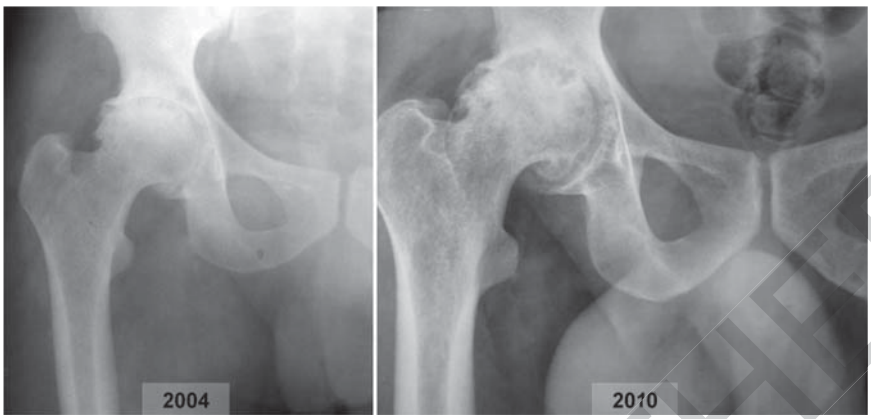

Fig. 8.23C: At 42 years gradually deteriorating osteoarthrosis in X-rays.

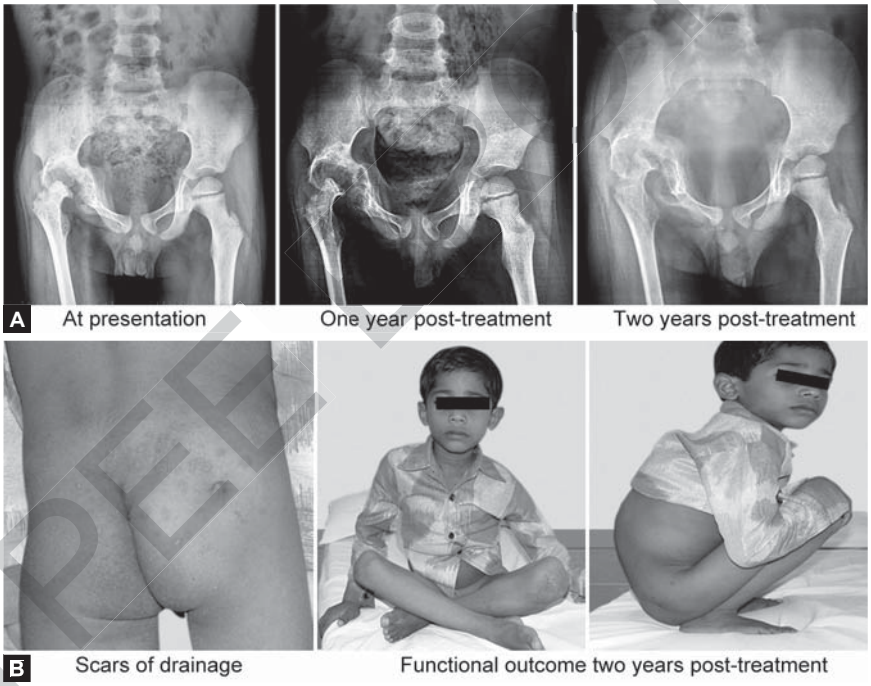

Figs. 8.24A and B: In children, expectant treatment is justified with multidrug therapy, and active/assisted ROM exercises. Despite gross destruction of femoral head and its growth plate, and gross destruction of acetabulum producing **"wandering" acetabulum** and **"protrusio" acetabulum** the infection healed with nearly complete range of motion.

Management in Children

In children with arthritis, the deformity and subluxation/dislocation is corrected or minimized by employing traction. Rarely, one may require correction of the deformity by applying plaster under general anesthesia with or without adductor tenotomy. Failure to achieve correction of gross deformities and minimization of subluxation/dislocation in children warrants open arthrotomy, synovectomy and debridement

JAYPEE BROTHERS

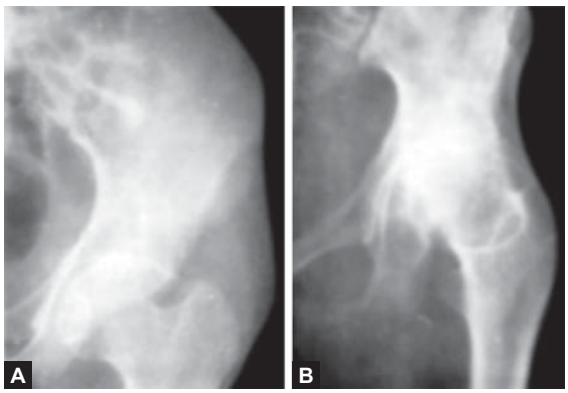

Figs. 8.25A and B: Tuberculosis of the left hip joint with destruction of the weight bearing part of the iliac bone (A). The patient did not receive specific treatment and in the next 3 years developed wandering acetabulum with gross ankylosis of the hip joint (B). Tuberculous pathology was proved from the tissues at the time of excisional arthroplasty—specimen in **Figure 8.27**.

of the diseased joint and improvement of displacement. Arthrodesis of the grossly destroyed hip joint or excisional arthroplasty in children is contraindicated till the completion of growth potential of the proximal femur. Children presenting with disease healed with gross deformity (flexion more than 30 degrees, adduction more than 10 degrees or abduction more than 10 degrees), require an extra-articular corrective osteotomy to enable them to walk better till they reach skeletal maturity. In some children, the disease may heal with gross fibrous ankylosis. If there is no gross distortion of anatomy of the hip joint subtotal excision of the contracted fibrous capsule (*arthrolysis*) followed by traction and repetitive exercises may restore a useful range of movement for a few years (Agarwal et al. 2014, Saraf 2015).

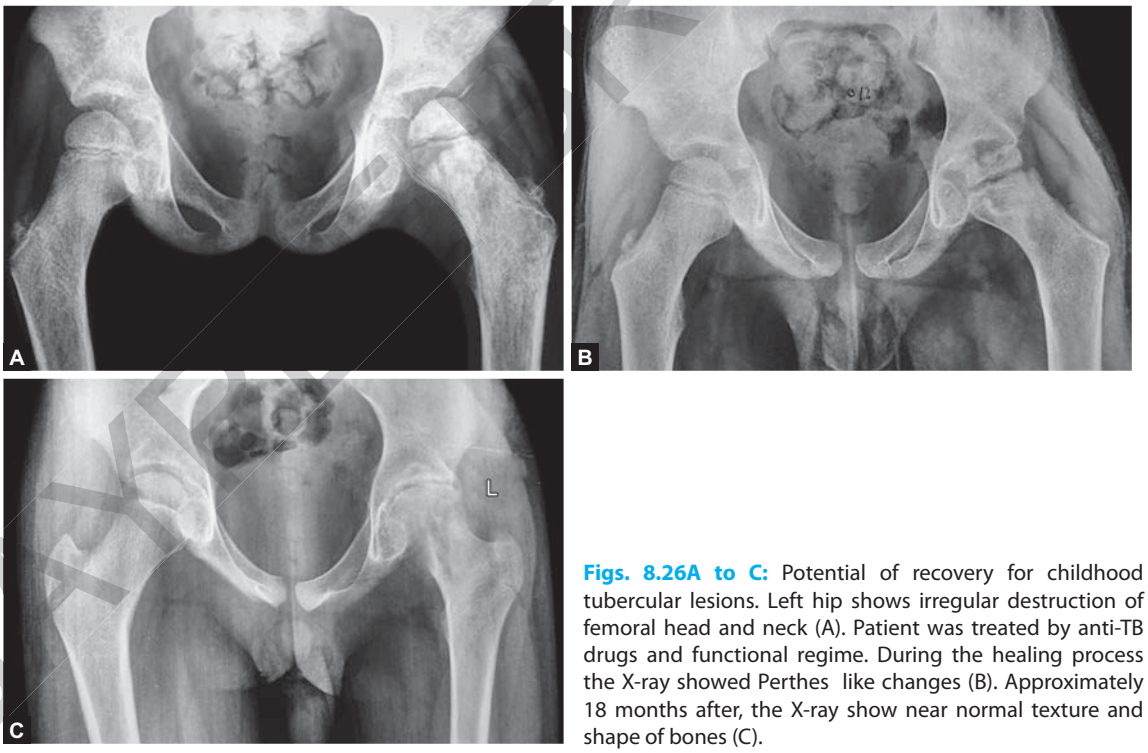

Figs. 8.26A to C: Potential of recovery for childhood tubercular lesions. Left hip shows irregular destruction of femoral head and neck (A). Patient was treated by anti-TB drugs and functional regime. During the healing process the X-ray showed Perthes like changes (B). Approximately 18 months after, the X-ray show near normal texture and shape of bones (C).

JAYPEE BROTHERS











Figs. 8.26D to H: A 2012 at presentation with follow-up to 2024. Healed disease left joint is an adult patient, observe the functional outcome.

JAYPEE BROTHERS

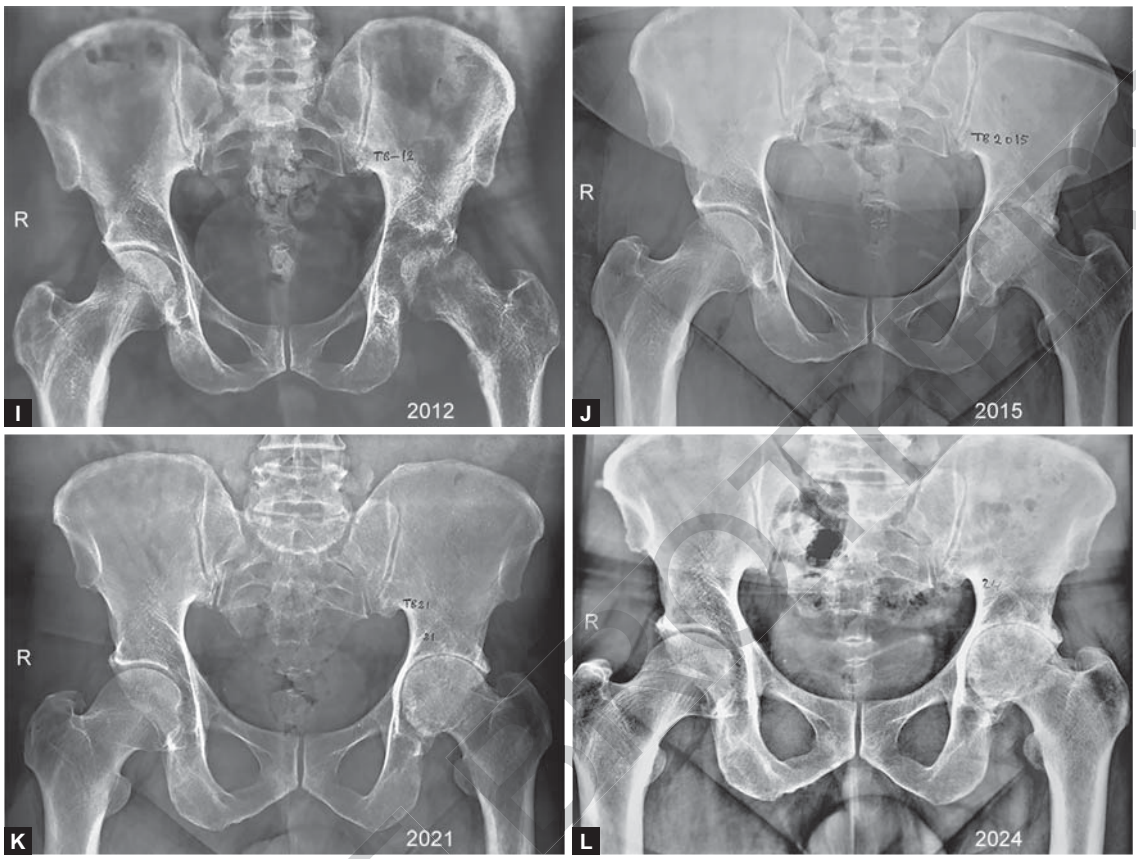

Figs. 8.26I to L: (I) Increased joint space in left hip joint, erosions in acetabular and in femoral head and osteoporosis. (J and K) One can appreciate the role of anti-TB drugs with "function" treatment in adult having tuberculosis of left hip joint and (L) early degenerative enthesophytes, observe the healed statins: reduced joint space restored bone density.

Table 8.2: Guidelines for treatment according to clinical presentations.

Guidelines for indications and operations in tuberculosis of hip	
Therapeutically refractory or doubtful diagnosis	Arthrotomy, synovectomy, debridement
Dislocation/subluxation during active stage of disease	Arthrotomy and repositioning of joint
Juxta-articular non-resolving lesion threatening the joint	Debridement of the lesion
Unacceptable gross ankylosis of hip in active stage of disease in adults	Excision arthroplasty
Partial ankylosis with healed disease with "useful range" of motion	Juxta-articular femoral osteotomy to bring the range of motion to the "functional arc" or arthrolysis
Bony ankylosis of hip in non-functioning position	Juxta-articular corrective femoral osteotomy to bring the fused joint to the best functioning position
Painful ankylosis of hip in adults	Excisional arthroplasty or replacement arthroplasty
Unacceptable ankylosis with healed disease (>3 years)	Replacement arthroplasty

JAYPEE BROTHERS

INDICATIONS FOR SURGICAL TREATMENT

If the response to conservative treatment is not favorable or the outcome is unacceptable, the following selective operative procedures are useful and have stood the test of time **(Table 8.2)**.

Osteotomy

Patients presenting with sound ankylosis in non-functional position require upper femoral corrective osteotomy. Sometimes an unsound (fibrous-painful) ankylosis in a bad position becomes an osseous fusion (sound-painless) by a high femoral corrective osteotomy. This operation is a simple extracapsular procedure and can be done at any age. The ideal site for corrective osteotomy is as near the deformed joint as possible.

Arthrodesis

Before the availability of effective antitubercular drugs, one preferred to perform an **extra-articular fusion**. Bone grafts were used to bridge the gap between the ischium and femur (ischiofemoral arthrodesis, **Fig. 8.32**) or between the ilium and femur (iliofemoral arthrodesis, **Fig. 8.33**). With availability of modern drugs, however, direct intracapsular fusion is favored between the rawed surfaces of femoral head and the acetabulum. Classically, this operation is indicated in an adult presenting with unsound (painful fibrous ankylosis) ankylosis with active or healed disease. This procedure should be deferred so long as the bones of the hip joint have any growth potential. Young adults with sound bony ankylosis in functioning position learn to adopt themselves for active life **(Figs. 8.3 and 8.4)**. One has, however, to resort to chair and commode toilet system.

Excisional Arthroplasty

In the Indian subcontinent, Japan, China, Southeast Asia and Middleeast, majority of people do not like to accept a stiff hip joint. In these countries, squatting, sitting cross-legged, and kneeling are essential socioeconomic activities. Girdlestone's excision arthroplasty can be safely carried out in healed or active disease after the completion of growth potential of bones of the hip joint. This procedure provides a mobile, painless hip joint with control of infection and correction of deformity **(Figs. 8.27 and 8.28)**. However, some degree of shortening (3.5–5 cm) and instability is unavoidable. On an average, there is an addition of 1.5 cm to the preoperative shortening. Application of postoperative traction

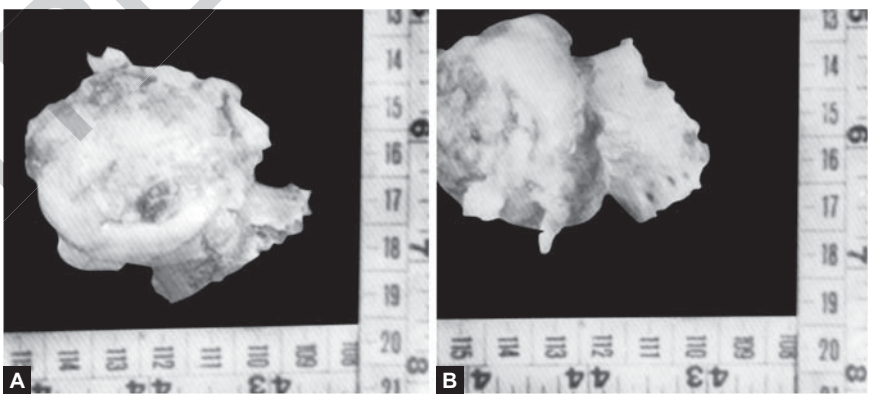

Figs. 8.27A and B: Gross appearance of the excised femoral head of the case of **Figure 8.25**. The articular cartilage is destroyed and eroded at many places, loose tags of the cartilage (A) are hanging (in the view on right), subchondral bone (B) shows cobbled appearance, the head is flattened and deformed.

JAYPEE BROTHERS

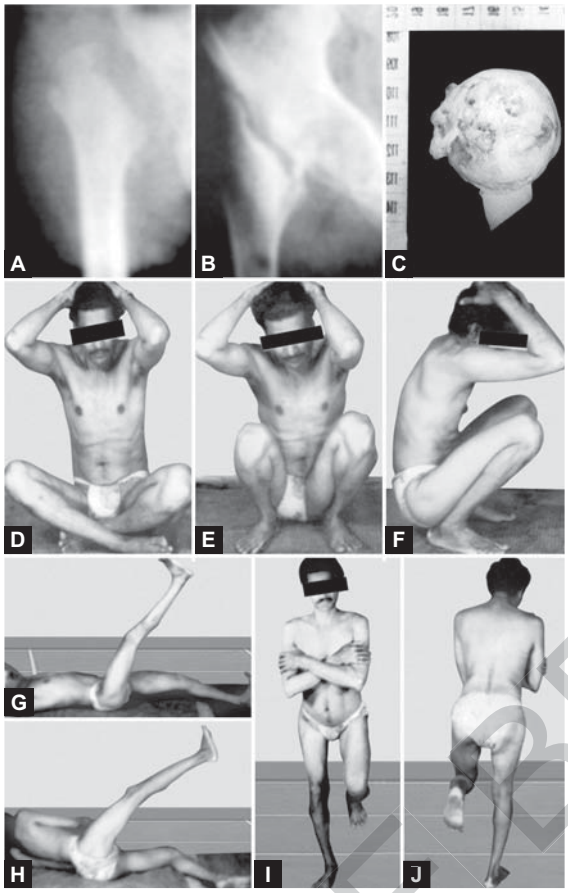

Figs. 8.28A to J: Composite picture of a patient of excision arthroplasty of right hip joint 5 years after the operation, showing the radiological appearance and functions of the joint. The excised femoral head (inset) shows the subchondral bone denuded of the articular cartilage. The remnant small patch of articular cartilage is showing the pock-marked appearance, (A) soon after surgery, (B) 5 years after surgery, (C) excised femoral head, (D to J) various activities performed by the patient at 5 years postoperative follow-up.

Courtesy: Tuli SM, Mukherjee SK. Excision arthroplasty for tuberculous and pyogenic arthritis of the hip. J Bone Joint Surg. 1981;63B:29-32.

for 3 months minimizes shortening and gross instability (Tuli and Mukherjee 1981, Saraf 2015).

We have observed 80 patients of tuberculous arthritis of hip joint treated by a mobilization procedure (by excision arthroplasty) for a period of 2–9 years. With the employment of effective antitubercular drugs the chances of recrudescence are no more in such patients than in those who obtained sound ankylosis. 90% of our patients, observed between 1965 to 1980, were able to squat and kneel **(Fig. 8.28)**, 85% were able to sit cross-legged, 60% were able to stand on the operated extremity unsupported, 90% were able to lift the limb straight against gravity, almost all were able to climb up the stairs using a walking-stick, 5% of patients required a change to newer drugs for control of their infection. With long follow-up radiologically, there was improvement in bone texture and remodeling of the bones of the false joint **(Fig. 8.28)**. 11% of patients did not feel satisfied with the result because of development of reankylosis of the joint. No patient was made worse. For a long time, it was considered that the most successful treatment for tuberculosis of the hip joint was to achieve a sound bony fusion, lest any mobility should cause reactivation (Girdlestone 1950, 1965, Mukopadhaya 1956) of the disease. There are, however, exponents (Adjrad and Martini 1987) who noted a favorable response to antitubercular chemotherapy in all their 40 patients treated by obtaining a sound ankylosis or by operative arthrodesis. We now safely recommend excision arthroplasty for active or healed tuberculous arthritis in adults without any apprehension of increased incidence of reactivation of the infection.

Stage of Disease and Operative Procedure (Table 8.2)

a. In *synovial stage,* if the disease is not responding favorably or the diagnosis is uncertain, arthrotomy and synovectomy should be carried out. In a similar clinical response in early arthritis, in addition to synovectomy removal of loose bodies/rice bodies, debris, pannus covering the articular cartilage, loose articular cartilage and careful curettage of osseous juxta-articular foci should be carried out (joint clearance or joint debridement). Postoperatively triple drug therapy, traction, intermittent active and assisted exercises should be continued for 4–6 weeks. Ambulation with suitable braces

JAYPEE BROTHERS

and orthosis should be started (according to the time-table as mentioned above) 3–4 months after the operation depending on the control of disease.

b. With *advanced arthritis* with or without dislocation/subluxation it is unlikely that the joint would attain a healed status with retention of good range of movements. However, with the modern effective antitubercular chemotherapy and employment of traction regime, it is surprising how some cases maintain good functional range of movements **(Figs. 8.5, 8.11, 8.15, 8.18 and 8.21 to 8.24)**, and therefore, ankylosis should not necessarily be the aim. If there is some "joint space" visible, *arthrolysis* and release of contracted capsule can minimize the deformity and improve the range of motion. Some of these patients may report back, with pain due to secondary osteoarthrosis after having enjoyed many years of useful mobility of the hip **(Figs. 8.15 and 8.20 to 8.24)**.

c. When *ankylosis is the aim* or the expected result in a patient with growth potential, the hip should be immobilized, during early stage of treatment in 10–15 degrees of abduction because with fibrosis during convalescence and healing there is a tendency toward adduction. A few degrees of flexion deformity of the hip joint must be added; one degree for each year of life up to a maximum of 30 degrees. The younger spine is more mobile and adaptable to compensate for loss of movements at the hip joint.

d. In *healed status of disease,* operations may be indicated in certain patients. Depending on the socio-economic status of the patient and facilities available following alternatives are available: (i) upper femoral corrective osteotomy to correct severe flexion-adduction deformity; (ii) upper femoral displacement-cum-corrective osteotomy in a case of fibrous ankylosis with gross deformity to correct the deformity and hopefully to convert fibrous ankylosis to bony fusion; (iii) conversion of a painful ankylosis to a sound arthrodesis by intra-articular or extra-articular or panarticular arthrodesis of the hip joint; and (iv) conversion of an ankylosed hip to a mobile state by Girdlestone's type excisional arthroplasty **(Fig. 8.28)** or by total joint replacement in selected cases.

e. *Joint replacement, in active disease* is being considered these days (Sidhu et al. 2009, Wang et al. 2010, Neogi et al. 2010, Kim et al. 2013). The author, however, does not feel justified in recommending replacement arthroplasty in the presence of active infection. One may try total joint arthroplasty 2–3 years or more after complete healing of infection (Eskola 1998, Caparros et al. 1999, Saraf et al. 2015). It is mandatory to administer modern antitubercular drugs for 3–5 months after any replacement procedure. Between 2000 to 2013 we had to remove the implants and accept pseudarthrosis like arthroplasty in 4 patients because of persisting active infection and sinuses after joint replacement despite years of postoperative antitubercular drugs.

SURGICAL APPROACHES TO THE HIP JOINT

The Anterior Iliofemoral Approach or Anterolateral Approach (Fig. 8.29)

As described by Smith-Petersen and modified by various workers should be considered almost as a universal surgical approach for any operative procedure for tuberculous disease of the hip joint. This incision can be extended proximally and/or distally depending upon the extent of surgical procedure and the deformities present in the joint.

With the patient supine and toward the edge of the table, give 20 degrees tilt to the opposite side by placing sandbags behind the sacrum. The extremity to be operated is always draped free to permit intra-operative manipulations and rotations. Make the incision along the outer lip

JAYPEE BROTHERS

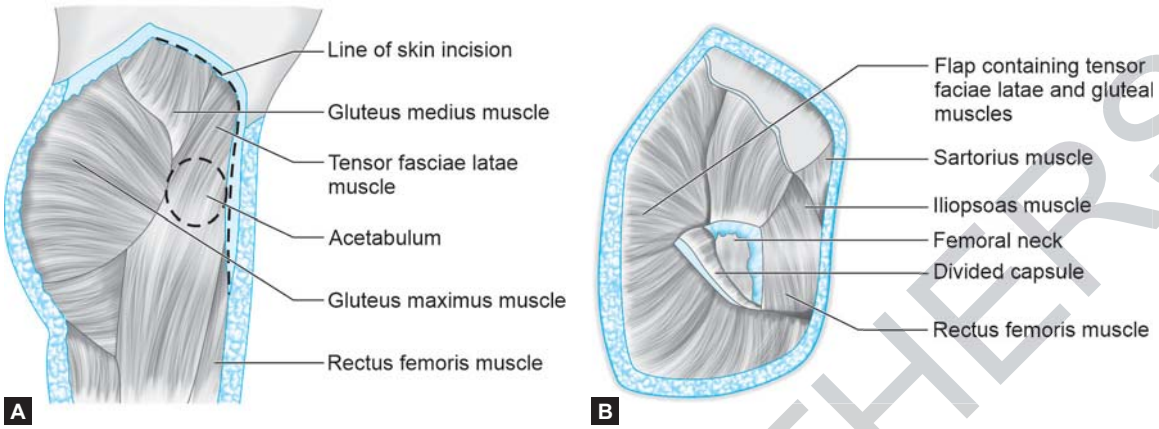

Figs. 8.29A and B: Diagrammatic representation of conventional anterolateral exposure to the right hip joint. This is like a universal approach for any surgical procedure like synovectomy, debridement, relocation of a displaced head, intra-articular arthrodesis of the hip joint, or for excisional arthroplasty.

of the anterior one-third of the iliac crest coming up to the anterosuperior iliac spine, then carry it distally for 8–10 cm in the direction of the lateral border of patella. The vertical limb of the incision is aimed to stay medial to the medial border of the tensor fasciae latae muscle. Now incise cleanly the deep fascia and the muscles (tensor fasciae latae and gluteus medius) along with the periosteum from the outer surface of the iliac bone leaving behind about 1.5–2 cm of muscles attached to the outer lip of the iliac crest. Using a broad chissel and large sponges, reflect these muscles and gluteus minimus as a continuous structure distally and laterally subperiosteally up to the superior, anterior and posterior margins of acetabulum.

Pack tightly the space between the outer surface of the iliac bone and the periosteo-muscular flap. Now carry the fascial incision in the deep fascia distally between the tensor fasciae latae and iliotibial band laterally, and sartorius, rectus femoris and vastus lateralis medially. Develop this plane working disto-proximally as there is more space and areolar tissue in the distal part. In the proximal part of the plane, about 5 cm distal to the hip joint, one may find a leash of blood vessels (from lateral femoral circumflex artery) entering into the medial surface of tensor fasciae latae muscle. These require to be identified, double ligated, cauterized and cut. The lateral femoral cutaneous nerve usually passes over the sartorius muscle and can be saved by retracting the nerve and muscle medially. The packing between the iliac bone and the reflected muscles would have controlled the bleeding by this time. If removal of the packs still shows bleeding it should be controlled by cauterization and ligation. In cases of severe flexion deformity of long-standing, the structures at the anterosuperior iliac spine are markedly contracted, 1–2 cm of the "spine" may be osteotomized free and allowed to retract with its attachments (sartorius, inguinal ligament) distally. Retraction of the lateral periosteo-muscular flap (consisting of tensor fasciae latae, gluteus medius and gluteus minimus) laterally, and sartorius and rectus femoris medially exposes the capsule of the hip joint. For better exposure one can pack and use long bone levers (extracapsularly) along the superior and inferior borders of the femoral neck. Incise the capsule (in an L-shaped manner) starting from the infero-medial aspect of the capsular attachment to the acetabular rim, extend it proximally just lateral and parallel to the acetabular labrum to the superoposterior aspect of the capsule, then curve it laterally parallel to the femoral neck coming up to the greater trochanter. A triangular flap of the capsule can now be lifted with a laterally placed

JAYPEE BROTHERS

base. This incision of the capsule divides the reflected head of the rectus femoris that blends with the capsule at the superior margin of the capsule. Now reposition the long bone levers intracapsularly. The ligamentum teres may be divided with a knife or with a curved scissors, the cut on the capsule may be extended in all the directions (if necessary) and the femoral head dislocated by external rotation of the femur. It is, however, not necessary to dislocate the femoral head in every case, and this maneuver may even be impossible and dangerous in a case with gross ankylosis of the hip joint which may in addition have osteoporotic bones.

Nearly all surgery of the hip joint for various stages of infection can be carried out through this approach. In the presence of gross deformity of long-standing and scarring of soft tissues, there is obliteration of anatomical planes and the surgeon has to be extra-careful for dissection in the deeper regions. The capsule may also be cut transversely or in a cruciate manner. In any surgical technique whenever preservation of the femoral head and neck is contemplated, one should avoid cutting of the capsule along the base of femoral neck to minimize the risk of loss of blood supply to the femoral head.

Transverse Anterior Approach to the Hip Joint

Luck (1955) described a transverse anterior approach to the hip joint. The tensor fasciae latae is divided transversely in its distal one-third and the cut is extended anteriorly into the fascia lata. Pandey (personal communication) suggested modification of this without cutting transversely the tensor fasciae latae **(Fig. 8.30)**. It preserves the integrity of all the muscles. This approach is not advised for extensive reconstructive procedures nor for restoration of anatomy in gross subluxation or dislocation of the hip joint. We have employed this technique since 1986 for selected cases for performing arthrotomy, synovectomy, joint clearance, and for excisional arthroplasty. We would recommend this approach only for limited procedures in cases where the anatomical position of bones is not grossly disturbed, and the joint does not have severe flexion-adduction deformity.

Begin the skin incision over the femoral head just lateral to the palpable femoral pulsations, carry it laterally, parallel to the flexor crease of the groin, up to a point lateral to the most prominent part of the greater trochanter. Dissect the skin and subcutaneous fatty tissue from the underlying fascia lata for 2–4 cm proximal and distal to the line of skin incision, now split the fascia lata vertically using finger or a blunt dissector. The split in the deep fascia is 8–10 cm long, centering on the hip joint. Retract laterally the lateral lip of fascia lata along with tensor fasciae latae. The medial lip is retracted medially along with the sartorius, the rectus femoris and the iliopsoas. The latter may require to be released from its attachments to the underlying capsule of the hip joint. Use of long bone levers along the upper and lower borders of the femoral neck (still covered with the capsule) to retract the muscles in respective directions, offers an adequate view of the entire anterior surface of the capsule of the hip joint. The capsule is cut in the usual manner, bone levers or skids are then inserted between the femoral neck and the capsule. One can now perform synovectomy, joint debridement or excision arthroplasty.

In case of difficulty of exposure, the lateral end of skin incision may be extended proximally or distally, the tensor fasciae latae and fascia lata cut transversely in the distal third of tensor fasciae latae, and the rectus femoris detached from its origin. However, all this is rarely necessary if we have not selected patients with gross displacements and gross deformities of flexion-adduction and internal rotation for this approach. In a usual case, the wound is closed only by stitching the skin. As no muscles are reflected or cut, postoperative mobilization of the hip joint is remarkably painless and easy.

JAYPEE BROTHERS

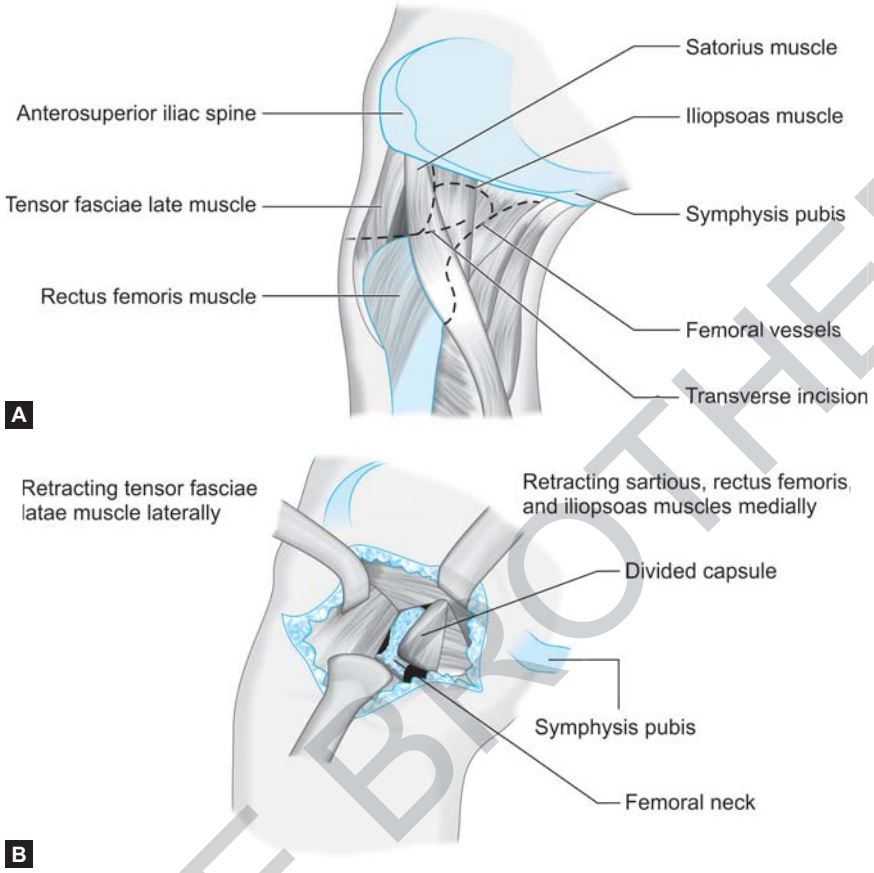

Figs. 8.30A and B: Diagrammatic representation of modified anterior approach to the hip joint. No muscles are cut. The incision in the capsule can be made longitudinally, or in L or T-shaped fashion. The approach is adequate for moderate surgical procedures (arthrotomy, biopsy, synovectomy, debridement, excision arthroplasty) only where the anatomy is not grossly disturbed.

ALTERNATIVE APPROACHES

There are many other approaches to expose the hip joint (Campbell's Operative Orthopedics 1987) which may be rarely necessary in infective lesions. Sometimes, due to infection the femoral head (especially in children) may be sequestrated and lie posterior to the hip joint. Such a sequestrated head can be best removed by making a direct incision centering over the hip joint or over the palpable rounded femoral head. With the patient placed on the sound side with 30–45 degrees flexion of the diseased hip, the skin incision is made in the gluteal region parallel to the direction of fibers of gluteus maximus. Generally, the incision falls on a line from a point 4 cm distal and lateral to the posterosuperior iliac spine to the posterosuperior angle of the greater trochanter. Separate the fibers of gluteus maximus parallel to its own fibers. Relatively little bleeding occurs because the split is through the water-shed of superior gluteal artery (supplying the proximal half of gluteus maximus) and inferior gluteal artery (supplying the distal half). If needed for more extensive procedure, the skin and the insertion of gluteus maximus can be divided further in a longitudinal direction **(Fig. 8.31)** like the vertical limb of the Gibson's or Osborne's

JAYPEE BROTHERS

for detailed information on orthopedic books, visit our website www.ejaypee.com, for detailed information on orthopedic books, visit our website www.ejaypee

Tuberculosis of the Skeletal System

The philosophy of management of skeletal tuberculosis has been greatly influenced by the availability of effective antitubercular drugs, facility of modem imaging modalities for diagnosis at predestructive stages of disease, and changes in the socioeconomic status of the people. Techniques have evolved to retain and restore the mobility of articular disease. The looming challenge of "super-bugs" has been addressed with possible modalities to combat it by immune potentiating techniques. The 7th edition is a compilation of the personal clinical experience of the author and relevant information from the international literature. Many new pictures have been added mostly as "composites" to express the "Story" as it evolves in clinical management. This book is a source of knowledge of biological processes of activity and healing of disease, and for rational options for effective and safe management of tuberculosis of the skeletal system.

SM Tuli graduated in 1955 and postgraduated in 1958 from Government Medical College, Amritsar, Punjab, India. He obtained PhD (1966, under Professor PK Duraiswami) from University of Delhi. He was awarded the Fellowship of Academy of Medical Sciences (India) and International Fellowship of National Institute of Health, US, 1972. American Biographical Institute included his name in "Great Minds of 21st Century". He founded the Department of Orthopedics at Banaras Hindu University (BHU) and at University College of Medical Sciences (UCMS), New Delhi. Based upon the laboratory work of Marshall Urist (US), Dr Tuli established clinically applicable Bone Banks at BHU, IJCMS and at Vidyasagar Institute of Mental Health and Neurosciences (VIMHANS). Presently, he is working at Moolchand Hospital, New Delhi.

His major contributions have been the evolution of "middle-path-regimen" for the treatment of osteoarticular and spinal tuberculosis, use of "allogenic bone grafts" for reconstruction of bone defects, development of an extra-articular operation—glenoplasty (for shoulder dislocation) and immune-potentiation technique for multidrug-resistant tuberculosis (MDR-TB). He worked as an Editor of the Indian Journal of Orthopedics with Varanasi team 1972 to 1987, and he also served as the President of Indian Orthopedic Association in 1984.

He has nearly 200 scientific publications, and contribution of chapters to Essential Surgery (WHO). Children's Orthopedics (Churchill Livingstone), APLEY's Orthopedics (Hodder-Arnold) and Neglected Musculoskeletal Injuries [Jaypee Brothers Medical Publishers (P) Ltd]. He is the author of the books *Practical Orthopedics (2nd edition)*, and *Guidelines for Ageing with Health, Grace and Dignity*.

He has been a surgeon to the common man, VIPs, medical doctors, and most prestigiously, to many orthopedic surgeons. After six decades of professional journey, he has not lost his passion for caring of orthopedic patients and for furthering orthopedic education.

Shelving Recommendation
ORTHOPEDICS

ISBN 978-93-7202-872-0

9 789372 028720

Buy from ejaypee

JAYPEE BROTHERS