opedics books, visit our website www.ejaypee.com,for detailed information on orthopedics books, visit our website www.ejaypee.com, for detailed information on orthopedics books

5

Master Series Monographs

Failed Fracture Fixation

Volume 1: Upper Limb

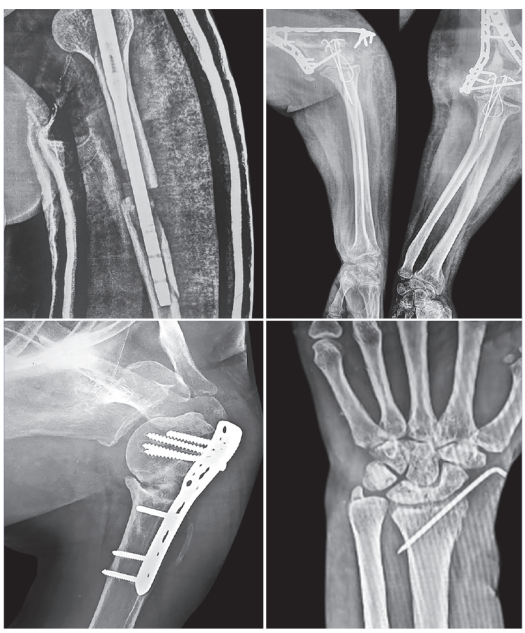

Editor-in-Chief
Gautam Zaveri

Section Editors
Dipit Sahu
Prashant Kamble
Parag Lad

JAYPEE

Contents

Note from the Editor-in-Chief xiii

Note from the Section Editors xv

Contributors xvii

1. **Failed Fracture Fixation** 1
   Gautam Zaveri

2. **Mechanobiology of Fracture Healing** 5
   Anoop Dhamangaonkar, Gautam Zaveri

3. **Nonunion of Fractures** 15
   Ashish Phadnis, Niharika Virkar

4. **Failed Fixation of Proximal Humerus Fractures** 29
   Gautam Zaveri, Dipit Sahu

   Case 1: Isolated Greater Tuberosity Fracture *32*
   Parag Munshi, Gautam Zaveri

   Case 2: Innovative Management after Failed Fixation of Proximal Humerus Fracture *39*
   J Maheshwari, Dipit Sahu, Aditya Chaubey

   Case 3: Two-part Varus Posteromedial Fracture of Neck of Humerus *44*
   Dipit Sahu, Aditya Chaubey

   Case 4: A Four-part Valgus Impacted Head Split Proximal Humerus Fracture *47*
   Dipit Sahu, Aditya Chaubey

   Case 5: Failure of Locked Plating of a Four-part Proximal Humerus Fracture in the Older Individual *52*
   Dipit Sahu, Aditya Chaubey

   Case 6: Failure of Locked Plate Fixation in a Head-split Fracture-managed by "Sheek-Kebab" Reverse Shoulder Arthroplasty *55*
   Dipit Sahu

5. **Failed Fixation of Fractures of Humeral Diaphysis** 59
   Gautam Zaveri, Prashant Kamble

   Case 1: Fracture Shaft Humerus in an Epileptic Treated with Locked Intramedullary Nail *61*
   Parag Shah, Aditya Chaubey, Aashay Sonkusale, Dipit Sahu

Case 2: Third Time's a Charm: A Journey Through Two Failed Fixations of a Humeral Shaft Fracture *65*
Prashant Kamble, DD Tanna

Case 3: Bridge to Nowhere: A Case of Failed Anterior Plating in Midshaft Humerus Fracture *70*
Prashant Kamble, Karan Chaudhary

Case 4: Implant Failure Following Inadequate Fixation in Humeral Shaft Fracture: A Case of Neglected Principles Leading to Deformity *75*
Sachin Yashwant Kale

Case 5: Failed Fixation—Fracture Shaft Humerus *80*
Prashant Kamble, Karan Chaudhary

Case 6: Atrophic Nonunion of Proximal Third Humerus Fracture *85*
Abhijit Kale

6. Distal Humerus Fractures **93**
Gautam Zaveri, Prashant Kamble

Case 1: Supracondylar Fracture of Humerus in Young Adult Treated with Closed Pinning *97*
Jignesh Pandya

Case 2: Supracondylar Humerus Fracture Treated with Dual Plating *102*
Sachin Yashwant Kale, Sandeep Deore

Case 3: Failed Fixation Distal Humerus Fracture *106*
Prashant Kamble, Karan Chaudhary

Case 4: Comminuted Supracondylar Fracture of Humerus with Intercondylar Extension *111*
Jignesh Pandya

Case 5: Nonunion Supracondylar Humerus Fracture in an Open Floating Elbow *115*
Hemant Patankar

Case 6: Failed Elbow Fracture Fixation *122*
Satish Mutha, Rohit Somani, Gautam Zaveri

7. Failure of Fixation of the Radius and Ulna Diaphysis **129**
Gautam Zaveri, Parag Lad

Case 1: 15-year-old Ulna Nonunion Following Intramedullary Nailing of Both Bones of the Forearm *131*
Prashant Kamble, Karan Chaudhary

Case 2: Early Deep Surgical Site Infection Following Plating of Both Bones Forearm *136*
Parag Lad

Case 3: Grade 2 Open Monteggia Fracture—Dislocation Treated with Intramedullary Nailing *139*
Kashyap Ardhesana

Case 4: Fracture Both Bones Forearm in an 80-year-old Treated with Plating *144*
Vikas M Agashe

Case 5: Multiple Failed Fixations of Both Bones Forearm *148*
Hemant Patankar

8. Failed Fixation of Distal Radius Fractures **153**
Gautam Zaveri, Parag Lad

Case 1: From Malposition to Motion: Salvaging a Distal Radius Fixation Error! *156*
Parag Lad

Case 2: Failed Plating for a Volar Barton Fracture *161*
Hemant Patankar, Gautam Zaveri

Case 3: Comminuted Distal Radius Fracture *164*
Hemant Patankar

9. Failed Fixation of Metacarpal and Phalangeal Fractures **169**
Parag Lad, Gautam Zaveri

Case 1: Fracture 5th Metacarpal Neck Fixed with Cross K-wire Fixation *171*
Hemant Patankar, Parag Lad

Case 2: Proximal Phalanx Fracture Fixed to Nonunion *175*
Hemant Patankar, Parag Lad

Case 3: Failed Fixation Proximal Phalanx of Thumb *179*
Hemant Patankar, Parag Lad

Case 4: Malunion Base of Proximal Phalanx with Flexor Tendon Adhesions *182*
Hemant Patankar, Parag Lad

Index **189**

3 Nonunion of Fractures

Ashish Phadnis, Niharika Virkar

Introduction

"Has the fracture healed yet?"

Nonunion of fractures is a significant and commonly encountered orthopedic problem characterized by high morbidity and clinical burden. Although nonunion occurs in approximately 2% of all fractures, the incidence can reach up to 20% for certain diaphyseal fractures.

Nonunions of fractures may result in pain, deformity, and severe functional limitations, together with a reduced quality of life, psychological, social, and financial repercussions. Nonunion not only affects patients but also has significant implications for treating surgeons. These implications include perceived failures in treatment which can lead to potential legal challenges and socioeconomic pressure.[1]

Definition

"What is a nonunion?"

The FDA designates a fracture to be in nonunion when the fracture line persists for a minimum of 9 months, without signs of healing on serial radiographs for 3 months, and which is deemed incapable of healing if status quo is maintained or without further surgical intervention. On the other hand, fracture healing is said to be delayed when a fracture has not completely healed in the expected time frame but still has the potential to heal without further intervention.

While these definitions serve as a useful baseline, defining the expected time for healing of different bones and different types of fractures, and in addition to that, gauging the healing potential depending on the host and environmental factors can be a daunting task.[2]

Classification

- *Classification based on etiology of nonunion:*[2,3]
  - Hypertrophic nonunion **(Fig 1)**
  - Atrophic nonunion **(Fig 2)**
  - Oligotrophic nonunion **(Fig 3)**
  - Septic nonunion **(Fig 4)**
  - Pseudoarthrosis **(Fig 5)**
- *Weber and Cech classification for aseptic nonunion*: **(Fig 6)**[4-6]
  - *Hypervascular nonunion*
    - Elephant foot: This is similar to hypertrophic nonunion where there is

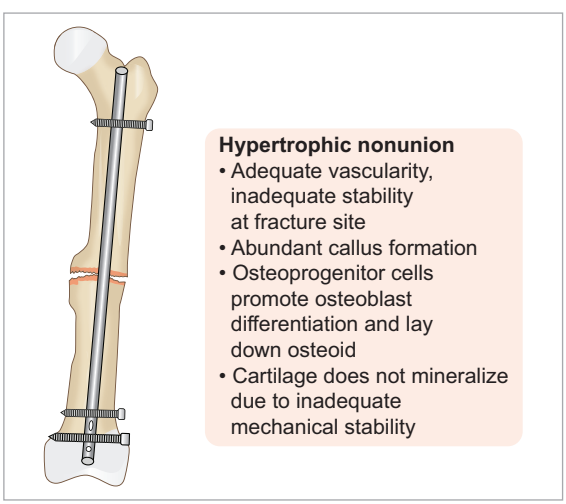

Fig 1: Hypertrophic nonunion.

JAYPEE BROTHERS

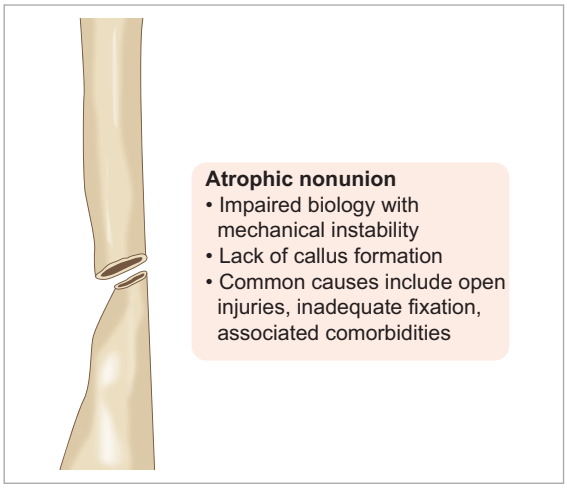

Fig 2: Atrophic nonunion.

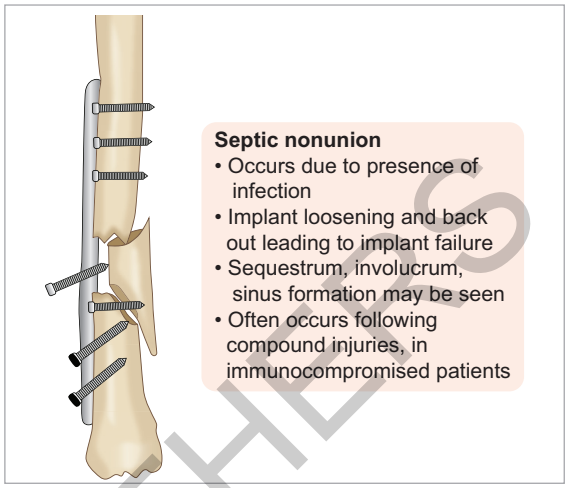

Fig 4: Septic nonunion.

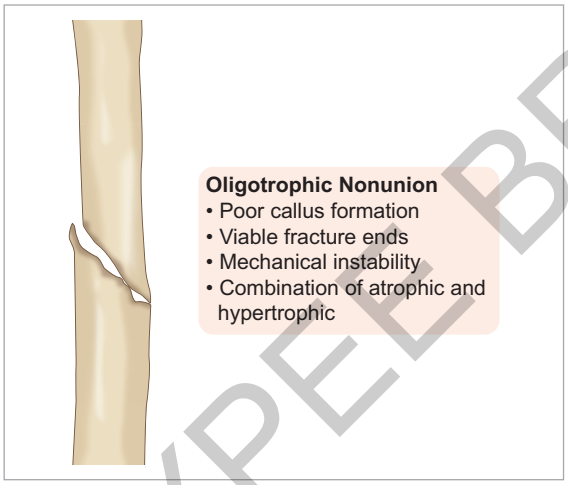

Fig 3: Oligotrophic nonunion.

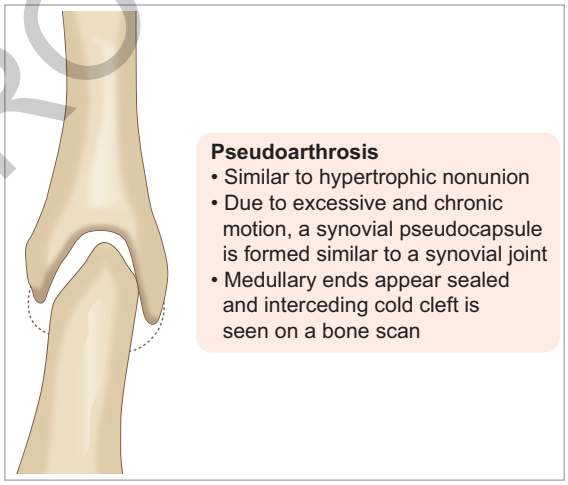

Fig 5: Pseudoarthrosis.

adequate callus formation but nonunion results from mechanical failure, i.e., inadequate fixation or premature weight bearing.

– Horse hoof: This type of nonunion is typically seen with an immobilization that allows slight movement between fracture fragments, e.g., unstable plate fixation or intramedullary nailing, cast immobilization. The bony ends may appear bulbous with lesser callus formation in comparison with that of the elephant foot nonunion.

– Oligotrophic: The vascularity is not affected. However, the fracture ends may be displaced or in distraction as a result of inadequate apposition. This type of nonunion is difficult to differen-

JAYPEE BROTHERS

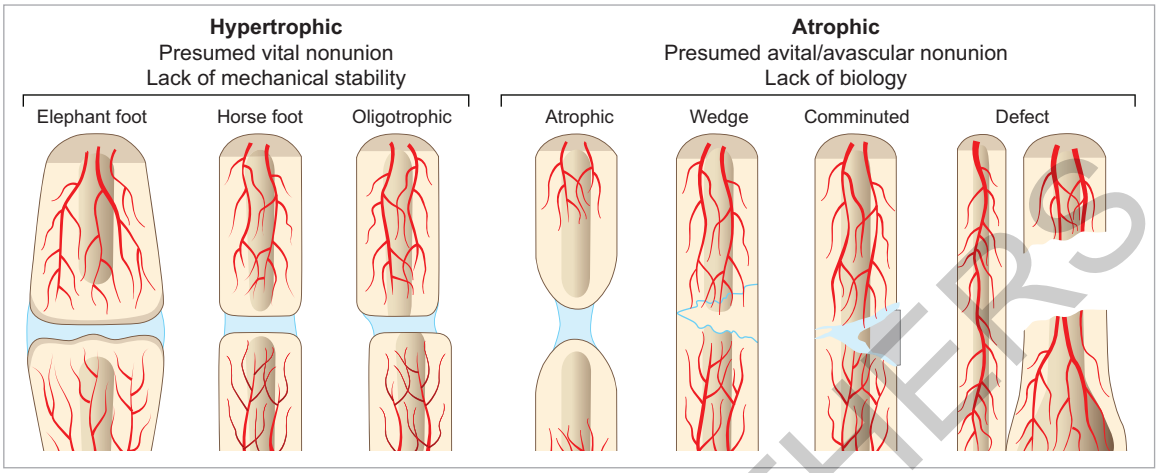

Fig 6: Weber and Čech classification of *aseptic nonunion*.

tiate from atrophic nonunion without further investigations like a scintigraphy.

- *Avascular nonunion*
  - Torsion wedge nonunion: As the name suggests, there is a wedge fragment that may be avascular that leads to partial union of the fracture. It is also known as dystrophic nonunion.
  - Comminuted nonunion: This type of nonunion is often seen in comminuted fractures which are treated with open reduction and plating as some fragments may lose their vascularity while achieving reduction.
  - Gap nonunion: Gap nonunion is seen in open, comminuted fractures. Open fractures can often lead to bone loss and septic nonunion. The intermediate fragment is lost in full circumference.
  - Atrophic nonunion: Due to loss of blood supply the fracture ends are atrophic.

Although the classifications mentioned above are the most commonly used, there are many others described in literature. These include Paley's classification for lower limb long bone nonunions, Umiarov's classification for septic nonunions and May and Jupiter classification for septic nonunions with bone loss.

Pathogenesis and Risk Factors

"What Causes a Nonunion?"

Fracture repair is a continuous process wherein many biologic and mechanical factors play a significant role. Giannoudis et al. (2007), put forth the "diamond concept of bone healing" **(Fig 7)**. The four corners of the diamond are the four key factors, namely, osteogenic cells, osteoconductive matrix, osteoinductive mediator signals and mechanical stability that must act in concert to achieve optimal bone healing. Additionally, vascularity and host factors are critical to bone healing. If vascular supply is compromised, it results in poor hematoma formation, leading to a low influx of osteoprogenitor cells and inflammatory mediators. Similarly, if the host has altered systemic physiology due to comorbidities or lifestyle choices, it directly affects the fracture healing.[7,8]

It is often difficult to pinpoint a single factor as the cause of nonunion, as usually multiple factors

JAYPEE BROTHERS

are at play. Risk factors can be broadly divided into local factors and host factors **(Table 1)**.[9,10] Local factors include the type, location, and anatomy of the fracture. The host factors take into account the physiological and pathological issues that the patient has, due to which there are increased chances of nonunion. Generally, disturbed vascularity and instability are the most important factors leading to a nonunion.

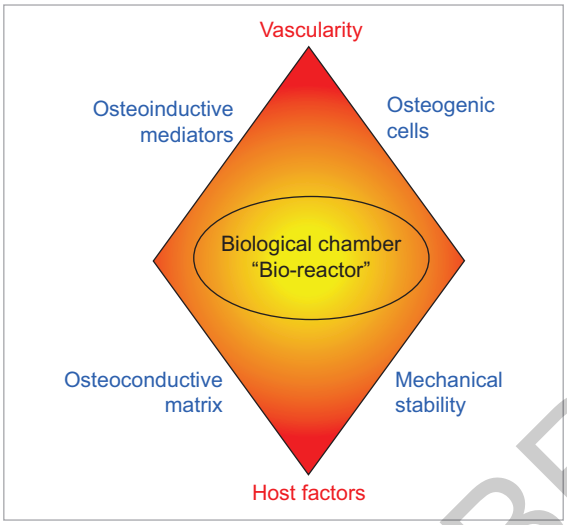

Fig 7: Giannoudis diamond concept of bone healing.

Diagnosis

"How to Assess a Nonunion?"

The aims of assessment include:

- Confirming the presence of a nonunion
- Identifying factors that have led to a nonunion
- Planning appropriate interventions—surgical/nonsurgical

Clinical Signs

- Deep, chronic pain at the fracture site, which may be present even at rest.
- Dull aching pain on activity and crepitus
- Weakness or limited mobility of affected joint/affected limb
- Instability at the fracture site with difficulty in load bearing

Table 1: Risk factors for fracture nonunion/delayed union.

Local/Mechanical factors	Host/Biological factors
Open fracture, bone loss	Osteopenia/osteoporosis
Infection	Obesity
Poor mechanical stability	Hypoproteinemia, micro, or macro nutrient deficiencies
Inadequate reduction	Malabsorption syndromes
Poor contact of fracture fragments, an acute fracture line	Diabetes mellitus, peripheral vascular disease, chronic renal failure, and malabsorption syndromes
Junctional and metaphyseal fractures, transverse diaphyseal fractures	Long-term steroid use, chemotherapy, organ recipient on immunosuppressants
Polytrauma—SIRS (systemic inflammatory response syndrome)	Alcohol, tobacco, and smoking
Mixing principles of absolute and relative stability leading to stiffness at fracture site, too much strain between fracture fragments	Rheumatoid arthritis, systemic lupus erythematosus, and ankylosing spondylitis
Vascular compromise, macro, or micro circulation	Chronic inflammation
Increased strain across fracture site	Hyperparathyroidism

JAYPEE BROTHERS

- Painless mobility at the fracture site (broken implant or no implant in situ).
- Patients may have pain at the nonunion site in case of subclinical infection.
- Deformity
- Limb length discrepancy
- Persistent tenderness and nonresolving edema at the fracture site
- Infective nonunions may even present with a wound, discharging sinuses, signs of inflammation.

Some of these signs are easily masked if a patient has rigid fixation in situ. In these patients it is important to elicit a history of sudden onset pain or deformity in the limb due to implant failure.[2]

Radiological Signs

Plain radiographs

- Persistent radiolucent line at the fracture site
- Incomplete callus, no callus formation
- Nonremodeling diffuse callus
- Reduced cortical thickness
- "Woolly" or rounded bony ends at the fracture site
- Implant loosening
- Peri-implant osteolysis

Computed tomography (CT) scan

- Cortical discontinuity, especially in complex fractures.
- Aided with 3D reconstruction and subtraction images.
- Fracture lines in oblique planes can be visualized.
- Quantitative evaluation of not just union, but fracture stability. In one study, patients with < 25% bridging of the circumference of bone were found to be at high risk (37.5%) for clinical failure of fracture union, whereas those with > 25% bridging had only a 9.7% failure rate.[2]

Magnetic resonance imaging (MRI) scan

To differentiate avascular fragments—especially in bones with precarious blood supply such as femoral neck, scaphoid, talus.

Ultrasonography

- To detect presence of synovial pseudarthrosis.
- Assess quality of the callus formation.
- Dynamic investigation can demonstrate movement between fragments in case of frank nonunions by performing a dynamic ultrasonography.
- Assess regenerate in case of bone transfer.
- Assess soft tissue around the fracture.

Fluorodeoxyglucose positron emission tomography (FDG PET) scan

- Highly sensitive and specific for differentiating infective nonunions from noninfective ones.
- Areas of increased uptake may suggest healing process whereas low uptake is suggestive of nonunion.
- Can differentiate between healing and non-healing fractures.

Computed tomography angiography

In patients with peripheral vascular disease, chronic limb edema and diabetes, assessment of vascularity of the limb and viability of soft tissue envelope may be useful. This can be done by determining capillary refill, peripheral oxygenation, color doppler examination, and if necessary, CT angiography.

Other Investigations

Apart from these interventions, patient comorbidities require evaluation to determine the risk factors for poor bone healing. Correctible factors must be optimized for fracture healing to occur.[2,11]

JAYPEE BROTHERS

All efforts must be made to rule out subclinical infection and to better characterize overt infections. Complete blood count (CBC), erythrocyte sedimentation rate (ESR), C-reactive protein (CRP), and serum procalcitonin are the common baseline investigations that are advised.[11] In addition, if the patient has a discharging sinus or an abscess, Gram-stain, Ziehl–Neelsen stain and culture-sensitivity report of the local tissue sample must be obtained. When a frank collection of pus is present and has been documented, freehand or USG-guided aspiration of the pus may be done to identify the offending organism. It is important to take a swab of the live tissue surrounding the pus-filled cavity in order to obtain an optimum sample for the investigations.[2,11]

Management

"What is the endpoint of treating a nonunion?"

- Achieving fracture union in a well aligned and functional limb
- Correction of limb length discrepancy and improving muscle strength while achieving union
- Eradication of infection if present. About one-third of all nonunions are infected. When infection is existent, nonunion surgery becomes particularly complex.[12]

Nonoperative Treatment of Nonunions

Refer to **Tables 2 and 3**.

Operative Treatment of Nonunions

Indications

- Infected nonunions
- Implant loosening or implant breakage
- A nonunion not responding to conservative modes of management
- Presence of functional deficits which can improve due to a surgical intervention.

Table 2: Indirect interventions for the nonoperative treatment of nonunions.

Indirect interventions	
Smoking cessation	Scolaro et al. reported an odds ratio for bone nonunion at 2.32 for current smokers against nonsmokers[2,13]
Optimizing nutrition	Correction of nutritional deficiencies such as vitamin D, calcium, vitamin B12, hypoproteinemia[2,13]
Correction of endocrine and metabolic disorders	• Raised HbA1c levels have a direct correlation with delayed wound healing, increased chances of superficial or deep infection, increased risk of nonunion. Other toxic effects include an osmotic diuresis of calcium associated with glycosuria, functional hypoparathyroidism and in some patients' renal osteodystrophy • Obesity (BMI > 30 kg/m^2) can affect fracture union by decreasing osteoblast differentiation, increasing proinflammatory cytokines that promote osteoclast activity and bone resorption and reducing intestinal calcium absorption, thereby decreasing calcium availability for bone formation • Comorbidities and chronic disease states have been associated with poor bone healing[11,13]
Elimination or reduction of certain medications	Numerous medications have been associated with increasing the risk of nonunion such as steroids, nonsteroidal anti-inflammatory drugs (NSAIDs), anticonvulsants, chemotherapeutic agents[11,13]

JAYPEE BROTHERS

Table 3: Direct interventions in the treatment of nonunions.

Direct interventions	
External immobilization and functional cast bracing	One of the commonest yet simple practice is to encourage weight bearing on the affected limb along with functional bracing. It works through osteoblast stimulation due to mechanical loading. Perren's strain theory suggests that excessive motion interferes with fracture healing. This is reflected in the treatment of clavicle or proximal one-third humerus shaft fractures which are difficult to immobilize[2,11]
Electromagnetic stimulation and low intensity pulsed ultrasound therapy (LIPUS)	• Direct current (DC), capacitive coupling (CC), pulsed electromagnetic field stimulation (PEMF), and combined magnetic fields (CMFs) are modalities of electromagnetic stimulation • Better union rates have been reported with PEMF and LIPUS when used in primary fractures and nonunions • Contraindications for electrical stimulation are considered to be prolonged nonunion, pseudarthrosis, prior bone graft surgery, prior electrical stimulation which failed, open fractures, active osteomyelitis, extensive comminution, and atrophic nonunion[14]
Recombinant parathyroid hormone	• It acts by stimulating vitamin D synthesis in the kidneys which leads to an increased uptake of calcium from the intestines, which is required for mineralization of the bone matrix. It has been shown that PTH can stimulate the differentiation of osteoblasts and chondroblasts by stimulating the expression of BMPs • Intermittently administered PTH can lead to a shift in balance of bone resorption and bone formation via direct activation of osteoblasts in the direction of osteogenesis • This is the rationale for the use of recombinant PTH in treatment of nonunions[15]

Timing of intervention: One of the common causes for delay in surgery for nonunion could be difficulty in diagnosis. Once the cause of the nonunion is established, appropriate intervention must be offered.

Single procedure or staged procedure: Staged procedures are often done for nonunions due to proven or suspected infection. In patients with gap nonunions or mal-nonunions treated with ring fixators, again multiple staged procedures may be required.

Internal fixation with absolute versus relative stability: If the mechanics of fracture fixation are incorrect, then the principles of stability must be revisited. Plate and screw constructs and surface implants can be used for diaphyseal as well as end segment nonunions, whereas intramedullary nails are universally recommended for diaphyseal nonunions. There is an increased interest and recommendations for dual implants and dual constructs for treatment of junctional nonunions and recalcitrant nonunions. Plate and screw fixation is often preferred in case of angular and rotational deformitities, and periarticular fractures. Care must be taken to maintain the length, alignment, rotation, and axis. Additionally, when surgeons opt for an open reduction, they should also opt for adjuvant procedures such as bone grafting, to complete the four cornerstones of the diamond concept of fracture healing.[2]

JAYPEE BROTHERS

Exchange intramedullary nailing: Nailing-related interventions for nonunions can be of three types, viz., primary nailing, exchange nailing and dynamization. Fractures which have been primarily stabilized by plating and have resulted in nonunions can also be treated with primary nailing. Exchange nailing is replacing the primary nail to obtain a better result with the help of reaming, upsizing the nail and/or adding a plate with a nail as an additional fixation.

Exchange nailing is a suitable choice for femur or tibia shaft aseptic nonunions with union rates ranging between 72 and 100% and it can be uniformly used for atrophic as well as hypertrophic nonunions. It has not produced favorable results in cases of humerus nonunions.

Bone loss or angular and rotational deformities are rarely corrected with the help of only exchange nailing. They often require an additional procedure in the form of open reduction and additional stability with plating and bone grafting in case of bone loss.[2,16]

Dynamization is the practice of removing screws at one end of the nail or from static slots in order to allow controlled motion across the fracture site, resulting in compression limited to the size of the dynamic slot in the nail, which is usually only a few millimeters.

Alternatively, all bolts from one end of the nail farther from the fracture site can be removed in order to enable compression at the fracture site on weight bearing. However, that may also risk instability, excess shortening, and malalignment at the fracture site.

It is typically used when there are clear signs of delayed healing characterized by lack of callus formation or mechanical stability.

Outcomes may vary depending on patient factors and fracture characteristics.[2]

External Fixation and Ilizarov

Indications for external fixation include need for correction of alignment, mechanical stimulation, anticipation of staged procedure, especially septic nonunions of tibia, humerus and juxta articular fractures.

Commonly used external fixation modalities include Ilizarov's ring fixator, Joshi's external stabilization system (JESS), and limb reconstruction system (LRS). Ilizarov's ring fixator, which became a popular technique to treat fracture nonunions in the 1980s is associated with excellent union rates, with some case series showing union rates close to 100%. It offers relative stability, possibility of bone transport in patients with septic nonunion and works on the principle of cyclic compression-distraction, which is the reason for it being known as "distraction osteogenesis".

The LRS is an effective alternative way of treating long bone nonunions, especially femur. The circular ring fixator (Ilizarov) is cumbersome for patients to handle and interferes with personal hygiene. The LRS uses half pins and is a monolateral external fixator. It allows compression and distraction and dynamization at the fracture site which is essential in the treatment of nonunions.[2,17,18]

Biological augments (Table 4): Inflammation is an important disruptor of physiological bone healing and the concept of osteoimmunology highlights the co-dependency between osseous cells and immune cells. Immune cells have a proinflammatory function, however, studies have shown that Interferon-gamma (IFN-γ) serves an anabolic function with respect to osseous biology. IFN-γ signaling leads to osteoblast activation via pathways causing osteoblast activation and upregulation of osteogenic factors such as osterix, osteocalcin and alkaline phosphatase. Additionally, IFN-γ inhibits osteoclastogenesis.[24]

JAYPEE BROTHERS

Table 4: Options for biological augmentation for fracture healing.	
Autologous bone grafting	• Iliac crest bone graft is the most common site to harvest cancellous autologous bone grafts while the fibular strut graft is often used in reconstruction procedures for cortical support • Cortical grafts have lower osteoinductive and osteogenic properties, while cortico-cancellous grafts are rich in mesenchymal stem cells and have high osteogenic and osteoinductive potential • The reamer irrigator aspirator (RIA) is less invasive and allows a larger volume of bone graft to be harvested from medullary canals of long bones. However, this is not commonly used in India • Donor site morbidity is a limiting factor to the use of autologous bone grafts[19]
Vascularized grafts	• Vascularized bone grafts have demonstrated increased perfusion, structural integrity, and ability to achieve good outcomes in challenging clinical situations when compared with nonvascularized grafts • Pedicled grafts from the distal radius, medial femoral condyle, ribs, and fibula have improved outcomes in challenging situations • Mulica et al. presented compelling data about scaphoid nonunion. They suggested that union rates improved from 47 to 88% for scaphoid nonunion on choosing a vascularized bone graft over a nonvascularized bone graft • They also advocate the use of indocyanine green fluorescence (ICG) angiography intraoperatively for scaphoid nonunions to demonstrate graft uptake[20,21]
Bone graft substitutes	Synthetic bone substitutes consist of hydroxyapatite, tricalcium phosphate, calcium sulphate, or a combination of these minerals. Synthetic porous substitutes share several advantages over allografts, including unlimited supply, easy sterilization, and storage. However, they also have some disadvantages, such as brittle properties, variable rates of resorption, and poor performance in some clinical conditions. The surgeon should understand the properties of each bone graft substitute to facilitate appropriate selection in each specific clinical situation[22]
Bone morphogenetic protein (BMP)	• Bone morphogenetic proteins are powerful osteoinductive agents and their use has been advocated for nonunions since 1970. BMP 2 and 7 have been shown to aid fracture healing in cases of nonunions. BMP use has shown good results in posterior lumbar and cervical spine fusion • Disadvantages of BMP include inflammation, ectopic bone formation, and a potential increased risk of cancer, especially when used at high, off-label doses. Other downsides are nerve-related complications like radiculitis and nerve root compression, as well as potential wound complications such as seroma and wound infection cost
Demineralized bone graft	• Urist identified osteoinductive properties of the demineralized bone matrix and discovered this property was due to the presence of bone morphogenetic proteins[23] • DBM stimulates new bone growth (osteoinductivity) and act as a scaffold (osteoconductivity). Its limitations include variable efficacy between products due to differences in preparation and composition, higher cost compared to some alternatives, and insufficient evidence for use in certain trauma applications

Continued

JAYPEE BROTHERS

Continued

Bone marrow aspirate concentrate (BMAC)	• This involves injecting the aspirate which contains growth factors, mesenchymal stem cells, regenerative components, at the nonunion site to promote healing. Bone marrow aspirate concentrate (BMAC) from the iliac crest needs to be processed before it is injected. After the bone marrow is aspirated, it is run through a centrifuge to separate and concentrate the stem cells, growth factors, and platelets from other components, like red and white blood cells. This concentrated product is then injected into the injured area. • Various studies have shown that it can improve the healing rates, particularly in cases of atrophic nonunions, chronic nonunions as an adjuvant to surgical treatment[19]

Site Specific Nonunions

Introduction

Approximately 5–10% of long-bone fractures end up in nonunion. This rate may increase up to 30% in high-risk patients. In the upper limb, nonunion rates for clavicle fractures are 5.5%, humeral shaft fractures 1–30% and forearm fractures 2–10%.[25]

Proximal Humerus Nonunion

Most proximal humeral fractures that are undisplaced or minimally displaced heal uneventfully when managed conservatively. Risk factors for nonunion of proximal humerus fractures include surgical neck fractures, varus collapse, and calcar comminution.

Both, nonoperative and operative management have been described for managing proximal humerus nonunions. However, nonoperative management is almost always reserved for patients with medical comorbidities who cannot be subjected to the risk of surgery.

Surgical management includes various modalities such as locking compression plate with autologous cancellous bone graft, allograft, use of bone substitutes, hemiarthroplasty, and reverse shoulder arthroplasty.[26]

Humerus Shaft Nonunion

A vast majority of humeral shaft fractures are managed conservatively with functional bracing as angulation of up to 20° is tolerated in antero-posterior as well as lateral planes. The fracture patterns that most commonly lead to nonunion include transverse and short oblique fractures. Also, fractures in the proximal humeral diaphysis are at greater risk of nonunion compared to middle or distal shaft, due to greater forces acting on the proximal third of humerus.

Surgical management is preferred due to poor results shown by conservative management. The various modalities for fixation include compression plating with bone grafting, cortical strut grafting (allograft/autograft) with plating, dual plating, biological augmentation of the fixation with BMP-2 and BMP-7.[26,27]

Distal Humerus Nonunion

Distal humerus nonunions are challenging to treat due to the decreased biological activity locally, intraoperative challenges such as inadequate stability in cases with extensive comminution, and postoperative challenges such as regaining range of motion. Any movement at the nonunion site often leads to hardware loosening or failure.

While fixing a distal humerus fracture, it is crucial to restore the alignment of the proximal and distal

JAYPEE BROTHERS

fragments, so as to re-establish the carrying angle and restore elbow flexion.

Various surgical options include internal fixation with uni- or bi-columnar variable angle LCP, augmentation of the fixation with cancellous autograft, BMP-2 or BMP-7, allograft or bone substitutes. For nonunions that persist in spite of attempting fracture union with the above-mentioned modalities, elbow replacement is a viable option. However, it has its own challenges such as longevity of the implant.[28]

Forearm Nonunion

Nonunions are often associated with the nature, extent and severity of the injury. Monteggia fractures are amongst the most common causes of proximal ulna nonunions, particularly posterior fracture-dislocations. Olecranon nounions are relatively uncommon and often occur following insufficient surgical fixation, implant failure or patient non-compliance.

Radial head nonunions may occur in patients with complex fracture patterns with three or more fracture fragments. Diagnosing radial head nonunions may take up to a year after the trauma or surgery. Surgical intervention is advised only if the patient is symptomatic and not based on the radiographic appearance of the nonunion.

Due to the advent of compression plating, nonunions following forearm fractures, once commonly seen, are now uncommon and nonunion rates < 5% have been reported. Although rare, these nonunions are severely disabling for the patient as the dysfunction extends to the elbow as well as the wrist. Length must be maintained, fibrous tissue if any must be excised and the fractures must be fixed with compression plating. Augments can be used as necessary.

Distal radius nonunion is uncommon and can often be clinically diagnosed due to decreased hand and wrist functions. Although operative treatment is warranted, there is no consensus on the optimal technique. Various options available range from open reduction and internal fixation (ORIF) to resection of the ulna or wrist arthrodesis.[29,30]

Clavicle Nonunion

Middle third clavicle fractures are the most common subset of clavicle fractures. These fractures are commonly managed nonsurgically except when the fracture pattern and associated injuries warrant a surgical fixation. Conservatively treated clavicle fractures result in nonunion in 6–15% of cases.

Management options include compression plating with bone grafting, fixation with vascularized bone grafting, considering adjuvant treatment options such as BMP to promote fracture healing.[31]

Conclusion

Nonunion represents a biological and mechanical failure of fracture healing and remains a major cause of morbidity and revision surgery following fracture fixation. Successful management requires accurate identification of the underlying cause—whether mechanical instability, biological insufficiency, infection, or patient-related factors. A structured approach integrating clinical evaluation, imaging, laboratory assessment, and intraoperative findings provides the foundation for tailored treatment. Revision surgery should address both the mechanical environment (restoration of stability, alignment, and load-sharing) and the biological environment (optimizing vascularity, viable bone contact, and osteogenic stimulation). Advances in fixation strategies, biological augmentation, and patient optimization have significantly improved outcomes, but meticulous planning and execution remain the cornerstones of success. Prevention through sound surgical technique, stable fixation, soft-tissue preservation, and early recognition of delayed healing remains the most effective strategy against nonunion.

JAYPEE BROTHERS

KEY POINTS

- ❑ Nonunion is the cessation of the fracture healing process without bone union, typically diagnosed after an appropriate time interval and lack of progression on serial imaging.
- ❑ Distinguishing between hypertrophic (mechanical) and atrophic (biological) nonunions guides management strategy.
- ❑ Factors responsible for nonunions include mechanical factors such as inadequate stability, fixation failure, malalignment, or excessive motion; and biological factors such as poor vascularity, infection, bone loss, systemic conditions, or medications.
- ❑ Treatment involves achieving mechanical stability and biological augmentation.
- ❑ Mechanic stability comes from revision fixation, appropriate implant selection, and correction of alignment or gap.
- ❑ Biological restoration/enhancement comes from bone grafting (autograft, allograft, BMPs, or cell-based therapies) and soft-tissue optimization.
- ❑ Correct nutritional deficiencies, control diabetes, stop smoking, and manage systemic illness before reconstruction.
- ❑ Address infection definitively if present, with staged protocols when necessary.

References

1. Stewart SK. Fracture Non-Union: A Review of Clinical Challenges and Future Research Needs. Malays Orthop J. 2019;13(2):1-10
2. Rockwood CA, Green DP, Bucholz RW, Heckman JD, Tornetta P, (Eds). Rockwood and Green's Fractures in Adults. 9th edition. Philadelphia: Wolters Kluwer; 2019.
3. Solomin LN. Universal long bone nonunion classification. J Orthop Trauma. 2009;23(2):114-21.
4. Weber BG, Cech O. Non-union of Long Bones. Berlin: Springer; 1976.
5. Nicholson JA. Fracture nonunion in long bones: A literature review of risk factors and surgical management. J Orthop Trauma. 2019;33(3):e85-e92.
6. Migliorini F, Fini M, Giannoudis PV. Bone grafts and biomaterials substitutes for bone defect repair: A review. Orthop Traumatol Surg Res. 2020;106(8): 1505-16.
7. Andrzejowski P, Giannoudis PV. The 'diamond concept' for long bone non-union management. Bone Joint J. 2018;100-B(4):437-45.
8. Giannoudis PV. Fracture healing: the diamond concept. J Orthop Trauma. 2017;31(6):321-8.
9. Hak DJ, Fitzpatrick D, Bishop JA, et al. Delayed union and nonunions: epidemiology, clinical issues, and financial aspects. Injury. 2014;45 Suppl 2:S3-7.
10. Jensen SS, Jensen NM, Gundtoft PH et al. Risk factors for nonunion following surgically managed, traumatic, diaphyseal fractures: a systematic review and meta-analysis. EFORT Open Rev. 2022;7(7):516-25.
11. Thomas JD, Kehoe JL. Bone nonunion. Orthop Clin North Am. 2021;52(3):393-405.
12. Zimmerman RE, DeLong WG, Koval KJ. Fracture nonunion in long bones: A literature review of risk factors and surgical management. J Orthop Trauma. 2009;23(10):760-7.
13. Nicholson JA. Fracture nonunion in long bones: A literature review of risk factors and surgical management. J Orthop Trauma. 2019;33(3):e85-e92.
14. Gan JC. Electrical stimulation therapies for spinal fusions: current concepts. Spine J. 2018;18(7): 1133-45.

JAYPEE BROTHERS

15. Kastirr I, Hering J. Therapy of aseptic nonunions with parathyroid hormone. Orthop Traumatol Surg Res. 2016;102(1):103-7.
16. Brinker MR, O'Connor DP. Exchange nailing of ununited fractures. J Orthop Trauma. 2011;25(10): 621-8.
17. Meselhy MA. Role of Ilizarov external fixator in treatment of humeral non-union. Injury. 2019; 50(12):2241-9.
18. Kumar SH, Karthik MN, Sachin HG. Limb reconstruction system (LRS) in infected non-union of femur: A case series. J Orthop Case Rep. 2019;9(4):47-53.
19. Migliorini F, Fini M, Giannoudis PV. Autologous bone grafting in trauma and orthopaedic surgery: An evidence-based narrative review. Orthop Traumatol Surg Res. 2021;107(2):237-44.
20. Archual AJ. Vascularized bone grafts in orthopaedic surgery: A review of options and indications. J Orthop Trauma. 2020;34(6):e197-e205.
21. Mulica V, Haines J, Davidson D. Autograft, allograft, and bone graft substitutes: Clinical evidence and indications for use in the setting of orthopaedic trauma surgery. Orthop Clin North Am. 2019;50(3): 317-28.
22. Baldwin PA. Autograft, allograft, and bone graft substitutes: Clinical evidence and indications for use in the setting of orthopaedic trauma surgery. J Orthop Trauma. 2018;32(4):221-9.
23. Fuchs T, Ruchholtz S, Bastian L. Effect of bone morphogenetic protein-2 in the treatment of long bone non-unions. Bone Joint J. 2019;101-B(5): 568-74.
24. Tang X, Zhang L, Liu Y. Osteoimmunology: The role of immune cells in bone regeneration and healing. Bone Joint J. 2020;102-B(7):878-85.
25. Tzioupis C, Giannoudis PV. Prevalence of long-bone non-unions. J Orthop Trauma. 2018;32(5): e228-34.
26. Cadet ER, Koval KJ, Della Rocca GJ. Proximal humerus and humeral shaft nonunions. Orthop Clin North Am. 2021;52(1):71-84.
27. Leiblein M, Schneider E, Perren SM. Nonunions of the humerus: Treatment concepts in the last five years. Bone Joint J. 2019;101-B(1):1-10.
28. Donders JCE. Surgical technique: Treatment of distal humerus nonunions. J Orthop Trauma. 2021;35(4):e115-22.
29. Kloen P, van der Merwe W, Chen X. Management of forearm nonunions: Current concepts. Orthop Clin North Am. 2022;53(3):373-85.
30. Kloen P, Wipperman J, Lazzaro R. Treatment of diaphyseal nonunions of the ulna and radius. J Orthop Trauma. 2020;34(8):e286-94.
31. Marteschlager F, Schalamon J, Fink C. Management of clavicle nonunion and malunion. J Orthop Trauma. 2017;31(6):373-80.

JAYPEE BROTHERS

JAYPEE BROTHERS

for detailed information on orthopedics books, visit our website www.ejaypee.com, for detailed information on orthopedics books, visit our website www.ejaypee.com,for detailed inform

Master Series Monographs
Failed Fracture Fixation

BOS Worldwide

Building bridges—Sharing knowledge, experience, and expertise…

The BOS Masterseries Monographs are a series of books commissioned by the Bombay Orthopaedic Society with the goal of providing updated information, decision-making algorithms, and surgical techniques on selected orthopedic conditions. Reputed orthopedicians from Mumbai, around India, and internationally renowned experts have shared their knowledge, experience, and expertise in the field through this series.

"Failed Fracture Fixation (Volume 1: Upper Limb)" will be immensely beneficial to practicing orthopedic surgeons and trainees alike.

Key Features

- The monograph is case-based. Thirty cases of failed fracture fixations in the upper limb are presented with expert analysis of the cause of fixation failure.
- Various techniques of successful salvage of these failed fractures have been also discussed.

Gautam Zaveri is President of the Bombay Orthopaedic Society and the Bombay Spine Society. He is the Director of Spine Surgery at the Jaslok Hospital and Research Centre, Mumbai, Maharashtra, India. He is also the Editor-in-Chief of the ASSI Monograph Series, a series of books on various spinal disorders.



Dipit Sahu practices as an exclusive Shoulder Surgeon in Mumbai where he is associated with some of the leading hospitals including the Reliance Foundation, Jupiter, and BSES Hospitals, Mumbai, Maharashtra, India. He has also won numerous awards for his work on shoulder problems including the prestigious KS Masalawala Gold Medal at the Western India Regional Orthopaedic Conference 2023.



Prashant Kamble practices as an Upper Limb Specialist primarily in Mumbai, Maharashtra, India, focusing on disorders of the hand, wrist, and elbow. He is an Associate Professor at the Seth GS Medical College and KEM Hospital, Mumbai, and an Honorary Consultant at the Reliance Foundation and Jaslok Hospitals, Maharashtra.



Parag Lad practices as a Hand and Reconstructive Microsurgeon at the Pinnacle and Jupiter Hospitals, Mumbai, Maharashtra, India.



Shelving Recommendation
ORTHOPEDICS

ISBN 978-93-7202-948-2

Buy from ejaypee

JAYPEE BROTHERS