aypee.com, for detailed information on surgery books, visit our website www.ejaypee.com, for detailed information on surgery books, visit our website www.ejaypee.com

Solved Papers Surgery for PG Students (Topic Wise)

A must for MS and DNB Surgery Students

Last 10 Years Exams Across Various State Health Universities, AIIMS & DNB

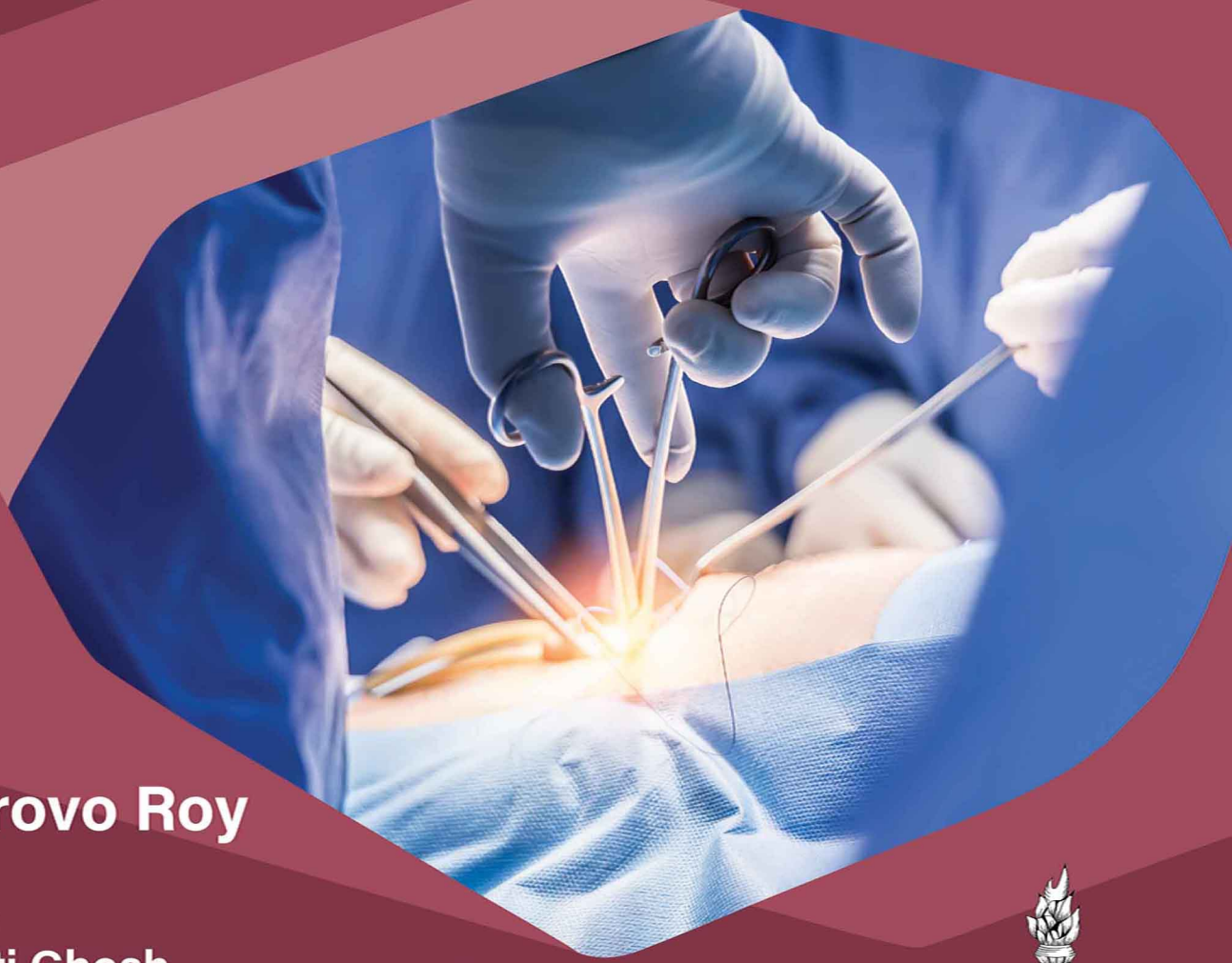

Editor
Arkaprovo Roy

Forewords
Shibajyoti Ghosh
Indranil Biswas

2nd Edition

JAYPEE

Contents

1. Basic Surgical Principle 1
2. Surgical Site Infection and Postoperative Complications 10
3. Nutrition 32
4. Fluid, Electrolyte, and Acid–Base Balance 55
5. Shock and Hemorrhage 67
6. Blood Coagulation 78
7. Blood Transfusion 83
8. Anesthesia and Critical Care 104
9. Trauma 115
10. Metabolic Response to Trauma 153
11. Wound 164
12. Burns 176
13. Damage Control Surgery 186
14. Daycare Surgery 194
15. Infections 197
16. Tuberculosis 213
17. Surgical Instruments and Energy Sources 221
18. Sterilization and Disinfection 241
19. Radiology 253
20. Orthopedics 264
21. Compartment Syndrome 269
22. Acute Abdomen and Abdominal Compartment Syndrome 274
23. Esophagus and Stomach 291
24. Bariatric and Metabolic Surgery 366
25. Small Intestine 383
26. Appendix, Colon, Rectum, and Anal Canal 449
27. Umbilicus 543
28. Peritoneum, Omentum, and Mesentery 548
29. Lymphoma 575
30. Surgical Diseases of Liver 582

31. Gallbladder and Bile Duct 606
32. Surgical Diseases of Pancreas 648
33. Spleen and Portal Hypertension 715
34. Hernia 756
35. Endoscopic, Laparoscopic, and Robotic Surgery 789
36. Breast 829
37. Endocrine Surgery 922
38. Diabetes 1005
39. Oncology 1010
40. Head and Neck 1045
41. Benign Skin Lesions and Soft Tissue Tumor 1079
42. Radiotherapy 1129
43. National Health Programme for Cancer 1134
44. Organ Transplantation 1139
45. Stem Cell Therapy 1178
46. Hair Transplantation 1180
47. Research in Surgery: Levels of Evidence 1182
48. Fast-track Surgery 1203
49. Vein, Artery, Nerve, and Lymphatics 1205
50. Abdominal Aortic Aneurysms 1265
51. Stents in Surgical Practice 1270
52. Cardiothoracic and Vascular Surgery 1272
53. Neurosurgery 1312
54. Plastic and Reconstructive Surgery 1337
55. Pediatric Surgery 1386
56. Investigations in Urology 1423
57. Kidney and Ureter 1426
58. Prostate and Urethra 1456
59. Urinary Bladder 1479
60. Penis 1490
61. Scrotum and Testis 1500

Index 1527

CHAPTER 35

Endoscopic, Laparoscopic, and Robotic Surgery

JAYPEE BROTHERS

LEARNING OBJECTIVES

- Physiological, Pathophysiological and Complications of Pneumoperitoneum
- Safe Laparoscopic Surgery
- Port Site Infection and Port Site Recurrence
- Diagnostic Laparoscopy
- Limitations of Minimal Access Surgery and Access Complications
- Notes and HALS
- Robotic Surgery
- Laparoscopic Hernia Surgery
- Ergonomics in Laparoscopic Surgery
- Endoscopy
- Robotic Surgery
- Artificial Intelligence in Surgery

PNEUMOPERITONEUM

1. What are the gases used for creating pneumoperitoneum? What are the physiological effects of pneumoperitoneum and complications of pneumoperitoneum in laparoscopic surgery?
WBUHS 2022, WBUHS 2025 Supplementary, DY Patil Educational Society Deemed to be University 2020

2. What are the pathophysiologic effect of CO_2 pneumoperitoneum? ***WBUHS 2013***

3. What are the complications of pneumoperitoneum and describe their management?
WBUHS 2016 , DY Patil Educational Society Deemed to be University 2020

Introduction

- Laparoscopic surgery is nowadays a common daily-performed procedure worldwide, replacing many types of open surgeries.
- It has the benefits of small incision, improved cosmetic aspects, less postoperative pain, and quick recovery time to normal activities.
- The most commonly used gas for insufflation is carbon dioxide (CO_2).
- Carbon dioxide pneumoperitoneum and increased intra-abdominal pressure (IAP) can induce many pathophysiologic disturbances, requiring the anesthesiologist to be well alert during the operation for necessary management.
- Moreover, advanced laparoscopic surgeries are being used also on older patients and in critically ill patients, requiring technically demanding anesthesia.

Different Gases Used for Pneumoperitoneum

Most common gas—CO_2

Other gases used are:

Air	Oxygen	N_2O	Helium	Argon	Mixture of these gases

Pathophysiologic Changes

Carbon dioxide pneumoperitoneum and increased IAP can induce many pathophysiologic disturbances, requiring the anesthesiologist to be well alert during the operation for necessary management.

Respiratory Changes

- The physiology of respiratory system is affected by pneumoperitoneum.
- With insufflation, causing an increase in IAP, the diaphragm is pushed upward causing stiffness of the chest wall, causing the total volume of the lungs to be reduced.
- Hence, the pulmonary compliance is decreased to 35–40% and also a non-negligible increase in the maximum respiratory system resistance.
- Hypoxemia may occur from a ventilation-perfusion mismatch and intrapulmonary shunting but is rare in healthy patients.

(CO_2 is usually administered at a rate of 1–2 mL/min being a highly soluble gas, it is readily absorbed into the circulation through the peritoneum, causing hypercapnia and acidosis)

- Several studies have shown the effect of CO_2 pneumoperitoneum on the arterial partial pressure of CO_2 ($PaCO_2$) and end-tidal CO_2 ($ETCO_2$). CO_2 is mainly excreted by the lungs, depending on alveolar and mixed venous CO_2 exchange rates, which are themselves controlled by the cardiac output, alveolar ventilation, and respiratory quotient.
- Normal excretion of CO_2 is 100–200 mL/min and is increased by 14–48 mL/min when CO_2 is administered intraperitoneally.
- After a long laparoscopic operation, achieving a normal CO_2 value can take several hours after desufflation.

Cardiovascular Changes

- Cardiovascular system effects during CO_2 pneumoperitoneum are caused mainly by hypercarbia followed by acidosis and increased IAP.
- Euvolemic status is of great importance prior to surgery to reduce any cardiac depression via reduced preload caused by the pneumoperitoneum.
- Hypercarbia has direct and indirect sympathoadrenal stimulating effects on cardiovascular functions.
- These effects are not pronounced with mild hypercarbia ($PaCO_2$ 45–50 mm Hg).
- Moderate-to-severe hypercarbia affects cardiac function since it is then a myocardial depressant and has direct vasodilatory effect.

Renal Changes

- Oliguria is the most common renal effect of pneumoperitoneum.
- Different mechanisms are involved in the reduction of the urine amount during IAP. IAP also activates of the renin-angiotensin-aldosterone system following decreased renal perfusion, which results in renal cortical vasoconstriction.
- Level of antidiuretic hormone (ADH), renin, and aldosterone significantly increased during laparoscopic gastric bypass (GBP).
- Renal blood flow (RBF) has been measured during increasing IAP, and a gradual decrease in RBF up to 75% was observed upon reaching a pressure of 15 mm Hg.
- Those with maintenance fluid, whereas this change was not noticed in well-hydrated animals with adequate volume loading.

Splanchnic Changes

- The splanchnic circulation is also affected during raised IAP. Depending on IAP, studies in animals have shown to decrease in splanchnic macro and microcirculation.
- Signs of hepatocytic damage were noticed, with increase of glutamic oxaloacetic transaminase and glutamic pyruvic transaminase. Impaired Kupffer cell function and gastric intramucosal pH drop were also noticed.

JAYPEE BROTHERS

Complications

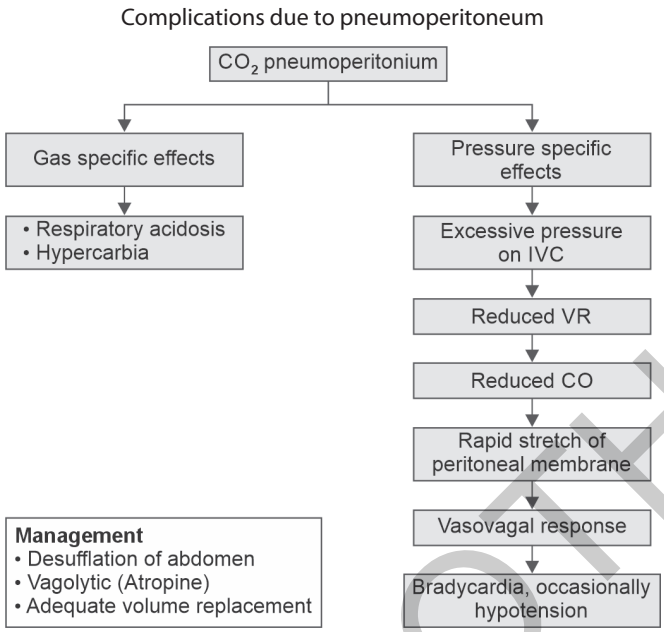

(CO: cardiac output; IVC: inferior vena cava; VR: venous resistance)

Pulmonary Complications of Pneumoperitoneum

- Gas embolism
- Barotraumas, hypoxemia
- Pulmonary edema
- Atelectasis
- Subcutaneous emphysema
- Pneumothorax
- Pneumomediastinum
- Pneumopericardium

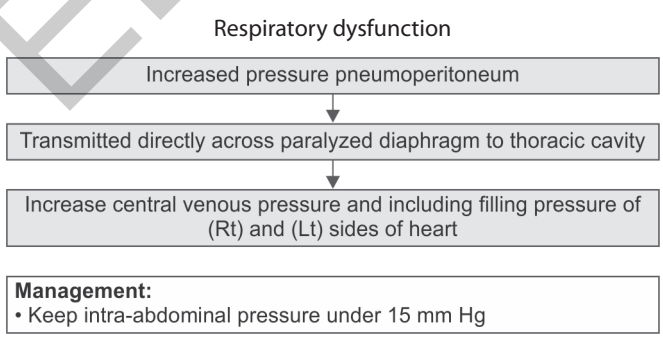

- *Carbon dioxide embolism:*
  - Rare
  - *Incidence:* 0.0014–0.6% of laparoscopic surgeries
  - Mortality rate of about 28%
  - Carbon dioxide enters the circulation through an opening in a damaged vessel under raised IAP.
  - It can also occur if the Veress needle is misplaced into a vessel or parenchymal organ.
  - Transesophageal echocardiography studies have shown bubbling of CO_2 in the right heart chamber in 68% asymptomatic patients during pneumoperitoneum.

JAYPEE BROTHERS

- *Clinical manifestations of gas embolism:*
  - Severe drop in blood pressure
  - Cyanosis
  - Cardiac arrhythmias or asystole
  - A mill-wheel murmur may be heard on auscultation of the heart.
  - $ETCO_2$ will increase.

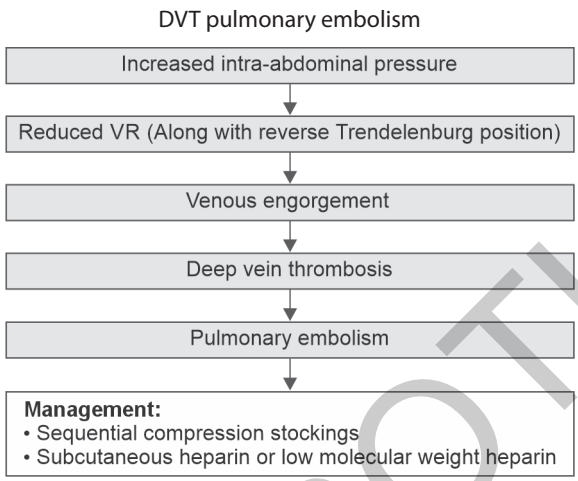

(DVT: deep vein thrombosis; VR: venous resistance)

- *Subcutaneous emphysema:*
  - *Incidence:* 0.3–3.0% laparoscopic surgeries
  - Mild-to-severe subcutaneous emphysema has generally not been shown to have clinical effects, but upper airway obstruction must be considered if there is neck involvement.

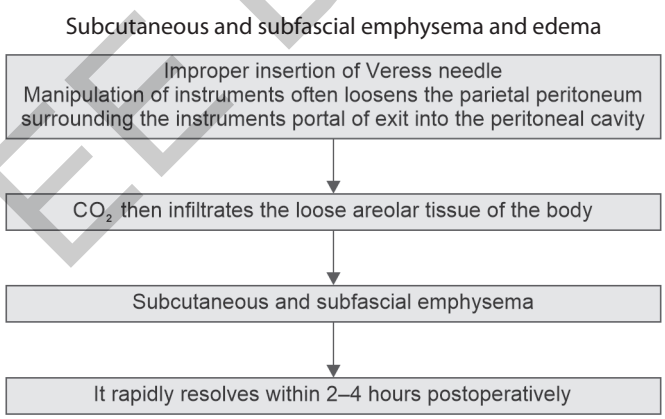

- *Pneumothorax* can occur following peritoneum visceral tear, parietal pleura tear during resection around the esophagus or congenital defect in the diaphragm through which CO_2 gas travels. Pneumothorax should be differentiated with capnothorax following CO_2 diffusion into the intrapleural space.
  - *Diagnosis:* Presence of rapidly falling oxygen saturation or pO_2 together with difficult ventilation and decreased breath sounds.
  - *Management:*
    - Immediate needle thoracostomy
    - Aspiration
    - Chest radiograph
    - Placement of chest tube

JAYPEE BROTHERS

- Extension of emphysema can also occur, causing *pneumothorax and pneumomediastinum*.
  - With both pneumothorax and capnothorax, the $ETCO_2$ increases, so capnothorax can be suspected if the mean airway pressure increases with a drop in SpO_2, and confirmation should be made with a chest X-ray.
- *Pneumopericardium* can develop when CO_2 is forced into the mediastinum and pericardium. It can also occur if CO_2 enters the defect in the membranous portion of the diaphragm, resulting in a communication between the pericardial and peritoneal cavities.

Cardiovascular Complications

- Hypertension
- Arrhythmias
- Hypotension and cardiac arrest
  - *Hypertension* seems to have a higher incidence at the beginning of insufflation when the blood volume in the splanchnic vasculature is reduced due to increased IAP, thereby increasing preload and arterial pressure.
  - *Arrhythmias* occur in up to 14–27% of laparoscopies. These must be differentiated from arrhythmias caused by release of catecholamine.
  - *Sinus tachycardia* and *ventricular extrasystoles* are usually more benign, and dangerous ones like bradyarrhythmias (bradycardia, nodal rhythm, atrioventricular dissociation, and asystole) are also seen.
  - *Bradyarrhythmia:*
    - It arises due to the vagal nerve-mediated cardiovascular response following acute stretching of the peritoneum.
  - *Hypotension:*
    - It occurs in up to 13% of laparoscopies, a potentially serious complication. IAP of 20 mm Hg or more results in compression of the inferior vena cava, reducing the venous return. Cardiac output is reduced, leading to hypotension.
    - This complication is aggravated by high intrathoracic pressure.
  - *Vasovagal responses* to quick intraperitoneal CO_2 insufflation and gas embolism have both been related to *cardiac arrest*. The possible development of acute tubular necrosis in response to long-lasting hypoperfusion from pneumoperitoneum is controversial.
  - Free radicals are released by inflation and deflation of the peritoneum. Oxygen and organic free radicals may contribute to ischemia reperfusion phenomena or chemical carcinogenesis. Still, the impact of production of free radicals is smaller than with open surgery injury.

Renal Complications

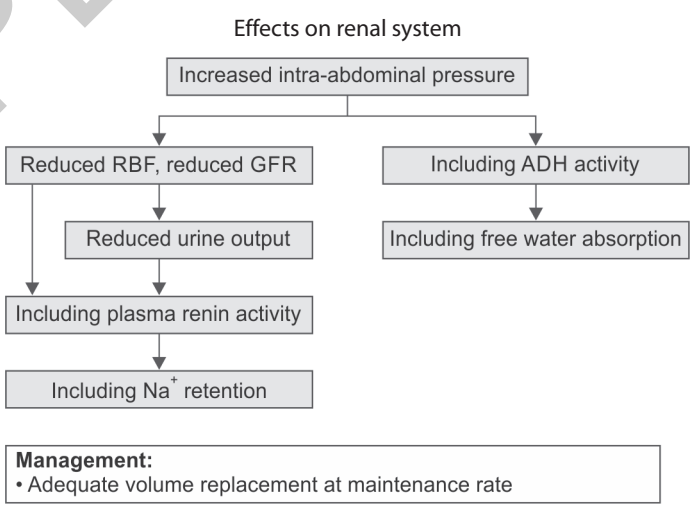

(ADH: antidiuretic hormone; GFR: glomerular filtration rate; RBF: renal blood flow)

JAYPEE BROTHERS

- The possible development of acute tubular necrosis in response to long-lasting hypoperfusion from pneumoperitoneum is controversial.
  - *Free radicals* are released by inflation and deflation of the peritoneum. Oxygen and organic free radicals may contribute to ischemia reperfusion phenomena or chemical carcinogenesis.

4. Write down the indications, complications, and prevention of complication of carbon dioxide pneumoperitoneum. ***WBUHS 2025***

Carbon Dioxide Pneumoperitoneum

Indications:

- *Laparoscopic surgery:* Used to create a working space in the abdominal cavity for procedures like cholecystectomy, appendectomy, hernia repair, and gynecologic surgeries (e.g., hysterectomy, ovarian cystectomy).
- *Diagnostic laparoscopy:* Facilitates visualization of abdominal organs for diagnostic purposes, such as evaluating chronic abdominal pain or staging malignancies.
- *Minimally invasive procedures:* Employed in robotic surgeries and endoscopic interventions requiring abdominal insufflation.

Complications:

I. *Gas-related complications:*
   - *Hypercarbia:* Excessive CO_2 absorption leading to respiratory acidosis.
   - *Gas Embolism:* Rare but life-threatening; CO_2 bubbles enter the bloodstream, potentially causing cardiovascular collapse.
   - *Subcutaneous emphysema:* CO_2 leaks into subcutaneous tissues, causing swelling and crepitus.
   - *Pneumothorax/pneumomediastinum:* Gas migration into the thoracic cavity or mediastinum.

II. *Pressure-related complications:*
   - *Increased intra-abdominal pressure (IAP):* Can reduce venous return, leading to decreased cardiac output, especially in patients with cardiovascular compromise.
   - *Organ ischemia:* Elevated IAP may impair blood flow to abdominal organs (e.g., kidneys, liver, intestines).
   - *Diaphragmatic splinting:* High pressure restricts diaphragm movement, reducing lung compliance and causing respiratory distress.

III. *Procedure-related complications:*
   - *Visceral or vascular injury:* During trocar insertion or due to excessive pressure.
   - *Postoperative shoulder pain:* Referred pain from diaphragmatic irritation by residual CO_2.
   - *Postoperative nausea/vomiting:* Due to CO_2 absorption or peritoneal irritation.

IV. *Patient-specific complications:*
   - Exacerbation of pre-existing conditions (e.g., chronic obstructive pulmonary disease, heart failure) due to hypercarbia or increased IAP.
   - *Compartment syndrome:* Prolonged high-pressure pneumoperitoneum may lead to abdominal compartment syndrome.

Prevention of Complications

I. *Monitoring and technique:*
   - *Intraoperative monitoring:* Continuous monitoring of end-tidal CO_2, arterial blood gases, and intra-abdominal pressure (typically maintained below 12–15 mm Hg in adults, lower in pediatric patients).
   - *Low-pressure pneumoperitoneum:* Use the lowest effective pressure to minimize cardiovascular and respiratory effects.
   - *Proper trocar placement:* Use open (Hasson) technique or optical trocars to reduce risk of visceral/vascular injury.

JAYPEE BROTHERS

- *Gradual insufflation:* Slow initial insufflation to monitor for adverse effects and avoid sudden pressure spikes.

II. *Patient selection and preparation:*
- *Preoperative assessment:* Evaluate cardiopulmonary status to identify patients at risk of complications from hypercarbia or increased IAP.
- *Optimize patient condition:* Correct hypovolemia and stabilize comorbidities before surgery.

III. *Intraoperative strategies:*
- *Ventilation adjustments:* Use adequate positive end-expiratory pressure (PEEP) and adjust tidal volumes to manage hypercarbia and prevent atelectasis.
- *Warming CO_2 gas:* Use warmed, humidified CO_2 to reduce peritoneal irritation and postoperative pain.
- *Limit Procedure Duration:* Minimize duration of pneumoperitoneum to reduce CO_2 absorption and pressure-related effects.

IV. *Postoperative care:*
- *Complete gas evacuation:* Ensure thorough desufflation at the end of surgery to minimize residual CO_2 and reduce shoulder pain.
- *Monitor for complications:* Observe for signs of subcutaneous emphysema, pneumothorax, or gas embolism in the recovery period.
- *Pain management:* Administer analgesics to manage referred shoulder pain or abdominal discomfort.

V. *Special considerations:*
- *Alternative gases:* In high-risk patients, consider helium insufflation (less soluble, lower risk of hypercarbia) if available, though CO_2 remains standard due to safety and availability.
- *Training and expertise:* Ensure surgeons and staffs are trained in laparoscopic techniques to minimize procedural errors.

---

5. Describe peritoneal access in laparoscopic abdominal surgery and principles of VATS.

Srimanta Sankaradeva University, Assam 2025

Peritoneal Access in Laparoscopic Abdominal Surgery

Definition

Peritoneal access is the initial entry into the abdominal cavity to establish pneumoperitoneum (insufflation of CO_2), which allows visualization and working space for laparoscopic instruments.

Methods of Access

- *Closed (Veress Needle Technique)*
  - *Steps:*
    - A small infra- or supra-umbilical incision is made.
    - The *Veress needle* is inserted through the abdominal wall into the peritoneal cavity.
    - Correct placement is confirmed (e.g., saline drop test, low insufflation pressure).
    - CO_2 is insufflated to create pneumoperitoneum (usually 12–15 mm Hg).
    - A trocar is inserted after adequate distension.
  - *Advantages:* Quick, small incision.
  - *Risks:* Blind entry—risk of injury to bowel or major vessels.
- *Open (Hasson Technique)*
  - *Steps:*
    - Small incision at the umbilicus.
    - Layers of abdominal wall dissected under direct vision to enter peritoneum.
    - A blunt-tipped (Hasson) trocar is secured with sutures.
    - CO_2 insufflation is started.
  - *Advantages:* Direct vision reduces injury risk—preferred in patients with prior surgeries or suspected adhesions.

JAYPEE BROTHERS

- *Optical trocar/direct entry technique*
  - A trocar with an integrated endoscope is inserted directly through the abdominal wall under visual guidance.
  - *Advantages:* Direct visualization during entry, rapid, less risk of insufflation errors.

Principles of Safe Peritoneal Access

- *Patient positioning:* Usually supine, table level.
- *Empty bladder and stomach* before entry.
- *Choice of site:* Umbilicus is common; alternate sites (Palmer's point) for patients with prior laparotomy or suspected adhesions.
- *Check insufflation pressure:* Should remain low (<10 mm Hg initially).
- *Always confirm intraperitoneal placement* before inserting additional trocars.

Principles of VATS (Video-Assisted Thoracoscopic Surgery)

Definition

VATS is a minimally invasive surgical approach to the thoracic cavity using a thoracoscope and specialized instruments inserted through small intercostal incisions.

Basic Principles

- *Single-lung ventilation:* Achieved with double-lumen endotracheal tube to collapse the operative lung and allow visualization.
- *Port placement:* Typically 2–4 small ports placed strategically depending on the procedure (e.g., lobectomy, pleurodesis).
- *Thoracoscopic visualization:* Camera provides magnified image on video monitor.
- *CO_2 insufflation (optional):* Sometimes used at low pressure to aid collapse and visualization.
- *Instrumentation:* Long, articulated instruments for dissection, stapling, and specimen retrieval.

Advantages

- Smaller incisions, less pain.
- Reduced postoperative complications (less atelectasis, faster recovery).
- Shorter hospital stay and improved cosmetic results.

Limitations/Precautions

- Requires adequate lung isolation and trained anesthetic support.
- Limited tactile feedback.
- Conversion to thoracotomy may be necessary if bleeding or poor visualization occurs.

SAFE LAPAROSCOPIC SURGERY

6. Enumerate the principles of safe laparoscopic surgery. Discuss the technique of primary trocar insertion.
WBUHS 2022

7. Basic principle of port site placement in laparoscopic surgery and technique for primary trocar insertion.
Rajasthan University of Health Sciences 2025

Principles of Safe Laparoscopic Surgery

- Patient positioning and how this aids surgery
- Gaining access into the abdomen
- Methods of establishing pneumoperitoneum
- Maintaining good vision during surgery and how this can be achieved
- Insertion of additional ports
- A description of available laparoscopic instruments

JAYPEE BROTHERS

- Limitations of laparoscopy
- Closure of port sites
- Threshold for conversion

Basic Principles of Port Site Placement in Laparoscopic Surgery

Port placement follows *6 core principles* to ensure *safety, efficiency, and ergonomics*:

The 6 Golden Rules

#	*Principle*	*Key rule*	*Purpose*
1	Triangulation	Form a *60°–90° triangle* between camera and two working instruments pointing to the *target organ*	Enables natural manipulation, prevents clashing
2	Target-centric	All ports *converge toward the operative field*	Keeps instruments in view, avoids blind zones
3	Trocar spacing	*≥5–7 cm between ports ≥2–3 cm from bony landmarks*	Prevents external collision, gas leaks, hernia
4	Camera first	Insert *camera port first* (usually *umbilicus*) under direct vision	Establishes safe pneumoperitoneum and overview
5	Tailored to anatomy	Adjust for *BMI, height, prior scars, organ location*	Avoids poor reach, injury, or conversion
6	Ergonomic alignment	Ports at *mid-abdominal level*, surgeon's elbows *90°–110°*	Reduces fatigue and musculoskeletal strain

Standard Camera Port Locations

Procedure Type	*Camera port*
Upper GI/biliary	*Umbilicus or supraumbilical*
Colorectal/pelvic	*Umbilicus or infraumbilical*
Reoperative/adhesions	*Left upper quadrant (Palmer's point)*

Quick Placement Tips

- *Right-hand port*: Slightly *cephalad and lateral* to camera
- *Left-hand port*: *Mirror image* across midline
- *Assistant port*: For *retraction only* (e.g., subxiphoid in cholecystectomy)
- *Avoid midline below umbilicus* for large (>10 mm) ports → ↑ hernia risk
- *Transilluminate* to avoid epigastric vessels

Complications of Poor Placement

Issue	*Cause*	*Fix*
Instrument fighting	Ports too close	Increase spacing
Limited reach	Ports too far	Pre-check with spinal needle
Bleeding	Epigastric injury	Transilluminate
Hernia	Large port in midline	Close fascia, use lateral sites

Technique of Primary Trocar Insertion

- *The open "Hassan" technique* can be likened to the now infrequently used "diagnostic peritoneal lavage" approach.
- Whilst there are minor surgeon-dependent variations in this approach, the technique is standardized.
  - The approach commences with a small vertical skin incision (1 cm) below or above the umbilicus depending on the position of the patient's umbilicus in relation to the territory being operated on.
  - The cicatrix of the umbilicus is then elevated using a clip and dissection is performed to expose the abdominal fascia at the base of the cicatrix.

JAYPEE BROTHERS

- The abdominal fascia can then be raised with sutures placed on either side of the midline or with a second clip in order to maximize the distance from the underlying intra-abdominal organs.
- The fascia and peritoneum are then incised in a controlled and progressive manner in order to maintain a truly open technique as opposed to bluntly pushing in instruments, which can easily cause injury.
- A 10-mm trocar and port is generally inserted through this opening, though with the advent of smaller scopes 5-mm ports can now be used instead.
- Inserting the trocar through the fascia has significant potential for iatrogenic injury and reports of aortic or inferior vena cava injury unfortunately occur more frequently than they should.
- Damage to the underlying structures can be minimized by elevating the fascia, ensuring the technique is truly open and by pointing trocars down to the pelvis away from the main vessels on insertion.
- There are several variations to the described method. Some are due to surgeon choice and others are driven by specific surgical indications.

- *Closed method:*
  - A Veress needle can be used to create a pneumoperitoneum prior to port insertion. The Veress needle has a spring-loaded, inner blunt stylet positioned centrally within an outer cannula that has a beveled end.
  - As the Veress needle is pushed through firm tissue, pressure on the tip pushes the blunt stylet into the shaft of the outer cannula, allowing the outer needle to cut through.
  - As the needle passes through the firm layer, the blunt-tipped inner stylet springs out and serves to protect any abdominal viscera from iatrogenic injury by the sharp cannula.
  - Once the Veress needle is in the abdominal cavity, the abdomen is filled with gas before the port is inserted. Patients that have had previous surgery are prone to adhesion formation and carry an increased risk of visceral injury on entry into the abdomen.
  - Special techniques may be required in such circumstances to permit safe entry. One common technique involves an open cut down at a safe site away from scars, such as Palmer's point in the left upper quadrant. An alternative method of entry involves the use of a visual port.
  - The laparoscope is mounted into this port, which is then carefully twisted through the layers of the abdominal wall and into the peritoneal cavity under direct laparoscopic vision. In this instance, it is helpful to have the insufflation gas attached and flowing at the high-flow rate as this aids identifying when the peritoneal cavity has been entered.

PORT SITE INFECTION AND PORT SITE RECURRENCE

8. Discuss the causes of port site infections with particular reference to microbiology. How are they managed? ***WBUHS 2018***

Introduction

- Mycobacterial infections due to atypical mycobacteria at the laparoscopic port site are a common menace encountered in patients undergoing laparoscopic surgery.
- Atypical mycobacterial colonies often exist in tap water, natural waters, and soil and so can easily contaminate solutions and disinfectants used in hospital settings.
- These infections have been a source of significant morbidity for patients recovering from laparoscopic surgeries.

Port Site Wound Infections in Laparoscopy can be of Two Types

1. The first type occurs immediately within 1 week of laparoscopic surgery due to gram negative or positive bacteria derived from infection acquired during surgery from the infected gall bladder or from the skin or the surgical procedure itself and can be treated by common antibiotics and local wound dressing.
2. The second type is caused by atypical mycobacteria which includes the group of mycobacterial species that is not part of the *Mycobacterium tuberculosis* complex having an incubation period of 3–4 weeks which do not respond to common antibiotics.

JAYPEE BROTHERS

Infections with Atypical Mycobacteria

- Infections with atypical mycobacteria have been primarily reported after laparoscopic procedures.
- This is because, unlike open surgery, the instruments used for laparoscopic surgery have a layer of insulation that restricts the use of the autoclave in the sterilization process as the high temperatures involved destroy the insulation on them.
- The standard sterilization procedure has been a 20-minute exposure to 2.0–2.5% glutaraldehyde.
- At the current exposure time, these solutions act only as disinfectants and not as sterilizing agent thus allowing bacterial endospores to survive.
- Also, when proper mechanical cleaning of the instruments is not done, blood and charred tissue deposits are left in the joints of the instruments during laparoscopic surgery.
- These contaminated instruments deposit the endospores on to the subcutaneous tissue during the surgery which then germinate following which clinical symptoms appear after an incubation period of 3–4 weeks.

Prevention

- Disposable laparoscopic instruments are the best solution for prevention of infection and is used in western countries.
- The use of advanced sterilization systems like STERRAD, which utilizes gas plasma technology to kill spores at low temperatures, or using ethylene oxide gas for sterilization of insulated laparoscopic instruments. One can also keep instruments for 24 hours in a formalin gas chamber.

Treatment

- These microorganisms show limited response to first line antituberculosis drugs. The standard treatment consists of combinations of second-line antitubercular drugs including macrolides such as clarithromycin, quinolones like ciprofloxacin, tetracyclines like doxycycline, and aminoglycosides like amikacin.
- The standard treatment starts after manifestation of clinical symptoms which consist of a 28-day regimen of oral clarithromycin and ciprofloxacin or amikacin.
- However, local administration of aminoglycosides has been shown to be highly efficacious in the treatment of particularly stubborn nodules and sinuses that persist after completion of oral therapy.

9. Port site recurrences in laparoscopic surgery. *WBUHS 2006*

Port Site Recurrence

Background

The advent of laparoscopic surgery and the increasing use in intraabdominal and thoracic malignancy has brought forward an uncommon problem of port site recurrence of the primary tumor.

The Diagnosis must Ascertain

- Histologically proven tumor deposit
- A localized circumscribed subcutaneous tumor growth of the abdominal or thoracic wall occurs within the fibrous tissue of the scar as the consequence of a trocar or other sites after laparoscopy, thoracoscopy, or mediastinoscopy.
- Early tumor recurrence (<200 days)
- Port site metastasis is not identical to peritoneal metastasis, serosal invasion, skin metastasis, etc.

Etiology and Pathogenesis

The deposition of metastasis in port site can be attributed due to:

- Increased circulation to parietes in laparoscopic surgery
- *Chimney effect:* At all times, an exodus of the insufflation gas tends to spread the tumor to port site via aerosols.
- Contamination of port by tumor seedling (though not conforming to definition)

JAYPEE BROTHERS

Presentation

The revival of the same histologic nature of tumor along the site of extraction of the specimen/unrelated to extraction site may occur in early recurrence. Late recurrence is uncommon.

Diagnosis

As this is diagnosed during follow-up of epithelial cancer the diagnosis is mostly clinical followed by cross-sectional imaging. An excisional biopsy proves the diagnosis.

Treatment

Surgical excision of the port site recurrence with suitable margin (at least 1 cm) along with removal of intra-abdominal recurrence if any.

Prognosis

With a few reports available only port site metastasis does not have a favorable prognosis for epithelial cancers. Though they behave differently from recurrence and thus the longevity is much more than recurrence.

Prevention of Port Site Recurrence

Before resection	*During resection*	*After resection*
• Proper patient selection (exclude patients with very large lesions or lesions invading adjacent organs) • Adequate training and experience of surgeons and assistants • Careful tumor localization • Proper port placement • Anchor all ports	• Avoid gas leaks • Identify tumor bearing segment (intraoperative colonoscopy if needed) • Avoid direct tumor handling or manipulation • Sound surgical techniques (closed resection, en block resection with lymphatic drainage, proximal vessel control, and clearance of resection margin) • Respect oncologic principles • Thorough irrigation and suctioning of abdomen	• Adequate-sized incision for removal of specimen • Wound protector or specimen bag • Microscopic and, if needed microscopic analysis of resected specimen • Thorough irrigation of ports and abdomen with cytotoxic solution or normal saline before closure • Fascial and peritoneal wound closure for ports 10 mm or longer

DIAGNOSTIC LAPAROSCOPY

10. Indications and advantages of diagnostic laparoscopy. *WBUHS 2016*

Diagnostic laparoscopy is often done for the following:

- Find the cause of pain or a growth in the abdomen and pelvic area when X-ray or ultrasound results are not clear.
- After an accident to see if there is injury to the abdomen.
- Before procedures to treat cancer to find out if the cancer has spread. If so, treatment will change.

It is done to examine the following organs:

- Appendix
- Gallbladder
- Liver
- Pancreas
- Small and large bowel
- Spleen
- Stomach
- Pelvic or reproductive organs

JAYPEE BROTHERS

It can detect:

- An abdominal mass or tumor
- Fluid in the abdominal cavity
- Liver disease
- The effectiveness of certain treatments
- The degree to which a particular cancer has progressed.

Risks

- Stomach pain that becomes more intense overtime.
- Chills
- Fever
- Redness, swelling, bleeding, or drainage at the incision sites
- Continuous nausea or vomiting
- Persistent cough
- Shortness of breath
- Inability to urinate
- Lightheadedness

Abnormal results may be due to a number of different conditions, including:

- Scar tissue inside the abdomen or pelvis (adhesions)
- Appendicitis
- Cells from inside the uterus grow in other areas (endometriosis)
- Inflammation of the gallbladder (cholecystitis)
- Ovarian cysts or cancer of the ovary
- Infection of the womb, ovaries, or fallopian tubes (pelvic inflammatory disease)
- Signs of injury
- Spread of cancer
- Tumors
- Noncancerous tumors of the womb (uterine fibroids)

11. Diagnostic laparoscopy in staging of gastrointestinal malignancy. *WBUHS 2019*

Introduction

- The staging of gastrointestinal malignancies aims to ensure that each patient receives the most appropriate treatment with minimal morbidity and in a cost-effective manner.
- Thus, the goal of staging is to distinguish patients who have a potentially resectable localized tumor from those with advanced disease and/or distant metastases.
- Accurate staging has become increasingly important in view of the increasing alternatives for neoadjuvant therapy and nonoperative palliative procedures.

Inspection of the Peritoneal Cavity

- The initial step in staging laparoscopy is meticulous inspection of the four quadrants of the peritoneal cavity, which, if done properly, can identify serosal implants as small as 1 mm.
- To facilitate visualization, any ascitic fluid should be aspirated and sent for cytology prior to inspection.
- However, if laparoscopic ultrasonography (USG) is planned during the evaluation, it should be performed before aspiration, as the ascitic fluid is an excellent medium for the transduction of ultrasonic sound waves.

Peritoneal Washings

Peritoneal washings should be obtained, especially if the patient is being evaluated for pancreatic cancer, as the presence of malignant cells has been shown to influence resectability and prognosis.

JAYPEE BROTHERS

Biopsy

- When a parenchymal lesion, peritoneal implant, or suspicious lymph node is identified, laparoscopic biopsy can be done with great precision.
- Depending on the size and location, tissue may be obtained by a variety of techniques, including fine-needle, core-needle, forceps, and incisional or excisional biopsy.

Role of Laparoscopic Staging Procedures in Various Regions of them Gastrointestinal Tract

Hepatic Malignancies

- Laparoscopic techniques are well suited to confirm the diagnosis of hepatocellular carcinoma or metastatic liver lesions, in that they can be used to visualize a surface lesion and perform a biopsy.
- Laparoscopy is a reliable method for detecting additional small lesions and peritoneal seeding, which are usually missed by other imaging methods.
  - *Primary liver tumors:*
    - In a recent series of 50 consecutive patients diagnosed with potentially resectable liver tumors, laparoscopy alone demonstrated unresectability in 46%, and nontherapeutic laparotomy was avoided in these patients.
    - Numerous studies have shown that intraoperative ultrasound during open operations is more sensitive for the detection of liver lesions than preoperative imaging modalities, including ultrasound, CT, CT portography, and magnetic resonance imaging (MRI).
    - Based on the results of intraoperative USG, the operative plan was altered in one-third of the study group. Intraoperative USG also may be used to evaluate surrounding structures, including the portal vein and perihilar structures.
    - Laparoscopy and laparoscopic USG averted a nontherapeutic laparotomy.
  - *Liver metastases:* Intraoperative ultrasound may also be used during primary resection of colorectal cancer to identify liver metastases that are not detected by preoperative ultrasound or CT.

Biliary Tract Malignancies

- Malignancies of the biliary tree are relatively rare, and therefore comparisons of staging modalities are difficult to perform. Only a few studies have addressed the usefulness of laparoscopic staging in these diseases
- If, during laparoscopic staging, a gallbladder carcinoma is suspected, conversion to an open surgical approach is recommended.

Pancreatic Cancer

- Pancreatic cancer is notorious for its propensity to metastasize to the liver and peritoneum.
- Most of the patients exhibit local tumor invasion and metastatic spread by the time symptoms occur and therefore have disease that is unresectable for cure.
- Unfortunately, current preoperative imaging methods frequently the disease, and, based on these tests, patients with unsuspected advanced disease undergo laparotomy unnecessarily.
- Studies have demonstrated that over 40% of patients have peritoneal or liver metastasis despite negative preoperative imaging with ultrasound or CT.
- Laparoscopy currently plays a dominant role in the management of pancreatic cancer since it not only has a sensitivity and specificity of 93% and 100%, respectively, for the detection of pancreatic tumors but also enables the biopsy of such lesions.
- Furthermore, peritoneal washings for cytological examination should be obtained during laparoscopic staging of pancreatic malignancies.

Gastric Cancer

- Accurate staging of gastric cancer is increasingly important since more patients are being offered neoadjuvant or palliative therapy without surgical confirmation of disease stage. Endoscopic USG combined with CT is currently the state-of-the-art in staging gastric carcinoma.

JAYPEE BROTHERS

- These imaging modalities can miss small metastatic deposits from gastric cancer, resulting in unnecessary laparotomies in patients who already have a poor prognosis.
- Moreover, endoscopic USG has been reported to over stage T-stage in 40% of cases and may result in resectable patients being placed on palliative treatment protocols.
- Several recent reports have addressed the value of laparoscopic staging in gastric cancer.

Esophagogastric Cancer

The use of laparoscopy to stage cancer of the esophagus and gastric cardia remains controversial

Colon and Rectal Cancer

- Currently, there are few absolute indications for staging laparoscopy in the evaluation of a primary colon or rectal malignancy.
- It may be reasonable to perform diagnostic laparoscopy in a patient with an advanced rectal cancer if a suspicious liver lesion is noted on preoperative CT and the patient is being considered for neoadjuvant therapy.
- If the hepatic lesion is proven to be benign by laparoscopy and laparoscopic ultrasound, neoadjuvant therapy could then proceed.
- If malignant, such therapy could be canceled and an immediate palliative procedure performed.

Radioimmunoguided Surgery

- Radioimmunoguided surgery (RIGS) using laparoscopic probes is also on the horizon.
- The RIGS system utilizes a monoclonal antibody CC49-radiolabeled with iodine-125 targeted against a mucin that is highly expressed in human adenocarcinomas, tumor-associated glycoprotein-72 (TAG-72).
- Although the accuracy of RIGS is still being evaluated in open operations, preliminary results of a phase III trial indicate that it accurately determines disease stage and, therefore may influence perioperative therapy and extent of resection.
- Perhaps laparoscopic RIGS will have its greatest impact on improving staging accuracy so that decisions about appropriate neoadjuvant therapy can be made prior to resection, if indicated.

Conclusion

- Although the results of randomized trials comparing laparoscopic and conventional resections for abdominal malignancies will not be available for several years, it is clear that laparoscopic techniques are attaining a prominent role in the diagnosis and staging of many gastrointestinal malignancies.
- The recent addition of laparoscopic USG appears to have achieved an extremely high degree of sensitivity in the evaluation of solid organs without the need for a laparotomy.

12. Discuss laparoscopic management of acute abdomen. *Tripura University 2025; WBUHS 2010*

Introduction

The acute abdomen is characterized by the sudden appearance of abdominal complaints that oblige the surgeon to decide promptly whether to operate immediately to treat conservatively or to observe the patient.

Possibilities for Initial Diagnosis of the Acute Abdomen

Localized peritonitis

- Acute cholecystitis
- Acute appendicitis (right lower abdomen)
- Acute diverticulitis

Generalized Peritonitis of Unknown Origin

- *Peritonitis by perforation:*
  - Perforated gastroduodenal ulcer
  - Perforated acute diverticulitis (colon sigmoid)
  - Small intestinal perforation (typhoid and trauma)
- *Intestinal obstruction*

JAYPEE BROTHERS

Role of Laparoscopic Procedure in Different Causes of Acute Abdomen

- Percutaneous transhepatic cholecystostomy is a valuable and effective procedure in a high-risk group of patients with acute cholecystitis.
- Early laparoscopic cholecystectomy is the treatment of choice in patients with acute cholecystitis with acceptable risk.
- Helical CT or an USG will resolve the diagnosis in many patients with right iliac fossa.
- All patients suspected of acute appendicitis should have an USG. Patients will be clinically divided in equivocal and unequivocal appendicitis.
- Unequivocal clinical diagnosis plus positive USG will require diagnostic laparoscopy followed by laparoscopic appendicectomy.
- Unequivocal clinical diagnosis plus negative USG will lead to clinical observation. Helical CT should be done to exclude other diagnoses. If the clinical condition worsens, a diagnostic laparoscopy should be performed.
- An equivocal clinical diagnosis will lead to clinical observation. If local peritonitis develop, a diagnostic laparoscopy should be performed.
- Diagnostic laparoscopy should be performed in all patients with signs of generalized acute abdomen in whom no clear cause is suspected after clinical, radiological, and laboratory investigation. A correct diagnosis will dictate the right surgical approach.
- Laparoscopic closure of perforated duodenal ulcer, in experienced hands, confers superior short-term benefits in terms of postoperative pain and wound morbidity.
- Laparoscopic lavage and drainage in the acute management of perforated acute diverticulitis are a promising alternative to more radical procedures.
- Laparoscopy is an effective procedure for the treatment of acute small bowel obstruction with acceptable risk of morbidity and early recurrence, but conversion rates of 30–40% should be expected.

13. Laparoscopic versus conventional surgery in pregnancy. *WBUHS 2015*

Introduction

- The advantages of laparoscopic surgery are similar for pregnant and no pregnant women; nevertheless, this procedure had been avoided during pregnancy because of concerns that it may be harmful to the fetus.
- *Potential concerns include:*
  - The rise in IAP during pneumoperitoneum could decrease uteroplacental blood flow and result in fetal hypoxia.
  - Fetal acidosis could develop from absorption of CO_2.
  - The fetus could be injured directly or indirectly if the uterus is perforated by a trocar or Veress needle.
  - Uterine perforation may result in preterm premature rupture of the membranes and preterm delivery.

Advantages of laparoscopy in pregnancy	*Risk of laparoscopy in pregnancy*
Short hospital stay	More chance of uterine injury during port enters as uterus becomes an abdominal organ after first trimester
Early return to normal activities	Problems associated with pneumoperitoneum
Small incision, so rapid postoperative recovery and less incision complications such as hernia, postoperative wound infection, and pain	CO_2 absorption causes increase CO_2 pressure and decrease arterial PH
Less uterine manipulation and hence decrease uterine irritability and fetal loss	Risk of exposure to intra-abdominal smoke including carbon monoxide generated by electro surgery and LASER

Strategies for Safe Laparoscopic Surgery in Pregnancy

- Surgery should be done in second trimester.
- If patient presents in late third trimester, surgery should be postponed if possible until after delivery.

JAYPEE BROTHERS

- Nasogastric incubation is a must in all case as there is a high-risk aspiration into the lungs.
- Patient can be placed in dorsal lithotomy position in the first half of pregnancy, but in second half to prevent inferior vena cava compression patient is ideally placed in lateral recumbent position.
- Hypotension should be avoided; proper fluid replacement should be done.
- Ideal method for commencing pneumoperitoneum is open Hasson trocar method. Placement of trocar depends on the size of gravid uterus.
- Tocolysis is indicated if signs of uterine irritability are present.
- Decrease operation time by using adequate number of ports, and using most experienced surgeons.
- Maternal hyperventilation to maintain $ETCO_2$ pressure at 32 mm Hg.
- Lower CO_2 insufflations pressure of <12 mm Hg should be used to avoid fetal acidosis.
- Electrocautery should be used with care; the smokes containing carbon monoxide should be evacuated promptly to avoid toxic effect to fetus.
- Entry of all instruments must be under direct vision; care should be taken to avoid injury to the gravid uterus.
- All specimens should be removed with endobag to avoid spillage.
- Manipulators should never be fixed to vagina or cervix.

Society of American Gastrointestinal Endoscopic Surgery (SAGES) Recommendations

- Obstetrical consultation should be obtained preoperatively.
- When possible, operative intervention should be deferred until the second trimester, when fetal risk is lowest.
- Pneumoperitoneum enhances lower extremity venous stasis already present in the gravid patient and pregnancy induces a hypercoagulable state. Therefore, pneumatic compression devices should be utilized whenever possible.
- Fatal and uterine status, as maternal $ETCO_2$ and/or arterial blood gases, should be monitored.
- The uterus should be protected with a lead shield if intraoperative cholangiography is a possibility.
- Fluoroscopy should be utilized selectively.
- Given the enlarged gravid uterus, abdominal access should be attained using an open technique.
- Dependent positioning should be utilized to shift the uterus away from the inferior vena cava.
- Pneumoperitoneum pressures should be kept at 10 mm Hg.
- Future studies into methods that increase the safety of laparoscopy in pregnant patient should be done.

LIMITATIONS OF MINIMAL ACCESS SURGERY AND ACCESS COMPLICATIONS

14. Limitations of minimal access surgery. *WBUHS 2022, MAMC 2022*

Surgeons performing laparoscopy should be aware of some special considerations unique to this technique:

- The surgical field is a three-dimensional (3D) space, but most laparoscopes project an image onto a traditional two-dimensional monitor, creating limited depth perception for the surgeon.
- Most laparoscopic instruments can rotate around their long axis, and some may have some degree of articulation at the instrument tip, but they have significantly limited dexterity compared to the human hand and wrist.
- In addition, laparoscopic instruments can transmit some haptic input through the instrument shaft and handle to the operator's hand, but much of the haptic feedback that is central to appropriate tissue handling in open operations is lost during laparoscopy.
- Minimally invasive surgery requires specialized high-end medical equipment.
- Surgeons need specialized training.
- The equipment used with MIS is more expensive.
- There are various procedures, especially the most recent surgeries that may take longer.

JAYPEE BROTHERS

15. Access complications. *WBUHS 2022*

Introduction

- Complications of abdominal access can occur, particularly during blind portions such as Veress needle or blind trocar insertion, including visceral or vascular injuries.
- If bowel contents or blood is aspirated during Veress insertion, the needle should be withdrawn and reinserted and laparoscopic access should proceed.

Complications

- Upon entry into the abdomen, bowel, or other injured organs should be examined and managed per established protocols for traumatic injury to intraperitoneal organs. Veress needle stick to intraperitoneal viscera should prompt close inspection, but in many cases may need only a simple repair or no intervention at all.
- Inadvertent intraluminal insufflation of the bowel with the Veress needle, however, can cause significant injury requiring bowel resection.
- The retroperitoneum should also be closely examined on abdominal exploration, particularly in situations where blood was encountered on initial Veress insertion.
- A stable hematoma in the mesentery or lateral retroperitoneum can usually be observed. However, central or rapidly expanding hematomas require exploration of the retroperitoneum.
- *Trocar insertion can cause injuries far more severe than Veress insertion:*
  - Bowel and visceral injuries should be considered penetrating traumas and managed accordingly, and any central or rapidly expanding retroperitoneal hematoma should be explored.
  - If a rush of blood is encountered on trocar insertion or open cannula placement, the surgeon must assume that a critical vascular injury has occurred and conversion to open must be performed immediately (without yet removing the trocar, which may be partially tamponading the injury).
- Abdominal wall hemorrhage is a common complication of laparoscopic surgery that may be caused by injury to the epigastric arteries, veins, or their tributaries.
  - These are often self-limited and cease with the tamponading effect of the port.
  - If this fails to control the bleeding, control may be attempted using electrosurgical energy or with a transfascial suture.

NOTES AND HALS

16. NOTES. *WBUHS 2014*

- *Natural orifice transluminal endoscopic surgery (NOTES)* is an experimental surgical technique whereby "scarless" abdominal operations can be performed with an endoscope passed through a natural orifice (mouth, urethra, anus, etc.) then through an internal incision in the stomach, vagina, bladder, or colon, thus avoiding any external incisions or scars.
- Portions of the gastrointestinal tract such as the stomach and colon commonly examined with endoscopy (such as for colon cancer screening) also reside in the peritoneal cavity. Perforation (inadvertent puncture creating a hole) of the gastrointestinal tract has been traditionally considered an undesirable event. Interventions using NOTES, however, intentionally perforate the stomach, bowel, or vagina, thereby allowing the operator to access the peritoneal cavity using a normal body orifice as a conduit. Here, any peritoneal structure is theoretically approachable.
- As an example, in natural orifice surgery the gallbladder might be removed through the mouth. The doctor would insert a tube down the esophagus, make a small incision in the stomach wall to gain access to the abdominal peritoneal cavity and take the gallbladder out by the same route. Potential advantages of the NOTES technique include reduced postoperative pain, shortened recovery times, and improved cosmesis (lack of surgical incision scars).

JAYPEE BROTHERS

- A range of procedures might be performed this way, such as GBP, fallopian tube ligation, removal of the ovaries, and diagnostic work. Some operations might be done via the rectum, vagina, urethra, or bladder as well. Because NOTES is so new, research generally has been confined to animals, mainly pigs. Recently, however, human studies have emerged that report the procedures to be feasible. Further studies involving a variety of NOTES procedures, under close supervision by medical experts and Institutional Review Boards, are being performed. The first multicenter human clinical trial in the US is currently underway.
- The last surgical innovation with such radical changes was laparoscopic surgery which was introduced in the late 1980s. Laparoscopic surgery was initially associated with an increased rate of specific complications which threatened to discredit the technique at that time. As a result, extensive research regarding safety measures was conducted in the following years. Laparoscopy is a mature technique today and is the standard procedure for many abdominal operations.

18. HALS (hand-assisted lap surgery). *WBUHS 2011*

Introduction

- Hand-assisted laparoscopic surgery is an alternative laparoscopic approach in which a mini-laparotomy is planned and performed to enable the surgeon to introduce his or her hand while the pneumoperitoneum is maintained and the dissection maneuvers are performed under video-endoscopic control.
- The insertion of the hand restores the tactile feeling and the sensation of depth, and facilitates the exposure, traction, and retraction maneuvers during the procedure.

HALS Devices

- The simplest way to perform HALS is to insert the hand through a mini-laparotomy performed for that purpose.
- However, it is difficult to keep the seal tight and to avoid loss of gas; in addition, the movements of the arm and the hand are limited.
- Three different devices are available for HALS.
- One type is a glove fixed to a circular platform that adheres to the surface of the skin, around the incision. This device has the drawback of requiring adherence to the skin, which must be well prepared; adhesive substances are needed, and the device itself is easily lifted from the skin by the wound fluid.
- There are also devices with two elements (Hand Port; Smith and Nephew, London, England). The inflatable circular base adapts to the inner contour of the abdominal wall wound and is attached to a sleeve that is fixed to the surgeon's arm, which allows the insertion and withdrawal of the hand. This device is comfortable and easy to install.
- Third, there are single-piece devices that adapt to the inner contour of the wall incision and permit the interchange of hand insertion, either mechanically (LapDisc; Hakko-Medical, Tokyo, Japan) or by inflation (Omniport; Advanced Surgical Concepts, Dublin). Some special surgical instruments have been designed for HALS. These instruments may help some delicate steps of surgical procedures such as those used in splenic or kidney vessel dissection.
- A procedure derived from HALS is finger-assisted LS (fingerscopy). By introducing a finger through a trocar wound the surgeon can free adherences or palpate and identify structures in situations such as appendectomy.

Advantages

- The obvious advantage of HALS is that it recovers the tactile feeling and improves hand-eye coordination despite the fact that the operation is performed under videoscopy.
- The recovery of tactile feeling shortens certain dissection maneuvers, avoids unnecessary movements, favors the smooth traction and exposure of structures, and facilitates the control of unexpected or difficult situations such as hemorrhage or the handling of a voluminous or adherent specimen.
- All of these advantages enhance the efficiency of the endoscopic procedure.

JAYPEE BROTHERS

Disadvantages

- The main drawback of HALS is that it requires an additional incision, thus increasing trauma. For this reason, the best indications are those that involve the performance of a mini-laparotomy to extract the specimen.
- The HALS technique requires a new operative strategy to capitalize on the presence of the hand being inside the abdomen, and the scope and the trocars must be correctly placed.
- Furthermore, the hand takes up space inside the abdomen and may hamper certain maneuvers, particularly if the patient is thin or if the surgeon's hand is large.
- Hand-assisted laparoscopic surgery may also induce hand fatigue in long or complicated procedures.

Election of Incision Site for Placement of the HALS Device

- The choice of incision site is likely to depend on whether the intra-abdominal hand is the surgeon's or the assistant's.
- If it is the surgeon's, the nondominant hand is used; if it is the assistant's, the dominant hand is used. If it is the surgeon's hand that is introduced, it should not impair visual field of the scope, so as to permit adequate triangulation over the target organ manipulated by the hand.
- In addition, the hand should not be placed over the structure to be dissected because this may impair the manipulation of the organ.
- When the procedure includes an accessory incision to extract the specimen (e.g., in splenectomy for splenomegaly) or to perform the anastomosis (e.g., in colectomy), the hand may be introduced through the anatomical site at which the incision is performed.
- If it is the assistant who introduces the hand, the accessory incision may be made far away from the introduction points of the operative trocars (Pfannenstiel incision).
- In some situations, the incision should be made in a multifunctional site (for instance, in the periumbilical midline, for a subtotal colectomy).

Indications

- Hand-assisted laparoscopic surgery has been applied in many clinical situations, and its safety and efficacy have been amply demonstrated.
- HALS definitely facilitated the procedure (58% of the surgeons considered that HALS reduced operation time and 88% that the intra-abdominal hand was helpful). Furthermore, immediate postoperative evolution was similar to conventional LS procedures. This suggests that HALS maintains the advantages of LS.
- *Hand-assisted laparoscopic surgery should be considered a priori as an aggressive surgery because:*
  - It requires a mini-laparotomy incision at the beginning of the procedure.
  - This incision is stretched by the HALS device.
  - The area of manipulation and traction is greater than in other procedures that use 5- to 10-mm instruments.

Laparoscopic Procedures Performed with Hand-assisted Laparoscopic Techniques

Stomach and esophagus	***Hepatobiliary and pancreas***	***Colorectal***	***Other operations***
Transhiatal esophagectomy	Hepatectomy	Colorectal cancer	Splenectomy for massive splenomegaly
Preparation of gastric tube	Cryoablation liver metastasis	Colonic polyps	Staging hematological diseases
Nissen fundoplication paraesophageal hernia	Living-donor nephrectomy	Diverticulitis	Adrenalectomy exeresis retroperitoneal tumor
Partial or total gastrectomy	Distal pancreatectomy	Crohn disease	Nephrectomy
Gastric bypass	*Pancreatoduodenectomy*	Rectal prolapse	Vertebral fusion aortobifemoral bypass

JAYPEE BROTHERS

Conclusion

- Hand-assisted laparoscopic surgery may be an interesting alternative to conventional laparoscopic splenectomy (LS) or open surgery.
- It simplifies the performance of difficult procedures for experienced surgeons and can initiate less experienced surgeons in advanced LS.
- Comparative trials with well-established laparoscopic techniques are required to define the absolute advantages of HALS.
- However, it may well be a useful resource before conversion to open surgery now that it has been demonstrated that it maintains the advantages of LS.

ROBOTIC SURGERY

19. Enumerate various robotic platforms available for use in surgery. Discuss the components of Da Vinci robotic system. ***AIIMS, Patna 2025***

Various Robotic Platforms Available for Use in Surgery

Here is a non-exhaustive list of major robotic surgical systems currently in clinical use or advanced development (as of 2025). These platforms span general surgery, orthopedics, neurosurgery, and other specialties:

- *da Vinci surgical system* (intuitive surgical)
  - Dominant platform for minimally invasive soft-tissue surgery.
  - *Applications:* Urology (prostatectomy), gynecology (hysterectomy), general surgery (colorectal), cardiothoracic, head and neck.
  - *Generations:* da Vinci Xi (latest multiport), da Vinci SP (single-port), da Vinci 5 (2024 release with enhanced haptics, AI integration, and ion endoluminal system).
- *Senhance surgical system* (Asensus surgical, formerly transenterix)
  - Digital laparoscopy with haptic feedback and eye-tracking camera control.
  - *Applications:* General surgery, gynecology, urology.
  - *Key differentiator:* Reusable instruments and lower cost per procedure.
- *Versius surgical system* (CMR surgical)
  - Modular, portable robotic arms on individual biomimetic trolleys.
  - *Applications:* General surgery, gynecology, urology (especially in Europe and emerging markets).
  - *Advantages:* Small footprint, rapid setup, cost-competitive.
- *Mazor X Stealth edition* (Medtronic)
  - Spine and brain surgery navigation + robotic arm for pedicle screw placement.
  - Integrates with StealthStation navigation.
- *ROSA (Robotic Surgical Assistant)* (Zimmer Biomet)
  - Used in knee arthroplasty (ROSA Knee) and neurosurgery (ROSA Brain).
  - Provides haptic guidance and intraoperative planning.
- *ExcelsiusGPS (Globus Medical):* Spine surgery robot with real-time navigation and rigid robotic arm.
- *MAKO SmartRobotics* (Stryker)
  - Orthopedic surgery (hip, knee, partial knee replacement).
  - Combines 3D planning, AccuStop haptic feedback, and robotic arm.
- *Ion endoluminal system* (Intuitive Surgical)
  - Shape-sensing robotic bronchoscopy for lung biopsy.
  - Catheter-based, reaches peripheral lung nodules.
- *Monarch platform* (Johnson & Johnson/Auris Health)
  - Robotic bronchoscopy and urology (ureteroscopy).
  - Electromagnetic navigation + robotic control.

JAYPEE BROTHERS

- *Vicarious surgical system* (Vicarious Surgical)
  - Miniaturized humanoid robots inserted through a single incision.
  - 9-DoF arms, 3D HD vision; in clinical trials (FDA clearance pending).
- *MicroPort MedBot – Toumai* (China): Laparoscopic robot similar to da Vinci; approved in China and expanding globally.
- *Revo-i* (Meere Company, South Korea): Cost-effective da Vinci alternative; used in Asia.
- *Avatera* (Avatera Medical, Germany): Single-use instruments, compact design; CE-marked in Europe.
- *Hugo RAS* (Medtronic): Modular soft-tissue robot; received CE mark and in U.S. clinical trials.
- *Hinotori* (Medicaroid/Kawasaki, Japan): First Japan-made surgical robot; approved in Japan.

Components of the da Vinci Robotic System (Focus on da Vinci Xi/X/5)

The da Vinci system consists of *three primary subsystems*:

I. *Surgeon console (Master Controller)*
- Ergonomic-seated workstation.
- *Components*:
  - *Master controllers* (two hand grips with 7-DoF + grip).
  - *Footswitch clutch panel* (camera control, instrument clutch, energy pedals).
  - *3DHD stereoscopic viewer* (dual 1080p displays, 10× magnification, immersive view).
  - *Touchpad* (system settings, telestration, UI).
  - *da Vinci 5 additions*: Integrated TruSense haptics, AI-guided tremor filtration, voice/gesture controls.

II. *Patient cart (Slave Robot)*
- Four articulated robotic arms mounted on a mobile base.
- *Components*:
  - *Arm 1–3*: Instrument arms (EndoWrist instruments with 7-DoF, 540° rotation).
  - *Arm 4*: Endoscope arm (0° or 30° 3DHD camera).
  - *Boom system*: Motorized positioning with collision avoidance.
  - *Instrument interface*: Quick-change couplers for sterile adapters.
  - *da Vinci 5*: Force-feedback actuators in arms, dynamic motion scaling.

III. *Vision Cart (Image Processing and Support)*
- Houses core electronics and peripherals.
- *Components*:
  - *Vision system*: Image processing unit, light source (xenon/LED), insufflator.
  - *24-inch touchscreen monitor* (for OR team).
  - *Core processor*: Synchronizes motion scaling, tremor filtration, and 3D rendering.
  - *EndoWrist instruments*: Portfolio of >90 reusable instruments (needle drivers, scissors, graspers, staplers, vessel sealers).
  - *Single-port (SP)*: Uses a 25-mm flexible port with four internal channels.

Additional System—Wide Features
- *Motion scaling* (1:1, 3:1, 5:1).
- *Tremor filtration* (6 Hz low-pass filter).
- *Firefly fluorescence imaging* (ICG dye for vascular/perfusion assessment).
- *Integrated OR table compatibility* (Trumpf, Maquet).
- *Skills simulator* (backpack module for training).
- *da Vinci Connect* (remote proctoring/telementoring platform).

JAYPEE BROTHERS

19. What are the advantages and limitations of robotic surgery compared to laparoscopic surgery?
WBUHS 2021 Supplementary; Ayush University, Chhattisgarh 2025

Introduction

Robotic surgery was associated with superior ease to laparoscopy in 8 of the 13 factors, including image quality, depth perception, comfort, eye fatigue, dexterity, precision of motion, speed of motion, and range of motion.

- The advantages of robotic surgery over conventional laparoscopic surgery are greater degree of movement, precise dissection, 3D vision, tremor filtration, and a shorter learning curve. The disadvantages are mainly the high cost and lack of haptic feedback.
- Absence of bespoke microsurgical instruments increases in operating time, and high costs associated with robotic-assisted provide a barrier to using such systems effectively for reconstructive microsurgery.

Aspects evaluated	*Robotic surgery*	*Laparoscopy*
Vision	Three dimensional	Two dimensional
Instrument manipulation	360°	Limited
Costs	Extremely high	Lower
Assembly	Extremely long	Faster
Ergonomics	Very good (like human wrist)	Poor
No. of ports	3	3 or more
Port diameter	8 mm	2 mm or more
Diffusion in clinical practice	Rare	In all surgical centers

20. Robotic surgery. ***WBUHS 2008***

Introduction

- Computer-assisted surgery, and robotically assisted surgery are terms for technological developments that use robotic systems to aid in surgical procedures.
- Robotically assisted surgery was developed to overcome the limitations of preexisting minimally-invasive surgical procedures and to enhance the capabilities of surgeons performing open surgery.

Comparison to Traditional Methods

- Major advances aided by surgical robots have been remote surgery, minimally invasive surgery and unmanned surgery.
- Due to robotic use, the surgery is done with precision, miniaturization, and smaller incisions; decreased blood loss, less pain, and quicker healing time.
- Articulation beyond normal manipulation and 3D magnification helps resulting in improved ergonomics.
- Due to these techniques, there is a reduced duration of hospital stays, blood loss, transfusions, and use of pain medication.
- The robot normally costs very high and while it is disposable supply cost is normally also very high per procedure, the cost of the procedure is higher.
- Additional surgical training is needed to operate the system.
- Surgeons report that, although the manufacturers of such systems provide training on this new technology, the learning phase is intensive and surgeons must operate on twelve to eighteen patients before they adapt.
- During the training phase, minimally invasive operations can take up to twice as long as traditional surgery, leading to operating room tie ups and surgical staffs keeping patients under anesthesia for longer periods.
- Patient surveys indicate they chose the procedure based on expectations of decreased morbidity, improved outcomes, reduced blood loss, and less pain.

JAYPEE BROTHERS

for detailed information on surgery books, visit our website www.ejaypee.com, for detailed information on surgery books, visit our website www.ejaypee.com, for detailed

Solved Papers Surgery for PG Students (Topic Wise)

In my short teaching career, I have seen that postgraduate students of surgery get little time in preparing the answers of theory paper. Besides, during their 3 years' training course, they do not appear in any theory examinations except in few institutions. It is also very difficult for them to write answers to long questions in brief. Nowadays, some questions have also started coming from recent advances and current journals which are not easy to answer for them as they are yet to come in textbooks. I have collected questions from different AIIMS, DNB examinations, different state health universities, and a major bulk from the West Bengal University of Health Sciences and grouped them according to chapters.

- So, in this book, I have tried to give an idea of point-wise answering of short notes and brief answering of long questions in a simple manner
- I also wanted to illustrate how to approach a clinical question in the theory paper
- I have also addressed the topics found only in journals.

I request all postgraduate students that they should use this book as a guide while referring to their textbooks in order to build up the answers on their own.



Arkaprovo Roy MS (General Surgery) did his schooling from one of the oldest schools of India, Hindu school. He graduated from Calcutta National Medical College, Kolkata and did his postgraduation from RG Kar Medical College, Kolkata, under the guidance of Professor Shibajyoti Ghosh (currently Professor and Head, Department of Surgery, Medical College, Kolkata) in 2010. He joined as an RMO-cum-Clinical Tutor in Calcutta National Medical College in 2011, later he appointed as an Assistant Professor in Malda Medical College. He then worked as an Associate Professor in Medical College Kolkata, which happened to be the oldest Medical College of Asia. Presently, he is Professor, Department of Surgery, North Bengal Medical College, Darjeeling, West Bengal, India. He went for Observership in Liver Transplant in Fortis Hospital, Noida, Uttar Pradesh, India under Dr Vivek Vij. He also sought training in Trauma Surgery. He has a keen interest in gastrointestinal surgery. He also enjoys teaching surgery. Currently, he is the Secretary of West Bengal State Chapter of Association of Surgeons of India.

Buy from ejaypee

JAYPEE BROTHERS

Shelving Recommendation
SURGERY

ISBN 978-93-7202-962-8

9 789372 029628