Ready Reckoner in Orthopedics



Vijay Kumar
Abdul Ghani

JAYPEE

JAYPEE BROTHERS

CONTENTS

1. **Introduction and History of Orthopedics** 1
   Abdul Maajid, Ashish Kumar, Abdul Ghani, Nikhil Kumar Sharma

2. **Basic Applied Orthopedic Sciences and Musculoskeletal Biology** 10
   Rifaaqat Ghani, Nusrat Jabeen, Saroj Sharma, Kashish Mahajan

3. **Biomechanics and Gait Analysis** 43
   Siva Srivastava Garika, Aman Koul, Aditya Chaubey, Mitin Pal Singh

4. **Principles of Diagnosis, Investigations, and Imaging in Orthopedics** 60
   Ashish Devgun, Sarita Dhankhar, Kartik Verma, Pratik Raj

5. **Musculoskeletal Tumors and Tumor-like Lesions** 95
   Love Kapoor, Pardeep Sharma, Tarkik Thami, Satinderpal Kaur

6. **Metabolic and Endocrine Bone Disorders** 133
   Sajal Maingi, Utkarsh Jain, Sandip Mahapatra

7. **Pyogenic Infections in Orthopedics** 163
   Akash Kumar Singh, Vijay Kumar

8. **Musculoskeletal Tuberculosis** 209
   Sumit Banerjee, Ritvik Sharma, Azhar Ud Din

9. **Rheumatology and Inflammatory Arthritis (Rheumatoid Arthritis, Systemic Lupus Erythematosus, Juvenile Idiopathic Arthritis, and Seronegative Spondyloarthropathies)** 230
   Sumit Banerjee, Abdul Ghani

10. **Crystal Arthropathies** 246
    Rehan Ul Haq, Ashish Kumar

11. **Osteoarthritis and Degenerative Joint Disease** 255
    Barkat Anwar Shah, Asif Nazir Baba

12. **Osteonecrosis and Osteochondroses** 267
    Rohit Rambani, Rojibul Islam, Rudradeep Choudhury

JAYPEE BROTHERS

13. Neuromuscular Disorders **283**
Samarth Mittal

14. Peripheral Nerve Injuries and Entrapment **300**
Shamim Ahmad Bhat, Subqat Farooq, Reyan Najmi, Aasim Maqbool

15. Spine **332**
Vivek Shankar, Nitin Chauhan

16. Shoulder **370**
Niaz Ahmed

17. Elbow **399**
RB Kalia, Kshitij Gupta, Ankit Gaurav

18. Wrist and Hand **438**
Abhimanu Kaith, Shriya Bhat, Khalid Muzzafar, Younis Kamal

19. Pelvis and Sacroiliac Joint **463**
Priti Ranjan Sinha, Mohd Afzal Khan, Shubham Jain

20. Hip **471**
Harsh Chauhan, Abhishek Bral, Sakib Arfee, Jay Sharma

21. Knee **494**
Tarun Goyal, Lakshmana Das S, Lokendra Singh

22. Foot and Ankle **523**
Prakash Kumar Prajapati, Binit Kumar

23. Pediatric Orthopedics **555**

Part A: Congenital Musculoskeletal Anomalies ***555***
Venkatesan Sampath Kumar, Jaiben George, Dilip Kumar Sankhwar, Puneet Yadav

Part B: Pediatric Noncongenital Musculoskeletal Disorders ***596***
Rashid Anjum, Gagandeep Singh, Abhishek Mahajan

24. Genetics and Skeletal Dysplasias **633**
Pankaj Kandwal, Harisha R, Sanchita Gupta

25. Geriatric Orthopedics **647**
Dev Kant, Prasun Karmakar, Dheeraj Singh Jamwal

26. Sports Orthopedics **661**
Amandeep Singh Bakshi, Tejpal Singh, Debjit Banerjee, Davinder Singh

JAYPEE BROTHERS

27. **Orthopedic Considerations during Pregnancy** 678
Bhat Jameel Mohd Jabbar

28. **Peripheral Vascular Disorders** 686
Vishal Verma, Ravi Kant Thakur, Anil Regmi

29. **Amputations and Disarticulations in Orthopedics** 699
Biswajit Sahu, Sachin Kudyar, Diptiranjan Sahoo, Sudhanshu Sekhar Panda

30. **Bone Grafting, Bone Substitutes, Biomaterials, and Metallurgy** 723
Rajesh Kumar Rohilla, Ashish Nehru, Pawan Jakhar, Pulkit Sharma

31. **Perioperative Orthopedics** 730
Heemanshu Bhat, Abhishek Bral, Farid Hussain

32. **Principles of Orthopedic Surgery** 749
Mukund Madhav Ojha, Qusai Ali, Denish Kumar Chandrakar, Mohammad Maaz, Afsal K, Ujwal HP

33. **Complications in Orthopedics: Prevention and Management** 779
Jujhar Singh, Vedant Bajaj, Arnav Harshit

34. **Pain Management in Orthopedics** 803
Ashish Kumar, Sonakshi Gupta

35. **Orthopedic Pharmacology** 816
Bhaarath KS, Kashish Mahajan, Shubham Pandoh

36. **Recent Advances in Orthopedics** 845
Arun K Sharma, Tushar Garg, Nayan Kharadi

37. **Principles of Rehabilitation and Physiotherapy** 874
Sukhil Raina, Deepali Gupta

38. **Research Methodology, Biostatistics, and Evidence-Based Orthopedics** 903
Mozam Hamid Wani, Tadeel Rashid, Pranveer Singh

39. **Miscellaneous and Nonspecific** 911
Naresh V, Abhai Singh Bhadwal, Ankita Khajuria

Index 941

JAYPEE BROTHERS

CHAPTER

4

Principles of Diagnosis, Investigations, and Imaging in Orthopedics

Ashish Devgun, Sarita Dhankhar, Kartik Verma, Pratik Raj

SECTION 1: INTRODUCTION

Accurate diagnosis in orthopedics requires a *stepwise and systematic integration* of:

- Detailed clinical history
- Thorough physical examination
- Appropriate laboratory tests
- Targeted imaging studies
- Invasive investigation

The aforementioned points will be discussed in detail in the sections to follow.

SECTION 2: HISTORY AND CLINICAL EXAMINATION

History

Detailed, Chronological Order, Symptom and Function Oriented

Physical Examination

Methodical, standardized, detailed, and comparative

Clinical Pearl

Always examine the joint above and below the affected site.

SECTION 3: LABORATORY INVESTIGATIONS

Laboratory Investigations in Orthopedics

Introduction

Laboratory investigations in orthopedics complement clinical assessment and imaging. They are essential for:

- Confirming or excluding infection
- Diagnosing metabolic and endocrine bone disorders
- Identifying systemic inflammatory conditions
- Assessing preoperative fitness
- Monitoring treatment progress

The process should avoid unnecessary tests, focusing on cost-effectiveness, safety, and patient comfort.

General (Baseline) Laboratory Tests (Table 1)

These are commonly ordered for most orthopedic patients, especially before surgery.

JAYPEE BROTHERS

TABLE 1: Common laboratory tests.

Test	Normal range	Orthopedic relevance
Complete blood count (CBC)	*Hb*: 13–17 g/dL (M), 12–15 g/dL (F)	Anemia (chronic disease, blood loss), leukocytosis (infection)
	WBC: 4,000–11,000/mm^3	↑ in infection, ↓ in marrow suppression
	Platelets: 150–400 × 10^3/mm^3	Thrombocytopenia in marrow disease or drug effect
Erythrocyte sedimentation rate (ESR)	<20 mm/h (M), <30 mm/h (F)	↑ in chronic infection, inflammation, tumors
C-reactive protein (CRP)	<5 mg/L	↑ in acute infection, it flares up in inflammatory arthritis
Random blood sugar/glycated hemoglobin (HbA1c)	<140 mg/dL/<6.5%	Perioperative glycemic control, infection risk prediction
Renal function tests	*Creatinine*: 0.6–1.3 mg/dL	• Dose adjustment for renally cleared drugs • For monitoring in cases of crush syndrome
Liver function tests	• AST/ALT < 40 IU/L • Albumin > 3.5 g/dL	• Preoperative safety, drug metabolism • Marker of nutritional status

Inflammatory and Infection-Related Tests

Erythrocyte Sedimentation Rate and C-Reactive Protein

- *Erythrocyte sedimentation rate (ESR)*: Slow to rise and fall; useful for chronic conditions (TB and RA) (nonspecific)
- *CRP*: Rises within 6–12 hours; normalizes quickly after resolution → better for acute monitoring.

Combined Use

- *High ESR + high CRP* → infection/inflammation likely.
- *High ESR + normal CRP* → chronic or low-grade inflammation.

Procalcitonin

- Marker for bacterial infection and sepsis.
- May support the diagnosis of systemic bacterial infection/sepsis; its role in diagnosing septic arthritis is adjunctive and it should not replace synovial fluid analysis and culture.

Synovial Fluid Analysis (Table 2)

Performed in suspected joint infection or crystal arthropathy.

Crystal Identification

- *Gout*: Needle-shaped, negatively birefringent under polarized light.
- *Calcium pyrophosphate dihydrate (CPPD)*: Rhomboid-shaped, weakly positive birefringent.

Other Advanced Techniques for Detection of Infection

- *Leukocyte esterase reagent (LER) strips, interleukin 6 (IL-6) assay, alpha-defensin test*—for rapid diagnosis of joint infections.
- *Sonication*—to study bacteria from biofilm, gives a better culture yield.
- *Matrix-assisted laser desorption/ionization-time of flight (MALDI-TOF)*: Rapid identification of bacteria and fungi from direct samples.

JAYPEE BROTHERS

TABLE 2: Analysis for synovial fluid.

Parameter	Normal	Septic arthritis	Inflammatory arthritis	Noninflammatory
Appearance	Clear	Turbid, purulent	Cloudy	Clear
WBC count	<200/mm^3	Often >50,000 cells/mm^3 with neutrophil predominance; lower counts do not exclude septic arthritis	2,000–50,000/mm^3	<2,000/mm^3
Neutrophils	<25%	>75%	50–70%	<25%
Gram stain/culture	Negative	Positive in 30–50%	Negative	Negative
Crystal analysis	None	None	Uric acid/CPPD	None

(CPPD: calcium pyrophosphate dihydrate; WBC: white blood cell)

TABLE 3: Investigations of parameters for various metabolic and endocrine bone diseases.

Test	Normal range	Interpretation in orthopedics
Serum calcium	8.5–10.5 mg/dL	↓ in osteomalacia, ↑ in hyperparathyroidism
Ionized calcium	1.1–1.3 mmol/L	More accurate physiological calcium status
Phosphate	2.5–4.5 mg/dL	↓ in hyperparathyroidism, ↑ in CKD
Alkaline phosphatase (ALP)	44–147 IU/L	• ↑ in high bone turnover (Paget's, fracture healing, osteomalacia) • Normally raised in children
25(OH) vitamin D	30–100 ng/mL	↓ in rickets/osteomalacia
Parathyroid hormone (PTH)	10–65 pg/mL	↑ in primary/secondary hyperparathyroidism
Thyroid function tests	*Thyroid-stimulating hormone (TSH)*: 0.4–4.0 mIU/L	Hyperthyroidism → osteoporosis

Metabolic and Endocrine Bone Disease Investigations (Table 3)

Bone Turnover Markers (Flowchart 1)

Uses

- Assess treatment response in osteoporosis.
- Evaluate abnormal bone metabolism in Paget's disease.

Autoimmune and Rheumatology Tests

See **Table 4**.

Tumor and Oncologic Workup

See **Table 5**.

Microbiology and Molecular Tests in Orthopedics

See **Table 6**.

Perioperative Laboratory Panel

Major Overtesting Statement

- Preoperative investigations should be individualized according to age, comorbidities, procedure and anesthetic requirements; routine universal testing is not required.
- Complete blood count (CBC), ESR, and CRP

JAYPEE BROTHERS

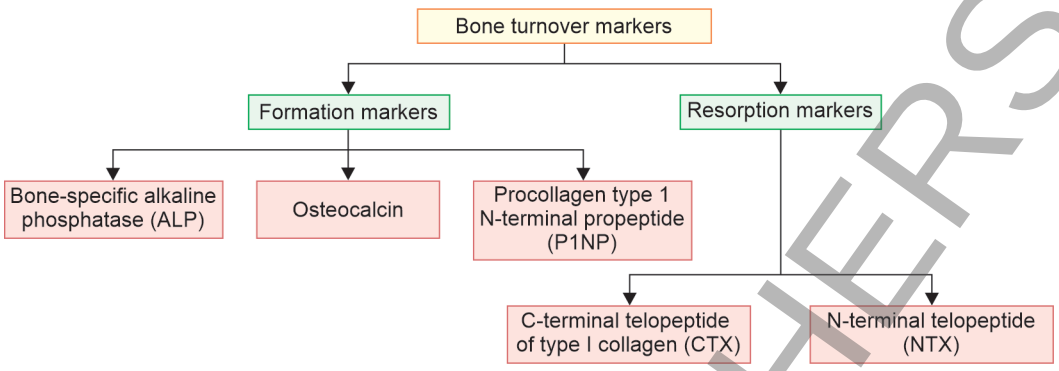

FLOWCHART 1: Bone turnover markers.

TABLE 4: Autoimmune and rheumatology tests.

Test	Indication
Rheumatoid factor (RF)	RA suspicion
Anti-CCP antibodies	*More specifically* for RA
ANA and Anti-dsDNA	SLE and connective tissue disease
HLA-B27	Ankylosing spondylitis, reactive arthritis
Complement C3/C4	Autoimmune activity monitoring

(Anti-CCP: anticyclic citrullinated peptide; HLA-b27: human leukocyte antigen B27; RA: rheumatoid arthritis)

TABLE 5: Tumor and oncologic workup.

Test	Use
LDH	Marker for *Ewing's sarcoma* prognosis
Serum/urine protein electrophoresis	*Multiple myeloma*
Beta-2 microglobulin	Myeloma prognosis
Tumor-specific markers	PSA for prostate CA (bone metastasis risk)

(CA: cancer; LDH: lactate dehydrogenase; PSA: prostate-specific antigen)

TABLE 6: Microbiology and molecular tests in orthopedics.

Test	Use
Culture and sensitivity	Osteomyelitis, septic arthritis
Biofilm disruption methods	Prosthetic joint infection
GeneXpert/CB-NAAT	Rapid TB diagnosis, rifampicin resistance
Line probe assay	MDR-TB
PCR for *Kingella kingae*	Pediatric septic arthritis

(CB-NAAT: Cartridge-based Nucleic Acid Amplification Test; MDR-TB: multidrug-resistant tuberculosis; PCR: polymerase chain reaction; TB: tuberculosis)

- Random blood sugar (RBS) and glycated hemoglobin (HbA1c)
- Renal/liver function tests
- Coagulation profile [prothrombin time/international (PT), international normalized ratio (INR), and activated partial thromboplastin time (aPTT)]
- Blood grouping and crossmatch
- Urinalysis [exclude urinary tract infection (UTI)]

Laboratory Investigation Protocols by Condition

See **Table 7**.

Key Clinical Principles

- Always interpret labs in the *clinical context*.
- Avoid overtesting—each result should have a potential impact on management.
- Repeat tests for *monitoring* trends rather than relying on a single value.

JAYPEE BROTHERS

TABLE 7: Laboratory investigation protocols by condition.

Condition	Essential tests	Special/Confirmatory
Suspected septic arthritis	CBC, ESR, CRP, joint aspiration (cell count, Gram stain, culture)	PCR (TB), PCT
Osteoporosis	Serum Ca, P, ALP, vitamin D, and PTH	DEXA scan (imaging)
Bone tumor	CBC, ESR, ALP, and LDH	Tumor markers, biopsy
RA	CBC, ESR, CRP, and RF	Anti-CCP and ANA
Chronic osteomyelitis	CBC, ESR, and CRP	Bone biopsy, culture
Paget's disease	ALP	Bone scan and bone turnover markers

[ALP: alkaline phosphatase; CCP: cyclic citrullinated peptide; CRP: C-reactive protein; DEXA: dual-energy X-ray absorptiometry (a type of scan); ESR: erythrocyte sedimentation rate; LDH: lactate dehydrogenase; PTH: parathyroid hormone; RA: rheumatoid arthritis; RF: rheumatoid factor]

Imaging

Conventional Radiography (X-ray)

Role in orthopedics

First-line imaging for most bone and joint pathologies.

The advantages and limitations of conventional radiography are discussed in **Table 8**.

TABLE 8: Advantages and limitations of conventional radiography.

Advantages	Limitations
Widely available	Poor soft-tissue visualization
Quick	Overlapping structures
Inexpensive	2D representation
Low radiation (compared to CT)	

Physics overview (Flowchart 2)

- *High-density tissues (bone)* absorb more → appear *white*.
- *Low-density tissues (air, fat)* absorb less → appear *dark*.

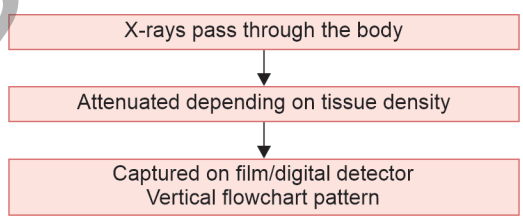

FLOWCHART 2: Physics overview of conventional radiography.

Indications in orthopedics

See **(Flowchart 3)**.

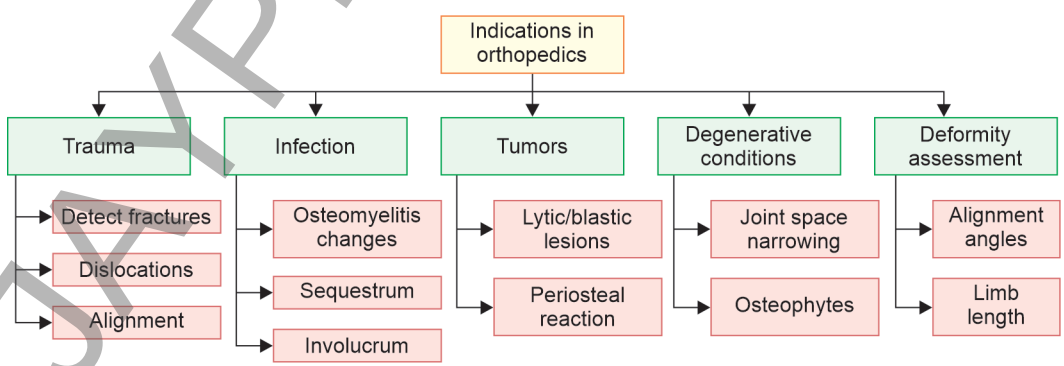

FLOWCHART 3: Indications in orthopedics.

Orthopedic X-ray views

See **Table 9**.

JAYPEE BROTHERS

TABLE 9: Orthopedic X-ray views.

Region	Standard views	Special views
Shoulder	Anteroposterior (AP), axillary, and scapular Y	Stryker notch, Zanca view
Elbow	AP, lateral	Radial head–Greenspan view
Wrist	PA, lateral	Scaphoid view
Hip	AP pelvis, cross-table lateral	Dunn's view, frog-leg
Knee	AP, lateral, skyline	Rosenberg, tunnel view
Spine	AP, lateral	Oblique, dynamic flexion–extension

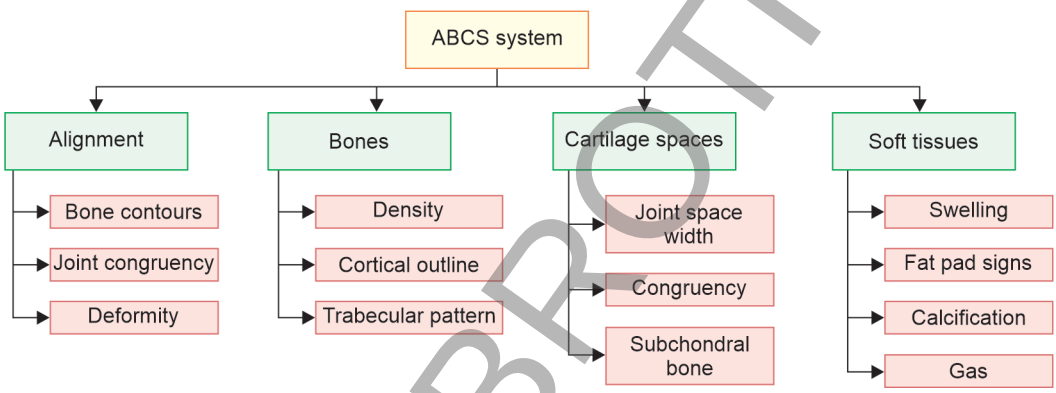

FLOWCHART 4: ABCS system interpretation.

Interpretation

ABCS system **(Flowchart 4)**.

Example:

- Knee X-ray in OA → ↓ medial joint space, osteophytes, subchondral sclerosis, cysts **(Fig. 1)**.

Limitations

- Fractures may be occult initially (e.g., scaphoid and stress fractures).
- Early infection and tumor may show a normal X-ray.

Pitfalls and tips

- Always order *at least two orthogonal views*.
- Compare with the contralateral side if in doubt.
- Repeat films in 10–14 days for suspected occult fracture.

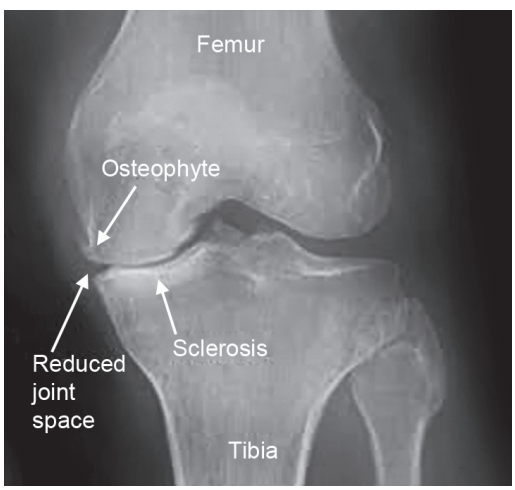

FIG. 1: X-ray of the knee joint to show osteoarthritic changes.

JAYPEE BROTHERS

Computed Tomography

Role in orthopedics

Computed tomography (CT) uses multiple X-ray beams with computer processing to produce cross-sectional images, often with three-dimensional (3D) reconstructions.

Advantages

- Excellent *cortical bone detail*.
- Precise *fracture mapping*.
- 3D reconstructions for surgical planning.
- Detects small cortical disruptions missed on X-ray.

Indications in orthopedics

- *Fractures*:
  - Complex intra-articular fractures (acetabulum, tibial plateau, and calcaneus).
  - Occult fractures (scaphoid, spine pedicle fractures).
- *Preoperative planning*:
  - Osteotomies.
  - Corrective surgery for deformities.
- *Bone tumors*: Assess cortical involvement, mineralization pattern.
- *Spinal pathology*: Bony canal stenosis, fracture classification.
- *Postoperative*: Assess implant position, union, fusion status.

Special orthopedic computed tomography applications

See **Table 10**.

Limitations

- Higher radiation than X-ray.
- Less soft tissue contrast than magnetic resonance imaging (MRI).
- Metal artifacts can obscure detail [reduced by metal artifact reduction (MAR) algorithms].

Interpretation tips

- Use *a bone window* for cortical/trabecular detail.
- Use *soft-tissue windows* to assess adjacent structures.
- Always correlate with plain radiographs.

Pitfalls

- Over-reliance without functional/clinical correlation.
- Misinterpretation of developmental variants as pathology.
- Failure to adjust slice thickness → missed subtle fractures.

TABLE 10: Special orthopedic CT applications.

Application	CT protocol	Advantage
Acetabular fractures **(Figs. 2A to C)**	Thin slices + 3D	Visualize fracture lines and roof impaction
Tibial plateau/distal radius fractures **(Figs. 3A to C)**	Thin coronal/sagittal	Assess depression and split
Spine trauma	Helical computed tomography (CT)	Canal compromise, fracture pattern
Tumor assessment	Bone algorithm	Matrix calcification, cortical breach
Foot and ankle	Multiplanar recon	Midfoot/hindfoot complex fracture
Polytrauma	Whole body CT	Rapid one-stop diagnosis
Chronic osteomyelitis	Bone assessment	Delineates the extent of the involucrum
Vascular injuries	CT angiography	Identifies the level of injury and collaterals

JAYPEE BROTHERS

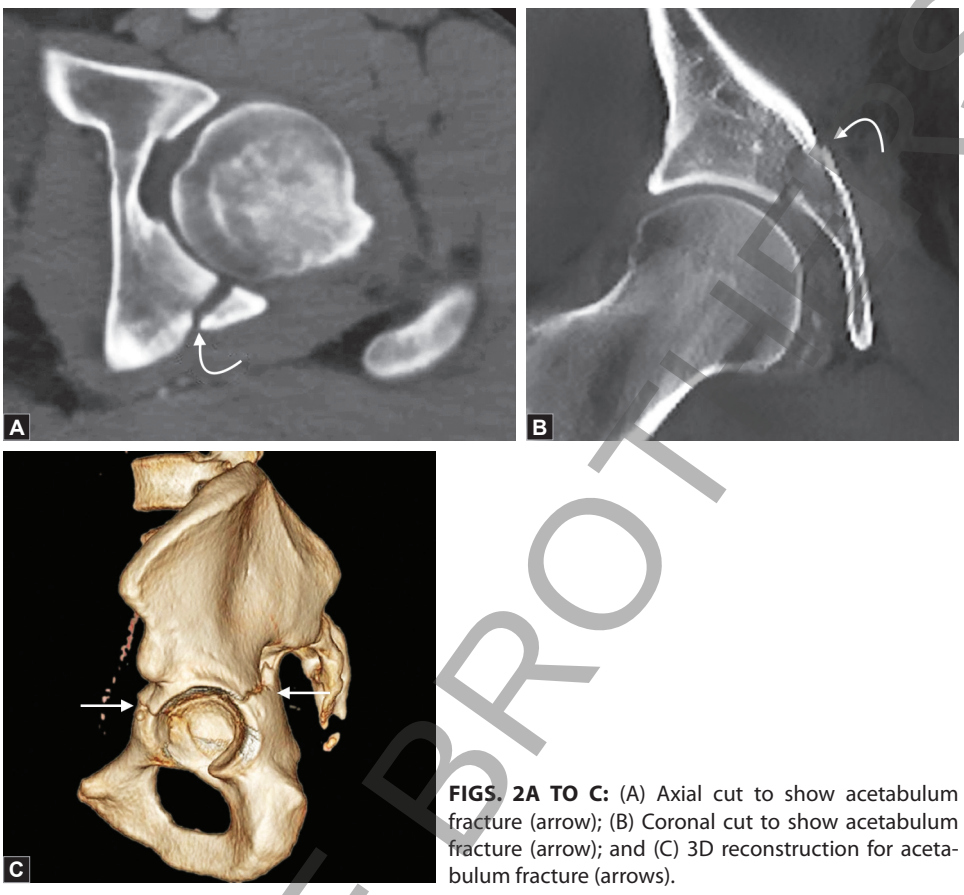

FIGS. 2A TO C: (A) Axial cut to show acetabulum fracture (arrow); (B) Coronal cut to show acetabulum fracture (arrow); and (C) 3D reconstruction for acetabulum fracture (arrows).

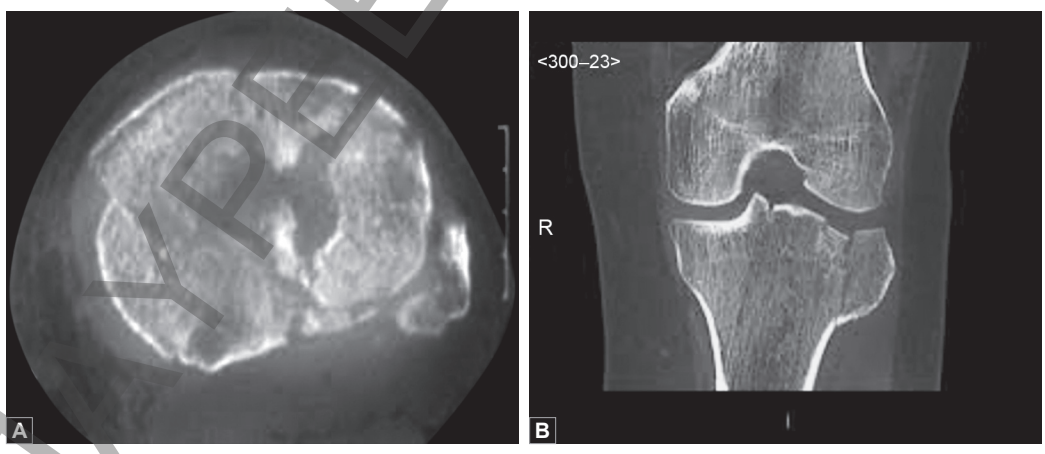

FIGS. 3A TO C: *Continued*

JAYPEE BROTHERS

Continued



FIGS. 3A TO C: (A) Axial cut to show proximal tibia fracture; (B) Coronal cut to show proximal tibia fracture; and (C) 3D Reconstruction for proximal tibia fracture.

MRI

Role in orthopedics

Magnetic resonance imaging is the gold standard for musculoskeletal soft-tissue imaging.

- *Principle*: It uses strong magnetic fields and radiofrequency pulses to produce detailed images *without ionizing radiation.*
- *Strengths*:
  - Excellent contrast for muscles, tendons, ligaments, cartilage, and bone marrow.
  - Multiplanar imaging (sagittal, coronal, axial) without repositioning.
  - Sensitive to early bone pathology before radiographic changes appear.

Physics in brief

See **Flowchart 5**.

Common sequences and their uses

See **Table 11**.

Indications in orthopedics

- *Trauma*:
  - Occult fractures (scaphoid, femoral neck, and stress fractures).

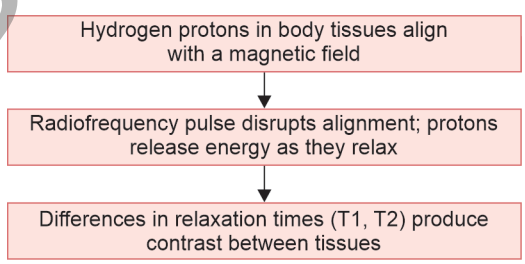

FLOWCHART 5: Brief physics of magnetic resonance imaging (MRI).

TABLE 11: Common sequences and their uses.

Sequence	Appearance	Orthopedic application
T1-weighted	Fat bright, *water dark*	Anatomy, marrow replacement
T2-weighted	*Water bright*, fat intermediate	Edema, inflammation
Proton density (PD)	Intermediate signal	Meniscus, cartilage
Short tau inversion recovery (STIR)	Fat suppressed, *water bright*	Marrow edema and occult fractures
Fat-saturated T2	Fat suppressed, *fluid bright*	Soft tissue and joint effusions
Gradient echo (GRE)	Sensitive to metal, hemorrhage	Cartilage defects, hemosiderin
Contrast-enhanced (gadolinium)	Highlights vascular lesions	Tumors, infection (tuberculosis)

JAYPEE BROTHERS

- Bone marrow edema in contusions.
- Ligamentous injuries [anterior cruciate ligament (ACL), posterior cruciate ligament PCL, and collateral ligaments].
- Meniscal tears (knee).
- Rotator cuff tears (shoulder).

- *Degenerative disorders*:
  - *Osteoarthritis*: Cartilage thinning, bone marrow lesions.
  - Intervertebral disc degeneration.
- *Infection*:
  - *Osteomyelitis*: Marrow signal changes before X-ray findings.
  - *Septic arthritis*: Joint effusion, synovial thickening.
  - *Spinal infections*: Discitis and epidural abscess.
- *Tumors*:
  - Benign versus malignant characteristics.
  - Marrow involvement, soft-tissue extension.
  - Prebiopsy mapping.
- *Miscellaneous*:
  - Avascular necrosis (AVN)—earliest detection.
  - Cartilage mapping [T2 mapping, delayed gadolinium-enhanced MRI of cartilage (dGEMRIC)].

Special Orthopedic MRI Techniques

See **Table 12**.

Contraindications

See **Table 13**.

Artefacts and pitfalls

- *Motion artefact*: Patient movement → blurring.
- *Metal artefact*: Orthopedic implants → signal void [reduced by MAVRIC (multiacquisition variable-resonance image combination) and SEMAC (Slice Encoding for Metal Artifact Correction) sequences].
- *Chemical shift*: Misregistration between fat and water signals.
- *Magic angle effect*: Increased signal in tendons at approximately 55° to the magnetic field—may mimic pathology.

TABLE 12: Special orthopedic MRI techniques.

Technique	Use
MR arthrography	Shoulder/labral tears, hip FAI
Diffusion-weighted imaging (DWI)	Tumor cellularity, abscess versus cellulitis
Functional MRI of muscles	Assess muscle activation patterns
Whole-body MRI	Metastasis screening, multiple myeloma
3D MRI cartilage mapping	Early OA detection, cartilage repair follow-up

TABLE 13: Contraindications.

Absolute	Relative
Absolute/major contraindication: Unsafe ferromagnetic intracranial/ocular foreign body or MR-unsafe device. Implanted cardiac/electronic devices require device-specific MR safety assessment and protocol	Claustrophobia (can be mitigated with an open MRI)
Certain metallic foreign bodies in the eyes	Non-MRI-conditional pacemakers
	Pregnancy (first trimester—avoid unless essential)

Interpretation tips:

- Always correlate MRI with plain radiographs.
- Review in multiple planes and sequences in a systematic method.
- Distinguish normal variants from pathology (e.g., meniscofemoral ligaments vs. meniscal tear).
- Compare with the contralateral side if needed.

Clinical box: MRI in orthopedic emergencies.

- *Suspected spinal cord compression*: Urgent MRI within hours.

JAYPEE BROTHERS

- *Suspected septic arthritis in a child*: Ultrasound is usually preferred for rapid detection of hip effusion and aspiration guidance; MRI is useful when osteomyelitis, deep infection or extent of disease needs evaluation.
- *Post-traumatic hip pain with normal X-ray*: MRI for occult fracture.

Examples of MRI in orthopedics

See **Figs. 4 to 6**.

Ultrasound (US) in Orthopedics

Overview

Musculoskeletal ultrasound (MSK US) is a real-time, dynamic, radiation-free imaging modality that uses high-frequency sound waves to visualize superficial and some deep

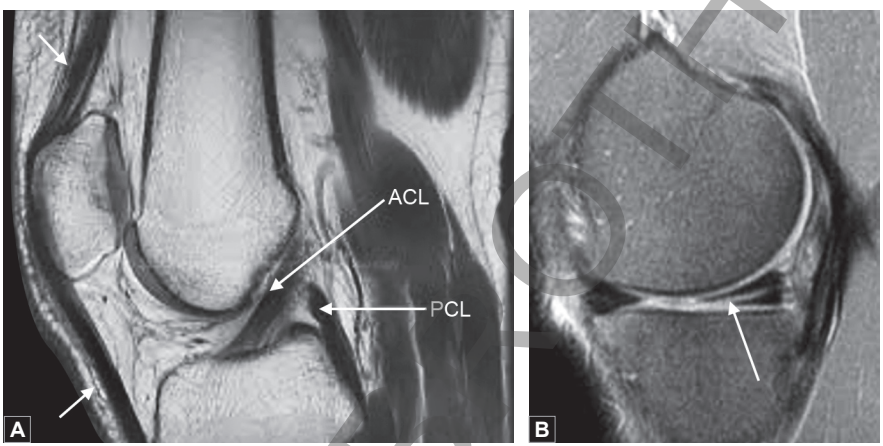

FIGS. 4A AND B: (A) Normal anatomy of the knee showing ACL and PCL and (B) Sagittal section of the knee showing a meniscus tear.

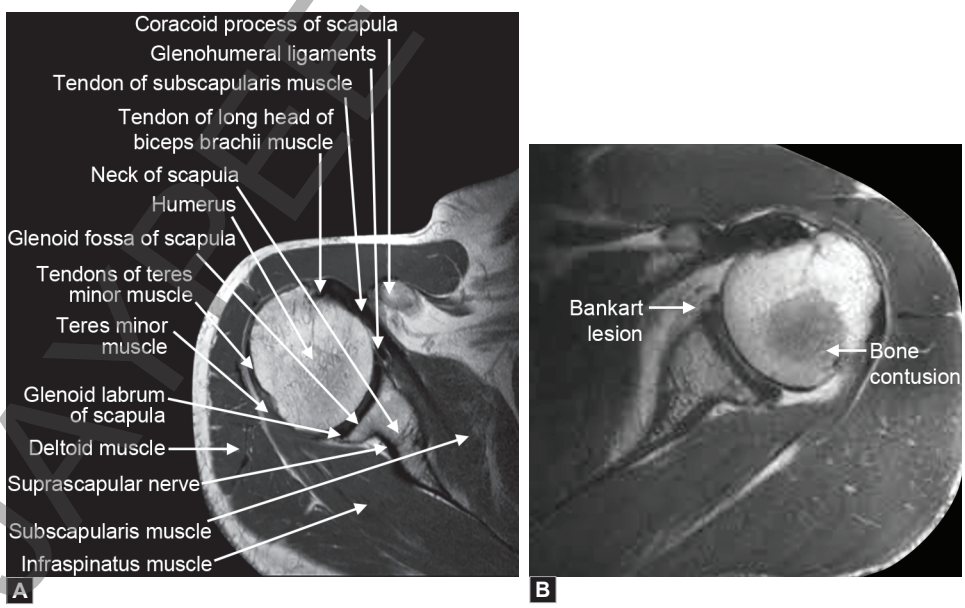

FIGS. 5A AND B: (A) Axial section of the shoulder; and (B) Axial section of the shoulder showing a Bankart lesion.

JAYPEE BROTHERS

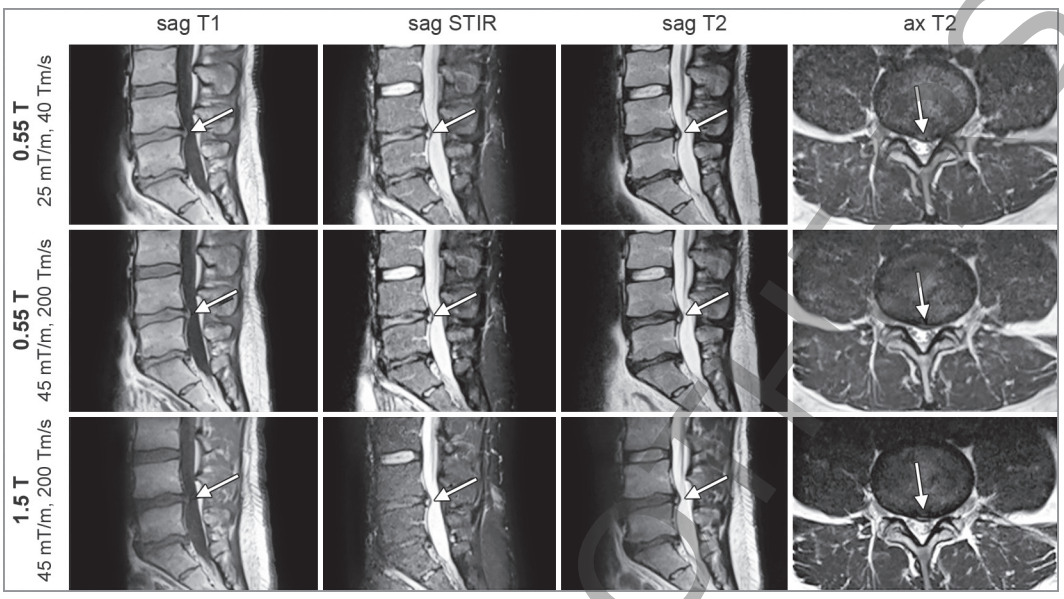

FIG. 6: Sagittal and axial sections of the lumbosacral spine in different magnetic resonance imaging (MRI) sequences.

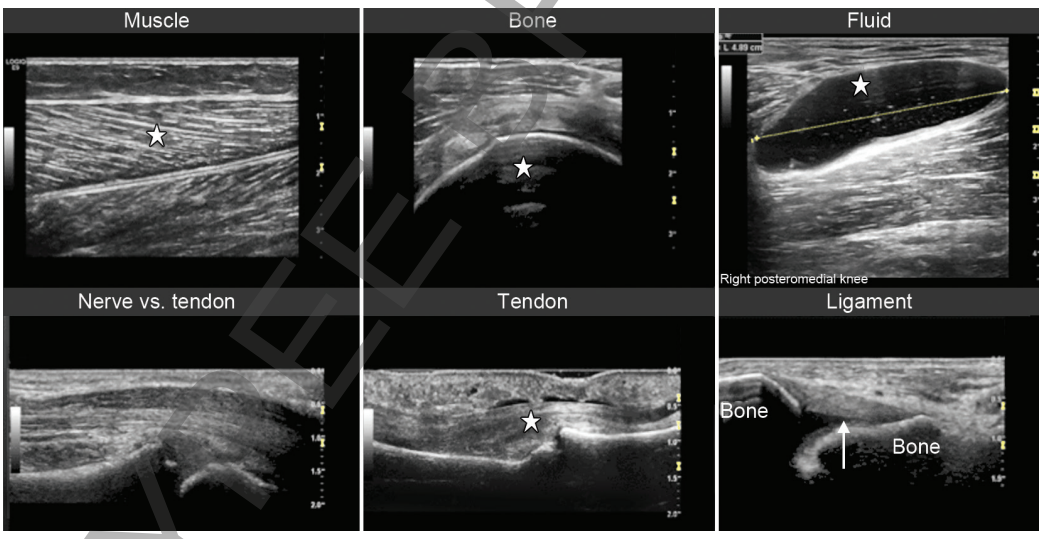

FIG. 7: To show different tissue appearances in ultrasound (US).

musculoskeletal structures. It is increasingly used in orthopedics for both diagnosis and guided interventions.

Physics in Brief

- *High-frequency transducers* (7–15 MHz) → better resolution but lower penetration.
- Ultrasound waves reflect differently from tissues of varying densities **(Fig. 7)**:
  - *Hyperechoic (bright)*: Bone cortex and calcification.
  - *Hypoechoic*: Muscle and tendon.
  - *Anechoic (dark)*: Fluid collections.

JAYPEE PROOFS

Advantages and Limitations of Ultrasound in Orthopedics

See **Table 14**.

Orthopedic Indications

Soft-tissue pathologies

See **Table 15**.

Joint pathologies

- Joint effusions (knee, shoulder, elbow, ankle).
- Synovitis (RA, psoriatic arthritis).
- Loose bodies (especially in superficial joints).
- Dynamic instability assessment.

TABLE 14: Advantages and limitations of ultrasound (US) in orthopedics.

Advantages	Limitations
Dynamic assessment: Can evaluate structures during movement	Operator-dependent → requires expertise
Real-time guidance: For aspirations, injections, biopsies	Poor penetration for deep structures (e.g., hip joint in adults)
No radiation: Safe in children, pregnant patients	Cannot visualize intraosseous lesions well
Portable: Bedside use, outpatient clinics	Limited in obese patients due to attenuation
Cost-effective: Lower cost compared to MRI	

TABLE 15: Orthopedic indications for soft-tissue pathologies.

Structure	Pathology detected
Tendons	Tendinitis, partial/complete tears (rotator cuff, Achilles, and patellar)
Ligaments	Sprains and partial tears (ankle ATFL and MCL)
Muscles	Strains and hematomas
Nerves	Entrapments (carpal tunnel—median nerve) and neuromas

(ATFL: anterior talofibular ligament; MCL: medial collateral ligament)

Trauma

- Hematomas, muscle tears.
- Detection of superficial foreign bodies.
- Guidance for fracture hematoma aspirations in suspected infection.

Infection

- Distinguish cellulitis versus abscess.
- Detect subperiosteal collections in children (early osteomyelitis).
- Guide aspiration of septic joints.

Tumors

- Evaluate superficial soft tissue masses.
- Differentiate cystic versus solid lesions.
- Guide biopsy.

Ultrasound-guided interventions

- Joint injections (e.g., shoulder, knee, and hip).
- Tendon sheath injections (de Quervain's and trigger finger).
- Cyst aspiration (ganglion cyst).
- Biopsy guidance.
- Percutaneous drainage of abscesses.

Technique and Tips

- *Patient positioning*: Optimized to expose structure and allow dynamic movement.
- *Transducer choice*:
  - High-frequency linear (7–15 MHz) for superficial structures.
  - Curvilinear (2–5 MHz) for deep structures (hip and pelvis).
- *Dynamic maneuvers*:
  - Shoulder abduction/adduction → rotator cuff impingement.
  - Knee valgus stress → medial collateral ligament (MCL) evaluation.
  - Ankle inversion → anterior talofibular ligament (ATFL) stability.

Artefacts in MSK Ultrasound (Table 16)

Specific orthopedic applications by region **(Table 17)**.

When to Prefer Ultrasound over MRI

- *Superficial soft-tissue lesions*.
- *Dynamic instability assessments*.

JAYPEE BROTHERS

TABLE 16: Artefacts in MSK ultrasound.

Artefact	Description	Clinical relevance
Anisotropy	Loss of tendon echogenicity when the beam is not perpendicular	May mimic tear; correct probe angle
Posterior acoustic shadowing	Behind the bone or calcification	Normal finding for cortical bone
Posterior acoustic enhancement	Increased echo behind fluid	Confirms cystic lesions

TABLE 17: Specific orthopedic applications by region.

Region	Ultrasound uses
Shoulder	Rotator cuff tears, biceps tendinitis, subacromial bursitis
Elbow	Lateral epicondylitis, triceps tendon tears
Wrist	Triangular fibrocartilage complex (TFCC) tears (limited), ganglion cysts, median nerve compression
Hip	Effusion detection (children), snapping hip syndrome
Knee	Effusion, Baker's cyst, and quadriceps/patellar tendon pathology
Ankle/foot	Achilles tendon tears, plantar fasciitis, and peroneal tendon subluxation

- *Bedside guided injections*.
- *Pediatric joint effusion detection* (e.g., transient synovitis vs. septic arthritis).

Clinical pearl: In children with hip pain, ultrasound can detect an effusion before X-ray or MRI changes appear, allowing urgent aspiration in septic arthritis.

ARTHROGRAPHY IN ORTHOPEDICS

Introduction

Arthrography is an imaging technique that involves the injection of contrast material (iodinated or gadolinium-based) into a joint space to enhance visualization of intra-articular structures. Traditionally performed using fluoroscopy, it has evolved with the advent of CT and MRI, becoming a dynamic diagnostic tool in musculoskeletal radiology. Arthrography allows direct assessment of joint capsules, ligaments, cartilage, labrum, and intra-articular bodies.

Historically, conventional (fluoroscopic) arthrography was a mainstay in diagnosing meniscal tears, rotator cuff injuries, and labral pathologies before the widespread availability of MRI. While its use has declined with advanced cross-sectional imaging, arthrography continues to hold specific indications, often in conjunction with CT and MRI (CT arthrography and MR arthrography).

Technique

See **Flowchart 6**.

Magnetic Resonance Arthrography

Indications

- *Shoulder joint*:
  - Labral tears [Bankart and superior labral anterior posterior (SLAP) lesions].
  - Rotator cuff tears (particularly partial-thickness and undersurface tears)
  - Postoperative evaluation (instability repair, cuff repair integrity)
- *Hip joint*:
  - Acetabular labral tears.
  - Femoroacetabular impingement (FAI) evaluation

JAYPEE BROTHERS

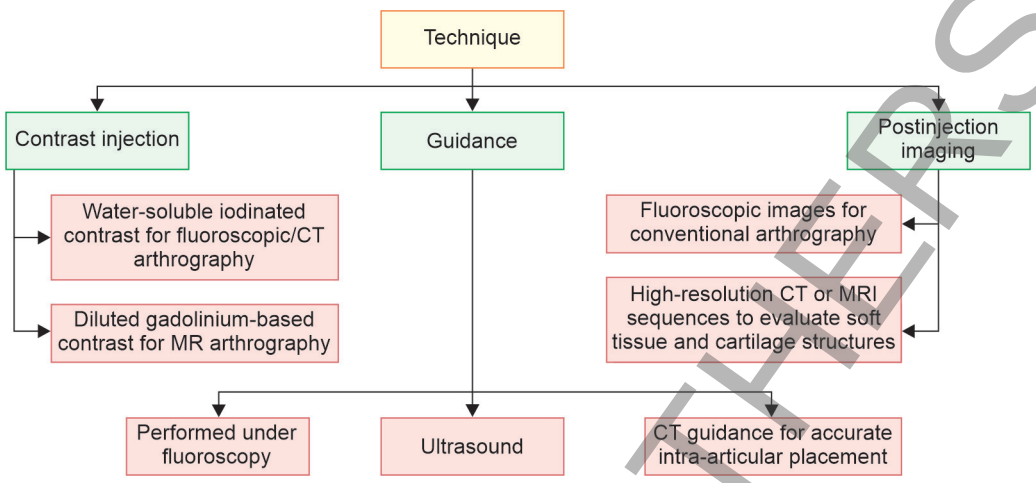

FLOWCHART 6: Technique of arthrography in orthopedics.
(CT: computed tomography; MR: magnetic resonance; MRI: magnetic resonance imaging)

  - Cartilage defects and early osteoarthritis
- *Wrist*:
  - Triangular fibrocartilage complex (TFCC) tears.
  - Intercarpal ligament injuries (scapholunate and lunotriquetral).
- *Knee*:
  - Meniscal tears (particularly recurrent tears postsurgery).
  - Cartilage evaluation (especially with CT/MR arthrography).
- *Elbow and ankle*:
  - Ligamentous injuries.
  - Loose bodies and osteochondral defects.

Current Role in Orthopedics

- *Declining role of conventional arthrography*: With MRI becoming the gold standard for most intra-articular pathologies, conventional fluoroscopic arthrography is now rarely used as a stand-alone test.
- *MR arthrography (MRA)*:
  - MR arthrography has high diagnostic accuracy for subtle labral and capsuloligamentous lesions and is particularly useful when conventional MRI is inconclusive.
  - Superior sensitivity and specificity compared to conventional MRI in subtle intra-articular lesions.
  - Provides detailed visualization of cartilage surfaces, ligamentous structures, and capsular abnormalities.
- *CT arthrography*:
  - Valuable in patients who cannot undergo MRI (contraindications, such as pacemakers, metallic implants, severe claustrophobia).
  - Provides exquisite detail of bony anatomy and cartilage defects.
- *Postoperative assessment*: Useful in detecting recurrent tears, integrity of surgical repairs, and evaluation in the presence of metallic hardware that may obscure MRI.
- *Interventional role*: Arthrography often precedes intra-articular therapeutic injections (steroids, viscosupplements, and biologics), ensuring accurate placement of medication.

JAYPEE BROTHERS

Advantages and Limitations of Magnetic Resonance Arthrography

See **Table 18**.

Future Perspectives

With the increasing refinement of high-resolution MRI and novel cartilage imaging techniques (T2 mapping, dGEMRIC, and T1rho), the role of arthrography is gradually shifting from first-line diagnosis to a *problem-solving tool*. It retains significance in evaluating subtle labral and ligamentous injuries, cartilage mapping in young athletes, and post-operative joints with hardware artifacts. The integration of *MR arthrography with 3D imaging* and *CT arthrography for preoperative planning in joint preservation surgeries* continues to maintain its clinical relevance **(Fig. 8)**.

TABLE 18: Advantages and limitations of MR arthrography.

Advantages	Limitations
• High diagnostic accuracy in certain conditions (labral and cartilage pathology)	• Invasive procedure with risk of pain, infection, bleeding, and contrast reactions
• Allows dynamic evaluation with joint movement under fluoroscopy	• Radiation exposure in fluoroscopic and CT-guided techniques
• Useful alternative when MRI is inconclusive or contraindicated	• Superseded by noninvasive MRI in most first-line diagnostic situations

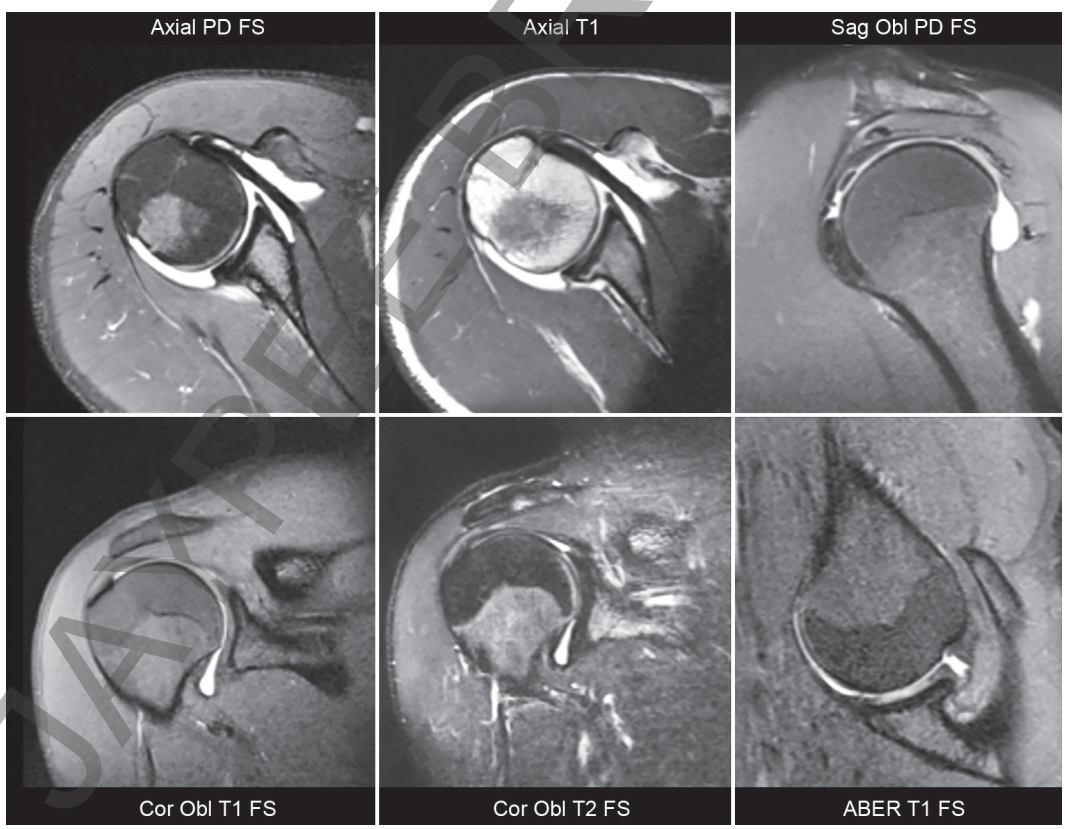

FIG. 8: To show different sections of a magnetic resonance (MR) arthrogram of the shoulder.

JAYPEE BROTHERS

DIGITAL SUBTRACTION ANGIOGRAPHY IN ORTHOPEDICS

Introduction

Digital subtraction angiography (DSA) is an imaging technique that digitally subtracts precontrast images from contrast-enhanced radiographs, allowing precise visualization of vascular anatomy. In orthopedics, while not a routine investigation, DSA plays an important role in selected scenarios involving vascular evaluation, trauma, tumors, and interventional procedures.

Historically, conventional angiography was used for vascular mapping before reconstructive procedures or to assess vascular injuries. DSA has replaced conventional angiography in most centers due to its *superior image quality, reduced contrast requirement, and real-time digital processing* **(Fig. 9)**.

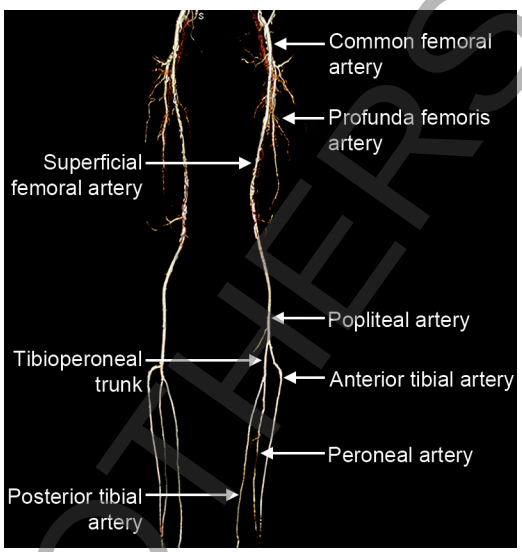

FIG. 9: To show the normal computed tomography (CT) angiography of the bilateral lower limbs.

Technique

See **Flowchart 7**.

Catheter-based injection of iodinated contrast medium into arterial or venous systems

↓

Sequential radiographs are acquired and processed to subtract background bone and soft tissue

↓

Allows clear delineation of vessels, stenosis, aneurysms, occlusions, or abnormal vascular blush

FLOWCHART 7: Technique of digital subtraction angiography (DSA) in orthopedics.

Computed Tomography Angiography

Indications in Orthopedics

- *Vascular trauma*:
  - Detection of arterial injuries associated with high-energy fractures/dislocations (e.g., knee dislocations with popliteal artery injury, supracondylar humerus fracture with brachial artery compromise).
  - Differentiation between arterial spasm and transection.
  - Helps guide emergency vascular repair or bypass grafting.
- *Bone and soft tissue tumors*:
  - Identification of feeding vessels of hypervascular tumors (e.g., osteosarcoma, giant cell tumor, and hemangioma).
  - Preoperative *tumor embolization* to reduce intraoperative bleeding.
  - Assessment of tumor vascularity and residual tumor post-treatment.
- *Chronic ischemia and limb salvage*:
  - Evaluation of peripheral arterial disease in diabetic foot or post-traumatic ischemia before orthopedic reconstructive surgery.
  - Planning microsurgical flaps and limb-salvage procedures.
- *Arteriovenous malformations (AVMs) and aneurysms*:
  - Diagnosis of AVMs and their feeder vessels in bone or soft tissue.
  - Preoperative embolization or endovascular treatment.

JAYPEE BROTHERS

- *Interventional applications*:
  - Therapeutic embolization in uncontrolled bleeding after pelvic/long bone fractures.
  - Selective intra-arterial chemotherapy (historically used in osteosarcoma before systemic regimens became standard).
  - Coil embolization or vascular stenting in trauma-related vascular injuries.

Current Role in Orthopedics

- *Decline in routine use*: With computed tomography angiography (CTA) and MRA now widely available, DSA is less frequently used as a diagnostic modality.
- *Reserved for intervention*: DSA remains the *gold standard for vascular interventions*, particularly in trauma, tumor embolization, and preoperative vascular planning.
- *Dynamic assessment*: Provides real-time functional evaluation of blood flow, unlike static CTA/MRA.
- *Adjunct to limb-salvage surgeries*: Particularly relevant in orthopedic oncology and complex trauma reconstruction.

Advantages and Limitations of Computed Tomography Angiography

See **Table 19**.

TABLE 19: Advantages and limitations of CT angiography/DSA.

Advantages	Limitations
High-resolution, real-time vascular imaging	Invasive procedure with risks (bleeding, thrombosis, pseudoaneurysm, contrast nephropathy)
Therapeutic and diagnostic roles in a single setting	Radiation exposure
Requires less contrast compared to conventional angiography	Superseded by CTA/MRA for first-line diagnosis in most centers

Future Perspectives

While CTA and MRA are increasingly first-line, *DSA continues to be indispensable as a therapeutic tool* in orthopedic oncology and vascular trauma. With advances in interventional radiology, techniques like *drug-eluting beads, embolization agents, and endovascular stents* are expanding their role in orthopedic practice, particularly in limb preservation.

NUCLEAR MEDICINE IMAGING IN ORTHOPEDICS

Nuclear medicine techniques provide *functional and metabolic information* about the musculoskeletal system, which is often complementary to anatomical imaging (X-ray, CT, and MRI).

They are particularly useful for *early detection* of disease before structural changes become apparent.

Basic Principles

- Involves the administration of a *radiopharmaceutical* (radioisotope + carrier molecule) that targets specific tissues.
- A gamma camera or PET scanner detects gamma rays emitted.
- The image represents *physiological activity* (blood flow, bone turnover, and metabolism).

Common Nuclear Imaging Modalities in Orthopedics

Bone Scintigraphy (Bone Scan) – Technetium-99m MDP

Mechanism

Tc-99m methylene diphosphonate binds to hydroxyapatite in bone, especially at sites of high turnover **(Figs. 10A and B)**.

Indications

- Detection of *bone metastases* (prostate, breast, and lung cancer).

JAYPEE BROTHERS

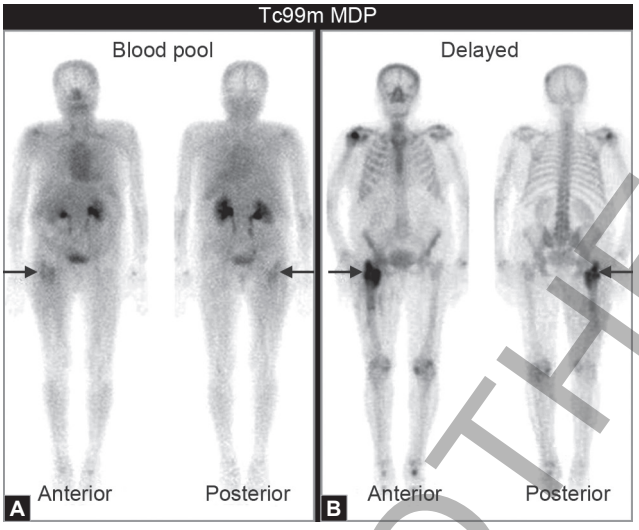

FIGS. 10A AND B: To show imaging in a bone scan.

Flow phase (seconds): Blood flow
↓
Blood pool phase (minutes): Soft tissue perfusion
↓
Delayed phase (2–4 hours): Bone turnover

FLOWCHART 8: Phases of bone scintigraphy (bone scan)—technetium-99m MDP.

TABLE 20: Advantages and limitations of bone scintigraphy (bone scan)–technetium-99m MDP.

Advantages	Limitations
• High sensitivity	• Low specificity—increased uptake in fracture, infection, tumor, arthritis
• Detects multifocal disease	

- Early detection of *stress fractures*.
- Evaluation of *osteomyelitis* (especially multifocal or in children).
- Assessment of *prosthetic joint infection* versus aseptic loosening.
- Evaluation of *Paget's disease* extent.
- Diagnosis of *complex regional pain syndrome (CRPS)*.

Phases

See **Flowchart 8**.

Advantages and Limitations of Bone Scintigraphy (Bone Scan)–technetium-99m MDP

See **Table 20**.

Single-Photon Emission Computed Tomography (SPECT) and SPECT-CT

- Single photon emission computed tomography (*SPECT*) provides *3D functional imaging* ***(Fig. 11)***.
- *SPECT-CT* combines functional SPECT with anatomical CT, improving localization and specificity.

Uses in Orthopedics

- Localizing spinal pain generators (facet arthropathy and pars defect).
- Differentiating between infection and loosening in prostheses.
- Evaluating subtle fractures and osteochondral lesions.

JAYPEE BROTHERS

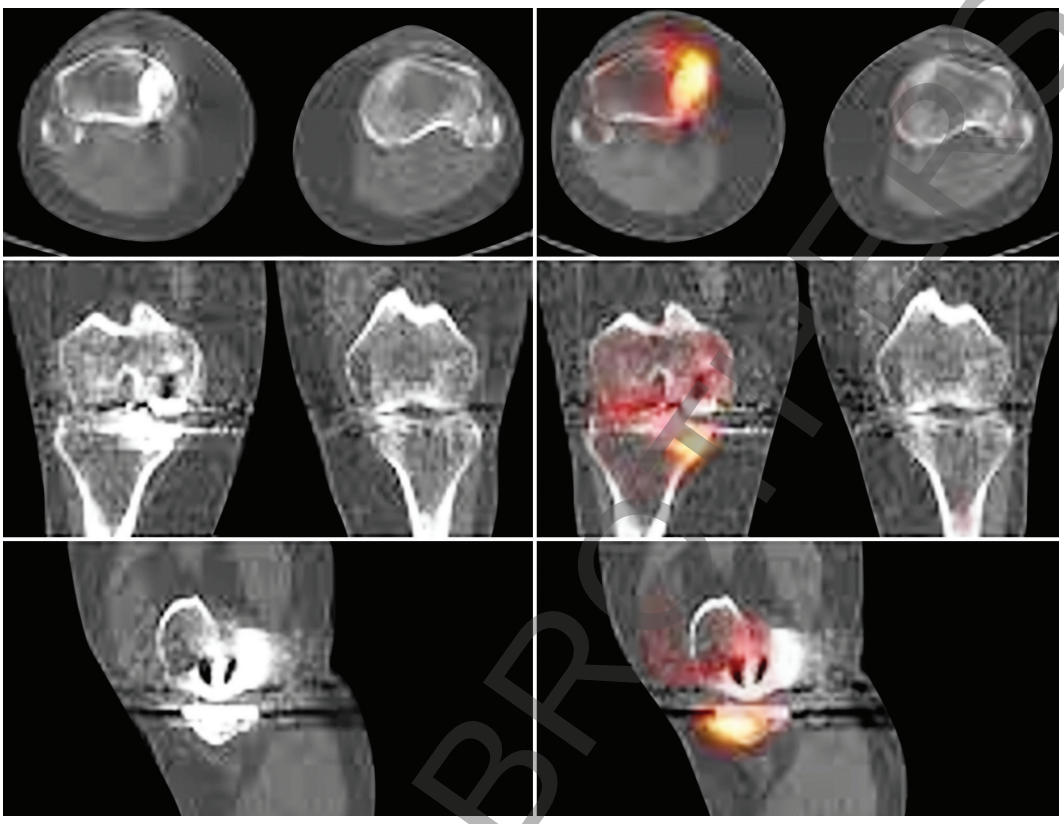

FIG 11: To show single photon emission computed tomography–computed tomography (SPECT-CT) imaging.

Positron Emission Tomography-Computed Tomography and Positron Emission Tomography-Magnetic Resonance Imaging

Principle

Positron emission from radionuclide (commonly F-18 fluorodeoxyglucose [FDG]) is detected, combined with CT or MRI for anatomical detail.

Applications

- *Oncology*: Detecting primary bone tumors, staging, and metastases.
- *Infection*: Detecting chronic osteomyelitis, prosthetic joint infections.
- *Inflammatory conditions*: Mapping active arthritis or enthesitis.

Advantages and limitations of PET-CT and PET-MRI:

See **Table 21**.

Gallium and Indium-111 Scans

- *Gallium-67*: Binds to lactoferrin in inflammatory cells; used for infection localization.

TABLE 21: Advantages and limitations of PET-CT and PET-MRI.

Advantages	Limitations
High sensitivity and specificity for many malignancies	High cost
Whole-body survey possible	False positives with inflammatory conditions

JAYPEE BROTHERS

Ready Reckoner in Orthopedics

"Ready Reckoner in Orthopedics" is a concise, exam-oriented, and clinically relevant resource designed specifically for MS and DNB orthopedic postgraduates. The book covers the entire breadth of cold orthopedics—from basic sciences, biomechanics, to rehabilitation and recent advances. The text is presented in a clear, structured, and high-yield format that allows rapid revision before examinations while also functioning as a reliable day-to-day reference. With its comprehensive coverage, evidence-based content, and quick readability, this book is positioned to become a one-stop solution for postgraduate trainees preparing for theory and viva, as well as a go-to refresher for orthopedic surgeons in busy clinical settings.

Vijay Kumar MBBS MS(Orthopedics, AIIMS) FRCS(Glasgow) FACS FICS FIMSA MAMS Diploma in Tissue Banking(Singapore) Fellow in Sports Medicine(Singapore) Commonwealth Fellow in Arthroplasty(Oxford, UK) AAHKS Fellow IOS-UK Fellow is a Professor of Orthopedics at AIIMS, New Delhi, India, with over two decades of academic, clinical, and research experience. A distinguished orthopedic surgeon, he has trained extensively in India and abroad including Commonwealth Fellowship in Joint Replacement at Oxford and Sports Medicine Fellowship at Singapore. He has to his credit numerous publications, scientific paper presentations, guest lectures at national and international conferences, as well as several funded research projects. Renowned for his expertise in arthroplasty, arthroscopy, and orthopedic research, Dr Kumar continues to make significant contributions to orthopedic education, innovation, and clinical practice.

Abdul Ghani MBBS MS(Orthopedics, AIIMS) MRCS is a distinguished Orthopedic Surgeon, Professor, and Head of Unit at the Government Medical College, Jammu, Jammu & Kashmir, India. With over three decades of clinical, surgical, and academic experience, he has a special interest in trauma care, postgraduate teaching, and orthopedic education in India. He is the author of eight books, including highly acclaimed titles on the handbook of fractures, musculoskeletal pain management, a competency-based logbook manual, solved papers for MS and DNB orthopedic exams, and self-help strategies for life and exam success. His work consistently bridges the gap between textbook knowledge and real-world clinical application. This book reflects not just his experience but his vision—to provide all the knowledge/resource gaps in the most comprehensive manner.

JAYPEE BROTHERS

Shelving Recommendation
ORTHOPEDICS

ISBN 978-93-7545-434-2

9 789375 454342

Buy from ejaypee

JAYPEE BROTHERS