3rd Edition

Textbook of Pediatric Dermatology



Ragunatha Shivanna
Aparna Palit
Arun C Inamadar

JAYPEE

JAYPEE BROTHERS

Contents

1. Structure and Functions of Skin 1

Chidambara Murthy S, Gouhare Afshan

- Embryogenesis of the Skin *1*
- Embryonic Skin *1*
- Unique Features of Developing Skin *4*
- Structure of the Newborn Skin *5*
- Functions of the Newborn Skin *9*
- Skin of the Premature Infant *10*
- Skin Care *10*

2. Neonatal Dermatology 16

Niti Khunger, Pratibha Kuchana, Alka Goel

- General *16*
- Vascular Phenomena *23*
- Pigmentary Changes *24*
- Miscellaneous *25*
- Cutaneous Signs of Spinal Dysraphism *26*
- Cutaneous Manifestations of Congenital Infections *27*
- Neonatal Skin Care *31*

3. Genodermatosis 33

Aparna Palit, Subhojit Ray, Arun C Inamadar

- Principles of Genetics *33*
- Major Patterns of Genetic Transmission *33*
- Genetic Counseling *36*
- Prenatal Diagnosis of Hereditary Skin Disorders *36*
- Classification of Genodermatoses *36*
- Ectodermal Dysplasia *36*
- Hereditary Disorders of Pigmentation *45*
- Hereditary Disorders of Immune System *49*
- Hereditary Disorders with Photosensitivity *57*
- Hereditary Disorders of Metabolism *73*
- Multiple Tumor Syndromes *76*
- Hereditary Disorders of Connective Tissue *84*
- Premature Aging Syndromes *93*
- Chromosomal Disorders *95*
- Skin Gene Therapy *97*

JAYPEE BROTHERS

4. Inherited Ichthyosis and Other Hereditary Disorders of Keratinization **107**
Arun C Inamadar, Ragunatha Shivanna

- Classification *107*
- Complications *116*
- Diagnostic Approach to Inherited Ichthyosis *117*
- Differential Diagnosis *119*
- Ichthyosiform Syndromes *119*
- Management *123*
- Erythrokeratoderma *126*
- Palmoplantar Keratoderma *127*

5. Atopic Dermatitis **137**
Sandipan Dhar, Maitreyee Panda, Arunima Ray

- Etiopathogenesis *137*
- Prevalence and Incidence of Atopic Dermatitis *138*
- Key Steps to Diagnose Atopic Dermatitis *141*
- Complications *144*
- Natural History and Prognosis *145*
- Management of Atopic Dermatitis *145*
- Current Investigational Therapies of Unproven Efficacy *150*

6. Eczemas Other than Atopic Dermatitis **158**
Sanjeev Handa, Apoorva Sharma

- Classification *158*
- Exogenous Eczemas *158*
- Endogenous Eczemas *162*

7. Bacterial Infections **174**
Arun C Inamadar, Amruthvarshini Inamadar

- Classification *174*
- Superficial Pyogenic Infections *174*
- Deep Pyogenic Infections *179*
- Nonpyogenic Bacterial Infections *182*
- Bacterial Toxin-mediated Illnesses *183*
- Secondary Pyoderma *186*
- Special Situations *186*

8. Mycobacterial Infections **190**

Cutaneous Tuberculosis ***190***
Vikrant A Saoji, Bhushan Madke

- Immunopathogenesis *190*
- Classification *191*
- Clinical Types *191*

JAYPEE BROTHERS

- Dermatological Complications due to BCG Vaccination *195*
- Histopathology of Cutaneous Tuberculosis *196*

Nontuberculosis Mycobacterial Infections *199*

Ragunatha Shivanna

- History *199*
- General Characteristics and Classification *199*
- Epidemiology *199*
- Pathogenesis *200*
- Clinical Features *200*
- Histopathology *202*
- Diagnosis *202*
- Differential Diagnosis *202*
- Treatment *203*
- Complications, Course, and Prognosis *203*

Leprosy *205*

Chetan Rajput, Avinash A Sajgane, Ashutosh Trivedi

- Epidemiology *205*
- Susceptibility to the Disease *205*
- Reservoir of Infection *206*
- Routes of Transmission *206*
- Pathogenesis of Leprosy *206*
- Classification of Leprosy *208*
- Clinical Features *208*
- Differential Diagnosis *212*
- Diagnosis of Leprosy *212*
- Treatment of Leprosy *213*
- Reactions in Leprosy *215*
- Leprosy-Related Deformities in Children *216*
- Counseling *216*
- Vaccination and Chemoprophylaxis *216*

9. Viral Infections and Exanthems 219

Viral Infections *219*

KA Seetharam, Sowmya Srirama

- Herpesviruses *219*
- Poxviruses *234*
- Human Papillomaviruses *239*
- Viral Hemorrhagic Fevers *246*
- Newer Infections *252*

JAYPEE BROTHERS

Viral Exanthem ***256***

Vijay Zawar, Shibani Sudheer Hegde

- Traditional Exanthems *256*
- Other Viral Exanthems *262*
- Vasculitis with Possible Viral Triggers *268*
- Miscellaneous Exanthems *273*

10. Fungal Infections **283**

Madhu Rengarajan

- Superficial Fungal Infections *283*
- Deep Fungal Infections *301*

11. Sexually Transmitted Infections and HIV Infection **316**

Sexually Transmitted Infections ***316***

Sachin Kore

- Bacterial Sexually Transmitted Infections *317*
- Sexually Transmitted Infections by Parasites *327*
- Viral Sexually Transmitted Infections *327*
- Sexual Assault and Abuse and Sexually Transmitted Infections *330*

HIV Infection ***333***

Sachin Kore

- Prevention of Mother-to-Child Transmission *333*
- Diagnosis of HIV Infection in Infants and Children *334*
- Mucocutaneous Manifestations in HIV Positive Children *336*
- Management of Newly Diagnosed HIV Infection in Children Including ART Initiation *344*
- Antiretroviral Therapy for Children *345*
- Treatment Failure and Switch to Second-line ART in Children with HIV *348*

12. Diseases due to Protozoa and Helminths **351**

Subhojit Ray, Aparna Palit

- Protozoan Infections *351*
- Helminthic Infestations *357*

13. Bites, Stings, and Infestations **366**

Sanmitra Aiholli

- Papular Urticaria *366*
- Other Reactions to Arthropod Bites and Stings *368*
- Other Noxious and Venomous Stings *373*
- Injuries by Aquatic Creatures *374*
- Other Animal and Human Bites *374*
- Infestations *374*

JAYPEE BROTHERS

14. Diseases of the Mucous Membranes 383
Shruthi Kulkarni, Keshavmurthy Adya

- Mouth Ulcers *383*
- White Patches *389*
- Red and Pigmented Lesions *391*
- Swellings/Lumps *392*
- Lesions of the Tongue *393*

15. Disorders of Hair 397
Chandrashekahr BS, Warood Albadri

- Normal Hair *397*
- Congenital or Early Onset Alopecia *399*
- Nonscarring Alopecia *405*
- Scarring Alopecia *423*
- Hypertrichosis *427*
- Hirsutism *432*
- Eruptive Vellus Hair Cysts *434*
- Abnormalities of Hair Color *434*
- Altered Pigmentation of Hair Due to Exogenous Agents *437*

16. Nail Disorders 439
Chander Grover

- Nail Anatomy *439*
- Physiology of Nail Growth *439*
- Physiological Changes of Nail Apparatus *440*
- Pathological Changes of Nail Apparatus *441*
- Ingrown Nail *445*
- Nail Tic Disorders *445*
- Paronychia *446*
- Nail Changes in Primary Cutaneous Disorders *446*
- Nail Changes in Genodermatoses *450*
- Nail Changes in Systemic Disorders *452*
- Pigment Alterations Over Nail *453*
- Tumors *454*
- Nail Changes Associated with Chemotherapy in Children *454*

17. Disorders of Cutaneous Appendages 456
Umamaheshwari G Chitapur, Keshavmurthy Adya

- Disorders of Sebaceous Glands *456*
- Disorders of Eccrine Sweat Glands *467*
- Disorders of Apocrine Glands *473*

JAYPEE BROTHERS

18. Psoriasis 480
Sunil Dogra, Hitaishi Mehta, Dipankar De
- Etiology and Pathogenesis *480*
- Histopathology *481*
- Clinical Features *481*
- Differential Diagnosis *487*
- Comorbidities *487*
- Quality of Life *488*
- Long-Term Behavior of Childhood Psoriasis into Adulthood *488*
- Treatment *488*

19. Erythroderma 495
Dipankar De, Sunil Dogra, Ishita Kaushal
- Epidemiology *495*
- Causes and Clinical Features *495*
- Pathogenesis *498*
- Approach to a Child with Erythroderma *499*
- Management of Childhood Erythroderma *500*
- Recent Advances *503*

20. Lichen Planus, Lichenoid Disorders, and Other Papulosquamous Disorders 504
Ragunatha Shivanna, Anitha B
- Lichen Planus *504*
- Lichenoid Disorders *508*
- Other Skin Diseases with Lichenoid Eruptions *511*
- Other Papulosquamous Disorders *512*

21. Vesiculobullous Disorders 521
Archana Singhal, Sonia Agrawal
- Immunobullous Disorders *521*
- Mechanobullous Disorders *536*

22. Vitiligo 553
Najeeba Riyaz, Faiz Riyaz Arakkal
- Epidemiology *553*
- Etiopathogenesis *553*
- Classification *555*
- Clinical Features *555*
- Associations of Vitiligo *556*
- Course of Vitiligo *559*
- Differential Diagnoses *559*
- Diagnosis *560*
- Management *560*
- Other Modalities in Pipeline *564*

JAYPEE BROTHERS

23. Disorders of Pigmentation 567
Manjunath Shenoy, Sahana Srihari, Sahana P Raju
- Classification *568*
- Disorders of Hyperpigmentation *569*
- Disorders of Hypopigmentation *578*

24. Photosensitivity and Photodermatoses 586
Minu Jose Chiramel, Dharshini Satish Kumar
- Ultraviolet Spectrum and Skin *587*
- Approach to Suspected Photodermatoses *587*
- Management *591*

25. Urticaria, Angioedema, and Annular Erythemas 596
Arun C Inamadar, Ragunatha Shivanna
- Epidemiology *596*
- Classification *596*
- Etiopathogenesis *597*
- Clinical Features *598*
- Differential Diagnosis *602*
- Laboratory Investigations *602*
- Treatment *603*
- Annular Erythemas *604*

26. Nevi and Nevoid Disorders 607
Nilendu Sarma, Ajit Janagond
- Insight into Mosaicism *607*
- Classification of Nevi *609*
- Nevomelanocytic Nevi *609*
- Epidermal Nevi *617*
- Vascular Nevi *623*
- Nevus Syndromes *636*

27. Neoplastic Disorders 644
Shruthi Kulkarni, Keshavmurthy Adya
- Classification *644*
- Nevi and Hamartomas *644*
- Benign and Malignant Neoplasia *650*
- Syndromes Associated with Cutaneous Tumors and Tumor-Like Conditions *655*
- Cutaneous Metastases from Internal Malignancies *655*

28. Disorders of Dermis and Subcutaneous Fat 663
Aparna Palit, Vishalakshi Pandit
- Panniculitis *663*
- Granuloma Annulare *673*

JAYPEE BROTHERS

- Lipodystrophy *676*
- Fibromatosis *680*

29. Histiocytoses and Cutaneous Mastocytosis **688**

Kunal Kumar Paul, Arun C Inamadar, Aparna Palit

- Histiocytosis *688*
- Cutaneous Mastocytosis *695*

30. Skin in Systemic Diseases **704**

Balkrishna Pralhadrao Nikam, Prajakta Anand Sharma, Neha Shirish Nagare

- Disorders of Gastrointestinal System *704*
- Hepatic and Pancreatic Disorders *707*
- Disorders of Cardiovascular System *709*
- Disorders of Respiratory System *710*
- Renal Disorders *711*
- Hematological Disorders *714*
- Endocrine Disorders *715*
- Psychocutaneous Disorders *721*
- Cutaneous Manifestations of Internal Malignancies *725*
- Purpura Fulminans *727*
- Sarcoidosis *732*
- Graft-versus-Host Disease *735*

31. Collagen Vascular Disorders **741**

Anju George, Lydia Mathew, Dharshini Satish Kumar

- Lupus Erythematosus *741*
- Discoid Lupus Erythematosus *741*
- Systemic Lupus Erythematosus *745*
- Monogenic Lupus *746*
- Neonatal Lupus Erythematosus *757*
- Juvenile Dermatomyositis *759*
- Childhood Scleroderma *768*
- Lichen Sclerosus *780*
- Mixed Connective Tissue Disease *783*
- Cutaneous Manifestations of other Collagen Vascular Disorders *784*

32. Cutaneous Vasculitides and Neutrophilic Dermatoses **789**

Sushil Pande

- Classification *789*
- Small-Vessel Vasculitis *790*
- Medium-Vessel Vasculitis *795*
- Behçet's Disease *799*
- Neutrophilic Dermatoses in Children *800*

JAYPEE BROTHERS

33. Nutritional Deficiency Disorders 806
Aparna Palit, Anitha B

- Micronutrient Deficiency Disorders *806*
- Macronutrient Deficiency Disorders *815*
- Heritable Disorders of Nutritional Deficiency *817*
- Nutritional Deficiency in Patients With Eating Disorders *820*
- Nutritional Deficiency in Children with Other Medical/Surgical/Cutaneous Disorders *821*

34. Pruritus in Children 823
Aparna Palit, Sneha Manjunath

- ITCH Pathway *823*
- Cutaneous Disorders Causing Pruritus *824*
- Systemic Disorders Causing Pruritus *830*

35. Dermatological Drug Therapy in Children 835
Lalit Gupta, Manisha Balai, Khushboo Gupta

- Basic Principles of Drug Therapy in Children *835*
- General Principles of Topical Therapy *836*
- Topical Drug Therapy in Children *838*
- Systemic Drug Therapy in Children *844*
- Adverse Cutaneous Drug Reactions: Issues in Children *855*
- Some Important Adverse Cutaneous Drug Reaction Patterns in Children *856*

36. Pediatric Dermatological Emergencies 865
Arun C Inamadar, Ragunatha Shivanna

- Epidemiology *865*
- Classification *865*
- Diseases Causing Acute Skin Failure *865*
- Diseases with/due to Underlying Systemic Illness *870*
- Localized Diseases *874*

37. Dermoscopy in Pediatric Dermatology 876
Balachandra Ankad, Sankappanavara Veeranna Smitha

- Instrument *876*
- Principle *876*
- How to do it? *876*
- What to See? *877*
- Dermoscopy–Histopathology Correlation *879*
- Hypopigmentary Dermatoses *881*
- Hyperpigmented Dermatoses *884*
- Infective Disorders *885*
- Leprosy *888*
- Hair Disorders *892*

JAYPEE BROTHERS

- Inflammatory Disorders *895*
- Vascular Lesions *897*
- Nevi *898*
- Nail Disorders *899*

38. Dermatosurgical Procedures in Pediatric Age Group **903**

Swapnil Shah, Shibani Sudheer Hegde

- Preoperative Preparation *904*
- Consent *904*
- Distraction Techniques for Pediatric Dermatosurgery *904*
- Anesthesia *905*
- Biopsy *908*
- Curettage *909*
- Fusiform/Elliptical Excision *910*
- Cyst Excision *910*
- Suture Materials *910*
- Cryotherapy *910*
- Electrosurgery with Radiofrequency Units *911*
- Chemical Cauterization *912*
- Phototherapy *912*
- Photodynamic Therapy *914*
- Intralesional Injections *914*
- Lasers and Pediatric Population *915*
- Vitiligo Surgery in Children *917*
- Postoperative Care *920*
- Pediatric Conditions and Dermatosurgical Procedures *920*

Index **925**

JAYPEE BROTHERS

CHAPTER 4

Inherited Ichthyosis and Other Hereditary Disorders of Keratinization

Arun C Inamadar, Ragunatha Shivanna

JAYPEE BROTHERS

INTRODUCTION

Ichthyosis is a heterogeneous group of disorders of keratinization characterized by generalized scaling of the skin. The term "ichthyosis" has been derived from the Greek word "ichthys" meaning fish scale. This descriptive term refers to the similar appearance of the skin seen in this group of disorders resulting from abnormal keratinization, including severe congenital forms and different ichthyosiform syndromes. Ichthyosis may result from either increased stratum corneum production or abnormal corneocyte shedding.

CLASSIFICATION

There is no universally accepted terminology and classification of the diseases considered under the umbrella term "ichthyosis." Initiative by the "First World Congress on Ichthyosis" in 2007 led to the "2009 Ichthyosis Consensus Conference" on the terminology and classification of inherited ichthyosis. The classification remains clinical based and distinguishes between syndromic form and nonsyndromic form. A clinicogenetic classification of inherited ichthyosis has been presented in **Boxes 1 and 2**. Clinical expression of these disorders is greatly variable ranging from mild ichthyosis vulgaris (IV) to severe, lethal harlequin ichthyosis (HI). There are certain clinical pointers to diagnose individual conditions; however, confirmative diagnosis is possible only by ultrastructural study and molecular diagnostic studies.

Ichthyosis Vulgaris

Ichthyosis vulgaris is a common variant of the disease. It is more common in atopic individuals. The transmission is autosomal semidominant with variable penetrance. However, cases without family history are commonly seen. Some authors believe it to be a polygenic disorder, sharing common genetic predisposition as atopic dermatitis.

BOX 1: Nonsyndromic forms of inherited ichthyosis.

Common ichthyosis (often delayed onset):
- Ichthyosis vulgaris
- X-linked recessive ichthyosis (nonsyndromic form)

Autosomal recessive congenital ichthyosis:
- *Major types*:
  - Harlequin ichthyosis
  - Lamellar ichthyosis
  - Congenital ichthyosiform erythroderma
- *Minor variants (pleomorphic ichthyosis)*:
  - Self-healing collodion baby
  - Acral self-healing collodion baby
  - Bathing-suit ichthyosis

Keratinopathic ichthyosis:
- *Major types*:
  - Epidermolytic ichthyosis (EI)
  - Superficial EI
- *Minor variants*:
  - Annular EI
  - Ichthyosis Curth–Macklin
  - Autosomal recessive EI
  - Epidermolytic nevi
- *Other forms*:
  - Loricrin keratoderma
  - Erythrokeratoderma variabilis
  - Peeling skin disease
  - Ichthyosis variegata (congenital reticular ichthyosiform erythroderma)
  - Keratosis linearis–ichthyosis congenital–keratoderma

Pathogenesis

This is a disorder involving keratinocyte protein (bricks) keratohyalin. The skin of patients with IV is deficient in histidine which is a basic molecule necessary for synthesis of profilaggrin and filaggrin. Profilaggrin is not available for keratin synthesis, impairing the formation of keratohyalin granules and keratin filaments. Stratum corneum ceramide level may be decreased in these patients. Affected gene is filaggrin (*FLG*) gene. There will be

BOX 2: Syndromic forms of inherited ichthyosis.

X-linked ichthyosis syndromes:
- Recessive X-linked ichthyosis (syndromic form)
- Ichthyosis follicularis, alopecia, and photophobia syndrome
- Conradi–Hünermann–Happle syndrome

Autosomal ichthyosis syndromes with:
- *Prominent hair abnormalities*:
  - Netherton syndrome
  - Ichthyosis hypotrichosis syndrome
  - Ichthyosis–hypotrichosis–sclerosing cholangitis syndrome
  - Trichothiodystrophy syndrome
- *Prominent neurologic signs*:
  - Sjögren–Larsson syndrome
  - Refsum syndrome
  - Mental retardation–enteropathy–deafness–neuropathy–ichthyosis–keratoderma syndrome
- *Fatal disease course*:
  - Gaucher syndrome type 2
  - Multiple sulfatase deficiency
  - Cerebral dysgenesis–neuropathy–ichthyosis–palmoplantar keratoderma
  - Arthrogryposis–renal dysfunction–cholestasis syndrome
- *Other associated signs*:
  - Keratitis–ichthyosis–deafness syndrome
  - Neutral lipid storage disease with ichthyosis
  - Ichthyosis prematurity syndrome

decreased corneocyte hydration as a result of low natural moisturizing factor (NMF) and high stratum corneum pH resulting in increased protease activity. Biallelic mutation in *CASP14* gene encoding caspase responsible for proteolytic degradation of filaggrin has been reported in a mild form of ichthyosis. The patient presents with generalized fine white scales without erythema or itching clinically representing overlap between IV and mild type of autosomal recessive congenital ichthyosis (ARCI).

Clinical Features

Ichthyosis vulgaris manifests during the first few months of life (2–6 months), and clinical features are mild. There is light-gray-colored fine scale involving extensor extremities and trunk **(Fig. 1)**. The flexures, such as the axillae, groins, and antecubital and popliteal fossae, are spared **(Fig. 2)**. The condition is asymptomatic and family history may be positive. Although reduced in severity, it persists till adult life. The course of the disease is stable; often it is better in summer. In patients with associated atopy, keratosis pilaris, hyperlinearity of palms and soles and pruritus may be present.



Fig. 1: Ichthyosis vulgaris with hyperlinearity of palms.



Fig. 2: Sparing of flexural area (cubital fossa) in ichthyosis vulgaris.

Histopathology

Histopathology reveals compact orthohyperkeratosis, and the granular layer is almost absent. Occasional follicular hyperkeratosis is observed. Other features include small and reduced eccrine sweat and sebaceous glands and mononuclear infiltrate in the upper dermis. Electron microscopy shows fragmented, small, or only rudimentary keratohyalin granules. Antigen mapping shows reduced or negative filaggrin staining.

JAYPEE BROTHERS

X-linked Recessive Ichthyosis

X-linked recessive ichthyosis (XLRI) is the second most common variant of ichthyosis with X-linked recessive transmission.

It is unique among congenital ichthyosis by the presence of extracutaneous manifestations.

Pathogenesis

Two molecular pathways are involved in the pathogenesis of XLRI. The prime factor is the lack of steroid sulfatase (STS) (isomer of aryl sulfatase C, a membrane-bound microsomal enzyme) in affected patients. This enzyme is normally present in the leukocytes, keratinocytes, and fibroblasts and is responsible for epidermal hydrolysis of cholesterol sulfate to cholesterol. In deficiency of STS, there is accumulation of cholesterol sulfate in the epidermis. This results in barrier instability by nonlamellar phase separation in the stratum corneum interstices. The high level of cholesterol sulfate also delays the corneodesmosome degradation which results in corneocyte retention. High Ca^{2+} in the stratum corneum of patients with XLRI may be another contributory factor, which enhances corneocyte retention.

The gene encoding STS is located at Xp22.3 which is particularly susceptible to deletions. Complete deletion of the *STS* gene is seen in most cases (>90%), and it is one of the genetic disorders with the highest chromosomal deletions. Contiguous gene syndromes may occasionally result when deletions extend to the neighboring genes. Examples of these include XLRI in association with Kallmann syndrome, ocular albinism type 1, X-linked recessive chondrodysplasia punctata, short stature, and mental retardation. Point mutations may also occur in *STS* gene, leading to amino acid substitutions in the polypeptide chain.

Clinical Features

The baby may be born with mild collodion membrane or clinical features start within a few weeks of birth. The scales are typically large, polygonal (rhomboid), dark in color, and firmly attached, especially over extremities **(Fig. 3)**, neck, and preauricular area of the face **(Fig. 4)**. Over the sides of the trunk **(Fig. 5)** and back of the neck, the scales give a dirty appearance. Flexural involvement may be seen in some cases. Palms and soles are not involved. Clinical features persist till adult life. The course of the disease is stable, often better in summer.



Fig. 3: Dark-colored, polygonal scales on the leg in a case of X-linked recessive ichthyosis.



Fig. 4: Scales in the preauricular area in a case of X-linked recessive ichthyosis.

Main extracutaneous manifestations of XLRI are corneal opacities (25–50%) and cryptorchidism (10–20%). XLRI is regarded as syndromic when accompanied by associated manifestations such as testicular maldescent. Rarely, mental deficiency or hypogonadism may be present. Numerous corneal opacities (dots or commas), without hindering the vision, are present in adult patients

JAYPEE BROTHERS



Fig. 5: Dark-colored, polygonal scales on the back in a case of X-linked recessive ichthyosis.

and carrier females. These are demonstrable by slit-lamp examination. There is an increased risk of testicular cancer in these patients which may involve even normally descended testes. Female patients and carriers may develop obstetric complications like prolonged labor due to inadequate cervical dilatation resulting from deficient placental STS.

Histopathology

Histopathological features are nonspecific with a normal or prominent granular layer. Sebaceous glands are present. Electron microscopic findings include numerous keratohyalin granules which may be smaller or normal.

Other Investigations

Detection of absent STS activity in leukocytes or fibroblasts, fluorescence in situ hybridization (FISH) tests for STS deletion and elevated blood cholesterol sulfate levels are the helpful investigations. Fetal STS deficiency leads to low maternal serum and urinary estriol levels; hence, XLRI may be detected in utero by measurement of maternal estriol levels.

Autosomal Recessive Congenital Ichthyosis

Autosomal recessive congenital ichthyosis is a group of nonsyndromic congenital ichthyotic disorders mainly comprising HI, lamellar ichthyosis (LI), and congenital ichthyosiform erythroderma (CIE). Various proteins and enzymes such as 12R-lipoxygenase, epidermal lipoxygenase 3, cytochrome P450 4F22, magnesium transporter NIPA4 (ichthyin), short-chain dehydrogenase/reductase family 9C member 7, ceramide synthase-3, patatin-like phospholipase domain containing protein 1, and long-chain fatty acid transport protein 4 are involved in the pathogenesis of ARCIs resulting in defective cornified envelope cross-linking, lipid attachment, ceramide biosynthesis, and formation of an intercellular lipid bilayer.

Harlequin Ichthyosis

Harlequin ichthyosis is a very rare, severe form of congenital ichthyosis with autosomal recessive (AR) inheritance. Sporadic cases may also occur. It is associated with high perinatal mortality and the survivors experience high morbidity due to subsequent development of severe erythroderma and other deformities.

Pathogenesis

In patients with HI, there is abnormal localization of epidermal lipids and lamellar granule formation is defective. There is mutation of the *ABCA12* [ATP (adenosine triphosphate) binding cassette (ABC) subfamily A member 12] gene encoding an ABC transporter. *ABCA12* is associated with lipid transport in lamellar granules, and loss of this function leads to a defective lipid barrier in the stratum corneum. Post-translational block in conversion of profilaggrin to filaggrin leads to deficiency of the latter.

Genetic heterogeneity is observed in HI. Depending upon the pattern of keratin expression, there are three types: Type I (normal keratin, profilaggrin staining+), type II (hyperproliferation of suprabasal keratin, K6/K16), and type III (hyperproliferation of suprabasal keratin, K6/K16 and negative profilaggrin staining).

Clinical Features

Preterm delivery and stillbirth are common in this disorder. The affected newborn is encased in armor-like thick, yellow, diamond-shaped scales separated by deep red fissuring simulating the traditional costume of a harlequin **(Fig. 6)**. The skin is stretched tightly over the face resulting in a grotesque appearance. The facial features include extreme ectropion, loss of eyelashes and eyebrows, extreme eclabium, and flattening or synechiae of the ears and broadened nose. Presence of constriction bands leads to swelling of the limbs and flexion of the digits which may

JAYPEE BROTHERS



Fig. 6: A newborn with harlequin ichthyosis, encased in armor-like thick, yellow, diamond-shaped scales separated by deep red fissuring, ectropion, and eclabium.

become hypoplastic and rudimentary. Affected babies are at risk of life-threatening complications in the postnatal period, such as respiratory distress (due to constriction of chest wall), hypoglycemia and dehydration (esophageal stenosis), electrolyte imbalance, temperature instability, feeding problems, and bacterial infections, often with fatal consequences. Death within the first few days of life is usual resulting from these complications. Few surviving children eventually shed this armor and develop a severe CIE-like phenotype.

Histopathology

Light microscopic findings are nonspecific. Ultrastructural examination of stratum corneum shows vesicular lamellar body ghosts and paucity of secreted lamellar structures.

Lamellar Ichthyosis

Lamellar ichthyosis is a severe form of disorder transmitted as AR trait. Rarely, a clinically indistinguishable form with autosomal dominant (AD) inheritance has been reported.

Pathogenesis

Patients with LI have a deranged process of cornification and desquamation resulting from mutations in transglutaminase 1 (*TGM1*) gene located on chromosome 14q11. This leads to abnormal keratinocyte TGM1 enzyme which catalyzes calcium-dependent amide cross-linking between amino acid residues on precursor proteins forming the impermeable layers of epidermal cell envelope. Moreover, this enzyme helps in the formation of lipid envelope by linkage of epidermis-specific omega-hydroxyl ceramides to the plasma membrane. Hence, in the absence of the enzyme, synthesis of protein and lipid envelope of keratinocytes is disturbed.

Clinical Features

Lamellar ichthyosis presents at birth and is one of the causes of collodion baby. The ichthyosis is generalized with involvement of face, flexures, palms, and soles. The scales are large plate-like, quadrilateral, dark brown in color, free, and raised at the edges but adherent at the center. Deep fissures are present in between the scales. The overall appearance is that of a tree bark **(Figs. 7A and B)**. There is intense tautness of the skin, resulting in ectropion, eclabium **(Fig. 8)**, hypoplasia of nose and pinna **(Fig. 9)**, and flexion contracture of limb joints and digits. Occlusion of sweat ducts leads to loss of sweating and heat intolerance. Scarring alopecia may be present, especially over scalp margins. Nail changes include ridging, thickening, and nail dystrophy. Ectropion may lead to conjunctivitis and keratitis. Severe involvement may result in short stature.

Histopathology

Histopathological study reveals marked orthohyperkeratosis, mild acanthosis, and regular papillomatosis. Electron microscopic findings include elongated cholesterol clefts and lipid droplets in the stratum corneum. Minimized or absent cornified cell envelope has been reported.

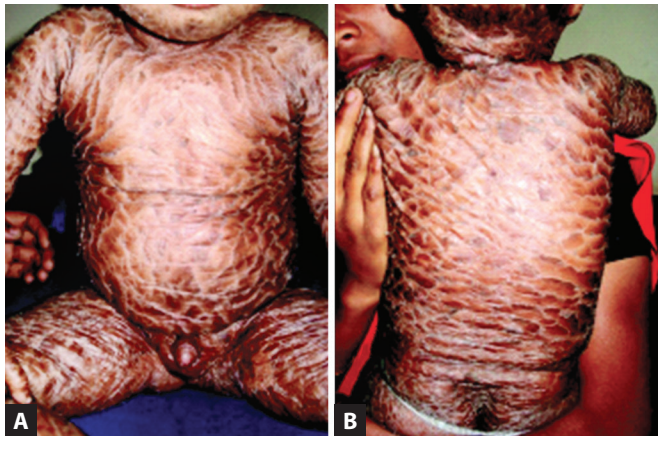

Figs. 7A and B: Large plate-like scale in lamellar ichthyosis simulating bark of a tree.

JAYPEE BROTHERS



Fig. 8: Ectropion and eclabium.



Fig. 9: Hypoplastic ear in lamellar ichthyosis.

Nonbullous Ichthyosiform Erythroderma (CIE)

Nonbullous ichthyosiform erythroderma (NBIE) is a rare type of ichthyosis with AR transmission, present at birth. The AD inheritance pattern has been reported in some families.

Pathogenesis

There is extensive genetic heterogeneity in this disorder. Some patients with NBIE have TGM1 deficiency (mutation in TGM1), resulting in abnormal cornified cell envelope and impaired skin barrier.

Clinical Features

As many as 90% of the infants with NBIE present with collodion membrane at birth. In infancy and thereafter, there is persistent erythroderma with thin, white, small, and semiadherent scales **(Fig. 10)**. However, the degree of erythema and scaling is highly variable, even among affected family members. Scarring alopecia, nail dystrophy, hypohidrosis, and heat intolerance may be present.



Fig. 10: A newborn with nonbullous ichthyosiform erythroderma (small, white, and semiadherent scales).

Histopathology

Light microscopic findings are nonspecific. Ultrastructural findings reveal lipid droplets in the stratum corneum resulting from retained, abnormal lamellar bodies in the corneocytes. Intercellular lipid lamellae are highly disorganized.

Minor Variants of ARCI

The minor variants of ARCIs **(Box 2)** are now grouped under pleomorphic ichthyosis (PI) characterized by a severe form of ichthyosis at birth followed by spontaneous improvement in childhood and subsequent mild skin lesions.

Collodion Baby

This term is used for a transient appearance of neonates born with some congenital ichthyosis. The newborn is encased in a shiny, taut membrane, which sheds thereafter and gradually clinical features of a definitive ichthyosis become apparent. NBIE is the most common condition (60–80%) resulting in collodion baby, followed by LI. Some ichthyosiform syndromes, such as Sjögren–Larsson syndrome (SLS), Conradi–Hünermann syndrome, and trichothiodystrophy (TTD), may also present with collodion membrane at birth.

JAYPEE BROTHERS

These neonates are usually born preterm. A parchment-thin, yellowish, and plastic-like membrane covers the whole body **(Fig. 11)**, tethering at the body orifices. The appearance is typical with ectropion, eclabium, flat pinna, absence of skin creases, and sausage-shaped digits. Limb movements are restricted. Following birth, the membrane dries up and breaks resulting in the development of fissures around the flexures. It is completely shed in the next few weeks **(Fig. 12)**, and thereafter the clinical features of specific ichthyosis become evident.

Self-healing Collodion Baby

In 10–20% of patients, the condition is transient and the child subsequently develops normal skin within 3 months of life. This condition is termed "self-healing collodion baby (SHCB)" or "LI of newborn."

Acral SHCB

It is a localized form of collodion membrane, which is present over acral areas at birth **(Fig. 13)**. The condition heals completely subsequently.

Bathing-suit Ichthyosis

Bathing-suit ichthyosis (BSI) is a distinct type of ARCI. It is predominantly observed in families from South Africa and is caused by mutations in *TGM1*. Skin lesions are present at birth and may present as collodion baby. It has been hypothesized that the differential cutaneous expression in BSI is a temperature-sensitive phenotype where temperature-dependent activity of TGM1 markedly decreases at high temperature. Hence, there is diffuse scaling of scalp, trunk, and proximal parts of the upper limbs **(Fig. 14)** sparing skin areas such as face and distal extremities.

Keratinopathic Ichthyosis

Keratinopathic ichthyosis is caused by mutations in the suprabasal keratins. The resulting change in protein structure causes cytoskeletal fragility. The mutation also interferes with secretion of lamellar bodies and formation of extracellular lipid membrane. Epidermolytic hyperkeratosis (EHK) or ichthyosis is the major variant of this group of ichthyosis. It is characterized by hyperkeratosis, erythroderma, and superficial skin fragility with or without palmoplantar keratoderma (PPK).

Epidermolytic Hyperkeratosis or Bullous CIE

Bullous CIE refers to a rare AD ichthyosis, also known as epidermolytic ichthyosis or EHK. At birth, it does not



Fig. 11: Collodion baby.



Fig. 12: Shedding of collodion membrane.

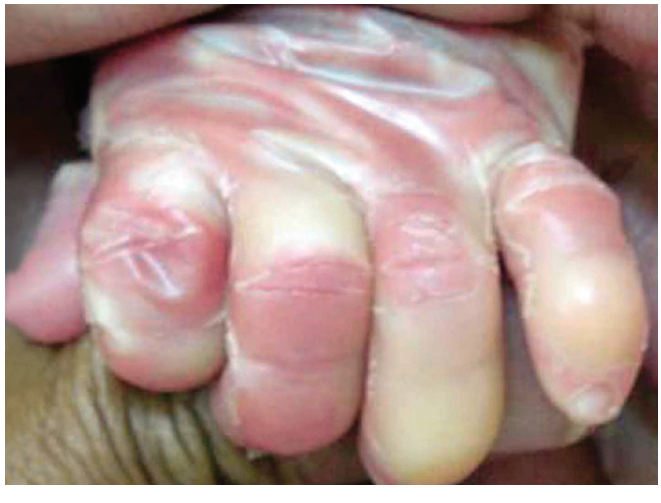

Fig. 13: Acral self-healing collodion baby.

JAYPEE BROTHERS



Fig. 14: Bathing-suit ichthyosis.



Fig. 15: Dirty brown, spiny skin ridges distributed over the periumbilical area in an older child with bullous ichthyosiform erythroderma.

present as collodion baby and is a result of mutations in genes encoding epidermal keratins. The condition is distinct from other congenital ichthyosis because of blister formation. AR (due to *KRT10* mutation) and sporadic forms may also occur.

Pathogenesis

In suprabasal keratinocytes committed to terminal differentiation, the intermediate filaments are composed of keratin 1 or keratin 10 heterodimers. In bullous ichthyosiform erythroderma (BIE), there are mutations in the epidermal keratin 1 or keratin 10 genes resulting in abnormal keratin-intermediate filament cytoskeleton. This results in abnormal clumping of suprabasal keratinocytes and impaired tonofilament network in the differentiating epidermal cells.

Clinical Features

Skin lesions are present at birth as generalized flaccid bullae and extensive areas of denudation. This is provoked by friction resulting from passage through the birth canal. With time, the tendency to extensive vesiculation decreases and hyperkeratotic skin lesions supervene. In older children and adolescents, there are dirty brown, spiny skin ridges, especially distributed over the joints, flexures, back, scalp, and periumbilical **(Fig. 15)** and periareolar regions. However, episodes of focal vesiculation are common, precipitated by friction, trauma, or infection. In severe cases with generalized hyperkeratosis, the skin has a cobblestone appearance which may be shed in large plates revealing underlying erosion. Erythroderma with peeling and scaling may be present. In the neonatal period, sepsis and fluid electrolyte imbalance are the potential causes of mortality.

Palmoplantar keratoderma may be present and depending on the presence or absence of this feature, six phenotypes of EHK have been identified (PS-1, -2, -3 and NPS-1, -2, -3). PPK is diffuse with a sharply demarcated, erythematous border. The keratoderma may be severe with fissuring and digital contractures (PS-2) or rarely cerebriform (PS-3). NPS types have normal palms and soles except NPS-3, where hyperlinearity is the feature. Limited spiny lesions in the nevoid form simulating ichthyosis hystrix (IH) may be present over flexures and extremities. Severe scalp involvement resulting in encasement of hair shafts with scale is a common feature. Nails may be dystrophic. Mucosae and teeth are normal.

Histopathology

Epidermal changes include marked hyperkeratosis and acanthosis. Multiple perinuclear vacuoles and large clumps of keratohyalin granules are present in the granular and upper spinous layer cells. Bullae result from suprabasal splits. These combined histopathological features are known as "'epidermolytic hyperkeratosis." Mild perivascular lymphocytic infiltrate is present in the upper

JAYPEE BROTHERS

dermis. Electron microscopy reveals perinuclear clumping of tonofilaments (keratin filaments) in suprabasal cells and variable desmosomal disruption with cleft formation.

Superficial Epidermolytic Ichthyosis or Ichthyosis Bullosa of Siemens

Ichthyosis bullosa of Siemens (IBS) is a superficial variant of EHK characterized by lack of erythema and palmoplantar involvement. The epidermolysis in IBS correlates with sites of expression of *K2e* gene, and several mutations involving this gene have been reported. The transmission is AD.

Symptoms start during the neonatal period and may persist till adult life. Flexures, shin, and lower abdomen are commonly involved areas. Initial lesions are bullae which rupture shortly with annular peeling of the involved skin with a collarette-like border (mauserung or molting) **(Figs. 16A and B)**. Subsequently, circumscribed areas with grayish, rippled scales develop **(Figs. 17A and B)**. Rarely, hypertrichosis and palmoplantar blistering with hyperhidrosis may be associated. Histopathological changes are similar to classic EHK, but more superficial, confined to granular and upper spinous layers with normal suprabasal and basal cells. Areas of blistering show intracorneal split surrounded by orthohyperkeratosis. Electron microscopy reveals cytolysis in the granular cells of affected body areas without any keratin clumping.

Annular Type of Epidermolytic Ichthyosis

It is a phenotypic variant of BIE characterized by intermittent development of numerous annular, polycyclic, erythematous, scaly plaques on trunk and extremities that enlarge slowly and then resolve. Histopathology and genotype are similar to those of BIE.

Ichthyosis Hystrix

Ichthyosis hystrix resembles EHK due to the presence of spiny scales. However, here the lesions are localized and there is no skin fragility or bullae formation. There is no evidence of epidermolysis in histopathology. Skin lesions may be present at birth or appear during childhood and include muddy, spiny hyperkeratosis on extensor extremities and trunk with or without mild erythema. Lesions may follow Blaschko's lines. Diffuse, mutilating PPK may be present. Hystrix skin changes may be observed in keratitis–ichthyosis–deafness (KID) syndrome and particular types of ectodermal dysplasia.

Vacuolated and binucleate cells in the upper epidermis are a characteristic feature. Ultrastructural findings are perinuclear tonofilament shells forming cytoplasmic compartments in granular and upper spinous cell layers, surrounded by a ribosome-rich region.

Other Forms of Ichthyosis

Ichthyosis Variegata

Ichthyosis variegata, also known as CIE, is caused by AD mutations in the tail region of *KRT-1* and *KRT-10* genes. The genetic defect causes collapse of keratin intermediate filament network. Clinically, it presents as erythroderma similar to CIE in the neonatal period and later in life develops confetti-like spots or reticular pattern of normal skin surrounded by ichthyotic skin. The surface area of



Figs. 16A and B: Mauserung over hands and feet in a case of ichthyosis bullosa of Siemens.

JAYPEE BROTHERS

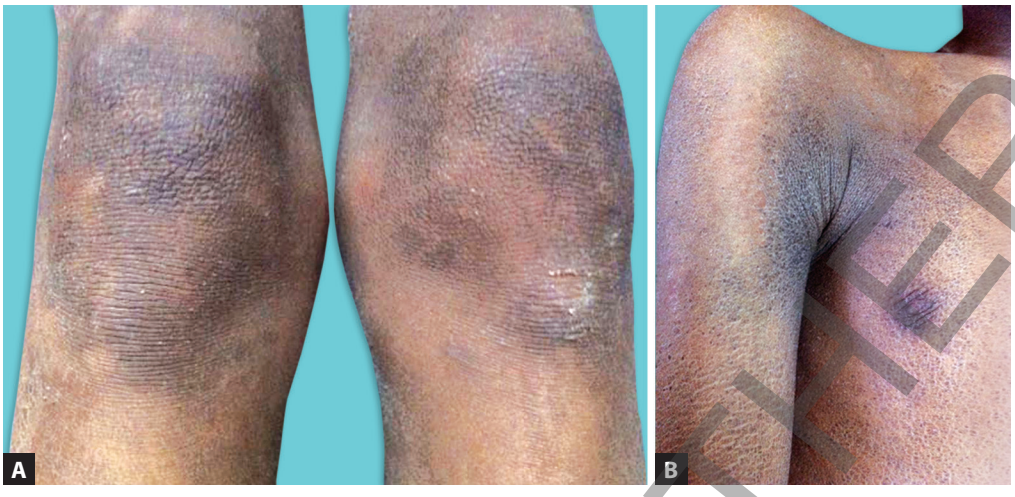

Figs. 17A and B: Circumscribed areas (knees and axillary fold) with grayish, rippled scales in a case of ichthyosis bullosa of Siemens.

normal skin increases with growing age. It can be explained by revertant mosaicism caused by mitotic recombination that results in somatic homozygosity of the wild-type allele.

Multiple Sulfatase Deficiency

Multiple sulfatase deficiency is a very rare AR disorder of childhood, where neurological manifestations are the predominant clinical feature.

There is deficiency of all seven types of sulfatases; however, the relatively milder cutaneous manifestations indicate partial deficiency of STS.

Neurological manifestations simulate late infantile metachromatic leukodystrophy. Clinical features start during the second year as psychomotor retardation, limb hypotonia, and unsteady gait which are progressive. In the late stage, the child is bed-bound and blindness supervenes. Death may be seen within the first year of life. Ichthyosis resembles XLRI but is less severe. Estimation of urinary metabolites may be diagnostic.

Peeling Skin Syndrome

Peeling skin syndrome is a rare disorder, characterized by continual shedding of the entire stratum corneum in sheets. Two variants of the disorder are recognized, noninflammatory (type A) and inflammatory (type B). The inflammatory variant shows clinical overlap with Comèl–Netherton syndrome. Unlike Netherton syndrome (NS), peeling skin syndrome (PSS) does not show hair anomalies and is not related to *SPINK5* mutations. Disease confined only to palms and soles (acral PSS) has been reported. Onset is at birth or during the first weeks of life. Initial clinical presentation may resemble ichthyosiform erythroderma or atopic dermatitis. There may be large peeling scales with varying erythema **(Figs. 18A and B)**. Occasionally, bullous lesions may be seen in these patients. The pathognomonic histopathological feature is cleavage within or below the stratum corneum. This disorder may be associated with hair shaft and nail anomalies, hypogonadism, growth retardation, and aminoaciduria. The disease course is mild to moderate with spontaneous remissions and relapse.

COMPLICATIONS

Complications are common with all types of ichthyosis. Recurrent bacterial infections are common in these patients which may lead to fatal sepsis in some cases. In HI and epidermolytic ichthyosis, the risk of bacterial infections is very high due to deficient release of antimicrobial peptides (AMP). In ARCIs, AMPs are upregulated due to transglutaminase-1 deficiency resulting in relatively reduced risk of bacterial infections. Erythroderma due to LI, NBIE, and HI may lead to hypothermia, fluid, electrolyte imbalance, and metabolic disturbances. Severely erythrodermic children are prone to developing protein-energy malnutrition and stunted growth. Ocular complications in the form of exposure keratitis and dystrichiasis are common in the presence of poorly managed ectropion. Dysmorphic appearance causes severe psychological impact to children suffering from ichthyosis.

JAYPEE BROTHERS

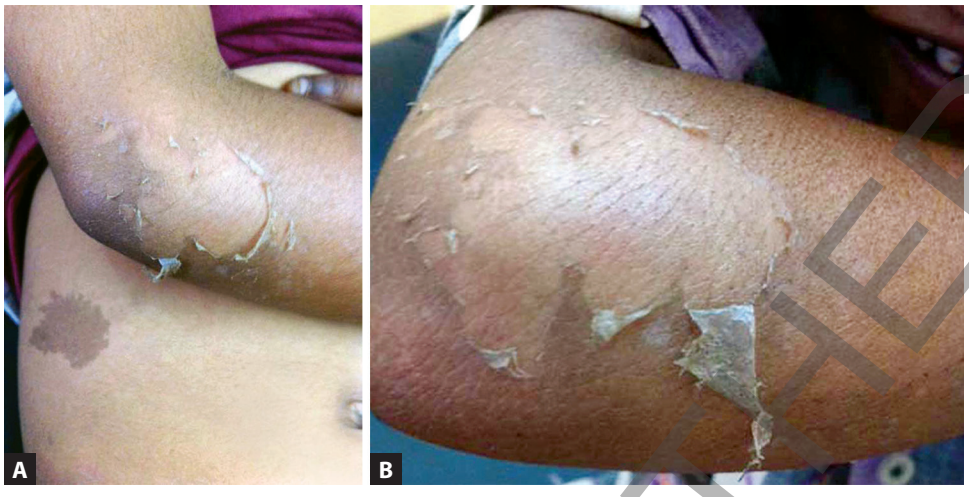

Figs. 18A and B: Peeling skin syndrome.

DIAGNOSTIC APPROACH TO INHERITED ICHTHYOSIS

Diagnosis is based on clinical evaluation of skin and other systems combined with careful history **(Flowcharts 1 and 2)**. Molecular analysis and prenatal diagnosis are suggested if available. History should be taken in detail to collect information about disease onset and progression. Pedigree chart has to be prepared to assess the mode of inheritance. Extracutaneous symptoms, if there are any, have to be recorded **(Flowchart 3)**. Initial dermatological evaluation consists of study of type and pattern of scale **(Flowchart 4)**, type of hyperkeratosis **(Fig. 19)**, and erythroderma **(Fig. 20)**. Symptom and system-directed investigations are performed for supporting the diagnosis and to evaluate the extent of the damage, disease course, and prognosis **(Box 3)**.

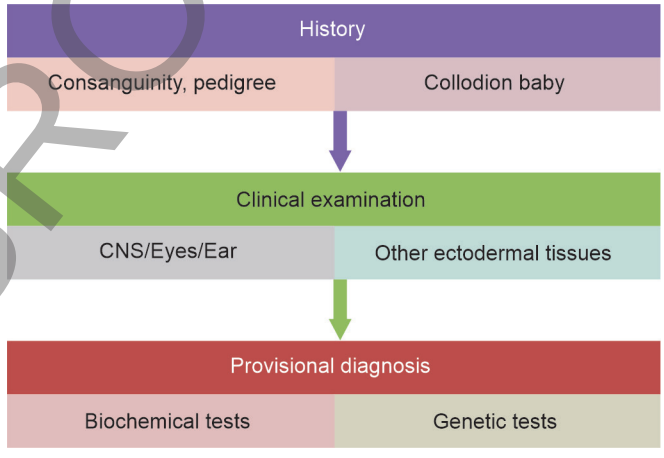

Flowchart 1: Approach to a patient with inherited ichthyosis.

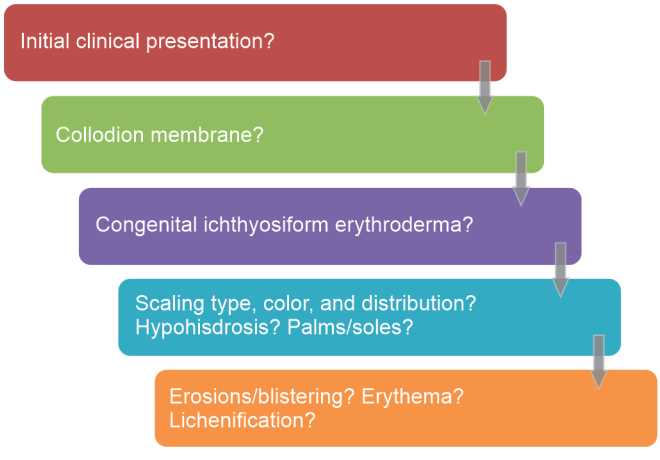

Flowchart 2: Clinical evaluation of a patient with inherited ichthyosis.

Investigations

Although minor differences may exist, light microscopic examination of skin biopsy specimens is nonspecific and usually noncontributory. Electron microscopic features are distinct and this is mandatory to categorize the type of ichthyosis. In patients with XLRI, testing STS activity provides confirmative diagnosis; however, the testing is cumbersome and not available in all the centers. An alternative screening test for these patients is serum electrophoresis, where the electromobility of beta-lipoprotein is enhanced due to accumulation of cholesterol sulfate in this fraction. Pregnant women with risk of carrying a fetus with XLRI and multiple sulfatase

JAYPEE BROTHERS

deficiency can be screened by estimation of maternal serum and urinary estriol, which are low in such cases.

Prenatal diagnosis is advisable in all severe forms of congenital ichthyosis. Ultrastructural study of amniotic fluid cells or fetal skin during the second trimester helps in determining characteristic findings. DNA-based studies from chorionic villus or amniotic fluid cells help to localize the mutation as early as 10–12 weeks.

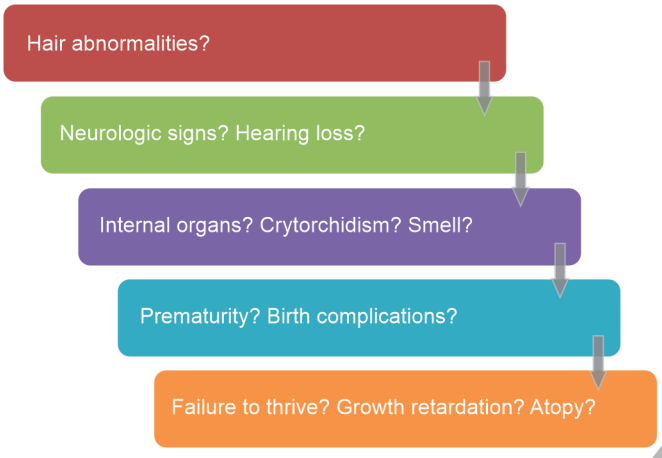

Flowchart 3: Recording of extracutaneous manifestations.

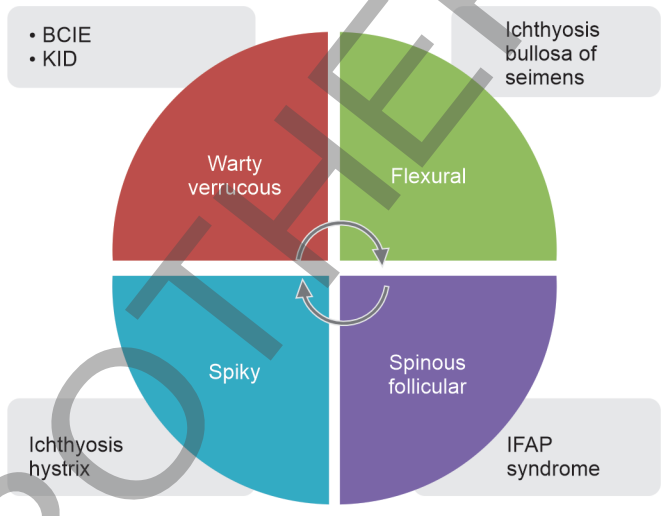

Fig. 19: Types of hyperkeratosis in various ichthyosis and ichthyosiform syndromes.

(BCIE: bullous congenital ichthyosiform erythroderma; KID: keratitis–ichthyosis–deafness)

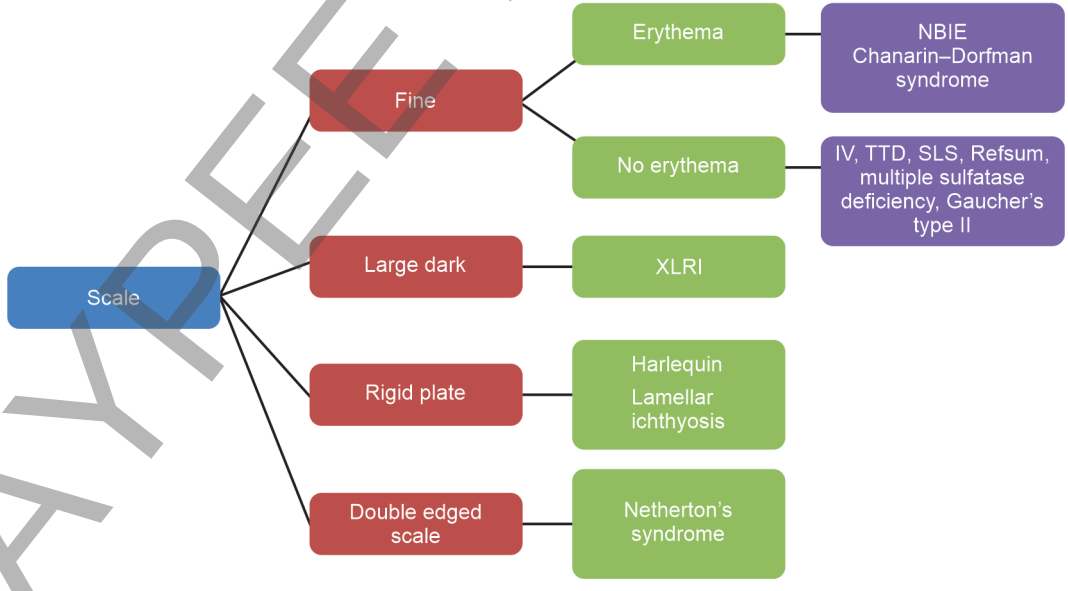

Flowchart 4: Study of type and pattern of scales.

(IV: ichthyosis vulgaris; SLS: Sjögren–Larsson syndrome; TTD: trichothiodystrophy)

JAYPEE BROTHERS

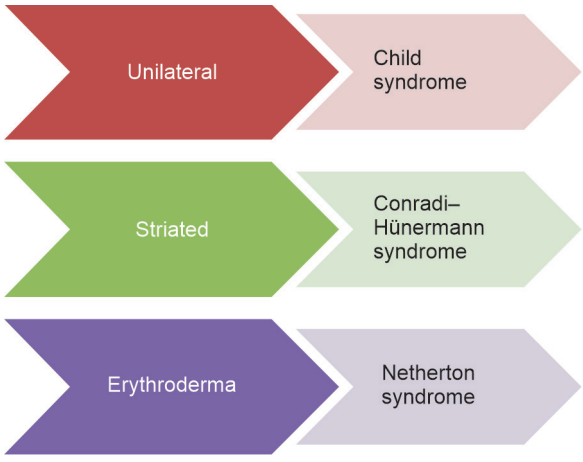

Fig. 20: Clinical clues to erythroderma.

BOX 3: Symptoms and system-directed investigations in inherited ichthyosis.

- Complete blood count
- Immunoglobulin E level
- Hair shaft microscopy or polarizing microscopy
- Hair shaft sulfur analysis
- Liver function tests
- Steroid sulfatase activity
- X-ray
- Phytanic acid level
- Fundoscopy
- Audiometry

DIFFERENTIAL DIAGNOSIS

Mild IV may be mistaken for the xerosis of atopic children, especially when these conditions are coexisting. Individual types of ichthyosis can be differentiated from each other by detailed history, meticulous clinical examination, and electron microscopic features of skin biopsy specimens. In all cases, other systemic involvements must be looked for to rule out ichthyosiform syndromes.

ICHTHYOSIFORM SYNDROMES

Sjögren–Larsson Syndrome

Sjögren–Larsson syndrome is an AR disorder characterized by the clinical triad of congenital ichthyosis, neurological impairment, and mental retardation. Mutation of the *ALDH3A2* gene located on chromosome 17p11.2 results in this condition. This gene encodes fatty aldehyde dehydrogenase (FALDH), which catalyzes oxidation of medium- and long-chain fatty aldehyde to fatty acids. Abnormal lipid accumulation in skin and brain results in cutaneous and neurological symptoms.

The ichthyosis is present at birth which may rarely present as collodion baby. Scales are variable, ranging from velvet-like fine white to large, plate-like **(Figs. 21A and B)**. Associated pruritus is a distinct feature in this type of ichthyosis. Neurological manifestations appear



Figs. 21A and B: (A) Large plate-like scales and diplegia in a case of Sjögren–Larsson syndrome; (B) Diffuse fine scaling with diplegia in a child with Sjögren–Larsson syndrome.

JAYPEE BROTHERS

Textbook of
Pediatric Dermatology

Salient Features

- The third edition of "*Textbook of Pediatric Dermatology*" has been planned to update the recent advancement in the field.
- Almost 900 clinical photographs, more than 170 tables, and a large number of flowcharts have been incorporated to ensure easy readability.
- Recent advances in pathogenesis, diagnosis, and management of skin diseases in children are incorporated, and this edition will continue to stimulate interest among dermatologists and pediatricians helping them to deal with childhood dermatoses proficiently.

Ragunatha Shivanna MD is Director–Professor and Head, Department of Dermatology, Venereology and Leprosy, ESIC Medical College and PGIMSR, Rajajinagar, Bengaluru, Karnataka, India. He has 50 publications in indexed journals and contributed 40 chapters in various national and international textbooks. He has worked as Assistant Editor for ACS(I) Textbook on Cutaneous and Aesthetic Surgery and as Section Editor in IADVL Textbook of Dermatology (5th edition). He was Editor-in-Chief of Clinical Dermatology Review journal from 2020 to 2023. He was a recipient of the International League of Dermatological Society (ILDS) Scholarship (WCD, Buenos Aires, 2007; WCD, Vancouver 2015; WCD, Milan 2019), International Congress of Dermatology Scholarship (ICD, Prague, 2009), and Imrich-Sarkany Non-European Memorial Scholarship (EADV, Gothenburg, 2010). He has delivered Professor Dr Shivakumar and Professor Dr K Rajendran Oration and received Young Dermatologist Award in CUTICON-KN. His areas of interest are pediatric dermatology, dermoscopy, and leprosy.

Aparna Palit MD is Professor and Head, Department of Dermatology, Venereology and Leprosy and Dean (Research), All India Institute of Medical Sciences, Kalyani, West Bengal, India. She has 183 published articles in indexed journals and has contributed more than 40 chapters in various textbooks and co-edited 7 books and monographs in dermatology. She is a recipient of IADVL-AAD Fellowship (2008), Professor LK Bhutani Memorial Award for Teaching and Research (2012), ICMR Travel Fellowship for attending World Congress of Dermatology (2015), and Professor Dr Shivakumar and Professor Dr K Rajendran Memorial Oration at CUTICON-KN in 2016. She has presented papers and delivered guest talks in several national and international meets. Her areas of interest are pediatric dermatology and leprosy. She has keen interest in medical writing and publication.

Arun C Inamadar MD DVD FRCP(London) FAAD is Vice Chancellor, BLDE University and Professor, Department of Dermatology, Venereology and Leprosy, Shri BM Patil Medical College, Hospital and Research Center, BLDE University, Vijayapura, Karnataka, India. He is a dedicated academician with more than 400 published articles in indexed and nonindexed journals. He has contributed more than 30 chapters in various textbooks and edited four books in dermatology. He has presented papers and delivered guest talks in several national and international meets. He has been awarded the WHO fellowship (USA), IADVL-Glaxo SmithKline Oration (2009), and Professor LK Bhutani memorial award for teaching and research (2011). His path-finding work on cutaneous manifestations of "Chikungunya fever" and detailed review on the concept of acute skin failure are well known. He has served the Indian Association of Dermatology, Venereology and Leprology (IADVL) as Vice President and is the Chairperson of IADVL Academy of Dermatology. He is a member of the membership committee of the European Academy of Dermatology and Venereology (EADV). He is International Fellow of the American Academy of Dermatology (AAD). He is a recipient of Professor Surinder Kaur Award for Excellence in Pediatric Dermatology by the International Society of Pediatric Dermatology. He is Editorial Board Member of Pediatric Dermatology Journal, Associate Editor of BMJ Case Reports, and Reviewing Editor of Springer Nature Reviewer Community. He is Founder Editor of Clinical Dermatology Review journal. His areas of interest are pediatric dermatology (namely, genodermatology), clinical/medical dermatology, and critical care in dermatology.

JAYPEE BROTHERS

Shelving Recommendation
DERMATOLOGY

ISBN 978-93-7545-501-1

Buy from ejaypee

JAYPEE BROTHERS