jaypee.com, for detailed information on dermatology books, visit our website www.ejaypee.com, for detailed information on dermatology books

Year Book of

Facial Hyperpigmentation

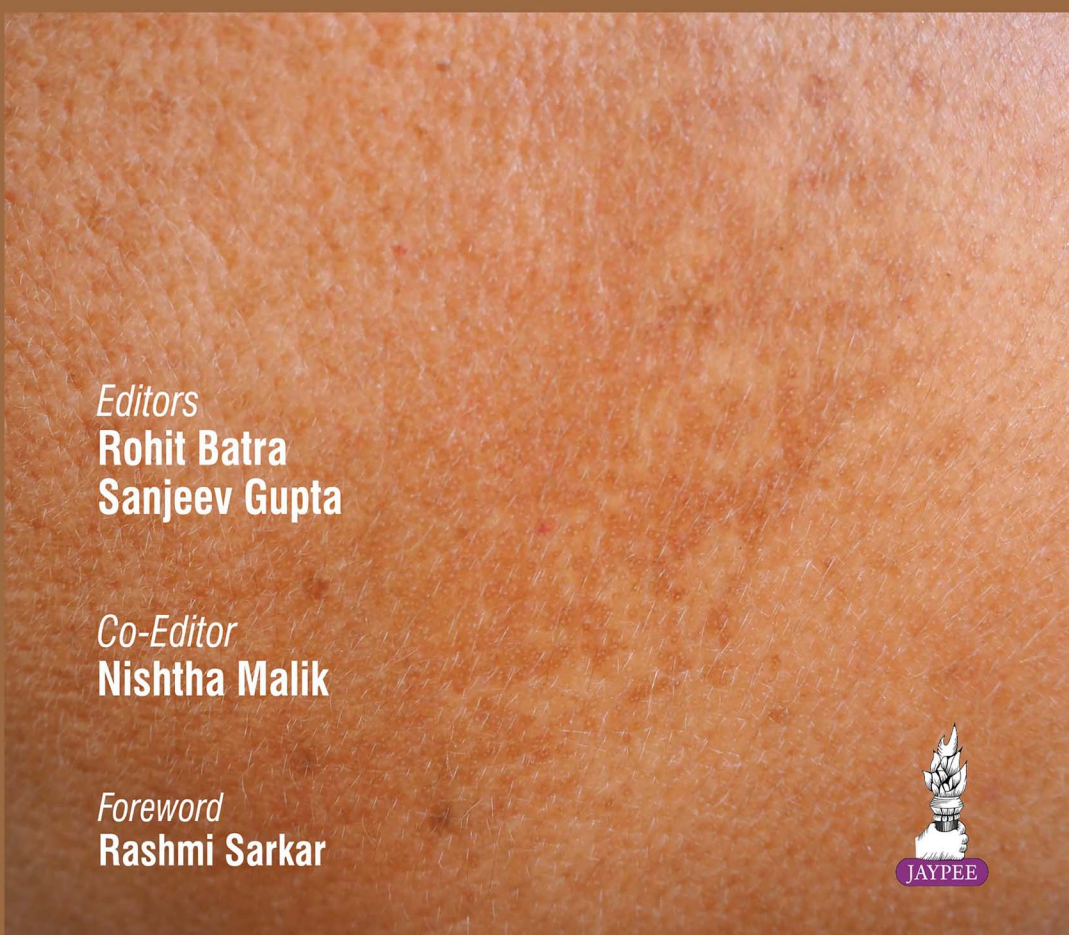

Editors
Rohit Batra
Sanjeev Gupta

Co-Editor
Nishtha Malik

Foreword
Rashmi Sarkar

JAYPEE

CONTENTS

Section 1: Epidemiological Studies

Section Editors: Rohit Batra, Nishtha Malik, Sanjeev Gupta

Chapter 1.1: Facial Hyperpigmentation: Epidemiology Across Populations **3**

1. Melasma Revisited: National Survey Reveals How Dermatologists Diagnose and Treat this Complex Skin Condition 3
2. Infraorbital Hyperpigmentation (Dark Circles): A Study of its Prevalence, Etiology and its Association with Other Dermatological Symptoms among Young Adults 4
3. Melasma: A Clinical and Epidemiological Single-group Observational Study in the Greek Population 5
4. The Burden of Melasma: Race, Ethnicity, and Comorbidities 7

Section 2: Diagnosis

Section Editors: Sanjeev Gupta, Rohit Batra, Nishtha Malik

Chapter 2.1: Dermoscopy **11**

1. Dermoscopic Patterns of Facial Melanoses in Adult Patients: A Cross-sectional Study 11
2. 51985 Dermoscopy of Acquired Pigmentation Disorders in Skin of Color 12
3. Clinical and Dermoscopic Characteristics of Exogenous Ochronosis: Results of a Multicentre Study by the International Dermoscopy Society Dermoscopy in Skin of Color Task Force 13
4. A Clinico-epidemiological Study of Different Dermoscopic Patterns in Hyperpigmented Facial Lesions in a Tertiary Care Center 15
5. Facial Dyschromias: A Review of Clinical and Dermoscopic Features 16

Chapter 2.2: Histopathology **18**

1. Histopathological Spectrum of Hyperpigmented Skin Lesions—A Study in a Tertiary Hospital from Western Uttar Pradesh 18
2. Lichen Planus Pigmentosus: A Clinicopathological Study from Northeast India 19
3. Dermoscopy of Lichen Planus Pigmentosus and Histopathological Correlation: A Case Series 20

Section 3: Management

Section Editors: Arushi Nanda, Sanjeev Gupta, Rohit Batra, Nishtha Malik

Chapter 3.1: Melasma **25**

Tranexamic Acid

1. Efficacy of Oral, Topical, and Intradermal Tranexamic Acid in Patients with Melasma—a Meta-analysis 25
2. Effectiveness of Topical Tranexamic Acid in the Treatment of Melasma 26
3. Effectiveness of Oral Tranexamic Acid in the Treatment of Melasma: A Systematic Review 27
4. Treatment-resistant Melasma Response to Oral Tranexamic Acid 28
5. Efficacy and Safety of Microneedling with Topical Tranexamic Acid for Melasma Treatment: A Systematic Review and Meta-analysis 29
6. Oral Tranexamic Acid Treatment beyond 6 Months for Melasma Patients: A Retrospective Case Series 31
7. Efficacy and Safety of Mesotherapy with Tranexamic Acid versus Vitamin C in Treatment of Melasma: A Meta-analysis and Systemic Review 32
8. Assessing the Efficacy of Oral Tranexamic Acid as an Adjuvant to Triple Combination Topical Treatment in Melasma: A Meta-analysis of Randomized Controlled Trials 33
9. Comparison of Efficacy of 5% Tranexamic Acid versus 20% Azelaic Acid in Patients of Melasma 34
10. Papulonodular Acneiform Eruptions in Melasma Patients after Initiation of Oral Tranexamic Acid: A Report of Three Cases 35
11. Melasma: A Step-by-Step Approach toward a Multimodal Combination Therapy 38
12. Fractional Carbon Dioxide Laser-assisted Delivery of Tranexamic Acid versus Ascorbic Acid in the Treatment of Melasma: A Split-face Comparative Study with Digital Skin Analysis 39
13. Pilot Clinical Safety and Efficacy Evaluation of a Topical 3% Tranexamic Acid Cream and Serum Protocol for Managing Facial Hyperpigmentation in Caucasian Patients 40
14. Dual Benefits of Oral Tranexamic Acid: Reducing Melasma Severity and Inflammation 42
15. Comparative Efficacy of Tranexamic Acid and Vitamin C with Microneedling: A Split-face Study in Melasma Management 43

Hydroquinone

1. Efficacy and Safety of Nicotinamide 10%, Associated with Magnesium Ascorbyl Phosphate 5% and Hyaluronic Acid 5%, Compared to Hydroquinone 4% in Women with Facial Melasma: A Randomized, Double-blind, Controlled Clinical Trial 44

2. Review on Skin Lightning and Management of Pigmentation, by Using Natural Ingredient 45
3. A Randomized, Controlled, Split-face, Double-blind Comparison of Multimodality Pigment-correcting Serum Containing Lotus Sprout Extract versus Hydroquinone for Moderate-to-severe Facial Hyperpigmentation, Including Melasma, in a Diverse Population 46
4. Melasma Management in Primary Care 48
5. The Efficacy of Topical Cosmetic Containing Alpha-arbutin 5% and Kojic Acid 2% Compared with Triple Combination Cream for the Treatment of Melasma: A Split-face, Evaluator-blinded Randomized Pilot Study 49
6. Effectiveness of a Standardized Treatment Protocol in the Management of Melasma: A Retrospective Analysis 50
7. Combination of Plasma Rich in Growth Factors with Topical 4% Hydroquinone Compared with Topical 4% Hydroquinone Alone in the Treatment of Dermal Type of Melasma: A Single-blinded Randomized Split-face Study 51
8. Evaluation of Efficacy of Serum Containing Niacinamide, Tranexamic Acid, Vitamin C, and Hydroxy Acid Compared to 4% Hydroquinone in the Management of Melasma 52
9. The Effectiveness and Safety of 3% Tranexamic Acid Cream versus 4% Hydroquinone Cream for Mixed-type Melasma in Skin of Color: A Double-blind, Split-face, Randomized Controlled Trial 54
10. Diffuse Facial Leukoderma Secondary to Localized Use of Hydroquinone 55
11. Sequential Therapy with Topical Clobetasol for 14 Days Followed by Hydroquinone versus Hydroquinone Alone in Facial Melasma Treatment: A Randomized, Double-blind, Controlled Clinical Trial 55

Kojic Acid

1. Comparison of the Effectiveness and Safety of 5% Cysteamine and 2% Kojic Acid Creams in the Treatment of Melasma in Indian Adult Females 57
2. A Review of Therapies for Hyperpigmentation Modulating the Synthesis of Eumelanin to Pheomelanin 58
3. The Effect of Emulgel Preparation on the Stability of Kojic Acid in the Topical Anti-hyperpigmentation Products 59

Peels

1. 80% Lactic Acid Peel versus 50% Glycolic Acid Peel for Melasma: A Randomized Clinical Trial 60
2. Comparison of Efficacy and Safety of Low-fluence Neodymium-doped Yttrium Aluminium Garnet Laser versus Glycolic Acid Peeling in Patients of Melasma: A Split-face Study 62
3. Multi-acid Synergistic Peel Technology for Professional Use to Reduce Hyperpigmentation: Clinical Evidence and Mechanistic Understanding 63
4. Effectiveness of a Standardized Treatment Protocol in the Management of Melasma: A Retrospective Analysis 64

Azelaic Acid

1. Comparative Study of Effectiveness between 20% Azelaic Acid with Low-fluence 1064-nm ND:YAG Picosecond Laser and 20% Azelaic Acid Alone in the Treatment of Melasma in Thai Female Patients, Split-face, Prospective Study 65
2. Efficacy, Safety, and Cost-effectiveness of Glycolic Acid versus Azelaic Acid in Melasma 66
3. 755-nm Picosecond Laser Plus Topical 20% Azelaic Acid Compared to Topical 20% Azelaic Acid Alone for the Treatment of Melasma: A Randomized, Split-face and Controlled Trial 67

Arbutin

1. Effectiveness and Safety of Combined Use of Home-based Radiofrequency Device and Arbutin Cream in Melasma and Facial Rejuvenation 68
2. Comparative Efficacy of Skin-lightening Formulations in Suppressing Ultraviolet B (UVB)-induced Arachidonic Acid, Alpha-melanocyte-stimulating Hormone (α-MSH), and Melanin Expression: An in vitro Keratinocyte Melanocyte Co-culture Study 70
3. Efficacy and Safety of a Topical Formulation Containing Trihydroxybenzoic Acid Glucoside and α-Arbutin, Applied Along with a Sunscreen: A Noncomparative, Prospective, Interventional Study in Indian Females with Facial Melasma or Dark Spots 71

Cysteamine

1. Comparison of the Effectiveness and Safety of 5% Cysteamine and 2% Kojic Acid Creams in the Treatment of Melasma in Indian Adult Females 73
2. Efficacy of Overnight Leave-on Sandwich Therapy with 5% Cysteamine and Ectoine Cream Compared to Hydroquinone 4% Cream for Treatment of Melasma: A Double-blind Randomized Controlled Trial 74

Sunscreen

1. Sunscreens Prescribed to Patients with Skin of Color and/or with Melasma: A Survey of 221 Dermatologists and Dermatology Residents in Spain 75
2. Sunscreens in Pigmentary Disorders: Time to Revise the Message 77
3. Sunscreen Use for Photoprotection in Skin of Color: A Literature Review 78

Lasers

1. Definition of Refractory Melasma and its Treatment: A Review 79
2. Efficacy and Safety of Q-switched 1064/532 nm Nd:YAG Lasers on Benign Hypermelanosis in Dark-skinned Individuals—A Preliminary Study 80
3. Management of Melasma: Laser and Other Therapies—Review Study 81
4. Evaluation the Safety and Efficacy of Fractional CO_2 Laser in the Treatment of Melasma 82

5. Comparative Efficacy and Safety of the Novel Picosecond Alexandrite Laser and the Traditional Combined Q-switched and Long-pulse Nd:YAG Lasers in Melasma Treatment: A Randomized Evaluator-blinded Trial 83
6. Comparative Observation of the Efficacy of Q-switched Nd:YAG Laser with PhotoAcoustic Technology Pulse versus Traditional Mode in Treating Melasma 84
7. Novel Melasma Therapy Using Combined Low Fluence and Microsecond Pulse Q-switched 1064 nm Neodymium Doped Yttrium Aluminium Garnet Laser 86

Miscellaneous

1. Efficacy and Tolerability of a Microneedling Device Plus Exosomes for Treating Melasma 87
2. Glutathione as a Skin-lightening Agent and in Melasma: A Systematic Review 88
3. Comparison of Platelet-rich Plasma Efficacy with and without Photoactivation in Melasma: A Randomized Double-blind Study 89
4. Melasma Management: A Comprehensive Review of Treatment Strategies Including BTX-A 90
5. Efficacy of Subdermal Poly-D,L-lactic Acid Injections for the Treatment of Melasma 92
6. Unveiling Tyrosinase Inhibitors: Current Challenges and Future Directions in Hyperpigmentation Therapy 93
7. Exploring the Safety and Efficacy of Glutathione Supplementation for Skin Lightening: A Narrative Review 94

Chapter 3.2: Periorbital Hyperpigmentation 96

1. Platelet-rich Plasma Injection Combined with Q-switched Ruby Laser in the Treatment of Periorbital Hyperpigmentation 96
2. Treatments for Periorbital Hyperpigmentation in Fitzpatrick Skin Types IV–VI: A Systematic Review 97
3. Frequency of Periorbital Hyperpigmentation Risk Factors 98
4. Illuminating the Shadows: An Insight into Periorbital Hyperpigmentation 99
5. Is Acanthosis Nigricans, Periorbital/Perioral Pigmentation, Maturational Hyperpigmentation, Pigmented Transverse Nasal Band, and Cutaneous Amyloidosis a Frictional Dermatitis a Feature of Frictional Dermatitis Developed on Atopic Dermatitis Skin? 101
6. The First Systematic Review and Meta-analysis of Pharmacological and Nonpharmacological Procedural Treatments of Dark Eye Circles (Periorbital Hyperpigmentations): One of the Most Common Cosmetic Concerns 102
7. Nonablative Fractional 1927-nm Laser for Periorbital Rejuvenation: A Prospective, Double-arm, Open-label Trial 103
8. Evaluation of the Effects of Carboxytherapy in Treatment of Periorbital Dark Circles 105

Chapter 3.3: Postinflammatory Hyperpigmentation **107**

1. Assessing the Effectiveness of Stabilized Cysteamine 5% Cream Compared to Hydroquinone 4%/Ascorbic Acid 3% Combination Cream in Treating Acne-induced Postinflammatory Hyperpigmentation: A Randomized, Controlled Study 107
2. Therapeutic and Preventive Effects of Light-emitting Diode (LED) for Postinflammatory Erythema and Hyperpigmentation: A Pilot Study 108
3. Treatment of Postinflammatory Hyperpigmentation in Skin of Color: A Systematic Review 109
4. Experience of Using Intense Pulsed Light Safely and Effectively, with Cases Sharing of Treating Postinflammatory Hyperpigmentation with Different Origins 110
5. Oral Tranexamic Acid for Prevention and Treatment of Postinflammatory Hyperpigmentation 111
6. Predictive Factors of Acne Scarring and Postinflammatory Hyperpigmentation: A Retrospective Cohort Study 113
7. Multimodality Management of Skin Hyperpigmentation 114
8. Low-fluence Q-switch 1064 nm Laser Combined with Oral Tranexamic Acid: A Quicker Treatment for Laser-induced Postinflammatory Hyperpigmentation 115
9. A Pilot Study on the Comparative Efficacy and Tolerability of a Novel Dermocosmetic Cream with 15% Azelaic Acid for Mild-to-moderate Acne: A New Approach to Acne Treatment 116
10. Concurrent Management of Vitiligo and Acquired Disorders of Hyperpigmentation: A Comprehensive Literature Review and Current Practice Gaps 117
11. Anti-acne and Reduction of Hyperpigmentation Effects of Products Containing Retinol, Niacinamide, Ceramides, and Dipotassium Glycyrrhizinate in Chinese Women 119
12. Pathophysiological Insights into Facial Hyperpigmentation and Aesthetic Treatment Modalities 120
13. Sunscreens in Pigmentary Disorders: Time to Revise Message 121
14. A Comprehensive Review of the Role of Ultraviolet Radiation in Photoaging Processes between Different Types of Skin 122
15. Importance of Treating Acne Sequelae in Skin of Color: 6-month Phase IV Study of Trifarotene with an Appropriate Skincare Routine Including UV Protection in Acne-induced Postinflammatory Hyperpigmentation 123

Chapter 3.4: Lichen Planus Pigmentosus **125**

1. The Efficacy of Platelet-rich Plasma in Facial Lichen Planus Pigmentosus: A Prospective Pilot Study 125

2. Generalized Lichen Planus Pigmentosus and a New Management Approach 126
3. Hyperpigmented Macules and Patches on the Face: Exogenous Ochronosis or Lichen Planus Pigmentosus? 128

Chapter 3.5: Riehl's Melanosis 130

1. Riehl Melanosis 130
2. Case Report: Usefulness of a Picosecond Alexandrite Laser Therapy on Atypical Henna-induced Riehl's Melanosis Inferred from Immunohistochemical Analyses 131
3. Efficacy and Safety of the Combination of Oral Tranexamic Acid and Intense Pulsed Light versus Oral Tranexamic Acid Alone in the Treatment of Refractory Riehl's Melanosis: A Prospective, Comparative Study 132

Chapter 3.6: Facial Acanthosis 134

1. Review of Facial Acanthosis Nigricans: Easy to Diagnose and Difficult to Treat Marker of Hyperinsulinemia/Metabolic Syndrome 134
2. Clinical Features, Investigative Profile, and Association with Metabolic Syndrome in Facial Acanthosis Nigricans: A Case–Control Study in Indian Patients 135
3. Addressing the Cardiovascular Implications of Acanthosis Nigricans: What a Dermatologist Needs to Know 136
4. An Indian Expert Group Review of Acanthosis Nigricans with Recommendations for Early Detection and Timely Management 138
5. Efficacy of 15% Trichloroacetic Acid Peel versus 35% Glycolic Acid Peel in Acanthosis Nigricans: A Randomized Open-label Study 139

Chapter 3.7: Solar Lentigines and Freckles 141

1. Treatment of Solar Lentigines: A Systematic Review of Clinical Trials 141
2. Postoperative Risk Assessment of Postinflammatory Hyperpigmentation and the Efficacy of Delayed Prevention Following 532 nm Q-switched Nd:YAG Laser Treatment of Solar Lentigines: A Randomized Controlled Study 142
3. A Novel Combination of Broad Band Light (BBL® HERO™) and Nonablative Fractionated 1927 nm (MOXI™) Laser for Addressing Solar Lentigines 143
4. Comparing a Low-fluence Picosecond 1064 nm Nd:YAG Laser with a 532 nm Nd:YAG Laser for the Treatment of Pigmented Lesions in Chinese Patients: A Retrospective Analysis 144
5. Clinical Evaluation of Liposome-based Gel Formulation Containing Glycolic Acid for the Treatment of Photodamaged Skin 146
6. Successful Treatment of Freckles Using a 730-nm Picosecond Laser: A Prospective Study 147

7. Comparison of Efficacy and Safety of Fractional CO_2 Laser versus 70% Trichloroacetic Acid Peel in the Treatment of Facial Freckles and Lentigines 148
8. Efficacy and Safety of 577-nm Yellow Laser in the Treatment of Pigmented Epidermal Lesions 149

Chapter 3.8: Exogenous Ochronosis 151

1. Administration of Exosome-based Treatment for Exogenous Ochronosis Caused by Prolonged Use of Topical Hydroquinone 151

Chapter 3.9: Nevus 153

Beckers Nevus

1. Successful Treatment of Challenging Becker's Nevus with Continuous Low-fluence Q-switched Nd:YAG 1064 nm Laser and Long-pulsed Nd:YAG 1064 nm Laser 153
2. Atypical Location of Becker Nevus on Face–Clinical and Dermoscopic Features: A Case Report 154

Nevus of Ota

1. Congenital Halo Nevus Associated with Vitiligo Aggravated by Lasers Targeting Nevus of Ota: A Case Report 155
2. Comparison of the Efficacy and Safety of A 730-nm Picosecond Titanium Sapphire Laser and a 1064-nm Picosecond Neodymium Yttrium Aluminum Garnet Laser for the Treatment of Acquired Bilateral Nevus of Ota-like Macules: A Split-face, Evaluator-blinded, Randomized, and Controlled Pilot Trial 156
3. Analysis of Efficacy of Picosecond Laser Treatment for Nevus of Ota 157
4. Nevus of Ota with Excellent Response to Q-switched Nd:YAG (1064 nm) Pigmented Laser: A Case Report 159
5. Overlapping Large Facial Nevus Spilus and Nevus of Ota: A Case Report Diagnosed with Dermoscopy and Reflectance Confocal Microscopy 160
6. Acquired Bilateral Nevus of Ota-like Macules: A Case Report 161
7. Laser and Energy-based Devices for the Treatment of Pigmented Lesions in Asians 162
8. Comparison of the Efficacy of 1064 and 730-nm Picosecond Lasers for Acquired Dermal Melanocytosis 162

Melanocytic Nevus

1. Serial Skin Grafting Technique for Management of a Facial Giant Congenital Melanocytic Nevus: Case Report with a Literature Review 164
2. Successful Treatment of Facial Multiple Melanocytic Nevus-like Dark Macules Caused by Severe Acne Vulgaris by a Single Session of Intense Pulsed Light Treatment 165

3. Serial Tissue Expansion and Skin Grafts in the Management of a Giant Congenital Nevus of the Face: Review of Literature and Case Report 166
4. Using a Zipper Device to Minimize Scarring after Excision of Facial Nevi in Pediatric Patients 167

Home-based Care and Over-the-counter Treatment Options

1. A Practical Guide to Over-the-counter Treatments for Hyperpigmentation 168
2. Integrating Skincare into Medical Practice 169
3. Efficacy of Natural Products as Tyrosinase Inhibitors in Hyperpigmentation Therapy: Anti-melanogenic or Anti-browning Effects 170
4. Vitamin C: Its Role in Cosmeceuticals 171
5. Guide to Tinted Sunscreens in Skin of Color 172
6. 54330 Cosmeceuticals for Melasma and Hyperpigmentation: Reviewing the Evidence and Political Influences 173

Section 4: Novel Developments and Updates in the Management of Facial Hyperpigmentation

Section Editors: Rohit Batra, Sanjeev Gupta, Nishtha Malik, Arushi Nanda

Chapter 4.1: Novel Advances in Facial Hyperpigmentation Management 177

1. Topical Isoniazid as a Novel Treatment for Melasma: A Randomized, Double-blind, Vehicle-controlled Clinical Trial 177
2. An Update on New and Existing Treatments for the Management of Melasma 178
3. A Novel Professional—Use Synergistic Peel Technology to Reduce Visible Hyperpigmentation on Face: Clinical Evidence and Mechanistic Understanding by Computational Biology and Optical Biopsy 179
4. The Remarkable Role of Nano-phytocosmeceuticals for Elevating Skincare in Facial Hyperpigmentation 180
5. Evaluation of a Novel Dermal Cooling System for the Treatment of Benign Pigmented Lesions in Asians 181
6. Hybrid Skin Booster Injectables Hyaluronic Acid with Growth Factors and/or Hyperdiluted Calcium Hydroxyapatite "For Treating Facial Skin Pigmentations" 182
7. The Efficacy of a Novel Tomato Extracts Formulation on Skin Aging and Pigmentation: A Randomized, Double-blind, Parallel-controlled Trial 184
8. Full-face and Neck Resurfacing with a Novel Ablative Fractional 2910 nm Erbium-doped Fluoride Glass Fiber Laser for Advanced Photoaging 185
9. Combined Thiamidol and Low-fluence Q-switched Nd:YAG Laser for the Treatment of Facial Hyperpigmentation 186

10. Efficacy of a 2-MNG-containing Depigmenting Serum in the Treatment of Postinflammatory Hyperpigmentation 188
11. Small-molecule Tyrosinase Inhibitors for Treatment of Hyperpigmentation 189
12. Efficacy of Natural Products as Tyrosinase Inhibitors in Hyperpigmentation Therapy: Antimelanogenic or Antibrowning Effects 190
13. A Multimodal Approach to Acne-induced Postinflammatory Hyperpigmentation: Trifarotene as a Long-term Intervention 191
14. Advancements in Hyperpigmentation Management: Exploring Conventional Methods, Phytoconstituents, Novel Approaches, and Instrumental Techniques 192
15. A Concise Review on Contemporary and Novel Treatments Addressing the Prevention and Control of Hyperpigmentation 193
16. Vitamin K (Menadione)-incorporated Chitosan/Alginate Hydrogel as a Novel Product for Periorbital Hyperpigmentation 194
17. Efficacy and Safety of Novel Topical Pigment-correcting Regimen with Biweekly Diamond Tip Microdermabrasion Procedures on Facial Hyperpigmentation 196
18. Evaluation of Pomegranate Seed Extract as a Tyrosinase Inhibitor for Hyperpigmentation Treatment 197
19. Exosomes in Dermatology: A Comprehensive Review of Current Applications, Clinical Evidence, and Future Directions 198
20. Efficacy and Safety of a Novel Weekly Topical Metformin-loaded Peel-off Mask in the Treatment of Melasma: A Split-face, Placebo-controlled Study 199
21. Efficacy of Rose Stem Cell-derived Exosomes in Skin Treatment: From Healing to Hyperpigmentation Management: Case Series and Review 200
22. Ionized Plasma Jet Therapy in Removal of Dermatosis Papulosa Nigra 201
23. Maturational Hyperpigmentation: An Update 202
24. Discovery of Novel Diesters Incorporating Kojic Acid with NSAIDs and Palmitic Acid as Dual Inhibitor of Melanogenesis and Inflammation 203
25. Preparation and Evaluation of Nanoemulsion Formulation Containing Kojic Acid and Kojyl 3-aminopropylphosphonic Acid 205
26. The Kesty Hyperpigmentation Scale: A Study to Validate a New Tool for Assessing Facial Hyperpigmentation 206

Section 5: Quality of Life in Patients with Facial Hyperpigmentation

Section Editors: Sanjeev Gupta, Rohit Batra, Nishtha Malik

Chapter 5.1: Impact of Facial Hyperpigmentation on Quality of Life 211

1. An Eye-tracking and Questionnaire Study of How Facial Pigmentation Spot are Perceived by Laypeople 211
2. Assessment of Dermatological Quality of Life Index in Patients Attending to Laser Unit 212

3. Clinical and Dermoscopic Evaluation of Periorbital Melanosis and its Psychological Impact and Effect on Quality of Life: A Descriptive Study 213
4. Prevalence of Postinflammatory Hyperpigmentation, Impact on Quality of Life and Social Stigmatization: Results of the First Large International Survey 214
5. Melasma and Its Effect on Quality of Life: A Cross-sectional Perspective 215
6. Prevalence of Depression in Melasma: A Systematic Review and Meta-analysis 217
7. Assessing Impact of Melasma on Quality of Life using Hindi-Melasma Quality of Life Index Scale and Melasma Area and Severity Index Score 218
8. Quality of Life in Patients with Acquired Dermal Macular Hyperpigmentation: A Systematic Review 219
9. A Clinico-epidemiological Study and Quality of Life Assessment in Melasma at a Tertiary Care Centre in South India 220

Section 6: Interesting Case Reports

Section Editors: Nishtha Malik, Arushi Nanda, Sanjeev Gupta, Rohit Batra

Chapter 6.1: Case Reports 225

1. An Unusual Presentation with Facial Hyperpigmentation on Escalation of Dose of Sertraline 225
2. Facial Hyperpigmentation: A Rare Side Effect of Adalimumab 226
3. Facial Lichen Planus Pigmentosus-like Pigmentation Induced by Vicks VapoRub: A Case Report 227
4. Hyperpigmentation in a Child as Clue to Chikungunya 228
5. Slate Gray Perioral Pigmentation in a Boy 229
6. Polymyxin-B-induced Rapid Hyperpigmentation Confined to Face: A Rare Case Report with Literature Review 231
7. Velvety Perioral Enigma 232
8. Unmasking Pigmented Macular Chronic Cutaneous Lupus Masquerading as Lichen Planus Pigmentosus 233
9. Golimumab-induced Lichen Planus Pigmentosus in a Patient with Ulcerative Colitis 234
10. Blaschkoid Lichen Planus Pigmentosus on Face 236
11. A Case Series on a Rare Clinical Presentation of Lichen Planopilaris Restricted to the Face 237
12. Bilateral Hyperpigmented Linear Streaks on the Face: An Unusual Presentation of Allergic Contact Dermatitis 238
13. Lichen Planus Pigmentosus as a Cutaneous Extrahepatic Manifestation of Chronic Hepatitis C Virus Infection: A Case Report 239

Index **241**

CHAPTER

5.1 Impact of Facial Hyperpigmentation on Quality of Life

1. An Eye-tracking and Questionnaire Study of How Facial Pigmentation Spot are Perceived by Laypeople

Tanaka OM, Gasparello GG, Berlesi AH, de Lima LG, Busche GI, Miyagusuku LF, et al. An eye-tracking and questionnaire study of how facial pigmentation spot are perceived by laypeople. Res Soc Develop. 2024;13(1):e2613144654.

Abstract

Facial skin pigmentation is one of the most prominent visible features in everyday interactions and often influences the perception of beauty. There is currently no evidence on how facial pigmentation spots can influence aesthetic perception. The objective was to evaluate the perception of aesthetics and the attractiveness of smiling photos with the presence of facial pigmentation spots in different locations on the face. Four images of the smiling face were used in the frontal pattern, standardized and modified with the help of Photoshop®: No pigmentation spots, spots below the right perioral region, above the upper left perioral region, and in both the lower right region and upper left region of the face. The Eye-tribe hardware and Ogama software were used for eye-tracking, and a questionnaire with two questions—"Judging aesthetic aspects, do you consider this person attractive and beautiful?" and "What stood out the most about this image?"—was applied to laypeople observers with a word cloud typed on the Mentimeter. The dot maps showed that in all pigmentation spots positions, the right eye and the smile in the area of the central incisors attracted the most attention of laypeople. The smile was the most cited, with emphasis on the words "eyes" and "teeth" in Mentimeter. Facial pigmentation spots in different locations did not interfere with aesthetic perception. The face without the presence of nevi was considered the most attractive, and the smile, teeth, and eyes were the structures that most caught the attention of the laypeople.

COMMENT

This eye-tracking and questionnaire-based study investigated how laypeople perceive facial pigmentation spots in terms of attractiveness. Standardized photographs of a smiling Caucasian female model—with and without facial pigmentation spots at various locations—were analyzed using EyeTribe hardware and OGAMA (Open Gaze and Mouse Analyzer) software. 91 observers rated attractiveness using a visual

JAYPEE BROTHERS

analogue scale and identified attention-capturing facial features via a Mentimeter word cloud. Across all images, the smile and eyes particularly the right eye and central incisors drew the most attention. Faces without pigmentation spots received slightly higher attractiveness scores, though the differences were not statistically significant. Female observers generally rated images more favorably than males. Interestingly, the term "spot" was infrequently mentioned, indicating that pigmentation spots did not significantly impact aesthetic perception. The study concluded that small nevi (<5 mm) did not detract from perceived beauty. However, it acknowledged limitations in real-life applicability, as screen-based assessments may not fully capture interpersonal dynamics.

2. Assessment of Dermatological Quality of Life Index in Patients Attending to Laser Unit

Mohammed EM, Mahmoud WA, Rahim SQ. Assessment of dermatological quality of life index in patients attending to laser unit. Al-Azhar Assiut Med J. 2025;23(1):39-45.

Abstract

Background and aim: Many dermatological diseases have an impact on daily life activity. Dermatology Life Quality Index (DLQI) is a self-administered general dermatology quality of life (QoL) instrument. It is an easy and efficient tool for assessing the QoL in dermatology patients. We aimed to assess the psychological and social impact of chronic dermatological diseases on patients attending the laser unit by using the DLQI questionnaire.

Patients and methods: This is a cross-sectional study that was conducted on 300 patients showing various clinical forms of dermatological disorders. They were selected from patients who attended the laser unit of the Dermatology and Andrology Department of Al-Azhar University Hospital (Assuit).

Results: The total mean DLQI was 10.42. Skin disorders presented with poor QoL and high-DLQI score were hirsutism, melasma, acne, rosacea, postburn scar, nevus of Ota, Becker's nevus, and port-wine stain, with mean DLQI score of 16.77, 14.71, 13.63, 12.36, 12.34, 11.55, 11.25, and 10.0, respectively. However, skin disorders presented with mild or moderate DLQI scores were freckles, tattoo, keloid, stria rubra, and hypertrichosis, with mean DLQI scores of 6.16, 6.27, 7.80, 8.20, and 8.47, respectively.

Conclusion: Most dermatological diseases can affect QoL. DLQI is a valuable tool for the assessment of the impact of different skin disorders on QoL.

COMMENT

This cross-sectional study assessed the psychological and social impact of chronic pigmentary dermatological conditions in patients attending the laser unit at a tertiary

JAYPEE BROTHERS

hospital using the DLQI. 300 patients with various pigmentary, hair, sebaceous gland, and scar disorders were evaluated. Hirsutism, melasma, acne, rosacea, postburn scars, nevus of Ota, Becker's nevus, and port-wine stain were linked to greater impairment in quality of life. Freckles, tattoos, keloids, striae rubra, and hypertrichosis were associated with milder effects. Facial involvement strongly influenced DLQI scores across conditions. DLQI scores correlated with patient age in several disorders: Younger patients with melasma experienced greater impact, while older patients with hirsutism, acne, and rosacea showed higher scores. Female patients with tattoos reported greater psychosocial burden than males.

Limitations included reliance solely on DLQI for assessment, and recruitment was limited to laser unit patients, affecting generalizability. The study suggested incorporating additional QoL tools and conducting broader research across diverse populations to better understand the impact of dermatological diseases on patients' lives.

3. Clinical and Dermoscopic Evaluation of Periorbital Melanosis and its Psychological Impact and Effect on Quality of Life: A Descriptive Study

Banchhor S, Gupta S, Mahendra A. Clinical and dermoscopic evaluation of periorbital melanosis and its psychological impact and effect on quality of life: a descriptive study. Cureus. 2024;16(11).

Abstract

Introduction: Periorbital melanosis (POM) is a poorly defined condition that is becoming an increasing aesthetic concern. With its multifactorial origin, it necessitates a thorough assessment of targeted multimodal treatments. The psychological impact and underlying pathogenesis have been underexplored, as evidenced by the gap between the roughly 100 indexed articles and the 150 million search engine results on treatments for dark circles. This descriptive study aims to explore the clinical and dermoscopic evaluation of POM and its impact on quality of life.

Methods: This descriptive prospective, tertiary hospital-based study included 250 patients with POM attending the Dermatology Outpatient Department. After obtaining informed consent, patients were subjected to clinical assessment, hematological investigations, and Wood's lamp (by Dermaindia, Chennai, India) examination. The dermatoscopic examination was done using a Dino-Lite video dermatoscope AF4515ZT+WF-20 (AnMo Electronics Corporation, Taipei, Taiwan). Quality of life was measured using the Melasma Quality of Life (MELASQoL) scale, and the psychological impact was assessed using the Perceived Stress Scale (PSS) and Body Dysmorphic Disorder Questionnaire-Dermatology Version (BDDQ-DV).

Results: Among 250 patients, 179 (71.6%) were female and 71 (28.4%) were male, with a mean age of 30.53 ± 9.29 years and a disease duration of 6.82 ± 5.04 years. Constitutional POM was the most common type observed in 219 (87.6%) patients. Dermoscopy showed

JAYPEE BROTHERS

blotches in 166 (66.4%), telangiectasia in 211 (84.4%), and exaggerated skin markings in 17 (6.8%), and no atrophic changes were observed. Mean MELASQoL and PSS scores were 25.63 ± 10.52 and 16.64 ± 3.27, respectively; four (1.6%) patients had body dysmorphic disorder.

Conclusion: POM has a complex etiology with multiple underlying mechanisms. Thorough clinical assessment enables accurate diagnosis and a targeted treatment approach. Thus, unnecessary medications and procedures can be avoided by first understanding the underlying pathophysiology. Further studies are warranted in the Indian population with POM, as the skin type, demography, and socioeconomic status are diverse. Various proposed classifications are available but do not cater to the Indian skin type; hence, further research is due.

COMMENT

This prospective study assessed 250 patients with POM, evaluating clinical patterns, dermoscopic features, and psychological impact. The majority were women, with a mean age of 30.5 years and disease duration of 6.8 years. An anatomy-based classification identified four patterns—tear trough, shadow, visible lower eyelid bulge, and dermatochalasis—with tear trough being most prevalent. POM was further categorized into constitutional, postinflammatory, vascular, and shadow types. Grading showed mild POM as the most common. Screen time correlated with severity, with severe POM averaging 6.6 hours/day. Wood's lamp examination differentiated dermal from epidermal pigmentation. Dermoscopy revealed blotches, telangiectasia, and exaggerated skin markings. Aggravating factors included genetic predisposition, anemia, thyroid disorders, atopic diathesis, postinfectious states, poor sleep, sun exposure, prolonged screen time, and topical steroid misuse. The manual stretch test in natural light was emphasized for accurate evaluation. Higher POM grades were associated with poorer quality of life (mean MELASQoL score 25.6). Stress levels were mildly elevated but did not correlate with severity. Body dysmorphic disorder was detected in a small number of patients. The study underlined the importance of individualized management based on detailed clinical assessment. Limitations included the absence of histopathology, ultrasonography, and a control group.

4. Prevalence of Postinflammatory Hyperpigmentation, Impact on Quality of Life and Social Stigmatization: Results of the First Large International Survey

Kerob DK, Passeron T, Alexis A, Dreno B, Wei L, Morita AA, et al. 54728 Prevalence of post-inflammatory hyperpigmentation, impact on quality of life and social stigmatization: results of the first large international survey. J Am Acad Dermatol. 2024;91(3):AB73.

JAYPEE BROTHERS

Abstract

Introduction: Pigmentary disorders (PD), including postinflammatory hyperpigmentation (PIH), are frequent even if little is known on their prevalence and impact. A first worldwide survey evaluating the self-reported prevalence of PD and their impact has been conducted, and results on PIH are presented here.

Materials and methods: This survey (n = 48,000) was conducted in 34 countries from all continents from December 2022 to February 2023. The online autoadministered questionnaire covered demographics, phototype, self-reported pigmentation condition based on a descriptive text and image of each condition, its impact on QoL, stigmatization, and sun protection behavior.

Results: 15% of the population reported suffering from PIH (n = 7,126), mostly women (56%) with a mean age of 39 years. 30% declared having phototype >IV versus 25% worldwide. 71% of people suffering from PIH previously experienced acne pimples and 85% thought that early treatment of acne could have prevented their PIH. 38% had a diagnosis confirmed by a dermatologist, while 16% made their own diagnosis thanks to the questionnaire. For 70% of them, PIH was located on their face. PIH has a major impact on QoL and stigmatization. DLQI score was >10/30 for 35% of them. Besides, 26% faced discrimination at work. 79% protected their skin from sun exposure (only 44% all year long) but just 33% were aware that sun exposure is deleterious to their PIH.

Conclusion: This first large international survey shows the high prevalence of PIH worldwide. It also underlines its significant impact on QoL and stigmatization, and the need for photoprotection education.

COMMENT

This large-scale international survey conducted in 34 countries from all continents assessed the prevalence and psychosocial impact of PIH. PIH affected 15% of subjects, predominantly women with a mean age of 39 years, and was more common in individuals with darker phenotypes (>IV in 30%). Acne was the most frequent precursor, reported in 71%, and 85% believed earlier acne treatment could have prevented PIH. Facial involvement was reported by 70%, with only 38% having a dermatologist-confirmed diagnosis. PIH significantly affected quality of life—35% had a DLQI score >10/30, and 26% reported workplace discrimination. Although 79% used sun protection, only 33% were aware of its relevance to PIH, indicating a need for improved photoprotection awareness.

5. Melasma and Its Effect on Quality of Life: A Cross-sectional Perspective

Ghale RA, Nasimi M, Alidoost S, Talebi M, Ghale RA, Rahmani M, et al. Melasma and Its Effect on Quality of Life: A Cross-Sectional Perspective. Dermatol Pract Concept. 2025;15(1):4601.

JAYPEE BROTHERS

Abstract

Introduction: Melasma is a skin disorder that causes brown spots on the face, especially in females and people with dark skin. This situation can have a significant impact on the patient's quality of life, including issues with self-confidence, mental strain, and difficulty in social and familial relationships.

Objectives: This study aimed to evaluate the quality of life of patients with melasma.

Methods: We conducted a study analyzing the relationship between the severity of melasma and quality of life using the Dermatology Life Quality Index (DLQI) questionnaire.

Results: The study found that severity of melasma, which was measured by the Melasma Area and Severity Index (MASI), was closely related to the degree of maximum darkness in the affected area. The researchers also found a modest impact on quality of life related to the condition, with DLQI scores averaging 6.16, and a strong correlation between MASI scores and quality of life.

Conclusion: Healthcare professionals should also consider the emotional and societal consequences of skin pigmentation conditions in addition to providing medical and therapeutic interventions. Further research is needed to better understand the complex relationships between different factors and their impact on skin health.

COMMENT

This cross-sectional study assessed the quality of life in 111 patients with melasma at a dermatology clinic in Tehran using the DLQI and the MASI. The cohort, predominantly female (96%), had a mean age of 38 years and an average disease duration of 9 years. The mean DLQI score was 6.16, reflecting moderate impairment, particularly in emotional well-being and personal relationships. The average MASI score was 6.73, while the mean Maximum Darkness score was 2.02.

Statistical analyses showed that occupational status, sex, and education significantly affected specific DLQI domains. Both MASI and Maximum Darkness were positively correlated with DLQI scores, though Maximum Darkness demonstrated a slightly stronger association (r = 0.577 vs. 0.510), suggesting that perceived pigment intensity may have a more substantial psychosocial impact than overall disease extent. No significant associations were found between MASI and demographic variables such as age, education, or family history. The study underscored the emotional burden of melasma and the importance of addressing psychosocial dimensions in management. Limitations included a modest sample size and participant noncooperation. Further research on treatment outcomes and regional influences was recommended.

JAYPEE BROTHERS

6. Prevalence of Depression in Melasma: A Systematic Review and Meta-analysis

Chen W, Wan Y, Sun Y, Gao C, Li J. Prevalence of depression in melasma: a systematic review and meta-analysis. Front Psychiatry. 2024;14:1276906.

Abstract

Background: Due to cosmetic disfigurement, melasma can negatively affect the quality of life and emotional and mental health, further leading to depression.

Objective: Prevalence rates of depression in patients with melasma vary widely across studies. The aim of this systematic review and meta-analysis was to estimate the prevalence of depression among melasma patients.

Methods: The PubMed, Embase, Web of Science, and Scopus databases were searched to identify articles evaluating the prevalence of depression in melasma patients from their inception to 12 July 2023. Studies were reviewed in accordance with the Preferred Reporting Items for Systematic Reviews and Meta-Analyses (PRISMA) guidelines, and a meta-analysis was performed using the Stata 14.0 software.

Results: Sixteen studies met the eligibility criteria out of the 859 studies, containing a total of 2,963 melasma patients for this systematic review and meta-analysis. Meta-analyses revealed that the pooled prevalence of depression among patients with melasma was 43.4% (95% CI 30.5–56.2%, *Q*-value 808.859, d.f. = 15, $p < 0.001$, $tau^2 = 0.065$, $I^2 = 98.1\%$). The meta-regression found that the publication year, sample size, and study quality were not significant moderators for the observed heterogeneity in prevalence. A subgroup analysis according to depression assessment methods showed that the prevalence of depressive disorders was 24.2% (95% CI 16.8–31.6%), and the prevalence of depressive symptoms was 45.1% (95% CI 31.2–59.0%). A subgroup analysis by geographic regions showed that patients in Asia had the highest prevalence of depression at 48.5% (95% CI 26.0–71.0%), compared to other regions. A subgroup analysis by study design showed that the prevalence of depression in case–control studies was almost identical to cross-sectional studies. In the case of OR, the pooled OR of depression between patients with melasma and health controls was 1.677 (95% CI 1.163–2.420, $p = 0.606$, $I^2 = 0.0\%$).

Conclusion: The prevalence of depression was relatively high in patients with melasma, and there was a correlation between melasma and depression, encouraging clinicians to screen for depression in their patients and providing a combination of physical and psychosocial support. If necessary, they should be referred to formal mental health services to seek professional psychological intervention.

COMMENT

This systematic review and meta-analysis assessed the pooled prevalence of depression in melasma patients across 16 studies involving 2,963 individuals. The overall prevalence of depression was found to be 43.4%, substantially higher than the global

JAYPEE BROTHERS

estimate of 3.4%. Patients with melasma were 1.67 times more likely to experience depression than healthy controls. Prevalence estimates varied based on the assessment method. 24.2% for clinically diagnosed depressive disorders versus 45.1% for self-reported depressive symptoms.

Geographically, Asia reported the highest prevalence (48.5%), followed by the Americas (39.3%), with the lowest rates in Europe and Africa. No significant differences were noted between study designs or in meta-regression analyses by publication year, sample size, or study quality. Despite high heterogeneity, sensitivity analyses confirmed the stability of pooled estimates.

The study emphasized that visible pigmentary changes, cultural beauty ideals, and psychological stress likely contribute to this elevated risk. It advocated routine depression screening in melasma patients and recommended integrating psychosocial support into treatment strategies. Limitations included reliance on self-reported data, lack of longitudinal studies, and underrepresentation of certain regions. Future prospective studies are needed to clarify causality and bidirectional links.

7. Assessing Impact of Melasma on Quality of Life using Hindi-Melasma Quality of Life Index Scale and Melasma Area and Severity Index Score

Grewal L, Sood A, Narang R, Gupta P, Gupta S. Assessing impact of melasma on quality of life using Hindi-Melasma Quality of Life Index scale and Melasma Area and Severity Index score. Natl J Physiol Pharm Pharmacol. 2024;14(10):2058-62.

Abstract

Background: Melasma is a persistent and recurrent pigmentation disorder. It is a skin condition that affects facial skin esthetics and can lower self-esteem, causing emotional distress, which can lower a person's quality of life (QoL).

Aims and Objectives: To study the correlation of Hindi-Melasma Quality of Life Index (Hi-MELASQOL) in relation with Melasma Area and Severity Index (MASI) and to analyze the different patterns and influence of melasma on life quality.

Materials and Methods: This was a cross-sectional study involving 100 subjects. Hi-MELASQOL questionnaire comprising 10 items was used to assess the patient's QoL. MASI score was used to determine the severity of melasma. All the collected data were recorded, processed, and statistically analyzed using Epi Info 2000 and SPSS Inc., 20.0.

Results: A significant association was observed between the Hi-MELASQoL and MASI scores. It was evident that melasma had an adverse impact on the patients' QoL. The association between MASI score and type of melasma had $P < 0.05$ and hence showed a statistically significant association between them. However, the association between Hi-MELASQOL score (individually and total) and the type of melasma was statistically insignificant. The most common type was centrofacial (71%), followed by malar (25%) and mandibular (5%).

JAYPEE BROTHERS

Conclusion: There was a significant impairment in the QoL in our study population due to melasma as assessed by Hi-MELASQOL and MASI score. Utilization of Hi-MELASQOL scale should be considered in the evaluation of QoL of patients affected with melasma.

COMMENT

This cross-sectional study assessed the impact of melasma on quality of life using the Hi-MELASQOL and correlated it with the MASI in 100 Indian patients. The cohort was predominantly female (86%) with a mean age of 32.72 years. Centrofacial melasma (71%) and epidermal pattern (82%) were most frequent. Mean Hi-MELASQOL and MASI scores were 51.95 and 19.27, respectively, indicating considerable psychosocial burden.

A significant correlation was observed between MASI and select Hi-MELASQOL domains—M5 (impact on interpersonal relationships), M8 (feeling unattractive due to skin discoloration), and M10 (loss of freedom)—highlighting the emotional and social toll of visible pigmentation. However, age, sex, and melasma type showed no significant association with Hi-MELASQOL scores. MASI correlated significantly with sex, skin type, and melasma type, with higher scores in centrofacial involvement due to greater surface area.

Topical corticosteroid misuse was a common aggravating factor. The study underscored the discrepancy between clinical severity and patient-reported outcomes, supporting the integration of QoL instruments such as Hi-MELASQOL in routine care. Limitations included single-center design and recall bias. Broader studies are warranted to explore additional psychosocial determinants.

8. Quality of Life in Patients with Acquired Dermal Macular Hyperpigmentation: A Systematic Review

Jiang M, Wang E, Rodrigues M. Quality of life in patients with acquired dermal macular hyperpigmentation: a systematic review. Clin Exp Dermatol. 2024;49(12):1504-9.

Abstract

Acquired dermal macular hyperpigmentation (ADMH) encompasses conditions including lichen planus pigmentosus, erythema dyschromicum perstans, ashy dermatosis, Riehl melanosis, and pigmented contact dermatitis. This group of cosmetically distressing pigmentary disorders poses a therapeutic challenge, yet to our knowledge, there have been no systematic reviews published that describe their impact on quality of life (QoL). An electronic database search of PubMed, Embase, PsycINFO, and Cochrane Library was performed in December 2022 to search for articles published from inception until 15 December 2022. Articles were included if they (i) were a primary clinical publication, (ii) reported QoL in patients with ADMH, and (iii) were available in full text. Overall, the

JAYPEE BROTHERS

review highlighted a considerable gap in the literature concerning the impact of ADMH on QoL. Seven studies fulfilling the inclusion criteria were included, with a total of 259 patients. All seven studies reported impaired QoL in patients with ADMH. The currently available literature on this topic indicates that ADMH has a significant adverse impact on QoL, likely to a greater degree than melasma, and to a similar or lesser degree than vitiligo. Five of seven studies reported the QoL impairment for patients with ADMH based on the Dermatology Life Quality Index (DLQI); these studies consistently found a mean DLQI score reflective of a moderate effect on patients' QoL. Clinicians must be aware of the significant psychosocial burden associated with ADMH. This impact is often overlooked but should be considered when taking a holistic approach to management.

COMMENT

This systematic review assesses the psychosocial burden of ADMH, a group of pigmentary disorders including lichen planus pigmentosus, erythema dyschromicum perstans, ashy dermatosis, Riehl melanosis, and pigmented contact dermatitis. Despite their visible nature and therapeutic challenges, their impact on QoL has been underexplored. Seven studies with 259 patients were included; all reported impaired QoL, with mean DLQI scores indicating a moderate effect on daily life. Interestingly, the psychosocial burden appears greater than that of melasma and similar to vitiligo. Younger patients (18–30 years) and female gender showed worse QoL scores in some studies. Longer disease duration may correlate with greater impairment. The review underscores the need for clinicians to recognize this significant yet often overlooked burden, advocating a holistic management approach that may include cosmetic camouflage. Limitations include small sample sizes, varied diagnostic methods, and a lack of stratification by skin type. Further research is warranted to define patient-specific and disease-specific factors influencing QoL in ADMH.

9. A Clinico-epidemiological Study and Quality of Life Assessment in Melasma at a Tertiary Care Centre in South India

Gopalan K, Gunasegaran I, Anjum AA, Manickam N. A clinico-epidemiological study and quality of life assessment in melasma at a tertiary care centre in South India. J Pak Assoc Dermatol. 2024;34(4):985-9.

Abstract

Objective: To study the clinic-epidemiological features and the effect of melasma on the quality of life (QoL) of patients in a tertiary care hospital.

JAYPEE BROTHERS

Methods: Hundred patients with melasma were studied, and the quality of life was determined by melasma quality of life (MELASQoL) questionnaire.

Results: Mean age of the study population was 41.8 ± 7.1 years. Regarding Melasma Area Severity Index (MASI), 85% had a score of 0–5, followed by 13% who had a MASI score of 6–10. The mean value of MASI is 3.563 ± 2.7. In this study, 30% had a MELASQOL score of 10–20, 47% had a score of 21–30, 10% had a score of 31–40, 26% between 41 and 50, 6% had a score of 51–60, and 1% showed a score of 61–70. The mean value of the MELASQOL score is 30.86. There was no statistically significant association between MelasQoL and sex, education, marital status, duration of melasma, pattern of melasma, and severity of melasma.

Conclusion: The negative effect of melasma on the quality of life is not captured by MASI. Therefore, QoL should be assessed, and treatment should be planned by taking into account the psychosocial and emotional stress.

COMMENT

This cross-sectional study conducted in South India assessed clinicoepidemiological patterns and QoL in 100 melasma patients using MASI and MELASQoL scores. The mean age was 41.8 years, with 98% being female. Malar pattern and Fitzpatrick type V were the most common. Epidermal melasma was the predominant subtype on Wood's lamp examination. Despite low MASI scores suggesting mild clinical severity, many patients experienced moderate to severe quality-of-life impairment, with skin appearance and emotional distress being the most affected domains. Melasma was found to significantly impact patients' self-esteem and confidence, often influencing their social interactions and emotional well-being. No significant associations were found between MELASQoL scores and demographic factors, disease duration, or MASI. The study concluded that clinical severity underestimates psychosocial burden, advocating for routine QoL assessment in management. Limitations included a small sample size and a single-center design.

JAYPEE BROTHERS

for detailed information on dermatology books, visit our website www.ejaypee.com, for detailed information on dermatology books, visit our web

Year Book of
Facial Hyperpigmentation

Salient Features

- Comprehensive yearly compilation of significant recent publications on hyperpigmentation disorders from reputed journals
- Structured, reader-friendly format of each article presented with a concise abstract followed by expert critical commentary for quick understanding highlighting strengths, limitations, and practical takeaways
- Special emphasis on pigmentary disorders in darker skin types, particularly relevant to Indian and Asian populations
- Updated therapeutic perspectives: Covers evolving treatment modalities including lasers, topicals, and combination therapies



Rohit Batra MD is a renowned Dermatologist associated with Sir Ganga Ram Hospital, Delhi, and is Head and Founder of Dermaworld Skin and Hair Clinics, New Delhi, India. His areas of interest are clinical dermatology, pediatric dermatology, aesthetic dermatology, trichology and multidisciplinary care of dermatological disorders. He has numerous presentations at various national and international conferences. He has been the architect of two of the most famous Dermatology Conclaves—Dermatology and Allied Specialities Summit (DAAS) and Acne India Summit. A prominent organizational guru and a mentor for many, he has held various roles and posts in the IADVL including the President of the IADVL—Delhi State Branch.



Sanjeev Gupta MD DNB MNAMS is working as Professor and Head, Department of Dermatology, MM Institute of Medical Sciences and Research MMDU, Mullana, Ambala, Haryana, India. He is a member of most of national and international academic societies. He has around 170 publications, 8 books and 26 book chapters to his credit. He has invented many dermatological techniques and instruments to simplify the procedures and reduce the cost. Twenty-six of such inventions have been published one of the most prestigious journals of dermatology—Journal of the American Academy of Dermatology USA. He was awarded with "Making a Difference" award by the American Academy of Dermatology, USA. He is the first Indian to be honoured with this prestigious award. He has served his professional association [Indian Association of Dermatologists, Venereologists, and Leprologists (IADVL)] as Executive Committee Member at the state level as Treasurer, Secretary, Vice President, and President and also at the National level as Joint Secretary and Vice President IADVL. He was honoured with the LN Sinha Award by IADVL in 2013 and the ACSI Innovation Award 2021 by the Association of Cutaneous Surgeons of India (ACSI). He is the recipient of the Dr BM Ambady Oration awarded at DERMACON 2025 Jaipur.



Nishtha Malik MD completed her postgraduate training at Dr DY Patil Medical College and Research Institute, Pune, Maharashtra, India. She has a strong academic inclination with a keen interest in clinical research. Her primary areas of interest include vitiligo, psoriasis, acne, and energy-based devices, with a focus on integrating evidence-based medicine with procedural dermatology. She is currently pursuing her Senior Residency at University College of Medical Sciences (UCMS) and Guru Teg Bahadur Hospital, New Delhi, India. She is actively involved in scholarly work and aims to advance dermatologic science and patient-centered care.

Shelving Recommendation
DERMATOLOGY

ISBN 978-93-7545-609-4

Buy from ejaypee

JAYPEE BROTHERS