our website **www.jaypeebrothers.com,** for detailed information on radiology books, visit our website **www.jaypeebrothers.com**

RADIOLOGY
CASE VIGNETTES





Kapisoor Singh
Karunakaran M
Jai Vinod Shah

JAYPEE

Contents

Chapter 01	**Neuroimaging**	**1**
Chapter 02	**Neck Imaging**	**39**
Chapter 03	**Respiratory System Imaging**	**47**
Chapter 04	**Abdominal and Genitourinary Imaging**	**65**
Chapter 05	**Ultrasound Imaging**	**129**
Chapter 06	**Musculoskeletal Imaging**	**151**
Chapter 07	**Vascular and Cardiac Imaging**	**164**
Index		*203*

Chapter 2

Neck Imaging

JAYPEE BROTHERS

CASE-20

A 64-year-old male with history of growth on the right side of tongue and dysphagia since 3 months.

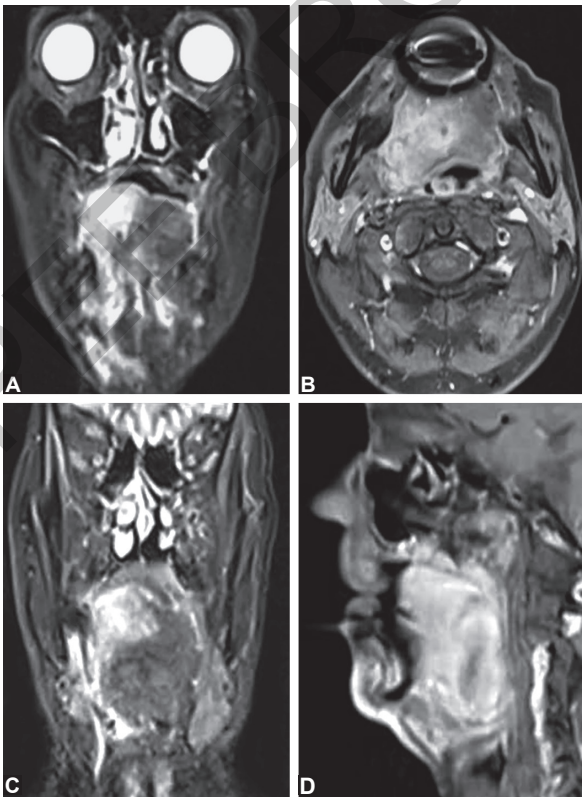

Figs 2.1A to D (A) T_2WI (coronal); (B) T_1 contrast axial; (C) STIR (coronal); (D) STIR (sagittal)

Findings

Mass lesion in right half of tongue with T_2-STIR hyperintense signals and heterogeneous contrast uptake. Prominence of right submandibular lymph node.

Diagnosis

- Carcinoma of tongue.

Discussion

Tongue-base carcinomas are often clinically silent, and the tongue base is a common location of 'occult' malignancies originating in the upper aerodigestive tract.

On MR imaging, T_2W fat suppressed sequence and post-contrast fat suppressed T_1W images are most helpful to visualize the full extent of these lesions and specifically to determine whether the tumor has crossed the midline.

Malignancies of the tongue base often are limited to one side of the tongue, crossing the midline only when the tumor becomes large. These tumors may also spread to the tonsillar pillar, pharyngeal wall, anteriorly into the sublingual space, and submucosally under the valleculae into the supraglottic larynx. If surgery is the treatment, this latter spread is critical to identify, as it determines if a partial or total laryngectomy is required. The hyoepiglottic ligament can usually be seen on imaging, and tumor extension below this structure indicates spread into the preepiglottic space of the larynx. Lesions may also grow inferiorly and laterally to spread into the deep soft tissues of the neck, eventually involving the styloid musculature and the internal carotid artery.

The primary lymphatic drainage is to level II to IV nodes, with occasional involvement of level V nodes.

JAYPEE BROTHERS

CASE-21

A 65-year-old female, history of swelling on the right side of the neck since 6 months.

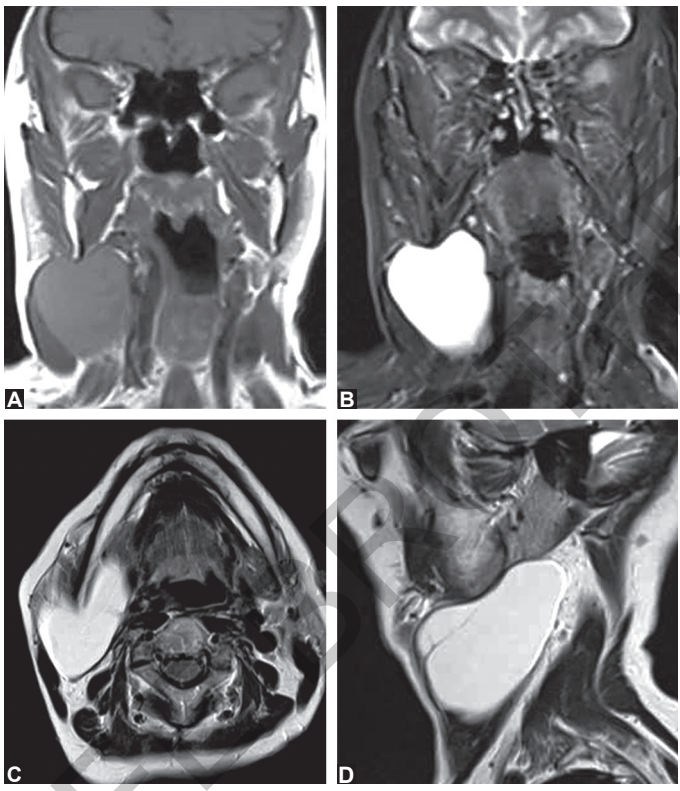

Figs 2.2A to D (A) T_1WI (coronal); (B) STIR (coronal); (C) T_2WI (axial); (D) T_2WI (sagittal)

Findings

A large well defined cystic lesion along the anterior surface of the sternocleidomastoid muscle, lateral to the carotid space seen which appears hypointense on T_1WI and hyperintense on T_2WI and FLAIR.

Diagnosis

- Branchial cleft cyst.

Discussion

Branchial cleft anomalies arise from incomplete obliteration of the cervical sinus. The vast majority (95%) of branchial cleft anomalies arise from the second cleft.

JAYPEE BROTHERS

A 4 types of second branchial cleft cysts are described. The Bailey type I cyst is the most superficial and lies along the anterior surface of the sternocleidomastoid muscle, just deep to the platysma muscle. The type II cyst is the most common and found in the 'classic' location for these cysts: along the anterior surface of the sternocleidomastoid muscle, lateral to the carotid space, and posterior to the submandibular gland. A type III cyst extends medially between the bifurcation of the internal and external carotid arteries to the lateral pharyngeal wall. The type IV cyst lies in the pharyngeal mucosal space and is lined with columnar epithelium. Most second branchial cleft cysts are located in the submandibular space.

Magnetic resonance imaging better depicts the deep tissue extent of a second branchial cleft cyst, which allows accurate preoperative planning. The cyst fluid appears hypointense on T_1W images and is usually hyperintense on T_2W images. Occasionally, a 'beak sign' may be seen on axial CT or MR images. This sign represents a curved rim of tissue or 'beak' pointing medially between the internal and external carotid arteries. The 'classic' location of these cysts (at either CT or MR imaging) is at the anteromedial border of the sternocleidomastoid muscle, lateral to the carotid space, and at the posterior margin of the submandibular gland.

Differential Diagnosis

- Cystic lymphangioma
- Cystic metastasis
- Abscess 65 years female with dysphagia since 3 months.

JAYPEE BROTHERS

CASE-22

A 65-year-old female with dysphagia since 3 months.

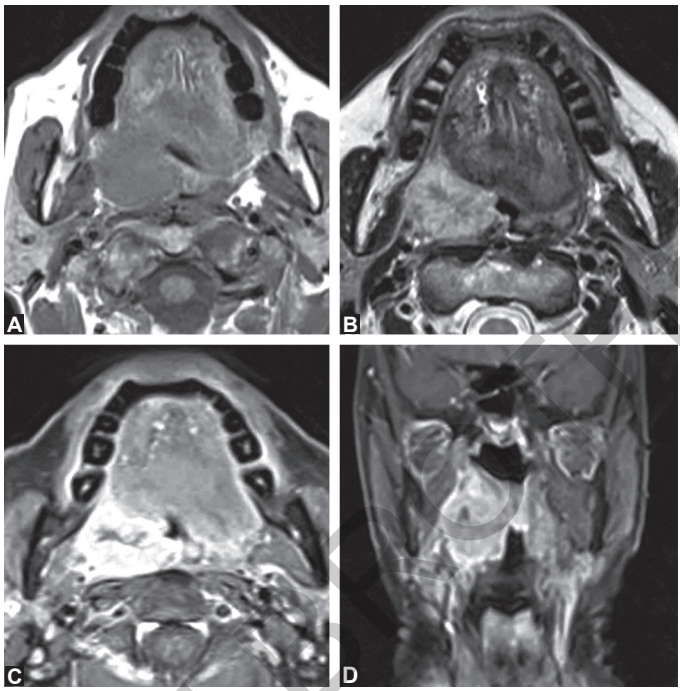

Figs 2.3A to D (A) T_1WI (axial); (B) T_2WI (axial); (C) T_1 contrast (axial); (D) T_1 contrast (coronal)

Findings

A well-defined large homogeneous mass lesion with central non-enhancing areas within is seen in right tonsillar fossa extending cranially upto nasopharynx and compressing posterior aspect of right half of the tongue with perilesional contrast enhancement and right submandibular lymphadenopathy.

Diagnosis

- Tonsillar malignancy.

Discussion

The majority of tumors involving the oropharynx are squamous cell carcinomas, followed by other, less common neoplasms such as lymphoma, minor salivary gland tumors, and other rare mesenchymal lesions. The incidence increases in patients with a history of tobacco or alcohol abuse.

JAYPEE BROTHERS

Staging

- TIS Carcinoma in situ T1 Tumor 2 cm or less in greatest dimension
- T2 Tumor more than 2 cm but not more than 4 cm in greatest dimension
- T3 Tumor more than 4 cm in greatest dimension
- T4 Tumor invades adjacent structures (e.g. pterygoid muscle(s), mandible, hard palate, deep muscle of tongue, larynx).

Malignancies of the tonsillar fossa are believed to arise from the mucosa lining the niche between the anterior tonsillar pillar and posterior tonsillar pillar or from remnants of the palatine tonsil. Given their location, these lesions may spread anteriorly or posteriorly to involve the adjacent tonsillar pillars. These lesions may also extend deeply and gain access to the parapharyngeal space and skull base. The primary lymphatic drainage for the tonsillar fossa is to level I to IV nodes and occasionally to level V and the parotid nodes.

Differential Diagnosis

- Oropharyngeal malignancy
- Lymphoma.

JAYPEE BROTHERS

CASE-23

A 25-year-old female with history of pain in left submandibular region.

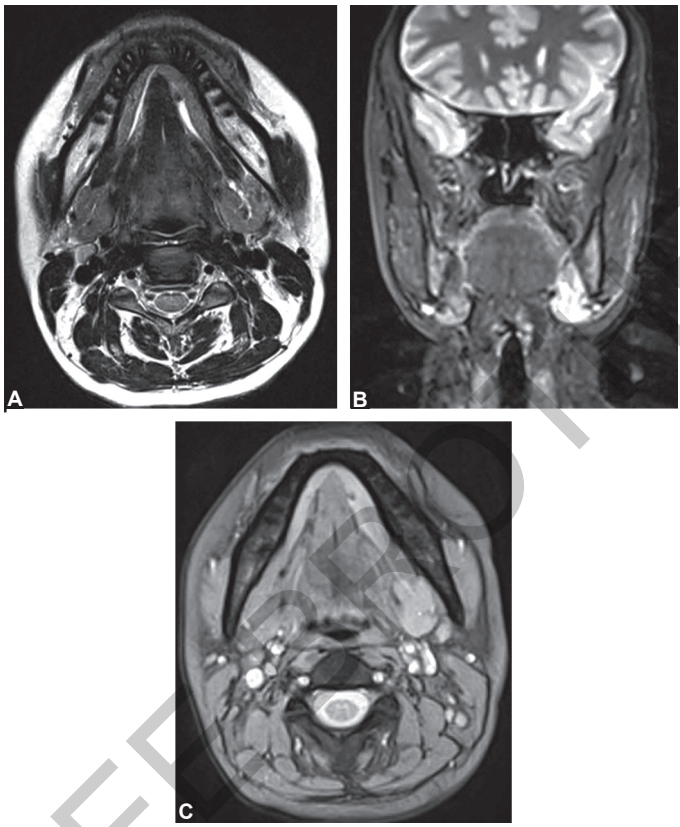

Figs 2.4A to C T_2WI (axial); (B) STIR (coronal); (C) GRE (axial)

Findings

A well-defined intraluminal hypointense lesion in left Wharton's duct proximal to its termination near the sublingual papilla in the anterior floor of the mouth with proximal dilatation of rest of submandibular duct. Primary and secondary intraglandular ducts also dilated.

Diagnosis

- Sialolithiasis of submandibular gland.

Discussion

Submandibular glands with sialolithiasis could be classified into three types on the basis of clinical symptoms and MR imaging features of the glands:

JAYPEE BROTHERS

Type I glands are positive for clinical symptoms and MR imaging abnormalities, and were characterized histopathologically by active inflammation.

Type II glands are negative for clinical symptoms and positive for MR imaging abnormalities, and the glands were replaced by fat.

Type III glands are negative for clinical symptoms and MR imaging abnormalities. CT features of these glands correlate well with those of MR imaging.

It is reasonable to consider that the MR imaging pattern may reflect the chronic and acute nature of the obstruction. In this context, type I patients are those with relatively acute and incomplete obstruction associated with secondary infection. Type II patients are those with chronic and complete obstruction, but this obstruction is not associated with secondary infection. Type III patients are those with a nonobstructing or partially obstructing sialolith without secondary infection.

The benefits of MR imaging are two fold. First, MR imaging can depict the status of the gland parenchyma affected by sialolithiasis. Sialography and CT are useful in obtaining the information about a sialolith, but the information about the gland itself is limited compared with MR imaging MR does not require the cannulation of the duct, which cannot be achieved every time. Furthermore, retrograde injection of contrast material may exacerbate the inflammation of the gland. In addition, MR sialography could replace the conventional sialography in depicting the dilated duct and also the sialolith in it. MR sialography was postulated as an alternative for the conventional sialography in diagnosing Sjogren's syndrome.

JAYPEE BROTHERS

for detailed information on radiology books, visit our website **www.jaypeebrothers.com,** for detailed information on radiology

RADIOLOGY
CASE VIGNETTES

Radiology Case Vignettes is useful to undergraduates, postgraduates and consultants to explore further how imaging can help making diagnosis.

This book provides basic to complex cases seen in day-to-day life by a radiologist in a simple and easily understandable text with images. Cases from different systems have been included with multimodality approach.



Kapisoor Singh MD completed his MD from King George's Medical University, Lucknow, Uttar Pradesh, India in 2005. Presently, he is working as a Chief Radiologist, KG Hospital, Coimbatore, Tamil Nadu, India, for past 6 years, and worked as Senior Resident, Department of Cardiac and Interventional Radiology at All India Institute of Medical Sciences (AIIMS), New Delhi, India, for 2 years. He has reported more than 6,000 cardiac CT cases.



Karunakaran M MD completed his MD from Assam Medical College, Assam, India, in 2009. Presently, he is working as a Consultant Radiologist, KG Hospital, Coimbatore, Tamil Nadu, India, for past 1 year, and worked as Assistant Professor, Amrita Institute of Medical Sciences, Kochi, Kerala, India.



Jai Vinod Shah MD completed his MD from Father Muller Medical College, Mangaluru, Karnataka, India, in 2013. Presently, he is working as a Consultant Radiologist, KG Hospital, Coimbatore, Tamil Nadu, India, for past 1 year, and worked as Senior Resident in Father Muller Medical College, Mangaluru.

Available at all medical bookstores
or buy online at www.jaypeebrothers.com

JAYPEE BROTHERS
Medical Publishers (P) Ltd.
www.jaypeebrothers.com

Join us on facebook.com/JaypeeMedicalPublishers

Shelving
Recommendation
RADIOLOGY

ISBN 978-93-85891-04-5