, for detailed information on PGMEE books, visit our website **www.jaypeebrothers.com,** for detailed information on PGMEE books

Surgery and Orthopedics

Buster

A Solution of WBHU Papers for Final MBBS Examination



Arkaprovo Roy

Forewords
Vivek Vij
Diptendra K Sarkar

JAYPEE

Contents

PAPER I PART II 2015-2008

1. Paper I Part II 2015 1
2. Paper I Part II Supplementary 2015 14
3. Paper I Part II 2014 26
4. Paper I Part II Supplementary 2014 57
5. Paper I Part II 2013 101
6. Paper I Part II Supplementary 2013 127
7. Paper I Part II 2012 150
8. Paper I Part II Supplementary 2012 183
9. Paper I Part II 2011 211
10. Paper I Part II Supplementary 2011 237
11. Paper I Part II 2010 259
12. Paper I Part II Supplementary 2010 288
13. Paper I Part II 2009 319
14. Paper I Part II Supplementary 2009 337
15. Paper I Part II 2008 353
16. Paper I Part II Supplementary 2008 365

PAPER II PART II 2015-2008

17. Paper II Part II 2015 381
18. Paper II Part II Supplementary 2015 392
19. Paper II Part II 2014 404
20. Paper II Part II Supplementary 2014 436
21. Paper II Part II 2013 459
22. Paper II Part II Supplementary 2013 490
23. Paper II Part II 2012 517

24. Paper II Part II Supplementary 2012 542
25. Paper II Part II 2011 565
26. Paper II Part II Supplementary 2011 589
27. Paper II Part II 2010 613
28. Paper II Part II Supplementary 2010 635
29. Paper II Part II 2009 658
30. Paper II Part II Supplementary 2009 686
31. Paper II Part II 2008 712
32. Paper II Part II Supplementary 2008 731

The West Bengal University of Health Sciences

MBBS 3rd Professional Part II (Supplementary) Examination 2015

SURGERY

Paper I

Time:2½ hrs. *Marks:60*

GROUP A

1. Define burns. Discuss the management of 40% burns in a 22 years female patient of 50 kg body weight, carrying 12 weeks pregnancy. 3+12 = 15

GROUP B

2. a. Classify ulcers. Discuss the pathology, clinical features, investigations and management of venous ulcer. 5+2+2+2+4 = 15

Or

b. Discuss the etiopathogenesis and management of acute pancreatitis. 7+8 = 15

GROUP C

3. Write short notes on (any three): 3x5 = 15

a. Warthin's Tumor
b. Colostomy
c. Fibroadenoma
d. Branchial cyst
e. Complications of splenectomy

GROUP D

4. Answer briefly on (any three): 3x5 = 15

a. Nonunion of fractures
b. Mallet finger

JAYPEE BROTHERS

c. Baker's cyst
d. Pott's fracture
e. Wrist drop

ANSWERS

GROUP A

Answer 1

See the Question 1 of Group A of Supplementary Paper I of 2008 Obstetric management of the pregnant burned woman:

Total % burn	Age of gestation		Management
< 30	First trimester		No obstetric interference
	Second trimester		No obstetric interference
	Third trimester	More than 36 wks	Induce labor/cesarian section
		Less than 36 wks	Conservative approach and monitoring of heart rate
30–50	First trimester		Fetal monitoring by ultrasound 3–4 wks
	Second trimester		Fetal monitoring every 3–4 wks. Tocolytic therapy
	Third trimester	More than 32 wks	Deliver fetus within 48 h
		Less than 36 wks	Careful Fetal monitoring
50–70	First trimester		Terminate pregnancy
	Second trimester		Terminate pregnancy
	Third trimester	If baby is viable	Induce labor/cesarian section within 24 h
		Intrauterine death	No active intervention up to 4 wks/monitoring of fetus of hemocoagulation factors

Contd...

JAYPEE BROTHERS

Total % burn	Age of gestation		Management
> 70	First trimester		No treatment
	Second trimester		No treatment
	Third trimester		Cesarian section as an emergency procedure at the earliest

GROUP B

Answer 2a

Wagner Classification System

Grade 0: Skin intact, but deformity present. Foot is 'at risk'.
Grade I: Localized superficial ulcer.
Grade II: Deep ulcer extending to tendon, joint and bone.
Grade III: Ulcer involving infection of bone.
Grade IV: Ulcer involving gangrene of toes or forefoot.
Grade V: Gangrene beyond forefoot.

UTSA Classification System

A new and more comprehensive system has been developed by podiatrists at the University of Texas at San Antonio (abbreviated here as 'UTSA').

Wounds in this classification system are graded as follows:First, the patient's medical condition is graded.

- *Grade A* refers to a clean, noninfected wound in a patient with adequate blood supply.
- *Grade B* refers to patients with infected wounds but have adequate blood supply.
- *Grade C* refers to patients with no infection in the wound, but has poor circulation.
- *Grade D* refers to patients with an infected wound and poor circulation.

Next, the wound is graded.

- *Grade 0* refers to pre- or postulcerative lesion that is completely healed.

JAYPEE BROTHERS

- *Grade 1* refers to patients with a superficial wound not involving tendon, capsule or bone.
- *Grade 2* refers to wounds penetrating to tendon or capsule.
- *Grade 3* refers to wounds extending to the bone or joint.

For venous ulcer—See the Question 4c of Group D of Supplementary Paper II of 2014.

Or

Answer 2b.

Etiologic Factors in Acute Pancreatitis

METABOLIC
Alcohol
Hyperlipoproteinemia
Hypercalcemia
Drugs
Genetic
Scorpion venom
MECHANICAL
Cholelithiasis
Postoperative
Pancreas divisum
Post-traumatic
Retrograde pancreatography
Pancreatic duct obstruction:pancreatic tumor, ascaris infestation
Pancreatic ductal bleeding
Duodenal obstruction
VASCULAR
Postoperative (cardiopulmonary bypass)
Periarteritis nodosa
Atheroembolism
INFECTION
Mumps
Coxsackie B
Cytomegalovirus
Cryptococcus

JAYPEE BROTHERS

See the Question 2a of Group B of Supplementary Paper I of 2009.
See the Question 2a of Group B of Supplementary Paper I of 2011.

GROUP C

Answer 3a

Warthin's Tumor

- Warthin's tumor (benign papillary cystadenoma lymphomatosum)
- It is the second most common benign tumor of the parotid gland.
- Its etiology is unknown, but there is a strong association with cigarette smoking. Smokers are at 8 times greater risk of developing Warthin's tumor than the general population.
- It accounts for 2–10% of all parotid gland tumors
- Bilateral in 10% of the cases
- *Male:*female 5:1
- Age: 6th–7th decade
- Primarily located in the lateral gland however multicentricity is described.
- May contain mucoid brown fluid in FNA
- Thought to arise from salivary gland inclusions within lymph nodes.
- Pathology:

Epithelial Component
- Consists of papillary fronds which demonstrate 2 layers of oncocytic epithelial cells
- Cytoplasm stains deep pink and shows granularity b/c of an abundance of mitochondria
- Occasionally undergoes squamous metaplasia (may mistakenly diagnose SCCa on FNA)

Lymphoid Component
- An abundance of this is present
- Occasional germinal centres will be seen
- Lymphoid tissue forms the core or papillary structures.

JAYPEE BROTHERS

Both lymphoid and oncocytic epithelial elements must be present to diagnose

Warthin's Tumor.

- The only neoplasms of salivary glands known to consistently concentrate Tc-99m pertechnetate are Warthin's tumor and oncocytoma. Warthin's Tumor produces hot spot on Tc-99m pertechnetate scan.

Treatment: Lateral or total glandular resection.

Answer 3b

Colostomy

Definition: Colostomy refers to a surgical procedure where a portion of the large intestine is brought through the abdominal wall to carry stool out of the body.

It maybe permanent or temporary.

Indications:

- Cancer of colon and rectum
- Diverticular disease
- Crohn's disease
- Ulcerative colitis
- Trauma.

Types of Colostomy

- *Loop colostomy:*This type of colostomy is usually used in emergencies and is a temporary and large stoma. A loop of the bowel is pulled out onto the abdomen and held in place with an external device. The bowel is then sutured to the abdomen and two openings are created in the one stoma:one for stool and the other for mucus.
- *End colostomy:* A stoma is created from one end of the bowel. The other portion of the bowel is either removed or sewn shut (Hartmann's procedure).
- *Double barrel colostomy:* The bowel is severed and both ends are brought out onto the abdomen. Only the proximal stoma is functioning.

JAYPEE BROTHERS

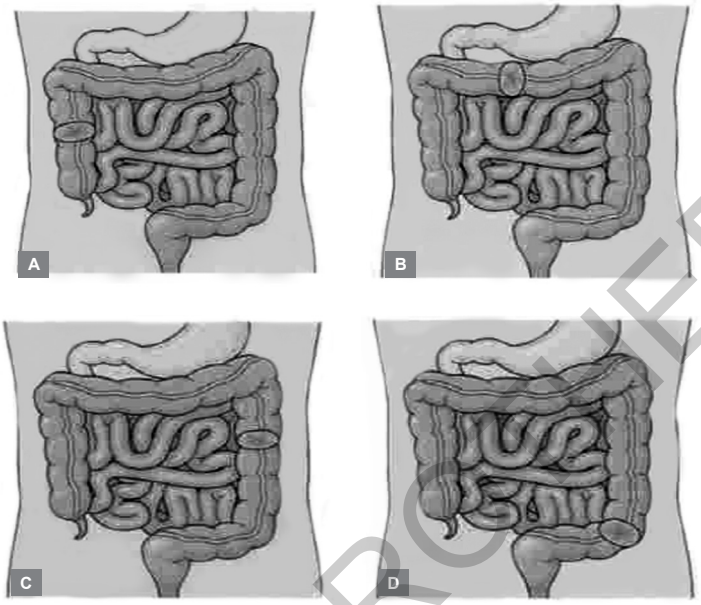

Fig. 1: Colostomy sites: **A.** Ascending colostomy; **B.** Transverse (single barrel colostomy; **C.** Descending colostomy; **D.** Sigmoid colostomy

Complications:

- Necrosis of stoma
- Prolapsed of stroma
- Parastomal hernia.
- Retraction of stoma
- Stenosis or narrowing

Answer 3c

Fibroadenoma

See the Question 3a of Group C of Supplementary Paper I of 2008

Answer 3d

Branchial Cyst

See the Question 3c of Group C of Paper I of 2010.

Answer 3e

Complications of Splenectomy

See the Question 3a of Group C of Supplementary Paper I of 2013.

JAYPEE BROTHERS

GROUP D

Answer 4a

Nonunion of Fractures

See the Question 4f of Group D of Paper I of 2012

Answer 4b

Mallet Finger

See the Question 4d of Group D of Supplementary Paper I of 2013

Answer 4c

Baker's Cyst

*Introduction:*A Baker's cyst, also known as a popliteal cyst, is a benign swelling of the semimembranosus or more rarely some other synovial bursa found behind the knee joint. This is not a 'true' cyst, as an open communication with the synovial sac is often maintained.

Cause:

- In adults, Baker's cysts usually arise from almost any form of knee arthritis (e.g. rheumatoid arthritis) or cartilage (particularly ameniscus) tear.
- Baker's cysts can also be associated with Lyme disease. Baker's cysts in children do not point to underlying joint disease.
- Baker's cysts arise between the tendons of the medial head of the gastrocnemius and the semimembranosus muscles. They are posterior to the medial femoral condyle.

Clinical Features

The synovial sac of the knee joint can, under certain circumstances, produce a posterior bulge, into the popliteal space, the space behind the knee. When this bulge becomes large enough, it becomes palpable and cystic. Most Baker's cysts maintain this direct communication with the synovial cavity of the knee, but sometimes, the new cyst pinches off. A Baker's cyst can rupture and produce acute pain behind the knee and in the calf and swelling of the calf muscles.

JAYPEE BROTHERS

Diagnosis

Diagnosis is by examination. A Baker's cyst is easier to see from behind with the patient standing with knees fully extended. It is most easily palpated (felt) with the knee partially flexed.

Diagnosis is confirmed by ultrasonography, although if needed and there is no suspicion of a popliteal artery aneurysm then aspiration of synovial fluid from the cyst maybe undertaken with care. An MRI image can reveal presence of a Baker's cyst.

An infrequent but potentially life-threatening complication, which may need to be excluded by urgent blood tests and ultrasonography, is a deep vein thrombosis (DVT). Quick assessment of the possibility of DVT maybe required where a Baker's cyst has compressed vascular structures, causing leg edema, as this sets up conditions for a DVT to develop.

A burst cyst commonly causes calf pain, swelling and redness that may mimic thrombophlebitis.

Treatment:

- Baker's cysts usually require no treatment unless they are symptomatic. It is very rare that the symptoms are actually coming from the cyst. In most cases, there is another disorder in the knee (arthritis, meniscal tear, etc.) that is causing the problem.
- Initial treatment should be directed at correcting the source of the increased fluid production. Often rest and leg elevation are all that is needed.
- If necessary, the cyst can be aspirated to reduce its size, then injected with a corticosteroid to reduce inflammation.
- Surgical excision is reserved for cysts that cause a great amount of discomfort to the patient. A ruptured cyst is treated with rest, leg elevation, and injection of a corticosteroid into the knee.
- Recently, prolotherapy has shown encouraging results as an effective way to treat Baker's cysts and other types of musculoskeletal conditions.

Baker's cysts in children, unlike in older people, nearly always disappear with time, and rarely require excision.

They can be treated by:

Cryotherapy	Medication	Heat	Bracing	Rest and specific exercise

JAYPEE BROTHERS

Answer 4d

Pott's Fracture

- Pott's fracture also known as Pott's syndrome I and Dupuytren fracture, is an archaic term loosely applied to a variety of bimalleolar ankle fractures.
- The injury is caused by a combined abduction external rotation from an eversion force. This action strains the sturdy medial (deltoid) ligament of the ankle, often tearing off the medial malleolus due to its strong attachment. The talus then moves laterally, shearing off the lateral malleolus or, more commonly, breaking the fibula superior to the tibiofibular syndesmosis. If the tibia is carried anteriorly, the posterior margin of the distal end of the tibia is also sheared off by the talus. A fractured fibula in addition to detaching the medial malleolus will tear the tibiofibular syndesmosis.
- The combined fracture of the medial malleolus, lateral malleolus, and the posterior margin of the distal end of the tibia is known as a 'trimalleolar fracture.'
- An example of Pott's fracture would be in a sports tackling injury. The player receives a blow to the outside of the ankle, causing the ankle to roll inwards (so that the sole of the foot faces laterally). This damages the ligaments on the inside of the ankle and fractures the fibula at the point of contact (usually just above the tibiofibular syndesmosis). A better way to visualize this is the two hands of a clock, with one hand facing 12 and the other facing 6. The vertical line they form represents the fibula of the person's right leg. The lateral force approaches from 3 o'clock, sending the lower hand snapping outwards to point at 5 o'clock.
- Bimalleolar fractures are less likely to result in arthritis than trimalleolar fractures.

Answer 4e

Wrist Drop

*Introduction:*Wrist drop, also known as radial nerve palsy, is a condition where a person cannot extend their wrist and it hangs flaccidly. To demonstrate wrist drop, hold your arm out in front of you with your forearm parallel to the floor. With the back of your

JAYPEE BROTHERS

hand facing the ceiling (i.e. pronated), let your hand hang limply so that your fingers point downward. A person with wrist drop would be unable to move from this position to one in which the fingers are pointing up towards the ceiling.

Anatomy of the Forearm

In anatomical parlance, the forearm is the part of the body which extends from the elbow to the wrist and is not to be confused with the arm which extends from the shoulder to the elbow. The extensor muscles in the forearm are extensor carpi ulnaris, extensor digiti minimi, extensor digitorum, extensor indicis, extensor carpi radialis brevis, extensor carpi radialis longus. These extensor muscles are supplied by the posterior interosseous nerve, a branch of the radial nerve. Other muscles in the forearm also innervated by the radial nerve are supinator, extensor pollicis brevis, extensor pollicis longus, and abductor pollicis longus. Note that all these muscles are situated in the posterior half of the forearm (posterior when in the anatomical position).

Also, brachioradialis, anconeus, triceps brachii, and extensor carpi radialis longus are all innervated by muscular branches of the radial nerve in the arm.

Causes

Wrist extension is achieved by muscles in the forearm contracting, pulling on tendons that attach distal to (beyond) the wrist. If the tendons, the muscles, or the nerves supplying these muscles, are not working as they should be, wrist drop may occur. The following situations may result in wrist drop.

Stab wounds to the chest at or below the clavicle may result in wrist drop. The radial nerve is the terminal branch of the posterior cord of the brachial plexus. A stab wound may damage the posterior cord and result in neurological deficits including an inability to abduct the shoulder beyond first 15 degrees, an inability to extend the forearm, reduced ability to supinate the hand, reduced ability to abduct the thumb and sensory loss to the posterior surface of the arm and hand.

The radial nerve can be damaged if the humerus (the bone of the arm) is broken, because it runs through the radial groove on the lateral border of this bone along with the deep brachial artery.

JAYPEE BROTHERS

Wrist drop is also associated with lead poisoning because of the effect of lead on the radial nerve.

Persistent injury to the nerve is also a common cause through either repetitive motion or by applying pressure externally along the route of the radial nerve as in the prolonged use of crutches or extended leaning on the elbows.

- Weakness of brachioradialis, wrist extension and finger flexion = radial nerve lesion
- Weakness of finger extension and radial deviation of the wrist on extension = posterior interossious nerve lesion
- Weakness of triceps, finger extensors and flexors = c7,8 lesion
- Generalised weakness of upper limb marked in deltoid, triceps, wrist extension and finger extension = corticospinal lesion.

Diagnosis

- The workup for wrist drop frequently includes nerve conduction velocity studies to isolate and confirm the radial nerve as the source of the problem.
- Plain films can help identify bone spurs and fractures that may have injured the nerve.
- Sometimes MRI imaging is required to differentiate subtle causes.

Treatment

Initial management includes splinting of the wrist for support along with osteopathy, chiropractic, physiotherapy and occupational therapy. In some cases, surgical removal of bone spurs or other anatomical defects that maybe impinging on the nerve might be warranted.

JAYPEE BROTHERS

for detailed information on PGMEE books, visit our website **www.jaypeebrothers.com,** for detailed information on PGMEE books, vi

Surgery and Orthopedics Buster

A Solution of WBHU Papers for Final MBBS Examination

Salient Features

- Answers of long questions are written in a simple and pointwise manner
- Short notes from general and special surgery are written in brief
- Short notes from orthopedics are also written as per demand
- Short notes from anesthesiology, dental surgery, radiology, physical medicine and physical therapy are also written here
- Topics from the recent advances are also covered
- Clinical questions and their answers are also written in the most simple way.



Arkaprovo Roy graduated from Calcutta National Medical College, Kolkata, West Bengal, India. He did his postgraduation from RG Kar Medical College, Kolkata in 2010. He joined as an RMO-cum-clinical tutor in Calcutta National Medical College in 2011 and is currently working as Assistant Professor in the Department of Surgery in Malda Medical College, Malda, West Bengal. He went for fellowship in liver transplant in Fortis Hospital, Noida, Uttar Pradesh, India under Dr Vivek Vij. He also sought training in trauma surgery. He has a keen interest in gastrointestinal surgery and oncosurgery. He also enjoys teaching surgery.

Available at all medical bookstores
or buy online at www.jaypeebrothers.com

JAYPEE BROTHERS
Medical Publishers (P) Ltd.
www.jaypeebrothers.com

Join us on facebook.com/JaypeeMedicalPublishers

ISBN 978-93-85891-12-0

9 789385 891120