n on PGMEE books, visit our website **www.jaypeebrothers.com,** for detailed information on PGMEE books

Dermatology Review

A Must for PG Entrance Exams

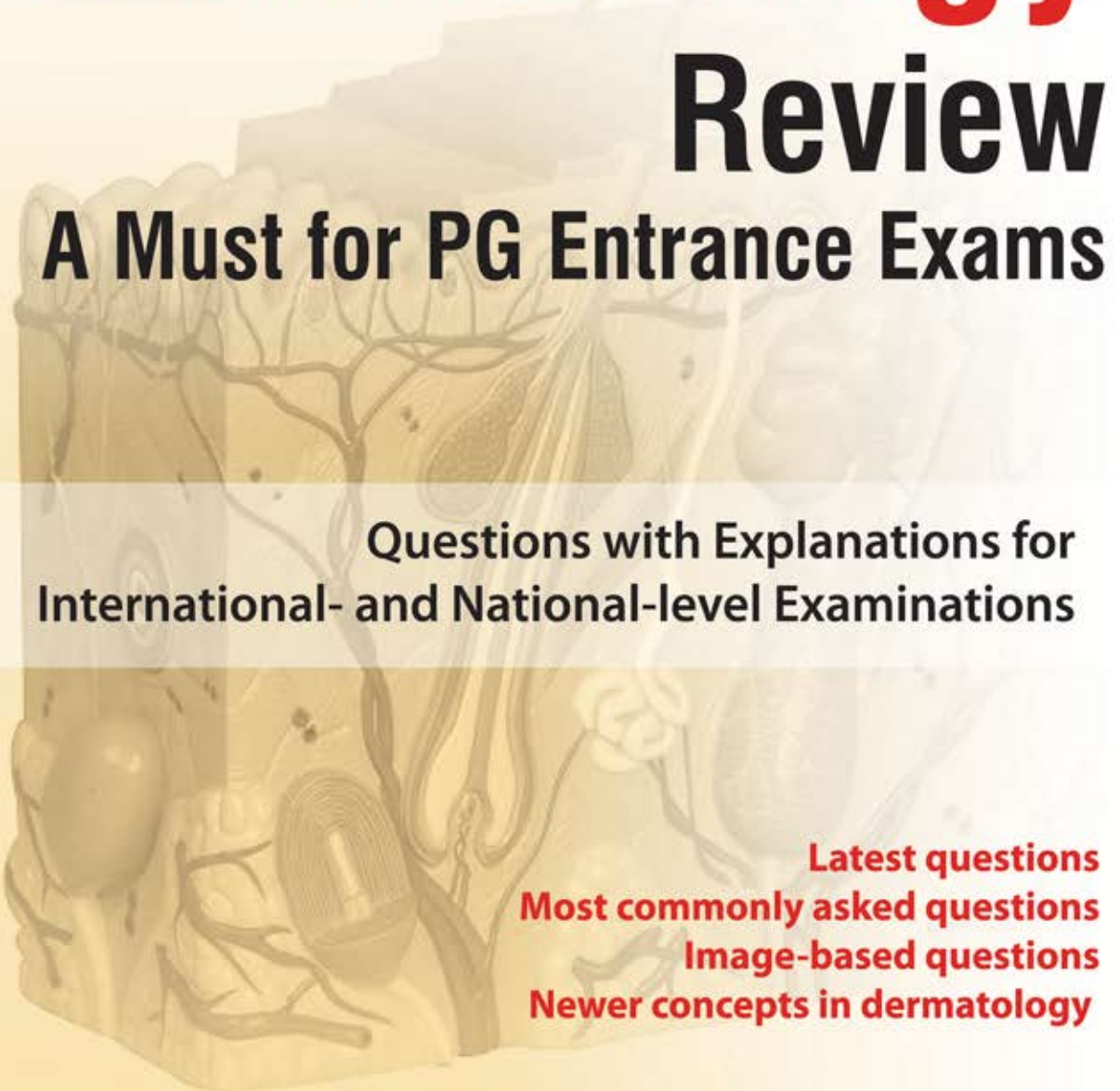

Questions with Explanations for International- and National-level Examinations

Latest questions
Most commonly asked questions
Image-based questions
Newer concepts in dermatology

Ashfaq Ul Hassan
Sheikh Manzoor Ahamed

JAYPEE

Contents

1.	**Latest Questions on Dermatology**	**1**
2.	**Dermatopathology**	**73**
3.	**Important Revision Points in Dermatology**	**87**
	Image-based Questions	**97**

3 Important Revision Points in Dermatology

Basic Histopathological Terms used in Dermatology

- *Acanthosis:* Increase in thickness of prickle cell layer.
- *Acantholysis:* Loss of coherence between epidermal cells. Seen in pemphigus
- *Corps Grains:* Acantholytic, dyskeratotic, basophilic cells with rouded nuclei and perinuclear halo. Seen in Darier's disease
- *Dyskeratosis:* Abnormal development of epidermal cells (feature of premalignant lesions)
- *Hyperkeratosis:* Increased thickness of stratum corneum
- *Parakeratosis:* Presence of immature nucleated cells in stratum corneum

Dermatological Associations never to be Forgotten

- Pseudomonas in 'Hot-tub folliculitis'
- 'Bacillary angiomatosis' by *Bartonella henselae*.
- 'Bullous impetigo' is due to *S. aureus*
- 'Cellulitis' may be caused by indigenous flora colonizing the skin and appendages by *S. aureus* and *S. pyogenes*
- 'Erysipelas' is due to *Strep. pyogenes*
- 'Impetigo contagiosa' is caused by *Strep. pyogenes*
- Infectious mononucleosis: EBV
- Oral hairy leukoplakia: EBV
- Erythema infectiosum: Parvovirus B19
- Burkitt's lymphoma: EBV
- Exanthema subitum: HHV 6
- Kaposi's sarcoma: HHV8
- Hand-Foot-Mouth Disease: *Coxsackie virus* A 16, *Enterovirus 71*
- Herpes labialis: HSV 1
- *Varicella*: VZV
- *Epidermodysplasia Verruciformis*: HPV
- 'Necrotizing fasciitis', formerly called streptococcal gangrene, may be associated with group A Streptococcus or mixed aerobic-anaerobic bacteria or may occur as part of gas gangrene caused by *Clostridium perfringens*

JAYPEE BROTHERS

- TENS/SSSS: by *Staphylococcus aureus*
- 'Swimmer's itch' in skin surface is exposed to water infested with freshwater avian schistosomes.
- 'Verruca peruana' is caused by *Bartonella bacilliformis*
- HSV (Herpes simplex virus) on the digits of health care workers, 'Herpetic whitlow'
- HSV (Herpes simplex virus) on the head and neck of young wrestlers, 'Herpes gladiatorum'
- HSV: *Eczema herpeticum*
- *Human papillomavirus* may cause singular warts 'verruca vulgaris'
- *Human papillomavirus* with warts in the anogenital area 'condylomata acuminata'
- *Mycobacterium leprae* may be associated with cutaneous ulcerations in patients with lepromatous leprosy related to 'Lucio's phenomenon'
- *Pseudomonas* in '*Ecthyma gangrenosum*'

Cutaneous Manifestations of Medically Important Diseases

- *Tuberous sclerosis:* The earliest cutaneous sign is an **ash leaf spot** plus **adenoma sebaceum** (multiple angiofibromas of the face), **ungual and gingival fibromas**, fibrous plaques of the forehead, and connective tissue nevi **(shagreen patches).**
- *Sarcoidosis:* **Lupus pernio** is a particular type of sarcoidosis that involves the tip of the **nose and the earlobes**, with lesions that are violaceous in color rather than red-brown.
- *Osler-Weber-Rendu disease:* In **hereditary hemorrhagic telangiectasia,** the lesions (Telangiectasis) usually appear during adulthood and are most commonly seen on the mucous membranes, face, and distal extremities, including under the nails.
- *Antiphospholipid syndrome:* **Livedo reticularis.** The majority of cases are secondary to venous hypertension, and disorders of hypercoagulability, e.g. the antiphospholipid syndrome.
- *Disseminated gonococcal infection***:** (**arthritis-dermatitis syndrome**), a small number of papules and vesicopustules with central purpura or hemorrhagic necrosis are found over the joints of the distal extremities. Additional symptoms include arthralgias, tenosynovitis, and fever.
- *Urticaria pigmentosa:* A generalized distribution of red-brown macules and papules is seen in the form of mastocytosis, known as **urticaria pigmentosa.** Each lesion represents a collection of **mast cells in the dermis**, with hyperpigmentation of the overlying epidermis. Stimuli such as rubbing cause these mast cells to degranulate, and this leads to the formation of localized urticaria **(Darier's sign)**.
- *Amyloidosis:* The cutaneous lesions associated with primary systemic amyloidosis are **pink in color** and translucent. As a result, petechiae and purpura develop in clinically normal skin as well as in lesional skin following minor trauma; hence the term '**pinch purpura.**' Amyloid deposits are also seen in the striated muscle of the tongue and result in macroglossia.(Pinch purpura is diagnostic of **primary systemic amyloidosis**).

JAYPEE BROTHERS

- *Sweet's syndrome:* Is characterized by red to **red-brown plaques** and **nodules** that are frequently painful and occur primarily on the head, neck, and upper extremities. The patients also **have fever, neutrophilia, and a dense dermal infiltrate of neutrophils in the lesions.**
- *Fabry's disease:* **Multiple angiokeratomas** are seen in Fabry's disease, an X-linked recessive lysosomal storage disease that is due to a deficiency of galactosidase A. The lesions are red to red-blue in color and can be quite small in size (1 to 3 mm), with the most common location being the lower trunk.

Dermatological Manifestations of Important Skin Conditions

Dermatological Features of Marasmus

- Dry, thin loose skin
- Hair loss, alopecia, fine brittle hair

Dermatological Features of Kwashiorkor

- Generalized dermatitis
- Flaking enamel paint dermatitis
- Increased pigmentaion
- Hair changes flag sign (Change in color from red to gray to white)

Dermatological Features of Vitamin A Deficiency

- Phrynoderma
- Xerosis
- Fissuring of skin

Dermatological Features of Pellagra

- Painful, pruritic dermatitis
- Casal's necklace seen
- Stomatitis, cheilitis, glossitis

Dermatological Features of Scurvy (Vitamin C Deficiency)

- Follicular keratotic plugging
- Corkscrew hairs
- Mucosal bleeding

Dermatological Features of Iron deficiency

- Spoon shaped nails
- Lusterless hair
- Hair loss
- Aphthous stomatitis

Dermatological Features of Acrodermatitis Enteropathica (Zinc Deficency)

- Eczematous dermatitis
- Alopecia

JAYPEE BROTHERS

Dermatological Features of Alkaptonuria

- Grayish discoloration of sclera, face, pinna and nails

Dermatological Features of Fabry's Disease

- Angiokeratomas
- Telangiectasia
- Pseudoacromegalic facies
- Lymphedema
- Raynaud's phenomenon

Dermatological Features of Xeroderma Pigmentosum

- Photosensitivity
- Lentigines/freckles
- Dry parchment like skin
- Premalignant actinic keratosis
- Skin cancers

Dermatological Features of Tuberous Sclerosis

- Hypomelanotic nodules (Confetti lesions)
- Facial angiofibromas
- Shagreen patches
- Ungual fibromas

Dermatological Features of Neurofibromatosis

- Café-au-lait spots
- Neurofibromas
- Freckling in axillary or inguinal region

Dermatological Features of Diabeties

- Acanthosis nigricans
- Eruptive xanthomas
- Fungal and bacterial infections
- Foot ulcers
- Necrobiosis lipoidica
- Bullosis diabeticorum

Dermatological Features of Cushing's Syndrome

- Increased central adiposity
- Skin thinning
- Easy skin brusibility
- Striae in skin

JAYPEE BROTHERS

Dermatological Features of Addisons disease

- Hyperpigmentation of skin and mucosae
- Vitiligo

Dermatological Features of Sarcoidosis

- Sarcoids in skin
- Apple jelly nodules
- Lupus pernio
- Angiolupoid lesions

Dermatological Features of SLE

- Malar/butterfly rash
- Photosensitivity
- Livedo reticularis
- Periungual telangiectasia
- Urticaria

Dermatological Features of Dermatomyositis

- Violaceous erythema
- Gottrons papules
- Poikiloderma

Dermatological Features of Scleroderma

- Raynauds phenomenon
- Calcinosis cutis
- Telangiectasia
- Hardened skin
- Digital ulcerations

Typical Lesions In Dermatological Conditions

Lichen Planus

- Papule
- Plain topped
- Polygonal
- Purple
- Papules
- Wickham's Striae
- Civatte bodies
- Pterygium of nails
- Hepatitis C association

JAYPEE BROTHERS

Atopic Dermatitis

- White dermographism
- Dennie Morgan Folds
- Hertoghes sign
- Cataract and keratoconus

Dermatomyositis

- Heliotrope rash
- Gottrons papules
- Poikiloderma
- Dowlings lines

Ptryiasis Rosacea

- Herald Patch
- Christmas Tree pattern
- Annular collarette of scales
- Mother patch
- Self limiting

Mycosis Fungoides/Cutaneous T Cell Lymphoma

- Sezary lutzner cells
- Pautrier microabscesses

Tuberous Sclerosis

- Ash leaf spot
- Adenoma sebaceum
- Shagreen patches
- Infantile spasms
- Delayed mile stones

Dermatological Disorders with Nail Changes

◆ Psoriasis	◆ Pits
◆ Alopecia areata	◆ Pits
◆ Lichen planus	◆ Pterygium
◆ Scleroderma	◆ Pterygium iversum unguium
◆ Darier's disease	◆ Wedge shaped, hyperkeratotic
◆ Pityriasis rubra pilaris	◆ Yellow brown, hyperkeratotic

The Nail Changes In Dermatology

- *Half and half nails:* White proximally, pink distally. seen in CRF
- *Terry's nails:* White nails with pink tip, seen in cirrhosis

JAYPEE BROTHERS

- *Blue nails:* Chloroquine, Wilsons disease
- *Mees lines:* Arsenic poisoning
- *Onycholysis:* Psoriasis
- *Koilonychia:* Iron deficiency anemia
- *Yellow nail syndrome:* Seen with pleural effusions, edema
- *Nail Patella syndrome:* Hypoplastic nails and patella.
- *Muehrcke nails:* Associated with hypoalbuminemia
- *Koenen's periungual fibroma:* Tuberous sclerosis.

Dermatological signs

- *Asboe Hansen sign (Bulla Spread Sign):* Pemphigus
- *Carpet tack sign:* DLE
- *Cerebriform tongue sign:* Pemphigus vegetans
- *Coup D lounge sign:* Tinea versicolor
- *Crowe sign:* Axillary freckling in neurofibromatosis
- *Fitzpatrick sign:* Dermatofibrosarcoma Protuberans
- *Dubois sign:* Congenital syphilis
- *Hertoghes sign:* Loss of lateral 1/3 of eye brow in atopic dermatitis
- *Leser trelat sign:* Appearance of large number of seborrheic keratoses
- *Ollendorff sign:* Tender papule in secondary syphilis
- *Pillow sign:* Patient sees hair on pillow on getting up at morning
- *Shawl sign:* Erythema over back and shoulders in dermatomyositis
- *Cullen's sign:* Pancreatitis
- *Grey turners sign:* Pancreatitis
- *Sister mary josephs nodule/sign:* Associated with GI Malignancies
- *Hutchinsons sign:* Herpes zoster ophthalmicus

Causative Organisms of STD

(Sexually Transmitted Diseases)

Dorovanosis LGV(esthiomene) Chancroid	Calymmatobacterium grdnulomatis Chlamydia trachomatis H. ducreyi, Herpes hominis
Condyloma acuminata Yaws Pinta	HPV 6, 11, 16, 18 T, pertune T. caratenum

Different Types of Erythema

- *Erythema chronicum migrans:* Lymes disease
- *Erythema ab igne:* Reticulate pigmentation due to long term heat exposure
- *Erythema gyratum repens:* Internal malignancies
- *Erythema nodosum:* Multisystemic disorders, e.g. sarcoidosis.

JAYPEE BROTHERS

- *Erythema multiforme:* Mucosal involvement with viral, bacterial, rickettsial diseases with target lesions
- *Erythema induratum:* Bazin's Disease
- Erythema elevatum diutinum (EED) chronic leukocytoclastic vasculitis, also presents with papules that are red-brown in color. The papules coalesce into plaques on the extensor surfaces of knees, elbows, and the small joints of the hand. Flares of EED have been associated with streptococcal infections.

Cells of Origin of Various Diseases

◆ Actinic keratosis ◆ Bowen's disease ◆ Keratoacanthoma ◆ SCC ◆ Basal cell carcinoma	◆ Keratinocyte
◆ Angiosarcoma ◆ Kaposi sarcoma	◆ Endothelial cell
◆ Melanoma	◆ Melanocyte
◆ Fibrosarcoma	◆ Fibroblast
◆ Liposarcoma	◆ Lipocyte
◆ Trabecular cell carcinoma	◆ Merkel cell
◆ Dermatofibrosarcoma protuberans	◆ Dermal dendrocyte

Side Effects of Important Drugs

- *Drug(s) causing:* Pseudomembranous colitis: Clindamycin
- *Drug(s) causing:* Thrombotic complications: Oral Contraceptives
- *Drug(s) causing tendonitis:* Fluoroquinolones
- *Drug(s) causing Stevens-Johnson syndrome:* Ethosuximide-sulfonamides-lamotrigine
- *Drug(s) causing P450 inhibition:* Cimetidine-ketoconazole-grapefruit juice-erythromycin-INH-sulfonamides
- *Drug(s) causing P450 induction:* Barbiturates-phenytoin carbamazepine-rifampin-griseofulvin-quinidine
- *Drug(s) causing fanconi's syndrome:* Tetracycline
- *Drug(s) causing cutaneous flushing:* Niacin-Ca++ channel blockers -adenosine -vancomycin
- *Drug(s) causing:* Photosensitivity: Tetracycline -amiodarone–sulfonamides
- *Drug(s) causing:* SLE-like syndrome: Hydralazine-Procainamide-INH -phenytoin
- *Drug causing red man syndrome:* Vancomycin
- *Drug causing purple toe syndrome:* Warfarin
- *Drug causing grey baby syndrome:* Chloramphenicol
- *Drug causing amelia:* Thalidomide

JAYPEE BROTHERS

Drugs of Choice for Dermatological Conditions

◆ DOC in brucella:	◆ Doxycycline+rifampicin
◆ DOC in cholera:	◆ Doxycycline
◆ DOC in gonorrhea:	◆ Ceftriaxone
◆ DOC in MRSA:	◆ Vancomycin
◆ DOC in VRSA:	◆ Linezolid
◆ DOC in toxoplasmosis:	◆ Cotrimaxazole
◆ DOC in Lymes disease:	◆ Doxycycline
◆ DOC in p. carnii:	◆ Cotrimaxazole
◆ DOC in syphilis:	◆ Pencillin G
◆ DOC in Actinomycosis:	◆ Pencillin G
◆ DOC in legionella:	◆ Azithromycin/levofloxacin
◆ DOC in LGV:	◆ Azithromycin
◆ DOC in plague:	◆ Streptomycin
◆ DOC in kala-azar	◆ Pentamidine
◆ Oral drug for kala-azar	◆ Miltefosine.

JAYPEE BROTHERS

for detailed information on PGMEE books, visit our website **www.jaypeebrothers.com,** for detailed info

Dermatology Review
A Must for PG Entrance Exams

Salient Features

- Book prepared with the aim of developing a concept in Dermatology
- Covering a wide range of most common dermatological conditions
- Image-based questions incorporated
- Pharmacology related to dermatology included
- Covering a wide range of examinations.

Ashfaq Ul Hassan MBBS MS is currently Consultant–Anatomy in Sher-i-Kashmir Institute of Medical Sciences (SKIMS), Srinagar, Jammu and Kashmir, India with an immense academic expertise in International- and National-level examinations like Membership of the Royal College of Surgeons (MRCS) and United States Medical Licensing Examination (USMLE).

Sheikh Manzoor Ahamed MD (Dermatology) is a renowned Dermatologist with a great expertise in dermatology. He is currently heading the Dermatology department in Sher-i-Kashmir Institute of Medical Sciences (SKIMS), Srinagar, Jammu and Kashmir, India. His academic interest in this project has been a rich source of inspiration. His research capabilities in the field of dermatology are well established.

Available at all medical bookstores
or buy online at www.jaypeebrothers.com



JAYPEE BROTHERS
Medical Publishers (P) Ltd.
www.jaypeebrothers.com

Join us on facebook.com/JaypeeMedicalPublishers

