n dental books, visit our website **www.jaypeebrothers.com,** for detailed information on dental books



MCQs

MCQs in Oral Pathology

(With Explanatory Answers)

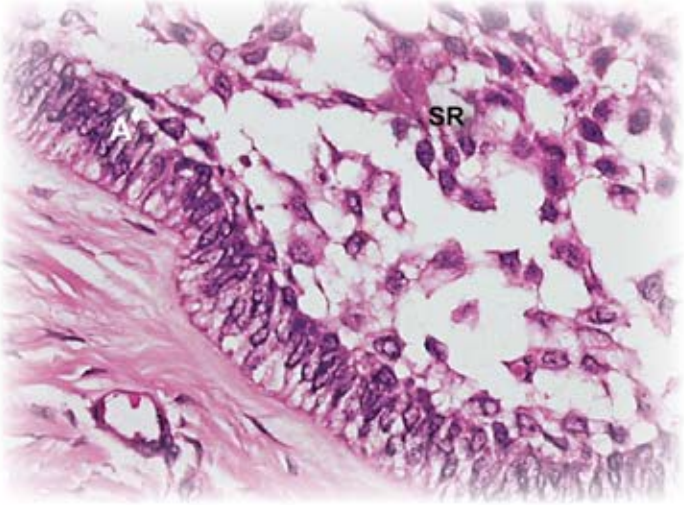

Sundeep S Bhagwath

Foreword
Dr (Col) NK Ahuja

JAYPEE

Contents

1. Developmental Anomalies of Orofacial Structures Including Teeth 1
2. Dental Caries 9
3. Diseases of Pulp and Periapical Tissues 17
4. Diseases of Periodontium 25
5. Infections: Bacterial, Viral and Mycotic 33
6. Spread of Oral Infections 40
7. Benign and Malignant Nonodontogenic Tumors of Oral Cavity 48
8. Odontogenic Cysts and Tumors 66
9. Diseases of Salivary Glands 85
10. Diseases of Osseous Structures 94
11. Diseases of Skin 102
12. Hematological Diseases 110
13. Diseases of Nerves and Muscles 118
14. Disorders of Metabolism 125
15. Healing of Oral Wounds 133
16. Physical and Chemical Injuries of Teeth 141
17. Regressive Changes of Oral Cavity 150

3 Diseases of Pulp and Periapical Tissues

1. The most common cause of odontalgia is
   (a) Dental caries (b) Pulpitis
   (c) Root fracture (d) Periodontitis
2. The phenomenon by which bacteria circulating in blood accumulate at the site of pulpal inflammation is called as
   (a) Chemotaxis (b) Retrograde pulpitis
   (c) Anachoretic pulpitis (d) Aerodontalgia
3. Most accepted explanation for anachoretic pulpitis is
   (a) Increased capillary permeability
   (b) Increased vascular pressure
   (c) Presence of large number of dilated capillaries
   (d) Lack of collateral blood supply
4. Pulpitis aperta and pulpitis clausa refer to types of pulpitis classified on the basis of
   (a) Severity of inflammation
   (b) Extent of inflammation
   (c) Location of inflammation
   (d) Presence/absence of direct communication with oral cavity
5. The more accepted terminology for pulp hyperemia is
   (a) Focal irreversible pulpitis
   (b) Focal reversible pulpitis
   (c) Subtotal pulpitis
   (d) Pulpitis clausa

JAYPEE BROTHERS

6. Focal reversible pulpitis is most commonly seen in all of the following cases except
   (a) Large metallic restorations
   (b) Shallow carious lesions
   (c) Deep carious lesions
   (d) Restorations with defective margins

7. Pain which increases in intensity as the patient lies down is characteristic of
   (a) Focal reversible pulpitis
   (b) Acute pulpitis
   (c) Chronic hyperplastic pulpitis
   (d) Chronic pulpitis

8. Microabscess formation within inflamed pulp is characteristic of
   (a) Acute pulpitis
   (b) Focal reversible pulpitis
   (c) Chronic pulpitis
   (d) Pulp hyperemia

9. Sensitivity to electric pulp vitality tester in acute pulpitis is lost in later stages because of
   (a) Necrosis of pulp
   (b) Reduction in inflammatory exudate
   (c) Increase in the size of capillaries locally
   (d) Decreased secretion of prostaglandins

10. Pulp reacts to electric pulp vitality tester at higher levels in chronic pulpitis due to
    (a) Slow advance of pulp inflammation
    (b) Lack of edema fluid collection within inflamed pulp
    (c) Degeneration of nerves in affected pulp
    (d) Deposition of collagen around inflamed area

11. Which amongst the following characteristics is not associated with chronic hyperplastic pulpitis?
    (a) Open carious lesion
    (b) Occurs in children and young adults
    (c) Occurs in people with high tissue resistance
    (d) Occurs around margins of a restoration

JAYPEE BROTHERS

12. Which teeth are most commonly involved by chronic hyperplastic pulpitis?
    (a) Deciduous anteriors and permanent canines
    (b) Deciduous molars and permanent 1st molars
    (c) Deciduous canines and permanent incisors
    (d) Exclusively deciduous molars

13. All of the following except _____ occur as a sequel to pulpitis.
    (a) Lateral periodontal cyst
    (b) Periapical granuloma
    (c) Apical periodontal cyst
    (d) Periapical abscess

14. All of the following except _____ are common radiological features associated with a periapical granuloma.
    (a) Thickening of PDL around root apex
    (b) Well-defined radiopacity
    (c) Root resorption of involved tooth
    (d) Well-defined radiolucency with sclerotic borders

15. Giant cell hyaline angiopathy and Rushton bodies are associated with which of the following lesions?
    (a) Ludwig angina
    (b) Odontogenic keratocyst
    (c) Pulp polyp
    (d) Periapical granuloma

16. Which cells, secreting osteoclast activating factor are believed to be responsible for much of root and bone destruction in periapical granulomas?
    (a) B lymphocytes
    (b) T lymphocytes
    (c) Macrophages
    (d) Mast cells

17. Foam cells within periapical granulomas are _____ cells that have ingested lipids.
    (a) Polymorphonuclear leukocytes
    (b) Langerhans cells
    (c) Macrophages
    (d) Plasma cells

JAYPEE BROTHERS

18. Cholesterol clefts observed in periapical granulomas are derived from
    (a) Breakdown of adipose cells
    (b) Breakdown of epithelial cells
    (c) Breakdown of RBCs
    (d) Breakdown of cholesterol

19. Apical periodontal cyst usually occurs as a sequela of
    (a) Acute pulpitis (b) Periodontal abscess
    (c) Osteomyelitis (d) Periapical granuloma

20. _____ is least likely to produce any noticeable signs or symptoms.
    (a) Radicular cyst (b) Acute pulpitis
    (c) Periapical abscess (d) Ludwig angina

21. Which amongst the following is not a predisposing factor of osteomyelitis?
    (a) Trauma to bone (b) Radiation damage to bone
    (c) Paget's disease (d) Fibrous dysplasia

22. What is the most frequent cause of acute osteomyelitis of jaw?
    (a) Dental infection (b) Trauma
    (c) Paget disease (d) Malnutrition

23. Condensing osteitis is another name for
    (a) Chronic suppurative osteomyelitis
    (b) Chronic focal sclerosing osteomyelitis
    (c) Chronic diffuse sclerosing osteomyelitis
    (d) Garre's osteomyelitis

24. In which type of osteomyelitis will you find focal gross thickening of periosteum with peripheral reactive bone formation?
    (a) Chronic focal sclerosing osteomyelitis
    (b) Chronic diffuse sclerosing osteomyelitis
    (c) Florid osseous dysplasia
    (d) Garre's osteomyelitis

25. Root resorption is commonly seen in
    (a) Cellulitis (b) Radicular cyst
    (c) Garre's osteomyelitis (d) Periapical abscess

JAYPEE BROTHERS

26. What term is applied to a radiolucent lesion within the alveolar ridge at the site of a previous tooth extraction?
    (a) Lateral radicular cyst (b) Lateral periodontal cyst
    (c) Residual cyst (d) Periapical abscess

27. If a periapical abscess drains intraorally through a sinus tract after perforating the buccal cortical plate and surface epithelium it forms a mass of granulation tissue known as
    (a) Phoenix abscess (b) Residual cyst
    (c) Parulis (d) Lateral radicular cyst

28. The lateral radicular cyst arises from
    (a) Cell rests of Malassez
    (b) Cell rests of Serres
    (c) Overlying oral epithelium
    (d) Dental lamina

29. Which of the following lesions cannot be differentiated from each other on the basis of size and radiographic appearance?
    (a) Periapical granuloma from periapical cyst
    (b) Periapical abscess from periapical cyst
    (c) Periapical granuloma from periapical abscess
    (d) Periapical cyst from phoenix abscess

30. Chronic apical periodontitis is another name of
    (a) Phoenix abscess (b) Periapical abscess
    (c) Periapical granuloma (d) Periapical cyst

ANSWERS

1. (b) Pulp is a soft connective tissue like any other connective tissue throughout the body and reacts to bacterial or other stimuli by an inflammatory response which causes toothache or odontalgia.
2. (c) Anachoresis is a phenomenon by which blood-borne bacteria, dyes, pigments, etc. are attracted to the site of inflammation.
3. (a) Current evidence indicates increased capillary permeability to be the most probable cause for the phenomenon of anachoresis. The capillary size increases due to the

JAYPEE BROTHERS

liberation of cytokines by the inflammatory cells mediating the response.

4. (d) Pulpitis aperta and clausa refer to open and closed pulpitis respectively. Open pulpitis refers to pulpitis in which direct communication exists between the inflamed pulp and oral cavity while it is absent in case of closed pulpitis.
5. (b) Vascular dilatation can occur pathologically due to dentinal as well as pulpal irritation and also artefactually during tooth extraction. Hence the term pulp hyperemia needs to be avoided.
6. (b) Focal reversible pulpitis is a mild form of pulpitis localized primarily to the pulpal ends of irritated dentinal tubules and is mostly seen in deep carious lesions, beneath large uninsulated restorations and restorations with defective margins.
7. (b) As intrapulpal abscess formation involves more of the pulp tissue, the pain becomes more acute and is liable to increase when the patient lies down. This may be due to the pressure on pulpal nerves by the intrapulpal abscesses. Heat application can exacerbate the pain.
8. (a) Rise in intrapulpal pressure associated with inflammatory exudate leads to collapse of venous part of circulation in that area which leads to anoxia, which in turn, leads to localized destruction and formation of small abscess called micro or pulp abscess.
9. (a) Early stages of acute pulpitis is characterized by stabbing or lancinating pain and high sensitivity to electric pulp vitality tester. But when more of pulp is involved and necrosis sets in this sensitivity is lost.
10. (c) Due to degeneration of the small nonmyelinated nerve fibers, the pulp in chronic pulpitis exhibits little or no pain and reacts to electric pulp vitality tests at higher voltages even in advanced cases.
11. (d) Pulp polyp or chronic hyperplastic pulpitis is characterized by excessive and exuberant pulp proliferation. It is seen almost exclusively in children and young adults with large, open carious lesions.
12. (b) These teeth are primarily involved because of their excellent blood supply and large root opening.

JAYPEE BROTHERS

13. (a) Lateral periodontal cyst is a developmental variety of odontogenic cyst and does not arise due to inflammatory changes within pulp.
14. (b) Periapical granuloma is characterized radiologically by a well-defined radiolucent lesion associated with the root of a pulpally involved tooth.
15. (a) Giant cell hyaline angiopathy consists of inflammatory cell infiltration, collections of foreign body type giant cells and ring-like eosinophilic material called Rushton bodies.
16. (b) The T-lymphocytes are thought to liberate osteoclast activating factor and also other cytotoxic lymphokines, collagenases and other enzymes which may be responsible for much of destructive potential of periapical granuloma.
17. (c) In some periapical granulomas, large numbers of phagocytes (macrophages) ingest lipid material and become collected in groups of so called foam cells. Cells appear "clear" because the entire ingested lipid is washed off during tissue processing involving solvents like alcohol, xylene, etc.
18. (c) Cholesterol clefts seen in chronic inflammations like periapical granuloma are usually derived from the breakdown of extravasated red blood cells. Here also, the same explanation as above holds true for the formation of clear, needle-like spaces.
19. (d) The usual mode of development of apical periodontal cyst or radicular cyst is through stimulation and proliferation of cell rests of Malassez within the periapical granuloma.
20. (a) Majority of cases of radicular cysts are asymptomatic and the dentist discovers them accidentally during routine dental radiological examination. This is due to the fact that cysts are chronic lesions, developing slowly.
21. (d) The major predisposing factors of osteomyelitis are – trauma, gunshot wounds, Paget's disease, osteopetrosis and systemic conditions like malnutrition, acute leukemia, uncontrolled diabetes, chronic alcoholism, sickle cell anemia, etc.
22. (a) A periapical abscess if it is not walled off and is very virulent, may spread spontaneously throughout the surrounding bone.
23. (b) Condensing osteitis is an unusual reaction of bone to mild bacterial infection entering the bone through carious tooth

JAYPEE BROTHERS

in persons having high degree of tissue resistance and reactivity.

24. (d) Garre's osteomyelitis results from mild irritation or infection and is seen almost exclusively in premolar (–) molar regions of young individuals below 25 years of age. The subperiosteal reaction is manifested characteristically as "onion skin" appearance on a radiograph.
25. (b) As the radicular cyst enlarges in size, it causes the resorption of root to which it is attached primarily due to pressure exerted by it.
26. (c) A residual cyst is one that remains behind on the alveolar ridge after a tooth is extracted without initially ascertaining its periapical condition.
27. (c) With progression, a periapical abscess spreads along the path of least resistance. The pus may extend through the medullary spaces away from the apical area (osteomyelitis), or it may perforate the cortex and spread diffusely through the overlying soft tissue (cellulitis). It can also channelize through the overlying soft issue leading to parulis or gumboil.
28. (a) Like the periapical cyst this lesion also usually arises from rests of Malassez. The source of inflammation may be periodontal disease or pulpal necrosis with spread through a lateral foramen.
29. (a) Both lesions are a result of a chronic process. Due to this they enlarge slowly and produce similar radiographic appearances.
30. (c) The term periapical granuloma refers to a mass of chronically inflamed granulation tissue at the periapical region of a nonvital tooth.

JAYPEE BROTHERS

for detailed information on dental books, visit our website **www.jaypeebrothers.com,** for detailed info

MCQs in
Oral Pathology
(With Explanatory Answers)

Salient Features

- Purports to orient the undergraduate students towards attempting the multiple choice questions (MCQs) that are increasingly becoming a part of both the regular examinations as well as the entrance examinations for various postgraduate courses in dentistry
- Different levels of questions have been framed on the subject of Oral Pathology so that students of all types of academic capabilities can benefit from the book
- Questions framed and explanations offered in clear and lucid language so that there is no ambiguity in understanding the questions and the explained answers.
- Explanatory answers have been provided so that the students can easily review the entire chapter easily.

Sundeep S Bhagwath is presently working as a Professor (Oral Pathology) and Head, Department of Basic Sciences, College of Dentistry, University of Háil, Kingdom of Saudi Arabia. He is involved in teaching the subjects of Oral Pathology, Oral Anatomy and Oral Histology for the past 13 years. He has been appointed as the Examiner of undergraduate as well as postgraduate examinations in different universities.



He has already published a book on Oral Anatomy, Oral Histology, Oral Embryology, and Oral Physiology. Besides, he has published papers in several national and international journals.

Available at all medical bookstores
or buy online at www.jaypeebrothers.com



JAYPEE BROTHERS
Medical Publishers (P) Ltd.
www.jaypeebrothers.com

Join us on facebook.com/JaypeeMedicalPublishers

Shelving Recommendation
DENTISTRY

