on radiology books, visit our website **www.jaypeebrothers.com,** for detailed information on radiology books, visit our website **www.jaypeebrothers.com**

Get Full Access with added features at **emedicine360.com**



Vascular Imaging and Intervention

ation on radiology books, visit our website **www.jaypeebrothers.com,** for detailed information on radiology books, visit our website **www.jaypeebrothers.com**

Get Full Access with added features at **emedicine360.com**



Vascular Imaging and Intervention

Volume 1







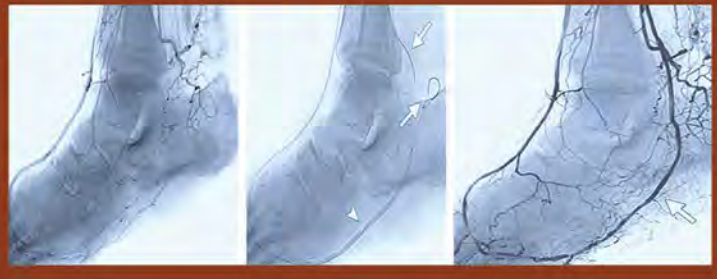





Ducksoo Kim
Dan E Orron
Nilesh H Patel
Alik Farber

Forewords
Sven Paulin
Jacob Cynamon
Anthony J Comerota

JAYPEE

Contents

VOLUME 1

Section 1: Vascular Imaging

1. **Digital Subtraction Imaging and Cone-beam C-Arm CT Imaging** 3
   Kerstin Müller, Sanjit Datta, Gloria Hwang, David S Wang, Nishita Kothary
2. **CT Angiography** 19
   Erin Angel
3. **Magnetic Resonance Angiography** 31
   Hernán J Jara
4. **Intravascular Ultrasound** 44
   Mohamed A Zayed, Jason T Lee
5. **Angioscopy** 57
   Yasumi Uchida, Yasuto Uchida

Section 2: Radiation Safety

6. **Radiation Safety and Protection Systems** 81
   Richard H Behrman, Chet R Rees

Section 3: Contrast Agents

7. **Intravascular Contrast Media** 127
   Carla C Moreira, Jordan V Lao, Ducksoo Kim
8. **CO_2 Angiography** 141
   Kyung J Cho

Section 4: Patient Care and Pharmacologics

9. **Conscious Sedation, Pain Management, and Patient Monitoring** 165
   Emerson E Sharpe III, Charles E Ray
10. **Pharmacologics: Systemic and Transcatheter Therapies** 178
    Lindsay M Arnold, Ashvin N Pande

Section 5: Vascular Anatomy

11. **Arterial Anatomy of the Chest and Neck** 199
Steven Deso, Dan E Orron, Ducksoo Kim

12. **Arterial Anatomy of the Abdomen and Pelvis** 212
Steven Deso, Gabriel P Howles-Banerji, Dan E Orron, Ducksoo Kim

13. **Arterial Anatomy of the Upper and Lower Extremities** 238
Dan E Orron, Ibrahim A Idakoji, Ducksoo Kim

14. **Venous Anatomy** 268
Ducksoo Kim, John R McGrath, Nilesh H Patel, Dan E Orron

Section 6: Vascular Pathology

15. **Pathology of Vascular Disease** 309
Gilad W Vainer, Juri Kopolovic, Sho Torii, Aloke V Finn, Renu Virmani

16. **Pathophysiology of Thrombosis** 343
Andrea T Obi, Rafael Alvarez, Jose A Diaz, Daniel D Myers, Peter K Henke, Thomas W Wakefield

Section 7: Noninvasive Vascular Imaging

17. **Imaging of the Extracranial Carotid Artery** 363
Tjun Y Tang, Umar Sadat, Marina C Bernal-Fernández, Mohamad Abdalkader

18. **CT and MR Imaging of the Thoracic Vasculature** 393
Tetsuro Araki, Galit Aviram, Ashish Khandelwal, Michael L Steigner, Manav Bhalla, Hiroto Hatabu

19. **Noninvasive Vascular Imaging of the Abdomen and Pelvis** 422
Jeanette Y Chun, Matthew Hoimes, Young Kim

20. **Noninvasive Vascular Imaging of the Female and Male Reproductive Organs** 465
Marco Molina, Igor Latich, Daniel Cornfield, Jeffrey S Pollak, Leslie M Scoutt

21. **Noninvasive Vascular Testing and Imaging: A Brief Introduction and Selected History** 513
Joseph R Schneider

22. **Imaging of Upper and Lower Extremity Vascular Diseases** 551
Parag P Tolat, William D Foley

Section 8: Angiographic Techniques

23. **Basic Techniques and Complications of Angiography** 589
Roger T Tomihama, Elizabeth Tang, Dan E Orron, Charles Y Kim, Carlos J Guevara, Charles S Sutton, Ducksoo Kim

24. **Selective Catheterization Technique** 635
Charles Y Kim, Carlos J Guevara, Dan E Orron, Ducksoo Kim

Section 9: Endovascular Devices

25. **Interventional Devices: Guidewires, Catheters, Balloons, and Stents** 649
Adam R Geronemus, Barry T Katzen

26. Endovascular Devices for Vascular Occlusive Disease 668
Matthew Walsworth, Justin P McWilliams

27. Advanced Endovascular Devices 696
Brian F Stainken

28. Endovascular Embolization Devices, Agents, and Techniques 720
Matthew Walsworth, Stanley Kim, Ripal T Gandhi, Sekhar Rao, Ducksoo Kim

29. Endovascular Robotics 771
Sandeep Rao, Francis MacNamara

30. Endovascular Simulation 780
Sandeep Rao, Kevan Stewart

Section 10: Head and Neck Vascular Disease and Intervention

31. Endovascular Management of Cervical Carotid Arterial Disease 789
Naren Gupta, Jeffrey J Siracuse, Eyal Avraham, Ron Karmeli

32. Chronic Cerebrospinal Venous Insufficiency 818
Nii-Kabu Kabutey, Paolo Zamboni

33. Carotid and Vertebral Arterial Injuries: Penetrating and Blunt Trauma 832
Mohammad H Eslami, Jonathan D Gates

34. Neuroendovascular Management of Tumors and Vascular Malformations of the Head and Neck 843
Laligam N Sekhar, Farzana Tariq, Louis J Kim, Danial K Hallam, Basavaraj Ghodke

VOLUME 2

Section 11: Thoracic and Abdominal Vascular Disease and Intervention

35. Central Venous Stenosis and Occlusion 875
Seanthan Senthilnathan, Dheeraj K Rajan, Nilesh H Patel

36. Clinical and Therapeutic Overview of Pulmonary Embolism 897
Alison Witkin, Praveen Hariharan, Christopher Kabrhel

37. Pharmacomechanical Treatment of Pulmonary Embolism 912
Jason T Salsamendi, Rahul Arya, Shanchita Ghosh, Issam I Kably, Mehul H Doshi, Govindarajan Narayanan

38. Pulmonary Interventions 924
Steven Zangan, Brian Funaki, Jonathan Lorenz

39. Aortic Dissection: Diagnosis, Classification, and Endovascular Management 944
Dan E Orron, Tilo Kölbel, Martin Funovics, Michael J Verta, Johannes Lammer

40. Overview of Endovascular Aortic Replacement: Past, Present, and Future 1000
Jessica P Simons, Andres Schanzer

41. Abdominal Aortic Aneurysms: Endovascular Aneurysm Repair (EVAR) 1010
Parag J Patel, Matthew J Scheidt, Cuong H Lam, James F Benenati, Michael J Verta

42. Thoracic Endovascular Aortic Repair (TEVAR)..... 1035
Michael J Verta, Michael Singh, Eitan Heldenberg, Ralf R Kolvenbach, Dan E Orron

43. Management of Endoleak after EVAR and TEVAR..... 1083
Edward Kim, Amish Patel, Vinit B Amin

44. Trauma of the Abdomen and Pelvis: Penetrating and Blunt..... 1097
Thomas N Carruthers, Alik Farber

45. Vena Cava Filters..... 1133
Nilesh H Patel, Renato Ripamonti, Venkataramu N Krishnamurthy, Ducksoo Kim

Section 12: Visceral Vascular Disease and Intervention

46. Gastrointestinal Interventions (Arterial and Venous)..... 1175
Tze-Woei Tan, Wayne W Zhang

47. Gastrointestinal Hemorrhage and Intervention..... 1192
Carlos J Guevara, Charles Y Kim, Rahul Arya, Ducksoo Kim

48. Interventions for Portal Hypertension and Budd-Chiari Syndrome..... 1223
Claire S Kaufman, Keith B Quencer, John A Kaufman

49. Portal Vein Embolization..... 1247
Sekhar Rao, Sirish Kishore, Rahul Arya, Ducksoo Kim, Winston Brooks Davis

50. Hepatic Interventional Oncology..... 1265
Winston Brooks Davis, Matthew S Johnson

51. Vascular Interventions in Nonhepatic Abdominal and Pelvic Malignancies..... 1290
Bruno C Odisio, Sanjay Gupta

52. Renal Vascular Interventions..... 1308
Nilesh H Patel, Dan E Orron, Venkataramu N Krishnamurthy

Section 13: Peripheral Vascular Disease and Intervention

53. Peripheral Arterial Disease and Intervention..... 1357
Tze-Woei Tan, Alik Farber

54. Role of Exercise Training for Patients with Peripheral Arterial Disease..... 1375
Mickey Scheinowitz

55. Clinical Aspects of the Diabetic Foot..... 1380
Palma M Shaw, Gary W Gibbon

56. Collagen Vascular Disorders and Vasculitides: General Overview and Endovascular Considerations..... 1393
Kush Agrawal, Ashvin N Pande, Robert T Eberhardt

57. Acute Limb Ischemia: Atherosclerotic and Nonatherosclerotic Causes in the Upper and Lower Extremities..... 1410
Michael D Sgroi, Nii-Kabu Kabutey, Dan E Orron, Michael Singh

58. Endovascular Management of Chronic Lower Extremity Limb Ischemia..... 1433
Danielle E Casasso, Megan Bowen, Palma M Shaw, Tariq M Bhat, Lawrence A Garcia, Dan E Orron, Peter A Schneider

59. Endovascular Interventions in Diabetic Foot Care 1486
Dan E Orron, Roberto Ferraresi, Alex Belenky, Marco Manzi

60. Trauma of Extremity: Penetrating and Blunt 1517
Jeffrey Kalish, Rajendran Vilvendhan

61. Thromboembolic Disease: Lower Extremity and Inferior Vena Cava 1525
Suresh Vedantham

62. Venous Insufficiency 1535
Michael J Verta

Section 14: Vascular Malformations

63. Congenital Vascular Malformations: A Concise Overview in Diagnosis and Management 1559
Naomi Shin, Byung-Boong Lee

64. Vascular Anomalies 1579
Orhan Konez

Section 15: Venous and Hemodialysis Access

65. Central Venous Access 1631
Yosef S Golowa, Paul J O'Connor, Jacob Cynamon

66. Hemodialysis Access Interventions 1655
Dirk M Hentschel, R Furman Borst, Paul Laeseke, Nii-Kabu Kabutey, Ducksoo Kim, John R Ross

Section 16: Venous Sampling and Foreign Body Removal

67. Venous Sampling 1687
Barry A Sacks, Olga R Brook, Ian M Brennan, Johanna A Pallotta

68. Endovascular Foreign Body Retrieval: A Modern Reappraisal of Indications, Techniques, and Complications 1727
Kush Agrawal, Dan E Orron, Ducksoo Kim

Section 17: Genitoreproductive Diagnosis and Interventions

69. Prostatic Artery Embolization for Benign Prostatic Hyperplasia 1743
Dan E Orron, Sandeep Bagla, Shivank Bhatia, Ducksoo Kim, Francisco Cesar Carnevale

70. Failure of the Testicular Venous Drainage System (Varicocele): Male Infertility and Benign Prostatic Hyperplasia—Diagnosis and Management 1796
Menachem Goren, Dan E Orron, Yigal Gat

71. Erectile Dysfunction: Endovascular Diagnosis and Treatment 1832
Neeraj Rastogi, Nii-Kabu Kabutey, Ducksoo Kim

72. Female Genitoreproductive Interventions 1843
Ducksoo Kim, Leslie M Scoutt, Rahul Arya, Dan E Orron

Index 1895

Chapter

4

Intravascular Ultrasound

Mohamed A Zayed, Jason T Lee

INTRODUCTION

Ultrasonography is a tenant of vascular imaging, diagnosis, and therapy. The wide application of this technology has considerably increased alongside the rapid and popular use of percutaneous endovascular interventions for the treatment of a spectrum of vascular disease spanning nearly all body parts and arterial beds.[1] With the advent of miniaturized piezoelectric transducers at the tips of intraluminal catheters, intravascular ultrasound (IVUS) has emerged as a new and powerful tool that provides interventionalists an added diagnostic advantage to detect and treat vascular disease.[2,3] Popularized by its demonstrated efficacy in the coronary circulation, IVUS has since been incorporated into the diagnosis and three-dimensional characterization of a variety of arterial and venous diseases.[4,5] In addition, its applications for use has in recent years expanded to facilitate complex procedural planning, assist with the choosing of necessary endovascular devices, and guide the accurate deployment of these devices. Herein is a review of the different designs of IVUS catheters, diagnostic imaging modalities, and potential uses for endoluminal vascular therapy.

CATHETER DESIGNS

First utilized for measuring intracardiac dimensions in the 1950s, initial IVUS prototypes were fixed to large intraluminal catheters and used A-mode imaging transducers. It was not until the 1970s that IVUS catheters were redesigned to allow acquisition of intraluminal cross-sectional imaging.[2,6] At the time 360° cross-sectional imaging was facilitated by mechanical rotation of the catheter tip transducer element, or by using an electronically switched array for automatic acquisition. With either modality the ultrasound beam was emitted across a circumferential area and a receiver element simultaneously detected the direction and intensity of the reflected signals.

Current IVUS catheters are designed to have a smaller transducer element attached at the tip of a low profile catheter that may be advanced into a vessel lumen. The catheters are designed to be flexible and withstand high torque in order to provide adequate pushability, as they are advanced across intraluminal vascular segments of interest. The transducer element at the tip of the catheter contains a piezoelectric crystal that produces sound waves when electrically excited (Figs. 4.1A and B). There are currently two major different IVUS catheter transducer designs. One is a mechanical single element rotating design and the other is an electronic phased array design.[4,7] Mechanical rotating element devices use a single piezoelectric transducer that rotates ~1,800 rotations per minute to assemble a 360° cross-sectional image of the vessel lumen of interest. To avoid guidewire-related artifacts, newer mechanical IVUS catheters allow for guidewire retrieval prior to activation of the transducer element for image acquisition. Electronic phased array devices use multiple stationary piezoelectric transducers that are sequentially activated to also provide a complete 360° cross-sectional image.[7] With either catheter design, sound waves generated by catheter tip transducer elements penetrate, propagate, and reflect back to the catheter receiver elements based upon tissue impedance and reflection properties to generate the cross-sectional image. Compared to phased array, rotational IVUS catheters are thought to have less ringdown artifacts because they operate in a small saline-filled chamber or lumen.

Current IVUS catheters range between 2.9 and 9 Fr (0.87 and 1.17 mm), and have transducer element frequencies ranging between 10 and 40 MHz. At these frequencies,

JAYPEE BROTHERS

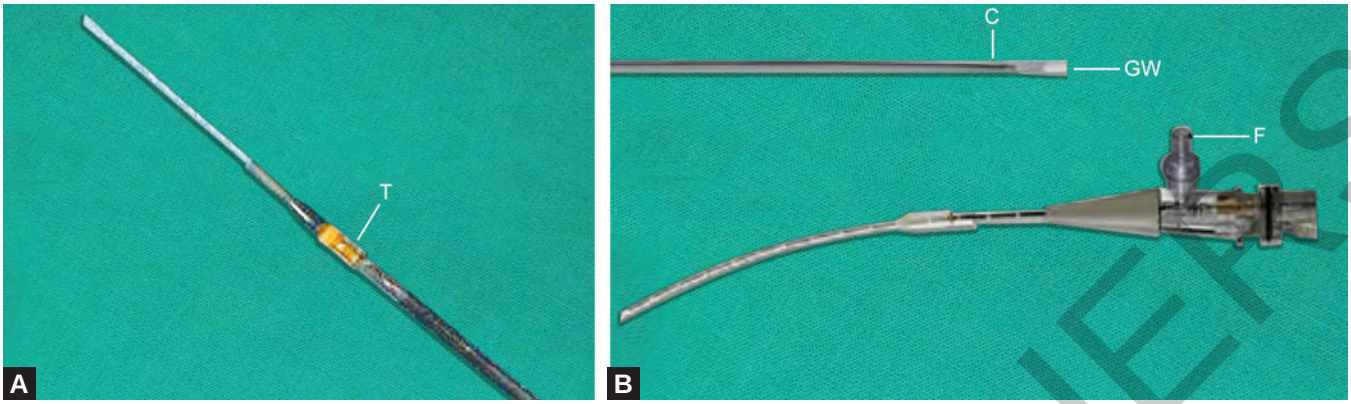

Figs. 4.1A and B: Commonly used peripheral vascular intravascular ultrasound catheters. (A) Visions PV 018 (Volcano Therapeutics, Rancho Cordova, CA, USA); (B) Atlantis SR Pro (Boston Scientific, Natick, MA, USA). (T: Transducer element; C: Catheter; GW: Guidewire; F: Flush port).

Table 4.1: Specifications of commonly used IVUS catheters.

Size	*Frequency*	*Length*	*Introducer sheath*	*Guidewire*	*Target vessel*
8.2 Fr	10 MHz	90 cm	9 Fr	0.038″	Aorta iliac
3.4 Fr	20 MHz	135 cm	6 Fr	0.018″	Carotid renal iliac femoral
2.9 Fr	20 MHz	150 cm	5 Fr	0.014″	Femoral popliteal tibial
Volcano Corporation, Rancho Cordova, CA, USA					
9 Fr	9 MHz	110 cm	9 Fr	0.035″	Aorta iliac
6 Fr	12.5 MHz	110 cm	8 Fr	0.035″	Iliac femoral
3.2 Fr	40 MHz	135 cm	6 Fr	0.018″	Femoral popliteal tibial
Boston Scientific, Natick, MA, USA					

(IVUS: Intravascular ultrasound).

the axial resolution is 200 µm, and the lateral resolution is ~200–250 µm. Although this is associated with limited spatial resolution and higher signal-to-noise ratio compared to other forms of conventional ultrasonography, newly designed IVUS catheters have improved electronic programming that allows for enhanced image acquisition, processing, and analysis. These include image postprocessing methods such as virtual histology IVUS (VH-IVUS, Volcano Corporation, Rancho Cordova, CA, USA), iMAP-IVUS (Boston Scientific, Natick, MA, USA), Integrated Backscatter IVUS (IB-IVUS), and Automated Differential Echogenicity (ADE).[8]

ACCESS

Intravascular ultrasound catheters are introduced in either arterial or venous vascular structures following standard vascular access. These accesses are established either percutaneously, or via direct arteriotomy or venotomy. Placement of a sheath (5–9 Fr) over a guidewire into the newly established vascular access maintains a hemostatic access to the vessel of interest. Sheath size and type will depend on the access vessel diameter and anatomic location (Table 4.1). A typical retrograde common femoral artery access will require only a 5 or 6 Fr access sheath.

JAYPEE BROTHERS

Upper extremity brachial or axillary artery sheath access may require 5, 6, or 7 Fr access sheaths with lengths of 10–65 cm. Larger 10–14 Fr sheath sizes may be needed to maintain access to the aorta from a common femoral entry, or to the vena cava from a common femoral vein or internal jugular vein entry. After establishing sheath access to the vessel of interest, an IVUS catheter can then be advanced over a standard guidewire (0.014"–0.035") into the vessel that is intended for imaging.

CATHETER SELECTION

The choice of IVUS catheter to be used will depend on several factors and requires preprocedural planning. The type of IVUS catheter to be used will primarily depend on the indication for vascular imaging, on the planned adjunct procedures, and on the vascular segment that is planned for imaging. In the United States, currently available IVUS catheters that are produced by Volcano Corporation include Eagle Eye Platinum (compatible with a 5-Fr access and a 0.018" wire), Eagle Eye Gold (compatible with a 0.014" wire), Revolution 45 MHz (a rotational IVUS catheter), Visions PV 018 (compatible with a 0.018" wire; Fig. 4.1A), and Visions PV8.2F (compatible with a 0.038" wire). Boston Scientific also produces the iCross (compatible with a 6 Fr access and at least a 0.014" wire), and Atlantis SR Pro (40 MHz, and compatible with a 6 Fr access; Fig. 4.1B).

The second consideration when selecting a catheter of choice is the approximate distance between the vascular access site and the vascular segment that is being planned for imaging. Currently available IVUS catheter lengths range from 90 to 150 cm. From a standard retrograde transfemoral access, these catheter lengths can image proximally in the thorax and distally to into the tibial vessels.

Third, the desired lateral imaging resolution of selected vascular structures of interest also determines the type of IVUS catheter to be used (Table 4.1). Larger 8.2-Fr catheters can image up to 6 cm depth, while smaller 2.9-, 3.2-, and 3.4-Fr catheters have more limited lateral resolution. For aortic and vena caval imaging larger catheter diameters are preferable and may be advanced into position over a 0.035" guidewire. On the other hand, imaging of femoral, popliteal, and tibial arteries is preferable using smaller catheters, which are advanced over 0.018" or 0.014" guidewires.

IMAGE ACQUISITION

Mobile IVUS catheters used to interrogate vascular segments of interest are anchored to an electronic port to facilitate data transmission to an imaging computer console. This allows for real-time image acquisition that can then be simultaneously displayed on an associated computer unit display monitor. Snapshot gray-scale cross-sectional images can be obtained from areas of interest in the imaged vessel, or a sequence of images may be recorded at a preset frame acquisition rate as the IVUS catheter is moved through the lumen of the vessel. Generally, IVUS image quality is better if the catheter is withdrawn through the area of interest rather than being advanced through it. Therefore, it is advisable to pass the IVUS catheter beyond the vascular area of interest, and then withdraw the catheter through the area of interest during the process of image acquisition.

Intravascular ultrasound image quality is dependent on appropriate catheter selection, as well as appropriate positioning and maneuvering of the catheter tip through the vessel lumen of interest. Catheter size, length, and transducer element frequency will mostly depend on the segment of vasculature that is planned for imaging. Thus, appropriate preprocedure planning can aid with this and with appropriate device selection. Moreover, eccentric positioning of the IVUS catheter in a vessel lumen may yield cross-sectional imaging that is hyperechoic along the segment of arterial lumen closest to the catheter transducer element.[9] These artifacts can decrease image quality, and misrepresent vessel lumen diameter and wall thickness. Therefore, it is important to carefully position the IVUS parallel to the walls of the vessel and with the catheter tip near the center of the vessel lumen.

DIAGNOSTIC APPLICATIONS

The diagnostic benefits of IVUS use are widely reported. As reviewed in Table 4.2, various data parameters can be collected from IVUS-derived images. In addition to multidimensional length, width, and area measurements at various different cross-sectional and longitudinal vascular segments, IVUS can also provide detailed information regarding plaque thickness, length, morphology, and composition characteristics. Furthermore, IVUS can identify other vessel wall defects (such as flaps, dissections, or ulcerations), as well as luminal pathologies (such as thrombosis, stenosis, or occlusion).[2]

JAYPEE BROTHERS

Table 4.2: Summary of IVUS diagnostic image parameters and applications.

Categories of IVUS imaging parameters and applications
Luminal measurements
True lumen diameter
Lumen width and length
Cross-sectional area and luminal volume
Wall characteristics
Wall thickness
Layers
Morphology and composition
Plaque lesions
Size (diameter, area, volume)
Position (concentric vs eccentric)
Type (fibrous, fibrofatty/lipid, calcific, necrotic, mixed)
Vessel wall defects
Flaps and dissections
Wall ulceration
Patency
Luminal thrombus
Extent of stenosis
Intimal thickening

(IVUS: Intravascular ultrasound).

Intravascular ultrasound–derived vessel wall morphology, luminal dimensions, and wall thickness measurements are accurate to within 0.05 mm in normal to minimally diseased vessels. However, measurements of outer vessel wall diameter can be less accurate with an error margin up to 0.5 mm. Cross-sectional areas calculated from IVUS also have good accuracy and correlate well with biplanar angiographic assessments. In severely disease vessels, IVUS has actually been shown to be more accurate in lumen area assessments when compared to angiography, which could sometimes underestimate the severity of luminal atherosclerosis.[8]

In muscular arteries, there are distinct sonographic features associated with different vessel wall layers.[10] The media appears as a dark echolucent layer that is layered between more echodense intima and adventitia. The internal and external elastic laminae appear in these layers as hazy backscatter substrates. The adventitial layer thickness is variable and is best evaluated if there are distinct identifiable surrounding tissue layers of different echogenicity, such as fat or muscle tissue. This three layer wall appearance is partially lost in the aorta and larger elastic arteries due to high elastin content in the vessel wall media. Similarly, smaller distal arterial structures and venous structures have less discernable vessel wall layers.[11] Nevertheless, luminal fibrosis, intimal hyperplasia, or stenosis in these vascular structures yield pathologically distinct features compared to the nondisease native vasculature, which facilitates the diagnosis of these conditions.

Cross-sectional gray-scale IVUS imaging can yield important information about stage and extent of atheromatous disease in imaged vessel segments.[5] Mixed plaques represent >80% of plaque subtypes that are visualized in disease arterial lumens imaged in different parts of the body and are composed of heterogenous echos.[12,13] Soft plaque lesions are hypoechoic densities that may encroach into the vessel lumen and are usually less echoic than the adventitia surrounding the vessel being imaged (Fig. 4.2). This type of plaque is widely disbursed throughout the vasculature, but is more often visualized in medium and small diameter arteries. Fibrous plaque has intermediate echogenicity, while calcified plaque is highly echoic and may be associated with significant imaging artifacts such as acoustic shadowing or ring down effects. These plaque types are more common in larger arteries and at vascular bifurcation points.

Cross-sectional IVUS imaging is also an important tool for mapping out vascular anatomy. Like angiography, IVUS can provide detailed diameter and length measurements in the thoracic aorta, paravisceral and pararenal abdominal aorta, and pelvic iliac systems. For example in the thoracic aorta, IVUS can clearly demonstrate the bifurcation points of the right innominate artery, left carotid artery, and left subclavian artery (Fig. 4.3A). This detailed visualization can facilitate cannulation of these orifices, or provide measurements necessary for periprocedural planning. Similarly, in the paravisceral abdominal aorta, major side branches such as the celiac trunk, superior mesenteric artery, renal arteries, and even larger accessory renal arteries can be adequately visualized (Fig. 4.3B).

Longitudinal gray-scale IVUS imaging is also a feature of newer IVUS catheters and linked electronic processing units (Fig. 4.2). Similar to cross-sectional images, these images are obtained while mechanically withdrawing the IVUS catheter through the vessel of interest at a controlled rate, while recording images at a predefined frame acquisition rate. Some IVUS units streamline this process with automated pullback devices that provide an even more accurate reconstructed view of the vessel of interest. The cross-sectional images obtained by a pullback view are then stacked by the processing unit and turned sideways to produce a longitudinal view, similar to an angiogram, of the vessel being interrogated. The utility of longitudinal images is expanding, and has so far been useful in

JAYPEE BROTHERS

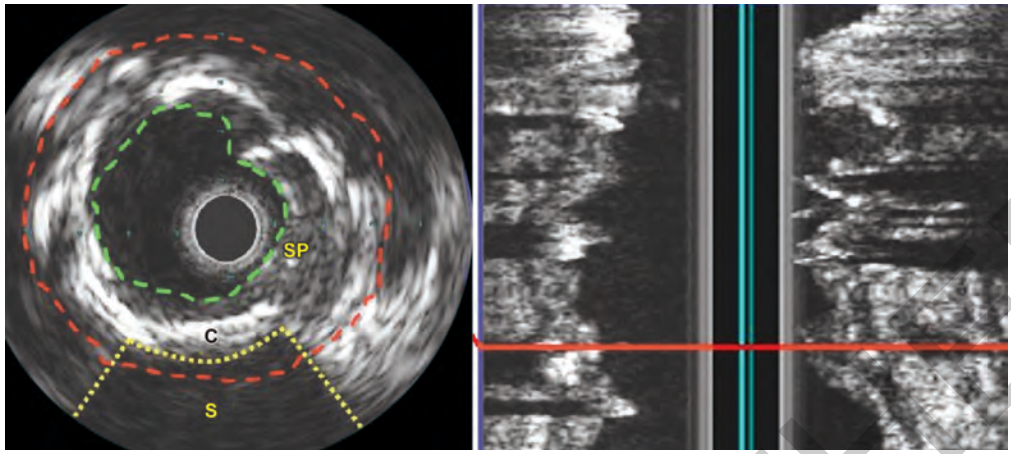

Fig. 4.2: Cross-sectional and longitudinal image of a diseased segment of the superficial femoral artery. Cross-sectional intravascular ultrasound (IVUS) image with vessel wall demarcated between luminal border (green) and outer boundary of the vessel adventitia (red). Moderate heterogeneous plaque formations are observed in vessel walls in both cross-sectional and longitudinal IVUS images. There is mild luminal narrowing also observed in the cross-sectional image. (SP: Soft plaque; C: Clacific plaque; S: Shadowing artifact posterior to calcific plaque).

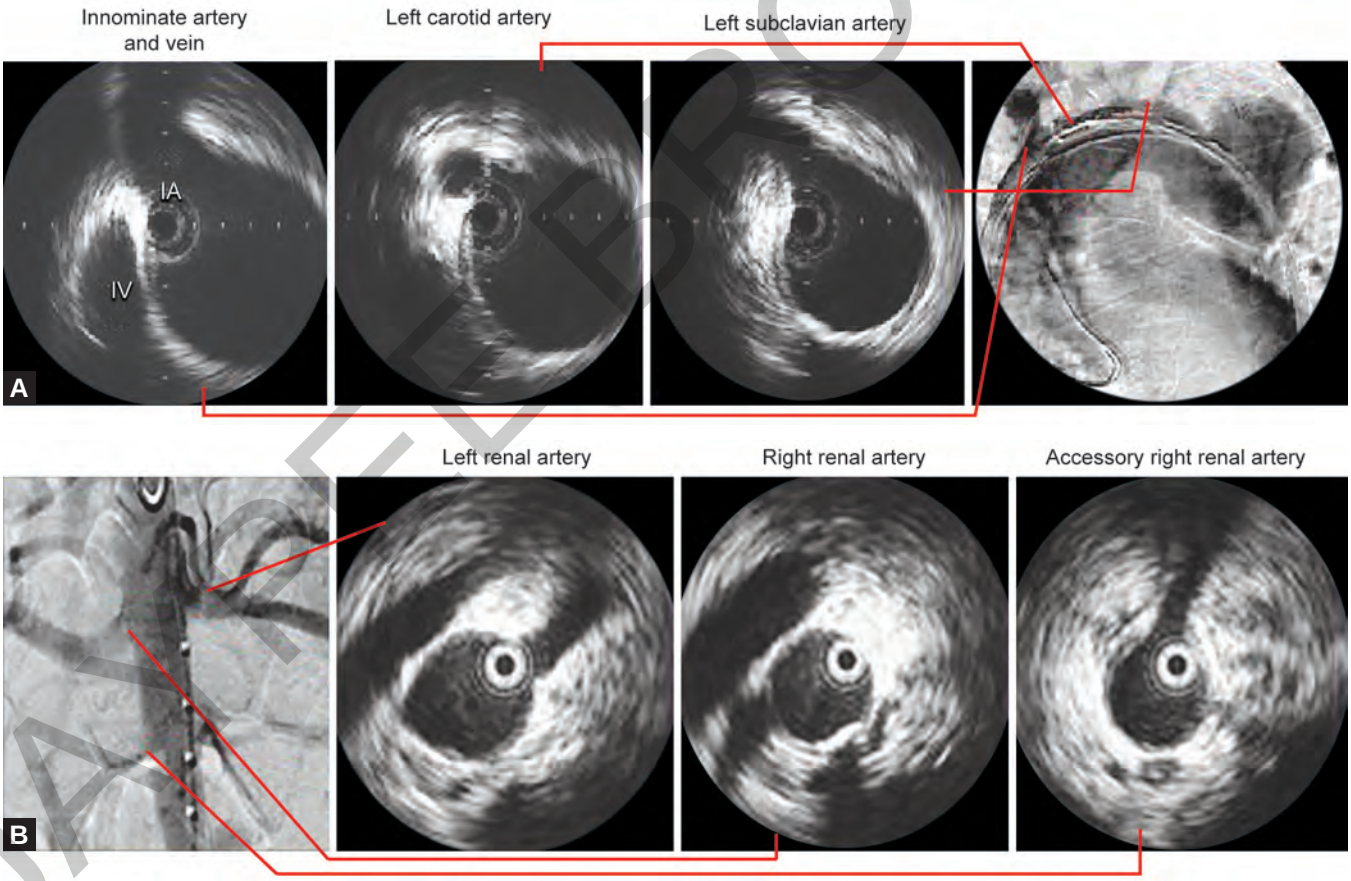

Figs. 4.3A and B: Diagnostic intravascular ultrasound (IVUS) imaging helps detail major aortic bifurcation points. (A) In the thoracic aorta, the right innominate artery, left carotid, and left subclavian artery orifices are clearly visualized on IVUS at corresponding points on thoracic aortic angiogram. Aortic diameters at each of these bifurcation points can be obtained as well as length measurements from each orifice to the other. (B) In the abdominal paravisceral aorta, the celiac artery, superior mesenteric artery, bilateral renal arteries, and a large accessory renal artery are visualized with IVUS at corresponding points on abdominal aortic angiogram. (IA: Innominate artery; IV: Innominate vein).

JAYPEE BROTHERS

delineating lumen and vessel diameters, assess vessel wall plaque morphology and characteristics, evaluate for false lumens or dissection planes, and measure distances between important orifices or branches.[8]

As useful adjuncts to qualitative gray-scale imaging, new imaging capabilities have recently become readily available to help yield additional diagnostic information in vascular segments of interest. One example of this is raw radiofrequency analysis (RF analysis), which is a novel signal-based analysis tool that allows for vessel wall tissue composition analysis.[8] Using either a 45 MHz 3.2 Fr rotational catheter (Revolution, Volcano Therapeutics) or a 20 MHz 2.9 Fr phased array transducer catheter (Eagle Eye Gold, Volcano Therapeutics), RF backscatter signals can be collected and electronically processed using virtual histology software (VH-IVUS, Volcano Therapeutics) to yield detailed descriptions of vessel wall atheromatous plaque composition (Fig. 4.4A).[14] Similarly, with a 40 MHz rotational single element IVUS catheter in the coronary vasculature, iMAP-IVUS may be used to analyze types of coronary plaque. In general RF-analysis describes subdivides plaques into four general categories including fibrous tissue, fibrofatty or lipid tissue, necrotic core, or dense calcium. When compared to gross histopathology of vessel tissue, this technique has demonstrated good plaque correlation, which has also been validated in several in vivo and ex vivo studies (Fig. 4.4B).[8,15]

Other luminal defects such as intimal flaps and tears may also be visualized on gray-scale IVUS imaging due to their contrasting echoic properties with surrounding blood and segment of normal arterial wall (Fig. 4.5). Similarly, intraluminal thrombus can be distinguished from the underlying vessel wall, and typically appears as a highly echogenic, homogenous layer with varying image attenuation beyond its location within the vessel lumen (Fig. 4.6). Moreover, several pathological vascular lesions can be diagnosed using IVUS. While coronary angiograms in cardiac transplant recipients may appear normal, IVUS has been shown to be useful in detecting accelerated intimal thickening (intimal hyperplasia) in this patient population.[16] Similarly, IVUS can aid in determining patient candidacy for pulmonary thromboendarterectomy in the setting of severe pulmonary hypertension,[17] provide intravena cava assessments of tumor thrombus burden in patients with renal cell carcinoma extension,[18] and help delineate the extent of thoracic aortic trauma in the setting of equivocal aortograms.[3]

THERAPEUTIC APPLICATIONS

Beyond the diagnostic advantages of IVUS in evaluating patterns of disease, lesion morphologies, and luminal dimensions, IVUS also provides opportunities to facilitate treatment of various types and distributions of vascular disease. As an adjunct imaging modality it can help to accurately visualize areas of interest, and image them in relation to associated vascular structures or nearby landmarks, such as adjacent organs, vessels, ostia, or branches. Moreover, IVUS can facilitate the guidance of endovascular treatment of vascular occlusive disease, venous thromboembolic disease, arterial aneurysmal disease, and luminal trauma and dissections. In these clinical scenarios, IVUS not only guides precise deployment of endovascular devices and implants but also provides useful post-treatment assessments that determine the success of the treatment and the likely durability of the repair.

PERCUTANEOUS BALLOON ANGIOPLASTY

Treatment of arterial occlusive disease with percutaneous transluminal angioplasty is now a mainstream method of care. Adjunctive use of IVUS in this setting provides useful pre- and postprocedural assessments.[19] In heavily diseased, but not occluded vascular segments, IVUS can provide information on the extent of vessel disease and the extent of calcific plaque content. These findings can guide the decision whether or not to pursue angioplasty of a diseased vascular segment, versus the pursuit of alternative methods of treatment such as primary stenting.[20] Furthermore, IVUS can provide pretreatment vessel and luminal measurements that can be helpful in balloon size selection, which can sometimes be underestimated with qualitative angiographic assessments. Accordingly, preprocedure IVUS evaluations of coronary arteries have been shown to guide such therapeutic decisions during coronary interventions either with angioplasty or stenting. These evaluations have demonstrated improved long-term patient outcomes and cost-effectiveness.[21]

Postangioplasty, IVUS has also been shown to be a useful procedure adjunct. In this setting, IVUS can accurately detect the degree of success in increasing luminal area, or on the other hand detect the presence of residual plaque, plaque ruptures, luminal dissections, and tears in

JAYPEE BROTHERS

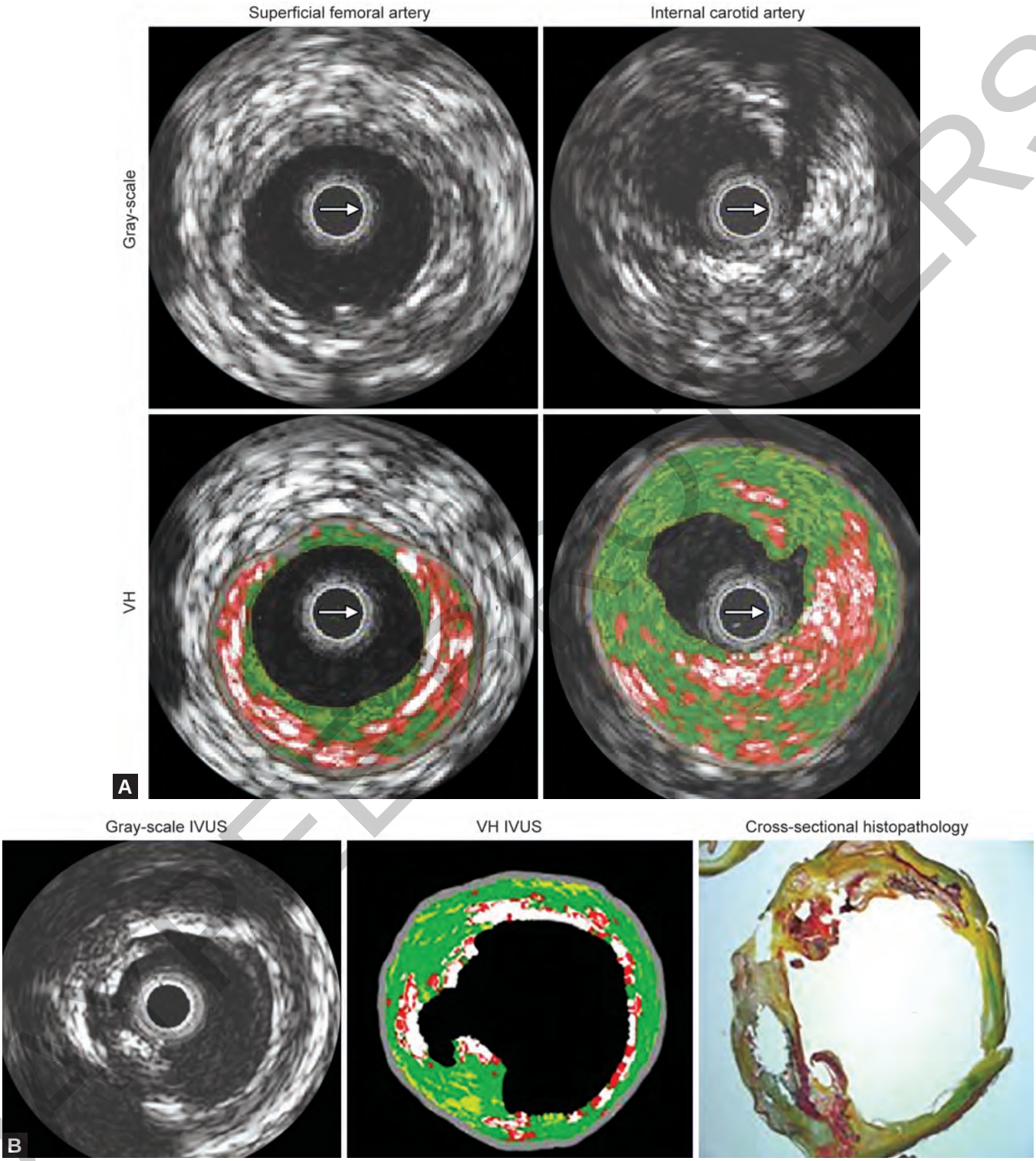

Figs. 4.4A and B: Correlation of virtual histology (VH) intravascular ultrasound with gray-scale imaging and gross histopathology. (A) Different plaque morphologies and composition are observed in segments of diseased superficial femoral artery and internal carotid artery. Areas that are hyperechoic correlate with VH calcific plaque, while areas that are hypoechoic correlate with VH fibrous and fibrofatty plaque. (B) Segment of diseased superficial femoral artery demonstrates areas of calcific plaque that correlate on gray-scale imaging, VH, and gross histopathology. *Courtesy*: Volcano Corporation, Atlas of Peripheral Vascular Disease, Rancho Cordova, CA, USA.

JAYPEE BROTHERS

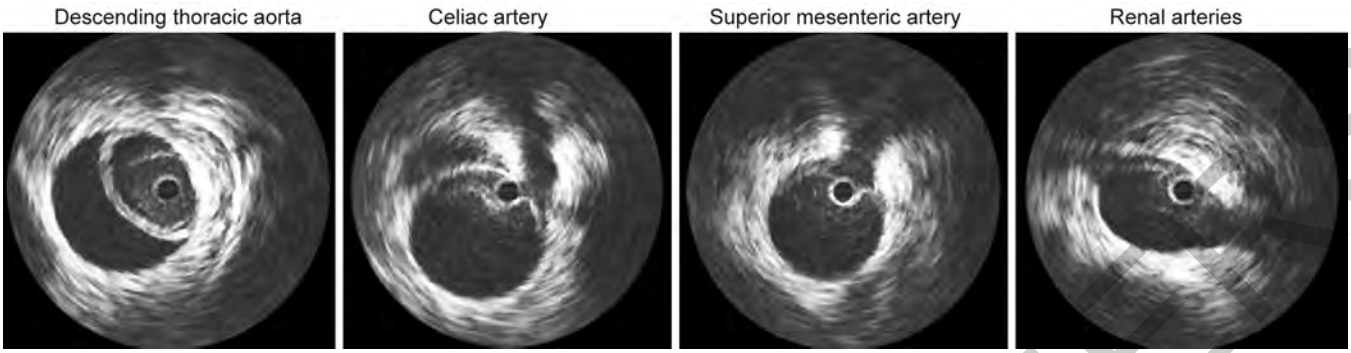

Fig. 4.5: Characterization of a type B descending aortic dissection using intravascular ultrasound (IVUS). Intravascular ultrasound catheter is advanced from a standard transfemoral approach into the true aortic lumen in the descending aorta. A dissection plane is visualized in IVUS cross-sectional images with variable degrees of patency of the true and false lumens. Critical aortic side branches are also visualized at different aortic levels.
Courtesy: Volcano Corporation, Atlas of Peripheral Vascular Disease, Rancho Cordova, CA, USA.

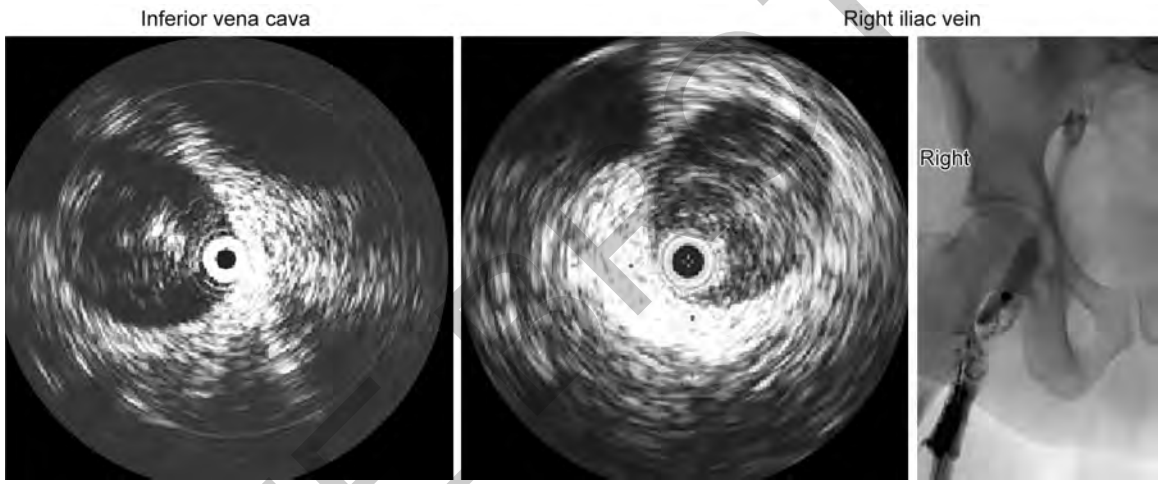

Fig. 4.6: Diagnosis of inferior vena cava and right iliac venous thrombosis using intravascular ultrasound (IVUS). Heterogenous hyperechoic structures visible in cross-sectional IVUS images of inferior vena cava and right iliac vein are indicative of intraluminal thrombus. Findings on IVUS correlate with right iliac venogram.
Courtesy: Volcano Corporation, Atlas of Peripheral Vascular Disease, Rancho Cordova, CA, USA.

vessel intima and internal elastic lamina (Fig. 4.7).[6,22] It can also detail areas of possible residual stenosis, which may or may not appear flow limiting on completion angiograms. In these situations further therapy with follow-up stenting may be considered depending on the location, size, and plaque anatomy of the vascular segment undergoing treatment. In the short-term, IVUS has been shown to detect post-angioplasty hemodynamically significant luminal dissections that required follow-up stenting. In the longer term, IVUS in patients who underwent superficial femoral artery interventions was helpful in predicting factors associated with postangioplasty vessel restenosis from possible recoil, intimal hyperplasia, or recurrence of disease.[6,23] Interestingly, in these studies the majority of patients who underwent angioplasty, luminal dimensions increased due to overstretching of the arterial wall from intimal microtears, while the plaque volume essentially remained the same. Similar findings were also reported in the coronary circulation, demonstrating that Postangioplasty IVUS can help predict areas for possible future disease progress and restenosis in the coronary vasculature.[21]

INTRAVASCULAR STENTS

The most common indications for stent deployment following balloon angioplasty include complex or deep arterial wall dissections, elastic recoil with significant residual stenosis, hemodynamically significant pressure gradient across a previously treated lesion, or a plaque

JAYPEE THE PEERS

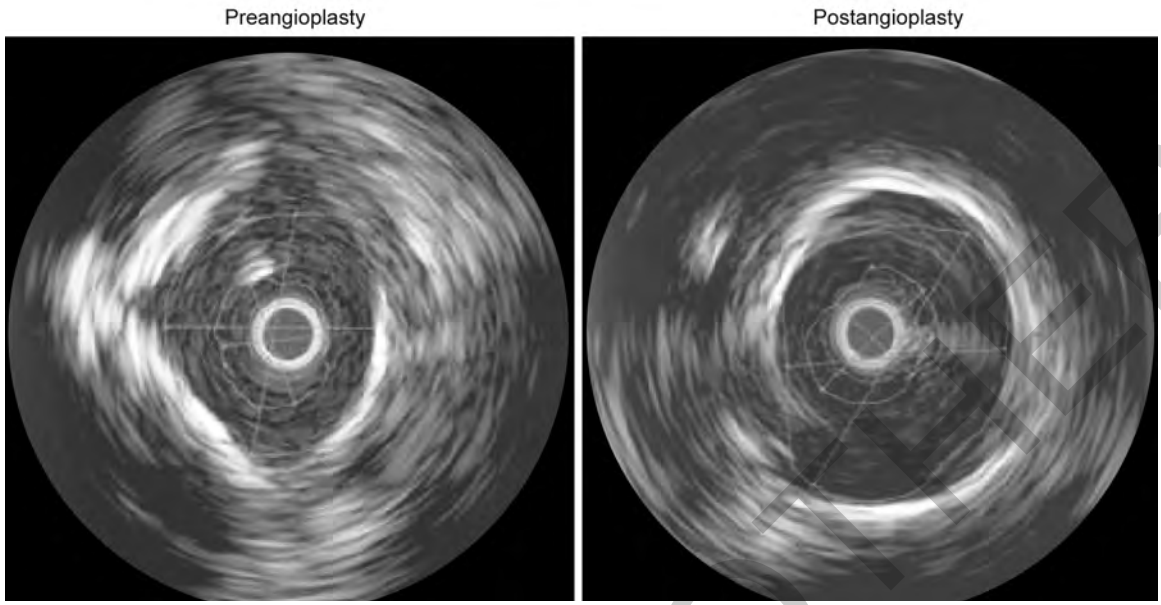

Fig. 4.7: Intravascular ultrasound (IVUS) assessment of superficial femoral artery segment pre- and postangioplasty treatment. Preangioplasty IVUS demonstrates a moderately diseased superficial femoral artery segment with mild calcific plaque and moderate luminal narrowing. Postangioplasty luminal area is increased from 21.8 to 31.4 mm^3. There is mild luminal wall irregularity, likely a result of luminal tears associated with angioplasty-induced distension.

ulceration with local thrombus accumulation.[6] Several studies have demonstrated the improved patency of primary and selective stenting following incomplete or suboptimal results following angioplasty.[20] In specific arterial segments such as the external iliac arteries, there is compelling data that demonstrates that primary stenting of hemodynamically significant stenoses or arterial occlusions have longer patency compared to selective stenting or angioplasty alone. However, stent placement is not devoid of risk, and can be complicated by stent migration, inadequate stent expansion (Fig. 4.8), excessive intimal hyperplasia, vessel damage and/or perforation, early thrombosis, or occlusion.[24]

In addition to evaluating the need for stenting a vascular segment, IVUS also guides the stent deployment process. In the coronary arteries, IVUS technology demonstrates adequate stent expansion in only 13–20% of treated coronary lesions that appeared satisfactory on fluoroscopic angiography.[25] In the majority of procedures that demonstrated incomplete stent expansion, IVUS facilitated the use of further angioplasty to enhance complete stent effacement, apposition, and expansion. Similarly, in the peripheral vasculature it is estimated that stent deployment using standard angiographic guidance results in suboptimal positioning and/or expansion of stents in as many as 20–40% of cases.[3] In these cases, IVUS provides essential cross-sectional information that may otherwise not be appreciated on standard two-dimensional angiography.[26] Arko et al. demonstrated that long-term patency is improved in stented iliac arteries that also undergo IVUS to help define appropriate post-stenting angioplasty diameter endpoint and adequacy of stent apposition.[27]

Intravascular ultrasound has also demonstrated utility with carotid artery stenting procedures. Complementary to standard fluoroscopic angiography, IVUS can accurately visualize carotid artery stent placement and adjacent vessel wall morphology. This information is critical in helping decide whether additional post-stenting angioplasty is necessary to achieve the desired luminal diameter endpoint. Moreover, with newer imaging processing software, virtual histology of carotid artery lesions can yield novel information regarding carotid plaque morphology and composition (*see* Figs. 4.4A and B).[15] Current investigations are underway to determine whether specific plaque characteristics render patients at higher risk of periprocedural cerebral microembolic events or stroke.[28]

ENDOVASCULAR AORTIC ANEURYSM TREATMENT

The success of endoluminal exclusion of abdominal and thoracic aortic aneurysms depends on appropriate patient

JAYPEE BROTHERS

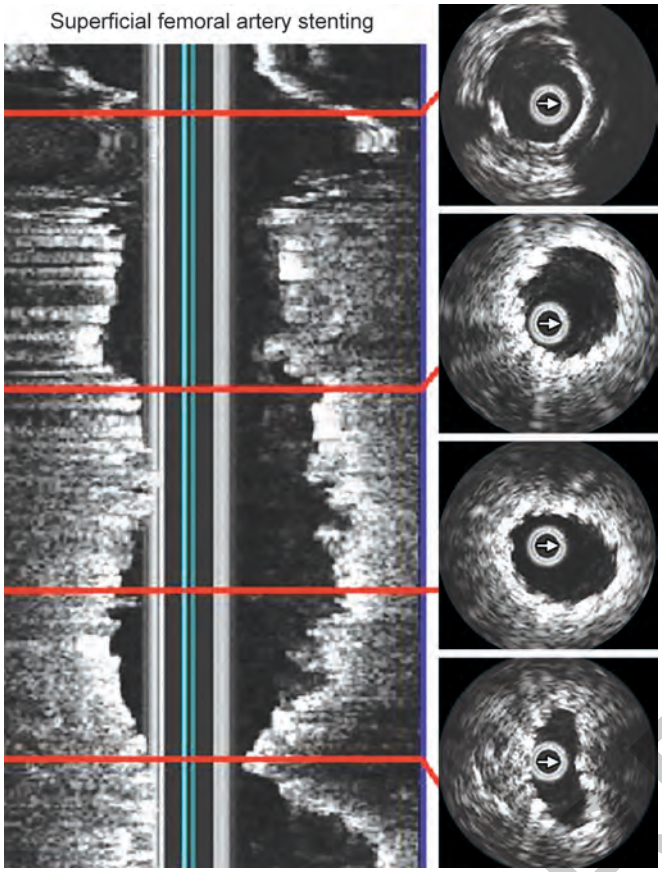

Fig. 4.8: Poststenting intravascular ultrasound (IVUS) can identify areas with incomplete stent expansion. Longitudinal IVUS image demonstrates unstented region (top part of the imaged segment) and stented region (mid and lower parts of the imaged segment) of the superficial femoral artery. Distal segment of stented superficial femoral artery with moderate luminal narrowing as demonstrated on longitudinal IVUS. Corresponding cross-sectional IVUS image confirms incomplete stent expansion in this segment. Remainder of the stent appears to be fully expanded with adequate wall apposition.

selection, accurate preoperative, and intraoperative visualization of the aortic and para-aortic anatomy, and the proper physical deployment of stent-graft devices. Several studies have demonstrated the utility and benefit of adjunctive IVUS to help determine the optimal sites for stent-graft deployment.[29] Particularly in paravisceral and pararenal aortic segments IVUS can accurately identify essential side branches that need to be preserved and not covered by the stent-graft deployment. Furthermore, immediately prior to stent-graft selection and deployment intraoperatively, IVUS can be used to visualize the aortic proximal fixation and iliac distal fixation sites to help confirm appropriate device selection.[3] In some series 30–40% of patients treated with endovascular stent-grafts were found to require stent-grafts with diameters that are different than what was anticipated on preoperative CT scans.[30]

Intraoperatively IVUS can also help determine whether full stent-graft expansion has occurred, and provide information regarding stent-graft surface topography, alignment, and movement of the graft material in the aortic lumen (Fig. 4.9). Incomplete proximal or distal stent-graft fixation can be visualized by observing either aortic or iliac incomplete stent-graft apposition against the arterial side wall, stent-graft enfolding, or motion of the stent-graft with arterial pulsations. Experimental series observed incomplete proximal balloon-expandable stent expansion in nearly 20% of patients, which was not observed on standard two-dimensional arterial angiography techniques.[3] Intraoperative identification of these subtle findings are important since underexpansion of either proximal or distal fixation sites can lead to endoleaks, device migration, increased need for secondary interventions, and a continued risk of aneurysm sac rupture.

In specific cases, some have also demonstrated that deployment of aortic stent-grafts can be guided by only using IVUS.[31] Although the use of cine-fluoroscopy is considered to be the standard technique, IVUS in these cases is used in patients who are unable to tolerate contrast boluses due to tenuous comorbidities including poor renal function. Nevertheless, the potential for IVUS to guide procedures such as aortic stent-graft deployment, which are conventionally thought to require fluoroscopic guidance, can help to minimize radiation exposure to both personnel and the patient, as well as decrease the risk of contrast-induced nephrotoxicity.

AORTIC TRAUMA AND DISSECTIONS

Endovascular interventions for acute aortic traumatic injuries, or acute and chronic type B aortic dissections provide an appealing alternative to open surgical techniques that are associated with higher rates of morbidity and mortality.[32] With deployment of an endovascular stent-graft an aortic pseudoaneurysm can be covered and completely sealed off to prevent risk of rupture and hemorrhage. In the case of aortic dissection, accurate stent-graft placement can also effectively seal the dissection entry site and allow for obliteration of the dissection flap while restoring blood flow to the true lumen. Intravascular ultrasound confirms placement of the guidewire within the true lumen, accurately sizes proximal and distal landing zones, and helps identify important anatomic landmarks

JAYPEE BROTHERS

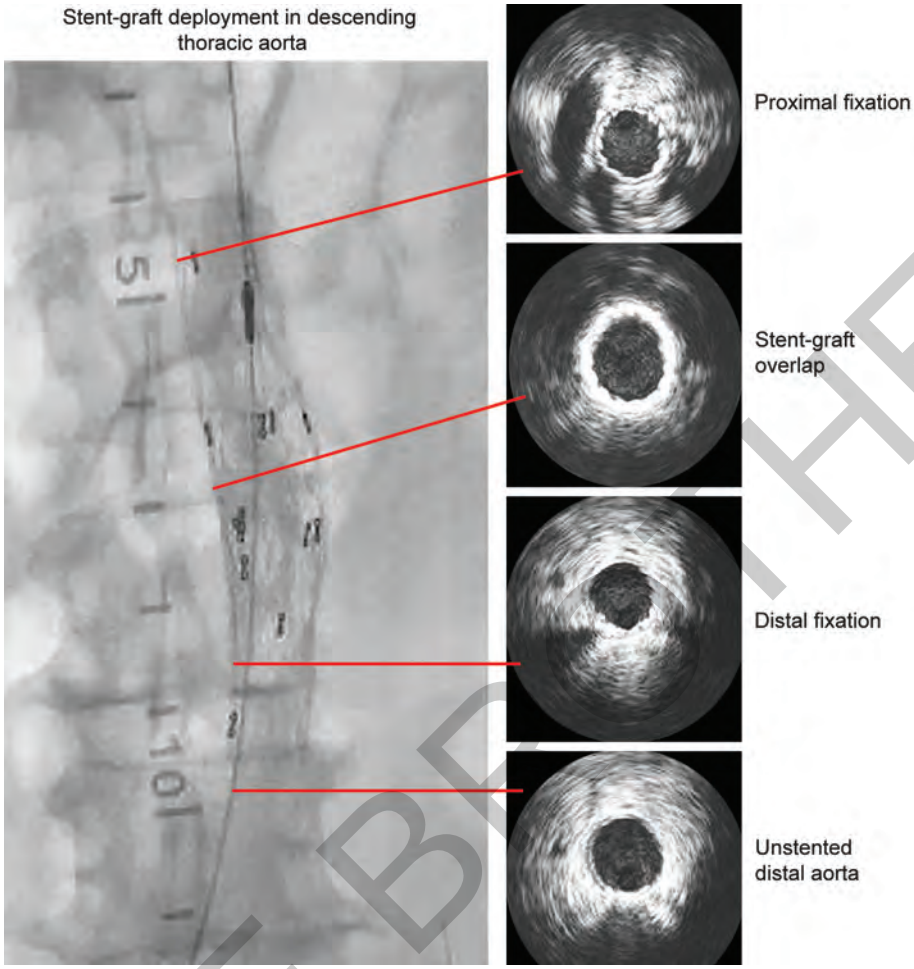

Fig. 4.9: Intravascular ultrasound (IVUS) evaluation of descending thoracic aorta stent-graft deployment. Cross-sectional IVUS images at corresponding levels on fluoroscopy demonstrate a well-apposed aortic stent-graft, with fully expanded stent-graft proximally and distally. Area of stent-graft overlap is also fully apposed. Full-stent apposition suggests a decreased likelihood of postoperative endoleaks.
Courtesy: Volcano Corporation, Atlas of Peripheral Vascular Disease, Rancho Cordova, CA, USA.

and their relative distance to the level of aortic trauma (Fig. 4.10) or dissection entry point. This is particularly important in the proximal descending thoracic aorta where it may be necessary to obtain precise visualization of the left carotid and left subclavian artery orifices as they originate from the distal aortic arch. Similarly, in paravisceral and pararenal aortic dissections, it may be necessary to accurately visualize the origin of major aortic side branches, such as the celiac trunk, superior mesenteric artery, renal arteries, and important accessory renal arteries. For procedural planning it is also necessary to determine from which lumen (true or false) the relevant side branches take origin. The use of IVUS is particularly useful to help determine this since it will remain constrained to the lumen that it was advanced into from its initial access site. Moreover, the use of IVUS in patients with aortic dissections has the added advantage of limiting contrast boluses that can further impair renal function that may already be affected in the setting of an aortic dissection.

VENOUS INTERVENTIONS

Endovascular venous interventions may also be performed with the help of IVUS. Standard transfemoral venography for evaluation of iliac vein stenosis or obstruction has various limitations. It is reported that standard venography can underestimate iliac stenosis by up to 30%.[33] On the other hand, IVUS can provide detailed assessments of iliac vein diameter, thrombus burden, nature and chronicity of thrombus, and visualize intraluminal defects

JAYPEE BROTHERS

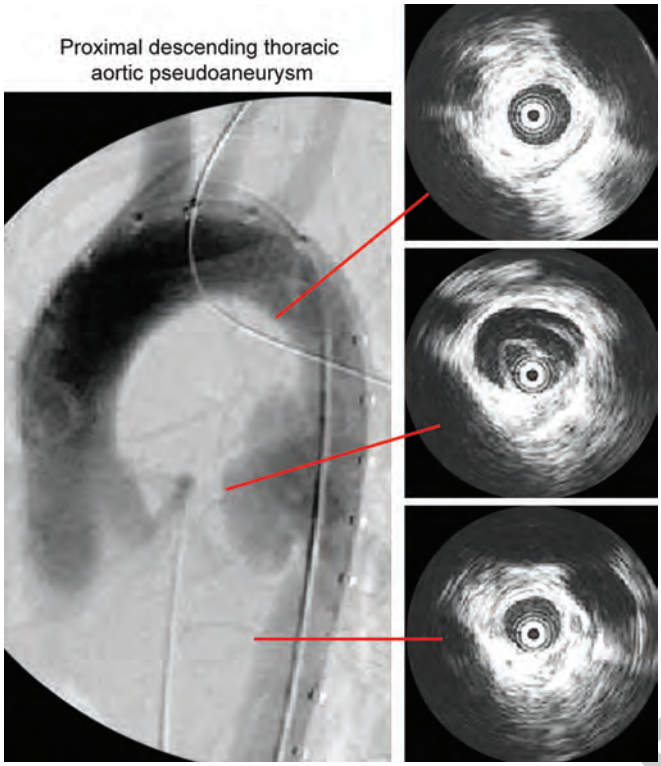

Fig. 4.10: Characterization of a proximal descending thoracic aortic pseudoaneurysm using intravascular ultrasound (IVUS). Intravascular ultrasound images demonstrate a clear disruption and expansion of the aortic lumen at level of a pseudoaneurysm detected on fluoroscopy. Cross-sectional IVUS images provide essential luminal diameter measurements proximal and distal to the pseudoaneurysm segment to allow for appropriate endovascular device selection and optimal fixation of the device.
Courtesy: Volcano Corporation, Atlas of Peripheral Vascular Disease, Rancho Cordova, CA, USA.

and webs. Following treatment of iliac vein stenosis or thrombosis, IVUS may also be useful for follow-up evaluation and help assess efficacy of treatment modality either with thrombolysis, angioplasty, or stenting.

Several reports have also detailed the use of IVUS in facilitating the deployment of permanent as well as retrievable inferior vena cava filters as prophylaxis against venous thromboembolisms.[34,35] This has been demonstrated to be particularly useful in critically ill patients, usually in an intensive care setting, who are unfit to travel to the fluoroscopy suite for a standard fluoroscopy-guided inferior vena cava filter placement. In these patients, standard ultrasound-guided access of the common femoral vein or internal jugular vein is obtained, and an IVUS catheter is advanced into the inferior vena cava. Particular attention is paid to the diameter of the abdominal inferior vena cava, the origin of the renal veins, and other important anatomical landmarks such as visualization of the adjacent aortic lumen and the posterior crossing right renal artery.[35] Once the inferior vena cava area of deployment is identified, the filter deployment catheter is advanced to position, and the filter is deployed. Following filter deployment, IVUS can be repeated to confirm appropriate deployment and alignment of the filter.

FUTURE DEVELOPMENTS

Continued miniaturization and cost-effective manufacturing of IVUS devices will continue to popularize their use for both diagnostic and therapeutic procedures. Recent development of endovascular devices with combined IVUS transducer and receiver elements will continue to expand the utility of IVUS in the treatment of complex arterial and venous pathologies. Such devices are currently in use in European countries and are pending Food and Drug Administration (FDA) approval in the United States. In the meantime, imaging software and postimage acquisition processing will continue to help broaden the utility and benefit of IVUS in the treatment of patients with vascular disease.

REFERENCES

1. Diethrich EB. Future potential of endovascular techniques for vascular surgeons. Semin Vasc Surg. 2003;16:255-61.
2. Cavaye DM, White RA. Intravascular ultrasound imaging: development and clinical applications. Int Angiol. 1993;12:245-55.
3. Lee JT, White RA. Basics of intravascular ultrasound: an essential tool for the endovascular surgeon. Semin Vasc Surg. 2004;17:110-8.
4. Yock PG, Linker DT, Angelsen BA. Two-dimensional intravascular ultrasound: technical development and initial clinical experience. J Am Soc Echocardiogr. 1989;2:296-304.
5. Mallery JA, Tobis JM, Griffith J, et al. Assessment of normal and atherosclerotic arterial wall thickness with an intravascular ultrasound imaging catheter. Am Heart J. 1990;119:1392-400.
6. Lee JT, Fang TD, White RA. Applications of intravascular ultrasound in the treatment of peripheral occlusive disease. Semin Vasc Surg. 2006;19:139-44.
7. Nissen SE, Grines CL, Gurley JC, et al. Application of a new phased-array ultrasound imaging catheter in the assessment of vascular dimensions. In vivo comparison to cineangiography. Circulation. 1990;81:660-6.
8. Garcia-Garcia HM, Gogas BD, Serruys PW, et al. IVUS-based imaging modalities for tissue characterization: similarities and differences. Int J Cardiovasc Imaging. 2011;27:215-24.
9. Geselschap JH, Heilbron MJ, Hussain FM, et al. The effect of angulation on intravascular ultrasound imaging observed in vascular phantoms. J Endovasc Surg. 1998;5:126-33.

JAYPEE BROTHERS

10. Gussenhoven EJ, Essed CE, Lancee CT, et al. Arterial wall characteristics determined by intravascular ultrasound imaging: an in vitro study. J Am Coll Cardiol. 1989;14: 947-52.
11. Kopchok GE, White RA, Guthrie C, et al. Intraluminal vascular ultrasound: preliminary report of dimensional and morphologic accuracy. Ann Vasc Surg. 1990;4:291-6.
12. Gussenhoven EJ, Essed CE, Frietman P, et al. Intravascular ultrasonic imaging: histologic and echographic correlation. Eur J Vasc Surg. 1989;3:571-6.
13. Mintz GS, Nissen SE, Anderson WD, et al. American College of Cardiology Clinical Expert Consensus Document on Standards for Acquisition, Measurement and Reporting of Intravascular Ultrasound Studies (IVUS). A report of the American College of Cardiology Task Force on Clinical Expert Consensus Documents. J Am Coll Cardiol. 2001;37: 1478-92.
14. Diethrich EB, Irshad K, Reid DB. Virtual histology and color flow intravascular ultrasound in peripheral interventions. Semin Vasc Surg. 2006;19:155-62.
15. Diethrich EB, Pauliina MM, Reid DB, et al. Virtual histology intravascular ultrasound assessment of carotid artery disease: the Carotid Artery Plaque Virtual Histology Evaluation (CAPITAL) study. J Endovasc Ther. 2007;14:676-86.
16. Pinto FJ, Chenzbraun A, Botas J, et al. Feasibility of serial intracoronary ultrasound imaging for assessment of progression of intimal proliferation in cardiac transplant recipients. Circulation. 1994;90:2348-55.
17. Ricou F, Nicod PH, Moser KM, et al. Catheter-based intravascular ultrasound imaging of chronic thromboembolic pulmonary disease. Am J Cardiol. 1991;67:749-52.
18. Barone GW, Kahn MB, Cook JM, et al. Recurrent intracaval renal cell carcinoma: the role of intravascular ultrasonography. J Vasc Surg. 1991;13:506-9.
19. Kopchok GE, White RA, Guthrie C, et al. Intravascular ultrasound: a new potential modality for angioplasty guidance. Angiology. 1990;41:785-92.
20. Cavaye DM, Diethrich EB, Santiago OJ, et al. Intravascular ultrasound imaging: an essential component of angioplasty assessment and vascular stent deployment. Int Angiol. 1993;12:214-20.
21. Gaster AL, Slothuus SU, Larsen J, et al. Continued improvement of clinical outcome and cost effectiveness following intravascular ultrasound guided PCI: insights from a prospective, randomised study. Heart. 2003;89:1043-9.
22. The SH, Gussenhoven EJ, Zhong Y, et al. Effect of balloon angioplasty on femoral artery evaluated with intravascular ultrasound imaging. Circulation. 1992;86(2):483-93.
23. Tobis JM, Mahon DJ, Goldberg SL, et al. Lessons from intravascular ultrasonography: observations during interventional angioplasty procedures. J Clin Ultrasound. 1993; 21:589-607.
24. White RA, Donayre CE, Kopchok GE, et al. Utility of intravascular ultrasound in peripheral interventions. Tex Heart Inst J. 1997;24:28-34.
25. Fuessl RT, Hoepp HW, Sechtem U. Intravascular ultrasonography in the evaluation of results of coronary angioplasty and stenting. Curr Opin Cardiol. 1999;14:471-9.
26. Diethrich EB. Endovascular treatment of abdominal aortic occlusive disease: the impact of stents and intravascular ultrasound imaging. Eur J Vasc Surg. 1993;7:228-36.
27. Arko F, Mettauer M, McCollough R, et al. Use of intravascular ultrasound improves long-term clinical outcome in the endovascular management of atherosclerotic aortoiliac occlusive disease. J Vasc Surg. 1998;27:614-23.
28. Schiro BJ, Wholey MH. The expanding indications for virtual histology intravascular ultrasound for plaque analysis prior to carotid stenting. J Cardiovasc Surg (Torino). 2008;49: 729-36.
29. White RA, Donayre C, Kopchok G, et al. Intravascular ultrasound: the ultimate tool for abdominal aortic aneurysm assessment and endovascular graft delivery. J Endovasc Surg. 1997;4:45-55.
30. Tutein Nolthenius RP, van den Berg JC, Moll FL. The value of intraoperative intravascular ultrasound for determining stent-graft size (excluding abdominal aortic aneurysm) with a modular system. Ann Vasc Surg. 2000;14:311-7.
31. von Segesser LK, Marty B, Ruchat P, et al. Routine use of intravascular ultrasound for endovascular aneurysm repair: angiography is not necessary. Eur J Vasc Endovasc Surg. 2002;23:537-42.
32. Dake MD, Kato N, Mitchell RS, et al. Endovascular stent-graft placement for the treatment of acute aortic dissection. N Engl J Med. 1999;340:1546-52.
33. Neglen P, Raju S. Intravascular ultrasound scan evaluation of the obstructed vein. J Vasc Surg. 2002;35:694-700.
34. Oppat WF, Chiou AC, Matsumura JS. Intravascular ultrasound-guided vena cava filter placement. J Endovasc Surg. 1999;6:285-7.
35. Wellons ED, Rosenthal D, Shuler FW, et al. Real-time intravascular ultrasound-guided placement of a removable inferior vena cava filter. J Trauma. 2004;57:20-3.

JAYPEE BROTHERS

for detailed information on radiology books, visit our website **www.jaypeebrothers.com,** for detailed information on radiology books, visit our website **ww**

Vascular Imaging and Intervention

The book in its expanded edition covers vascular anatomy and imaging as well as endovascular management of vascular diseases. It is intended primarily for practitioners who evaluate and treat patients with arterial, venous and lymphatic diseases. Those include specialists in the field of interventional radiology, vascular surgery, vascular medicine, cardiology, nephrology and angiology. Some chapters will be of specific interest to practitioners of gynecology, urology and oncology. This book will be a benefit to both established practitioners and those in training including medical students, residents, and those studying to be nurses and physician assistants. Finally this book will be of great utility for those in device and pharmaceutical industry.



Ducksoo Kim MD FSIR After graduation from the Catholic University of Korea, College of Medicine and subsequent completion of a Radiology Residency, Beth Israel Deaconess Medical Center and Cardiovascular and Interventional Radiology Fellowship (NIH Postdoctoral Scholar), Stanford University Medical Center, he has been working for over 35 years as a Cardiovascular and Interventional Radiologist. He has devoted himself to teaching and medical research for over 33 years at Harvard Medical School (1983–1998) as an Associate Professor/Chief of Cardiovascular and Interventional Radiology, the Beth Israel Deaconess Medical Center, Boston, MA, the University of Massachusetts Medical School (1999–2006) as a Professor of Radiology and Surgery/Chief of Cardiovascular and Interventional Radiology at the University of Massachusetts Medical Center, Boston University School of Medicine (2006–Present) as a Professor of Radiology/Chief of Cardiovascular and Interventional Radiology at Boston University Medical Center (2006–2011) and Chief of Vascular and Interventional Radiology at Boston VA Health Care (2011–Present). He has written over 100 scientific papers, co-edited two textbooks and authored/co-authored 36 book chapters. He also invented/co-invented more than 15 medical devices.



Dan E Orron MD received his medical degree from the Tel Aviv University Sackler School of Medicine (1981), completed Residency in Diagnostic Radiology, Beth Israel Deaconess Medical Center/Mt Sinai School of Medicine (1986), and a Fellowship in Angiography/Interventional Radiology under Dr Ducksoo Kim, at the Beth Israel Deaconess Hospital/Harvard Medical School (1987). Drs Dan E Orron and Ducksoo Kim published the original text, Peripheral Vascular Imaging and Intervention (1992). He has spent most of his subsequent career in Israel. Between 1993 and 2003, he was the Director of Angiography/Interventional Radiology, Tel Aviv Sourasky Medical Center. He is currently the Director of Angiography/Interventional Radiology, Carmel Medical Center, Haifa Israel, affiliated to the Technion University School of Medicine.



Nilesh H Patel MD FSIR is a Fellow of the Society of Interventional Radiology, past Editor-in-Chief of Society of Interventional Radiology Syllabus Series and currently President of Darshan, Inc., Reno, Nevada, USA. He spent 14 years of his career in academics training radiology residents and interventional radiology fellows at University of Washington, Indiana University and Rush University prior to private practice and consulting. He has published extensively and holds numerous patents on medical devices. He is a graduate of Harpur College of Arts and Sciences, Binghamton University (State University of New York) and obtained his medical degree from Upstate Medical University College of Medicine. He completed a Residency in Diagnostic Radiology and Nuclear Medicine at Michigan State University, and Vascular and Interventional Radiology Fellowship at Henry Ford Hospital.



Alik Farber MD is the Chief, Division of Vascular Surgery, Boston Medical Center (BMC) and Professor of Surgery and Radiology, Boston University School of Medicine, Boston, Massachusetts, USA. He is a graduate of Brown University and obtained his medical degree from Harvard Medical School. He completed a Residency in General Surgery, Massachusetts General Hospital; a Vascular Surgery Fellowship, Dartmouth-Hitchcock Medical Center and an Endovascular Surgery Fellowship, Southern Illinois School of Medicine. His administrative responsibilities include being an Associate Chair for Clinical Operations in the Department of Surgery and Medical Director of BMC's Catheterization and Angiography Laboratories. He is currently a National Co-Chair of the Best Endovascular versus Best Surgical Therapy in Patients with Critical Limb Ischemia (BEST-CLI) trial, a $25 million grant awarded by the National Institutes of Health.

Available at all medical bookstores
or buy online at www.jaypeebrothers.com

JAYPEE BROTHERS
Medical Publishers (P) Ltd.
www.jaypeebrothers.com

Join us on facebook.com/JaypeeMedicalPublishers

Shelving Recommendation
RADIOLOGY

ISBN 978-93-85999-02-4