ebsite **www.jaypeebrothers.com,** for detailed information on neurology books, visit our website **www.jaypeebrothers.com**

# BRAIN & NEUROLOGICAL DISORDERS

## A Simplified Health Education Guide

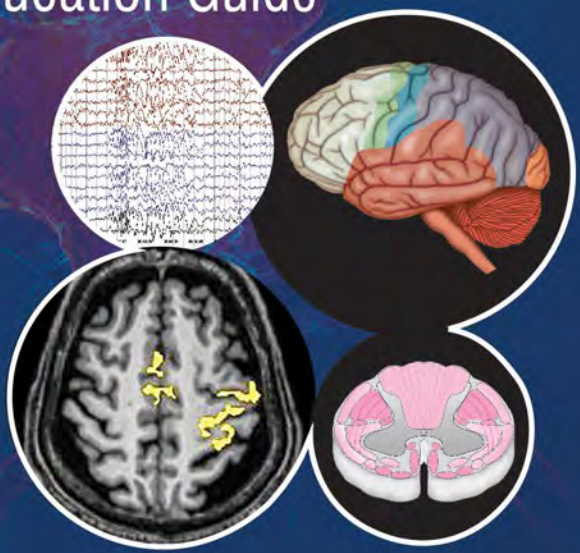

*Authors*
**Dr. Sudhir V Shah**
**Dr. Heli S Shah**

*Foreword*
**Dr. BS Singhal**

JAYPEE

# Contents


| | | |
|---|---|---|
| CHAPTER 1 | An Overview of the Nervous System | 1 |
| CHAPTER 2 | Neuroradiology: Imaging of the Brain | 23 |
| CHAPTER 3 | Coma | 35 |
| CHAPTER 4 | Epilepsy | 44 |
| CHAPTER 5 | Ischemic Stroke | 63 |
| CHAPTER 6 | Intracranial Hemorrhage | 86 |
| CHAPTER 7 | Headache, Migraine, and Vertigo | 104 |
| CHAPTER 8 | Movement Disorders and Dystonia | 116 |
| CHAPTER 9 | Parkinsonism | 133 |
| CHAPTER 10 | Cerebellar Disorders and Ataxias | 148 |
| CHAPTER 11 | Dementia and Tips to Improve Memory | 157 |
| CHAPTER 12 | Sleep Disorders | 180 |
| CHAPTER 13 | Infections of the Central Nervous System | 196 |
| CHAPTER 14 | HIV and AIDS: Effects on the Nervous System | 219 |
| CHAPTER 15 | Brain Tumors | 228 |

**CHAPTER 16** Cerebral Palsy, Autism, and Attention Deficit Hyperactivity Disorder 240

**CHAPTER 17** Diseases of the Spinal Cord: Myelopathies 250

**CHAPTER 18** Multiple Sclerosis 264

**CHAPTER 19** Motor Neuron Disease 278

**CHAPTER 20** Diseases of the Peripheral Nerves: Neuropathies 285

**CHAPTER 21** Myasthenia Gravis 303

**CHAPTER 22** Diseases of the Muscles: Myopathies 311

**CHAPTER 23** Stress 321

**CHAPTER 24** Common Psychiatric Disorders 333

**CHAPTER 25** Neurosurgery: An Overview 345

**CHAPTER 26** Side Effects of Some Commonly Used Neurological Medicines 364

**CHAPTER 27** Tips for Hospitalized Patients 375

***APPENDIX: Patient Information Guide*** ***385***

***Glossary*** ***387***

***Index*** ***399***

CHAPTER
2

# Neuroradiology: Imaging of the Brain

*No matter how closely you examine the water, glucose and electrolyte salts in the human brain, you can't find the point where these molecules became conscious.*

**Deepak Chopra**



## Points to Ponder

- Neuroradiology is a subspecialty of radiology, focusing on the diagnosis and characterization of abnormalities of the central nervous system (CNS), peripheral nervous system, spine, head, and neck
- Neuroradiology covers imaging and interventional therapy of diseases of the CNS, i.e., brain and spinal cord, and the surrounding structures, skull and spine
- Neuroradiology also covers angiographic studies of the brain and spine and interpretation of the findings
- The examinations allow neurologists to diagnose strokes, tumors, genetic conditions, aneurysms, Alzheimer's disease, and many other causes of neurological dysfunction at an early stage and start the best therapy at the earliest possible time.

## INTRODUCTION

A clinician's diagnosis and treatment of a patient is based on history taking, observation of symptoms, and clinical examination, but sometimes this may prove insufficient in terms of exact location, extent, and damage caused by the disease. This can be overcome by radiology of various parts of the body. Neuroradiology consists of X-rays, ultrasound, computed tomography (CT or CAT) scan, magnetic resonance imaging (MRI), angiography, single photon emission computed tomography (SPECT) scan, positron emission tomography (PET)-MRI, etc.

The earliest history of neuroradiology dates back as early as first half of 20$^{th}$ century and is based on the work of pioneers like:

JAYPEE BROTHERS

- Arthur Schuller, a neuropsychiatrist who first systematically studied the X-ray of the skull and changes induced by intracranial disease, and is also regarded as "Father of Neuroradiology"
- Egas Moniz, a Portuguese neuropsychiatrist, developed cerebral angiography, and was awarded the Nobel Prize in medicine for initiating prefrontal lobotomy
- Walter Dandy, a great neurosurgeon of John Hopkins institute, introduced the procedure of ventriculography and pneumoencephalography.

## X-RAY

X-rays, microwaves, and radio waves are all electromagnetic rays and each differ only in form of energy content.

An amazing feature of human eye is that it can perceive only sun rays and is unable to see the other types of rays. The X-rays, which were discovered by the German scientist, Roentgen in 1895, have been used in all possible innovative ways and miraculously makes the structures inside the body visible to human eye.

The energy from the X-rays is 10,000–15,000 times greater than light and can penetrate through objects, but the common X-rays only give rough picture of the bones, like a skull with only a one-dimensional picture without estimating the depth of the lesion like a tumor inside the brain. However, a rough picture of a space occupying lesion can be indirectly indicated on an X-ray. For example, a calcification of tumor or signs of raised intracranial pressure can be detected.

## COMPUTED TOMOGRAPHY (COMPUTED AXIAL TOMOGRAPHY) SCAN (CT SCAN )

The in-depth information and inner structure of lesions could not be obtained or visualized on X-rays. The introduction of the CT or computed axial tomography scan, invented by a British Scientist, Sir Godfrey Hounsfield, overcame this problem by creating a three-dimensional view of the body. The depth and position of the lesion can be determined by dividing the brain into imaginary parts, like slices of bread, and X-rays of each part is obtained from different angles. Many describe this creation as exerting a great impact on clinical medicine and surgery as Roentgen's discovery of X-rays; any minutest change inside the brain can be determined with the help of this machine.

The CT scan machine resembles a cubicle box with a two feet long circular tunnel and is called gantry (Fig. 1).

- The patient lies in a recumbent position on stretcher like table and can be moved in all directions, like sideways, upwards, and downwards
- The part of the body that is to be examined is kept at the center of tunnel that rotates in a circular motion, taking photographs of the body part from each angle
- A CT scan image is display of anatomy of thin slices of body developed from multiple X-ray absorption measurements made around the body's circumference
- An image layer of the body is produced, while the images of the structures above and below that layer are made invisible by blurring.

JAYPEE BROTHERS



**FIG. 1:** Computed tomography scanner

These photographs are digital data that are reflected on the detector with the computer carrying out accurate calculations on thin cross-sectional divisions resembling bread slices which are then photographed with the help of laser camera. The entire procedure takes around 3–5 minutes and the patient has to lie still throughout the entire procedure. On an average, twenty photographs are taken on a 14 × 17 inches X-ray film, which are interpreted by the radiologist for a report.

A CT scan procedure is painless and gives detailed information of organs and therefore, specification of part to be scanned becomes necessary. In cases of brain tumor or infection, a contrast agent is injected intravenously to figure out the blood circulation inside the diseased part. This iodine-based drug (iodinated contrast) sometimes can cause nausea in patient or may temporarily increase the body temperature (which subsequently becomes normal in few minutes), and hence, the patients are advised to fast for 3 hours prior to contrast CT scan. Patients who have history of allergy, asthma, kidney or thyroid disease can show a reaction to contrast CT scan and have to be advised nonionic dye to prevent a reaction.

Pregnancy is not an absolute contraindication to CT scan, but prior information of pregnancy status has to be obtained. Though it has no side effects except that of radiation, the relatives and friends of the patient are not allowed inside the CT scan room and rest of the body of the patient is kept covered.

Computed tomography scan is now a preliminary diagnostic procedure easily available at almost all established healthcare centers.

## MAGNETIC RESONANCE IMAGING (MRI )

The CT scan can reveal limited information about the structures, like the white matter of the brain, the spinal cord, etc. In 1972, Damadian discovered the use of magnetic field in the examination of the human body. Advanced computers are used to photograph the brain by using powerful magnetic fields in the examination of the human body known as MRI. Magnetic resonance imaging has advantage of diagnosing certain cases of brain tumor, stroke, white matter disease like multiple

JAYPEE BROTHERS

sclerosis, congenital disorders, and other diseases of the nervous system, innermost parts of eyes and ears—all without risks of exploratory surgery or the radiation associated with traditional scanning methods.

## Magnetic Resonance Imaging Machine

- Magnetic resonance imaging machine is cylindrical in shape and made up of powerful magnet which is 1,000 times more powerful than magnetic field of the earth and the patient has to lie in the tunnel formed in this cylinder (Fig. 2)
- The power of machine is defined in terms of unit called tesla and is configured as 0.2, 0.3, 0.5, 1.0, 1.5 T, and 3.0 T and as the tesla power increases, the accuracy, speed, and minuteness of the machine also increases
- Like CT scan, MRI can be utilized for obtaining detailed information of organs ranging from the brain to the spinal cord, bones, muscles, lungs, stomach, kidney, etc., without using the X-ray. Instead of this, radiofrequency waves and strong magnetic fields are used without the danger of harmful radiation.



**FIG. 2:** Magnetic resonance imaging machine

Hydrogen protons (in water) are present in large quantities in the body. Nuclear magnetic resonance detects these protons by subjecting them to a large magnetic field and influences them to enter in excited state after which they are brought back to normal state with help of gradients. A cross-section of tissue can be produced by a well-calibrated magnetic field gradient across the tissue. The proton signal frequency is proportional to that magnetic field and a given proton signal frequency can be assigned to a location in the tissue which is imaged by MRI. Since the proton density varies with the type of tissue, a certain amount of contrast is achieved to image the organs and other tissue variations in the subject tissue. Differentiation occurs with the help of advanced computer calculations with images taken by laser camera from every angle on a 14 × 17 inches photofilm. This differentiates areas like white matter from gray matter easily.

Each photoplate accommodates around 16–20 images and during the entire MRI procedure, 4–5 such sequences are prepared. Each sequence lasts around

JAYPEE BROTHERS

5–8 minutes and in 30–40 minutes, 80–100 images of the brain can be taken from different axes based on which the radiologist opines. With newer machines total procedure time is reduced to half. During the procedure of MRI, the gradients of the machine make lot of sound that can be muffled by use of earplugs, earphones, etc. Since the patient lies in the cylinder, many of them feel claustrophobic, in which case, mild sedatives have to be administered.

In newer types of MRI machines, the design of the magnet is open type, making patient more comfortable Also, with newer machines, the scanning time is reduced pretty much. Special contrast is administered for characteristic findings and with negligible side effects.

Magnetic resonance imaging scan is much more advanced in comparison to a CT scan. It is less risky as it does not carry any risks of radiation. Computed tomography scan reveals axial slice cuts only, whereas in MRI, a three-dimensional (X, Y, and Z axes) view can be obtained giving a complete picture. The complicated parts, like spinal cord, can be visualized minutely only by an MRI (Fig. 3). Because of presence of strong magnetic field, things like watch, credit card, pen, rings, bangles, etc., are not permitted in the MRI room. Also, patients with pacemaker in the heart or any other metallic device placed in their body may have to be excluded from MRI scan due to the fear of dislodging the device. Substitution with MRI friendly metal, like titanium, has made the procedure possible even in these patients. Also newer researches, like diffusion and perfusion MRI, have made diagnosis of impaired blood circulation in brain easy, due to which immediate treatment can be instituted.




**FIG. 3:** Magnetic resonance imaging of the spine showing lumbosacral region

## MAGNETIC RESONANCE SPECTROSCOPY (MRS)

Proton magnetic resonance spectroscopy of the brain is a noninvasive *in vivo* technique that allows the detection of regional chemical environment and is frequently used nowadays.

JAYPEE BROTHERS

It is valuable along with MRI imaging sequence, providing for detection of infection of the brain, brain tumor characteristics, progression and response to treatment, and other diseases.

In this innovative technique, voxel proton spectroscopic data is obtained from the lesion detected on MRI, mathematical graphical values of choline, creatinine, and N-acetylaspartate is plotted. This helps to differentiate various pathologies in a noninvasive way. The presence of biomarker in certain brain disorders, such as Alzheimer's disease, can be detected even in presence of apparently normal structural imaging. However, drawbacks associated with this technique are the issues of reproducibility and the accuracy of biochemistry of measured neurometabolites, sufficient enough to draw a conclusion (Fig. 4) .

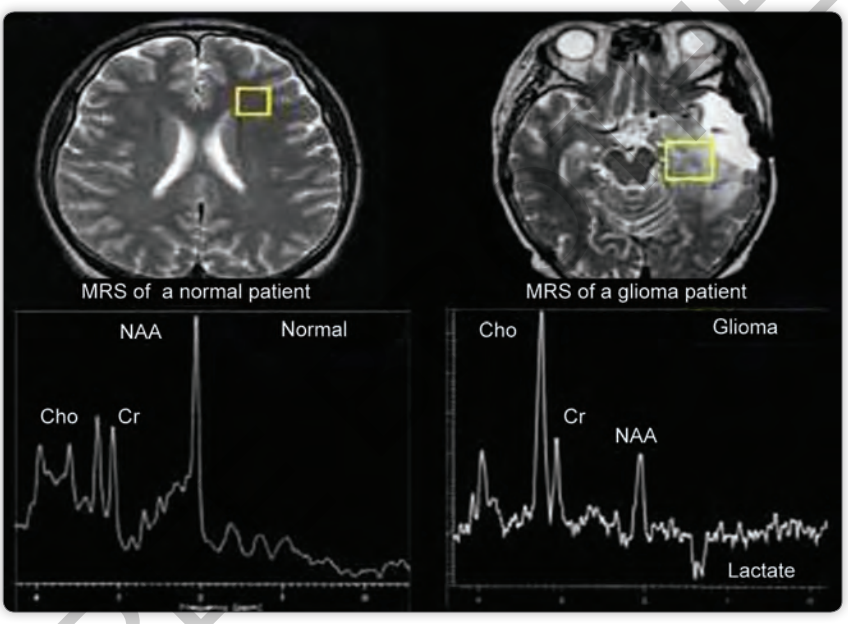


Cho, choline; Cr, creatinine; NAA, N-acetylaspartate.

**FIG. 4:** Magnetic resonance spectroscopy showing peak variation of neurometabolites

## FUNCTIONAL MAGNETIC RESONANCE IMAGING (fMRI)

- Functional magnetic resonance imaging (fMRI) is a technique for measuring brain activity and detects any changes in the flow and oxygenation of blood that appear in response to neural activity (Fig. 5)
- The brain area is more active and thus consumes high oxygen to meet the demand of blood flow of the active area, which is depicted on activation maps of the portions of brain that are involved in mental processes
- Functional MRI differentiates various areas of brain associated with movement, memory, speech, or articulation, based on which surgery and radiotherapy can be planned

JAYPEE BROTHERS

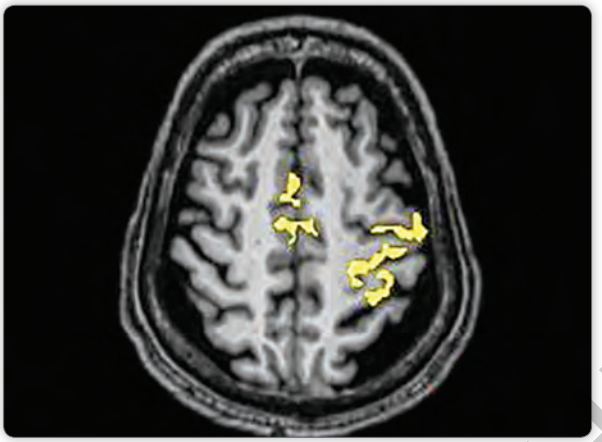

**FIG. 5:** In functional magnetic resonance imaging, brain areas "light-up" when performing certain tasks

- The important centers in the brain can be avoided from being harmed and the patient can be saved from permanent disability or defects with the help of fMRI before any surgery or intervention.

## Diffusion Tensor Imaging (DTI)

Diffusion tensor magnetic resonance imaging and fiber tractography are the new methods that are able to demonstrate the orientation of white matter fibers by evaluation of white matter anatomy and structural integrity. It is based on anisotropy of Brownian motion of water molecules in biological tissues (Fig. 6).

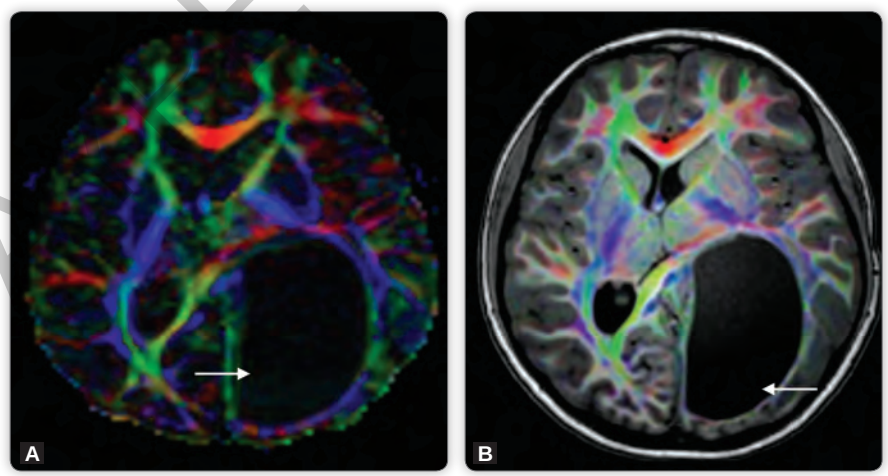


**FIG. 6:** Diffusion tensor imaging (white arrows representing tumors)

JAYPEE BROTHERS

## ANGIOGRAPHY

Angiography defines the blood flow through arteries and veins of various parts of body and amongst them is the angiography of heart which is familiar to a common man. Digital subtraction angiography (DSA) procedure, which is angiography of brain, helps to determine blood flow through brain and detects certain diseases of brain like constriction of blood vessels, plaque formation in vessels, arteriovenous malformations, aneurysms, etc.

In cerebral angiography, a scanner is used to take the images which are then assembled into a three-dimensional view of blood vessels using the computer softwares, based on which the radiologist can accurately view the structure of blood vessels in diseases such as aneurysms, intracranial or extracranial vessel stenosis, and stroke. This procedure involves:

- Introduction of a catheter from femoral artery in the thigh along the blood flow
- It is then allowed to enter into the arteries of brain under the guidance and monitoring of X-ray and computer
- A contrast medium is injected through the catheter and its flow is seen live on a monitor and visualized from various angles as the drug progresses into the blood vessel.

In DSA, an X-ray of brain is done prior to starting the procedure after completion of which another X-ray is taken to compare the differences seen on both X-rays that leads to a diagnosis.

If the carotid artery that supplies blood to the brain shows constriction or narrowing, usually due to presence of plaques, then a simultaneous procedure known as carotid angioplasty can be performed. During this procedure, a carotid stent (a small, metal mesh tube) is inserted inside the carotid artery at the spot of the blockage and provides support keeping the artery open. Angiography procedures on both heart and brain carry the same minimal risk that can be managed.

There are some total nonrisky methods too, like color Doppler, CT angiography, MRI angiography, etc., that investigates the flow of blood through brain vessels. However, the accuracy of DSA is very high and next best is CT angiography.

## COMPUTED TOMOGRAPHY ANGIOGRAPHY (CTA)

Computed tomography angiography is a minimal invasive procedure that uses a CT scanner to produce images of both blood vessels and tissues, and involves the use of an iodine contrast medium (dye) that is usually injected through a small catheter in the arm vein (Fig. 7)

- A CT scan is performed while the contrast flows through blood vessels
- Computed tomography angiography is important in cases of hemorrhagic episodes of brain and is preferred in emergency cases over MRI angiography, as it is less time consuming, fairly simple intravenous technique, and can be of immediate help for diagnosing an acute stroke patient
- Its use for routine screening purpose in high risk patients or in asymptomatic individuals with a cerebral disease can help proactively diagnose and treat aneurysms that are likely to rupture later.

JAYPEE BROTHERS

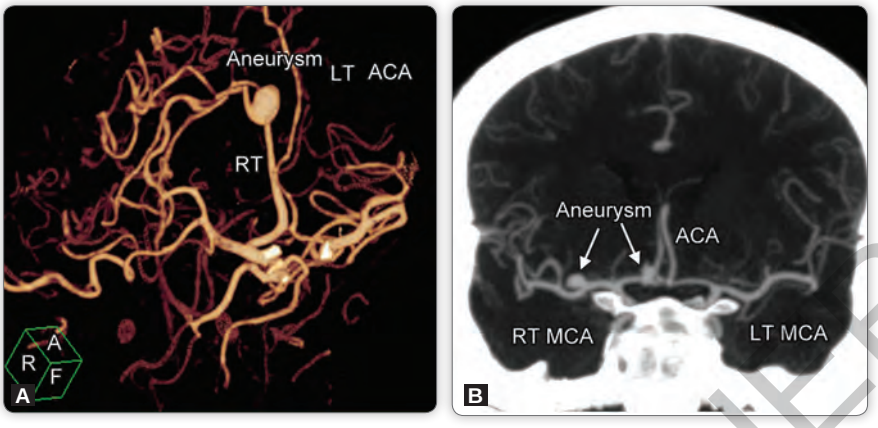


ACA, anterior cerebral artery; MCA, middle cerebral artery; RT, right; LT, left.

**FIG. 7:** **A,** Computed tomography angiography (three-dimensional) showing right anterior cerebral artery aneurysm; **B,** Computed tomography angiography brain showing aneurysm

## MAGNETIC RESONANCE ANGIOGRAPHY (MRA)

Magnetic resonance angiography is a procedure that can reveal minute details of arteries and veins (Fig. 8), however, CT angiography is a better option. It uses

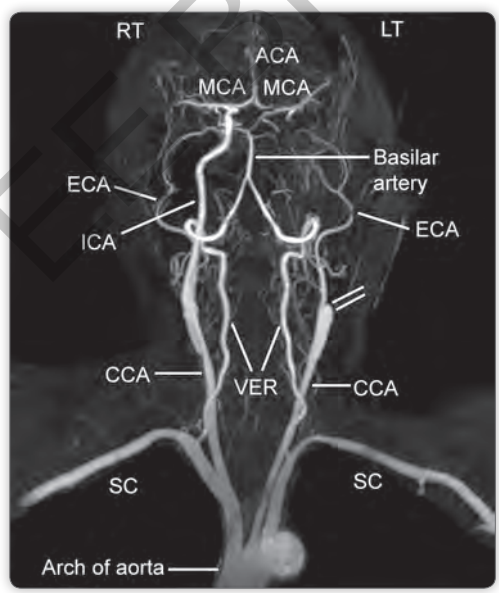


ACA, anterior cerebral artery; MCA, middle cerebral artery; ICA, internal carotid artery; ECA, external carotid artery; CCA, common carotid artery; RT, right; LT, left; SC, subclavian artery; VER, vertebral artery.

**FIG. 8:** Head and neck magnetic resonance angiography showing extra- and intracranial vessels

JAYPEE BROTHERS

magnetic fields and radiowaves to produce three-dimensional images of internal structures. Certain conditions, like aneurysms, dissection of aorta, stenosis, and hardening or blockages of an artery can be diagnosed easily along with a treatment planned out. Magnetic resonance angiography may be performed with or without contrast material. It may be done with an MRI.

## COLOR DOPPLER

Color Doppler is a noninvasive method and gives fairly complete information about the carotid and vertebral arteries, like their diameter, pressure, and any deposits in walls of artery and helps to locate a hematoma. It can also check the state of carotid and vertebral artery after surgery regarding restoration of the blood flow and the position of a stent, etc. It helps the physician to diagnose the blockage of an artery, its blood flow, etc., including presence of clots, narrowing of blood vessels, tumors, and any congenital malformations.

## POSITRON EMISSION TOMOGRAPHY SCAN (PET SCAN)

Positron emission tomography scan gives better information about the organ, but is not easily available. It is a type of nuclear medicine imaging that helps to diagnose and treat a variety of diseases like cancers, heart disease, endocrine, neurological, and gastrointestinal disorders and other abnormalities.

A PET scanner is a large machine with a circular, doughnut shaped hole in the center, similar to a CT or MRI unit, consisting of multiple rings of detectors that record the emission from radiotracer (Fig. 9).

They offer the potential to identify disease in its earliest stage as well as a patient's immediate response to therapeutic interventions. A PET scan measures blood flow, oxygen use, and sugar (glucose) metabolism. This information helps in evaluation of functions of organs and tissues. A whole body PET/CT scan is

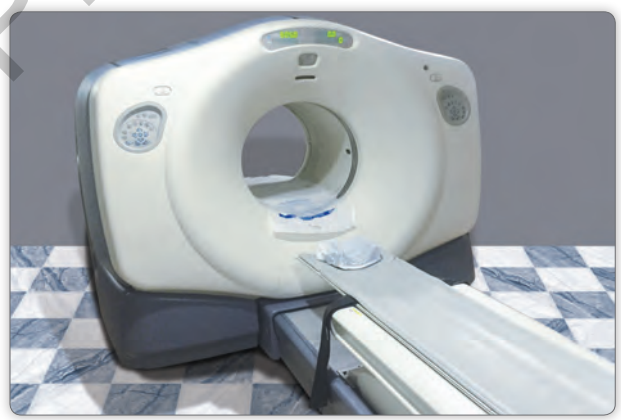

**FIG. 9:** Positron emission tomography equipment

JAYPEE BROTHERS

especially useful in detecting the primary malignancy and also the location and extent of metastasis.

## Single Photon Emission Computed Tomography Scan (SPECT)

The single photon emission computed tomography scan is a type of a nuclear imaging test, using a radioactive substance to create three-dimensional pictures that determines the blood flow to organs like brain (Fig. 10) or heart. It integrates technologies of CT and a radioactive material to view the organs. Before the procedure of SPECT scan, a radiocontrast medium is injected which can be detected by a scanner and the information is collected by computer and translated into two-dimensional cross-sections which are added back together to form three-dimensional image of the brain. A SPECT scan views blood flow through arteries and veins in the brain and is believed to be more sensitive to brain injury than either MRI or CT scan, since it detects reduced blood flow to damaged sites. A SPECT scan determines the parts of brain affected or damaged by blocked blood vessels, dementia, epilepsy, head injuries, and seizures.

Single photon emission computed tomography scanning is used for presurgical evaluation of uncontrolled seizures and this test can be performed in between seizures or during the course of a seizure episode to define blood flow to areas where the seizures originate.

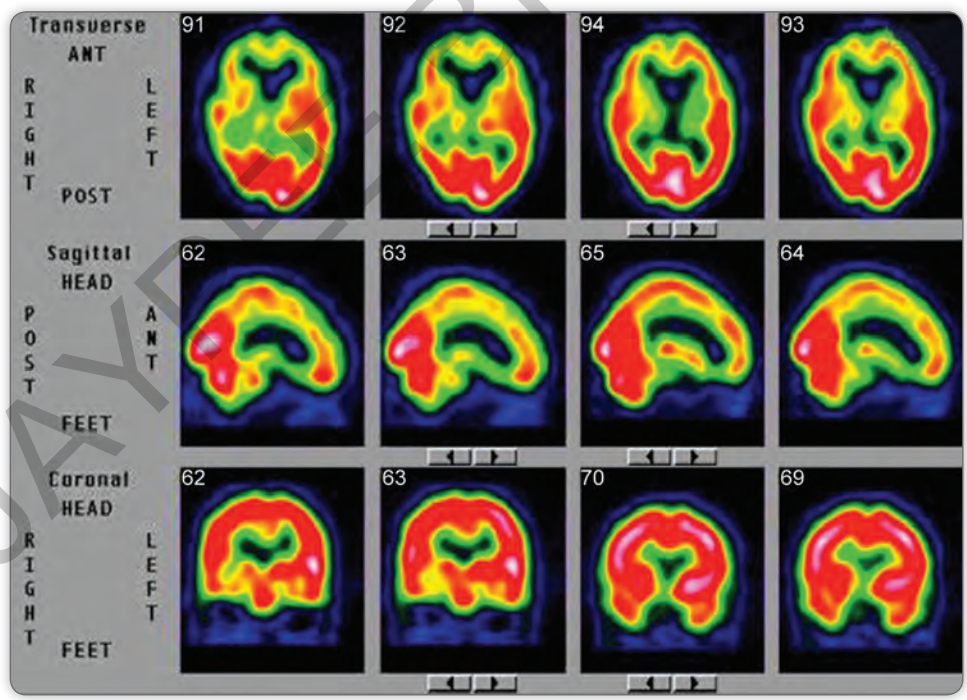


**FIG. 10:** Single photon emission computed tomography scan of a brain

JAYPEE BROTHERS



## Pearls of Wisdom

- Computed tomography (CT) scan has now become a primary investigation for diagnosis of the brain and magnetic resonance imaging (MRI) scan is for detailed and in-depth information
- Magnetic resonance imaging investigation has more advantages as compared to a CT scan for diagnosing diseases of the deeper and posterior portions of brain as well as of spinal cord and it does not involve the risk of radiation
- The investigation and diagnosis of disorders of blood vessels supplying the brain and other diseases can be done with CT scan angiography, MRI angiography as well as digital subtraction angiography
- With the help of color Doppler, sonography of neck area for carotid and vertebral vessels can easily reveal the status of the arterial blood supply to the brain and tell us about narrowing of vessels
- Positron emission tomography (PET)-CT scan is the advanced technology in radiology, and PET and single photon emission computed tomography (SPECT) scans are very useful for diagnosing biochemical changes and blood flow in the brain
- Introduction of newer technologies in near future will facilitate the diagnosis of many unrevealed conditions and diseases of the brain.

JAYPEE BROTHERS

for detailed information on neurology books, visit our website **www.jaypeebrothers.com,** for detailed information on neur

# BRAIN & NEUROLOGICAL DISORDERS
## A Simplified Health Education Guide

***Salient Features***

- The book is a humble attempt to fill the gap in the understanding of neurological disorders by providing authentic, research backed information in a simple and lucid manner for one and all
- This edition is primarily intended to benefit the patients, their families, and care givers. It will also be useful for physicians, medical students, paramedics, and physiotherapists who have to counsel the patients and their families as well as nurse practitioners
- The purpose of this book is to educate people in a fair depth and help them navigate through complexities of neurological disorders as and when affected/confronted. It is also to enlighten and inspire community towards prevention as well as early detection of diseases, all in a reassuring and reader friendly language
- Supplemented with a large number of figures and diagrams, it further makes learning and understanding simpler for everyone
- Presented in a simple and lucid format, the book is for all who are keen to learn but do not have the time to pool all the relevant authoritative information concisely in a small span of time
- Written with a noble and benevolent cause, the authors wish to strengthen the scholarship imbued with a spirit of compassion and life. This will serve the purpose of authors to help humanity by saving lives and preventing morbidities.

**Professor Dr. Sudhir V Shah** MD DM (Neurology)
Senior Consultant, Professor and Head
Department of Neurology
VS General Hospital
Director of Neurosciences
Sterling Hospital
Ahmedabad, Gujarat, India



**Dr. Heli S Shah** MD (Medicine)
Resident, DM Neurology
VS General Hospital
Ahmedabad, Gujarat, India



*For any queries or correspondence*
**Professor Dr. Sudhir V Shah** MD DM (Neurology)
Clinic Address: 206/7/8 Sangini Complex
Near Parimal Railway Crossing, Ellisbridge
Ahmedabad, Gujarat, India
*www.sudhirneuro.org*

**Available at all medical bookstores**
**or buy online at www.jaypeebrothers.com**

**JAYPEE BROTHERS**
**Medical Publishers (P) Ltd.**
**www.jaypeebrothers.com**
Join us on facebook.com/JaypeeMedicalPublishers

Shelving Recommendation
**NEUROLOGY**

ISBN 978-93-85999-65-9
9 789385 999659