it our website **www.jaypeebrothers.com,** for detailed information on orthopedics books, visit our website **www.jaypeebrothers.com**

Patellofemoral Instability

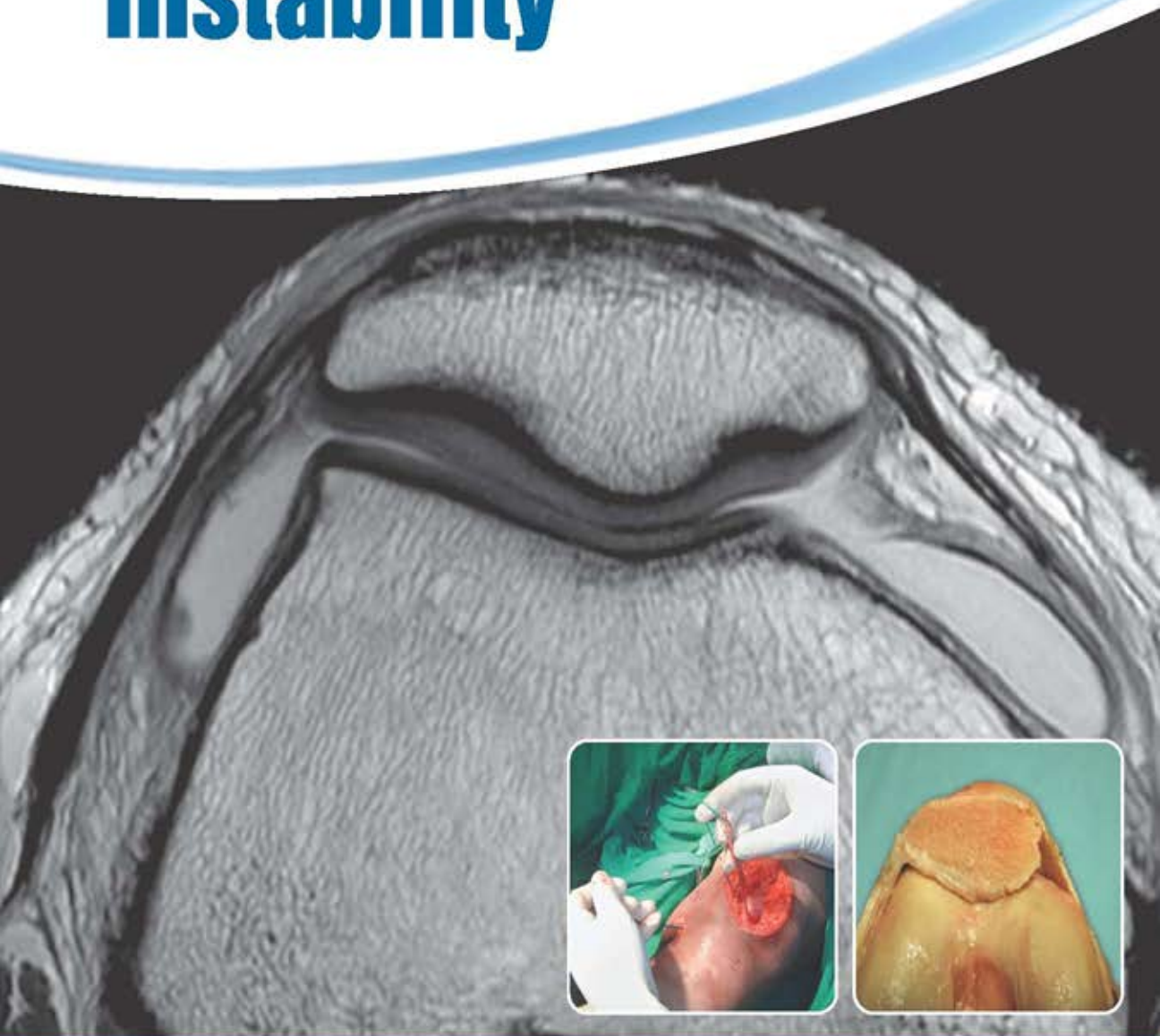

Sachin Ramchandra Tapasvi

Forewords
Padma Vibhushan KH Sancheti
Elizabeth A Arendt

JAYPEE

CONTENTS

1. The Epidemiology and Natural History of Patellar Dislocation **1**
Shantanu Sudhakar Patil

Incidence *1*
Biomechanics of the Patellofemoral joint *1*
Incidence in the Adolescents and Children *2*
Risk Factors *2*
Clinical Presentation and Physical Examination *2*
Investigations *3*
Natural History *3*

2. Anterior Knee Pain—Pathophysiology and Management **5**
Parag Sancheti

Pathophysiology of Anterior Knee Pain *5*
Clinical Findings *8*
Radiological Assessment *10*
Treatment *10*
Rehabilitation Protocol *10*
Operative Treatment *11*
Treatment for Osteochondral Defect in Patella *14*

3. Pathoanatomy of Lateral Dislocation **16**
Nilesh Kamat

Anatomical Factors *17*
Secondary Factors *18*
Osseous Factors *18*
Patella Alta *18*
Rotational and Axial Limb Deformities *19*
Soft Tissue Abnormalities *20*

4. Imaging in Patellofemoral Instability **23**
Anupama Sunil Patil

Normal Soft Tissue Stabilisers of the Knee *23*
Bony Stabilizers of the Knee *24*
Radiographs *25*
Magnetic Resonance Imaging *26*
CT Scan *33*
Postoperative Evaluation *34*
Advantage of MRI over Arthroscopy *34*
Mocart Score *34*
Role of Cartilage Mapping *35*

5. Role of Conservative Treatment in Patellar Dislocation **37**
Shirish Pathak

Natural History of Patellar Dislocation *37*
Treatment Philosophy—First-time Dislocator/Recurrent Dislocator *38*
Evidence in Literature Comparing Results of Nonooperative vs Operative Treatment in Acute Patellar Dislocation *38*
Cochrane Review and Meta-analysis *39*
MPFL Tear Location—its Implication in Decision Making of Conservative VS Operative Treatment for Patellar Dislocation *39*
Conservative Treatment Protocols *39*
Role of Nonoperative Treatment in Recurrent Patellar Dislocation *40*

6. Surgical Management of Acute Patellar Dislocations **44**
Sachin Ramchandra Tapasvi

Review of Literature *44*
Indications of Surgery *45*
Surgical Technique *46*
Pearls and Pitfalls *47*

7. Medial Patellofemoral Ligament Reconstruction **48**
Rahul Ajit Damle

Other Techniques *56*
Important Principles *57*
Post-operative Rehabilitation *58*
Complications *58*
Results *58*
Pearls and Pitfalls *59*

8. The Superficial Quad Technique
A Better Anatomic and Biomechanical Match for MPFL Reconstruction **61**
Deepak Goyal

Surgical Technique *61*
Postoperative Care *66*
Discussion *66*

9. Medial Patellofemoral Ligament Reconstruction—The 'Basket Weave' Technique **68**
Pranjal Sharad Kodkani

Surgical Technique *69*
Postoperative Rehabilitation *73*
Advantages of Technique *73*
Results *75*

10. Complications after MPFL Surgery: Tips and Pearls for Prevention of Complication and Successful MPFL Reconstruction **76**
Vivek Pandey

Complication of MPFL Reconstruction *76*
Take Home Tips for a Successful MPFL Reconstruction *80*

11. Trochleoplasty **82**
Sachin Ramchandra Tapasvi, Miten Rajendra Sheth
Normal Trochlear Anatomy and Biomechanics *82*
Abnormal Trochlear Anatomy and Biomechanics *83*
Diagnosis of Trochlear Dysplasia *83*
Indications for a Trochleoplasty *85*
Contraindications *85*
How does Trochleoplasty Help? *85*
Trochleoplasty *86*
Surgical Technique *86*
Postoperative Rehabilitation *89*
Complications *89*
Outcomes after Trochleoplasty *89*
Pearls and Pitfalls *90*

12. Tibial Tubercle Osteotomy **91**
Raju Easwaran
Essential Pre-Op Workup *91*
Surgical Technique *94*
Postoperative Physiotherapy and Follow-Up *96*
Pearls and Pitfalls *96*

13. Nonsurgical and Surgical Management of the Lateral Patellar Compression Syndrome **98**
Jonathan Austin Herald, Sagar Vivek Kakatkarr
Pathoanatomy *98*
Diagnosing the Lateral Patellar Compression Syndrome *100*
Nonsurgical Management of Lateral Patellar Compression Syndrome *102*
Surgery *104*
Surgical Procedure *105*
Discussion *108*

14. Cartilage Lesions in Patellofemoral Instability **111**
Raghu Raman
Diagnosis *112*
Which Lesions Should We Treat? *113*
Defects to Treat *113*
Postoperative Rehabilitation *119*
Other Treatments *120*
Pearls and Pitfalls *122*

15. Patellofemoral Instability after Total Knee Arthroplasty **124**
Miten Rajendra Sheth
Etiology *125*
Diagnosis *127*
Treatment *129*

Index *131*

CHAPTER 3

Pathoanatomy of Lateral Dislocation

Nilesh Kamat

JAYPEE BROTHERS

INTRODUCTION

Normal patellofemoral stability is a complex interplay between various static and dynamic factors. To understand the pathophysiology of a recurrent dislocating patella, we first need to understand normal patellofemoral biomechanics.

The innate osseous anatomy provides little stability to the patellofemoral articulation. At full extension, the patella is not in direct contact with the trochlea.[1] As the knee increases in flexion, different portions of the patella's articular surface contact the underlying trochlea.[2] From full extension to approximately 90°, the area of the patella in direct contact with the femur shifts gradually from the distal to the proximal pole; however, the odd facet has no contact at this point.[3] From 90° to 135° of flexion, the patella rotates and a ridge between the medial and odd facet engages the trochlea. From 120° to 135° of flexion, the odd facet is in contact with the femoral condyle and there is less contact between medial and lateral facets with the trochlea (Fig. 3.1).[1,3]

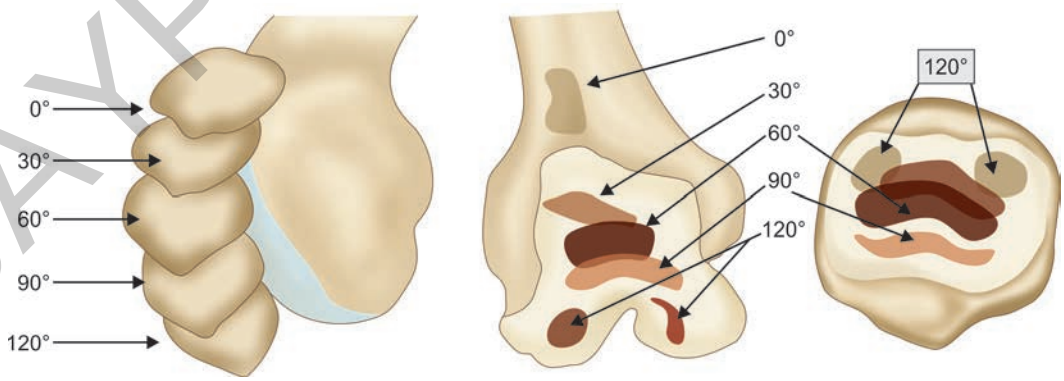

Fig. 3.1: Displacement of the medial patellofemoral ligament in relation to varying attachment positions at the femoral condyle

So effectively considering the shallow bony anatomy of the trochlea and the inadequate bony stability in early flexion, the soft tissue stabilizers play a pivotal role in stabilizing the patella.

Among the quadriceps muscles, the vastus medialis obliquus (VMO) and vastus lateralis (VL) also confer patellofemoral stability. These muscles insert with a deviation from the anatomic axis that pull the patella medially and laterally, respectively. Atrophy or weakness of either muscle may cause alteration of tracking of the patella.[4] On the lateral side of the knee, the iliotibial (IT) band originates from the distal aspect of the tensor fascia lata and inserts onto Gerdy's tubercle in the proximal tibia. The IT band also has insertions onto the patellar and quadriceps tendons thus influencing the patella to track in a more lateral position.[1] In addition the medial patellofemoral ligament (MPFL) is the primary stabilizer of the patellofemoral joint.[1] The MPFL provides 50%–60% of lateral restraint from 0° to 30° of flexion.[5] In a cadaveric study, Senavongse et al. reported that rupturing the medial retinaculum, including the MPFL, resulted in a 49% decrease in the force required to move the patella 10 mm laterally.[6] Passive stabilizers in the patellofemoral joint include patellofemoral and patellotibial ligaments and the retinacula.

In summary, in a normal patellofemoral articulation these would form the most important restraints to prevent the patella from dislocation (Fig. 3.2):

a. Primary dynamic stabilizer: VMO
b. Primary bony stabilizer: Trochlear groove
c. Primary soft tissue static stabilizer: MPFL

However, for the patella to dislocate there has to be a complex interplay of multiple factors.

This can be best explained on basis of the classification devised by Dejour.[7] In 1987, H Dejour established a classification of patellofemoral disorders, with three patterns, involving the four main anatomical factors and the four secondary factors described.

ANATOMICAL FACTORS

- Increased TT—TG distance
- Trochlear dysplasia
- Patella alta
- Excessive patellar tilt.

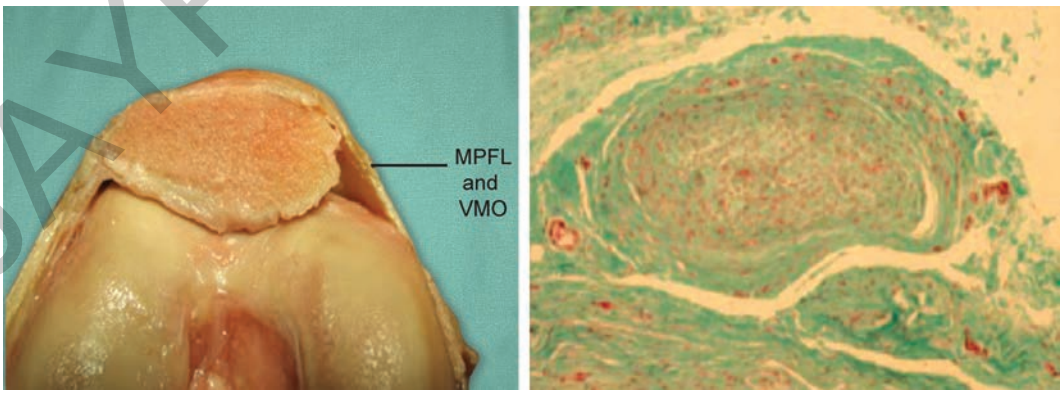

Fig. 3.2: Normal patellofemoral articulation

JAYPEE BROTHERS

SECONDARY FACTORS

- Excessive femoral anteversion
- Excessive tibial extorsion
- Genu valgum
- Genu recurvatum.

The three patterns are:

a. *Objective patellar instability (OPI)*: Patients presenting with this pattern will have a history of at least one true dislocation of the patella (permanent loss of contact between two joint surfaces), and at least one anatomical abnormality.
b. *Potential patellar instability (PPI)*: Patients in this group will not have had any true patellar dislocation, but will have pain and anatomical abnormalities.
c. *Painful patella syndrome (PPS)*: These patients will have neither dislocation nor anatomical abnormalities; however, they will have pain.

These factors can be best described as:

- Osseous
- Soft tissue
- Combination.

OSSEOUS FACTORS

Trochlear Dysplasia

A trochlea is described as dysplastic if it has lost its congruence with the patella, i.e. if it is flat or even convex. The anatomy of the femoral trochlea has been investigated by a number of authors. H Dejour, in 1987, defined dysplasia of the trochlea in terms of the crossing sign (croisement) on strictly lateral knee radiographs. If the sulcus floor line crosses the anterior border of the two condyles, the trochlea is said to be flat.[7] In 1998, D Dejour et al, in the light of a new study, proposed a classification based upon the morphology of the trochlea on CT scans of the reference section (first slice showing cartilage), and the patterns seen on the lateral radiograph. This analysis permits a better definition of the four grades of dysplasia (Fig. 3.3).[8]

PATELLA ALTA

Patella alta is frequently missed or ignored as most focus has been on alignment and the medial restraints, but the role of patella alta in instability may be more important than realized.

- Patella alta also has been reported in 24% of patients with patellar instability versus 3% of patients with stable patellae[7]
- It is important to note that patella alta rarely occurs in isolation—it is frequently associated with trochlear dysplasia[9]
- Patients who suffer a dislocation with minimal trauma are more likely to have patella alta than those with traumatic dislocations.[10]

Patella alta reduces patellofemoral stability because the patella does not engage the trochlea until higher degrees of flexion when compared with a normal knee.[8] As a result, there is less osseous stability conferred by the trochlea at full extension and early flexion.[1]

JAYPEE BROTHERS

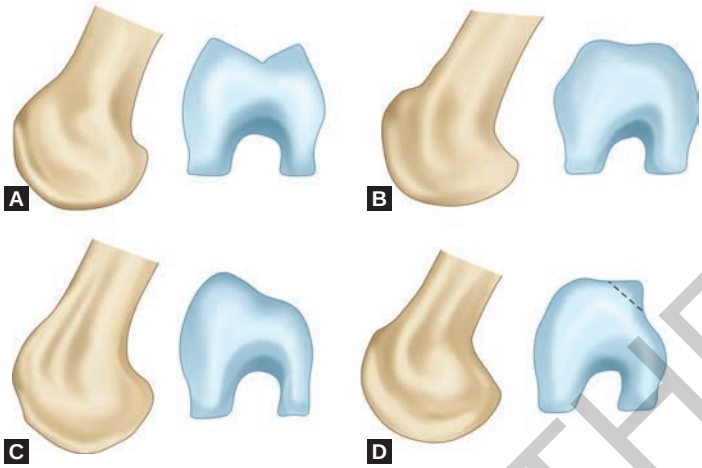

Figs 3.3A to D: Dejour's classification of trochlear dysplasia

(A) **Grade A:** Crossing sign and shallow trochlea
(B) **Grade B:** Crossing sign, supratrochlear spur, flat trochlea
(C) **Grade C:** Crossing sign, double contour, asymmetry of trochlear facets
(C) **Grade D:** Grade B + C, asymmetry of trochlear facets, cliff pattern

ROTATIONAL AND AXIAL LIMB DEFORMITIES

Brattstrom described the Q angle as the angle formed by the line of pull of the quadriceps and that of the patellar tendon as they intersect at the center of the patella (Fig. 3.4).[11] The Q angle changes based on knee flexion and it is largest in extension as the tibia externally rotates in

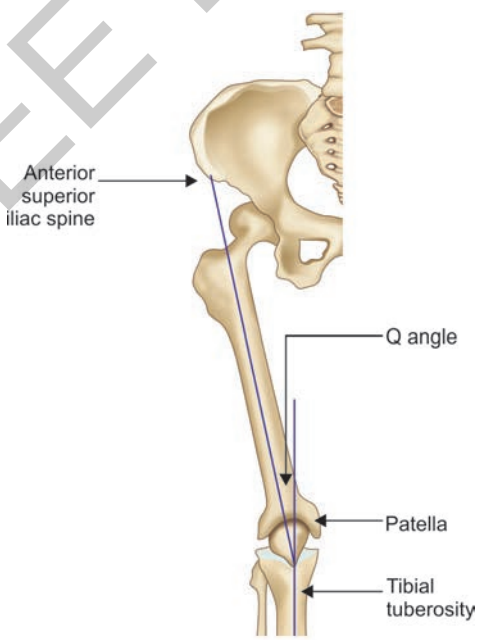

Fig. 3.4: Q angle

JAYPEE BROTHERS

terminal extension. The patellofemoral joint is at greatest risk of instability at full extension when the Q angle is largest and the patella is not in contact with the trochlea.[1] The Q angle is largest in extension in relation to the screw home mechanism of the knee. For this measurement to be accurate, the patella should be centered on the trochlea. The mean Q angle for males is 11.2° and in females it is 15.8°.[12] It should be noted that the relationship between the Q angle and clinical signs and symptoms has not always been consistent.

A possible reason for the lack of association is related to the fact that there has been no consensus with respect to how this measurement should be taken, but more important is the fact that this measurement is taken statically, therefore, the contribution of abnormal segmental motions and muscle activation to the Q angle during dynamic activities may not be appreciated.

The Q angle is an expression of patellar kinematics that is guided by the static bony restraints and by dynamic muscle vectors. Therefore, the analysis of the static deformities that can alter the patellar kinematic are better evaluated with CT scan taking into consideration femoral neck anteversion, distal femoral rotation and tibial rotation. Patellar centration is more reliably evaluated by the measurement of TT-TG that considers femoral rotation as well as the rotation of tibial tuberosity (Fig. 3.5).[7]

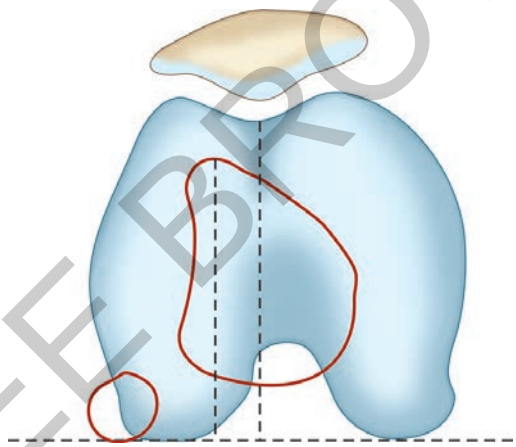

Fig. 3.5: TT–TG distance calculation

It has been noted that in these knees with axial or rotational deformities the Q angle tends to increase resulting in exaggerating the lateral destabilizing forces. This manifests as a Dynamic patellar instability and is seen in knees with genu valgum, excessive femoral anteversion and excessive tibial torsion.

SOFT TISSUE ABNORMALITIES

These would include:

- Extensor muscle dysplasia
- Ipoplasia of VMO
- Patellofemoral, patellotibial ligament issues
- Iliotibial band (ITB) tightness
- Generalized hyperlaxity.

JAYPEE BROTHERS

Normally, the patella needs to be well-centered along the trochlea during knee flexion and extension. However, in the above conditions there is stress concentration along the lateral patellar facet and maltracking of the patella resulting in increased propensity to lateral dislocation (Fig. 3.6).

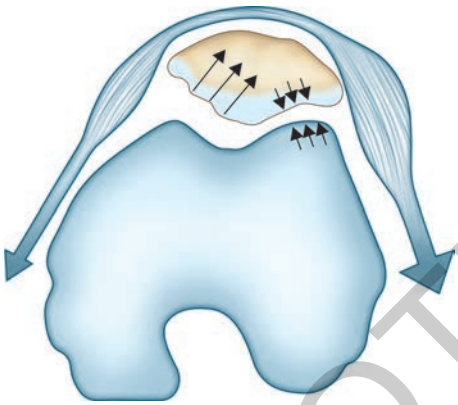

Fig. 3.6: Soft tissue abnormalities in lateral patellar dislocation

Whenever surgical option is considered for management of recurrent dislocation of the patella, it is important to consider all the predisposing osseous and soft tissue factors to have a favorable outcome (Table 3.1).

Table 3.1: Summary of associated abnormalities in pathoanatomy of lateral patellar dislocation

Osseous	*Soft tissue*
Trochlear dysplasia	Extensor muscle dysplasia
Patella alta	Hypoplasia of VMO
Rotational limb deformities	ITB tightness
Axial limb deformities	Patellofemoral Patellotibial ligament issues
Patellar dysplasia	Generalized laxity

Abbreviation: VMO—vastus medialis obliquues, ITB—iliotibial band

REFERENCES

1. Colvin AC, West RV. Patellar instability. JBJS Am. 2008;90(12):2751-62.
2. Grelsamer RP. Patellar malalignment. JBJS Am. 2000;82–A(11):1639-50.
3. Goodfellow J, Hungerford DS, Zindel M. Patello-femoral joint mechanics and pathology.1: Functional anatomy of the patello-femoral joint. J Bone Joint Surg Br. 1976;58(3):287-90.
4. Stokes M, Young A. Investigations of quadriceps inhibition: implications for clinical practice. Physiotherapy. 1984;70:425-8.
5. Desio SM, Burks RT, Bachus KN. Soft tissue restraints to lateral patellar translation in the human knee. Am J Sports Med. 1998;26(1):59-65.
6. Senavongse W, Amis AA. The effects of articular, retinacular, or muscular deficiencies on patellofemoral joint stability: a biomechanical study in vitro. J Bone Joint Surg Br. 2005;87(4):577-82.

JAYPEE BROTHERS

7. Dejour H, Walch G, Nove-Josserand L, et al. Factors of patella instability: an anatomic radiographic study. Knee Surg Sports Traumatol Arthrosc. 1994;219-26.
8. Dejour D, Reynaud P, Douleurs LB, et al. Instabilite rotulienne: Essai de classification. Med Hyg. 1998; 56:1466-71.
9. Caton J, Mironneau A, Walch G, Levigne C, Michel CR. Idiopathic high patella in adolescents. Apropos of 61 surgical cases. Rev Chir Orthop Reparatrice Appar Mot. 1990;76(4):253-60.
10. Geenen E, Molenaers G, Patella MM, et al. in patellofemoral instability. Acta Orthop Belg. 1989;55(3):387-93.
11. Brattstrom H. Shape of the intercondylar groove normally and in recurrent dislocation of patella. Acta Orthop Scand Suppl. 1964;68:1-40.
12. Horton MG, Hall TL. Quadriceps femoris muscle angle: normal values and relationships with gender and selected skeletal measures. Phys Ther. 1989;69(11):897-901.

JAYPEE BROTHERS

for detailed information on orthopedics books, visit our website **www.jaypeebrothers.com,** for detailed information on orthopedics

Patellofemoral Instability

Salient Features

- Complete and comprehensive information on patellofemoral instability collated by experts and presented in simple and lucid language
- Surgical techniques, developed by Indian surgeons and described in detail by themselves
- Includes pearls and pitfalls at the end of certain chapters
- Text enhanced by illustrations, photographs, tables, flowcharts and X-ray photographs
- Useful guide for the general orthopedists as well as for the experts.



Sachin Ramchandra Tapasvi MS (Orth) DNB (Orth) MNAMS AFAOA (Australia) graduated at the top of his class from Byramjee Jeejeebhoy Medical College, Pune in 1991 and is today one of the leading arthroscopy and joint replacement surgeons in India. He served his fellowship in Adelaide, Australia where he acquired extensive training in the science and art of orthopedic surgery. At 45, he has behind him 17 years of extensive experience in sports medicine, arthroscopic surgery and arthroplasty. He is an astute clinician who renders his services across multiple hospitals in Pune and Nashik. His passion in sharing his knowledge and experiences sees him constantly engaged with his fellows and as a faculty in academic events around the globe. His zeal for research is reflected in multiple peer-reviewed publications in scientific journals and his involvement in numerous clinical trials. He also serves at official positions in several regional, national and international academic bodies. He has a special love for wildlife photography and has trekked many a mile in harsh weather and difficult terrains to capture that elusive shots.

Available at all medical bookstores
or buy online at www.jaypeebrothers.com

JAYPEE BROTHERS
Medical Publishers (P) Ltd.
www.jaypeebrothers.com

Join us on facebook.com/JaypeeMedicalPublishers

Shelving Recommendation
ORTHOPEDICS

ISBN 978-93-85999-66-6