detailed information on ophthalmology books, visit our website **www.jaypeebrothers.com,** for detailed information on ophthalmology books

Practical Handbook of OCT Angiography

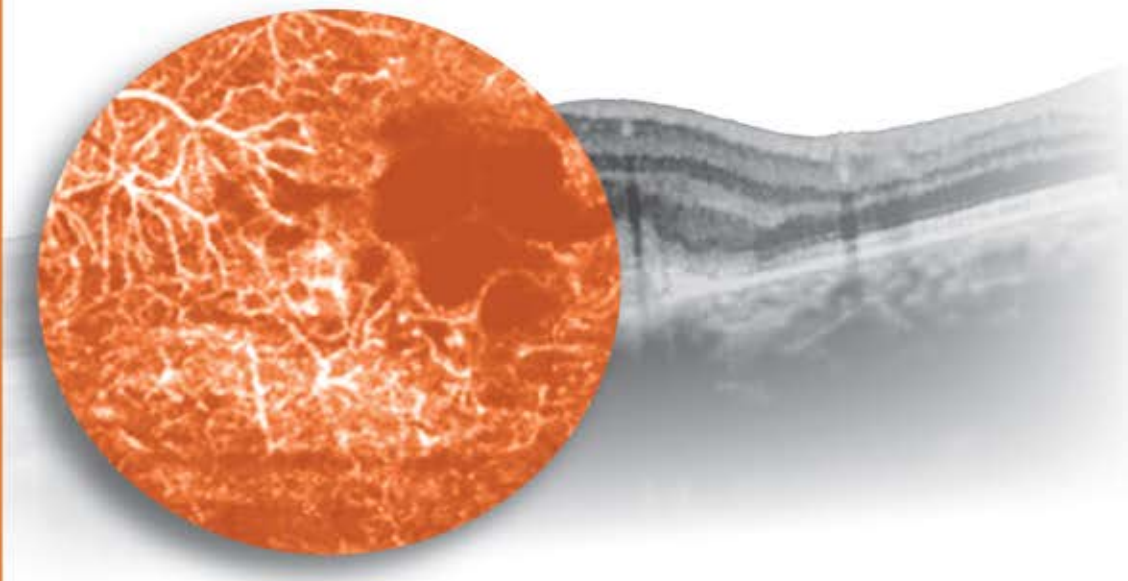

Editors
Bruno Lumbroso
David Huang
Eric Souied
Marco Rispoli

JAYPEE

Contents

1. Principles of Optical Coherence Tomography Angiography **1**
David Huang, Yali Jia, Simon S Gao
- Optical Coherence Tomography Angiography 1

2. Interpretation of Optical Coherence Tomography Angiography **6**
David Huang, Yali Jia, Simon S Gao
- Anatomic Reference Planes and Angiographic Slabs 6
- AngioVue Default Segmentation and Display 8

3A. Quantification of Vascular Layers with Optical Coherence Tomography Angiography **16**
Marco Rispoli
- Flow Area 16
- Nonflow Area (Vascular Dropout Area) 16
- Flow Density Map 16

3B. Practical Problems and Artifacts in Optical Coherence Tomography Angiography **22**
Marco Rispoli, Bruno Lumbroso

4. Optical Coherence Tomography Angiography of Normal Retina and its Vascular Structure **24**
Maria Cristina Savastano, Marco Rispoli, Bruno Lumbroso
- Retinal Vascular Networks 24

5. Diabetic Retinopathy and Optical Coherence Tomography Angiography **28**
Maria Cristina Savastano, Marco Rispoli, Bruno Lumbroso
- Objective Quantitative Analysis 32

6. Vascular Occlusions **33**
Marco Rispoli, Bruno Lumbroso, Maria Cristina Savastano, Jean Francois Le Rouic, Pascal Peronnet

Branch or Central Vein Occlusions **33**
Marco Rispoli, Bruno Lumbroso, Maria Cristina Savastano
- Central Retinal Vein Occlusion and Venous Branch Occlusion 33
- Optical Coherence Tomography Angiography 34

Retinal Artery Occlusion **40**
Jean Francois Le Rouic, Pascal Peronnet
- Retinal Artery Occlusion: Acute Stage 40
- Retinal Artery Occlusion: Late Phase 41
- Treatment 42

7. Type 1, Type 2 and Type 4 (Mixed) Choroidal Neovascularization **44**
Bruno Lumbroso, Marco Rispoli
- Assessing New Vessels 45
- Type 1 New Vessels 45

- Type 2 New Vessels 47
- Type 3 New Vessels 50
- Type 4 New Vessels (Mixed Type) 50
- Neovascular Membranes in Myopia 52

8. Type 3 Neovascularization Features on Optical Coherence Tomography Angiography **56**
Alexandra Miere, Giuseppe Querques, Ala El Ameen, Vittorio Capuano, Oudy Semoun, Eric Souied

9. Choroidal Neovascularization in Diseases other than Age-related Macular Degeneration **61**
Adil El Maftouhi, Maddalena Quaranta-El Maftouhi

Degenerative Myopia, CSC, Multiple Choroiditis **61**
Adil El Maftouhi, Maddalena Quaranta-El Maftouhi
- Degenerative Myopia 61
- Choroidal New Vessel Complications in Angioid Streaks 61
- Chronic Central Serous Chorioretinopathy 61
- Choroidal New Vessel Complications in Multifocal Choroiditis 62

Polypoidal Choroidal Vasculopathy **77**
Maddalena Quaranta-El Maftouhi, Adil El Maftouhi

10. Other Types of Choroidal Neovascularization not Linked to Age-related Macular Degeneration **87**
Leonardo Mastropasqua, Luca Di Antonio

11. Subretinal Fibrosis Features in Optical Coherence Tomography Angiography **93**
Eric Souied, Alexandra Miere, Oudy Semoun, Eliana Costanzo, Salomon Yves Cohen

12. Evolution in Time of Flows after Treatment **98**
Bruno Lumbroso, Marco Rispoli
- Early Changes after Treatment 98

13. Optic Nerve and Glaucoma **103**
Michel Puech
- Optical Coherence Tomography Angiography around the Optic Disc 103
- Vascularization Inside the Optic Disc 104

14. Comparing Fluorescein Angiography with Optical Coherence Tomography Angiography **107**
Bruno Lumbroso, Marco Rispoli
- Fluorescein Angiography 107

Index *115*

4 Optical Coherence Tomography Angiography of Normal Retina and its Vascular Structure

Maria Cristina Savastano, Marco Rispoli, Bruno Lumbroso

JAYPEE BROTHERS

INTRODUCTION

Optical coherence tomography (OCT) angiography shows the vascular structure of the retina *in vivo* without contrast agent. OCT angiography detects endoluminal flow at any time and is thus, independent of the time of administration of the contrast medium as in fluorescein angiography. However, at present, the periphery beyond the arches cannot yet be examined.

The classical anatomic studies described in the first half of the 20th century demonstrate the distribution of retinal vessels as organized into three distinct layers: (1) superficial plexus, observable with the ophthalmoscope, with the large and average sized vessels distributed in the retinal nerve fiber layer; (2) inner plexus, a body of small-sized capillaries located close to the inner surface of the inner nuclear layer; and (3) outer plexus: morphologically similar to the inner plexus but located on the outer surface of the outer plexiform layer.

OCT angiography has confirmed the findings of these studies *in vivo* and facilitates the separate study of the two vascular plexuses, the superficial vascular plexus and the internal/external that we consider as a single deep plexus. These two plexuses clearly have different features that cannot be distinguished by classical fluorescein angiography.

RETINAL VASCULAR NETWORKS

There are three vascular networks in the retina: one superficial and two deep. The resolution provided by OCT angiography with the split-spectrum amplitude-decorrelation angiography (SSADA) algorithm enables clear visualization of the superficial vascular plexus with a 60-micron section at the inner limiting membrane (ILM). The two deep plexuses cannot be clearly differentiated, since the smaller of 30-micron structures do not have sufficient resolution for them to be clinically useful. These two deep plexuses will therefore, be treated in this chapter as a single vascular entity, included in segmentation at the inner plexiform layer (IPL) of at least 30 microns.

The superficial vascular plexus is located in the ganglion cell layer and in the nerve fiber layer.

The two deep vascular nets are treated in this chapter as a single entity. They are located in the inner nuclear layers and external plexiform layer. From the anatomical standpoint, this plexus consists of two plexuses located respectively on the inside of the inner nuclear and on the outside of the outer plexiform layer. Since they cannot be individually seen by OCT angiography, they are considered as a single plexus.

In order to study the two main vascular plexuses, specific parameters that concern the intraretinal level (ILM, IPL, RPE , RPE ref), the thickness of the scan being examined and the offset are used. The need to establish very precise points of reference to analyze the vascular plexuses is determined in order to compare the analyses made by different operators and hence make the images as objective as possible.

The assessment of the superficial plexus (SP) uses a thickness of 60 μm from the ILM so as to include all the vessels of this plexus **(Fig. 4.1)**. The parameters for the deep plexus (DP) are defined with reference to the IPL in a 30 μm thick

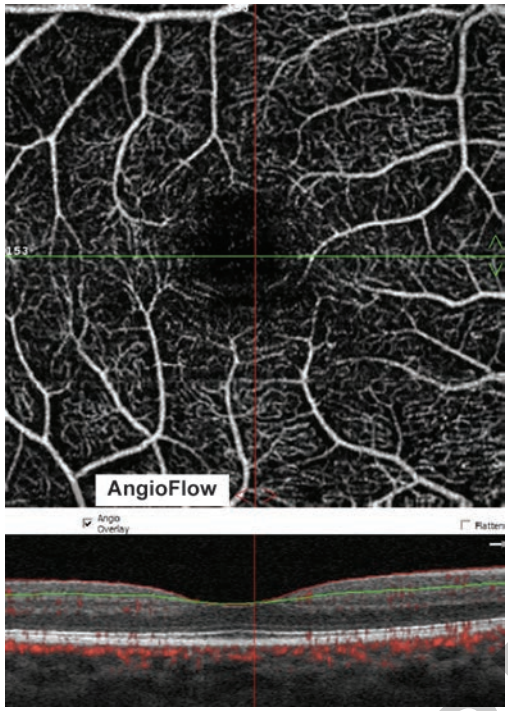

Figure 4.1 *The superficial plexus:* There are multiple white linear structures (flow) against a black background that converge towards the fovea with a centripetal pattern. Secondary vessels leave the main vessels forming a spider web. Around the avascular area, the capillaries form continuous perifoveal arcades with regular meshes. Below, the B-scan shows normal vessels in red



Figure 4.2 *The deep plexus*: This consists of a close-knit pattern of vessels whose orderly distribution around the avascular foveal zone presents numerous thin horizontal and radial interconnections. The vessels fan out and interconnect to form a complex pattern. Below, the B-scan shows normal vessels in red

scan to visualize the deep plexus in its entirety (**Fig. 4.2**).

OCT angiography shows different morphological features of the retinal blood supply for the two plexuses considered.

The superficial plexus: The vascular distribution is represented by multiple white linear structures (flow) against a black background that converge towards the fovea with a centripetal pattern and originate from the large upper and lower vascular arcades. Secondary vessels leave the main vessels, forming a spider web. The thickness of the vessels is homogeneous throughout the length of the scan. The course of the vessels is always rather linear; the web is regular without sudden changes in direction or without vascular meanders or loops. The vessels show a vascular signal (de-correlation) throughout the scan. Around the avascular area, the capillaries form continuous perifoveal arcades with regular meshes.

The deep plexus: This consists of a close-knit pattern of vessels whose orderly distribution around the avascular foveal zone presents numerous thin horizontal and radial interconnections. The pattern is concentric around the avascular foveal zone. Thickness of the vessels is constant throughout the scan as is their vascular signal. The vessels fan out and interconnect to form a complex pattern.

Interconnections between superficial and deep networks: The vascular network consists of

JAYPEE BROTHERS

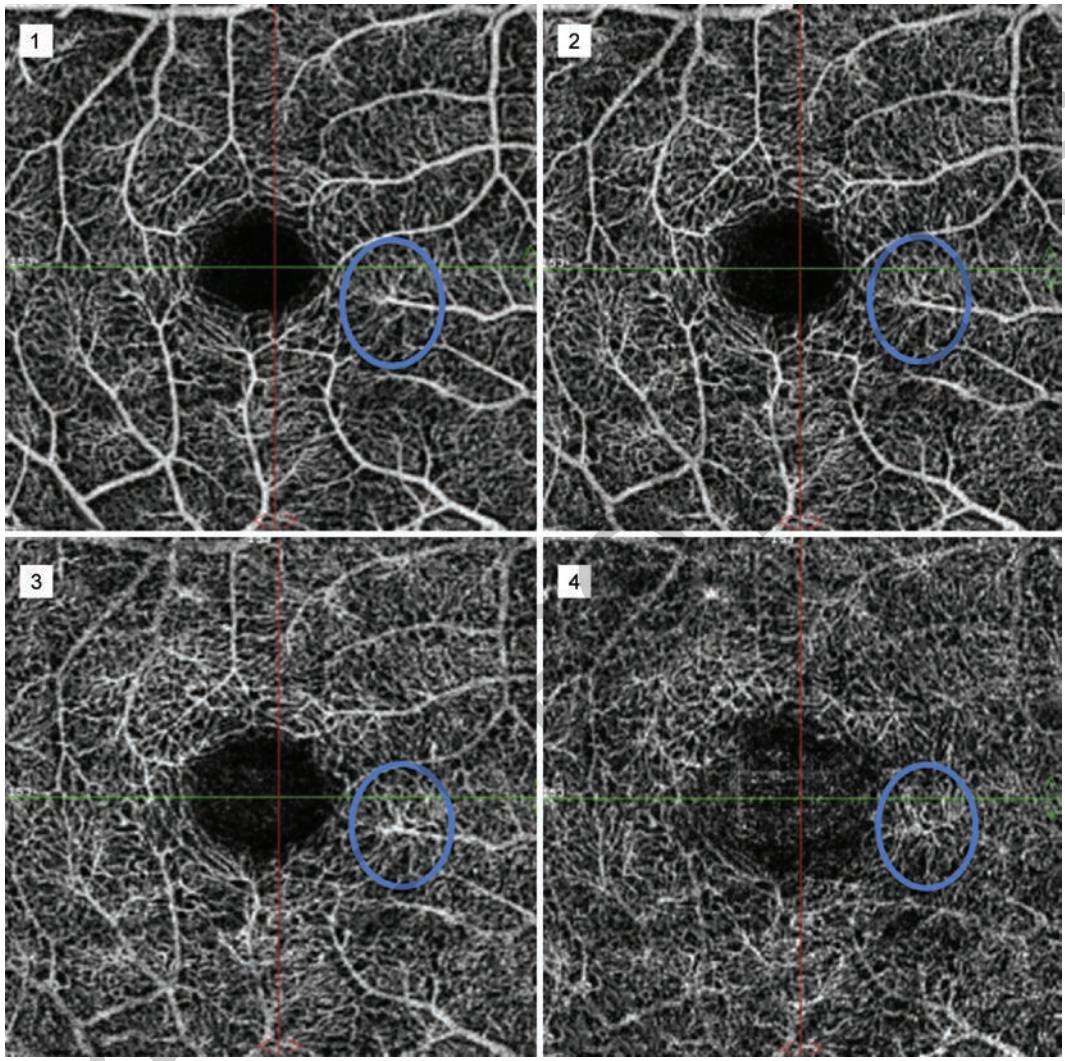

Figure 4.3 *Interconnections between superficial and deep networks:* Stack of consecutive "*en face*" OCT angiography scans (numbered from 1 to 4) from the superficial network to the deep network. The blue circle highlights different features of an interconnecting vascular branch, originating from the superficial net, going deeper and deeper, and eventually fanning out in the deep plexus

small vertical interconnecting anastomoses between the superficial and deeper vessels of the same deep plexus. The interconnecting vascular branches originate from the superficial net, go deeper and deeper, eventually fanning out in the deep plexus. From each lower extremity of the vertical anastomoses, horizontal vessels fan out and interconnect to form a complex pattern **(Fig. 4.3)**.

In fluorescein angiography, both plexuses overlap and therefore, they can neither be distinguished nor assessed separately. The contemporary visualization of both plexuses does not make it possible to analyze the superficial and deep vascular features that may be involved individually or separately in the various pathological processes. In healthy eyes, the superficial plexus consists of larger vessels with

respect to the deep complex. Both plexuses are distributed according to a centripetal pattern around the avascular foveolar zone. The deep plexus consists of small fan shaped vessels that interconnect to form a complex pattern.

With fluorescein angiography, the vascular tree and therefore, the vessel morphology cannot be directly visualized; what is seen is the result of intravascular fluorescein. This effect is particularly evident in the case of retinal walls lesions and hence the dye leakage or pooling masks the real aspect of the vessels.

The OCT angiography precisely demonstrates the intravascular flow without the use of a dye. While this warrants a good visualization of the vessels, it does entail newer methods of imaging interpretation. There is a need for newer diagnostic parameters for vascular disorders.

One of the present limitations of OCT angiography is the size of the scan area involving the macular region alone (3 × 3 mm–6 × 6 mm). In the near future, a full field will be obtained and provide greater information and offer better detail. Another limitation is with respect to the currently available software for visualizing the structures under the retinal pigment epithelium (RPE).

BIBLIOGRAPHY

1. Carpineto P, Mastropasqua R, Marchini G, et al. Reproducibility and repeatability of foveal avascular zone measurements in healthy subjects by optical coherence tomography angiography. Br J Ophthalmol, 2015. [Epub ahead of print].
2. Druault A. Appareil de la Vision. Traité d'Anatomie Humaine. Poirier et Charpy, 1911;1: 1018.
3. Duke-Elder S. The Anatomy of Visual System. London, United Kingdom. 1961;2:372-6.
4. Hogan M, Alvarado J, Weddell JE. Histology of the Human Eye—An Atlas and Textbook. Philadelphia, PA: WB Saunders; 1971.
5. Huang D, Swanson EA, Lin CP, et al. Optical coherence tomography. Science. 1991;254: 1178-81.
6. Jia Y, Bailey ST, Wilson DJ, et al. Quantitative optical coherence tomography angiography of choroidal neovascularization in age-related macular degeneration. Ophthalmology. 2014; 121:1435-44.
7. Jia Y, Tan O, Tokayer J, et al. Split-spectrum amplitude decorrelation angiography with optical coherence tomography. Opt Express. 2012;20: 4710-25.
8. Redslob E. Anatomie du Globe Oculaire. Traité d'Ophtalmologie. Paris, France: Masson, édit, 1939;5:382.
9. Savastano MC, Lumbroso B, Rispoli M. In vivo characterization of retinal vascularization morphology using optical coherence tomography angiography. Retina. 2015;35:2196-203.
10. Spaide RF, Klancnik JM Jr, Cooney MJ. Retinal vascular layers imaged by fluorescein angiography and optical coherence tomography angiography. JAMA Ophthalmol. 2015;133:45-50.

JAYPEE BROTHERS

for detailed information on ophthalmology books, visit our website **www.jaypeebrothers.com,** for detailed information on ophthalmology b

Practical Handbook of OCT Angiography

Salient Features

- Shows OCT angiography as a revolutionary development in ocular imaging
- Offers a step-by-step guide for interpreting the new images and data acquired by OCT angiography
- The noninvasive dyeless OCT angiography is taking an important place as diagnostic tool in everyday ophthalmology, as complement of, and in part replacing fluorescein angiography
- Allows to use the OCT angiography technology for studying inner and outer retina disorders, both qualitatively and quantitatively and classifying choroidal neovascularization (CNV) in a noninvasive manner, highlighting morphology, flow and depth
- Gives new technical and clinical information in the study of glaucoma
- Involves a technical dimension and an intellectual aspect in the assessment and interpretation activity
- Teaches a logical method of analysis and interpretation of the clinical images to help and guide the clinician in assessing, classifying and selecting information
- Helps practically the ophthalmologists, residents, ophthalmic technicians and optometrists in everyday clinical work, understanding and appreciating the new possibilities offered by OCT angiography imaging.



Bruno Lumbroso MD has been the Director, Department of Ophthalmology, Rome Eye Hospital and Professor LD of Clinical Ophthalmology, University of Rome La Sapienza for more than 35 years. Currently, he is the Director, Centro Italiano Macula, Rome, Italy, and General Secretary, the Italian Laser Society. He has written handbooks and retinal imaging in fluorescein angiography, microperimetry, spectral-domain OCT, "en face" OCT, and OCT angiography. He is involved in medical education in ocular imaging. His main interests are in logical methods of retinal imaging analysis and interpretation, and in clinical applications of OCT technology for retinal disorders.



David Huang MD PhD is Peterson Professor of Ophthalmology, Casey Institute, Oregon Health and Science University, Portland, USA. He has been the Manger Chair of Corneal Laser Surgery and an Associate Professor of Ophthalmology and Biomedical Engineering, University of Southern California, and the Director of the Doheny Laser Vision Center, Los Angeles, USA. He co-invented OCT when he was a PhD student with Professor James Fujimoto at the Massachusetts Institute of Technology. He heads the Center for Ophthalmic Optics and Lasers—a group that pioneered corneal and anterior segment OCT. He leads the Advanced Imaging for Glaucoma Bioengineering Partnership which developed OCT ganglion cell complex mapping and retinal blood flow measurement.



Eric Souied MD PhD is the Professor and Head, Department of Ophthalmology at both "Centre Hospitalier Intercommunal de Créteil" and "Henri Mondor" Hospital, in France. He earned his MD and PhD degrees in 1990–2006, at the University of Paris, Créteil, France where he also completed his ophthalmology residency. He completed a medical fellowship at the Creteil University Eye Clinic and a post-doctoral fellowship at the Jules Stein Eye Institute, University of California, Los Angeles (UCLA), USA. His main topics are Medical Retina (AMD, inherited macular and retinal dystrophies), Ophthalmic Surgery (retina and cataract) and OCT angiography. He has contributed to more than 300 peer-reviewed articles published in the areas of age-related macular degeneration (AMD), hereditary retinal diseases, ophthalmic genetics and gene therapy of retinal dystrophies. His main areas of research are genetics, imaging, OCT imaging and treatments of AMD.



Marco Rispoli MD is on Staff Ophthalmologist, Department of Ophthalmology, Ospedale Nuova Regina Margherita and in Centro Italiano Macula, Rome, Italy. He is interested in developing ocular imaging. He has written handbooks on retinal imaging interpretation of time-domain OCT and spectral-domain OCT.

Available at all medical bookstores
or buy online at www.jaypeebrothers.com



JAYPEE BROTHERS
Medical Publishers (P) Ltd.
www.jaypeebrothers.com

Join us on facebook.com/JaypeeMedicalPublishers

Shelving Recommendation
OPHTHALMOLOGY

