brothers.com, for detailed information on medicine books, visit our website www.jaypeebrothers.com, for detailed information on medicine books

RESPIRATORY SYSTEM

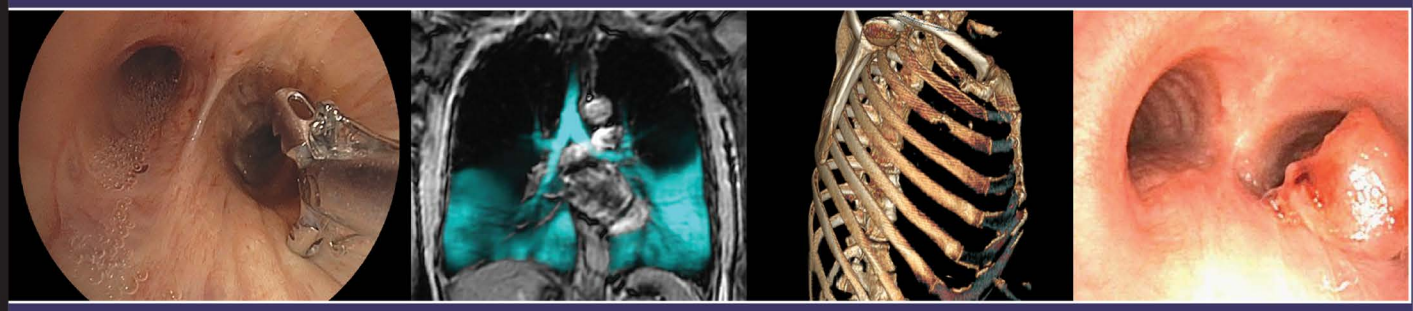

Diagnostic Evaluation of the RESPIRATORY SYSTEM

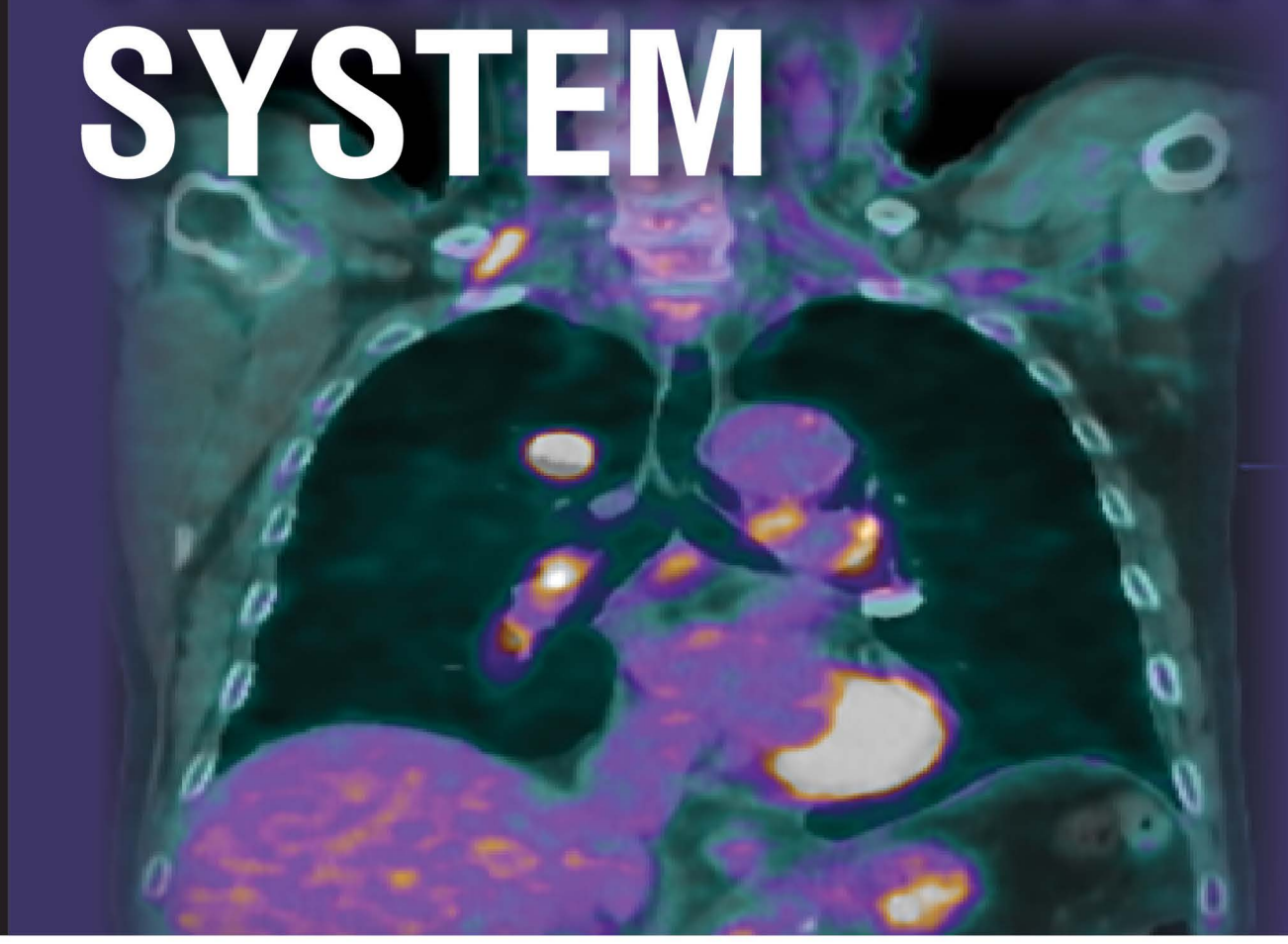

Claudio Sorino

Foreword
Nicola Scichilone

JAYPEE

Contents

Section 1: Respiratory System Assessment

1. Signs, Symptoms, and Medical History in Respiratory Medicine **3**
Claudio Sorino, Vincenzo Bellia

- History of Present Illness (HPI) *3*
- Past Medical History (PMH) *3*
- Drug History (DH) *4*
- Family History *4*
- Occupational History (OH) *4*
- Dyspnea *5*
- Chest Pain *10*
- Cough *14*
- Hemoptysis (Coughing up Blood) *15*
- Miscellaneous Symptoms *16*

2. Respiratory Examination **19**
Claudio Pedone, Giuseppe Augugliaro, Claudio Sorino

- Overview of the Semeiotics of the Respiratory System *19*
- Chest Inspection *20*
- Chest Palpation *23*
- Chest Percussion *24*
- Chest Auscultation *26*

3. Clinical Utility and Interpretation of Laboratory Tests in Respiratory Medicine **28**
Damiano Magrì, Giada Oliviero, Giuseppe Milani, Claudio Sorino

- Overview of Laboratory Tests in Respiratory Medicine *28*
- Blood Count *28*
- C-Reactive Protein *30*
- Erythrocyte Sedimentation Rate *31*
- Procalcitonin *31*
- Laboratory Diagnosis of Pneumonia *32*
- D-Dimer *33*
- Natriuretic Peptides *34*
- Markers for Myocardial Ischemia *37*
- Tumor Markers in Lung Cancer *39*

4. Diagnosis of Respiratory Allergy **41**
Francesca Puggioni, Claudio Sorino, Robert G Hamilton

- Overview of Allergy Diagnosis *41*
- In Vivo (Skin) Tests for Confirmation of Allergic Sensitization *41*
- In Vitro (Serological) Tests for Allergic Sensitization *44*
- Molecular-Based Allergy *47*
- Definitions *48*

5. Tuberculosis Diagnostics: In Vivo and in Vitro Techniques **53**
Claudio Sorino, Tiziana Cappelletti
- Background *53*
- Diagnosis of Latent Tuberculosis Infection *53*
- Diagnosis of Active Pulmonary Tuberculosis *56*

Section 2: Evaluation of Respiratory Function

6. Overview of the Pulmonary Function Tests **63**
Claudio Sorino, Theodore G Liou, Riccardo Pistelli
- Meaning of Lung Function *63*
- Spirogram and Displaceable Volumes *63*
- Nondisplaceable Lung Volumes *65*
- Parameters of Respiratory Flow *65*
- Parameters of Airways Resistance *66*
- Parameters of Lung Diffusing Capacity *67*

7. Displaceable Lung Volumes: Simple Spirometry **69**
Claudio Sorino, Salvatore Battaglia
- Overview of Simple Spirometry *69*
- Preparation of the Equipment *70*
- Preparation of the Patient and Precautions Before Testing *70*
- Test Execution *71*
- Quality Assessment of Spirometry *71*
- Interpretation of Test *75*
- Bronchodilator Reversibility Test *76*

8. Lung Volumes and Further Assessment: Beyond Spirometry **79**
Ann M Granchelli, Theodore G Liou, Richard Kanner, Claudio Sorino
- History of Lung Volume Measurement *79*
- Definitions *80*
- Clinical Value of Lung Volume Measurements *81*
- Body Plethysmography *82*
- Helium Dilution *86*
- Multiple-Breath Nitrogen Washout *87*
- Imaging *88*
- Evaluation of the Respiratory Muscle Strength *92*

9. Bronchoprovocation Challenge Test **95**
Claudio Sorino, Diego Bagnasco, Fulvio Braido
- Overview of Bronchoprovocation Challenge Test and Clinical Indications *95*
- Bronchial Hyperresponsiveness *95*
- Specific and Nonspecific Airway Responsiveness *95*
- How to Express Airway Responsiveness *96*
- How to Perform a Bronchoprovocation Challenge Test *97*
- Contraindications and Precautions *97*
- Pharmacologic Challenge Tests *97*
- Exercise Challenge Test *100*
- Cold Air Challenge Test *100*

- Eucapnic Voluntary Hyperpnea *101*
- Antigen Challenge Test *101*

10. Diffusing Capacity or Transfer Factor of the Lung **103**

Riccardo Pistelli, Claudio Sorino

- Pathophysiology of Pulmonary Diffusion *103*
- Alterations of Lung Diffusion Capacity *103*
- Overview of Lung Diffusion Measurement *104*
- Advantages of Using Carbon Monoxide *104*
- Patient Preparation *104*
- Procedure *104*
- Acceptability and Repeatability *105*
- Interpretation of Data *106*

11. Ventilation Homogeneity and Lung Elasticity **108**

Riccardo Pistelli, Claudio Sorino

- Lung Ventilation *108*
- Lung Elasticity: Statics *109*
- Lung Elasticity: Dynamics *110*
- Physiological Methods to Study the Distribution of Ventilation *113*

12. Lung Function Testing in Preschool Children **115**

Stefania La Grutta, Giuliana Ferrante, Enrico Lombardi, Claudia Calogero, Giorgio Piacentini, Giancarlo Tancredi, Caterina Lambiase, Claudio Sorino, Giovanni Viegi

- Overview of Lung Function Testing in Preschool Children *115*
- Interrupter Technique *115*
- Forced Oscillation Technique *116*
- Spirometry in Cooperating Children *117*
- Preschool Spirometry *118*
- Exhaled Nitric Oxide *119*
- Exhaled Breath Condensate *121*
- Static Lung Volumes *122*
- Broncoprovocation Challenge Test *123*

13. Arterial Blood Gas Analysis and Other Tools for the Evaluation of Gas Exchange Efficiency **126**

Claudio Sorino, Angelo Corsico

- Overview of the Measurement of Gas Exchange Efficiency *126*
- Pulse Oximetry *134*
- Transcutaneous Oxygen and Carbon Dioxide Measurement *135*

14. Cardiopulmonary Exercise Testing **136**

Claudio Sorino, Ross Arena, Adriano Di Paco, Daniel Forman

- Overview of Cardiopulmonary Exercise Testing and Main Indications *136*
- Equipment Required *136*
- Pre-Test Recommendations *139*
- Test Protocols *139*
- CPET Procedure *140*
- Key Variables, Normal Values and Significance *143*
- Anaerobic, Lactate, and Ventilatory Tresholds *143*
- Interpretation of Results *146*
- Report Preparation *147*

15. Diagnostic Tests for Sleep-Related Breathing Disorders **153**
Maria Rosaria Bonsignore, Claudio Sorino, Oreste Marrone
- Sleep Versus Wakefulness: What is Different *153*
- Overview of Sleep-Related Breathing Disorders *154*
- Tests for Measuring Excessive Daytime Sleepiness *158*
- How to Study Sleep? *158*
- How to Select the Most Appropriate Diagnostic Procedure? *160*
- Preparation of the Patient for Polygraphy *161*
- Analysis and Interpretative Strategies *161*
- Factors to be Included in a Summary Report *162*
- Diagnostic Criteria for Respiratory Events *165*

Section 3: Diagnostic Imaging

16. Chest Radiograph: Technical Aspects, Normal Findings and Extrapulmonary Structures **171**
Ali Nawaz Khan, Klaus L Irion, Prabhakar Rajiah, Carolyn Allen, Durr-e-Sabih, Koteyar Shyamsunder Radhakrishna, Hamdan Al-Jahdali, Syahminan Suut, Zeid Al-Ani, Claudio Sorino
- Overview *171*
- Notes on Technical Aspects *171*
- Normal Lung and Lung Parenchyma *173*
- Trachea and Central Airways *176*
- Pleura *177*
- Mediastinum *194*
- Chest Wall *196*
- Conclusion *202*

17. Chest Radiograph: Lung Pathological Findings and Main Signs **204**
Ali Nawaz Khan, Klaus L Irion, Prabhakar Rajiah, Carolyn Allen, Durr-e-Sabih, Koteyar Shyamsunder Radhakrishna, Hamdan Al-Jahdali, Syahminan Suut, Zeid Al-Ani, Claudio Sorino
- Overview *204*
- Decreased Pulmonary Density *224*
- Main Signs in Radiology *225*

18. Chest Computed Tomography for the Evaluation of Respiratory Diseases **234**
Maria Bellia, Claudio Sorino, Mario Spatafora, Fabio Cannizzaro, Ali Nawaz Khan, Vincenzo Bellia
- Introduction *234*
- Evolution of CT and Applications to the Respiratory Tract *234*
- Main Indications *238*
- Applications to Lung Cancer *240*
- Applications to Diffuse Parenchymal Lung Diseases *245*
- Pattern of Increased Pulmonary Density *247*
- Pattern of Decreased Pulmonary Density *248*
- Virtual Bronchoscopy *252*

19. High-Resolution Computed Tomography for the Evaluation of Airways Distensibility **254**
Alida Benfante, Robert H Brown, Claudio Sorino, Nicola Scichilone
- Summary: Airway Distension and Deep Inspirations *254*
- Beneficial Effects of Lung Inflation *254*
- Factors Affecting the Beneficial Effects of Lung Inflation *256*
- Role of HRCT In Assessing Airway Distensibility *257*

20. Computed Tomographic Pulmonary Angiography **260**
Johannes Gossner, Claudio Sorino
- Overview on Computed Tomographic Pulmonary Angiography *260*
- Indications and Contraindications *260*
- How the Test is Performed? *261*

21. Conventional Pulmonary Angiography **270**
Filippo Russo, Claudio Sorino, Mario Galli
- Overview of Pulmonary Angiography *270*
- Indications *270*
- Contraindications *274*
- Risks and Possible Complications *274*
- Technique *275*

22. Role of Magnetic Resonance Imaging in the Evaluation of Respiratory Diseases **278**
Miranda Kirby, Harvey O Coxson, Claudio Sorino, Grace Parraga
- Overview and History *278*
- Lung Parenchyma: The Black Hole of MRI *278*
- Is There Added-Value of MRI for Patient Assessment? *280*
- When is Pulmonary MRI the Modality of Choice? *286*
- Summary and Future Directions *288*

23. Lung Ultrasonography **293**
Riccardo Inchingolo, Andrew S Liteplo, Claudio Sorino
- Overview of Lung Ultrasound *293*
- Basic Knowledge of Lung Ultrasonography Technique *293*
- Ultrasound Equipment and Probes *293*
- Imaging of the Chest Wall *294*
- A Lines and B Lines *295*
- Evaluation of Pleural Disease *296*
- Study of Diaphragmatic Kinetics *300*
- Evaluation of Pulmonary Disease *300*
- Ultrasound-Guided Interventional Procedures *304*

24. Single Photon Emission Computed Tomography in the Evaluation of Lung Diseases **308**
Marika Bajc, Claudio Sorino
- Overview of Ventilation/Perfusion SPECT *308*
- V/P SPECT and Pulmonary Embolism *308*
- Basic Principles of Pulmonary Embolism Diagnosis with V/P Spect *309*
- Imaging Protocols *309*
- Reporting Findings *310*
- Role of Ventilation SPECT In Diagnosis of Other Lung Diseases *312*
- V/P SPECT Versus MDCT *313*
- Clinical Use of Hybrid V/P SPECT/Ct *315*
- Conclusions *316*

25. Positron Emission Tomography: Role in Lung Cancer Evaluation and Management **320**
Laura Serafino-Agrusa, Roberta Catania, Claudio Sorino, Mario Spatafora
- Overview *320*
- Role of PET in Diagnosis and Staging of Lung Cancer *321*
- Role of PET in Prognosis of Lung Cancer *323*

- Role of PET in Chemotherapy *324*
- Role of PET in Radiotherapy *325*

Section 4: Invasive Diagnostic Procedures

26. Diagnostic Applications of Flexible Bronchoscopy **331**

Dhruv Joshi, Sergio Agati, Claudio Sorino, Thomas R Gildea

- Background *331*
- Equipment and Advances in Bronchoscopy *331*
- Indications for Diagnostic Bronchoscopy (Box 1) *332*
- Contraindications to Flexible Bronchoscopy (Box 2) *334*
- Technique *335*
- Positioning and Routes of Access *335*
- Preparation *336*
- Sedation *337*
- Anatomy of Airways *338*
- Procedures *340*
- Risks and Complications *342*
- Cleaning and Reprocessing Flexible Bronchoscopes *342*

27. Bronchial Brushing and Biopsy **344**

Debabrata Bandyopadhyay, Thomas R Gildea, Sergio Agati, Claudio Sorino

- Bronchial Brushing *344*
- Endobronchial Biopsy *345*
- Transbronchial Biopsy *347*
- Bronchial Washing *352*

28. Transthoracic Needle Biopsy **354**

Zafar Neyaz, Dilip Kumar MP, Claudio Sorino

- Overview *354*
- Indications and Contraindications *354*
- Biopsy Planning *354*
- Needle Types *355*
- Prebiopsy Preparation and General Biopsy Technique *356*
- Biopsy Technique for Pulmonary, Mediastinal and Pleural Lesions *357*
- Postprocedural Precautions *363*
- Possible Complications *364*

29. Conventional Transbronchial Needle Aspiration **367**

Claudio Sorino, Danai Khemasuwan, Thomas R Gildea, Stefano Gasparini, Atul C Mehta

- Overview of Transbronchial Needle Aspiration and Main Indications *367*
- Planning of C-Tbna and Chest Imaging Study *368*
- Mapping Systems of The Lymph Nodes *368*
- Required Tools *368*
- Technique *370*
- Contraindications and Possible Complications *374*
- Diagnostic Yield of Transbronchial Needle Aspiration *374*
- Endobronchial Needle Aspiration *375*
- Peripheral Transbronchial Needle Aspiration *375*

30. Bronchoalveolar Lavage **378**
Simona Soresi, Claudio Sorino, Keith Meyer
- Overview on Bronchoalveolar Lavage *378*
- General Recommendations *380*
- Possible Complications *380*
- Safety Considerations *380*
- Macroscopic Examination of Bal *381*
- Cytological Examination From Bal *381*
- Microbiology From Bal *383*
- Evolving and Future Uses of Bal for Patient Management and Clinical Research *385*

31. Thoracentesis **388**
Claudio Sorino, Danai Khemasuwan, Anna Rosa Maspero, Atul C Mehta
- Overview of Pleural Effusion and Thoracentesis *388*
- Indications *389*
- Relative Contraindications *389*
- Patient Preparation and Position *389*
- Preprocedure Planning *390*
- How the Test is Performed *391*
- Risks and Possible Complications *392*
- Post-Procedure Care *392*
- Interpretation of Pleural Fluid Analysis *393*

32. Mediastinoscopy **395**
Massimo Guglielmetti, Angelo Maria Calati, Simona Maida, Daniele Trevisan, Claudio Sorino, Roberto Caronno
- Overview of Mediastinoscopy *395*
- Main Indications *395*
- Surgical Technique *395*
- Risks and Possible Complications *397*
- Discussion *398*

33. Video-Assisted Thoracic Surgery as a Diagnostic Tool **400**
Angelo Maria Calati, Massimo Guglielmetti, Claudio Sorino, Roberto Caronno
- Background *400*
- Indications and Contraindications *400*
- Procedure *401*

34. Endobronchial Ultrasound **404**
Sixto Arias, Hans Lee, Ricardo Ortiz, David Feller-Kopman, Lonny Brett Yarmus, Claudio Sorino, Kazuhiro Yasufuku
- Overview of Endobronchial Ultrasound *404*
- Technology *405*
- Indications *406*
- Technique *406*
- Mediastinal and Hilar Lymph Nodes *407*
- Ebus and Lung Cancer *408*
- Possible Complications *409*

Index 413

Chapter 2

Respiratory Examination

Claudio Pedone, Giuseppe Augugliaro, Claudio Sorino

OVERVIEW OF THE SEMEIOTICS OF THE RESPIRATORY SYSTEM

Physical examination of the chest is a crucial element of respiratory system assessment. Together with the medical history, it provides an important aid in determining the correct diagnosis, often before the laboratory and instrumental examinations are available.

Similarly to what is done for other parts of the body, chest examination includes four phases: (1) inspection, (2) palpation (feeling with the hands), (3) percussion (tapping with the fingers), and (4) auscultation (listening). The examination should be carried out in a quiet, well-lit room; no instruments are required but a phonendoscope. A marking pen and a tape measure can help when pathological changes are observed. For every section of the chest examination, right and left findings should be always compared. Natural landmarks and artificial lines are important in order to locate organs within the chest and to document the location of respiratory assessment findings. Most common thoracic landmarks are described in Box 2.1 and shown in Figures 2.1 and 2.2.

Box 2.1: Most common thoracic landmarks.

Natural landmarks

- *Jugular (or suprasternal) notch*: Between the clavicles, above the manubrium sterni
- *Intercostal spaces*: The space between two adjacent ribs; they are identified starting from the angle of Louis (the sternal angle, formed by the conjunction of the sternum and the manubrium sterni) that corresponds to the second rib
- *Infraclavicular fossae*: It is a triangular depression below the clavicle, at the angle formed by the great pectoral and the deltoid muscle
- *Supraclavicular fossae*: The depression between the clavicle and the anterior margin of the trapezius muscles
- *Suprascapular region*: Above the upper margin of the scapula (or the acromion), between the posterior midline and the lateral margin of the trapezius muscle
- *Scapular region*: The area over the scapula (between the second and the seventh rib), it is divided in supraspinous and infraspinous regions
- *Interscapular region*: The region between the medial borders of the two scapulae

Artificial vertical lines

- *Midsternal line (or anterior middle line)*: From the jugular notch to the xiphoid process (also known as "anterior midline")
- *Marginosternal (or lateral sternal) lines*: Parallel to the midsternal line, run along the vertical edges margins of the sternum
- *Midclavicular lines*: Parallel to the midsternal line, passing from the clavicular midpoint
- *Anterior axillary lines*: Parallel to the midsternal line, passing from the anterior axillary fold
- *Middle axillary line*: Parallel to the midsternal line, passing from the uppermost point of the axillary pit
- *Posterior axillary line*: Parallel to the midsternal line, passing from the posterior axillary fold
- *Scapular lines*: Running down the inferior angle of the scapulae as the arm is in the neutral position, parallel to the spine
- *Paravertebral lines*: Vertical line parallel to the spine running about 1-inch medially to the scapular lines, over the tip of the transverse processes of the vertebrae
- *Midspinal line*: Runs vertically through the posterior spinal processes

JAYPEE BROTHERS

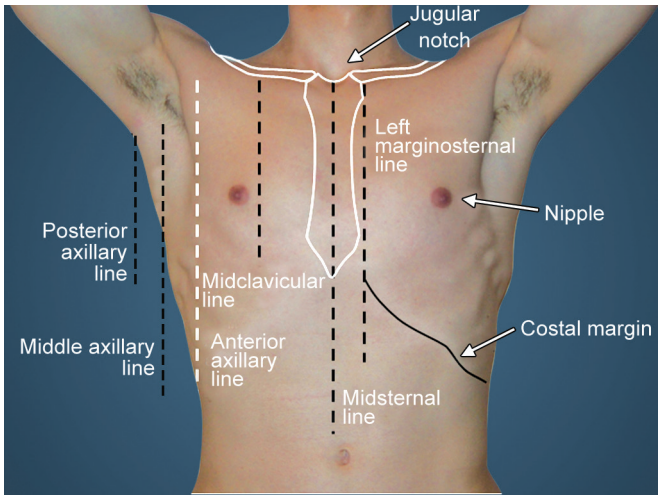

Fig. 2.1: Main landmarks on the anterior chest.

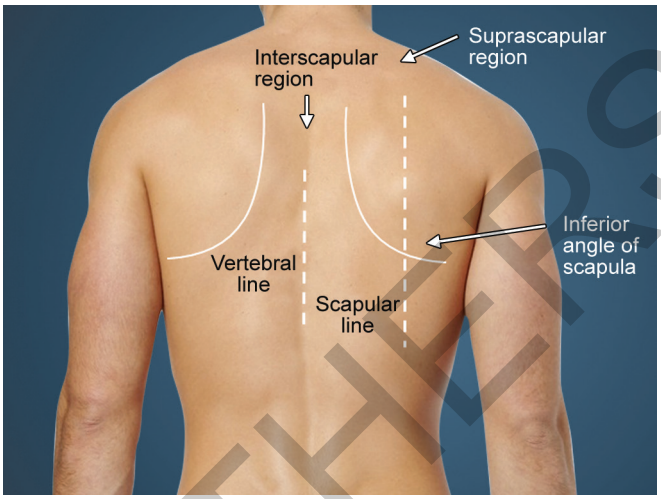

Fig. 2.2: Main landmarks on the posterior chest.

On the chest surface, both pulmonary apices project in the supraclavicular fossa. The upper lobes project mainly on the anterior surface, as well as the middle lobe, while the basal lobes project on the posterior surface. On the anterior thoracic surface, the right upper lobe projects in the region between the clavicula and the fourth intercostal space, while the middle lobe projects between the fourth intercostal space and the diaphragm, that is about at the sixth intercostal space on the parasternal line and at the eighth intercostal space on the middle axillary line. The upper left lobe projects anteriorly on the whole thoracic wall. The posterior projection of the two lungs is similar: the upper lobes project in the right interscapular region above the third thoracic vertebra, while the lower lobes occupy the space from the third thoracic vertebra to the diaphragm, at the ninth intercostal space. Figures 2.3A to D shows the projection of the lungs on anterior, posterior and lateral chest surface.

CHEST INSPECTION

Inspection consists in a methodical, accurate and complete observation of the patient.

In a patient with suspected respiratory disease, it should not be limited to chest, whereas it should include the evaluation of some general aspects, such as the appearance or expression of the face of the patient ("facies"), the preferred posture, the use of accessory respiratory muscles, the presence of nasal flaring, cyanosis.

At inspection, the general *shape* and *symmetry* of the thorax must be evaluated. The patient should be sited, if possible without support, unclothed to the waist. Normally, the ratio between the sagittal diameter (also known as anteroposterior diameter) and coronal (or transverse) diameter of the thorax ranges between 0.5 and 0.7. An increase in the ratio is seen in people with *hyperkyphosis* (exaggerated anterior curvature of the thoracic spine due to posture or vertebral fractures). It is also observed in subjects with *barrel chest*, where the ribs are horizontal, and the increased anteroposterior diameter results in a cylindrical shape of the thorax. Barrel chest can be a feature of severe emphysema, but is also common in elderly people with weight loss and increased thoracic kyphosis (Fig. 2.4).

Asymmetry of the thorax is frequently due to vertebral deformities (scoliosis) that cause an enlargement of the side of vertebral convexity with lung hyperexpansion, and a reduction in volume of the contralateral side, with consensual reduction of lung volume. Other thoracic deformities include:

Pectus carinatum (pigeon chest): It is a deformity characterized by a protrusion of the distal portion of the sternum, with increased anteroposterior diameter and reduction of the vertical diameter. The ribs adjacent to the protruding chest are depressed. This condition can be congenital, but is also seen in rachitic patients.

Pectus excavatum (funnel chest): It is a condition caused by the abnormal growth of ribs and sternum, causing a concavity most evident at the distal sternum. It is the most common congenital chest wall abnormality.

Flail chest: It is characterized by a paradoxical inward movement of a section of the thorax during inspiration and

JAYPEE BROTHERS

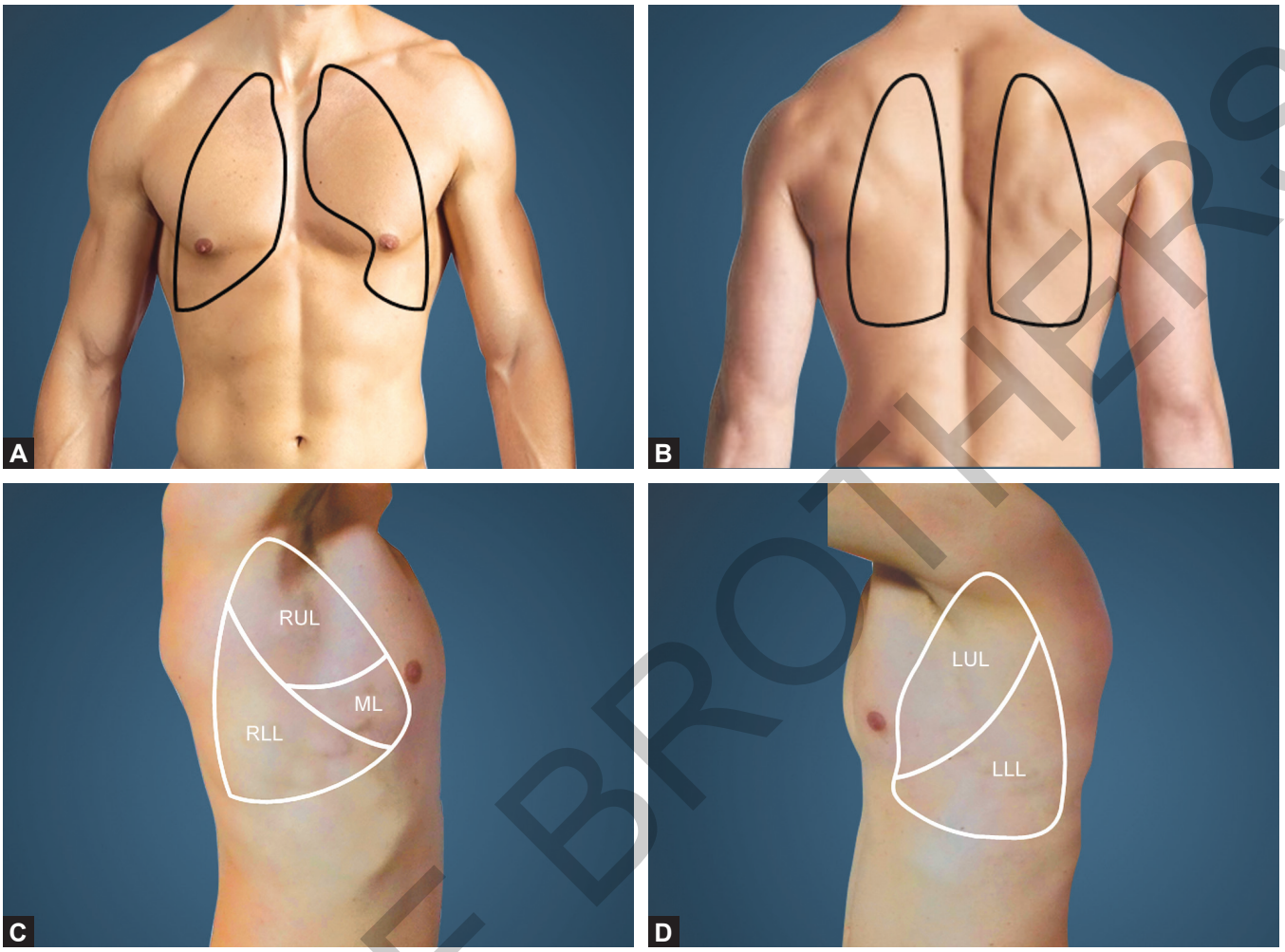

Figs. 2.3A to D: Projection of the lungs on (A) anterior, (B) posterior, and (C and D) lateral chest surfaces. (RUL: Right upper lobe; RLL: Right lower lobe; ML: Middle lobe; LUL: Left upper lobe; LLL: Left lower lobe).

outward movement during expiration. It is due to severe blunt trauma that causes both posterior and anterior fractures of three or more ribs.

Bulging or retraction of the intercostal spaces should be recorded. Uniform bulging of one side of the thorax can be seen in patients with massive pleural effusion, pneumothorax, or severe emphysema. Uniform retraction of one side of the thorax may be due to fibrothorax, atelectasis, or may be the consequence of demolitive lung surgery. Retraction of the intercostal spaces during inspiration can be observed in patients with obstruction to the free inward flux of air.

The *respiratory frequency* should always be recorded by observing the chest movements. It is of fundamental importance to evaluate the respiratory dynamics. The normal respiratory rate is 10–14 per minute, with slightly higher rates in women and infants. The use of accessory muscles should be noted. During normal breathing, muscular effort is required only during inspiration to expand the rib cage while expiration is passive due to the elastic recoil of the lungs. The most important inspiratory muscle is the diaphragm that moves downward during inspiration, causing an outward movement of the abdominal wall that is best seen in men compared to women. An increased length of the expiratory phase with contraction of accessory expiratory muscles (internal intercostal muscles, abdominal wall muscles) may be seen in patients with bronchospasm, while the use of accessory inspiratory muscles (sternocleidomastoid, scalene muscles) may be due to obstruction of the extrathoracic airways or to increased stiffness of the thorax or of the lung (pulmonary fibrosis). An inward motion of the abdominal wall

JAYPEE BROTHERS

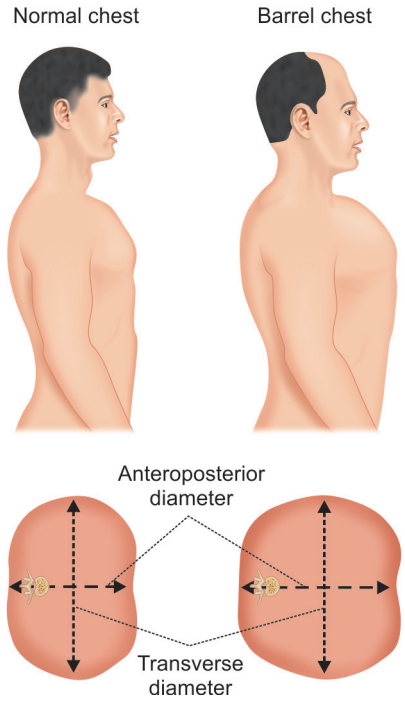

Fig. 2.4: Anteroposterior and transverse diameters in normal and barrel chests.

during inspiration indicates a severe dysfunction of the diaphragm that moves passively upward due to decreased thoracic pressure.

Abnormalities of the respiratory rhythm and pattern should be considered.

Cheyne-Stokes respiration is characterized by a progressive increase in tidal volume, followed by a progressive decrease and an apneic phase, and indicates an increased central hypercapnic ventilatory responsiveness. In *Kussmaul respiration*, seen in severe metabolic acidosis, the respiratory rate decreases with deep respiratory acts. *Biot's respiration* is characterized by irregular breathing with prolonged phases of apnea. It is seen in patients with increased intracranial pressure or lesion of the brain stem.

Asymmetry of thoracic movements during respiration can be due to both pleural and pulmonary diseases. Pleural effusions or pneumothorax can cause a reduction in the movements of the affected size. Complete pneumothorax or massive atelectasis can also cause changes in the size of the affected hemithorax.

Inspection of the thorax should include the observation of skin abnormalities such as scars or eruptions (e.g. vesicular eruption caused by *herpes zoster virus*). The superficial thoracic veins are normally scarcely visible, but may become evident when the vena cava (either inferior or superior) is occluded and collateral circulation is activated. The blood flow in thoracic varicose veins is downward when the superior vena cava is occluded and upward when the inferior vena cava is occluded. The causes of the occlusion of the superior vena cava include thrombosis, mediastinal masses, pericarditis and thoracic aortic aneurisms.

Inspection of the neck should complement the inspection of the thorax. As mentioned above, activation the sternocleidomastoid and scalene muscles can be seen when ventilation is markedly increased, and can also be seen in patients with severe chronic obstructive pulmonary disease (COPD). Distension of the neck veins can be seen in superior vena cava syndrome, in which it is associated with edema of the neck, shoulders and face. It can also be due to increased right atrium pressure in patients with heart failure.

A thorough inspection must also include the evaluation of extrathoracic manifestations of pulmonary diseases. Cyanosis is the appearance of a bluish discoloration of the skin or mucous membranes. It is due to excessive amounts of deoxygenated hemoglobin (*deoxyhemoglobin*) in the blood of the superficial capillaries and venules that become blue-colored. Usually cyanosis is apparent when deoxyhemoglobin is 5 g/dL or greater.

Since the presence of cyanosis depends on the absolute quantity of deoxyhemoglobin, the bluish color is more readily apparent in subjects with high hemoglobin counts than in those with anemia.

In some patients, a bluish tinge to the skin can result from increased amounts of methemoglobin or sulfhemoglobin.

We can distinguish two main forms of cyanosis: (1) central and (2) peripheral.

Central cyanosis is due to desaturation of central arterial blood resulting from cardiac and respiratory disorders that do not allow the venous blood to be oxygenated adequately before flowing into the systemic circulation (shunt effect).

Peripheral cyanosis is caused by decreased local circulation and increased extraction of oxygen in the peripheral tissues. It may occur in conditions associated with peripheral vasoconstriction and stasis of blood in the extremities, which are usually cold (e.g. congestive heart failure, circulatory shock, exposure to cold temperatures, abnormalities of the peripheral circulation). Peripheral cyanosis is often most evident in nail beds, while the mucous membranes of the oral cavity are usually spared. It may resolve just with warming of the extremity.

JAYPEE BROTHERS

Pseudocyanosis, on the contrary, refers to a permanent bluish discoloration caused by deposition of blue pigments in the skin.

Nail clubbing is characterized by enlargement of the distal segment of the fingers, with decreased (< 165°) of the angle between the made at the meeting of the nail fold and the nail plate. It can be associated with different lung diseases: lung cancer, bronchiectasis, mesothelioma, lung abscesses. *Peripheral edema* is commonly associated with reduced oxygen saturation and therefore can be seen in patients with respiratory failure, regardless of the coexistence of heart failure.

A *plethoric facies* (i.e. a face too red) may be the expression of elevated red blood cell count (polycythemia), which in turn may be secondary to a chronic respiratory failure. Polycythemia is considered when the hematocrit (HCT) is greater than 48% in women and 52% in men, or when the hemoglobin level is greater than 16.5 g/dL in women or greater than 18.5 g/dL in men.

It can be divided into two categories: (1) primary polycythemia, due to inherent problems in the process of red blood cell production and (2) secondary polycythemia that generally occurs as a response to other factors or underlying conditions promoting red blood cell production.

An example of the latter condition is the upregulation in erythropoietin secretion as a response to prolonged low oxygen levels in the blood (hypoxia).

CHEST PALPATION

The anterior surface of the chest is palpated by placing the palm of both arms flat on the chest wall with the thumbs touching on the midline while the patient is taking deep breaths. The hands are placed first at the angle of Louis, then on the fourth or fifth intercostal space, and finally at the lower costal margin. The posterior chest surface can also be palpated with the patient sitting, by putting the thumbs on the paravertebral lines and the other fingers each on a different intercostal space (Fig. 2.5A). The expansion of the apices can be appreciated by putting the palm of the hand flat on the supraclavicular fossa. The position of the trachea can be determined by placing the thumb and index finger on the lateral aspects of the trachea over the jugular notch. Lateral deviation of the trachea can be caused by mediastinal shift.

During anterior palpation, attention should be paid to the cardiac impulse, usually palpable at the anterior axillary line, at fourth or fifth intercostal space. Although it is not palpable in a large proportion of normal people, lack a palpable apex beat may be a sign of pulmonary emphysema. Palpation of the thorax also is important for the detection of enlarged axillary or supraclavicular lymph nodes. It can also disclose the presence of subcutaneous emphysema.

Most of the alteration of respiration dynamic suspected at inspection can be confirmed by palpation. Attention should be paid to the amplitude and symmetry of the movements, and to the presence of retraction of the costal margin at the end of inspiration, that indicates severe air trapping. Palpation is also of aid in detecting contractions of auxiliary respiratory muscles, by putting the hand on the sternocleidomastoid or on the abdominal wall, and to evaluate the presence of thoracoabdominal dyssynchrony, by putting on hand in the midline on the middle chest and the other on the upper abdomen. During this phase of the physical examination, an end-inspiratory retraction of the costal margin can be appreciated (*Hoover's sign*), indicating pulmonary hyperinflation.

While the subject is speaking, the lung parenchyma and the chest wall normally transmit a palpable vibration known as tactile fremitus. It should be assessed by placing the ulnar aspect of both hands firmly on the posterior chest wall while the patient says the word "ninety-nine". For comparison, both sides should be palpated simultaneously and symmetrically, using one hand quick alternating between the two sides (Fig. 2.5B). The vibration is best appreciated in the region close to the tracheal bifurcation (e.g. the interscapulovertebral region) and in people with low-pitched voice. The tactile fremitus is reduced when an obstruction of the airways block its transmission to the chest wall (e.g. endobronchial neoplasm) or lung elasticity is reduced (e.g. emphysema, pulmonary edema). Tactile fremitus is also reduced or absent in the area over a pleural effusion, but the lung parenchyma above the superior margin of the effusion may be compressed and hence transmits a reinforced vibration. Another cause of reduction or absence of tactile fremitus is pneumothorax. Tactile fremitus is better transmitted by consolidated lung parenchyma, provided that the bronchi are patent, and it is also reinforced in the presence of bronchiectasis or lung excavations.

Palpation of the thorax can also disclose enlarged lymph nodes, especially those of the supraclavicular region and of the axillary region. *Supraclavicular lymph nodes* are best appreciated at the insertion of the sternocleidomastoid on the clavicula. Lymph nodes of the right supraclavicular fossa may be enlarged in patients with pulmonary or intrathoracic diseases; while, because

JAYPEE BROTHERS



Figs. 2.5A to C: (A) Posterior palpation; (B) Tactile fremitus; (C) Percussion.

the subdiaphragmatic lymphatic drainage enters the venous circulation in the left subclavian vein, nodes in the left supraclavicular fossa may also be enlarged in patients with metastatic neoplasms of the stomach, gallbladder, kidney, ovarium, or testicle (*Virchow-Troisier's lymph node*). Lymph nodes of this region can also be enlarged in patients with tubercular peritonitis. Palpation of these lymph nodes should be performed while the patient is sitting in a neutral position; in particular the head should not be extended or rotated let the gland is compressed by the overlying skin. The characteristics (size, firmness, mobility) of the lymph node should be evaluated by compressing it between the fingers or against the underlying solid structure (e.g. bone), if present.

Axillary lymph nodes are divided into five groups. The lateral axillary nodes receive lymph from the arm and also from the posterior axillary group that drains the posterior chest wall. Anterior axillary lymph nodes drain lymph from the anterior chest wall and the breast. All axillary nodes eventually drain into the central and then apical (subclavian) groups that can be enlarged in pulmonary or mediastinal diseases. Palpation of the axillary lymph nodes is performed while the patient is sitting, with the arm abducted between 45° and 90°.

Moreover, chest palpation can also disclose the presence of a *crepitus*, a crackling sensation, can be heard and palpated under the skin during palpation. It indicates air in the subcutaneous tissue from rupture somewhere in the respiratory system or by infection with a gas-producing organism. Subcutaneous emphysema usually affects the neck or thorax, but it may also be found in the supraclavicular regions, abdominal wall, perineal region, or upper or lower limbs. In every circumstance, the *crepitus* requires attention.

CHEST PERCUSSION

There are two types of chest percussion: (1) direct and (2) indirect. "Direct" percussion of the thorax is usually used to explore the apexes and is performed by rapping with the tip of the middle finger on the middle third of the clavicles. "Indirect" percussion is performed rapping the middle finger of the dominant hand (plexor) on the distal interphalangeal joint of the index or middle finger of the opposite hand (pleximeter) that is firmly put flat on the region of interest (Fig. 2.5C). The pleximeter should not be placed directly on the ribs but rather on the intercostal spaces; the plexor should be promptly removed from the pleximeter to allow the propagation of the sound. During this phase of physical examination, the patient should be sitting with the arms crossed and the hands on the opposite shoulder, in order to move the scapulae laterally and clear as much as possible the region over the apexes. The percussion of the posterior thorax should begin in the region between the scapulae and the spine, proceeding from the top downward. The normal lung parenchyma produces a "resonant" sound that is a relatively loud and low pitched. It should be distinguished from other sounds such as the dull sound (normally heard percussing the area over the liver) or the hyperresonant sound that is louder and with a lower pitch compared to the resonant sound. Since the lung is contiguous with solid organs (heart, liver, spleen), it is possible to identify the borders of the lung by examining the changes in the sound elicited by percussion (*topographic percussion*).

The pulmonary apices can be delimited by identifying the Kronig's area: putting the pleximeter finger perpendicular to the superior border of the trapezius muscle and on the scapular line, and performing the percussion moving both medially and laterally, an area of

JAYPEE BROTHERS

resonant sound between two areas of dull sound caused by the muscles can be appreciated. It is usually 4–5 cm in width. The anterior pulmonary border can be delimited by following the resonant sound produced by a light percussion over the anterior chest wall. The percussion should begin on the midclavicular line at the second intercostal space and then proceeding medially and downward. On the horizontal line, the resonant sound is usually present up to the parasternal line. On the vertical line, on the right, the resonant sound is usually appreciated from the second to the sixth intercostal space, then the presence of the liver cause the sound to become more dull. On the left, the resonant sound is appreciated from the second to the fourth intercostal space, then the presence of the heart cause the sound to become more dull. Hence, the border of the lung can be followed moving the pleximeter laterally and then again downward to delimit the lingula. The area of resonant sound thus delimited becomes smaller in patients with cardiomegaly, mediastinal masses, or pulmonary sclerosis, while becomes larger in patients with pulmonary emphysema.

The inferior border of the lung is identified by light percussion along the vertical lines. Normally, the border between the resonant sound and the area of dullness due to surrounding organs is at the sixth intercostal space on the hemidiaphragm, on the seventy or eight intercostal space on the middle axillary line and on the tenth intercostal space on the paravertebral lines. The *Traube's space* is an area of hyperresonant sound due to the gastric bubble that is delimited by the sixth rib superiorly, the left costal margin inferiorly and the anterior axillary line laterally. Loss of this area of hyperresonance is seen in left pleural effusions.

A dull sound is appreciated in conditions that cause a reduction of the air content of the lung (e.g. atelectasis), or when air is substituted with fluid or solid tissue (e.g. flogosis, neoplasm). Dullness can also be present when there is liquid between the lung and the chest wall, as is the case in pleural effusions. Pleural effusions are typically appreciated at the base of the lungs; when the liquid is rich in protein (exudate), the upper margin of the area of dullness is convex with the highest point on the posterior axillary line. Because of a contralateral shift of the mediastinum caused by the effusion, a triangle of dullness can be present on the other side, delimited by the spine and the diaphragm. Diseases that increase the air content of the lung, such as pneumothorax, emphysema or excavations, cause the sound to become hyperresonant. See Table 2.1 for a list of causes of changes in pulmonary resonance.

Table 2.1: Causes of abnormal findings at percussion.

Dullness	Pleural effusion
	Pneumonia
	Atelectasis
	Neoplasm
	Marked pleural thickening
Hyperresonance	Pneumothorax
	Cavitation (e.g. tuberculosis, abscesses)
	Pulmonary emphysema

Percussion is fundamental to evaluate diaphragmatic mobility. The diaphragm is usually higher on the right than on the left because it sits over the bulk of the liver. In order to measure diaphragmatic excursion, the patient should take a deep breath and hold it. The percussion should be done along the scapular line until the lower limit of lungs, a point marked by a change in note from resonance to dullness. This point could be marked with a skin pencil at the scapular line. Now the patient is allowed to breathe, the percussion is repeated. The whole procedure could be repeated on the other side. The distance in centimeters between the marks on each side is recorded. Normally, the diaphragm shifts about 3–5 cm downward during inspiration. When percussion is performed over the posterior thoracic wall, an area of "relative" dullness can be appreciated where the lung parenchyma overlaps the liver or the spleen, about at the eight intercostal space, and of dullness two intercostal spaces below that line, because there is no more lung parenchyma between the chest wall and the solid organs. During maximal inspiration, the line between the resonant sound and the relative dullness shifts downward of about 2 cm. Causes of reduction of diaphragmatic movement are:

- Pulmonary fibrosis, in which the fibrotic lung parenchyma attracts the diaphragm, with an upward shift of the dullness line and loss or reduction of change in the dullness area due to reduced lung expansion
- Pulmonary emphysema, with downward shift of the diaphragm due to pulmonary hyperinflation and loss or reduction of change in the dullness area
- Ascites, liver or spleen enlargement, abdominal masses, subphrenic abscesses cause an upward shift of the diaphragm
- Diaphragmatic paralysis, with asymmetric upward shift of the affected hemidiaphragm.

Suspected abnormalities of the diaphragmatic position should be confirmed by a chest X-ray, while diaphragmatic mobility can be studied by ultrasonography.

JAYPEE BROTHERS

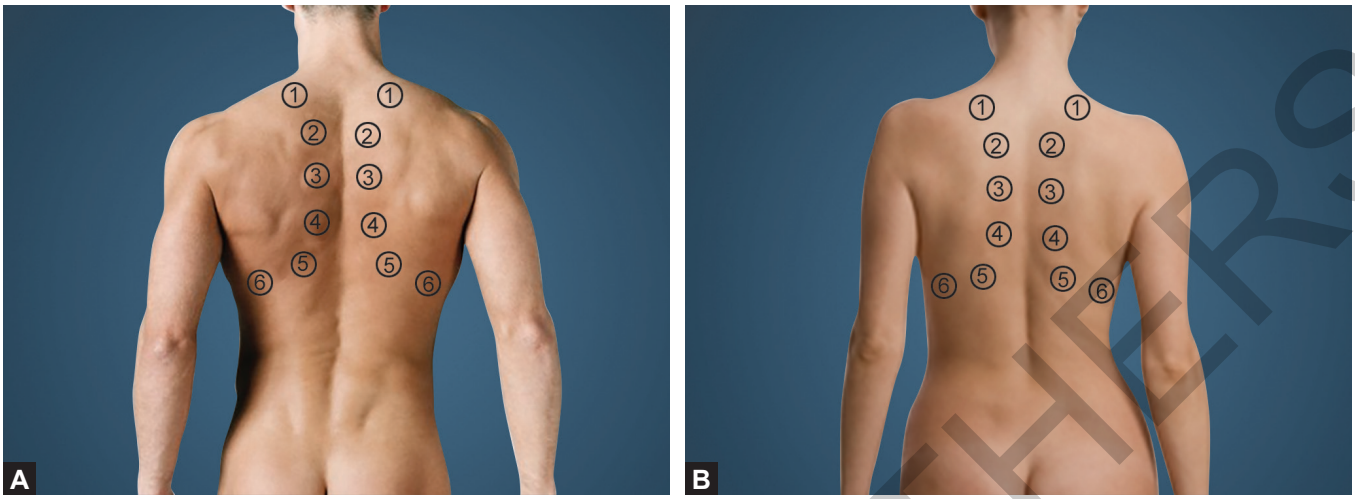

Figs. 2.6A and B: Sites of posterior chest auscultation.

CHEST AUSCULTATION

Auscultation provides information on the airways and the lung parenchyma. It can be performed either with the membrane or the bell of the stethoscope; sounds with higher frequency are best heard with the former, sound with lower frequency with the latter. During auscultation, the patient should be breathing deeply with the mouth open, in order to increase the flux of air in the airways. When the individual breath sound is being evaluated, there should be no movement of patient or stethoscope except for the respiratory excursion. Even if most of the pathological findings are usually found at the auscultation of patient's posterior chest walls (Figs. 2.6A and B), the auscultation of anterior chest is also recommended during physical examination.

Normally, the lung parenchyma produces a *vesicular murmur* sound that is best heard during inspiration, while the bronchi produce a louder, higher pitched sound that is typically heard over the trachea. The bronchial sound is not normally heard elsewhere. The intensity of the vesicular sound is proportional to the airflow in the region being examined, thus it is louder at the bases than at the upper lobes. A reduction or abolition of the vesicular sound indicates a consolidation of the lung parenchyma due to infection or neoplasm, or the presence of air (e.g. pneumothorax) or fluid (e.g. pleural effusions) between the lung and the thoracic wall. In these situations, the bronchial sound can usually be heard over the affected area. In people with reduced alveolar ventilation without alveolar consolidation, a reduced vesicular sound is heard along with the bronchial sound, resulting in what is sometimes referred to as *bronchovesicular* sound. This sound can also be heard at the apex of the right lung, where the alveolar component is normally minimal.

Vocal resonance is evaluated in the same way as the tactile fremitus is, by asking the patient to say the word "ninety-nine". Normally, the word is less loud and clear when heard through the stethoscope on the chest wall. In the presence of parenchymal consolidation without bronchial obstruction, vocal resonance is increased in both loudness and clarity (*bronchophony*). In some cases, usually when the consolidation is accompanied by a small pleural effusion, the vocal resonance is not only increased, but also has a "bleating" or nasal quality, with the vowel "E" heard as "A" (*egophony*).

During auscultation, additional sounds can be appreciated (Table 2.2):

Rhonchi: Low-pitched sounds that resemble snoring. They are usually caused by thick exudate in the larger bronchi and are typically heard in patients with inflamed bronchial walls (e.g. acute or chronic bronchitis).

Crackles: They are best heard during inspiration and occur when fluid is present in the airways. The crackles are fine when the air opens alveoli that are filled with fluid, e.g. in the early and final phases of pneumonia, and in pulmonary edema. In this latter case, crackles are first present at the basis because of gravity, then they spread to the upper pulmonary fields. Fine crackles with a characteristic "Velcro" sound are present in patients with interstitial

JAYPEE BROTHERS

Table 2.2: Causes of adventitious pulmonary sounds.

Rhonchi	Acute or chronic inflammation of the airways
Crackles	Acute pulmonary edema
	Heart failure
	Pneumonia (only at onset or during resolution)
	Pulmonary fibrosis ("Velcro" sounds)
Wheezes	Bronchospasm (asthma, exacerbated chronic obstructive pulmonary disease, acute bronchitis)
	Acute pulmonary edema ("cardiac asthma")
Stridor	Laryngeal stenosis (inflammation, neoplasm, foreign body)
	Tracheal stenosis (flogosis, neoplasm, foreign body, scars, tracheomalacia)
Pleural rubs	Pleuritis
	Pericarditis

lung disease. In such cases, idiopathic pulmonary fibrosis should be considered. When the sound originates from the airways, it becomes coarser as the size of the affected airways increases.

Wheezes: High-pitched sounds best heard during expiration that are caused by the passage of air through narrowed airways, as is typical during asthma attacks or exacerbated chronic bronchitis.

Stridor: it is similar to wheezes in quality, but tends to be louder and is usually heard during inspiration. It is often associated with the use of accessory inspiratory muscles and intercostal retraction. It is often due to laryngeal stenosis caused by foreign bodies, laryngeal edema or spasm, croup, or neoplasm. It can also be caused by tracheal stenosis, either fixed (e.g. scars, neoplasm, goiter) or dyna mic (tracheomalacia).

Pleural rubs: the sound is similar to the rubbing of leather, and is due to the friction between the inflamed and roughened visceral and parietal pleurae. Pleural rubs are present during both inspiration and expiration, and are synchronous with respiration. Rubs that are not synchronous with respiration and that are present also during apnea are due to inflammation of pericardial membranes.

BIBLIOGRAPHY AND FURTHER READING

1. Cottin V, Cordier JF. Velcro crackles: the key for early diagnosis of idiopathic pulmonary fibrosis? Eur Respir J. 2012;40:519-21.
2. Dalmay F, Antonini MT, Marquet P, et al. Acoustic properties of the normal chest. Eur Respir J. 1995;8:1761-9.
3. Meslier N, Charbonneau G, Racineux JL. Wheezes. Eur Respir J. 1995;8:1942-8.
4. Pasterkamp H, Brand PLP, Everard M, et al. Towards the standardisation of lung sound nomenclature. Eur Respir J. 2016;47:724-32
5. Piirilä P, Sovijärvi AR. Crackles: recording analysis and clinical significance. Eur Respir J. 1995;8:2139-48.
6. Simpson H. Respiratory assessment. Br J Nurs. 2006 May 11-24;15(9):484-8.
7. Sovijärvi AR, Dalmasso F, Vanderschoot J, et al. Definition of terms for applications of respiratory sounds. Eur Respir Rev. 2000;10:597-610.

JAYPEE BROTHERS

for detailed information on medicine books, visit our website **www.jaypeebrothers.com,** for detailed information on medicine books, visit our webs

Diagnostic Evaluation of the RESPIRATORY SYSTEM

The book *Diagnostic Evaluation of the Respiratory System* focuses on the methods available to study the respiratory system. It is a useful and practical tool that allows to understand the respiratory signs and symptoms, to know which tests are needed to diagnose a respiratory disease, and how to interpret the results of each examination.

This book has four major sections: 1. Respiratory System Assessment, 2. Evaluation of Respiratory Function, 3. Diagnostic Imaging, and 4. Invasive Diagnostic Procedures.

It has a high academic level and is addressed to physicians (specialists in respiratory diseases and internal medicine), general practitioners and medical students.



Claudio Sorino MD PhD is Physician, Specialist in Respiratory Disease, and Doctor of Philosophy in Experimental and Clinical Pulmonology.

He is Associate Medical Director of the Respiratory Pathophysiology Unit, Department of Pulmonary and Critical Care Medicine at S Anna Hospital, Como, Italy. Dr Claudio is also Assistant Professor at Biomedical Department of Internal and Specialistic Medicine, Cardiorespiratory Section, University of Palermo, Italy, and Adjunct Professor of Epidemiology and Biostatistics at the University of Arizona, Tucson, USA.

Dr Sorino is author of numerous scientific publications in international journals and book chapters in the field of Respiratory Medicine. His primary research interests include lung pathophysiology, chronic obstructive pulmonary disease (COPD), asthma, smoking-related diseases, and bronchial endoscopy.

Available at all medical bookstores
or buy online at www.jaypeebrothers.com

JAYPEE BROTHERS
Medical Publishers (P) Ltd.
www.jaypeebrothers.com

Join us on facebook.com/JaypeeMedicalPublishers

Shelving Recommendations
PULMONOLOGY
INTERNAL MEDICINE

ISBN 978-93-86056-00-9