ebrothers.com, for detailed information on pathology books, visit our website www.jaypeebrothers.com, for detailed information on pathology books

SOFT TISSUE AND BONE PATHOLOGY

A Question and Answer Based Review

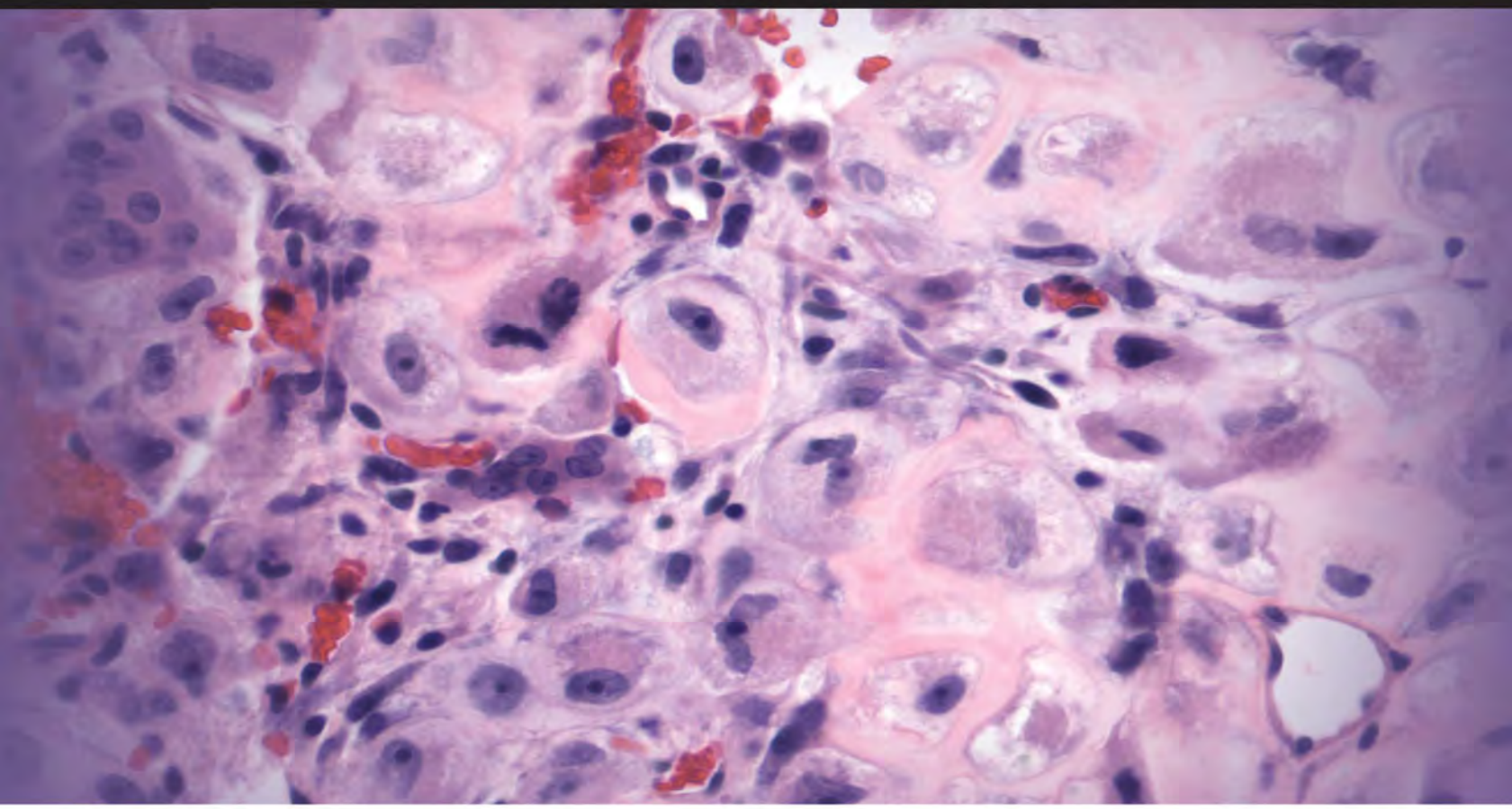

Agedi Boto
Jose Costa

JAYPEE

Contents

1. Monotonous Spindle Cell Lesions: Benign, Malignant and Pseudosarcomatous 1–32
2. Pleomorphic Lesions 33–51
3. Benign Entities 52–61
4. Lesions with a Prominent Vascular Component 62–76
5. Lesions with a Prominent Myxoid Component 77–88
6. Lesions with Epithelioid Cells or Abundant Vacuolated/Amphophilic/Eosinophilic Cytoplasm 89–106
7. Lytic and Cystic Lesions of Bones and Joints 107–116
8. Small Round Blue Cell Tumors 117–126
9. Joint and Bone Lesions with Giant Cells 127–132
10. Lesions Forming Bone and Cartilage 133–151

Index 153–154

CHAPTER 2

Pleomorphic Lesions

1. A 60-year-old female has a left infrascapular cyst. What is the correct diagnosis?

(a) Giant cell tumor of soft parts
(b) Elastofibroma
(c) Giant cell fibroblastoma
(d) Chemotherapy atypia
(e) Angiosarcoma

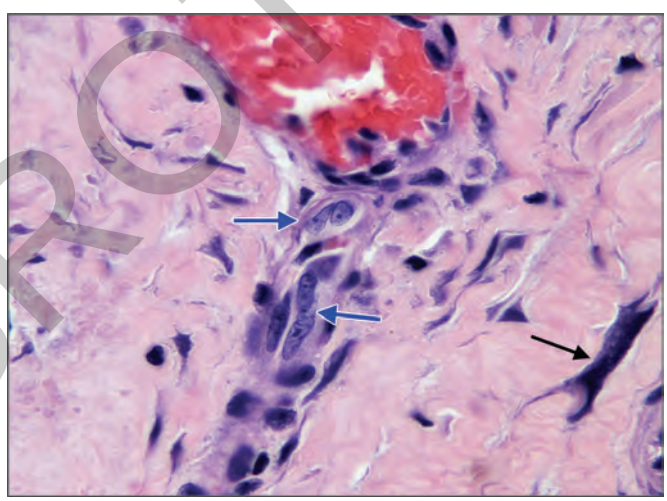

2. A 55-year-old man has this 8 cm retroperitoneal mass. What karyotypic changes are most likely present?

(a) Ring chromosomes
(b) Giant marker chromosomes
(c) Complex genetic changes
(d) No chromosomal changes
(e) Chromosome 16q aberrations

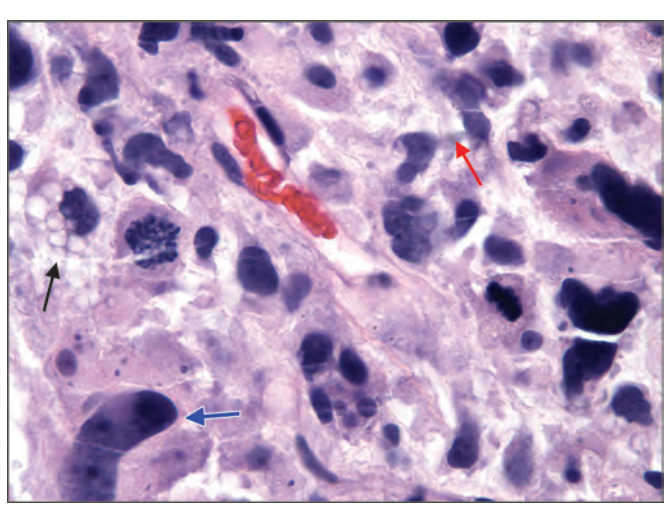

JAYPEE BROTHERS

3. Which of the following stains will reliably highlight this tumor?

(a) EMA
(b) S-100
(c) Pancytokeratin
(d) CD34
(e) None of the markers listed

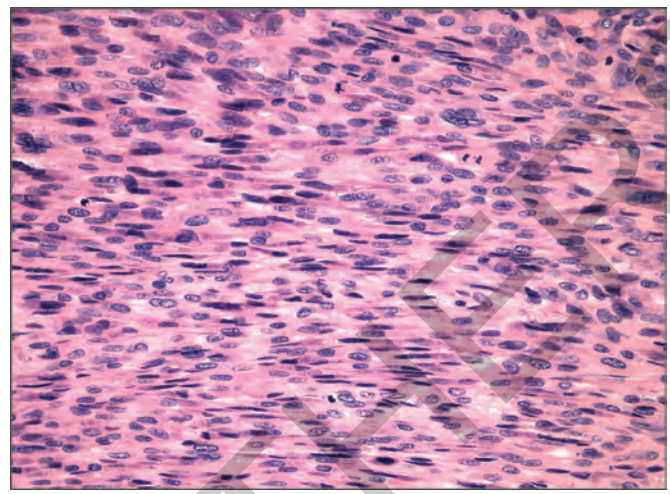

4. A 58-year-old female has a 20 cm retroperitoneal mass. What is the most correct diagnosis?

(a) Osteosarcoma
(b) Chondrosarcoma
(c) Dedifferentiated liposarcoma
(d) Rhabdomyosarcoma
(e) Leiomyosarcoma

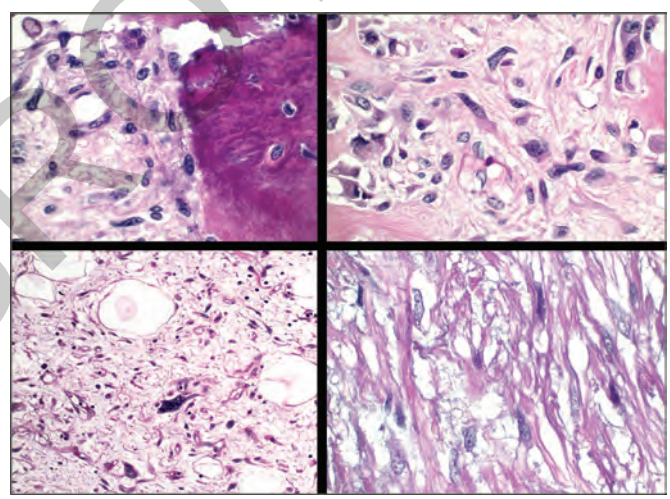

5. Given the histology on the right of this left thigh lesion, what stain would support the diagnostic process?

(a) CD34
(b) Actin
(c) Desmin
(d) S-100
(e) Keratin

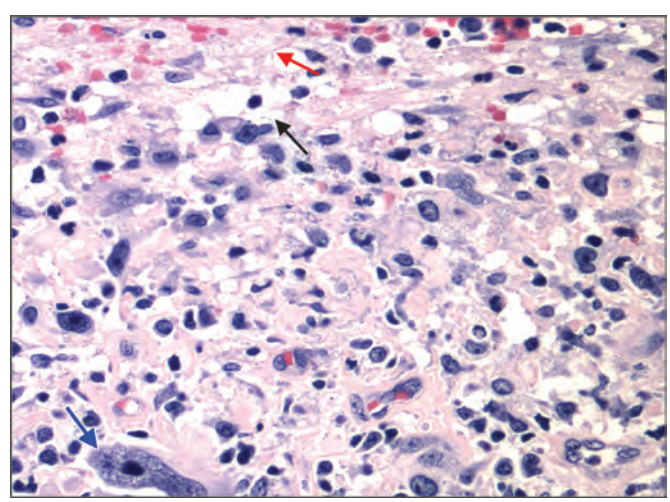

JAYPEE BROTHERS

6. An 87-year-old sun-damaged man with a history of squamous cell carcinoma of the scalp for which he was irradiated presents with a scalp lesion. What is the correct diagnosis?

(a) Squamous cell carcinoma
(b) Basal cell carcinoma
(c) Atypical fibroxanthoma
(d) Pleomorphic liposarcoma
(e) Hodgkin's lymphoma

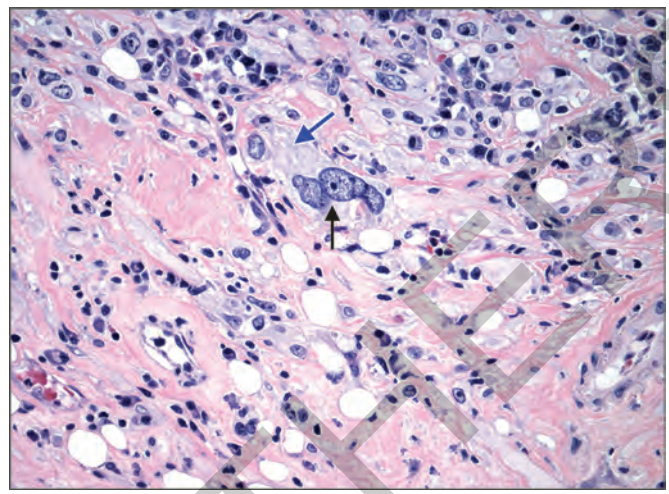

7. A 70-year-old female has a 2.8 cm left calf mass that "just showed up one day". What is the correct diagnosis?

(a) Pleomorphic liposarcoma
(b) Well-differentiated liposarcoma
(c) Undifferentiated pleomorphic sarcoma
(d) Dedifferentiated liposarcoma
(e) Pleomorphic lipoma

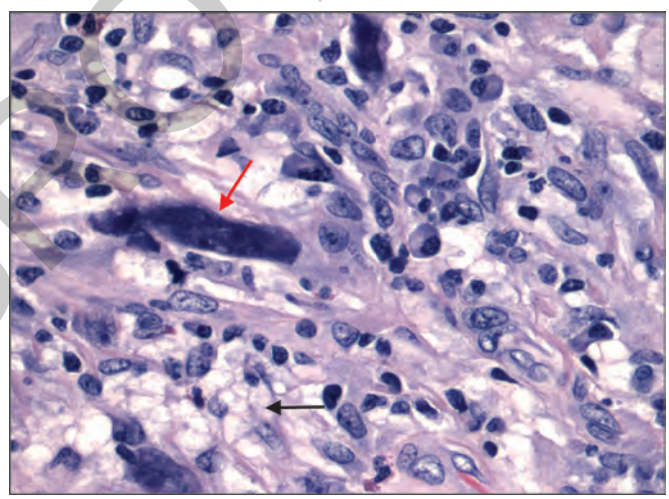

8. Which two genes are most likely amplified in the tumor to the right?

(a) Her2 and MDM2
(b) Her2 and CDK4
(c) CDK2 and MDM2
(d) CDK4 and MDM5
(e) MDM2 and CDK4

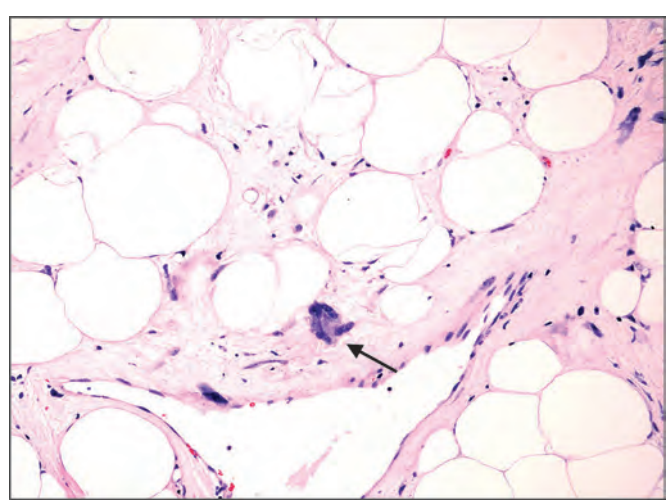

JAYPEE BROTHERS

9. Which of the following translocations is most likely found associated with this lesion?

(a) T(17;22)
(b) T(7;16)
(c) T(X;18)
(d) T(12;22)
(e) T(11;22)

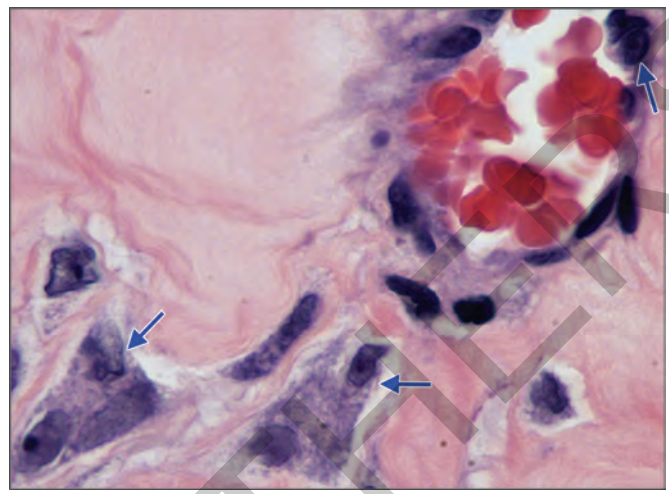

10. What is the most likely site of metastases for the sarcoma depicted which stains negatively for CD34, desmin, FLT-1, and S-100?

(a) Lungs
(b) Bone
(c) Lymph nodes
(d) Adrenal
(e) Brain

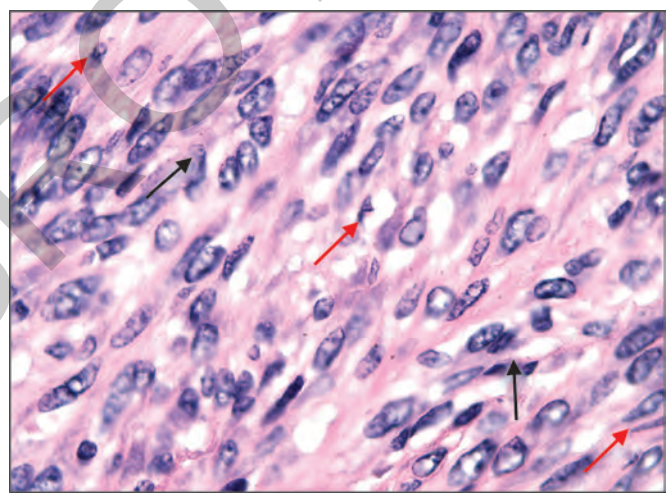

11. A 59-year-old male has a 5 cm left forearm mass with heterogeneous T2 signal which is mostly intermuscular in position with minimal intramuscular extension. What is the most specific correct diagnosis?

(a) Inflammatory myofibroblastic tumor
(b) Undifferentiated pleomorphic sarcoma, giant cell variant
(c) Undifferentiated pleomorphic sarcoma, inflammatory variant
(d) Undifferentiated pleomorphic sarcoma
(e) Anaplastic large cell lymphoma

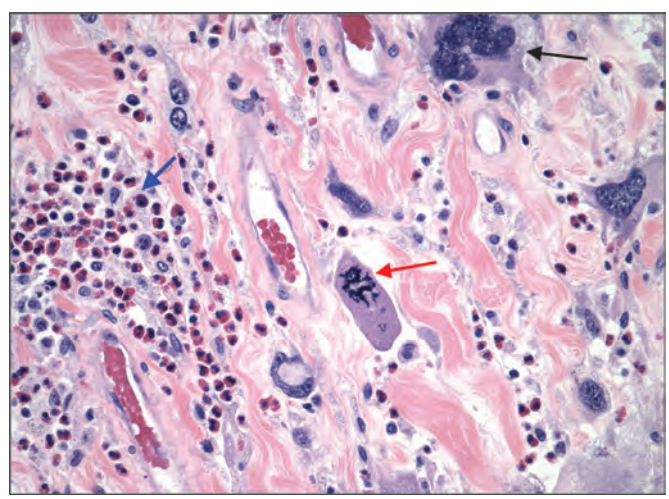

JAYPEE BROTHERS

12. A 70-year-old man has a 10 cm mass near the right colon embedded in mature adipose tissue. What is the correct diagnosis?

(a) Rhabdomyosarcoma
(b) Spindle cell lipoma
(c) Well-differentiated liposarcoma
(d) Dedifferentiated liposarcoma
(e) Pleomorphic liposarcoma

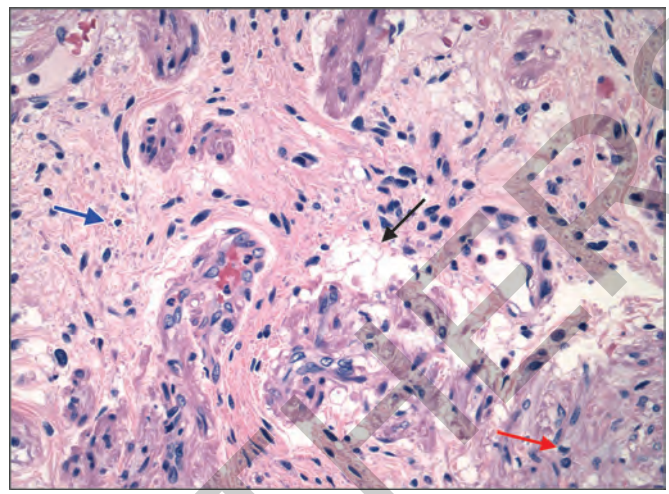

13. A 56-year-old man developed thigh pain and then a mass in the right lateral thigh. Imaging shows a 5 cm nontender mass in the right lateral thigh that just appeared one day, grew, then stopped growing. Imaging is nonspecific. What is the correct diagnosis?

(a) Osteosarcoma
(b) Nodular fasciitis
(c) Fibromatosis
(d) Undifferentiated pleomorphic sarcoma with a storiform pattern
(e) Pleomorphic liposarcoma

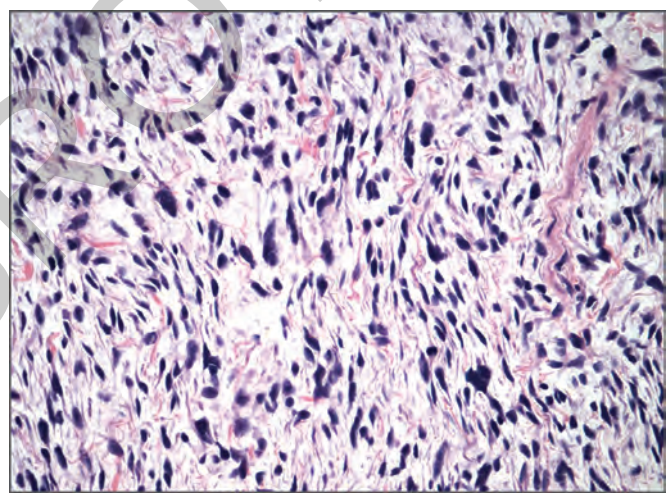

14. A 25-year-old male has the left ankle lesion depicted to the right. CD99 is positive and CD34 is negative. Which of the following stains would not stain these cells?

(a) Cytokeratin
(b) EMA
(c) Bcl-2
(d) TLE1
(e) Chromogranin

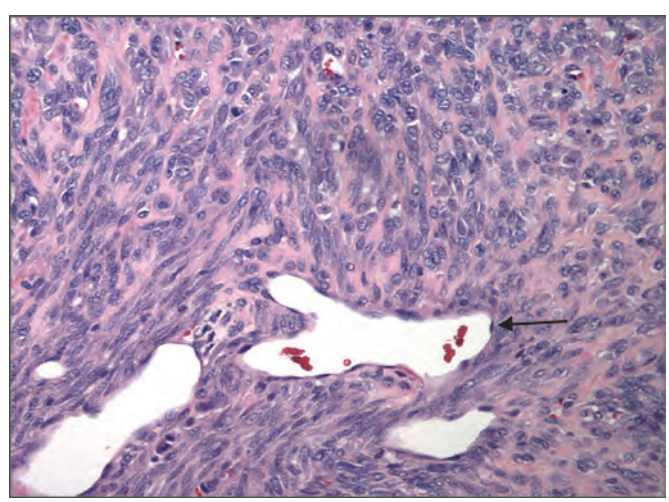

JAYPEE BROTHERS

15. A 71-year-old has a large mass in the anterior lateral portion of the thigh. What is the correct diagnosis?

(a) Pleomorphic liposarcoma
(b) Atypical lipoma/well-differentiated liposarcoma
(c) Pleomorphic lipoma
(d) Spindle cell lipoma
(e) Dedifferentiated liposarcoma

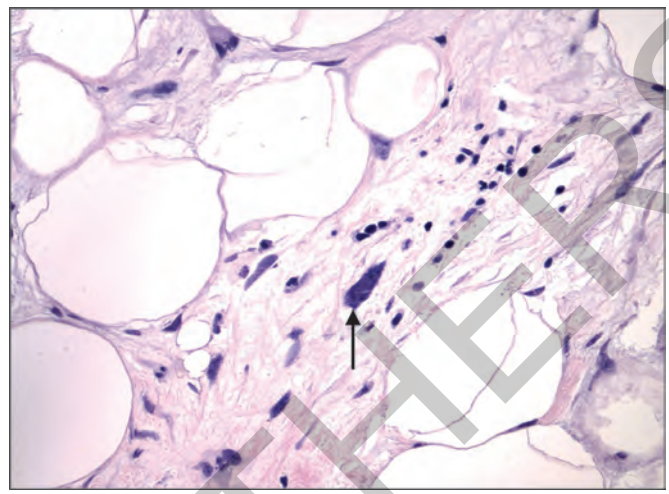

16. A 49-year-old female has a large soft tissue mass completely destroying the fibula in the mid to distal third of the fibula. CD99 and bcl-2 are positive in the tumor cells. CD34, smooth muscle actin, and S-100 are negative. What chromosomal rearrangement is most likely present?

(a) T(11;22)
(b) T(X;18)
(c) T(X;17)
(d) T(12;16)
(e) T(17;22)

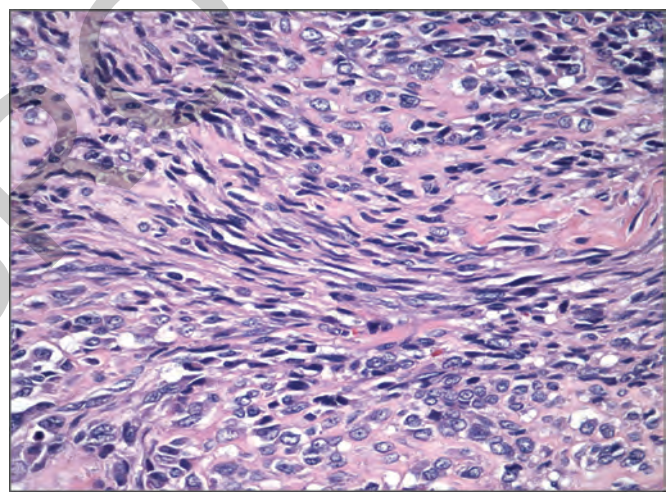

17. What clinical presentation is most often associated with this retroperitoneal tumor?

(a) Dementia
(b) Jaundice
(c) Paraesthesias
(d) Fever, leukocytosis
(e) Hypercalcemia

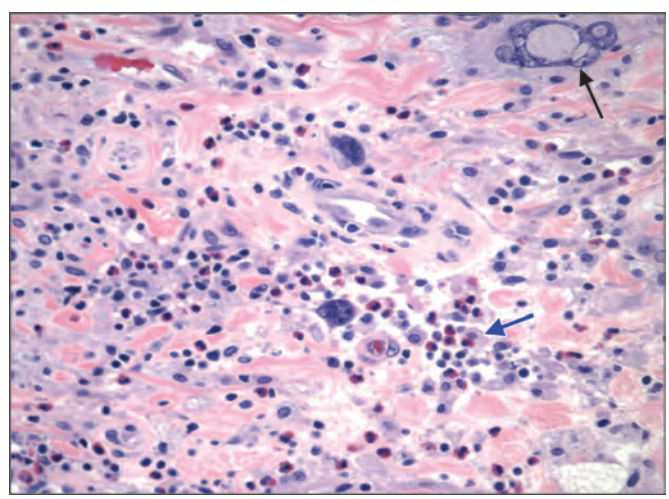

JAYPEE BROTHERS

18. A 15-year-old girl has a heterogeneous enhancing 10.9 cm chest wall mass, with tumor invading the left pectoralis muscle and left axillary fat. There is cortical destruction of the left third, fourth, and fifth ribs. Histology from the mass is shown to the right and an S-100 stain is shown in the inset. Staining for smooth muscle, skeletal muscle, and melanoma markers are negative. A TLE1 stain is negative. What is the correct diagnosis?

(a) Malignant peripheral nerve sheath tumor (MPNST)
(b) Fibrosarcoma
(c) Synovial sarcoma
(d) Undifferentiated pleomorphic sarcoma
(e) Leiomyosarcoma

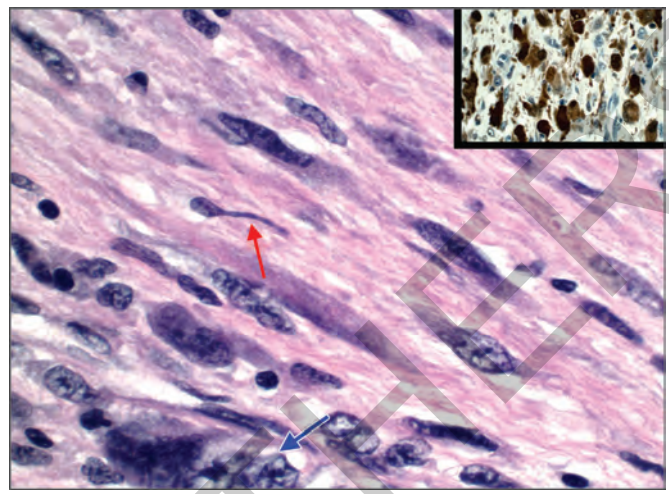

19. A 40-year-old female with a history of a left leg tumor status post chemotherapy now has a distal left femoral shaft lesion. What is the correct diagnosis?

(a) Osteosarcoma
(b) Stromal chemotherapy related atypia
(c) Low-grade fibrosarcoma
(d) Myxofibrosarcoma
(e) High-grade fibrosarcoma

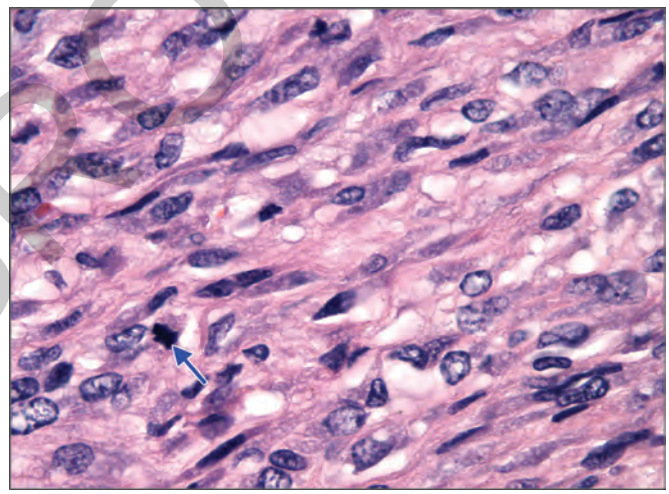

20. What is the most likely location for this lesion?

(a) Thigh
(b) Upper extremities
(c) Abdominal wall
(d) Scalp
(e) Retroperitoneum

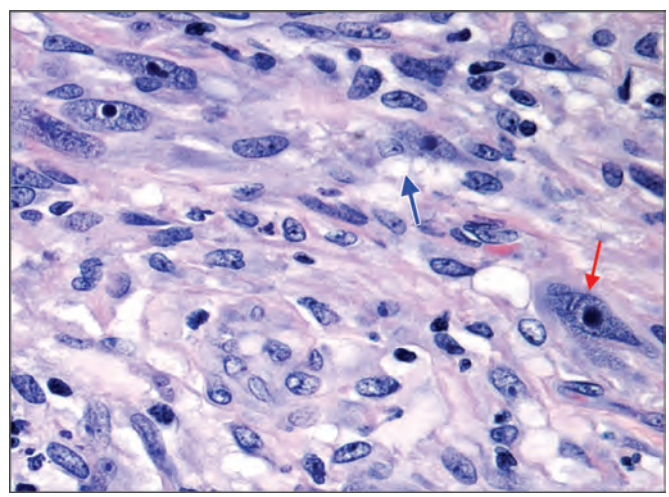

JAYPEE BROTHERS

21. A 73-year-old man presents with this scalp lesion. Which of the following is the strongest risk factor for this lesion?

(a) Previous trauma
(b) Chemical exposure
(c) Therapeutic radiation
(d) HPV exposure
(e) EBV exposure

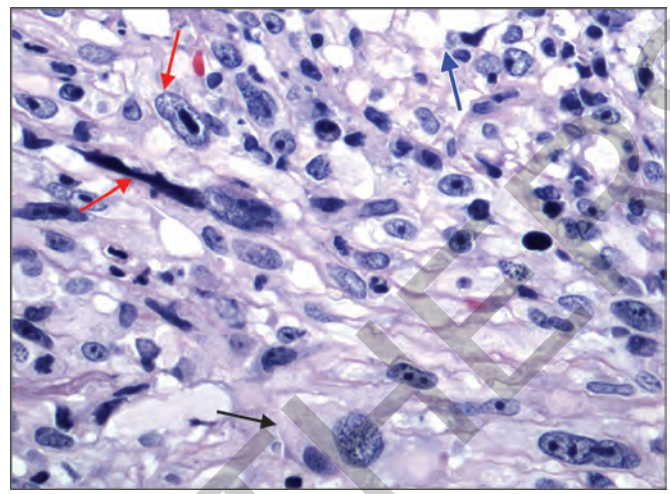

22. A 27-year-old female has the lesion to the right excised that stains positively for desmin. In which of the following sites would this lesion be considered to have a high malignant potential?

(a) Deep thigh
(b) Retroperitoneum
(c) Uterus, submucosal
(d) Uterus, subserosal
(e) Cervix

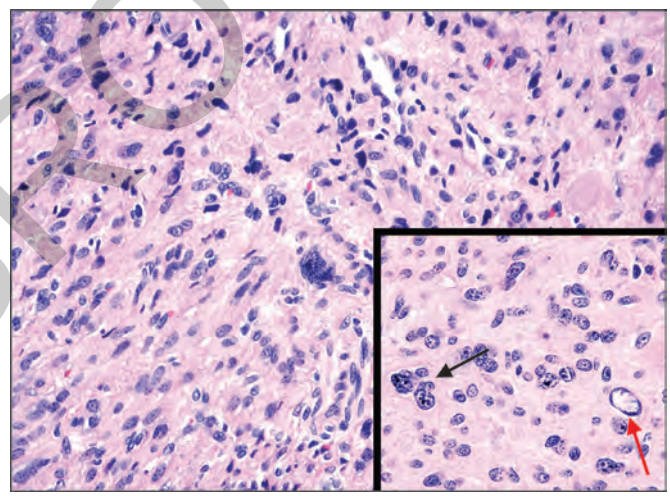

23. A 26-year-old female has a 2.4 cm tumor in the right ethmoid sinus with right orbital and dural extension. Stains for smooth muscle actin and desmin are positive while a stain for caldesmon is negative. The correct diagnosis is:

(a) High grade fibrosarcoma
(b) Monophasic synovial sarcoma
(c) Storiform pattern undifferentiated pleomorphic sarcoma
(d) High grade myofibroblastic sarcoma
(e) Leiomyosarcoma

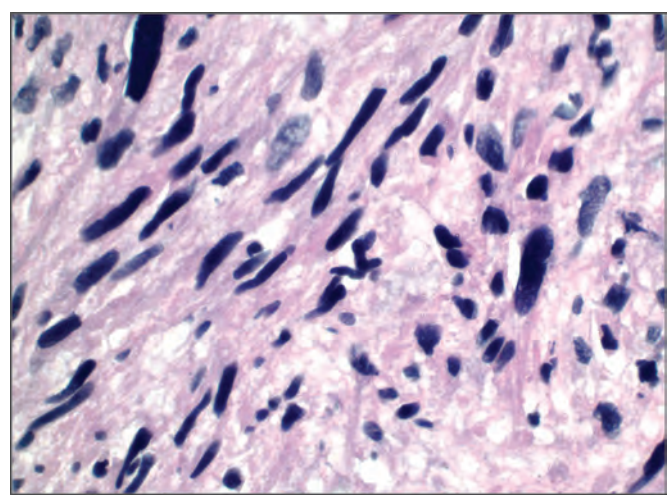

JAYPEE BROTHERS

24. An 84-year-old female has a 8 cm left upper extremity mass with central necrosis extending into the soft tissue with high T2 signal. The lesion infiltrates the medial biceps and extends posteriorly to infiltrate the lateral and long heads of the triceps. What is the most correct diagnosis?

(a) Undifferentiated pleomorphic sarcoma
(b) High-grade myxofibrosarcoma
(c) Low-grade myxofibrosarcoma
(d) Pleomorphic liposarcoma
(e) Undifferentiated pleomorphic sarcoma with giant cells

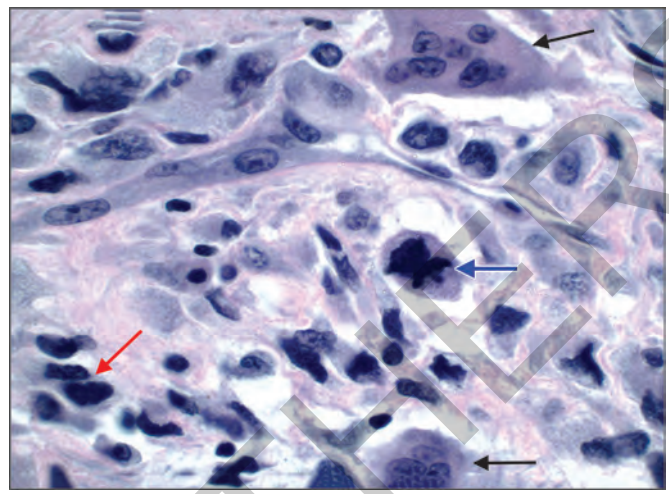

25. A patient has this tumor type in his lower extremity. The tumor cells stain negatively for cytokeratin, desmin, S-100, and myogenin. What is the approximate median 5 year survival for patients with this type of tumor.

(a) 10%
(b) 20%
(c) 50%
(d) 80%
(e) 90%

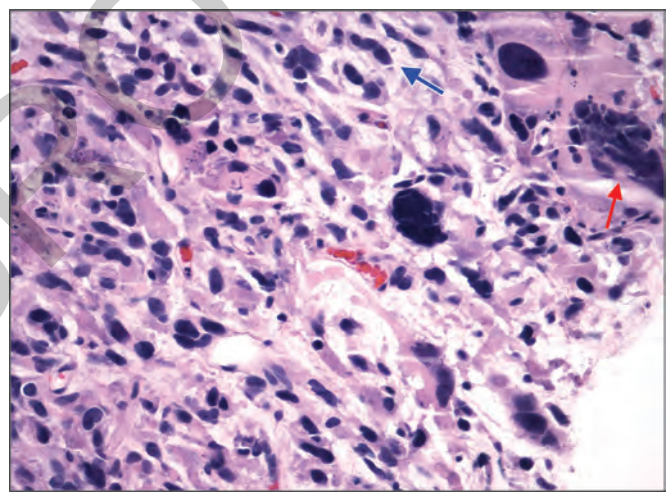

26. This 6 cm retroperitoneal mass in a 58-year-old female most likely represents a dedifferentiated

(a) Liposarcoma
(b) Chondrosarcoma
(c) Osteosarcoma
(d) No specific lineage
(e) Rhabdomyosarcoma

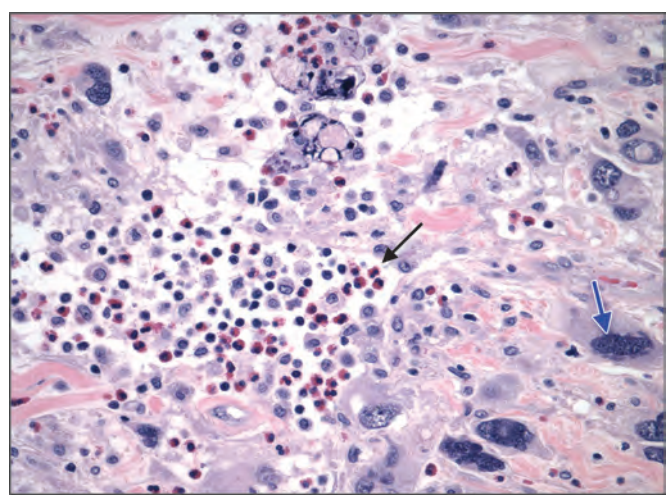

JAYPEE BROTHERS

27. A 65-year-old man with no known clinical history has the scalp lesion depicted. The neoplastic cells are negative for S-100 and pancytokeratin. What is the prognosis for this patient following resection?

(a) Poor
(b) Intermediate
(c) Variable
(d) Excellent
(e) Unknown

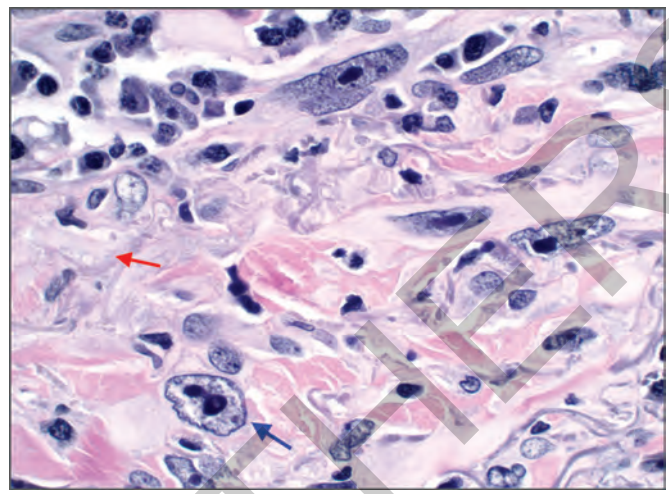

28. What is the most common site for the depicted CD34 positive tumor?

(a) Skin
(b) Liver
(c) Soft tissue
(d) Spleen
(e) Bone

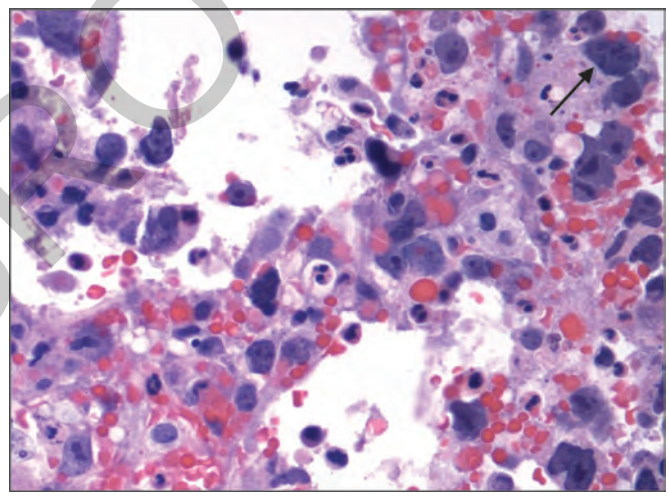

29. A 68-year-old man has a right upper lobe lung nodule and a skin nodule. The cells are focally positive for S-100 but negative for HMB45, Melan-A, CD34, and desmin. What is the correct diagnosis?

(a) Clear cell sarcoma
(b) Metastatic desmoplastic melanoma
(c) Monophasic synovial sarcoma
(d) Solitary fibrous tumor
(e) Leiomyosarcoma

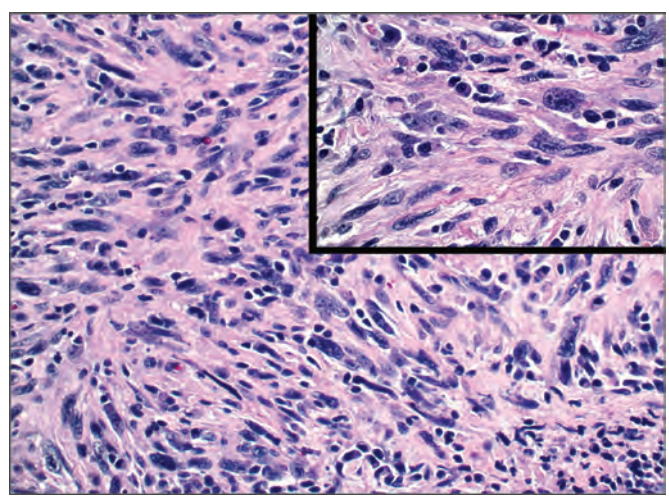

JAYPEE BROTHERS

30. What cytogenetic abnormalities are most often associated with this tumor?

(a) Loss of 16q, 13q
(b) Complex multifocal changes
(c) Ring and giant marker chromosomes
(d) Ring chromosomes and complex multifocal changes
(e) T(12;22) and t(12;16)

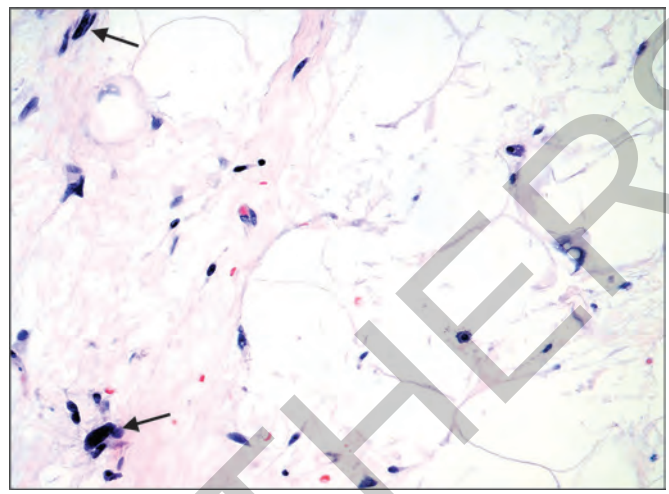

31. A 65-year-old man has a rapidly enlarging mass of the right thigh. What is the most likely karyotype?

(a) Complex karyotype
(b) PAX3-FOXO1A
(c) PAX7-FOXO1A
(d) 11p15.5 loss of heterozygosity
(e) No changes

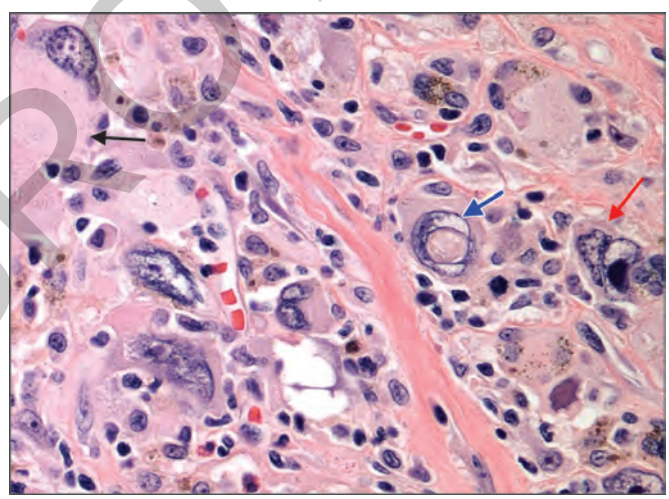

32. This retroperitoneal lesion in a 70-year-old man is associated with abundant mature adipose. What chromosomal pattern is most likely present?

(a) Loss of 16q, 13q
(b) Ring chromosomes and multifocal chromosomal abnormalities
(c) Multifocal chromosomal abnormalities without ring chromosomes
(d) No cytogenetic abnormalities
(e) Ring chromosomes and giant marker chromosomes

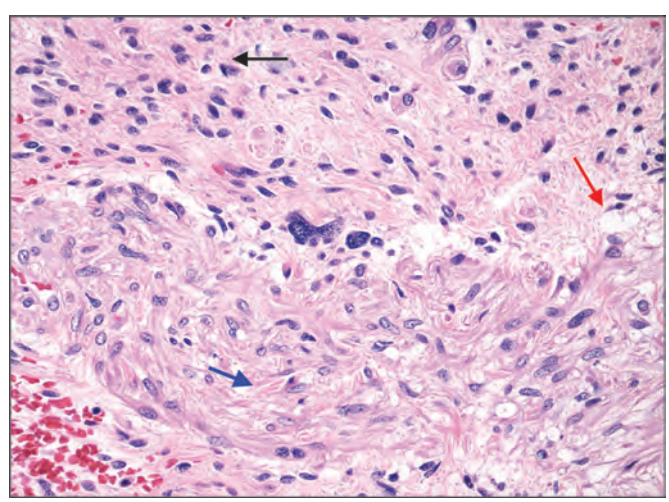

JAYPEE BROTHERS

33. A 63-year-old female has an 18 cm retroperitoneal mass that stains for desmin and exhibits high mitotic activity (>5/10 hpf). What is the correct diagnosis?

(a) Leiomyoma
(b) Leiomyosarcoma
(c) Dedifferentiated liposarcoma
(d) Fibrosarcoma
(e) Leiomyoma with degenerative atypia

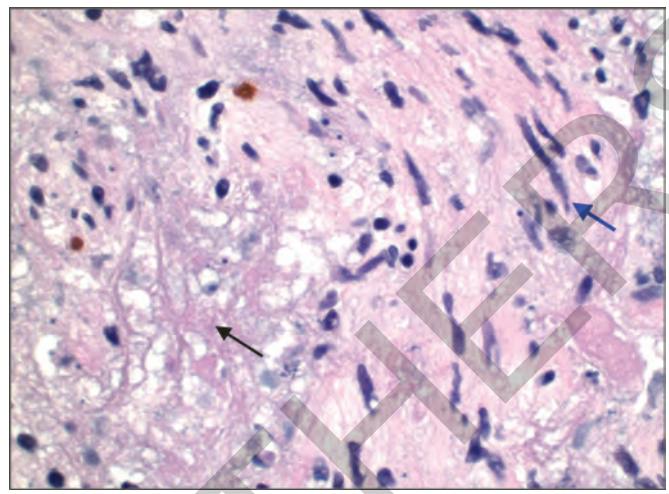

34. A 75-year-old female has a slowly growing anterior left knee mass. Cytogenetic testing shows a TGFBR3-MGEA5 translocation. What is the correct diagnosis?

(a) Inflammatory myofibroblastic tumor
(b) Myxoinflammatory fibroblastic sarcoma
(c) Myxoid undifferentiated pleomorphic sarcoma
(d) Inflammatory undifferentiated pleomorphic sarcoma
(e) Giant cell undifferentiated pleomorphic sarcoma

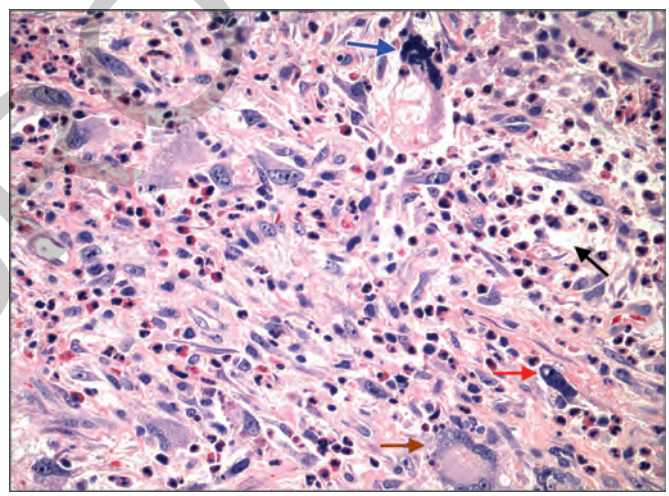

35. A 76-year-old female has worsening dyspnea with anasarca. She has a 8 cm mass in the right atrium with possible involvement of the right ventricle. The comprehensive immunophenotype is nonspecific but cytogenetic testing reveals a SYT-SSX translocation. Which of the following is the correct diagnosis?

(a) Intimal sarcoma
(b) Cardiac rhabdomyoma
(c) Cardiac myxoma
(d) Synovial sarcoma
(e) Leiomyosarcoma

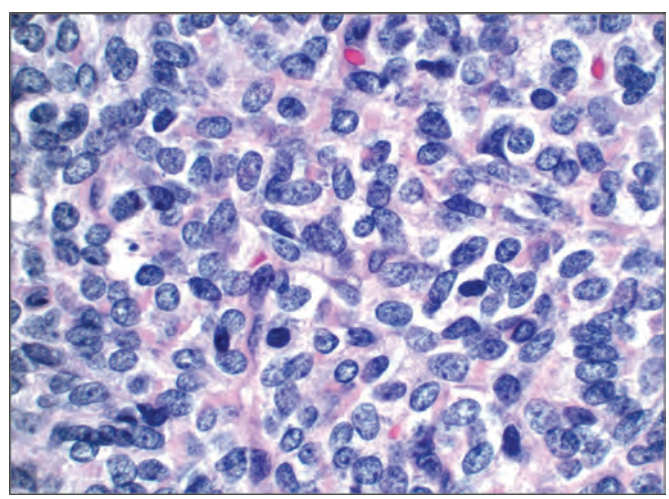

JAYPEE BROTHERS

36. Which of the following karyotypic abnormalities is typical of this lesion?

(a) Ring chromosomes
(b) Giant marker chromosomes
(c) Loss of 16q and 13q
(d) Complex multifocal chromosomal changes
(e) No chromosomal changes

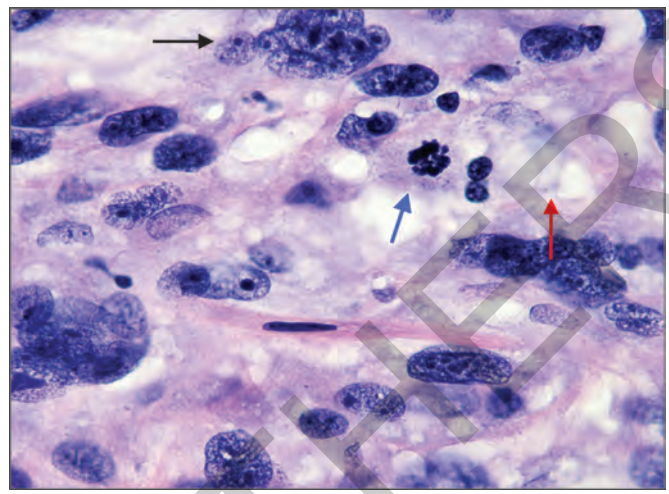

37. A 13-year-old girl has a 13 cm elbow mass , café au lait spots, and multiple additional smaller stable masses throughout her body. Histology from the elbow mass is shown to the right. What is the most likely site for metastases from her elbow lesion?

(a) Brain
(b) Lymph nodes
(c) Liver
(d) Lung
(e) Bone

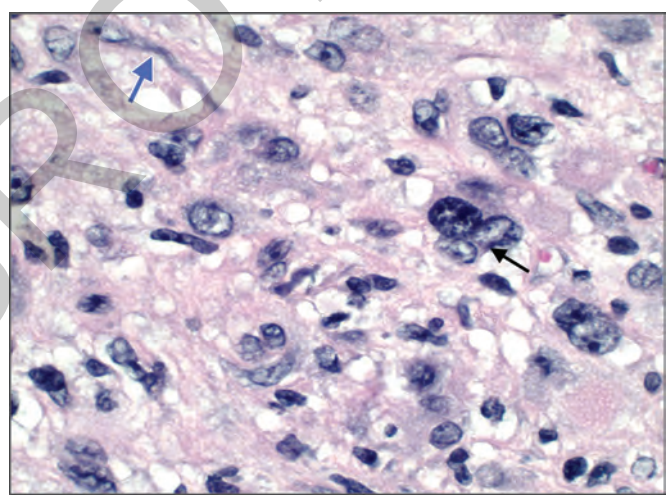

38. A 50-year-old man has an 8 cm posterior neck mass. What is the correct diagnosis?

(a) Lipoma
(b) Pleomorphic lipoma
(c) Hibernoma
(d) Angiolipoma
(e) Pleomorphic liposarcoma

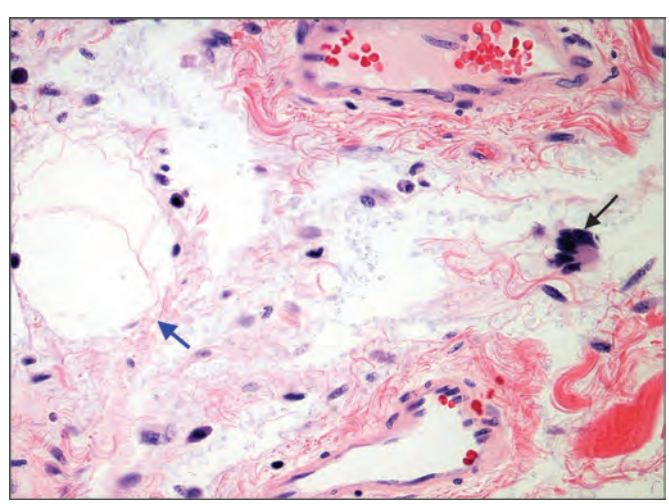

JAYPEE BROTHERS

ANSWERS

1. **(c) Giant cell fibroblastoma**
   Giant cell fibroblastoma is a lesion characterized histologically by perivascular accumulations of multinucleated cells (blue arrows) and hyperchromatic cells (black arrow). The site is correct for elastofibroma but giant cells are not characteristic of it. More giant cells with a uniform distribution would be seen in giant cell tumor of soft parts. The cell highlighted by the black arrow would be consistent with chemotherapy atypia; however, perivascular accumulations of giant cells with otherwise bland appearing endothelial cells is not found in chemotherapy atypia. Angiosarcoma should show markedly atypical endothelial cells and a vascular proliferation; giant cells are not typically found in angiosarcoma.
2. **(c) Complex genetic changes**
   This case demonstrates severely atypical and hyperchromatic cells (blue arrow) admixed with myxoid areas (red arrow) and rare pseudolipoblasts (black arrow). Thus, the differential diagnosis includes pleomorphic liposarcoma, dedifferentiated liposarcoma, and undifferentiated pleomorphic sarcoma/ high grade myxofibrosarcoma. All three of these tumors display complex genetic changes. Ring chromsomes and giant marker chromosomes are found in well-differentiated liposarcoma and chromosome 16q aberrations are seen in spindle cell lipoma; neither of these lesions display sufficient atypia to be a diagnostic consideration.
3. **(e) None of the markers listed**
   The tumor depicted is a fibrosarcoma. The characteristic herringbone pattern can be appreciated and nuclear pleomorphism is present. CD99 would be positive in Ewing's sarcoma and synovial sarcoma. S-100 would highlight melanoma and some malignant peripheral nerve sheath tumors. Pancytokeratin would be positive in synovial sarcoma. CD34 would stain a GIST or vascular tumor. Fibrosarcomas rarely stain for these markers and most markers except for vimentin.
4. **(c) Dedifferentiated liposarcoma**
   This lesion demonstrates osteosarcomatous differentiation with osteoid formation by atypical cells (upper right), well-differentiated liposarcomatous differentiation (bottom left), and leiomyosarcomatous differentiation (bottom right). Dedifferentiated liposarcoma can dedifferentiate along multiple pathways including showing osteosarcomatous, angiosarcomatous, leiomyosarcomatous, and rhabdomyosarcomatous differentiation. Thus, tumors like this one that have multiple lines of differentiation and have a well-differentiated liposarcomatous component are most likely dedifferentiated liposarcomas.
5. **(d) S-100**
   The lesion shown is a pleomorphic liposarcoma which most commonly occurs in the thigh. Diagnostic features include bizarrely atypical meganucleolated cells (blue arrow), necrosis (red arrow), and multivacuolated lipoblastic cells (black arrow). Due to these features, pleomorphic liposarcoma is at the top of the differential diagnosis. Many cases of pleomorphic liposarcoma do not exhibit clear lipoblastic features and require an S-100 stain to highlight adipocytic differentiation. CD34, keratin, actin, and desmin have been reported to be positive in a fraction of pleomorphic liposarcomas but positivity in these cases would point away from the correct diagnosis.
6. **(c) Atypical fibroxanthoma**
   Atypical fibroxanthoma features a dermal population of severely atypical, bizarre cells (black arrow) embedded in a solar elastotic background (blue arrow). The presence of single atypical cells makes squamous cell and basal cell carcinoma less unlikely. The presence of solar elastosis, the clinical history of sun damage, and the site (scalp) are not consistent with Hodgkin's lymphoma or pleomorphic liposarcoma.
7. **(a) Pleomorphic liposarcoma**
   Pleomorphic liposarcoma features highly atypical cells (red arrow) with atypia in the spectrum of undifferentiated pleomorphic sarcoma and abundant polyvacuolated lipoblasts (black arrow). Without the presence of the lipoblasts,

JAYPEE BROTHERS

undifferentiated pleomorphic sarcoma would be correct. The cellularity is too high and the pleomorphism too great for a well-differentiated liposarcoma. In dedifferentiated liposarcoma we should also see a well-differentiated liposarcomatous area which is not present. Pleomorphic lipoma would demonstrate floret-type giant cells and not as much atypia.

8. **(e) MDM2 and CDK4**
   The image depicts a well-differentiated liposarcoma with mature fat interspersed by atypical sparsely populated single cells (black arrow). Well-differentiated liposarcoma is characterized by amplification of MDM2 and CDK4. MDM2 and CDK4 both promote cell proliferation, the former by p53 inhibition and the latter through RB1 inhibition. These markers can help in the distinction of well-differentiated liposarcoma from lipoma in which they are not amplified.

9. **(a) T(17;22)**
   This is a giant cell fibroblastoma. Proliferations of giant cells are seen in a perivascular distribution (blue arrows). T(17;22) is found both in giant cell fibroblastoma and dermatofibrosarcoma protuberans. T(7;16) is found in low grade fibromyxoid sarcoma. T(x;18) is characteristic of synovial sarcoma. T(12;22) is found in myxoid liposarcoma. T(11;22) is found in Ewing's sarcoma and desmoplastic small round blue cell tumor.

10. **(a) Lungs**
    This is a fibrosarcoma, with a typical herringbone pattern. This pattern is highlighted by the arrows which show fascicles of malignant cells oriented in a repeating fashion, with fascicles marked with the red arrows giving an appearance of streaming in one way and fascicles highlighted by the black arrows appearing to stream in the opposite direction. The most common site of fibrosarcoma metastasis is the lungs followed by the bones. Hematogeneous spread is the rule and lymph node metastases are rare.

11. **(c) Undifferentiated pleomorphic sarcoma, inflammatory variant**
    This lesion displays the main hallmarks of undifferentiated pleomorphic sarcoma, inflammatory variant: A significant mixed infiltrate of eosinophils and macrophages (blue arrow); markedly atypical cells (black arrow); and atypical mitoses (red arrow). Inflammatory myofibroblastic tumor would not show this degree of atypia. Undifferentiated pleomorphic sarcoma, giant cell variant, is not correct due to the lack of giant cells. In the absence of the inflammation, undifferentiated pleomorphic sarcoma would be the correct diagnosis; however, in this case, due to the prominent inflammation, undifferentiated pleomorphic sarcoma, inflammatory variant is more specific. Anaplastic large cell lymphoma should feature sheets of cells, not scattered atypical cells.

12. **(d) Dedifferentiated liposarcoma**
    Dedifferentiated liposarcoma can take on two main forms, a form where the dedifferentiated areas are sharply demarcated from the well-differentiated areas, and another form where the two areas are intermixed, as in this image. The more well-differentiated areas with well-differentiated-liposarcoma-spectrum atypia and cellularity (blue arrow) make numerous interfaces with more spindled, pleomorphic, and cellular dedifferentiated regions (red arrow). The questions stem states that the lesion is embedded in mature adipose tissue and at the interface adipocytes can be seen, revealing the underlying differentiation of this lesion (black arrow). The retroperitoneum is the most likely site for this tumor.

13. **(d) Undifferentiated pleomorphic sarcoma with a storiform pattern**
    The presentation of a lower extremity mass exhibiting sudden rapid growth is consistent with undifferentiated pleomorphic sarcoma. Histologically, these tumors contain severely atypical nuclei with hyperchromasia and high N:C ratios. Occasionally, as in this image, a spindled, vaguely storiform architecture can be present, leading to the modifier "with a storiform pattern". Undifferentiated pleomorphic sarcoma with a storiform pattern can cause diagnostic confusion with a high grade fibrosarcoma. The lack of osteoid rules out osteosarcoma. Nodular fasciitis and fibromatosis should not display the cellular atypia seen here. Furthermore, nodular fasciitis is seldom greater than 4 cm. Lipoblasts, seen in pleomorphic liposarcoma, are not present.

JAYPEE BROTHERS

14. (e) Chromogranin

This is a monophasic synovial sarcoma with fascicles of spindled cells interspersed around hemangiopericytoma-like vessels (black arrow). Due to the CD34 negativity, hemangiopericytoma is unlikely and monophasic synovial sarcoma is the most likely diagnosis. Monophasic synovial sarcoma shows positivity for all the markers in the question except for chromogranin.

15. (b) Atypical lipoma/well-differentiated liposarcoma

The image depicts a well-differentiated liposarcoma. Among normal adipocytes are spindled cells some of which display significant atypia (black arrow). The atypia is not undifferentiated pleomorphic sarcoma-grade atypia and the lesion does not contain multiple polyvacuolated lipoblasts, both findings seen in pleomorphic liposarcoma. There are no floret type giant cells that would be seen in pleomorphic lipoma. The atypia is too great for a diagnosis of spindle cell lipoma. There is no worse differentiated component that would suggest a dedifferentiated liposarcoma.

16. (b) T(X;18)

This is a synovial sarcoma. The tumor cells are spindled and epithelioid. Staining for CD99 and bcl-2 moves synovial sarcoma and hemangiopericytoma to the top of the differential diagnosis. CD34 negativity makes synovial sarcoma the most likely diagnosis. Synovial sarcomas are characterized by the t(X;18) SYT-SSX translocation in 90% of cases and this case was positive for the translocation. T(11;22) is seen in desmoplastic small round blue cell tumor and Ewing's sarcoma. T(X;17) is seen in alveolar soft part sarcoma. T(12;16) is found in myxoid liposarcoma and angiomatoid fibrous histiocytoma. T(17;22) is found in DFSP which would stain positively for CD34.

17. (d) Fever, leukocytosis

This lesion is undifferentiated pleomorphic sarcoma, inflammatory variant, evidenced by the significant infiltrate of eosinophils and histiocytes (blue arrow) with scattered markedly atypical cells (black arrow). Undifferentiated pleomorphic sarcoma, inflammatory variant, patients frequently experience systemic symptoms such as fever, weight loss, and leukocytosis along with symptoms from the tumor itself.

18. (a) Malignant peripheral nerve sheath tumor (MPNST)

MPNST is a high grade sarcoma with marked cytologic atypia (blue arrow), buckled nuclei (red arrow, suggestive of neural differentiation), and variable S-100 staining (inset). The tumor cells can be spindled as in this case and many are associated with a neurofibroma. If a tumor that is suspicious for MPNST is not associated with a neurofibroma, a panel of stains must be performed to rule out other possibilities. Fibrosarcoma is usually S-100 negative. Synovial sarcoma should stain for TLE1. Leiomyosarcoma would be highlighted by smooth muscle markers. Undifferentiated pleomorphic sarcoma would not stain for S-100.

19. (e) High grade fibrosarcoma

Fibrosarcoma displays herringbone architecture as shown in the image as well as a high mitotic rate (blue arrow). This is not low grade fibrosarcoma because of the high mitotic rate, moderate nuclear atypia, and hypercellularity of the lesion without much interspersed collagen between atypical spindled cells. Many fibrosarcomas are associated with a history of trauma. The absence of osteoid formation rules out osteosarcoma. Chemotherapy related atypia in the stroma is typically individual stromal cells and would not lead to the spindled fascicular proliferation seen in the image. The lesion does not display enough myxoid stroma for a diagnosis of myxofibrosarcoma.

20. (a) Thigh

This is a pleomorphic liposarcoma. Adipocytic differentiation is seen by the presence of multivacuolated lipoblastic cells (blue arrow). The nuclear size varies greatly from one cell to the next with bizarre meganucleolated cells (red arrow), suggesting this is a high grade sarcoma. The top two differential diagnoses are thus pleomorphic liposarcoma and dedifferentiated liposarcoma. In dedifferentiated liposarcoma, found most commonly in the retroperitoneum, the high grade component is typically not adipocytic. Additionally, this lesion shows no better differentiated regions, thus this lesion is most likely a pleomorphic liposarcoma. Meganucleolated bizarre lipoblasts are a hallmark of pleomorphic liposarcoma. The most common site for this lesion is the thigh.

JAYPEE BROTHERS

21. (c) Therapeutic radiation

This lesion is an atypical fibroxanthoma. Characteristic features include bizarre meganucleolated cells and hyperchromatic cells (red arrows), a solar elastotic background (black arrow), and clear cell cytoplasmic changes (blue arrow). The main risk factors for atypical fibroxanthoma are therapeutic radiation and sun exposure.

22. (a) Deep thigh

This is a spindle cell lesion displaying scattered highly atypical cells (black arrow) and nuclear pseudoinclusions (red arrow). The nuclear and cytoplasmic features suggest this sarcoma has smooth muscle differentiation which is confirmed by desmin staining. In contrast to smooth muscle tumors in other locations, atypia indicates malignancy when found in smooth muscle tumors located deeply in the soft tissues. Atypia per se is not necessarily a sign of malignancy in the uterus or cervix (bizarre or symplastic leiomyoma) or in retroperitoneal lesions (degenerative atypia). Mitoses and necrosis may or may not be conspicuous in leiomyosarcoma.

23. (d) High grade myofibroblastic sarcoma

This tumor demonstrates a fascicular arrangement of spindled cells with pale pink cytoplasm and highly atypical hyperchromatic enlarged nuclei. These histologic findings and positive staining for desmin and smooth muscle actin while staining negative for caldesmon are typical of high grade myofibroblastic sarcoma. High grade fibrosarcoma, monophasic synovial sarcoma, and undifferentiated pleomorphic sarcoma would not stain for smooth muscle actin and desmin. Leiomyosarcoma would be highlighted by smooth muscle actin, desmin, and caldesmon. The caldesmon stain is critical for differentiating this lesion from leiomyosarcoma.

24. (e) Undifferentiated pleomorphic sarcoma with giant cells

This variant of undifferentiated pleomorphic sarcoma displays numerous multinucleated giant cells (black arrow), mitotic activity (blue arrow), and atypical hyperchromatic nuclei (red arrow). The numerous giant cells makes the other answer choices incorrect. This lesion has a similar prognosis to undifferentiated pleomorphic sarcoma.

25. (c) 50%

Considered a diagnosis of exclusion, in the face of severe cytologic atypia (red arrow), with no immunohistochemical evidence of differentiation, this tumor is a undifferentiated pleomorphic sarcoma. Some of these tumors can exhibit focally myxoid regions (blue arrow) leading some cases to be named high grade myxofibrosarcoma. The lower extremity is a typical site for this tumor. The median five year survival for undifferentiated pleomorphic sarcoma is approximately 50%.

26. (a) Liposarcoma

This is a undifferentiated pleomorphic sarcoma, inflammatory variant, as evidenced by a significant inflammatory infiltrate (black arrow) and scattered large atypical cells (blue arrow). Retroperitoneal undifferentiated pleomorphic sarcoma with inflammatory cells cases are almost uniformly synonymous with dedifferentiated liposarcomas due to the presence of chromosome 12q13-15 amplification and high levels of MDM2 expression in both groups.

27. (d) Excellent

The lesion is an atypical fibroxanthoma. The scalp location and the age of the patient support this diagnosis. Markedly atypical cells (blue arrow) with background solar elastosis (red arrow) are the hallmark of this lesion. Despite the high cytologic atypia, patients with this lesion that undergo excision with negative margins have an excellent prognosis. Lymph node metastases have been documented but they are rare.

28. (a) Skin

This is an angiosarcoma. CD34 positivity is nonspecific and can be seen in epithelioid sarcoma, dermatofibrosarcoma protuberans, solitary fibrous tumor, vascular tumors, as well as immature hematopoietic tumors. The histology depicted shows large atypical cells (black arrow), with high nuclear to cytoplasmic ratios, admixed with RBCs and surrounding vessels. These findings are diagnostic of angiosarcoma. The most common site for angiosarcoma is now the skin. Less common primary sites include the liver, soft tissue, spleen, and bone.

JAYPEE BROTHERS

29. (b) Metastatic desmoplastic melanoma

Desmoplastic melanoma, as illustrated here, can be a diagnostic pitfall since the image shows markedly atypical cells in a spindled pattern, suggestive of sarcoma. Additionally, the staining pattern is not typical of conventional melanoma which should stain S-100 positive, HMB45 positive, and Melan-A positive. Nevertheless, this is a metastatic desmoplastic melanoma which displays a unique S-100 positive, HMB45 and Melan-A negative staining pattern. Clear cell sarcoma can show S-100 positivity but the cells would be more glycogenated than those seen in the image. Monophasic synovial sarcoma would be negative for S-100. Solitary fibrous tumor would be positive for CD34. Leiomyosarcoma would show desmin positivity. A possible differential diagnosis not listed could be a malignant peripheral nerve sheath tumor. In a patient with neurofibromatosis this immunohistologic profile coupled with the history of a skin lesion would raise more concern for malignant peripheral nerve sheath tumor.

30. (c) Ring and giant marker chromosomes

This is a well-differentiated liposarcoma. The image displays the typical histologic findings including mature adipocytes and scattered atypical hyperchromatic cells (black arrows). Well-differentiated liposarcoma is associated with ring chromosomes and giant marker chromosomes. Loss of 16q and 13q is associated with spindle cell lipoma which would not be consistent with the atypia present. Complex multifocal changes are seen in pleomorphic liposarcoma which would be more atypical than the lesion depicted here. Ring chromosomes and complex multifocal changes are characteristic of dedifferentiated liposarcoma but no dedifferentiated component is present. T(12;22) and t(12;16) are found in myxoid liposarcoma which would feature a delicate vascular networks that is not seen here.

31. (a) Complex karyotype

This is a pleomorphic rhabdomyosarcoma judging from the abundant eosinophilic cytoplasm with eccentric nuclei (black arrow) and high level of cytologic atypia. Two abnormalities commonly seen in pleomorphic rhabdomyosarcoma are nuclear pseudoinclusions (blue arrow) and nuclear molding (red arrow). Pleomorphic rhabdomyosarcoma has a complex karyotype. PAX3-FOXO1A and PAX7-FOXO1A translocations are seen in alveolar rhabdomyosarcoma. 11p15.5 loss of heterozygosity is seen in embryonal rhabdomyosarcoma. Both alveolar and embryonal rhabdomyosarcoma show less atypia than that seen here. This is a rare tumor with the general architecture and cytology of a pleomorphic undifferentiated sarcoma showing striated muscle differentiation.

32. (b) Ring chromosomes and multifocal chromosomal abnormalities

This is a dedifferentiated liposarcoma. The image shows a more well-differentiated-liposarcomatous area (black arrow) adjoining a more pleomorphic, cellular, spindled, and dedifferentiated area (blue arrow). The question stem mentions that this lesion is associated with abundant mature adipose tissue and adipocytes are at the junction (red arrow), supporting underlying lipomatous differentiation. The well-differentiated liposarcomatous areas should cytogenetically display ring chromosomes and giant marker chromosomes. However, the dedifferentiated portion should have a complex karyotype with multiple diverse cytogenetic changes. Thus, the karyotype should be mosaic, reflecting both the well-differentiated liposarcomatous areas (ring chromosomes) and the dedifferentiated areas (multifocal chromosomal abnormalities). Loss of 16q, 13q is associated with spindle cell lipoma. The other incorrect answer choices do not reflect the mosaic nature of the karyotype.

33. (b) Leiomyosarcoma

This lesion meets diagnostic criteria for a leiomyosarcoma with the presence of coagulative necrosis (black arrow), cellular atypia (blue arrow), and the stated high mitotic rate. With coagulative necrosis, simply the atypia or the mitotic rate would merit the diagnosis leiomyosarcoma. Leiomyoma would lack all three of these characteristics. Although the site is good for dedifferentiated liposarcoma, no well-differentiated liposarcoma component is seen. Fibrosarcoma would stain negatively for desmin. Leiomyoma with degenerative atypia can be seen in the retroperitoneum; however, the presence of coagulative necrosis is not consistent with that diagnosis.

34. (b) Myxoinflammatory fibroblastic sarcoma

Myxoinflammatory fibroblastic sarcoma is composed of myxoid areas (black arrow) which abut hyalinized areas. There are pleomorphic spindled tumor cells (red arrow) with a mixed inflammatory infiltrate. An atypical mitosis

JAYPEE BROTHERS

(blue arrow) can be seen in this case as well as touton-type giant cells (brown arrow) that can be associated with this lesion. Inflammatory myofibroblastic tumor is unlikely due to the cytologic atypia present. Undifferentiated pleomorphic sarcoma is a close differential as well as its giant cell and inflammatory subtypes due to the giant cells and inflammation that accompany severe atypia in this case. However, the presence of the TGFBR3-MGEA5 translocation that has been found in the majority of myxoinflammatory fibroblastic sarcomas and not documented in undifferentiated pleomorphic sarcoma makes myxoinflammatory fibroblastic sarcoma the correct diagnosis.

35. (d) Synovial sarcoma

Due to the presence of the translocation, this lesion is a synovial sarcoma and not an intimal sarcoma. This lesion contains epithelioid cells deposited in a collagenous matrix with no definite differentiation. A nonspecific comprehensive immunophenotype and the intracardiac location would favor an intimal sarcoma. However, positive testing for the SYT-SSX translocation in a immunohistochemically nonspecific tumor is sufficient to merit a diagnosis of synovial sarcoma. The other answer choices are not consistent with the cytogenetic and immunophenotypic findings.

36. (d) Complex multifocal chromosomal changes

This is a pleomorphic liposarcoma. Defining features include the highly atypical multinucleated cells (black arrow), high mitotic rate (blue arrow), and numerous multivacuolated lipoblastic cells (red arrow). Ring chromosomes and giant marker chromosomes are seen in well-differentiated liposarcoma. Loss of 16q and 13q is seen in spindle cell lipoma. Pleomorphic liposarcoma, consistent with its high grade sarcoma nature, exhibits a complex karyotype.

37. (d) Lung

This is a malignant peripheral nerve sheath tumor (MPNST) from the clinical history of neurofibromatosis 1 symptoms (café au lait spots, numerous smaller masses), high level of cytologic atypia, (black arrow), and buckled wavy nuclei (blue arrow). These tumors can take on a spindled herringbone appearance or a more epithelioid appearance as in this case and 25%–50% of tumors arise in the background of NF1. The most likely metastatic destination of MPNST tumors is the lung, where 66% of metastases travel. MPNST metastasizes to the lymph nodes in only 10% of cases. Liver, brain, and bone have metastatic deposits less often than the lung.

38. (b) Pleomorphic lipoma

This lesion contains mature adipocytes (blue arrow) and scattered atypical floret-like giant cells with eosinophilic cytoplasm and peripherally oriented nuclei (black arrow). Atypical floret-like giant cells are the hallmark of pleomorphic lipoma. Lipoma would not feature these atypical giant cells. Hibernoma would show more brown fat. Angiolipoma would feature vessels with intravascular thrombi. Pleomorphic liposarcoma would have far greater atypia.

JAYPEE BROTHERS

for detailed information on pathology books, visit our website **www.jaypeebrothers.com,** for detailed information on pathology books, visit our websit

SOFT TISSUE AND BONE PATHOLOGY

This book is an instrument for pathologists in training to refresh and self-assess their soft tissue and bone pathology knowledge. Its focus is on the main entities in soft tissue and bone pathology that could be encountered on the AP board exam, with special focus on epidemiologically relevant lesions. The book covers morphologic, immunohistochemical, and molecular diagnostic approaches to these diseases.



Agedi Boto MD PhD is a clinical fellow at Yale-New Haven Hospital in New Haven, Connecticut, USA. He received his MD and PhD from the Johns Hopkins School of Medicine, Baltimore, Maryland, USA in 2012 and then completed his residency training in Anatomic Pathology at Yale-New Haven Hospital. He is board certified in Anatomic Pathology by the American Board of Pathology. He has taught medical students and trained residents in surgical pathology.



Jose Costa MD is Professor of Pathology and Medicine (Oncology) and Professor of Orthopedics and Rehabilitation at Yale University School of Medicine, Connecticut, USA. He received his MD from Barcelona Medical School, Barcelona, Spain in 1967. He was trained in anatomic pathology at Colorado University, Colorado, USA, and Washington University, Missouri, USA, and is board certified in anatomic pathology. In his career, he has held multiple leadership roles including the Branch Chief of the Anatomic Pathology Branch at the National Institutes of Health (NIH) Clinical Center, Bethesda, USA; Chair of Pathology at University of Lausanne, Lausanne, Switzerland, and between 1992 and 2007, he served as Vice Chairman of Pathology and Director of Anatomic Pathology at Yale-New Haven Hospital in New Haven, Connecticut, USA. He has served on numerous National and International committees and scientific advisory boards, including being the Editor-in-Chief of Pathology Research and Practice and Laboratory Investigation. He has contributed over 160 original publications to the technical literature.

Available at all medical bookstores or buy online at www.jaypeebrothers.com

JAYPEE BROTHERS
Medical Publishers (P) Ltd.
www.jaypeebrothers.com

Join us on facebook.com/JaypeeMedicalPublishers

Shelving Recommendations
PATHOLOGY
SURGICAL PATHOLOGY

ISBN 978-93-86056-02-3