eebrothers.com, for detailed information on obstetrics & gynecology books, visit our website www.jaypeebrothers.com, for detailed information on obstetrics & gynecology books

Get Full Access
with added features at
emedicine360.com

Celebrating 50 YEARS
Passion, Quality and Innovation in Healthcare Publishing

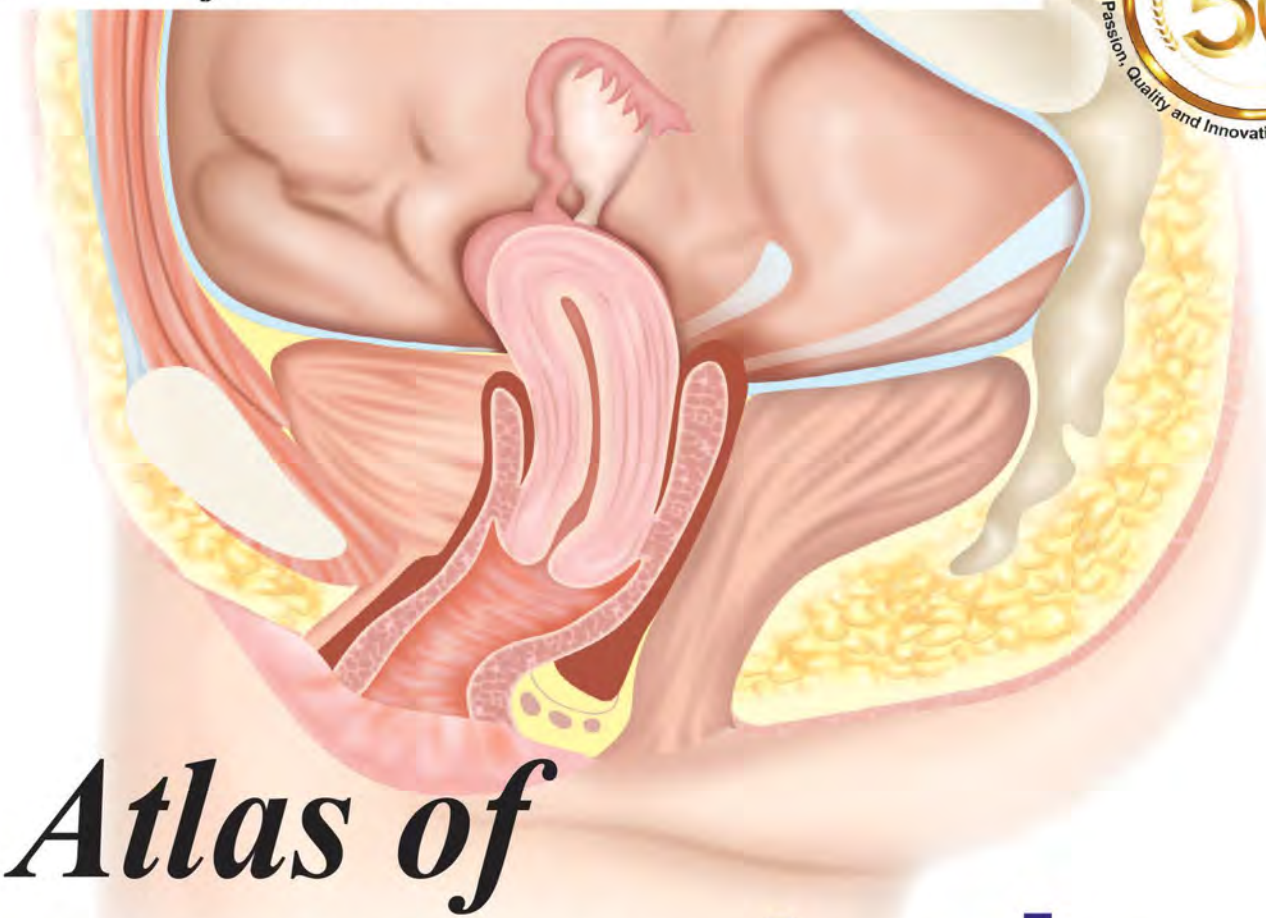

Atlas of Urogynecologic Surgery

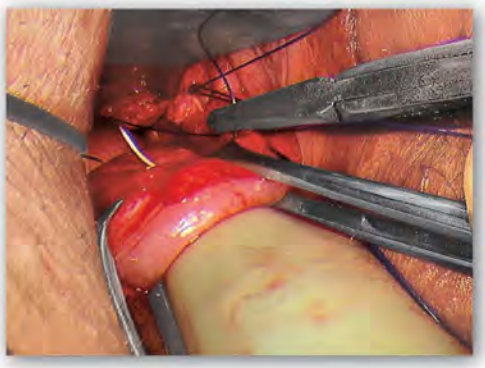

Editor
Tajnoos Yazdany

Co-Editor
Donald R Ostergard

JAYPEE

Contents

SECTION 1: PRE-SURGICAL PREPATATION

1. **Surgical Decision-making and Patient Preparation for the Operating Room** **3**
   Tajnoos Yazdany
   - Antibiotics *3*
   - Patient Skin Preparation *4*
   - Bowel Preparation *4*
   - Deep Vein Thrombosis Prevention *4*
   - Unique Considerations in the Elderly Patients *4*
   - The Consent Process and Patient Understanding *4*

SECTION 2: PATIENT POSITIONING FOR OPEN, VAGINAL, LAPAROSCOPIC AND ROBOTIC SURGERY

2. **Patient Positioning for Open, Vaginal, Laparoscopic and Robotic Surgery** **9**
   Joy Brotherton, Erica Stockwell
   - Universal Precautions and Preoperative Considerations *9*
   - Laparotomy *10*
   - Vaginal *10*
   - Laparoscopic *11*
   - Surgeon Ergonomics *12*
   - Robotic *13*

SECTION 3: GENERAL VAGINAL AND VULVAR PROCEDURES

3. **Hysterectomy, Salpingectomy and Oophorectomy through the Vaginal Route** **17**
   Tajnoos Yazdany
   - Vaginal Hysterectomy *17*
     - Difficult Cases *19*
   - Salpingectomy/Oophorectomy *20*
4. **Vaginal Cysts** **22**
   Christina M Truong, Tajnoos Yazdany
   - Preoperative Planning *22*
     - Gartner's Duct 22
     - Bartholin's Gland 22
5. **Labioplasty of the Labia Minora** **27**
   Christina M Truong
   - Preoperative Considerations *27*
   - Surgical Procedure *27*

SECTION 4: VAGINAL SURGERY FOR APICAL PELVIC ORGAN PROLAPSE

6. Uterosacral Ligament Suspension **33**
Sharon Jakus-Waldman
- Surgical Procedure and Technique *34*

7. Sacrospinous Ligament Fixation **37**
Tajnoos Yazdany
- Surgical Procedure 38

8. Colpocleisis **40**
Christina M Truong
- Obliterative Vaginal Procedures *40*

9. Uterine Suspension Procedures **44**
Jessica S Zigman
- Transvaginal Procedures *44*
- Abdominal or Laparoscopic or Robotic-Assisted Procedures *45*

SECTION 5: VAGINAL SURGERY FOR ANTERIOR AND POSTERIOR COMPARTMENT PROLAPSE

10. Anterior Vaginal Wall Repair **55**
Tajnoos Yazdany
- Surgical Procedure *55*

11. Posterior Repair Techniques and Perineorrhaphy **59**
Cecilia K Wieslander
- Surgical Procedure *59*

SECTION 6: URINARY INCONTINENCE PROCEDURES

12. Mid-Urethral Slings **65**
Gregory I Kanter, Gena Dunivan
- Retropubic Mid-urethral Slings: 'Bottom-Up' and 'Top-Down' Approach *66*
- Transobturator Tape: 'Outside to In' and 'Inside to Out' Technique *71*

13. Burch Urethropexy **76**
John N Nguyen
- Operative Setup *76*
- Surgical Procedure *76*

14. Urethral Bulking **80**
Aldene O Zeno, Amy Rosenman
- Patient Counseling *80*
- Operative Setup *80*
- Periurethral versus Transurethral Injection *81*

15. Fascial Slings **84**
John Navas, Cecilia K Wieslander
- Surgical Procedure *84*

16. Neuromodulation **87**
Angel M Johnson, Patricia Hudson, Milena M Weinstein
- Percutaneous Nerve Stimulation *87*
- Sacral Nerve Neuromodulation *88*

17. Intravesicular Injection of OnabotulinumtoxinA **95**
Tajnoos Yazdany
- Preoperative Assessment and Counseling *95*
- Surgical Procedure *95*

SECTION 7: OTHER URETHRAL PROCEDURES

18. Urethrovaginal Fistula Repair **99**
Janine Oliver, Ja-Hong Kim
- Etiologies and Patient Assessment *99*
- Diagnostic Considerations *99*
- Timing of Repair *99*
- Tissue Interposition *100*
- Step-by-Step Technique *100*
- Techniques for Severe and Salvage Cases *105*

19. Urethral Diverticulum **108**
Christina M Truong
- Preoperative Considerations *108*
- Surgical Procedure *109*

SECTION 8: BLADDER PROCEDURES AND REPAIRS

20. Vesicovaginal Fistula **115**
Tam Le
- Operative Setup *115*
- Vaginal Repair *115*
- Abdominal Repair *119*

21. Bladder Hydrodistention **123**
Tajnoos Yazdany
- Cystoscopy with Hydrodistention *123*

SECTION 9: LAPAROSCOPIC AND ROBOTIC APPROACHES

22. Surgical Considerations: Anatomy and Port Placements **127**
Joy Brotherton, Chirisse Taylor, Erica Stockwell
- Primary Laparoscopic Trocar Placement *127*
- Secondary Trocar Placement *130*

- Robotic-Assisted Laparoscopy *130*
- Removal of Trocars and Closure of Trocar Sites *134*

23. Sacral Colpopexy **136**
Tajnoos Yazdany
- Surgical Procedure *136*

SECTION 10: FECAL INCONTINENCE PROCEDURES

24. Anovaginal and Rectovaginal Fistula **143**
Tajnoos Yazdany
- Surgical Procedure *143*

25. Anal Sphincteroplasty for Chronic Third Degree Lacerations **145**
Christina C Liao
- Surgical Procedure *145*

SECTION 11: DEALING WITH POSTOPERATIVE MESH COMPLICATIONS

26. Transvaginal Tape Removal/Loosening **153**
Sylvia M Botros-Brey, Carolyn Botros
- Urinary Retention *153*
- Mesh Exposure Requiring Partial Removal *154*
- Complete Removal of Mesh *154*
- Erosion into Bladder or Urethra *154*

27. Treatment of Mesh in the Bladder **156**
Christina Dancz
- Step-by-Step Techniques (Abdominal Approach) *156*
- Step-by-Step Techniques (Vaginal Approach) *157*

28. Surgical Management of Vaginal Mesh Exposures **160**
Christina Dancz
- Step-by-Step Techniques *160*

Index *163*

Chapter

4 Vaginal Cysts

Christina M Truong, Tajnoos Yazdany

INTRODUCTION

Aside from pelvic organ prolapse, the different masses in the vagina can be epidermal inclusion cysts, diverticuli, Gartner's duct cysts, Bartholin's glands, leiomyoma, endometriotic cysts, ureteroceles, or cancers. Epidermal inclusion cysts can be found wherever there is squamous epithelium.[1]

PREOPERATIVE PLANNING

Imaging should be performed in patients with vaginal masses to rule out renal malformations, where duplicated kidneys and ureters can be found or even ectopic ureteroceles. A magnetic resonance imaging (MRI) is now the standard modality to evaluate the mass, communicating tissue, location and any malformations of the renal system. An ultrasound or computed tomography (CT) scan may also be helpful.

Gartner's Duct

Gartner's ducts are Wolffian remnants and tend to be found in the anterolateral aspects of the vagina. Patients with Gartner duct cysts may be asymptomatic at diagnosis, or present with dyspareunia, discomfort with tampon placement, pelvic pain or pressure, pelvic bulge, or urinary incontinence.[2] Treatment can be with excision or marsupialization.

Procedure

The patient should be placed in low dorsal lithotomy, prepped and draped in the normal sterile fashion and have a Foley placed to keep the bladder drained and for identifying the proximity of the urethra. With Allis clamps, place traction around the area to be incised and inject dilute vasopressin. Avoid injecting into the mass itself, or so much that the mass is distorted. An incision is made over the mass without entering the mass. Fine tipped Metzenbaum scissors are used to dissect the vaginal wall with the tips pointing away from the mass (Fig. 4.1). Dissect around to free up the mass and transect it off at the base. However, if the mass ruptures during the dissection, put the ruptured cyst wall on traction, and dissect it off the vagina and transect it off at the base. Irrigate the base with warm saline. Place several layers of stitches of 2-0 or 3-0 vicryl to close up the dead space and achieve hemostasis. The final layer can be closed with 2-0 vicryl in a running fashion (Fig. 4.2). A vaginal packing may be placed as needed for further compression. Perform a rectal examination or a cystoscopy if you suspect the integrity may be compromised by sutures.

Bartholin's Gland

Depending on whether this is a primary treatment or secondary and if it is infected, Bartholin's glands can be treated with a Word catheter placement, marsupialization or cystectomy. An obstructed Bartholin's duct can lead to an accumulation of mucus, and if this fluid collection becomes infected then an abscess forms. An abscess is best treated with a Word catheter placement or marsupialization to evacuate the infected debris. A cystectomy becomes difficult to dissect once it is infected, so repair is reserved for when it does not appear to be concurrently infected.

Generally, for the first occurrence of a Bartholin's cyst or abscess, an incision and drainage (I&D) is performed with Word catheter placement. For the second occurrence an I&D with Word catheter or marsupialization can be performed. For any recurrence where there is not

JAYPEE BROTHERS

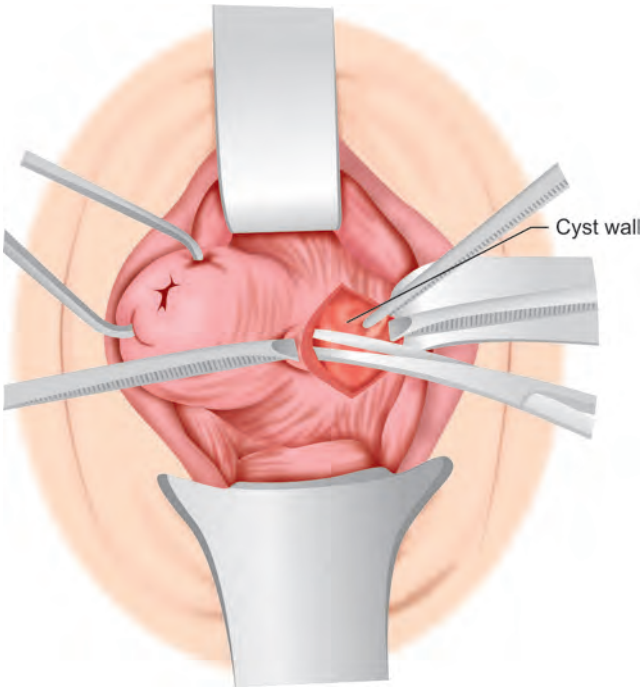

Fig. 4.1: Excision of Gartner's cyst along vaginal sidewall.

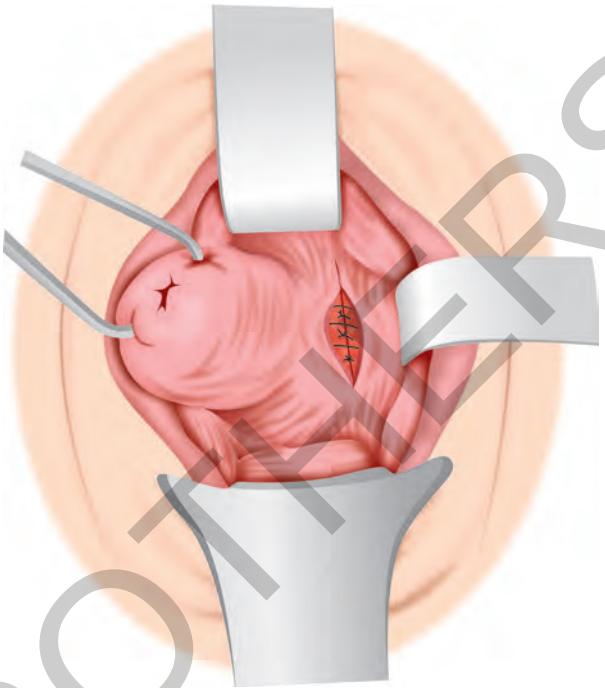

Fig. 4.2: Closure of space in layers with delayed absorbable suture.

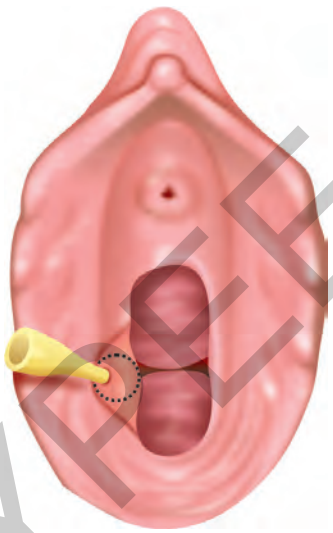

Fig. 4.3: Word catheter placed in stab incision.

an infection, cystectomy in the operating room can be performed. A biopsy of the cyst or gland is recommended if there are any suggestions or risks of malignancy, such as a solid area, a cyst wall that is difficult to dissect off, recurrence or if the patient is over 40 years old. If purulent drainage is noted, or in the case of a recurrence, aerobic and anaerobic cultures are taken and the patient can also be tested for gonorrhea and chlamydia.

Word Catheter Placement

Incision and drainage of a Bartholin's gland with Word Catheter placement can typically be done under local anesthesia in the clinic setting. The physician should wear protective gear, especially a face shield. Place the patient in low dorsal lithotomy, prep and drape in the normal sterile fashion. inject lidocaine or marcaine approximately 1–5 cc over and around the cyst avoiding popping the cyst. With a 15 blade scalpel make a 1 cm incision over the medial aspect of the mass puncturing into the fluid pocket. Allow the fluid to drain, collect cultures and swabs as needed. Irrigate with saline through a large syringe. With a hemostat or round tipped probe, explore the pocket for any other fluid collections not yet ruptured behind or adjacent to the initial pocket. Once all fluid pockets are drained and irrigated, a pretested Word Catheter may be placed. The stem of the catheter can be bent in and stored in the vagina to avoid irritation in undergarments (Fig. 4.3). The Word Catheter can be removed in 3 to 4 weeks depending on how well the gland has re-epithelialized. If the patient is uncomfortable with the size of the balloon tip, a small amount of fluid can be removed from the balloon as long as this does not cause the catheter to fall out.

JAYPEE BROTHERS

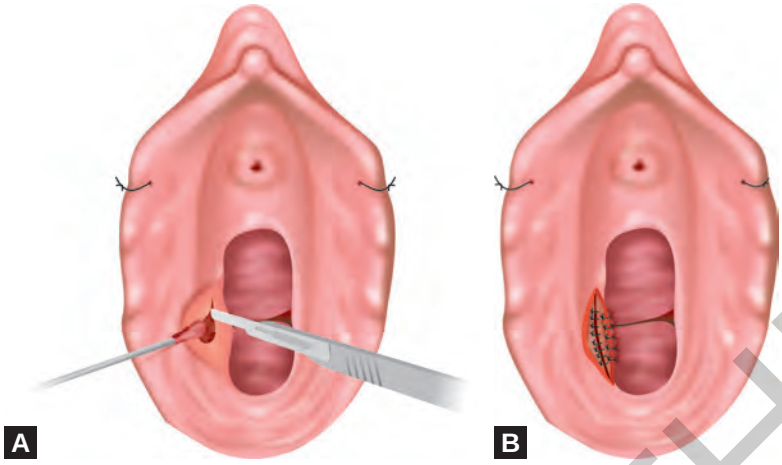

Figs. 4.4A and B: Marsupialization with incision of abscess and hemostatic sutures placed on the edges of the incision.



Fig. 4.5: Bartholin's cystectomy.

Marsupialization

Marsupialization of a Bartholin's gland can be performed under local anesthesia in the clinic setting or in the operating room depending on the physician's preference. The physician should wear protective gear, especially a face shield. Place the patient in low dorsal lithotomy, prep and drape in the normal sterile fashion. Inject lidocaine or marcaine, approximately 1–5 cc over and around the cyst avoiding popping the cyst. With a 15 blade scalpel make a 1–2 cm cruciate incision over the medial aspect of the mass puncturing into the fluid pocket. Be sure to provide appropriate traction while making the second cut on the cruciate incision (Figs. 4.4A and B).

Allow the fluid to drain, collect cultures and swabs as needed. Irrigate with saline through a large syringe. With a stylet or other round tipped probe, explore the pocket for any other fluid collections not yet ruptured behind or adjacent to the initial pocket. Once all fluid pockets are drained and irrigated, and biopsies taken as needed, use a 2-0 or 3-0 Vicryl to evert the cyst wall with interrupted stitches.

Bartholin's Cystectomy

The patient should be placed in low dorsal lithotomy, prepped and draped in the normal sterile fashion and drain the bladder. Place traction around the area to be incised and inject dilute vasopressin. Avoid injecting into the mass itself, or so much that the mass is distorted. An incision is made over the medial aspect of the mass without entering the mass (Figs. 4.5 and 4.6). Fine tipped Metzenbaum scissors are used to dissect the vaginal wall with the tips pointing away from the mass. Dissect around to free up the mass and transect it off at the base (Figs. 4.7A and B). However, if the mass ruptures during the dissection, put the ruptured cyst wall on traction and dissect it off the vagina and transect it off at the base. Irrigate the base with warm saline. Place several layers of stitches of 2-0 or 3-0 vicryl to close up the dead space and achieve hemostasis (Figs. 4.8A and B). The final layer can be closed with 2-0 vicryl in a running fashion.

JAYPEE BROTHERS

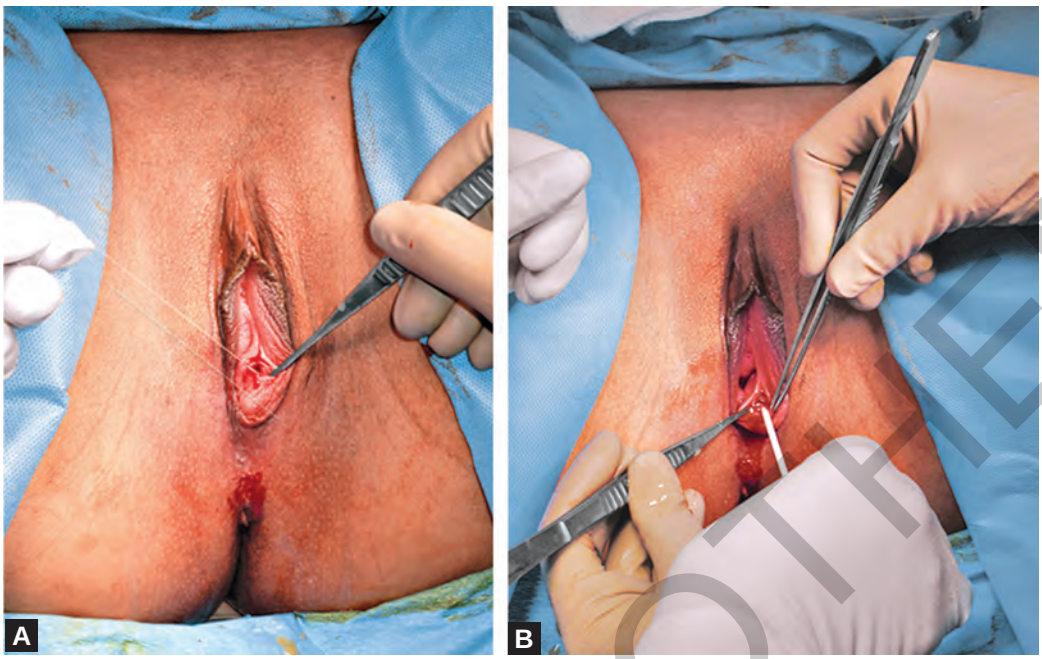

Figs. 4.6A and B: Close of dead space with absorbable sutures.

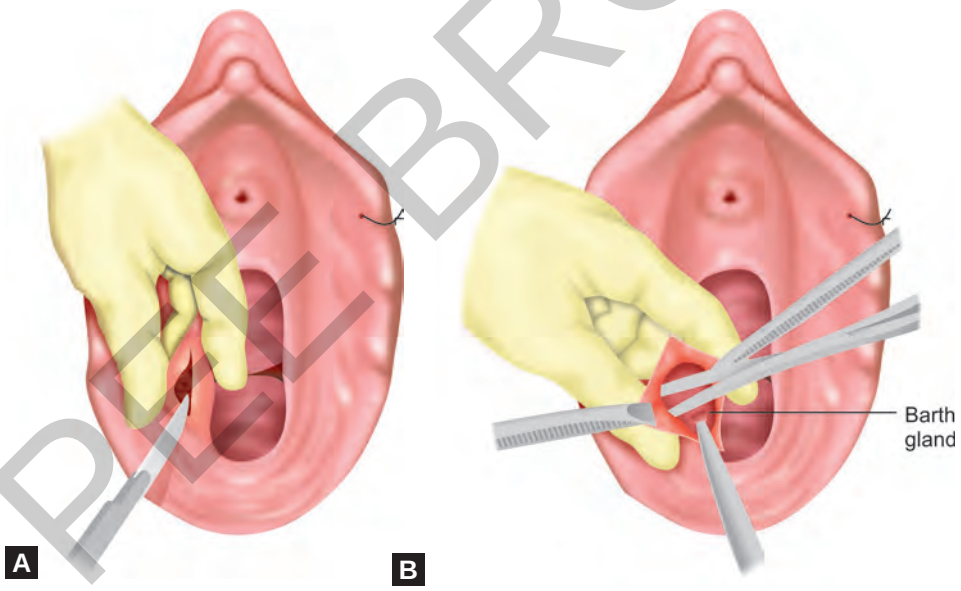

Figs. 4.7A and B: Incision and removal of Bartholin cyst using fine Metzenbaum or Iris scissors.

Surgical Tips

- It is best to make the incision over the Bartholin's gland closer to the vagina and introitus than over the labia majora to avoid pain.
- Bartholin cyst excision can be bloody, remember to use excellent hemostasis and surgical techniques, including gentle cautery and closure of dead spaces.

JAYPEE BROTHERS

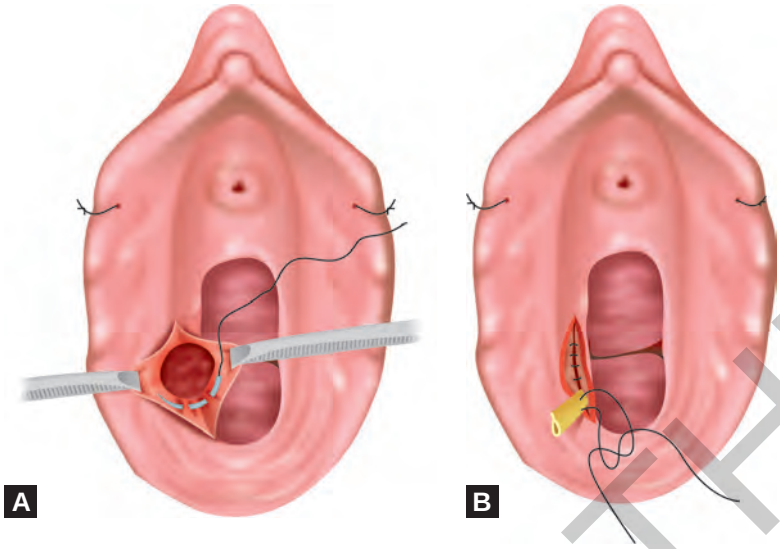

Figs. 4.8A and B: Closure of deep space with interrupted sutures and placement of drain if needed with closure of skin edges.

REFERENCES

1. Silva PD, Summers R, Omole M, et al. Large epidermal inclusion cyst presenting as a pelvic mass. WMJ. 2014;113:239-41.
2. Cope AG, Laughlin-Tommaso S, Famuyide A, et al. Clinical manifestations and outcomes in surgically managed Gartner duct cysts. J Minim Invasive Gynecol. 2017;24:473-7.

JAYPEE BROTHERS

for detailed information on obstetrics & gynecology books, visit our website www.jaypeebrothers.com, for detailed information on obstetrics & gynecology books, v

Atlas of
Urogynecologic Surgery

This book provides an opportunity to describe procedures in the field of Female Pelvic Medicine and Reconstructive Surgery (FPMRS) that have withstood the tests of time. Over the past few years, our field has been subject to numerous controversies regarding what materials to use with federal and local regulations abounding. The field continues to grow and expand, and comparative studies will further elucidate our understanding. The aim of this book is to describe FPMRS procedure in a simplified, straightforward way. We hope readers will enjoy the step-by-step approach of this illustrative book, and continue to help women with pelvic floor disorders, one patient at a time.

Tajnoos Yazdany MD FACOG FACS is a board-certified Female Pelvic Medicine and Reconstructive Surgeon (FPMRS) who has spent her career in training fellows and residents in urogynecology. She currently serves as Vice Chair of Education in the Department of Obstetrics and Gynecology, as well as the Program Director for the FPMRS fellowship.

Donald R Ostergard MD started the first fellowship in FPMRS at Harbor-UCLA Medical Center, Torrance, California, USA and has been the author of numerous textbooks and scientific publications in urogynecology, including the first edition of this atlas and a textbook on urodynamics. He has served as Past President of the International Urogynecology Association of which he was a founder. He also served as Past President of the American Urogynecology Society, of which he was also a founder. He was Editor-in-Chief of the International Urogynecology Journal for 13 years. His work and research in the field has paved the way for generations of FPMRS surgeons.

Available at all medical bookstores
or buy online at www.jaypeebrothers.com



JAYPEE BROTHERS
Medical Publishers (P) Ltd.
www.jaypeebrothers.com

Join us on facebook.com/JaypeeMedicalPublishers

Shelving Recommendation
OBSTETRICS AND GYNECOLOGY

ISBN 978-93-86056-04-7

