eebrothers.com, for detailed information on dental books, visit our website www.jaypeebrothers.com, for detailed information on dental books

Essential Quick Review

With Free Companion FAQs on Periodontics

Periodontics



HIGHLIGHTS

- Supplementary FAQ book containing Definitions, Classifications and Viva-voce
- Diagrams with supporting answers
- Recent question bank of all India universities
- Covers entire undergraduate DCI syllabus

Priya Verma Gupta
Vinita Ashutosh Boloor

JAYPEE

Contents

Section 1 Periodontics

1. Gingiva 03-10
2. Periodontal Ligament 11-14
3. Alveolar Process 15-20
4. Cementum 21-24
5. Age-related Changes in Periodontium 25-27
6. Classification of Periodontal Diseases 28-31
7. Epidemiology of Gingival and Periodontal Diseases 32-34
8. Periodontal Microbiology 35-36
9. Dental Calculus and Iatrogenic Factors 47-50
10. Inflammation and Immunity 51-63
11. Microbial Interactions with the Host in Periodontal Diseases 64-65
12. Smoking and Periodontal Diseases 66-66
13. Host Modulation and Host Modulation Agents 67-68
14. Influence of Systemic Disorders and Stress on the Periodontium 69-74
15. Periodontal Medicine 75-77
16. Halitosis (Oral Malodour) 78-79
17. Defence Mechanism of Gingiva 80-81
18. Gingival Inflammation 82-83
19. Clinical Features of Gingivitis 84-88
20. Gingival Enlargement 89-94
21. Acute Gingival Infections 95-100
22. Gingival Diseases in Childhood 101-102
23. Desquamative Gingivitis 103-105
24. Periodontal Pocket 106-110
25. Bone Loss and Patterns of Bone Destruction 111-115
26. Trauma from Occlusion 116-123
27. Chronic Periodontitis 124-126
28. Necrotising Ulcerative Periodontitis 127-127
29. Aggressive Periodontitis 128-132

30. AIDS and Periodontium 133-135
31. Clinical Diagnosis 136-137
32. Radiographic Aids in the Diagnosis of Periodontal Diseases 138-139
33. Advanced Diagnostic Techniques 140-142
34. Risk Assessment 143-144
35. Prognosis 145-147
36. Rationale for Periodontal Treatment 148-148
37. Periodontal Treatment for Medically Compromised Patients 149-151
38. The Treatment Plan 152-152
39. Phase I Periodontal Therapy 153-154
40. Plaque Control 155-159
41. Scaling and Root Planing 160-166
42. Chemotherapeutic Agents 167-168
43. Sonic and Ultrasonic 169-170
44. Adjunctive Role of Orthodontic Therapy 171-172
45. Occlusal Evaluation and Therapy 173-174
46. Periodontic-Endodontic Continuum 175-176
47. Preparation of the Periodontium for Restorative Dentistry 177-178
48. Phase II Periodontal Therapy 179-181
49. General Principles of Periodontal Surgery 182-183
50. Gingival Surgical Techniques 184-188
51. Treatment of Gingival Enlargements 189-189
52. The Periodontal Flap 190-193
53. Flap Technique for Pocket Therapy 194-195
54. Resective Osseous Surgery 196-198
55. Reconstructive Periodontal Surgery 199-203
56. Furcation 204-206
57. Periodontal Plastic and Aesthetic Surgery 207-210
58. Recent Advances in Surgical Techniques 211-212
59. Dental Implants 213-215
60. Supportive Periodontal Therapy 216-217

Section 2 Recently Asked Questions

61. Recently Asked Questions 221-246

Chapter 4

Cementum

LONG ESSAYS

Questiuon 1

Define cementum? Discuss in details the types, classification, composition and functions of cementum.

Answer

According to Carranza, cementum is defined as the calcified, avascular mesenchymal tissue that forms the outer covering of the anatomic root.

There are basically two types of cementum:

1. Acellular cementum.
2. Cellular cementum.

Acellular Cementum

It is also known as primary cementum since it is the first-formed cementum. It covers cervical third or half of the root and as the name suggests, it does not contain cells. It is formed before the teeth reaches occlusal plane. Its thickness is between 30–230 µm. The main component of the acellular cementum is Sharpey's fibres which plays an important role in supporting the tooth.

Cellular Cementum

It is formed after the tooth reaches the occlusal plane and as name suggests it contains cells, i.e. cementocytes, that are present in individual spaces known as lacunae which communicates with each other through a system of anastomosing canaliculi. This cementum is less calcified as compared to acellular cementum. Sharpey's fibres are found less in number in cellular cementum.

Classification of Cementum

According to Schroeder, cementum has been classified as follows:

- **Acellular afibrillar cementum (AAC):** This type of cementum neither contains cells nor collagen fibres. It consists of mineralised ground substance. It is produced by cementoblasts with a thickness of 1–15 µm.
- **Acellular extrinsic fibre cementum (AEFC):** It consists of mainly Sharpey's fibres and does not contain any cells. It is produced by fibroblasts and cementoblasts, commonly found in the apical third of the roots. Its thickness is around 30–230 µm.
- **Cellular mixed stratified cementum (CMSC):** It consists of both extrinsic and intrinsic fibres and also consists of cells. It is produced by fibroblasts and cementoblasts. It is found in the apical third of the roots, apex and in furcation areas.
- **Cellular intrinsic fibre cementum (CIFC):** It consists of cells and intrinsic fibres, but does not contain extrinsic fibres. It is formed by cementoblasts.
- **Intermediate cementum:** It consists of cellular remnants of Hertwig's epithelial sheath which is embedded in a calcified ground substance. It is seen near the cemento-dentinal junction.

Composition of Cementum

It consists of an organic portion and an inorganic portion:

- **Organic portion:** The organic matrix of cementum is basically of collagen. Out of which 90% is Type I and 5% Type III collagen. There are two main sources of collagen in cementum:
  1. **Sharpey's fibres** are also known as extrinsic fibres. They are the embedded portions of the principal fibres of the periodontal ligament (PDL). They are produced by fibroblasts.
  2. **Intrinsic fibres:** They belong to the cemental matrix and are produced by cementoblasts.

JAYPEE BROTHERS

Sharpey's fibres form the major bulk of cementum and is composed of Type I collagen. Type III collagen coats the Type I collagen of Sharpey's fibres. Ground substance consists of proteoglycan, glycoproteins and phosphoproteins.

- **Inorganic portion:** It is around 45–50% and is mainly composed of hydroxyapatite. Inorganic component of cementum is less than bone, enamel and dentine.

Functions of Cementum

- Cementum provides anchorage to the tooth in its socket. The ends of PDL fibres are embedded into the cementum, which helps in achieving this.
- Cementum helps in maintain the occlusal relationships. Whenever there is attrition, the incisal or the occlusal surface gets abraded, because of which the tooth is supra-erupted, to compensate for this occlusal discrepancy. Cementum gets deposited at the apex of the tooth, in such situations.
- It also maintains the integrity of root surface, by acting as a reparative tissue for the root.

SHORT ESSAYS

Question 1

What is cemento-enamel junction (CEJ)?

Answer

It is that junction where the cementum and enamel meet. There are three types of CEJ:

1. Cementum overlapping the enamel: It is seen in 60–65% cases.
2. Edge to edge contact: It is also referred as butt joint. It is seen in 30% of cases.
3. Gap between cementum and enamel: In this case the cementum and enamel do not meet. It is seen in 5–10% cases **(Fig. 4.1)**.

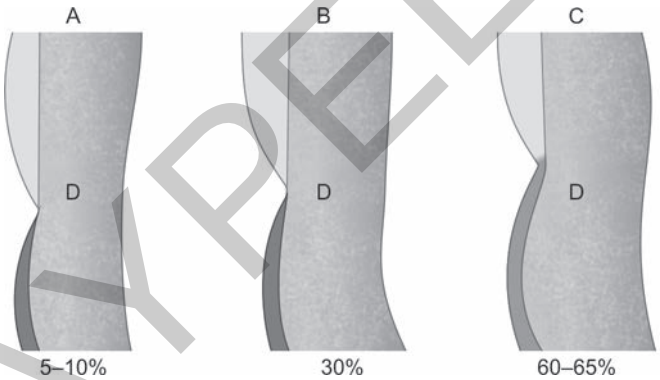

Fig. 4.1: Normal variations in tooth morphology at cemento-enamel junction. (A) Space between enamel and cementum with dentin (D); (B) End-to end relationship of enamel and cementum and (C) cementum overlapping the enamel.

Question 2

What is cemento-dentinal junction (CDJ) ?

Answer

- The part of cementum, which joins to the internal root canal dentine is referred to as CDJ.
- The width of CDJ remains almost constant throughout life.
- It is around 2–3 µm wide.
- It consists significant amount of proteoglycans, and the fibrils inter-mingle between the cementum and the dentine **(Fig. 4.1)**.

Question 3

What is cementum attachment protein (CAP)?

Answer

- It is a cementum-derived collagenous protein.
- It promotes spreading and adhesion of mesenchymal cell types.
- Osteoblasts and fibroblasts shows better adhesion than keratinocytes and gingival fibroblasts.

Question 4

What is cementum derived growth factor (CGF)?

Answer

- It is an insulin like growth factor like molecule.
- It helps in proliferation of PDL cells and gingival fibroblasts.

JAYPEE BROTHERS

Question 5

What are the functions of cementum?

Answer

- Cementum provides anchorage to the tooth in its socket. The ends of PDL fibres are embedded into the cementum, which helps in achieving this.
- Cementum helps in maintain the occlusal relationships. Whenever there is attrition, the incisal or the occlusal surface gets abraded, because of which the tooth is supra-erupted, to compensate for this occlusal discrepancy. Cementum gets deposited at the apex of the tooth, in such situations.
- It also maintains the integrity of root surface, by acting as a reparative tissue for the root.

Question 6

What is cementum resorption and repair?

Answer

- Cementum of erupted as well as unerupted teeth undergoes some amount of cemental resorption that may be of microscopic proportion.
- There are various local and systemic factors that are responsible for cemental resorption.
- Various local factors responsible for cemental resorption are as follows:
  - Trauma from occlusion
  - Orthodontic tooth movement
  - Pressure from mal-aligned erupting teeth
  - Cysts and tumours
  - Teeth without functional antagonists
  - Embedded teeth
  - Re-planted and transplanted teeth
  - Periapical disease
  - Periodontal disease.
- Various systemic factors responsible for cemental resorption are as follows:
  - Calcium deficiency
  - Hypothyroidism
  - Hereditary fibrous osteodystrophy
  - Paget's disease.
- Microscopically cementum resorption appears as bay like concavities in the root surface.
- Multi-nucleated giant cells and large mononuclear macrophages are seen adjacent to cementum undergoing resorption.
- Several resorption sites coalesce to form large areas of destruction.
- Resorption may extend into dentine and pulp, but is generally painless.
- Resorption may not always be continuous, but it may alternate with periods of repair, with deposition of cementum.
- The newly formed cementum may be demarcated by a deeply staining irregular line, referred to as reversal line.
- Embedded fibres of PDL forms a functional relationship with new cementum.
- Viable connective tissue is required for cementum repair.
- Cementum repair can take place in vital as well as non vital teeth.

Question 7

What are reversal lines?

Answer

- In periods of repair of cementum, the newly formed cementum is differentiated from the root by a deeply staining irregular line, which is known as reversal line. Reversal line consists of few collagen fibrils and a high content of proteoglycans with glycosaminoglycans.
- Fibril intermingling takes place in between reparative cementum and resorbed cementum or dentin. This takes place only at few places.
- Embedded fibres of the PDL re-establishes a functional relationship with the newly formed cementum.

Question 8

What is hypercementosis?

Answer

- Hypercementosis is also referred to as cemental hyperplasia.
- It is thickening of the cementum.
- It is mainly an age related process, and it may effect a single tooth or the entire dentition.

JAYPEE BROTHERS

- It appears as a nodular enlargement at the apical one-third or appear as spike like excrescences because of fusion of cementicles to the root or because of calcification of periodontal fibres which are embedded into cementum.

Causes of Hypercementosis

There can be two types of hypercementosis:

1. **Localised:** It is seen in teeth without antagonist to keep pace with active eruption. It is believed to be a compensatory mechanism to counteract the destruction of fibrous attachment of the tooth.
2. **Generalised:** It can be due to hereditary reasons or patients having Paget's disease. Acromegaly, arthritis, calcinosis, rheumatic fever and thyroid goitre are some of the systemic conditions associated with generalized hypercementosis.

Radiographic Features

- Lamina dura appears radiopaque and periodontal appears radiolucent, as it is seen in normal situation.
- Periapical cemental dysplasia, condensing osteitis, and focal periapical osteoporosis can be differentiated from hypercementosis that the above mentioned conditions fall outside the shadow of periodontal and lamina dura.

Clinical Significance

- Treatment is not required in cases of hypercementosis
- Extraction in such conditions can create a problem. In cases of multirooted teeth, sectioning of the tooth should be done before extraction procedure.

Question 9

Define ankylosis?

Answer

- Fusion of cementum with bone with obliteration of PDL is referred as ankylosis.
- Ankylosis may be seen in following situations.
  - It is a feature of abnormal repair as it occurs in teeth with cemental resorption.
  - After chronic periapical inflammation.
  - Tooth replantation.
  - Occlusal trauma
  - Around embedded teeth.
- Diagnostic sign for ankylotic resorption are:
  - Lack of physiologic mobility.
  - Upon percussion, there is usual a metallic sound.
  - Teeth would be in infra-occlusion, if the ankylotic process continues.
- Proprioception is lost in ankylosed teeth, since PDL is replaced by bone. The pressure receptor in the PDL is deleted or does not function.
- Also due to absence of periodontium, the physiologic drifting and movement of teeth does not take place.
- Resorption lacunae are filled with bone, and the periodontal space is absent.
- Treatment options for ankylosed teeth are as follows:
  - Restorative intervention.
  - Surgical extraction of the affected tooth.

Question 10

Enumerate the various differences between cellular and acellular cementum.

Answer

Acellular cementum	Cellular cementum
• It is also known as primary cementum.	• It is also known as secondary cementum.
• It is formed before the teeth reaches the occlusion.	• It is formed after the teeth has reached occlusion.
• It is devoid of cells.	• It contains cementocytes.
• Sharpey's fibre make up the bulk.	• Sharpey's fibre are found in smaller proportions.
• Seen at the coronal portion	• Seen at apical portion.
• Slow formation.	• Rapid formation.
• Collagen fibres are more organised.	• Collagen fibres are irregularly arranged.

JAYPEE BROTHERS

for detailed information on dental books, visit our website **www.jaypeebrothers.com,** for detailed information on dental books, visit our website **w**

Essential Quick Review

Periodontics

Essential Quick Review (EQR) is a simple and comprehensive series that contains all the important aspects of the final year syllabus. The language used here is lucid as well as scientific which can be easily gathered and reproduced in examinations. Efforts have been made to cover all important areas in the form of question–answers, definitions and classifications format. We hope that this effort of ours will prove out to be beneficial for students



Priya Verma Gupta is an experienced pedodontist, currently working as Professor at Divya Jyoti College of Dental Sciences and Research, Modinagar, Ghaziabad, Uttar Pradesh, India. She has keen interest in academics and has many international and national publications to her credit. She has so far authored four books and has contributed actively to other medical and dental textbooks as a co-author as well as contributor. Currently, she is associated with the editorial board of Journal of Indian Medical Gazette and Jaypee's International Journal of Clinical Pediatric Dentistry.



Vinita Ashutosh Boloor BDS MDS is an Associate Professor in Department of Periodontics, Yenepoya Dental College, Yenepoya University, Deralakatte, Mangalore, Karnataka. She completed BDS from SDM College of Dental Sciences, Dharwad and MDS from AB Shetty institute of Dental Sciences, Mangalore, Karnataka. Dr Boloor has authored a book and has various national and international publications to her credit.

Available at all medical bookstores
or buy online at www.jaypeebrothers.com

JAYPEE

JAYPEE BROTHERS
Medical Publishers (P) Ltd.
www.jaypeebrothers.com

Join us on facebook.com/JaypeeMedicalPublishers

Shelving Recommendation
DENTISTRY

ISBN 978-93-86056-18-4

9 789386 056184