ed information on PGMEE books, visit our website www.jaypeebrothers.com, for detailed information on PGMEE books, visit our website www.jaypeebrothers.com



Catalyst for all PG Medical Examinations

PLATINUM NOTES

2015–16

Platinum Notes

Thoroughly Revised and Updated Edition Including Latest Exam Topics, Questions and Image-based Concept

Completely updated till 2016

Volume 3

Surgical Sciences

Surgery, Obstetrics & Gynecology, Orthopedics, Ophthalmology, ENT, Anesthesiology

Important Topics Covered

AIPGMEE, AIIMS, PGI, Delhi PGMEE, Rajasthan PGMEE, UP PGMEE, Karnataka PGMEE, AP PGMEE, J&K BOPEE, Tamil Nadu PGMEE, Kolkata PGMEE, Bihar & Jharkhand PGMEE, Kerala PGMEE, MP PGMEE, DNB, Orissa PGMEE, and Maharashtra PGMEE

Latest Topics Covered from NBE 2015, DNB 2013, AIIMS 2015

5th Edition

Ashfaq Ul Hassan

Contents

1. Surgery 1
2. Obstetrics and Gynecology 191
3. Orthopedics 297
4. Ophthalmology 369
5. ENT 429
6. Anesthesiology 485

Ophthalmology



JAYPEE BROTHERS

4 Ophthalmology

ANATOMY AND IMPORTANT DIMENSIONS OF EYE

• Diameter of Macula:	• 5.5 mm	
• Diameter of Fovea:	• 1.5 mm	
• Diameter of optic disk:	• 1.5 mm	JK 2001
• Diameter of Fovela:	• 0.35 mm	

• Anteroposterior Length of eye ball	• 24 mm	UP 1997
• Height of eye ball:	• 23 mm	
• Vertical Length of eye ball:	• 23 mm	
• Circumference of eye ball:	• 70 mm	
• Depth of anterior chamber:	• 2–3 mm	AI 1992
• Volume of eye ball:	• 6.5 ml	
• Volume of vitreous	• 4 ml	JK 2001
• Volume of Orbit	• 30 cc.	JK 2007

- Thickness of lens is **3.5–5 mm.**
- **Critical angle of Cornea–Air Interface: 46 Degrees.** **AIIMS 2014**

MUSCLES OF EYE AND THEIR INNERVATIONS (SPECIAL HIGH YIELD FOR EXAMS 2016)

- The **'Extorter'** of Eye Ball is **Inferior Oblique and Inferior Rectus.**
- The **'Intorter'** of Eye ball is **Superior Oblique and Superior Rectus.** **PGI 2004, AIIMS 1995**
- Action of Superior oblique is **Abduction, Intorsion and depression**. **PGI 1997**
- Dilator Pupillae dilates pupil and is supplied by ***Sympathetics*.**
- Sphincter Pupillae constricts pupil and is supplied by ***Parasympathetics***.
- **LR_6S0_4**
- Lateral Rectus is supplied by **6th Cranial Nerve** (Abducent)
- Superior Oblique is supplied by **4th Cranial Nerve** (Trochlear) **AIIMS 2004**
- Rest other ocular muscles are supplied by **3rd Cranial Nerve** (Oculomotor)
- Levator palpebrae superioris is supplied by 3rd cranial nerve. **MAHE 2005**
- Muscle attached to posterior tarsal margin: **Müller's muscle** **KERALA 1994**

Contd...

JAYPEE BROTHERS

Contd…

- **Third nerve** gets affected in a variety of syndromes of Mid Brain such as: **PGI 1988**
  - **Benedikt's Syndrome**
  - **Claude's Syndrome**
  - **Weber's Syndrome**
  - **Nothangel's Syndrome**

Trigeminal nerve (Fifth Cranial nerve) is involved in **afferent pathway of corneal reflex.**

Muscles in Opthomology:

VOLUNTARY extraocular muscles:
- **Four recti**
- **Two oblique**
- **Levator palpebrae superioris**

INVOLUNTARY extraocular muscles:
- **Superior tarsal**
- **Inferior tarsal**
- **Orbitalis**

Glands of Eye

- **Zeis glands**: large sebaceous glands
- **Moll's glands**: sweat glands
- **Meibomian glands**: tarsal glands

Vascularity of Eye is by

Structure	Blood Supply
• Uveal tract	• Ciliary arteries
• Conjunctiva	• Palpebral branches of nasal and lacrimal arteries
• Cornea	• Avascular
• Sclera	• Avascular
• Lens	• Avascular
• Optic nerve	• Ophthalmic artery.

Gems about Pupil:

- Sphincter pupillae is a circular **'constrictor muscle'** innervated by **Parasympathetic** Nervous system.
- Dilator Pupillae is a **'radial dilator'** innervated by **Sympathetic** Nervous system.
- Pupillary inequality is called '**Anisocoria'.**
- **III Nerve lesion** causes **dilated pupil, Ptosis.** **AIIMS 2011**
- **Horner's syndrome causes constricted pupil.**
- **Argyll Robertson Pupil:** small pupils, irregular in shape which do not react to light but react to accommodation. **(ARP: Accommodation Reflex present)** **TN 1999**
- **Marcus Gunn Pupil (Pupillary Escape):** Illumination of one eye normally produces constriction. In case light source is swung from eye to eye, affected pupil may **'paradoxically' dilate. (Marcus Gunn Pupil) (Defect anterior to optic chiasma)** **MAHE 2005**
- **Aides Pupil** is dysfunction of constrictor muscle and hence does not respond to light or to accommodation **(Tonic pupil)**

JAYPEE BROTHERS

Absolute Afferent Pupillary Defect

An absolute afferent pupillary defect **(Amaurotic pupil)** is caused by a **complete optic nerve lesion** and is characterized by:
- The **involved eye is completely blind** (i.e. no light perception).
- Both pupils are **equal in size**.
- When the affected eye is stimulated by light neither pupil reacts but when the normal eye is stimulated both pupils react normally.
- The **near reflex is normal** in both eyes.

RELATIVE AFFERENT PUPILLARY DEFECT (HIGH YIELD FOR EXAMS 2016)

Also called as (Marcus Gunn pupil) is caused by an **incomplete optic nerve lesion** or severe retinal disease. Thus the pupils respond weakly to stimulation of the diseased eye and briskly to that of the normal eye. The difference between the pupillary reactions of the two eyes is highlighted by the **swinging-flashlight test** in which a light source is alternatively switched from one eye to the other and back, thus stimulating each eye in rapid succession.
- When the normal eye is stimulated both pupils constrict.
- Then when the light **is swung to the diseased eye, both pupils dilate instead of constricting.**
- When the normal eye is stimulated, both pupils constrict.

Marcus Gunn Jaw Winking Syndrome

- Usually unilateral.
- Abnormal regeneration like in Frey's syndrome. That a **branch of the mandibular division of the fifth cranial nerve is misdirected** to the levator muscle.
- Retraction of the ptotic lid in conjunction with stimulation of the ipsilateral pterygoid muscles by **chewing, sucking, opening the mouth or contralateral jaw movement**.
- Less common stimuli to winking include jaw protrusion, smiling, swallowing and clenching of teeth.
- **Treatment is with** Surgery if jaw-winking or ptosis represents a significant functional or cosmetic problem.

Cornea

- **The cornea is quite unlike most tissues in that it is perfectly transparent.**
- **The epithelium** consists of a thin layer of **non-keratinized stratified squamous**, **PGI 2001**
- Corneal epithelium is **very thin (**only a few cells thick).
- Corneal epithelium lies flat against the underlying substantia propria.
- There is **absence of connective tissue** papillae
- **The Basement membrane** between corneal epithelium and substantia propria is exceptionally thick and is called **Bowman's membrane**.
- **The substantia propria** of the cornea is mostly collagen and ground substance, with fibroblasts as the most common cell type. **AIIMS 1986**
- Collagen of the cornea is organized into extremely **regular layers**. All the collagen fibers in one layer arranged in parallel, and alternating layers run in different directions. **AIIMS 1986**
- Corneal connective tissue has no blood vessels.
- Even though cells of the cornea are not very active metabolically, they still need oxygen and nutrients.
- As long as the cornea is in direct contact with air, oxygen can be absorbed directly. **AI 1996**
- Nutrients can diffuse into cornea from aqueous humor. **(avascular coat)** **PGI 1999**
- Cells of corneal connective tissue are limited to fibroblasts.
- **There is** no immune-system component**;** hence the relative ease with which corneal tissue can be transplanted without need for careful tissue typing.
- **Descemet's membrane** is a thick basal lamina made of elastic fibers over endothelium.
- **Corneal endothelium** is simple squamous epithelium present below Descemet's membrane. Corneal epithelium contains **free nerve endings**. Since pain seems to be the only sensation of cornea.

JAYPEE BROTHERS

Layers of Retina

- Retinal pigment epithelium (RPE)
- Layer of rod and cone cells outer segments
- Outer limiting membrane
- Outer nuclear layer
- Outer plexiform layer
- Inner nuclear layer
- Inner plexiform layer
- Ganglion cell layer MOST RESISTANT TO RADIATION **AIIMS 2011**
- Nerve fiber layer
- Internal limiting membrane.

The 'Medial Longitudinal Fasciculus' (AIIMS 2008)

The Medial longitudinal fasciculus (MLF) connects the
- **Oculomotor (III),**
- **Trochlear (IV), and**
- **Abducens (VI) nuclei** and

is essential for **conjugate gaze.** **SGPI 2005**

'A lesion in the MLF will result in the inability to medially rotate (adduct) the ipsilateral eye on attempted lateral gaze.' (**Intranuclear opthalmoplegia (INO)**) **AIIMS 2002**

However, a lesion of the motor fibers of the right oculomotor nerve would also lead to the same symptoms. The way to truly distinguish between an INO from a lesion of the medial rectus muscle or a lesion of the motor fibers of CN III is to determine whether the patient can converge her eyes. If the innervation of the medial rectus muscle is interrupted, the patient will not be able to move the ipsilateral eye medially for either conjugate or dysconjugate (convergence) movements. **However, if the lesion is in the MLF, this would only affect conjugate movement, and not convergence.**

Important Membranes in Ophthalmology

• **Bowman's Membrane**	**'Anterior' limiting membrane of Cornea**
• **Descemet's Membrane**	**'Posterior' limiting membrane of Cornea**
• **Bruch's Membrane**	**Pigment membrane in Retina**
• **Elschnlg's Membrane**	**Astroglial membrane covering Optic Disk**

Important Glands in Ophthalmology

• Glands of **Zeis**:	• **Sebaceous** glands☛☛
• Glands of **Moll**:	• **Modified sweat** glands☛☛
• Glands of **Krause and Wolfring**:	• **Accessory Lacrimal** glands☛☛

Structures Passing Through 'Inferior Orbital Fissure' ☛☛☛

- **Maxillary division** of Trigeminal nerve
- **Infraorbital artery**
- **Zygomatic nerve**
- **Branches of inferior ophthalmic vein**

JAYPEE BROTHERS

Annulus of Zinn

'The Annulus of Zinn', also known as the 'Annular tendon' or 'Common Tendinous Ring' is a ring of fibrous tissue surrounding the optic nerve at its entrance at the apex of the orbit. It is the origin for five of the six extraocular muscles. **JKBOPEE 2015**

Annulus of Zinn (Annulus communis tendinis) is seen to transmit: 👓 **(NAO)**

- **Oculomotor nerve**
- **Nasociliary nerve**
- **Abducent nerve.**

Superior Orbital Fissure

Structures passing through '**Superior Orbital Fissure'** are:
Live Free To See NO Insult At All.

- **Lacrimal Nerve**
- **Frontal Nerve**
- **Trochlear Nerve**
- **Superior Ophthalmic Vein**
- **Nasociliary Nerve**
- **Inferior Ophthlamic vein**
- **Abducent Nerve**

Structures passing through **'Optic Canal':**

- **Optic nerve and ophthalmic artery**

'Optic Nerve Glioma'

- Causes **gradual, painless loss of vision**,
- A tumor of **first decade of life**

Aassociated with

- **Optic atrophy,**
- **Pappiloedema,**
- **Neurofibromatosis**.

Embryology of Eye (Very Important Topic for PG Examinations)

The Eyes are derived from

- The neuroectoderm of the forebrain
- The surface ectoderm of the head
- The mesoderm between the above layers
- Neural crest cells
  - The **neuroectoderm** of the forebrain differentiates into the
  - **Retina,** **MAH 2012**
  - **The posterior layers of the iris, and the optic nerve plus**
  - **Ciliary epithelium,** **PGI 2011**
  - **Sphincter pupillae and** **PGI 2011**
  - **Dilator pupillae** **PGI 2011**
  - The **surface ectoderm** forms the lens of the eye and the corneal epithelium. The mesoderm between the neuroectoderm and surface ectoderm gives rise to the fibrous and vascular coats of the eye. Mesenchyme is derived from mesoderm.

JAYPEE BROTHERS

- Neural crest cells migrate into the mesenchyme from the neural crest and differentiate into the choroid, sclera, and corneal endothelium. Homeobox-containing genes, including the **transcription regulator Pax6, fibroblast growth factors,** and other inducing factors play an important role in the molecular development of the eye.
- Eye development is first evident at the beginning of the **fourth week.**
- **Optic grooves** appear in the neural folds at the cranial end of the embryo. As the neural folds fuse to form the forebrain, the optic grooves evaginate to form hollow diverticula-**optic vesicles**-that project from the wall of the forebrain into the adjacent mesenchyme. The cavities of the optic vesicles are continuous with the cavity of the forebrain. Formation of the optic vesicles is induced by the mesenchyme adjacent to the developing brain, probably through a chemical mediator. As the optic vesicles grow, their distal ends expand and their connections with the forebrain constrict to form hollow optic stalks.
- The optic vesicles soon come in contact with the **surface ectoderm.** Concurrently, the surface ectoderm adjacent to the vesicles thickens to form lens placodes, the primordia of the lenses. Formation of lens placodes is induced by the optic vesicles after the surface ectoderm has been conditioned by the underlying mesenchyme. An inductive message passes from the optic vesicles, stimulating the surface ectodermal cells to form the lens primordia. The lens placodes invaginate as they sink deep to the surface ectoderm, forming lens pits. The edges of the pits approach each other and fuse to form spherical lens vesicles which soon lose their connection with the surface ectoderm. Development of the lenses from the lens vesicles is described after formation of the eyeball is discussed.
- As the lens vesicles are developing, the **optic vesicles invaginate** to form **double-walled** optic cups. The opening of each cup is large at first, but its rim infolds around the lens. By this stage, the lens vesicles have lost their connection with the surface ectoderm and have entered the cavities of the optic cups. Linear grooves-retinal fissures (optic fissures) develop on the ventral surface of the optic cups and along the optic stalks. The fissures contain vascular mesenchyme from which the hyaloid blood vessels develop. The hyaloid artery, a branch of the ophthalmic artery, supplies the inner layer of the optic cup, the lens vesicle, and the mesenchyme in the cavity of the optic cup. The hyaloid vein returns blood from these structures. As the edges of the retinal fissure fuse, the hyaloid vessels are enclosed within the primordial optic nerve. **Distal parts of the hyaloid vessels eventually degenerate, but proximal parts persist as the central artery and vein of the retina.**

Development of the Retina

The retina develops from the walls of the optic cup, an outgrowth of the forebrain. The outer, thinner layer of the optic cup becomes the retinal pigment epithelium (pigmented layer of retina), and the inner, thicker layer differentiates into the neural retina (neural layer of retina).

Congenital Anomalies of the Eye

- **Coloboma of the Retina**
- This defect is characterized by a localized gap in the retina, usually inferior to the optic disk. The defect is bilateral in most cases. A typical coloboma of the retina results from defective closure of the retinal fissure.
- **Coloboma of the Iris:** Coloboma is a defect in the inferior sector of the iris or a notch in the pupillary margin, giving the pupil a keyhole appearance.
- **Congenital Detachment of the Retina**
- **Cyclopia:** In this very rare anomaly, the eyes are partially or completely fused, forming a single median eye enclosed in a single orbit. There is usually a tubular nose (proboscis) superior to the eye.
- **Microphthalmia:** The eye may be very small with other ocular defects or it may be a normal-appearing rudimentary eye. The affected side of the face is underdeveloped and the orbit is small. Microphthalmia may be associated with other congenital anomalies (e.g. trisomy 13). Most cases of simple microphthalmia are caused by infectious agents (e.g. rubella virus, Toxoplasma gondii, and herpes simplex virus) that cross the placental membrane during the late embryonic and early fetal periods.
- **Anophthalmia**: It denotes congenital absence of the eye, which is rare. The eyelids form, but no eyeball develops.

JAYPEE BROTHERS

Mesoderm	Surface ectoderm	Neuroectoderm
Sclera	Corneal epithelium	Epithelium of iris and ciliary body **AIIMS 2003**
Choroid	Conjunctival epithelium **AIIMS 2006**	Muscles of iris (constrictor pupillae and dilator pupillae)
Corneal stroma and endothelium **AIIMS 2009, 2008**	Lens **AIIMS 2006**	**Retinal pigment epithelium**
	Lacrimal and tarsal glands	**Optic** vesicle
Iris **stroma and endothelium**	**L2 C2**	**Optic** nerve
Blood vessels		Part of vitreous
Muscles **except iris muscles**		
But only smooth muscles of iris are derived from mesoderm. **COMED 2006**		
Part of vitreous		

Important Miletones in Development of Eye

- Eye of new borne is '**Hypermetropic'** by 2–3 D **AIIMS 1996**
- Myelination of optic nerve is **complete at birth.**
- Orbit is **divergent.**
- At 6 weeks **Fixation reflex** is apparent.
- At 2–4 months is **critical period** for development of fixation reflex. **AI 1995**
- During **first 6 months** binocular single vision develops.
- Binocular vision has important role in **depth perception**.
- At **6–8 months depth perception** develops.

Angles of Eye

- **Alpha angle:** Between visual axis and optical axis. **AI 1988**
- **Kappa angle:** Between pupillary axis and visual axis. **AI 1988**
- **Visual angle:** angle subtended by object at nodal point of lens. **COMED 2006**

Ophthalmological Tests

Direct ophthalmoscopy	Indirect ophthalmoscopy
Condensing lens **not required**	Condensing lens **required**
Examination **close** to patient	Examination at a **distance**
Image is **virtual and erect**	**Image is real and inverted** **MAH 2012**
Magnification is **15 times**	Magnification **is 5 times** **PGI 1997**
Stereopsis **absent**	Stereopsis **present**
Area of field in focus **is 2 disk diopters**	Area of field in focus **is 8 disk diopters**
Examination through hazy media **not possible**	Examination through **hazy media possible**
Illumination **not so bright**	Illumination **bright**
	Is done for **examination of periphery of retina** up to ora serrata. **PGI 2002**

JAYPEE BROTHERS

- **Keratometry:** Measures **Curvature** of Cornea — **PGI 1999**
- **Pachymetry: Thickness** of cornea
- **Campimetry:** Measures field of vision
- **Electronystagmogram:** Graph of movement of eye: — **AMC 1999**
- **Anomaloscope** detects **color blindness** — **DNB 1990**
- **Retinoscopy: Objective assessment of refractive state of eye.** — **COMED 2008**

Remember

- **Tonometry** measures IOP.
- **Tonography** measures rate of fall in IOP from which facility of aqueous outflow is measured.
- **Gonioscopy measures angle of anterior chamber.** — **PGI 1997**
- **Best type tonometry is applanation tonometry.** — **MAHE 2005**
- **Arden ratio is seen in EOG.** — **AI 2010**

Macular Function is Tested by

- **Indirect slit lamp biomicroscopy**
- **Photo stress test**
- **Two point discrimination test (card board test)** — **MAHE 2005**
- **Amsler grid test** — **PGI 2000**
- **Maddox rod test** — **MAHE 2005**
- **Entopic view test**
- **LASER interferometry.**

Visual Tests Done in Infants

- **Visual evoked potentials**
- **Teller acuity tests**
- **Cardiff acuity tests**
- **Visual acuity by Landolt's rings** — **MAH 2002**

- **Swinging flash light test:** pupil. — **COMED 2008**
- **Snellen's chart tests:** vision. — **KERALA 1994**
- **Retinoscopy** detects errors of refraction. — **CUPGEE 1996**

Hirschberg and Kappa Tests

The Hirschberg test
is done while the child is binocularly viewing the examiner's transilluminator/penlight in primary gaze. The transilluminator/penlight is held at about 50 cm from the child and held just underneath the examiner's observing eye. The examiner observes the location of the corneal reflexes relative the center of the pupil. A nasal displacement is signified by a (+) sign and a temporal displacement is signified by a (–) sign. The amount of displacement is recorded in the distance, in millimeters, away from center. A normal location will likely be either centered, or + 0.5 mm nasally displaced. — **JKBOPEE 2012**

Kappa test
is a test of monocular fixation and is done while the child is monocularly viewing the examiner's transilluminator/penlight. The transilluminator/penlight is maintained at 50 cm away. The purpose of this test is to determine the visual axis of each eye. The examiner observes the location of the corneal reflexes relative the center of the pupil in the right eye and then in the left eye. A nasal displacement is signified by a (+) sign and a temporal displacement is signified by a (–) sign, with the amount quantified in millimeters away from center. Again, a normal location will likely be either centered, or + 0.5 mm nasally displaced.

JAYPEE BROTHERS

ELECTRORETINOGRAPHY (HIGH YIELD FOR EXAMS 2016 AIPGMEE)

The electroretinogram (ERG) is the record of an action potential produced by the retina when it is stimulated by light of adequate intensity.

The normal ERG is **biphasic.**

- **The a-wave** is the initial fast negative deflection directly generated by photoreceptors.
- **The b-wave** is the next slower positive deflection with larger amplitude. Although it is generated from fluxes of potassium ions within and surrounding Müller cells. The b-wave consists of b-1 and b-2 Subcomponents. **The former probably represents both rod and cone activity and the later mainly cone activity.**

Normal ERG: 1. Scotopic ERG, 2. Photopic ERG

Multifocal ERG

Multifocal ERG is a method of producing topographical maps of retinal function. The stimulus is scaled for variation in photoreceptor density across the retina.

Interpretation: As there is much variation in EOG amplitude in normal subjects, the result is calculated by dividing the maximal height of the potential in the light (Light peak) by the minimal height of the potential in the dark (dark trough). This is expressed as a ratio **(Arden ratio)** or as a percentage. The normal value is over 1.85 or 185%.

Visual Evoked Potential:

The visual evoked potential (VEP) is a recording of electrical activity of the visual cortex created by stimulation of the retina. The main indications are monitoring of visual function in babies and the investigation of optic neuropathy, particularly when associated with.

This Farnsworth-Munsell 100 Hue test is an easy-to-administer but highly effective method for measuring any individual's color vision.

The test consists of four trays containing a total of 85 removable color reference caps (incremental hue variation) spanning the visible spectrum. Color vision abnormalities and aptitude are detected by the ability of the test subject to place the color caps in order of hue. The Farnsworth-Munsell 100 Hue Test itself is used to separate persons with normal color vision into classes of superior, average and low color discrimination and to measure the zones of color confusion of color defective people.

Some examples of its use are:

- Examination of inspectors of color goods, color graders and color matchers.
- Testing for type and degree of color defectiveness.
- Detection of poor color vision in sales people.
- Selection of applicants for vocational training.
- Design of specialized tests for color vision.
- Measurement of effects of medical treatments.
- Independent control on validity of other color vision tests.

The Farnsworth-Munsell Dichotomous D-15 Test is an abridged version of the 100 Hue Test that is intended for screening color vision defects only. It can be used to detect color vision defects such as red-green and blue-yellow deficiencies as opposed to color acuity. Contains a reference cap and 15 numbered disks with all different hues.

Important Points About Lid

Chalazion of Lid

- **It is also called as tarsal or meibomian cyst.**
- It is a chronic noninfective granulomatous inflammation of meibomian glands.
- It usually presents as a painless swelling in the eyelids.
- **It is characterized by Lipogranulomatous inflammation.** **AIIMS 2014**
- **Secondarily infected Chalazion is Internal Hordeolum.**
- **It presents as a gradually enlarging painless nodule.**
- **It may resolve spontaneously.**

JAYPEE BROTHERS

Hordeolum Externum is Stye: Inflammation of Zeis Glands

Hordeolum Internum: is Suppurative Inflammation of Meibomian Glands

- **'Recurrent' chalazion is predisposed to sebaceous cell carcinoma.** **AIIMS 2006**
- **'Basal cell carcinoma' is the most common type of lid carcinoma.** **AIIMS 1996**
- **Adhesion of margins of two lids is called ankyloblepharon.** **MANIPAL 2006**

Congenital Chronic Dacryocystitis

- Failure of nasolacrimal duct to open into inferior meatus of nose leads to dacryocystitis.
- Presents with **epiphora (abnormal tear overflow)** **AI 2002**
- **Regurgitation of pus**.
  - **Congenital blockage**
  - **Presence of epithelial debris**
  - **Membranous occlusion at its upper end near lacrimal sac**
  - **Complete non-canalization**
  - **Rarely bony occlusion**

Treatment options for congenital NLD obstruction are:

- **Massage over the lacrimal sac area and topical antibiotics**
- **Lacrimal syringing (irrigation) with normal saline and antibiotic solution**
- **Probing of NLD with Bowman's probe**
- **Intubations with silicone tube**
- **Dacryocystorhinostomy (DCR)**
- **Conjunctivocystorhinostomy.** **PGI 2005**

FIELD DEFECTS

'Visual field defects'

The main points for the exam are:

- **Left homonymous hemianopia means visual field defect to the left, i.e. lesion of right optic tract** **DNB 2011**
- Homonymous quadrantanopias: **PITS** (Parietal-Inferior, Temporal-Superior)
- Incongruous defects = optic tract lesion; congruous defects = optic radiation lesion or occipital cortex

Homonymous hemianopia

- **Incongruous defects: lesion of optic tract☛☛** **SGPI 2005**
- **Congruous defects: lesion of optic radiation or occipital cortex☛☛**
- **Macula sparing: lesion of occipital cortex☛☛**

Homonymous quadrantanopias

- Superior: lesion of temporal lobe☛☛ **PGI 2003, PGI 2002**
- Inferior: lesion of parietal lobe☛☛
- Mnemonic = PITS (Parietal-Inferior, Temporal-Superior)

Bitemporal hemianopia **AIIMS 2002**

- Lesion of **optic chiasm**
- **Upper quadrant defect > lower quadrant defect** = **inferior chiasmal compression**, commonly a pituitary tumor
- **Lower quadrant defect > upper quadrant defect** = **superior chiasmal compression**, commonly a craniopharyngioma

CRANIAL NERVE II (OPTIC NERVE)

- It is the nerve of **Vision**.
- It is **not a true nerve** but basically a **diverticulum of the brain** or a tract of the CNS.
- It is **covered by the meninges** and hence any infection can spread directly to the brain.
- The Optic nerve has **no neurilemma** sheath and once damaged it **cannot regenerate**.
- It leaves the Orbit through the **Optic Canal**.

JAYPEE BROTHERS

<u>The complete Optic Pathway has</u>: **PGI 2002**
- A receptor
- A pathway to the Thalamus
- A nucleus in the Thalamus
- A radiation from the thalamus to the Cortex
- A sensory area in the Cortex

The receptors are the **rods and cones of the retina** and the thalamic nucleus for vision is the **lateral geniculate body**.

Functionally, the **retina** is composed of 3 elements, i.e. three neurones carry the impulses in the retina 'Itself', these are:

- The receptor cells (the rods and cones)
- The bipolar nerve cells
- The ganglion cells.

- The **rods and cones** synapse with the bipolar cells (in the retina).
- The **bipolar cells** synapse with the ganglion cells (in the retina also).
- The **axons of the ganglion cells** from the **OPTIC NERVE** which contains nasal and temporal fibers.
- The optic nerves pass to the **OPTIC CHIASMA** (which lies immediately in front of the pituitary gland).
- The **nasal fibers of the optic nerve cross to the opposite side while the temporal fibers remain on the same side.**
- The part of the visual pathway which passes backwards from the chiasma is called the **OPTIC TRACT**.
- Each optic tract carries «**temporal» fibers of its «own» side and «nasal» fibers from the «opposite» side.**
- Most of the fibers of the optic tract end in the **lateral geniculate body** while some fibers leave the optic tract to end in the **superior colliculus** of the midbrain and in the **pretectal nucleus**.

- The fibers of the optic tract which reach the superior Colliculus and the pretectal nucleus are concerned with the light reflex (i.e. narrowing of the pupil in response to excess light) while those fibers of the optic tract which reach the **lateral geniculate body** from part of the visual pathway which will reach the visual cortex.
- **The OPTIC RADIATION (or the geniculocalcarine tract)** [<u>The pathway from the lateral geniculate body to the visual area of the cortex</u>]
- **The lateral geniculate body (LGB) is the thalamic center for vision.**
- The axons of the cells of the LGB form the **«optic radiation»** which passes in the internal capsule to reach to the **«striate area» or the Area 17 or the Visual Area in the occipital lobe.**
- **The optic radiation has** fibers running downwards and forwards.

The visual area
- The **«Visual Area»** surrounds the calcarine fissure on the medial surface of the occipital lobe. It is formed of the **cuneus** and the **lingual gyrus.**

- Destruction to one **optic nerve** → **blindness** in the corresponding eye
- Lesion to the middle part of the optic **chiasma** is produced usually from a rumor of the pituitary gland (which lies very close to the optic chiasma). The nasal fibers of the optic nerve which decussate in the chiasma are destroyed and visual impulses from the nasal halves of each retina cannot pass to the optic tract; this means that there will be a **defect in the temporal field of each eye** (a condition called **Bitemporal hemianopia**); in this case the left eye does not see images in the left ½ if its field and the right eye does not see images in the right ½ of its field **AIIMS 2006**, **PGI 2001**
- **<u>A lesion of the optic tract interrupts fibers from one half of each retina. If the left tract is destroyed, visual function will be lost in the left halves of both retinas. In this case there is blindness for objects in the right ½ of each field of vision; this condition is called right homonymous hemianopia</u>.** In spite of the fact that one optic tract may be completely interrupted, vision is sometimes preserved in small area (the area of the macula) which is the center of fixation of the eye. **DNB 2011**
- A lesion which destroys the **left optic radiation** → **right homonymous hemianopia** (as in case of lesion of the left optic tract) **PGI 1997**

JAYPEE BROTHERS

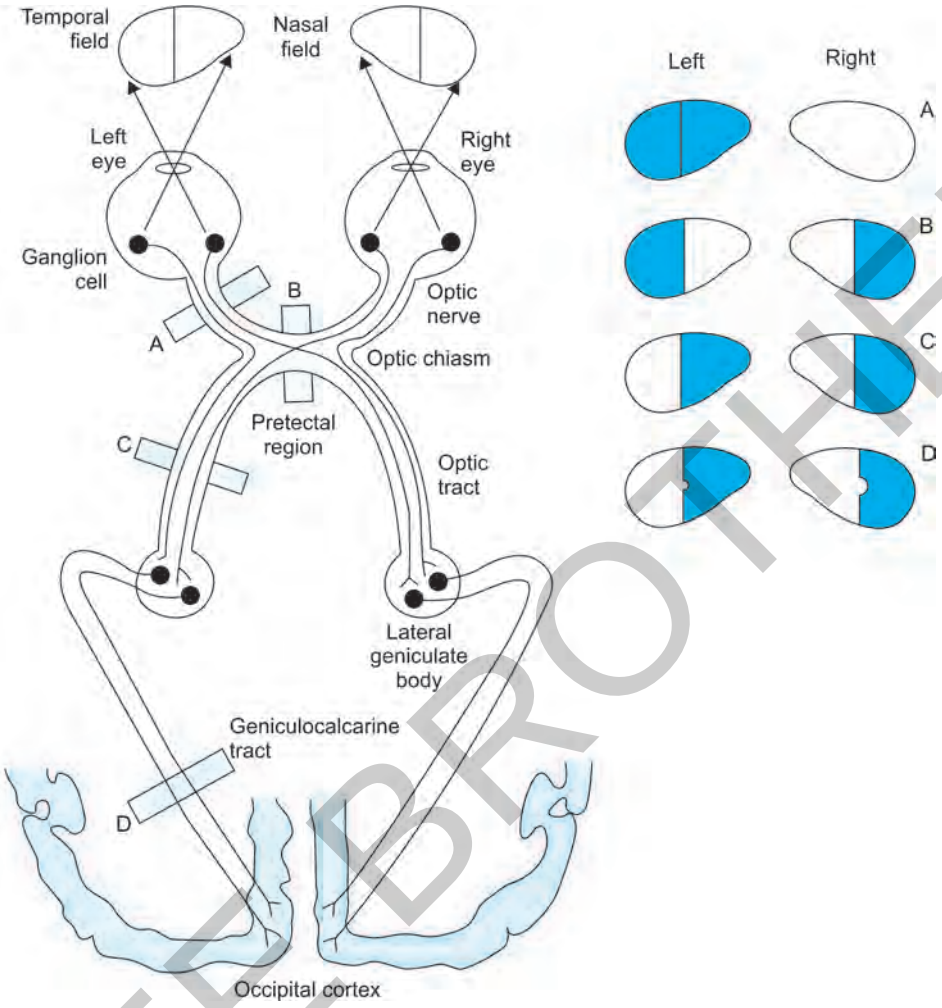

- Destruction of area 17 causes blindness.
- Destruction of area 18: Patient can see but cannot recognize what he sees. This is called as 'Mind blindness'
- Destruction of area 19: Patient may be able to recognize objects but cannot recall their meaning. This is called 'Word Blindness'.

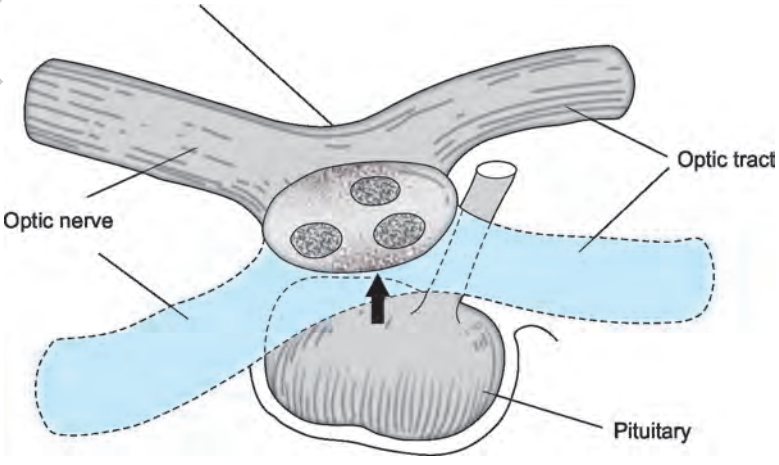

The pituitary tumor compressing the optic chiasma

JAYPEE BROTHERS

for detailed information on PGMEE books, visit our website www.jaypeebrothers.com, for detailed information on PGMEE books, visit our website www.jaypeeb

PLATINUM NOTES

Platinum Notes

Volume 3: Surgical Sciences

Ashfaq Ul Hassan

- Passed IELTS and Plab 1 (2002)
- Passed Plab 2 (2003)
- Passed J&K Board PG examinations (MS Anatomy) (2004)
- Passed USMLE 1(2007)
- Passed J&K Public Services Written and Oral Examinations (2007)
- Passed USMLE 2 (2007)
- Passed MOH United Arab Emirates Examinations (2007)
- Passed Dubai Healthcare City Examinations (2007)
- Passed J&K Board PG examinations (MS) (2009)
  - Senior Resident—Anatomy GMC, Srinagar, J&K, India
  - Resident Dermatology GMC, SMHS, Srinagar, J&K, India
  - Resident Radiology GMC, SMHS, Srinagar, J&K, India
  - SHO Trauma/Orthopedics, UK
  - SHO Accident/Emergency, UK
  - SHO Medicine, UK
  - HO Resident, Surgery, UK

Why this book?

Getting a good rank in PG examinations is a dream for every student. Revising and remembering all the subjects in a short period of time and concentrating on vital information on high-yield topics forms the core of success for PG examinations.

I have tried my level best with suggestions from toppers from ALL INDIA, AIIMS and PGI to present the most valuable information in this book for preparing Postgraduate Medical Entrance Examinations.

The book is in a different format with highly concentrated, core information which no student can afford to miss in anyway. With little experience that I have, all my efforts towards preparation of this book, is of such nature so that MBBS students from any part of country appearing in any examination can benefited.

I recommend the students to go through the text with a high degree of concentration and alertness and make maximum revision so as to acquire a top rank and I am sure that every student will find this book valuable, not only in keeping you one-step ahead of examinee but also in getting good rank in PG examination.

Salient Features

- Keeping in view the latest trends in all PG Medical Entrance Examinations, the book is designed in a manner to provide details in all important topics asked in various states and ALL INDIA, AIIMS and PGI examinations.
- Detailed explanation of all important topics in a simple language with the help of tables, flow charts and mnemonics.
- Saves a lot of TIME of looking up the TOPIC in various textbooks.
- Covers latest and old examinations (updated till ALL INDIA 2012, AIIMS 2015, PGI 2015).
- Highlights all questions asked in various examinations in the topic for emphasis.
- Emphasis on HIGH-YIELD TOPIC.
- Prepared in consultation with TOPPER's from ALL INDIA, AIIMS and PGI.
- An indispensable book for not only last minute revision but for thorough retention of important points and topics throughout the year.

Available at all medical bookstores
or buy online at www.jaypeebrothers.com



JAYPEE BROTHERS
Medical Publishers (P) Ltd.
www.jaypeebrothers.com

Join us on facebook.com/JaypeeMedicalPublishers

