& gynecology books, visit our website **www.jaypeebrothers.com,** for detailed information on obstetrics & gynecology books

OBSTETRICS

3rd Edition

Essentials of OBSTETRICS







Editors
Sabaratnam Arulkumaran
V Sivanesaratnam
Alokendu Chatterjee
Pratap Kumar

Foreword
Shirish S Sheth

JAYPEE

Contents

Section 1 Introduction

Chapter 1. Fundamentals of Reproduction 3

BN Chakravarty

- *Development of Morphologically and Functionally Competent Gametes* 4
- *Maturation and Fertilizing Competence of the Gametes* 5
- *Anatomy of Human Spermatozoa* 14
- *Events Leading to Release of Gametes, their Transport, Fusion and Fertilization, Cleavage and Implantation* 17
- *Fertilization* 19
- *Endometrial Preparation for Implantation (Endometrial Receptivity)* 19

Chapter 2. Anatomy of Female Reproductive Organs 24

Lubna Sheikh, Soma Mukherjee

- *Vulva* 24
- *Vagina* 25
- *Uterus* 25
- *Fallopian Tubes* 26
- *Ovaries* 26

Chapter 3. Anatomy of the Female Pelvis 27

James Leggett, Soma Mukherjee

- *Bony Pelvis* 27
- *Muscles of the Pelvic Wall* 27
- *Female Urological System* 28
- *Pelvic Floor* 30
- *Perineum* 31
- *Pelvic Pouches and Ligaments* 31
- *Pelvic Vessels* 32
- *Pelvic Nerves* 32
- *Pelvic Lymphatic Drainage* 33

Chapter 4. Pelvis and Fetal Skull 34

Amar R, Pratap Kumar

- *Pelvis—the Passage* 34
- *Fetus—the Passenger* 38
- *Fetopelvic Relationships* 40

Chapter 5. Contracted Pelvis, Cephalopelvic Disproportion and Trial of Labor 41
Amar R, Pratap Kumar
- *Classification of Pelvis* 41
- *Contracted Pelvis* 43
- *Diagnosis of Contracted Pelvis* 43
- *Cephalopelvic Disproportion* 45
- *Trial of Labor* 47

Chapter 6. Diagnosis of Pregnancy 48
Rajesh Bhakta, Pratap Kumar
- *First Trimester (1–13 Weeks)* 48
- *Second Trimester (14–28 Weeks)* 51
- *Third Trimester (29–40 Weeks)* 54
- *Differential Diagnosis of Pregnancy* 55

Chapter 7. Physiological Changes in Pregnancy 56
Wong Yat May
- *Placental Hormone Secretion* 56
- *Cardiovascular System* 57
- *Hematology* 59
- *Respiratory System* 60
- *Renal System* 60
- *Gastrointestinal System* 61
- *Endocrine Systems* 61

Chapter 8. Endocrinology of Pregnancy 64
Subrata Lall Seal, Joydev Mukherji, Subir Kumar Bhattacharyya
- *Steroid Hormones* 65
- *Role of Progesterone* 66
- *Role of Estrogens* 67
- *Human Chorionic Gonadotropin (hCG)* 68
- *Human Placental Lactogen (HPL)* 71

Chapter 9. Immunology of Pregnancy 76
A Padma Rao
- *Basic Immunology* 77
- *Summary of Immunoregulation* 78
- *Pregnancy Immunology* 78

Chapter 10. Fetus, Placenta and Membranes 82
Anita Thomas, Pratap Kumar
- *Placenta* 82
- *Amnion and Umbilical Cord* 85
- *Fetus* 87

Chapter 11. History and Examination of a Pregnant Mother 89
Lucie Spooner, Soma Mukherjee
- *History* 89
- *Examination* 91

Chapter 12. Miscarriage 93

Suku Mathew George, Pratap Kumar

- *Incidence* 93
- *Pathology* 93
- *Classification* 94
- *Etiology of Miscarriage* 95
- *Clinical Features* 96
- *Management* 96

Chapter 13. Ectopic Pregnancy 100

Si Lay Khaing

- *Management of Unruptured Stable Ectopic Pregnancy* 106

Chapter 14. Safe Motherhood 109

Alokendu Chatterjee, Partha Mukherjee, Somajita Chakrabarty

- *Janani Suraksha Yojana* 113
- *New Goals and Target* 114

Section 2 Fetomaternal Medicine

Chapter 15. Antenatal Care 119

Lauren Lacey, Soma Mukherjee

- *Aims of Antenatal Care* 119
- *Preconception Counseling* 119
- *General Lifestyle Advice* 120
- *First Trimester* 120
- *Second Trimester* 121
- *Third Trimester* 122

Chapter 16. Hyperemesis Gravidarum 123

Duru Shah, Sudeshna Ray

- *Pathogenesis* 124
- *Diagnosis and Clinical Features* 125
- *Maternal Consequences of Hyperemesis Gravidarum* 126
- *Fetal and Perinatal Outcomes* 127
- *Long-term Outcomes in the Offspring* 127
- *Investigations* 128
- *Complications* 128
- *Management of Hyperemesis Gravidarum* 128
- *Pharmacologic Agents* 129
- *Invasive Intervention in HG* 131
- *Alternative Treatments* 131
- *Termination of Pregnancy* 131

Chapter 17. Minor Disorders in Pregnancy 134

Sundararaj Raajkumar, Edwin Chandraharan

- *Gastrointestinal System* 134
- *Central Nervous System* 137
- *Musculoskeletal System* 138
- *Cardiovascular System* 139

Chapter 18. Basic Ultrasonography in Pregnancy 142

Jamiyah Hassan, Sofiah Sulaiman

- *Safety of Ultrasonography* 142
- *Methods* 142
- *Indications for Ultrasound Examination in Obstetrics* 143
- *The Schedule* 148
- *Doppler Ultrasound* 148

Chapter 19. Prenatal Diagnosis 150

Teresa WP Chow

- *Prenatal Screening* 150
- *Prenatal Diagnostic Tests* 154
- *Common Fetal Abnormalities* 156
- *Recent Development* 159
- *Important Terms* 161

Chapter 20. Anemia in Pregnancy 163

Shripad Hebbar

- *Physiological Considerations* 163
- *Iron Dynamics in Pregnancy* 164
- *Classification of Anemia in Pregnancy* 164

Chapter 21. Diabetes in Pregnancy 173

Lavanya Rai

- *Pregnancy as a Diabetogenic State* 174
- *Screening for Diabetes* 174
- *Complications* 176
- *Management* 178
- *Investigations* 179
- *Treatment* 180

Chapter 22. Tropical Diseases in Pregnancy 184

Debasis Bhattacharyya, Shelley Seth

- *Malaria in Pregnancy* 185
- *Clinical Features* 186
- *General Guidelines for Treatment* 186
- *Management of Complications* 186
- *Management of Labor* 187
- *Treatment of Vivax Malaria in Pregnancy* 187
- *Chemoprophylaxis in Pregnancy* 187
- *Kala Azar (Leishmaniasis)* 188

- *Dengue Fever 189*
- *Schistosomiasis 189*
- *Lymphatic Filariasis in Pregnancy 190*

Chapter 23. Infections and Immunization in Pregnancy 192

Subir Kumar Bhattacharyya, Joydev Mukherji, Arup Kumar Majhi

- *Routes of Transmission 192*
- *Duration of Pregnancy and Fetal Affection 192*
- *Prevention of Infection: Prepregnancy Counseling and Precautions 193*
- *Routine Antenatal Screening 193*
- *Herpes Simplex Viral Infection 194*
- *Syphilis 194*
- *Vaginitis 195*
- *Trichomoniasis 196*
- *Vulvovaginal Candidiasis 196*
- *Chickenpox in Pregnancy 196*
- *Group B Streptococcus 197*
- *Cytomegalovirus 197*
- *Rubella 198*
- *Toxoplasmosis 198*
- *Sexually Transmitted Infections 198*
- *Human Papillomavirus 198*
- *Gonorrhea 199*
- *Chlamydia 199*
- *Pregnancy and Severity of Infection 199*
- *Immunization During Pregnancy 201*

Chapter 24. Antepartum Hemorrhage 203

Eugene Leong Weng Kong

- *Etiology 203*

Chapter 25. Hypertensive Disorders in Pregnancy 215

Alokendu Chatterjee, Gita Banerjee (Basu)

- *Classification of Hypertensive Disorders Complicating Pregnancy 215*
- *Definitions 216*
- *Pre-eclampsia 216*
- *Prediction of Pre-eclampsia 219*
- *Management 219*
- *Intrapartum Management 222*
- *Eclampsia 222*
- *Chronic Hypertension in Pregnancy 225*

Chapter 26. Gynecological Disorders in Pregnancy 227

Naheed Tahir, Edwin Chandraharan

- *Physiological Vaginal Discharge 228*
- *Candidiasis 228*
- *Bacterial Vaginosis 228*
- *Trichomoniasis 229*
- *Chlamydia 230*

- *Gonorrhea 230*
- *Anogenital Warts 231*
- *Genital Herpes 231*
- *Syphilis 232*
- *Bartholin's Cysts and Abscesses 233*
- *Disorders of the Cervix 233*
- *Female Genital Mutilation 234*
- *Fibroids 235*
- *Retroverted Gravid Uterus 235*
- *Urogynecological Problem in Pregnancy 236*
- *Pelvic Organ Prolapse 236*
- *Abnormal Cervical Cytology in Pregnancy 237*
- *Carcinoma Cervix in Pregnancy 237*
- *Adnexal Masses in Pregnancy 237*

Chapter 27. Multiple Pregnancy and Polyhydramnios 240

Suchitra N Pandit, Vijay C Pawar, Sanjay B Rao

- *Multiple Pregnancy 241*
- *Nomenclature of Ultrasound in Twin Pregnancy 243*
- *Maternal Complications 244*
- *Fetal Complications 244*
- *Chorionic Villus Sampling 247*
- *Technique of Amniocentesis in Twin Pregnancy 247*
- *Polyhydramnios 250*
- *Diagnosis 251*

Chapter 28. Preterm Labor and Prelabor Rupture of Membranes 254

Tan Peng Chiong

- *Preterm Labor 255*
- *Preterm Prelabor Rupture of Membranes 263*

Chapter 29. Intrauterine Growth Restriction 269

Muralidhar V Pai

- *Complications 271*

Chapter 30. Prolonged Pregnancy 277

Prashant Joshi

- *Incidence 277*
- *Risk Factors 278*
- *Fetal and Maternal Complications 278*
- *Principles of Management 279*
- *Monitoring in Labor 279*
- *Clinical Practice Guidelines 279*

Chapter 31. Thalassemia and Rhesus Isoimmunization 281

Jamiyah Hassan, Sofiah Sulaiman

- *Normal Hemoglobin 282*
- *Alpha Thalassemia 282*
- *Beta Thalassemia 283*
- *Rhesus Isoimmunization 284*

Chapter 32. Medical Disorders in Pregnancy (Cardiac, Respiratory and Endocrine Disorders) 287

Hiralal Konar

- *Cardiac Diseases in Pregnancy 287*
- *Medical Disorders in Pregnancy (Cardiac, Respiratory and Endocrine Disorders) 288*
- *Respiratory Diseases in Pregnancy 290*
- *Thyroid Disorders in Pregnancy 291*

Chapter 33. Principles of Drugs Used in Pregnancy 294

Hari Muppala, Onnig Tamizian, Sabaratnam Arulkumaran

- *Overview of the Problem 294*
- *Pregnancy Outcome in Relation to Timing of Exposure 294*
- *Prescribing Principles in Pregnancy 295*
- *Breastfeeding and Maternal Pharmacotherapy 296*
- *Drugs Used in Pregnancy 296*
- *Supplements and Vitamins 296*
- *Antibiotics 297*
- *Sexually Transmitted Diseases 298*
- *Infections Caused by Parasitic Organisms 299*
- *Vaccination 299*
- *Anticoagulants 300*
- *Anticonvulsants 300*
- *Antihypertensive Drugs 301*
- *Asthma Medication 301*
- *Analgesics and Anti-inflammatory Drugs 302*
- *Immunosuppressants and Corticosteroids 302*
- *Psychotropic Drugs 303*
- *Antiretroviral Agents 304*
- *Chemotherapeutic Agents 304*
- *Treatment of Minor Ailments an Pregnancy 305*
- *Management of Pregnancy and Potential Teratogenesis 305*

Chapter 34. Acute Abdomen in Pregnancy 309

Asmita Muthal-Rathore

- *General Considerations 309*
- *Causes of Acute Abdomen During Pregnancy 311*
- *Adnexal Masses 311*
- *Red Degeneration of Fibroid 311*
- *Acute Appendicitis 312*
- *Intestinal Obstruction 313*
- *Reflux Esophagitis and Peptic Ulcer Disease 313*
- *Acute Cholecystitis 313*
- *Acute Pancreatitis 314*
- *Hepatic Hemorrhage and Rupture 315*
- *Renal Colic 315*
- *Acute Pyelonephritis 316*
- *Abdominal Trauma 316*
- *Infectious Diseases 317*

Chapter 35. Antenatal Assessment of Fetal Wellbeing 318

Neharika Malhotra Bora, Narendra Malhotra, Jaideep Malhotra

- *High-risk Patient* 319
- *Methods of Fetal Surveillance* 319
- *Amniotic Fluid Index* 321
- *Patients with Abnormal Fetal Ultrasound Finding* 322

Chapter 36. Induction of Labor 328

Srividya Sankaran

- *Indications* 328
- *Contraindications to Induction of Labor* 329
- *Preinduction Assessment* 329
- *Predicting the Success of IOL* 329
- *Methods for Inducing Labor* 330
- *Breast Stimulation* 330
- *Membrane Sweep* 330
- *Extra-amniotic Foley's Catheter* 330
- *Amniotomy/Artificial Rupture of Membranes* 331
- *Amniotomy Alone* 331
- *Amniotomy with Oxytocin Infusion* 331
- *Intravenous Syntocinon* 331
- *Prostaglandins* 332
- *Misoprostol* 333
- *Mifepristone* 333
- *Care of Women During IOL* 334
- *Fetal Monitoring During Induction of Labor* 334
- *Uterine Hyperstimulation* 334
- *Induction of Labor for Prolonged Pregnancy* 334
- *Prelabor Rupture of Membranes at Term* 335
- *Labor Induction with Previous Cesarean Section* 335
- *Induction of Labor for Maternal Request* 335
- *Failed Induction of Labor* 335
- *Future* 336

Chapter 37. Mechanism of Labor 338

Alokendu Chatterjee, Basab Mukherjee

- *Normal Labor* 338

Chapter 38. Normal Labor 345

K Sujatha

- *Onset of Labor* 345
- *Physiology of Normal Labor* 347
- *Mechanism of Labor* 351
- *Management of Normal Labor* 353

Chapter 39. Obstetric Analgesia and Anesthesia 357

Chan Yoo Kuen

- *Anatomy of Pain Pathways* 357

- *Analgesia for Labor 358*
- *Anesthesia for Cesarean Section 360*
- *Safety for Mother and Child 361*

Chapter 40. Malposition and Malpresentations 363

Sudip Chakravarti, Sajal Datta, Krishnendu Gupta

- *Occiput Posterior Position 363*
- *Types 363*
- *Incidence 363*
- *Causes 364*
- *Diagnosis 364*
- *Mechanism of Labor 364*
- *Outcome of Labor 366*
- *In Direct Occiput Position or Persistent Occipitoposterior Position 366*
- *Management of Labor 367*
- *Manual Rotation and Forceps Delivery 367*
- *Vacuum Extraction 367*
- *Face Presentation 368*
- *Abdominal Examination 368*
- *Brow Presentation 369*
- *Transverse Lie 371*
- *Breech Presentation 372*
- *Antenatal Management of Breech Presentation 375*
- *Management 375*
- *Assisted Breech Delivery 376*
- *Management of Complications in Breech Delivery 380*

Chapter 41. Operative Obstetrics 381

Silvam Sellappan, V Sivanesaratnam

- *Forceps Delivery 381*
- *Vacuum Delivery 383*
- *Cesarean Section 385*
- *Shoulder Dystocia 387*

Chapter 42. Injuries to Birth Canal 390

Partha Mukhopadhyay, Sebanti Goswami

- *Perineal Injuries 390*
- *Grades of Perineal Tear 391*
- *Vaginal Injury 394*
- *Paravaginal Hematoma (Pelvic Hematoma) 395*
- *Injuries to the Cervix 396*
- *Rupture of Uterus 396*

Chapter 43. Prolonged and Obstructed Labor 399

Joydev Mukherji, Rajendra Prasad Ganguly, Gourisankar Kamilya

- *Prolonged Labor 399*
- *Definition 399*
- *Obstructed Labor 403*

Chapter 44. Resuscitation of the Newborn **407**

Lim Chin Theam

- *Pathophysiology of Perinatal Asphyxia* 407
- *Causes of Perinatal Asphyxia* 408
- *Assessment of Infants at Birth* 408
- *Resuscitation of the Newborn* 409

Chapter 45. Diseases of the Newborn **414**

KK Diwakar, Sujata Deshpande

- *Birth Injuries* 415
- *Clinical Examination of the Newborn and a Few Common Problems* 417

Chapter 46. Complications of Third Stage of Labor **423**

Thaneemalai Jeganathan, V Sivanesaratnam

- *Physiology of Placental Separation* 424
- *Postpartum Hemorrhage* 425
- *Genital Tract Trauma* 430
- *Retained Placenta* 430
- *Placenta Accreta* 431
- *Uterine Inversion* 431

Chapter 47. Normal Puerperium **433**

Jyothi Shetty

- *Physiological Changes* 433
- *Management of Normal Puerperium* 435
- *Lactation* 436

Chapter 48. Abnormalities of Puerperium **439**

Sudip Chakravarti, Sajal Datta, Krishnendu Gupta

- *Puerperium Breast Problems* 440
- *Venous System Complications* 441
- *Mental Health Problems* 444

Index ***449***

Chapter 2

Anatomy of Female Reproductive Organs

Lubna Sheikh, Soma Mukherjee

OVERVIEW

1. The female reproductive organs consist of the external and internal genitalia.
2. The purpose of the external genitalia is to protect the internal organs (where fertilization and pregnancy occurs), to act as an outlet and to provide sexual pleasure.
3. Fertilization will occur in the fallopian tubes, once an ovum has been released by the ovary. The fertilized ova will then imbed itself into the uterine lining where it will develop into a fetus.

VULVA

The vulva (also known as the external genitalia) includes the mons pubis, labia majora and minora, clitoris, vestibule, bulb of the vestibule and greater vestibular glands. The internal pudendal artery supplies blood to the vulva, which is derived from the posterior division of the internal iliac artery. The vulva is highly vascular and tends to bleed heavily when damaged. Nerve supply is mainly from the pudendal nerves, which are branches of the sacral plexus. Embryologically, the vulva arises from the urogenital sinus. The lymphatics drain into the superficial inguinal and subinguinal nodes, deep subinguinal nodes (Cloquet), external iliac chain and the inferior hemorrhoidal nodes.

Mons Pubis

The mons pubis is a large fatty prominence that overlies the pubic symphysis. It is covered with skin and hair. It is not strictly a part of the reproductive system but acts as a cushion to the bony structures below.

Labia Majora

The labia majora extend from the mons pubis anteriorly to the perineum posteriorly. They are folds of skin with underlying adipose tissue and contain numerous sebaceous glands. Growth of pubic hair occurs on the lateral aspect and at the mons at puberty. The function of the labia majora is to protect the vaginal orifice with a cushioning effect.

Labia Minora

The labia minora are two folds of smooth skin containing sebaceous glands. Anteriorly they split into two parts to form the prepuce and frenulum of the clitoris. They fuse posteriorly to form the fourchette. The function of the minora is also to protect the vagina.

Clitoris

The clitoris is a small erectile structure measuring approximately 2.5 cm. It is homologous to the penis in the male. It consists of two corpora cavernosa, which are attached to the pubic rami by a suspensory ligament. The clitoris is highly sensitive to sexual stimuli and will become engorged and erect in response to stimulation similar to the male penis. The clitoris enhances the pleasurable experience of sexual intercourse.

Vestibule

The vestibule lies between the labia minora and consists of the external urethral meatus, the vaginal orifice and

JAYPEE BROTHERS

two pairs of gland ducts. The Bartholin's gland ducts are situated at the 5 and 7 o'clock position around the vaginal orifice. The Skene's glands open around the urethral orifice. Both pairs of glands produce mucous to moisten the external genitalia.

VAGINA

The vagina is a muscular tubular structure, which extends from the vulva to the opening of the uterus. It is longer posteriorly (9 cm) than anteriorly (7.5 cm). The anterior vaginal wall is in relation to the bladder and the urethra. The upper-third of the posterior vaginal wall is related to the pouch of Douglas and the middle-third to the rectum. The lower-third is separated from the anal canal by the anal sphincters and the perineal body.

The vagina is lined by stratified squamous epithelium, rich in glycogen. Lactobacilli breaks down the glycogen to form lactic acid, which makes the vagina very acidic.

The hymen is a thin transverse membrane at the opening of the vagina and is usually torn during first intercourse. The small tags that remain are called carunculae myrtiformis.

The function of the vagina is to act as a passage for the sperm and as an outlet for menstrual bleeds and the fetus. It also acts as a barrier to infections.

The vagina is supplied by the vaginal branch of the internal iliac artery and it forms anastomoses with the uterine, middle rectal and inferior vesical vessels. The veins drain into the internal iliac vein. The nerve supply is from the sacral plexus and the pudendal nerve.

The lymphatics from the upper vagina drain into the external and internal iliac group of lymph nodes. The lower vagina drains into the superficial inguinal nodes.

UTERUS

The uterus is divided into two main parts; the cervix (the neck) and the corpus (the body).

The cervix consists of a cervical canal with an internal and external opening. The internal opening, known as the internal os, opens into the corpus. The external opening, known as the external os, opens into the vagina.

The cervix is made of collagenous tissue, which undergoes significant changes during pregnancy and childbirth. The epithelium is columnar ciliated in the upper two-thirds and changes to stratified squamous around the external os.

The cervix is related to the bladder anteriorly and pouch of Douglas posteriorly. Laterally, the uterine artery and ureter are close to the supravaginal cervix.

The body of the uterus in the nonpregnant state measures 9 cm in length, 6 cm in width and is 4 cm thick. The uterus is held in place by the round, cardinal and uterosacral ligaments. It weighs approximately 50 g in nulliparous and 70 g in parous women. The uterus lies between the bladder anteriorly and the rectum posteriorly.

The uterus is supplied by the uterine and ovarian arteries. The uterine veins form a plexus at the base of the broad ligament and drain into the internal iliac vein. Nerve supply is from the sacral plexus.

The main lymphatic drainage of the uterus is into the external and internal iliac group of lymph nodes. Some lymphatics from the upper part of the uterus pass directly to the lateral aortic nodes, with the ovarian blood supply. A few branches run into the superficial inguinal nodes.

Different parts of the uterus are shown in Figure 2.1. The fallopian tubes insert into the uterus at the 'cornu' and the portion above the cornu is the fundus of the uterus. The cervix joins the uterus at the level of the isthmus.

Structure

The uterus consists of three layers—the outer serous (perimetrium), the middle muscular (myometrium) and the inner mucous layers (endometrium). The peritoneum covers the body of the uterus and laterally spreads out to form the leaves of the broad ligament.

The Pregnant Uterus

The isthmus elongates and its cavity becomes absorbed into the uterine cavity to form the lower uterine segment. At term, the lower segment is made up of 70% isthmus and 30% cervix.

Braxton Hicks contractions become evident from as early as 8 weeks of gestation. They start at the cornua of the uterus and gradually become contractions of labor at term.

During labor, the upper segment actively contracts and shortens (retraction) and the lower segment passively dilates and lengthens. Retraction is most marked in the third stage of labor, which occludes the vessels that transverse the myometrium, thus preventing postpartum hemorrhage.

Endometrium

The endometrium is made up of two layers: the functional layer and the basal layer. The functional layer is glandular and undergoes cyclical histological changes under the influence of hormones. This results in the building up and shedding of the endometrium with each menstrual cycle. Fertilized ova are embedded into this layer and provide the nourishment for the duration of the pregnancy.

The basal layer is lined by a single layer of columnar epithelium. It gives rise to the functional layer after each menstruation.

JAYPEE BROTHERS

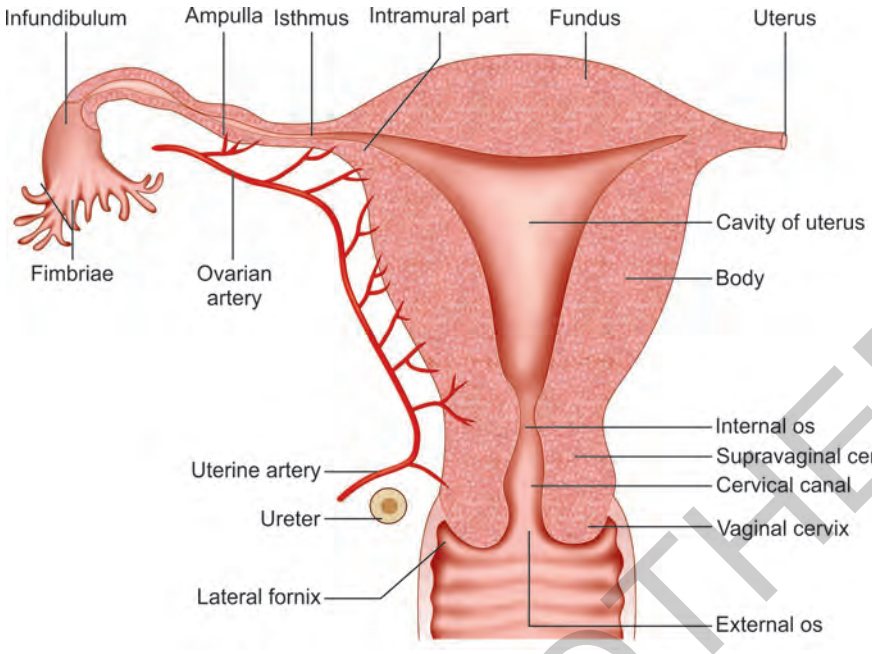

Fig. 2.1: The uterus

FALLOPIAN TUBES

The fallopian tubes run along the upper margin of the broad ligament and are 10 cm long. There are three parts to the tubes. The isthmus is closest to the uterus and is the narrowest portion. Next comes the ampulla and then the infundibulum which widens into finger-like projections known as fimbriae. The fimbriae play an important role in ovum pickup.

The mucous membrane is thrown into folds and is lined by ciliated columnar epithelium, which helps to transport sperm and ovum.

OVARIES

The ovary is white and almond shaped; 3 cm long, 1.5 cm wide and 1 cm thick. The ovarian ligament attaches the ovary to the cornu of the uterus and the broad ligament attaches it to the hilum. Laterally, it is attached to the pelvic wall by the infundibulopelvic ligament containing the ovarian blood vessels from the abdominal aorta.

The function of the ovary is to produce ova, estrogen and progesterone. The surface of the ovary is covered by a single layer of cuboidal cells, the germinal epithelium. Beneath this is a layer of connective tissue known as tunica albuginea.

Primordial follicles are found in the outer cortex and the inner medulla is vascular. The number of primordial follicles are maximum during intrauterine life and undergo a steady state of atresia from 20 weeks of intrauterine life. At puberty, primordial follicles form Graafian follicles each month, which mature and release an ovum at ovulation. This is followed by formation of corpora lutea and then corpora albicans.

The ovary is supplied by the ovarian artery. It crosses the ureter before entering the pelvic brim, to then enter the infundibulopelvic ligament and then ends by entering the ovary through the hilum.

The ovarian veins form a pampiniform plexus at the hilum. The right ovarian vein drains into the inferior vena cava and the left into the left renal vein.

The lymphatics drain into the para-aortic nodes alongside the origin of the ovarian artery. The nerve supply includes both sympathetic and parasympathetic.

CONCLUSION

- The functions of different parts of the external and internal genitalia
- The blood supply, nerve supply and lymphatic drainage of each organ
- How pregnancy affects the uterus.

BIBLIOGRAPHY

1. Arulkumaran S, Sivanesaratnam V, Chatterjee A, Kumar P. Essentials of Obstetrics, 2nd Edn, Jaypee Brothers Medical Publishers, New Delhi; 2011.
2. Chard T, Lilford. Basic Sciences for Obstetrics and Gynecology, 4th Edn, Springer Verlag, London; 1994.
3. Wylie L. Essential Anatomy & Physiology in Maternity Care, 2nd Edn, Elsevier, London; 2005.

JAYPEE BROTHERS

r detailed information on obstetrics & gynecology books, visit our website **www.jaypeebrothers.com,** for detailed informa

Essentials of OBSTETRICS

Salient Features

- *Essentials of Obstetrics* is a composite textbook consisting of 48 chapters starting from formation of the embryo to delivery of the baby and the after care of the newborn and the mother post-delivery
- The chapters cover the normal physiology and pathological deviations that occur due to pre-existing disease and the obstetric disorders that sets in because of the pregnancy
- Each chapter is well illustrated with color photographs, illustrations, well-constructed tables and flowcharts to make it easy to read and understand the concept that is dealt with
- The authors from India, Malaysia and the UK were invited to contribute the chapters recognizing their expertise
- The breadth and depth of obstetrics and gynecology needed for undergraduates and postgraduates during their early years are provided
- Greater incorporation of evidence-based medicine in each chapter and better illustrations than the previous edition.

Sabaratnam Arulkumaran DCH FRCS FRCOG FAMS MD PhD Hon: FACOG FSLCOG FSOGC is Emeritus Professor, Department of Obstetrics and Gynecology, St George's University of London, London, United Kingdom. He was former President of the International Federation of Gynecology and Obstetrics—FIGO (2012–2015); the British Medical Association (2013–2014), and Royal College of Obstetricians and Gynaecologists (2007–2010). He is the author/editor of 28 books. He is a Knight Bachelor in Recognition of Services to Medicine and Health Services by Her Majesty the Queens – Birthday Honours List—June 2009.



V Sivanesaratnam MBBS (S'pore) FRCOG FICS FACS FAMM FAOFOG is Emeritus Professor, Department of Obstetrics and Gynecology, University of Malaya, Kuala Lumpur, Malaysia. Formerly, he was Professor (Chair), Head and Senior Consultant, Department of Obstetrics and Gynecology, University of Malaya. Currently, he is Consultant Gynecologist/Gynecologic Oncologist at University of Malaya Specialist Centre, Kuala Lumpur. He has published extensively on various aspects of obstetrics and gynecology in refereed journals, including chapters in several textbooks. He has extensive experience in managing various gynecological and oncological problems. He was the Past President of the Asia and Oceania Federation of Obstetrics and Gynecology.



Alokendu Chatterjee FRCOG FICS was formerly Head, Department of Obstetrics and Gynecology, NRS Medical College, Kolkata, West Bengal, India; Member, National Human Rights Commission (Health), India; International Examiner of MRCOG; President, SAFOG (2013–2015) and FOGSI (1999–2000); Chairman, AICC RCOG (2004–2009), and Vice-President, National Board of Examination (2004–2009).



Pratap Kumar MD DNB is Professor, Department of Obstetrics and Gynecology, Kasturba Medical College, Manipal University, Manipal, Karnataka, India. He is Head, Division of Reproductive Medicine, Manipal University, Manipal. He was National Vice-President of the Federation of Obstetrics and Gynecology for the year 1999. He is the editor of 12 books. He has more than 250 publications and presented more than 500 presentations in national and international congresses. He was President, Karnataka State Obstetric and Gynecological Societies of FOGSI (2011–2012) and awarded Dr Kutty Lifetime Achievement Award for 2011–2012.



Available at all medical bookstores or buy online at www.jaypeebrothers.com

JAYPEE

JAYPEE BROTHERS Medical Publishers (P) Ltd.

www.jaypeebrothers.com

Join us on facebook.com/JaypeeMedicalPublishers

Shelving Recommendation
OBSTETRICS & GYNECOLOGY

ISBN 978-93-86056-66-5

9 789386 056665