nformation on obstetrics & gynecology books, visit our website **www.jaypeebrothers.com,** for detailed information on obstetrics & gynecology books, visit our website **www.jaypeebrothers.com**

THIRD EDITION

Childbirth & Obstetric Techniques

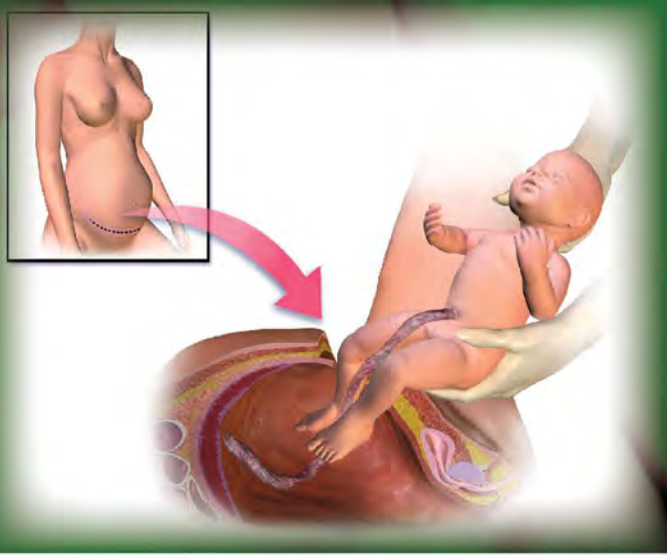

Sophia NE Webster
Farook Al-Azzawi

Foreword
Sir Sabaratnam Arulkumaran

JAYPEE

CONTENTS

1. Antenatal Care **1**
The Scope and Organization of Antenatal Care *1*
Ultrasound Scanning *2*
Magnetic Resonance Imaging *13*
Amniocentesis *13*

2. Mechanism of Childbirth **17**
Powers: Uterine Muscle *17*
Passage *18*
Passenger: Baby *25*
Cardinal Movements of Labor *25*
Pelvic Phase of Labor *26*

3. Management of Labor **29**
Management of the First Stage of Labor *29*
Management of the Second Stage of Labor *41*
Management of the Third Stage of Labor *42*

4. Pain Relief in Labor **44**
Saffana Shawket
Nitrous Oxide *44*
Systemic Analgesics *45*
Epidural Analgesia *45*
Caudal Analgesia *49*
Spinal Analgesia *50*
New Trends in Epidural Drugs and Techniques *52*

5. Normal Labor **53**
Positions for Labor and Birth *53*
Conduct of the Second Stage *54*
Conduct of the Third Stage *63*
Shoulder Dystocia *63*

6. Resuscitation of the Newborn **68**

7. Perineal Repair **76**
Episiotomy Repair *76*
Repair of Midline Episiotomy *77*
Repair of Posterolateral Episiotomy *78*
Repair of Mediolateral Episiotomy *83*

Vaginal Tears *86*
Repair of Second-Degree Perineal Tears *87*

8. Common Problems Immediately after Delivery **92**
Postpartum Hemorrhage *92*
Manual Removal of the Placenta *99*
Rupture of the Uterus *101*
Acute Uterine Inversion *101*
Amniotic Fluid Embolism *102*
Pulmonary Embolism *103*
Seizures *104*
Secondary Postpartum Hemorrhage *104*

9. Operative Vaginal Delivery **106**
Decision Making and Prerequisites *106*
Pudendal Nerve Block: Transvaginal Technique *109*
Vacuum-Assisted Delivery *110*
Obstetric Forceps *120*
Forceps Delivery for the Occipitoanterior Position *123*
Kjelland's Forceps Delivery *130*
Delivery of the Occipitoposterior Position *144*
Manual Rotation of the Head and Forceps Delivery *148*

10. Breech Presentation **151**
Types of Breech Presentation *151*
Optimal Mode of Delivery *152*
External Cephalic Version *152*
Vaginal Delivery of the Breech Baby *154*
Management of the Second Stage of Labor *155*
Pinard's Maneuver *160*
Lovset's Maneuver *161*
Delivery of the Fetal Head and Cephalic Complications *163*

11. Delivery of Twins **167**
Management of the Second Stage of Labor *167*
Internal Podalic Version *178*

12. Cesarean Section **180**
Lower Segment Cesarean Section *180*
Abdominal Delivery of the Small Baby *189*
Vertical Lower Segment Cesarean Section (De Lee's Operation) *189*
"En Caule" Cesarean Section for Delivery of the Very Low Birth Weight Baby *195*
Discussion *200*

Index *201*

Chapter 3

Management of Labor

MANAGEMENT OF THE FIRST STAGE OF LABOR

Diagnosis of Labor and Admission

Labor is defined as the onset of painful uterine contractions of increasing frequency and severity. Nonetheless, the final arbiter for the diagnosis of established labor is the progressive cervical dilatation and therefore it is at this stage that women booked for hospital confinement should be admitted to the labor ward or birthing center. To a large extent, a woman in labor dictates the exact time of her admission to hospital but women in early, nonestablished labor are often encouraged to spend time in their home environments where travel between the two is straightforward. In hospital, the woman may be seen for midwifery and/or obstetric assessment and offered further time at home to establish into labor. Where it is inappropriate for patients in early labor to be at home, hospital admission need not necessarily be to the labor ward or birthing center, where beds are both limited and expensive to maintain, but instead to a location where mobilization and observation are possible.

During assessment, information is obtained regarding the onset, duration, and severity of uterine contractions, whether a mucous "show" has been passed, if recent vaginal bleeding or rupture of membranes has occurred, fetal movements and the presence of other symptoms. On the basis of this information, the midwife or doctor triaging the call will make a recommendation regarding attendance at the facility. On arrival, these details can be confirmed and the vital signs of pulse, temperature, and blood pressure recorded as well as fetal heart activity. Once in established labor, these observations should usually be repeated at hourly intervals.

A general physical examination forms part of this initial assessment that should include abdominal examination with assessment of overall uterine size, measurement of fundal height and palpation of fetal presentation and position where possible, together with vaginal examination where indicated. The latter should include visual inspection of the vulva, speculum examination if preterm rupture of membranes, preterm labor or antepartum hemorrhage is suspected. In the absence of placenta previa, vaginal examination helps to determine the direction of the cervix—whether anterior, posterior, or midposition—its consistency, the length of the cervical canal, and the dilatation of the cervix. The level of the presenting part in relation to the ischial spines should also be documented and together these features help compute the Bishop score (Table 3.1). When these data are gathered, the examiner should consider sweeping his/her fingers over the vaginal walls to assess the pelvis in order to comment on

JAYPEE BROTHERS

Table 3.1: The Bishop score system of assessing cervical change.

	0	*1*	*2*
Direction of the cervix	Posterior	Midposition	Anterior
Consistency	Firm	Intermediate	Soft
Application to presenting part	Not applied	Loosely applied	Firmly applied
Length of the cervix	2 cm	1 cm	Effaced
Cervical dilatation	Closed	1–2 cm	3 cm

its adequacy. Fetal well-being is also assessed by way of sonicaid or cardiotocography (CTG), depending on the clinical situation and pregnancy risk factors. A decision is made regarding the mode of fetal monitoring for active labor-intermittent auscultation with the Pinard stethoscope, sonicaid or continuous CTG.

The findings at the time of hospital admission are considered, with careful reference to the whole antenatal history and the patient's previous labor and delivery. This information is used to decide whether the patient should be admitted, if so to where, and whether to proceed with an attempt of vaginal delivery or an emergency cesarean section.

The cervix undergoes progressive changes in preparation for labor. These changes include softening of its consistency, shortening (effacement), and a change in position to anterior. In the latent phase of labor, these changes progress further until the active phase of labor is reached, when progressive cervical dilatation occurs. The practice of Bishop scoring of the cervix in early labor or at the time of induction of labor serves a useful guide to assess progress on subsequent examinations.

Fetal Monitoring in the First Stage of Labor

For low-risk women in spontaneous labor, intermittent auscultation with a sonicaid is appropriate (Fig. 3.1). In the first stage of labor, this should be performed at least once every 15 minutes, during and for at least 30 seconds after a contraction, for at least 1 minute and recorded as a single heart rate. The presence of accelerations or decelerations and baseline rate should also be recorded. The normal range is 110–160 bpm. Where a fetal heart abnormality is suspected, the rate heard should be compared with the maternal pulse. Where fetal bradycardia or decelerations occur, a CTG is applied and obstetric review is urgently sought.[1-2]

Where the clinical situation dictates (e.g. where meconium-stained liquor is present or epidural anesthesia is administered), electronic fetal monitoring with CTG is required (Fig. 3.2). This rule applies even in women initially classified as 'low risk'. Two external sensors (three in the case of a twin pregnancy) are attached to the mother's abdomen and connected to the CTG machine. A fetal scalp electrode for fetal heart recording is applied to the fetal scalp at vaginal examination in place of the external sensor if external monitoring proves difficult.

The CTG needs careful analysis. There are several different classification systems and clinicians should be guided by those used nationally in their country of practice. Table 3.2 details the classification system of the International Federation of Obstetrics and Gynecology (FIGO) for CTG analysis in labor.[2]

JAYPEE BROTHERS



Fig. 3.1: The use of a sonicaid to monitor the fetal heart rate. Following abdominal palpation, the midwife positions the sonicaid posterior to the anterior fetal shoulder and listens for 1 minute.



Fig. 3.2: The use of cardiotocography to monitor the fetal heart rate and contraction pattern continuously. Following abdominal palpation, the midwife positions the two sensors (one to record the fetal heartbeat posterior to the fetal anterior shoulder and one to record intra-abdominal pressure at the uterine fundus) on the mother's abdomen and fixes them with elastic belts to prevent slippage.

The fetal heart baseline rate is defined as the mean level of the horizontal segments and estimated over 10 minute time periods. Preterm fetuses tend to have baseline rates at the upper end of the normal range and post-term fetuses toward the lower end. Variability is the oscillations in the fetal heart rate signal and calculated as the average bandwidth amplitude of

JAYPEE BROTHERS

Table 3.2: Adapted from the FIGO consensus guidelines on intrapartum fetal monitoring (http://www.jsog.or.jp/international/pdf/CTG.pdf).

	Normal	*Suspicious*	*Pathological*
Baseline	110–160 bpm	Lacking at least one characteristic of normality, but with no pathological features	<100 bpm
Variability	5–25 bpm		Reduced variability for >50 minutes, increased variability for >30 minutes, or sinusoidal pattern for >30 minutes
Decelerations	No repetitive decelerations		Repetitive late or prolonged decelerations during >30 minutes or 20 minutes if reduced variability, or one prolonged deceleration with >5 minutes
Interpretation	Fetus with no hypoxia/acidosis	Fetus with a low probability of having hypoxia/acidosis	Fetus with a high probability of having hypoxia/acidosis
Clinical management	No intervention necessary to improve fetal oxygenation state	Action to correct reversible causes if identified, close monitoring or additional methods to evaluate fetal oxygenation	Immediate action to correct reversible causes, additional methods to evaluate fetal oxygenation, or expedite delivery

(FIGO: International Federation of Gynecology and Obstetrics).[2]

the signal over 1 minute segments. Prolonged reduced variability is of great concern and can signify central nervous system hypoxia/acidosis. Normal sleep cycles also show short periods of reduced variability but rarely <5 bpm. Increased variability >25 bpm for 30 minutes or more probably represents rapidly evolving fetal hypoxia/acidosis. Decelerations are decreases from the fetal heart baseline rate of > 15 bpm for > 15 seconds and are labeled:

- Early decelerations are shallow, short, normal variability, occurring with contractions.
- Variable decelerations are rapid drops from baseline and recovery, varying size and shape, and relation to contractions.
- Late decelerations are decreases of gradual onset and/or return to baseline sometimes with reduced variability.

Early decelerations are due to fetal head compression and should not be concerning to the midwife or obstetrician. In contrast, late decelerations indicate fetal hypoxia and their presence should be clearly documented and a management review undertaken by an obstetrician. Variable decelerations, the most commonly found decelerations in labor, are rarely associated with a significant degree of fetal hypoxia unless they evolve to develop prolonged recovery to baseline and reduced variability within them. Figures 3.3 to 3.6 show different CTG patterns.

JAYPEE BROTHERS

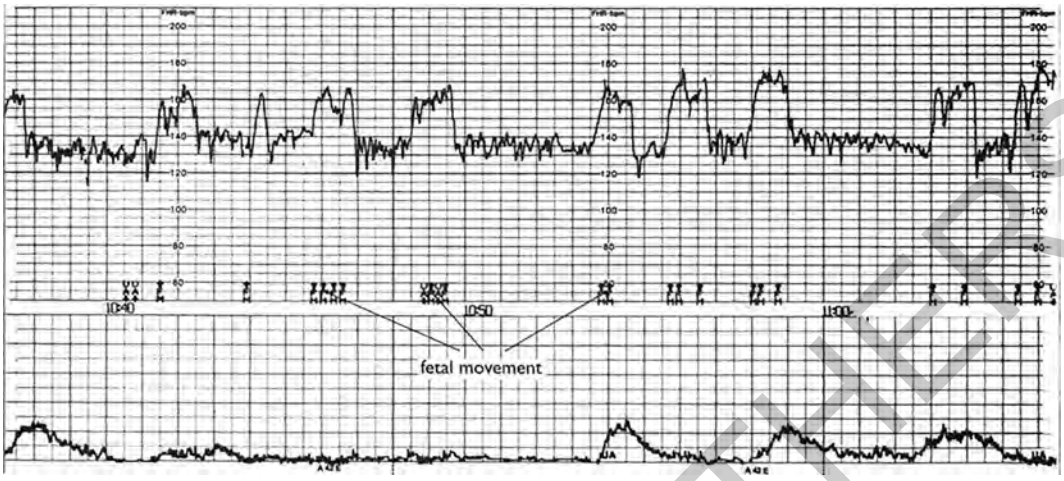

Fig. 3.3: Normal cardiotocogram in early labor of a singleton, showing good fetal heart variability and baseline rate, the presence accelerations and absence of decelerations.

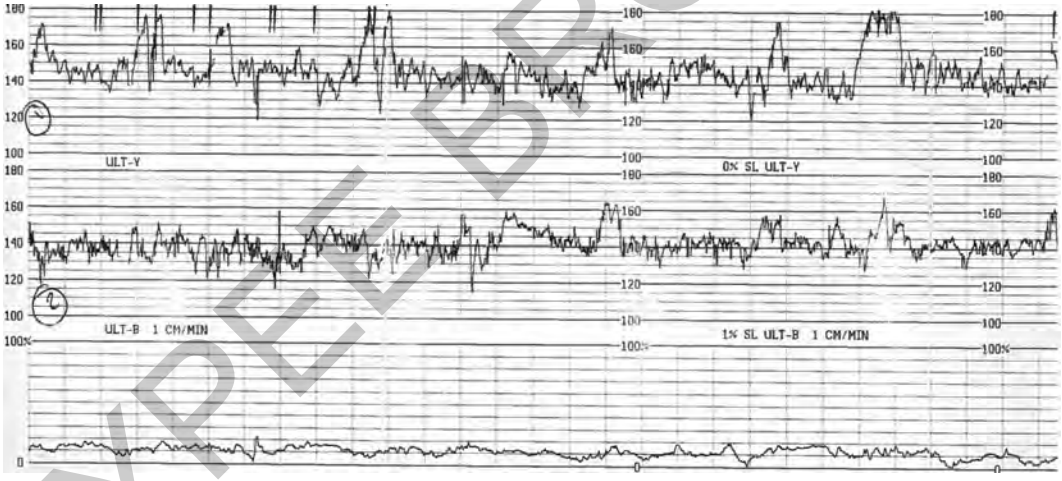

Fig. 3.4: Normal cardiotocogram in early labor of twins, showing good fetal heart variability and baseline rate, the presence accelerations, and absence of decelerations for both twins.

Progress in the First Stage of Labor

When the diagnosis of established or active labor is made, the findings are recorded on a partograph (Fig. 3.7). This graphical form of labor progress should demonstrate progressive cervical dilatation over time to ensure any sign of slow progress is diagnosed at an early stage so that intervention can be considered. In the first stage, 4-hourly vaginal examinations are the norm, or more frequently on an individualized basis, e.g. where there are fetal heart concerns

JAYPEE BROTHERS

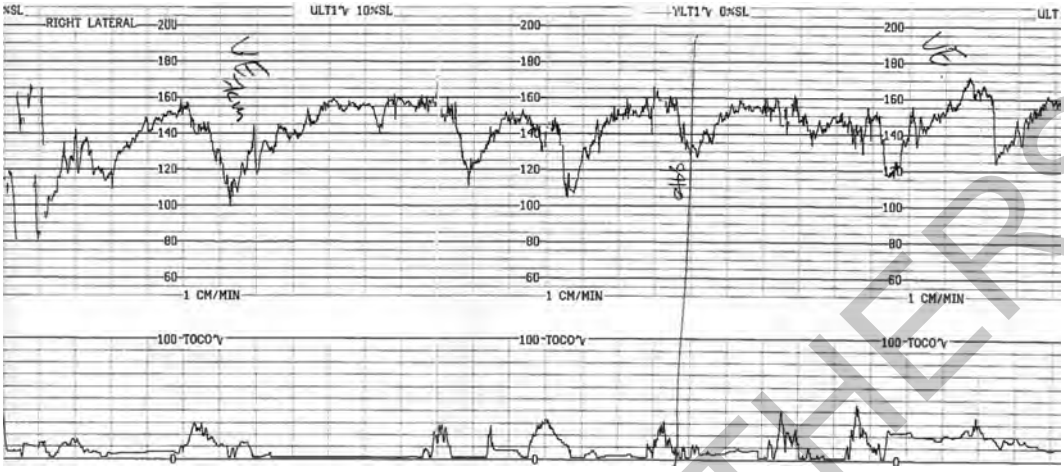

Fig. 3.5: Pathological cardiotocogram with recurrent late decelerations, although variability is normal.

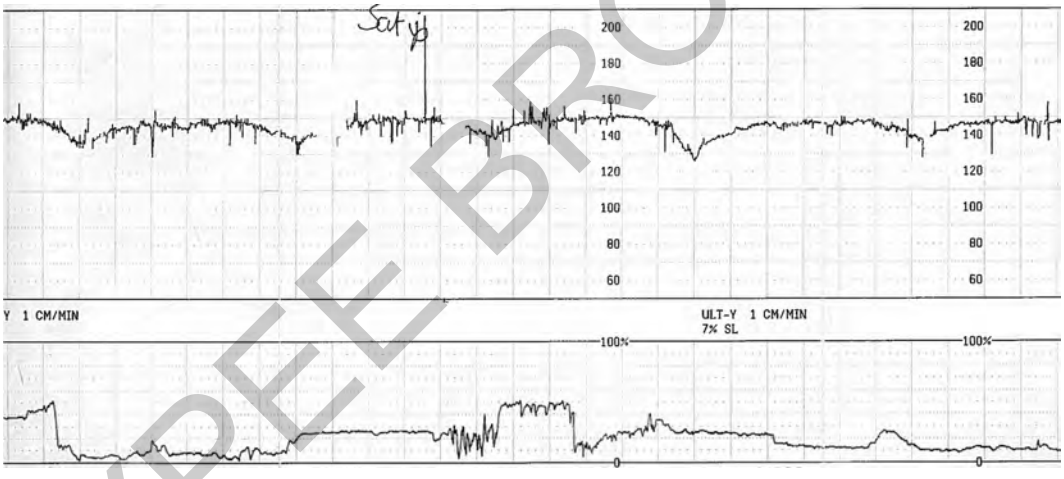

Fig. 3.6: Abnormal cardiotocogram (not in labor) showing much reduced variability and decelerations with prolonged recovery. This baby was hypoxic at birth.

and a progress update is required sooner, or where cervical dilatation has been suboptimal for some time. When this system is followed, the number of vaginal examinations per labor is minimized, as abnormal labors are identified and treated early and those with normal progress infrequently require more than four such examinations throughout the whole active labor.

In addition to the assessment of the progress of cervical dilatation, other reasons for vaginal examination in labor are to establish the descent of the head, the position of the fetal occiput/sacrum and to determine whether caput succedaneum and/or molding has developed. Fetal position is determined by identifying the sagittal suture, fontanelles and, not infrequently, the

JAYPEE BROTHERS

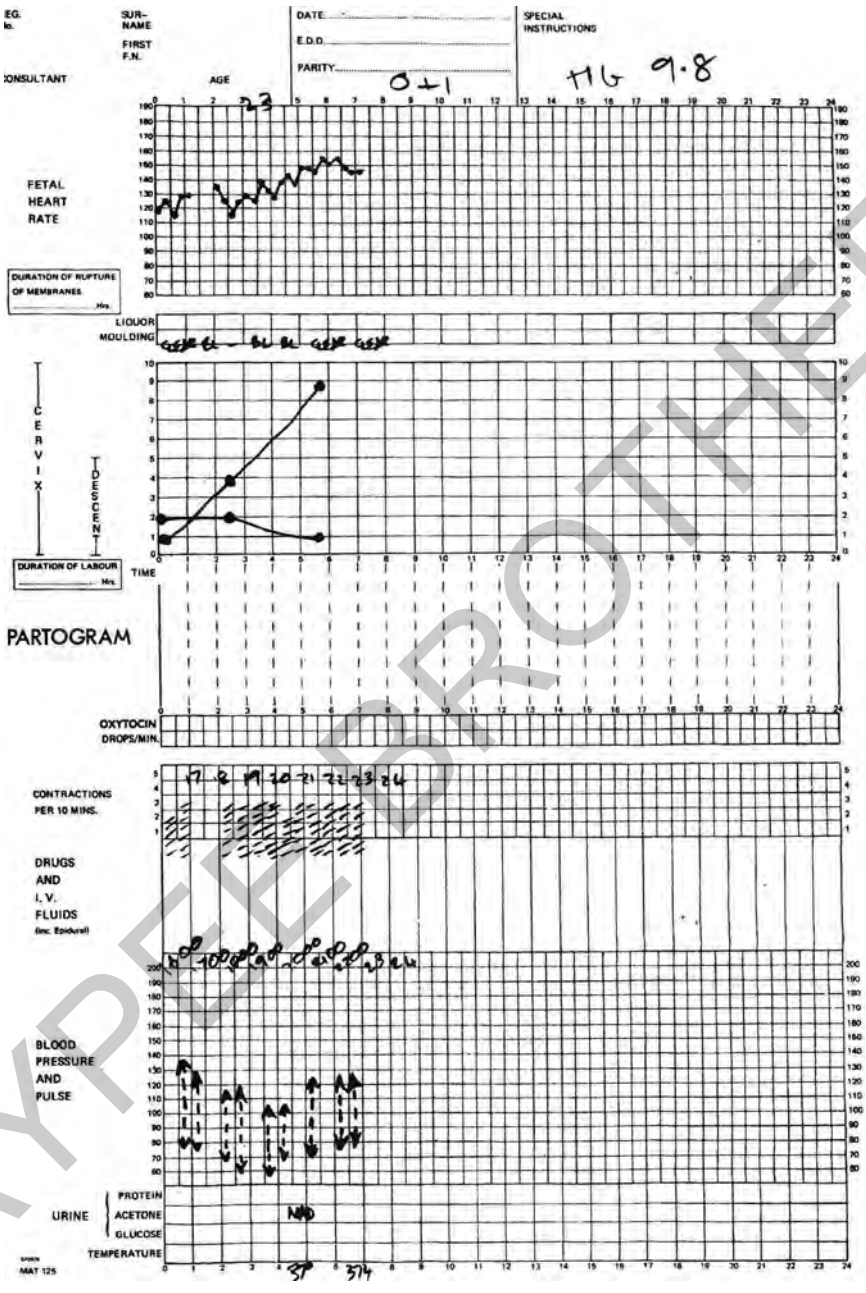

Fig. 3.7: The partograph is a composite chart on which to record individual patient data. It helps present the labor progress pictorially in addition to providing recordings of maternal vital signs, fetal heart rate, and any medications administered during labor.

fetal ear, although the correct determination can be difficult particularly when labor has been endured long enough for caput succedaneum and molding of the skull bones to develop and

JAYPEE BROTHERS

obscure these landmarks. It is therefore always prudent to perform an abdominal examination for presentation and position at the outset and prior to every vaginal examination. A bedside ultrasound scan can also aid position determination in skilled hands.

Women in established labor vary to a large extent in their pain threshold, the extremes being those who quietly reach full cervical dilatation, and those who look completely exhausted with mild contractions of short duration. The majority, however, can cope reasonably well during the early part of the first stage of labor, perhaps using simple analgesia such as paracetamol and codeine phosphate and/or entonox, progressing later to other options such as intramuscular pethidine (meperidine) and/or even epidural anesthesia, resources permitting.

Until recently, it had been customary to ensure that patients in established labor refrained from eating and drinking even clear fluids, in view of the delayed gastric emptying that prevails during pregnancy and, in a more pronounced form, during labor. However, women should be encouraged to drink clear fluids (including "energy/sports" drinks) throughout labor to reduce the incidence of dehydration and ketone body formation and maximize labor efficiency and their physical condition should they need surgery. Most women do not feel hungry when in labor; large meals including snacks should be avoided in all women with a high risk of requiring operative procedures.

A number of studies have investigated the rate of progress in labor. In order to construct a plan for expected dilatation and therefore decision-making during the management of the first stage, it is necessary to put the results of these studies into perspective. The main conclusion is that the mean duration of the observed first stage of spontaneous labor is about 6 hours in the nullipara, compared with about 4.5 hours in the multipara. In addition, the first stage of spontaneous labor takes <10 hours in 88% of nullipara, compared with 95% of multipara. Cervical dilatation at the rate of 1 cm/hour can therefore be viewed as the slowest mean rate of spontaneous progress in labor. Failure to achieve full cervical dilatation within these time limits, especially after the stage of a 6-cm dilated cervix, should alert the attendant to the possibility of cephalopelvic disproportion, whether it be absolute, due to the fetal head lying in the occipitoposterior position or, more commonly, the result of inefficient uterine contractions.

There have been a number of attempts at introducing a pressure catheter to measure intrauterine pressure as an index of "adequate uterine contraction". Its practicability has not been widely accepted. There is no evidence that the incidence of uterine rupture, maternal or perinatal morbidity or mortality is any lower when intrauterine pressure catheters are used routinely.

Induction of Labor

Interruption of the spontaneous course of pregnancy may be indicated in a number of conditions when it is judged that continuation of pregnancy may pose a greater risk to maternal or fetal well-being than delivery. Common indications for induction of labor include pre-eclampsia, a fetus that is small-for-gestational age, and the continuation of a singleton pregnancy beyond 41 weeks. The principle that governs successful induction of labor is the initiation of rhythmic uterine contractions that will induce effacement and dilatation of the cervix. This can be achieved by amniotomy (rupture of membranes) alone or followed by an oxytocin infusion. The process

JAYPEE BROTHERS

can be facilitated by prior vaginal administration of prostaglandin E_2 in a gel or tablet form, or the synthetic prostaglandin E_1 analog (misoprostol) which helps soften the cervix and stimulate uterine contractions, and which in turn induces further cervical ripening and dilatation. Some practitioners also advocate "membrane sweeps" as a less-medicalized approach to labor induction whereby a finger is inserted into the cervix with the aim of separating the fetal membrane from the lower segment that may result in the release of local prostaglandins. However, this may cause undue discomfort, it is not as effective as previous techniques and some practitioners are concerned about the possibility of introducing infection.

Amniotomy

Rupture of the membranes often occurs spontaneously during the first stage of labor, especially approaching full dilatation of the cervix. The frequency and strength of uterine contractions increase after membranes have ruptured and, given this, artificial rupture of the membranes (AROM, amniotomy) can be performed to enhance the progress of labor where spontaneous rupture has not occurred, should the first stage be slow. Amniotomy is conducted by vaginal examination, where the AmniHook is guided by the examining fingers to the forewaters (the bag of fetal membranes), which leads ahead of the presenting part (Figs. 3.8 and 3.9). The attendant should confirm that no cord is felt behind the membranes, or vessels within the membrane and that there is a presenting part (usually head) engaged in the pelvis before performing the AROM. The color of the liquor (clear, meconium-stained and/or blood-stained) is noted and it is wise to obtain a recording of the fetal heart by cardiotocography for the following 20 minutes.

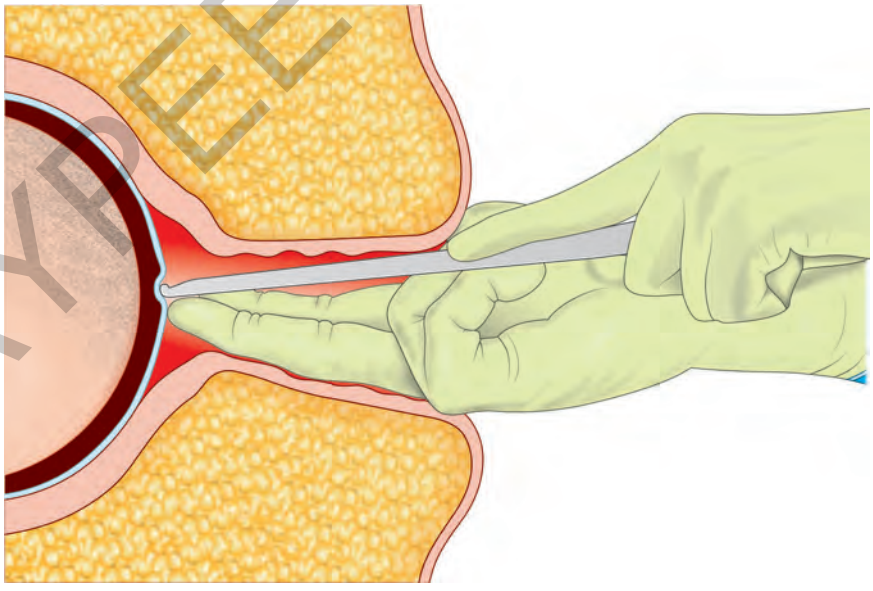

Fig. 3.8: Amniotomy.

JAYPEE BROTHERS



Fig. 3.9: A plastic AmniHook in common use.

Fetal Scalp Blood Sampling

During the course of labor, concern may arise regarding fetal well-being by way of an abnormal CTG. Fetal scalp capillary blood sampling (FBS) to measure blood gases and acid base balance can be used during labor as an adjunct to CTG analysis and allows labor to safely continue when results are reassuring (Figs. 3.10 to 3.14).

Fetal scalp blood sampling results must be interpreted carefully. A pH value <7.20 indicates urgent delivery by cesarean section or, in suitable cases, by operative vaginal delivery. The latter course can be followed in the case of full dilatation of the cervix with the head low down in the pelvis, especially in a rapidly progressive labor. If the fetal scalp blood pH is >7.25, it is reasonable to exclude acidosis, but if values lie between 7.20 and 7.25, the sampling must be repeated within 30 minutes, if the fetal heart tracing suggests that such a wait is permissible.

Technique

After taking consent and confirming that the blood gas analyzer is working, the patient is usually placed in the lithotomy position, with a wedge under her right side. The procedure can also be performed with the parturient in the left lateral position.

The vulva is cleaned with sterile water and an amnioscope inserted. The fetal scalp is then cleaned with cotton rolls or buds, sprayed with ethyl chloride by an assistant, and a high-vacuum silicone grease applied. Ethyl chloride helps arterialize the scalp tissue by inducing reactive vasodilatation, while the high-pressure silicone grease helps the blood released from the scalp to form a droplet. The fetal scalp is then stabbed with a small, 2-mm deep blade (Fig. 3.13), and the blood collected directly into a preheparinized capillary tube. It is important that no air bubbles enter the tube.

JAYPEE BROTHERS

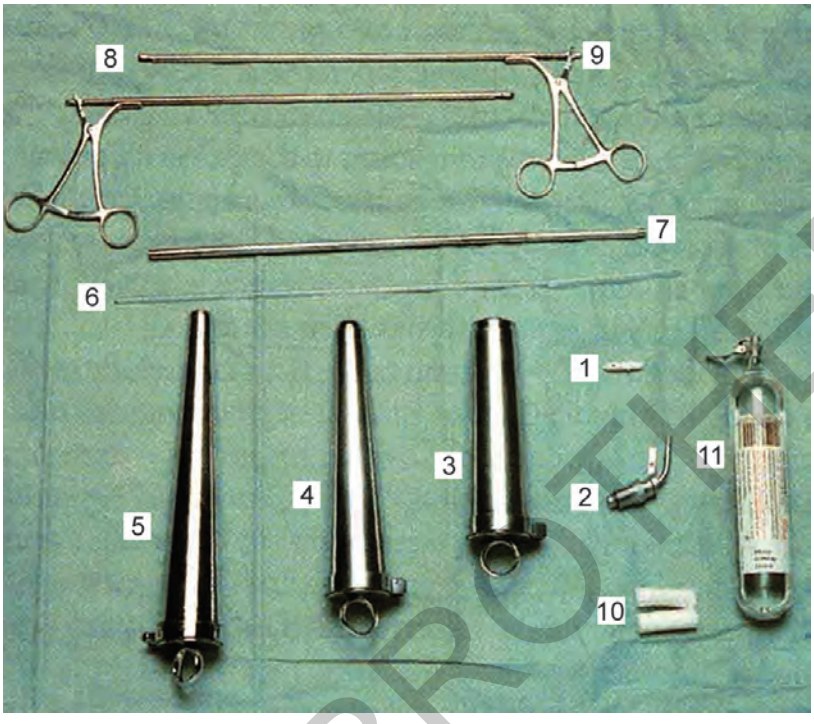

Fig. 3.10: The instruments required in fetal scalp blood sampling: 1. A 2-mm deep blade (*see* Fig. 3.7); 2. Light head (*see* Fig. 3.5); 3–5. Amnioscopes (various sizes); 6. Capillary tube; 7. Blade handle; 8 and 9. Swab holders; 10. Dental rolls (cotton); 11. Ethyl chloride spray.



Fig. 3.11: Fetal scalp blood sampling: a large-sized amnioscope, illuminated with a fiberoptic lead.

JAYPEE BROTHERS

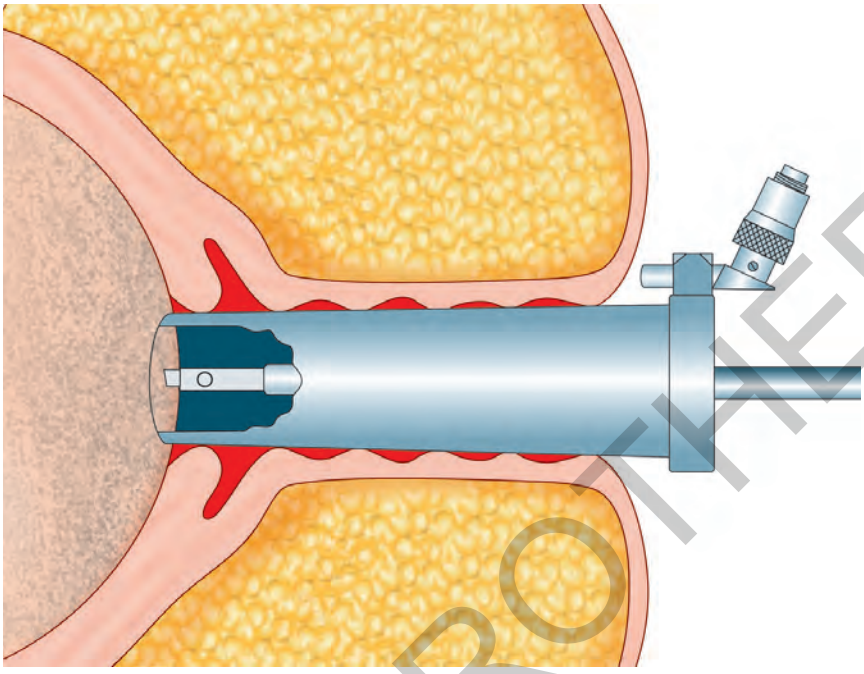

Fig. 3.12: The amnioscope is introduced into the vagina, guided into the cervix by the examiner's fingers, and pressed against the fetal head. A 2-mm blade is used to make a stab incision in the fetal scalp.



Fig. 3.13: A close-up view of the blade used for fetal blood sampling.

Sources of error that may contribute to false pH levels are contamination with amniotic fluid or meconium, the presence of fetal scalp edema and caput and where there is delay in sample processing. The presence of air bubbles and the presence of meconium may falsely elevate pH levels.

JAYPEE BROTHERS

for detailed information on obstetrics & gynecology books, visit our website www.jaypeebrothers.com, for detailed information on obstetrics & gynecology books, visit our website www.jaype

Childbirth and Obstetric Techniques

The third edition of the book *Childbirth and Obstetric Techniques* provides trainee obstetricians, medical students and midwives with an illustrative resource that demystifies the process of childbirth. It describes normal labor and birth and explains variations that may arise and the range of obstetric techniques available to deal with such variations.

The unique collection of color photographs and explanatory artwork brought together in this book emphasizes the practical approach necessary to manage daily situations on the labor ward. The management of childbirth, in all its variations, is illustrated by a step-by-step series of clear images and concise text that illustrate all relevant processes and procedures.

The topics covered are antenatal care and basic ultrasound, the mechanism of childbirth, the management of labor, pain relief in labor, normal labor, resuscitation of the newborn, perineal repair, common problems immediately after delivery, operative vaginal delivery, breech presentation, delivery of twins and cesarean section.

Sophia NE Webster BMedSci BM BS CertClinEd MRCOG is a Consultant Obstetrician in Newcastle Upon Tyne, UK. She has a special interest in high risk obstetrics and the running of the labor ward, as well as a passion for clinical teaching. She has spent considerable time in sub-Saharan Africa advocating for safer pregnancy and participating in skills training programs.



Farook Al-Azzawi MA(Cantab) PhD FRCOG compiled the original work and in collaboration with Dr Sophia Webster developed the 3rd Edition of the book.



JAYPEE BROTHERS

Available at all medical bookstores or buy online at www.jaypeebrothers.com

JAYPEE BROTHERS
Medical Publishers (P) Ltd.
www.jaypeebrothers.com

Join us on facebook.com/JaypeeMedicalPublishers

Shelving Recommendation
OBSTETRICS & GYNECOLOGY

ISBN 978-93-86107-02-2

9 789386 107022