brothers.com, for detailed information on dermatology books, visit our website www.jaypeebrothers.com, for detailed information on dermatology books



Tips & Tricks in Procedural DERMATOLOGY

Efficient and Effective Approaches to Achieving Optimal Diagnostic and Therapeutic Results

Robert T Brodell
Stephen E Helms
Michael T Cosulich
Jeremy D Jackson
Ashish C Bhatia
William Abramovits
Jennifer Schulmeier

Foreword
Marc D Brown

Get Supplementary Videos Access at ***emedicine360.com***

V-1: Lateral Incisions and Exposure of the Nail Matrix, V-2: PDL Criss-Cross Technique, V-3: Demonstration of the Fractionated CO_2 Laser Technique

JAYPEE

Contents

Part 1: Diagnostic Tips and Tricks

Section - A: Tips and Tricks: Office Dermatologic Testing

Stephen E Helms

1. The KOH Preparation 3

Madelyn King, Joy Fen King, Stephen E Helms, Amy E Flischel

- History *3*
- When to Utilize Potassium Hydroxide *3*
- Materials Needed *5*
- Obtaining an Adequate Sample *5*
- Preparation Methods *6*
- Interpretation and Microscopic Features *9*

2. The Scabies Preparation 12

Ira Daniel Harber, Kathleen Casamiquela, Stephen E Helms

- History and Clinical Findings *12*
- Procedures Utilized to Confirm the Diagnosis of Scabies *14*
- Materials *14*
- Recommended Procedure *15*
- Benefits Compared to Alternative Approaches *17*
- Risks and Limitations *19*

3. The Tzanck Preparation 21

Ashton B Davis, Maureen Offiah, Joy Fen King, Stephen E Helms

- History *21*
- Procedure *21*
- Techniques for Staining and Fixation *21*
- Utility of Tzanck Smear in Cytodiagnosis and the Associated Cytological Findings *22*
- Using Tzanck Smear to Narrow a Differential Diagnosis *26*
- Benefits Compared to Alternative Approaches *26*
- Risks and Limitations *26*

Section - B: Tips and Tricks: Biopsy—The Right Spot!

Jennifer Schulmeier, Caitlyn Reed

4. Biopsy Techniques in Dermatology: Maximizing Diagnostic Yield 31

Caitlyn Reed, Jennifer Schulmeier, Jeremy D Jackson, Robert T Brodell

- History *31*
- Subepidermal Blistering Diseases *31*
- Alopecia *33*
- Porokeratosis *34*
- Discoid Lupus *35*
- Pigmented Lesions of the Palm or Sole *36*
- Biopsy of Other Conditions *36*

Section - C: Tips and Tricks: Basic Procedural Techniques

Michael T Cosulich

5. Shave and Saucerization Techniques 41

Lucette Teel Liddell, Michael T Cosulich, Anna Wile

- History and Overview *41*
- Procedure *41*
- Benefits *47*
- Risks and Limitations *48*

6. Punch Biopsies and Other Uses for the Punch Tool 51

Michael T Cosulich, Anna Wile

- History/Overview *51*
- Standard Punch Biopsy Technique *51*
- Special Uses for a Punch *54*
- Risks/Limitations *59*

7. Curettage 62

Jess (Logan) Rush, Lauren M Craig

- History *62*
- Procedures *62*
- Risks and Limitations *68*
- Other Uses for Curettes *68*

8. Suturing 70

Jeremy R Etzkorn, Ilya Lim, Thuzar M Shin

- History/Overview *70*
- Selection of Suturing Materials *70*
- Suturing Technique *76*
- Troubleshooting High-tension Wounds *81*
- Benefits Compared to Alternatives *83*
- Risks/Limitations *84*

Part 2: Tips and Tricks: Chemical Destruction of Skin Lesions

Robert T Brodell

9. Dichloroacetic Acid in Dermatology 87

Jacqueline Graham, Elaine Kunzler, Kristen N Ramey, Robert T Brodell

- History *87*
- Description of Procedure *87*
- Benefits Compared to Alternative Approaches *95*
- Risks and Limitations *96*
- Appendix 1 *97*

Part 3: Tips and Tricks: Complex Surgical Procedures

Ashish C Bhatia

10. Mohs Surgery 101

Brittany L Vieira, Lara E Rosenbaum, Ashish C Bhatia

- History *101*

- Description of Procedure Highlighting Tips and Tricks *101*
- Benefits Compared to Alternative Approaches *104*
- Risks and Limitations *106*

11. Elliptical Excision 109

Derek Hsu, Lara E Rosenbaum, Ashish C Bhatia

- History *109*
- Description of Procedure *109*
- Comparison to Various Procedures *113*
- Complications *113*

12. Nail Procedures: Tips and Tricks 115

Ashley Nault, Sreya Talasila, Shuai "Steve" Xu, Simon Yoo, Aleksandar L Krunic

- History of Nail Procedures *115*
- Instrumentation: Tools of the Trade *115*
- Anesthesia Techniques *116*
- Common Nail Procedures *117*
- Anatomical Danger Zones *122*
- Wound Care *122*
- Avoiding Complications *123*

13. Flaps and Grafts 125

Michael W Pelster, Ashish C Bhatia

- History *125*
- Description of Procedures *125*
- Risks and Limitations *133*

Part 4: Tips and Tricks: Cryosurgery and Cryotherapy

William Abramovits

14. Cryotherapy and Cryosurgery 139

William Abramovits, Hannah R Badon, Kimberly Dawn Vincent, Hamad Patel, Stephen E Helms, Ronald Lubritz

- History of Cryosurgery *140*
- Principles behind Cryosurgery *140*
- Clinical Decision-making in Cryosurgery *143*
- Management *149*
- Failures *149*

Part 5: Tips and Tricks: Light-based Procedures

Robert T Brodell

15. Vascular Lesion Lasers 155

Natalie Semchyshyn, Anastasia Kurta, Dee Anna Glaser

- History *155*
- Procedure *155*
- Port-Wine Stain Birthmarks *156*
- Hemangiomas *158*
- Cherry Angiomas and Spider Angiomas *159*

- Telangiectasia: Rosacea, Poikiloderma of Civatte, Sun Damage *160*
- Striae Distensae *162*
- Scars *162*
- Postprocedural Ecchymosis *163*

16. Fractionated CO_2 Laser 166

Ardalan Minokadeh, Elizabeth I McBurney

- History *166*
- Description of Procedure *166*
- Benefits Compared to Alternative Approaches *173*
- Risks and Limitations *173*

17. Pigmented Lesion Lasers 174

Evan Stiegel, Shilpi Khetarpal, Michelle B Tarbox, Jennifer Lucas

- History *174*
- Procedure *175*
- Additional Tattoo Removal Treatment Tips *180*
- Benefits Compared to Other Approaches *181*
- Risks/Limitations *183*

18. Intense Pulsed Light 186

Jessica Tran, Daniel P Friedmann, Vineet Mishra

- History *186*
- Mechanism of Action *186*
- Indications *187*
- Contraindications *187*
- Preoperative Considerations *187*
- Treatment *188*
- Benefits Compared to Alternative Approaches *191*
- Risks/Limitations *192*

Part 6: Tips and Tricks: Photodynamic Therapy

Allison R Cruse, Dylan Harrell, Jeremy D Jackson

19. Photodynamic Therapy 197

Allison R Cruse, Patrick C Carr, Dylan Harrell, Jeremy D Jackson

- History of Photodynamic Therapy *197*
- Mechanism *197*
- Actinic Keratoses *198*
- Decreasing Adverse Side Effects *201*
- Other Uses of Photodynamic Therapy *202*
- Less Common Uses *203*

Index 205

PART 1

Diagnostic Tips and Tricks

SECTION - B

Tips and Tricks: Biopsy – The Right Spot!

—Jennifer Schulmeier, Caitlyn Reed

JAYPEE BROTHERS

CHAPTER 4

Biopsy Techniques in Dermatology: Maximizing Diagnostic Yield

Caitlyn Reed, Jennifer Schulmeier, Jeremy D Jackson, Robert T Brodell

"A skin biopsy of the right type from the right place will eventuate in the right histopathologic diagnosis"

—Robert T Brodell

HISTORY

The field of cutaneous surgery is continuously evolving as clinicians develop methods to accomplish therapeutic and diagnostic goals while minimizing cosmetic defects. Unfortunately, the laudable concern for cosmesis can have unintended consequences, including a tendency toward increasingly smaller biopsies which may be inadequate for pathologic interpretation.[1] In some cases, a specimen is not obtained from an optimal site or is not properly prepared at the bedside; and occasionally, clinicians provide historical information that is inadequate for proper clinical-pathologic correlation.[2] These shortcomings may result in everything from the dermatopathologist's request for additional tissue to a pathologic diagnosis that correlates poorly with the clinical presentation to a significant error in diagnosis.

This chapter stresses the need for clinicians to "think pathologically."

This chapter stresses the need for clinicians to "think pathologically." For example, selection of the correct biopsy site is often directed by both a good working diagnosis and knowledge of the histopathology of the disease processes entertained. In some cases, bedside "grossing" maximizes the information that can be gleaned from a tissue specimen while minimizing harm to the patient. Providing the laboratory with an abstracted history and physical examination and any requests for special specimen handling will help ensure the best possible pathologic diagnosis.[3] We will discuss optimal biopsy sites for a few selected disease processes and some directed bedside biopsy and "grossing" techniques that will help lead to correct histopathologic diagnoses.

SUBEPIDERMAL BLISTERING DISEASES

Subepidermal blistering diseases include bullous pemphigoid (BP), epidermolysis bullosa acquisita (EBA), dermatitis herpetiformis (DH), linear IgA bullous dermatosis (LABD) and porphyria cutanea tarda (PCT). Each of these conditions presents with tense bullae.

Traditionally, the diagnosis of these conditions is confirmed by obtaining two punch biopsies: one from perilesional skin for direct immunofluorescence (DIF) and the other from lesional skin for hematoxylin and eosin (H&E) light microscopy.[4-6] A biopsy of perilesional skin is required because the epidermis must be attached for successful DIF studies.[7] A more efficient approach requires only one punch biopsy used for both H&E and DIF studies. This punch may be obtained in one of two ways (Figs. 1A to D), both methods yielding an ideal specimen for diagnosis.[8]

JAYPEE BROTHERS

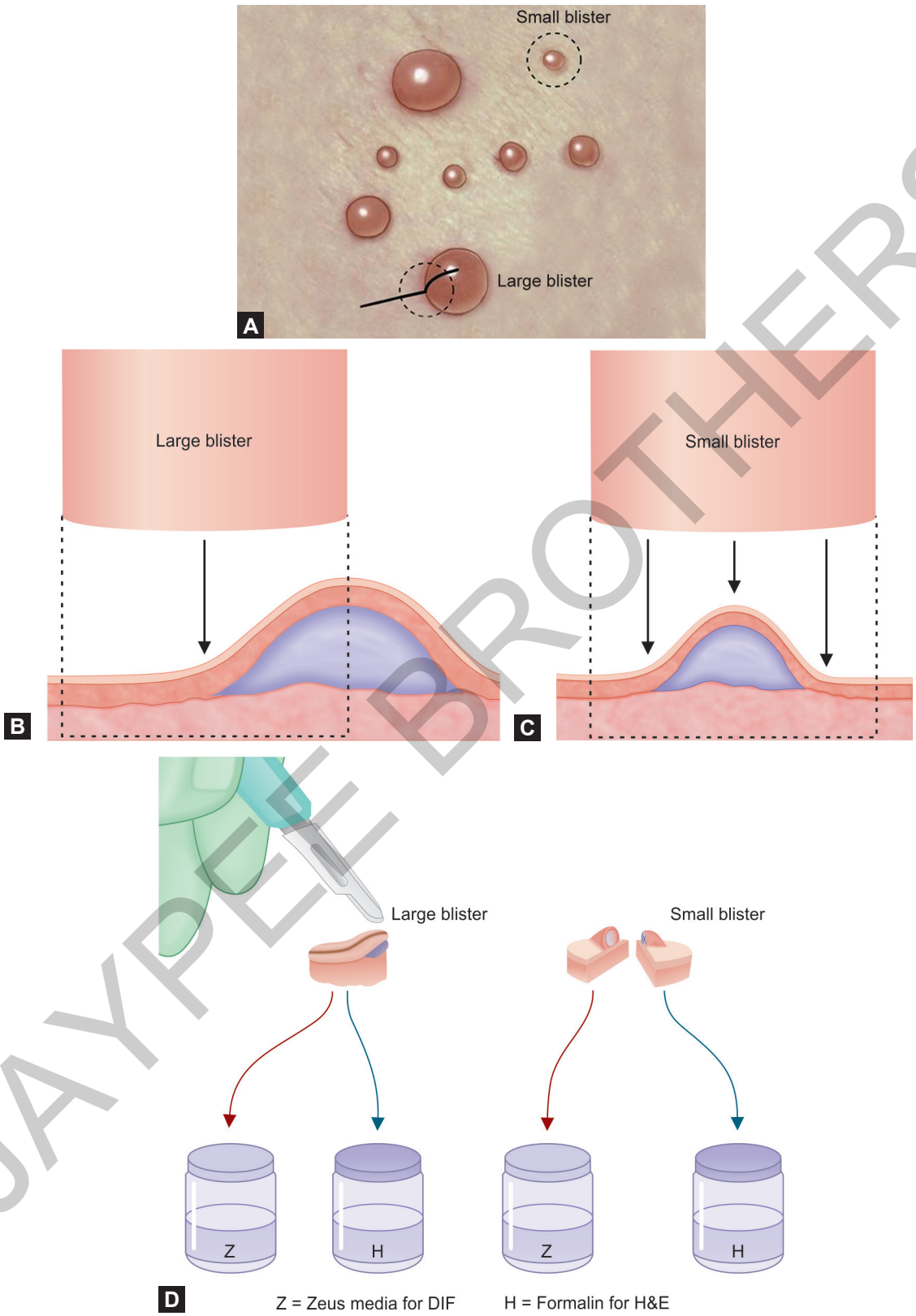

Figs. 1A to D: An efficient approach for obtaining maximal information from the biopsy of a tense blister.
Source: Adapted from reference 9.

JAYPEE BROTHERS

A more efficient approach requires only one punch biopsy used for both H&E and DIF studies.

To biopsy an entire blister, choose a small 1–2 mm tense blister. Anesthetize the area with 1% lidocaine with epinephrine. Using an 8-mm punch, center the blister under the punch. This will include at least 3 mm of perilesional skin all the way around the blister. Using a number 15 blade and holding the specimen with a pair of forceps, bisect the specimen with a sawing motion.

For the second approach, any intact blister may be chosen. First clean the skin with an alcohol pad. Then draw a line from the apex of the blister onto the adjacent perilesional skin. Anesthetize the area with 1% lidocaine with epinephrine. Using an 8-mm punch, take a biopsy, centered on the line, to include 75% perilesional skin and 25% blister. Bisect the specimen along the line using a number 15 blade with a sawing motion, stabilizing the specimen with a pair of forceps.

With each technique, one-half of the specimens is submitted in formalin for H&E and one-half in Zeus (or Michel's) medium for DIF. If the selected blister is located in an area that may be difficult to close after a deep punch biopsy, such as the anterior shins, a saucerization biopsy may be preferable. The biopsy should still be taken to include the blister "take-off point" as well as perilesional skin, but there is no need to include subcutaneous tissue.

Including the "take-off point" of the blister in the DIF specimen makes it possible to determine if the immunoprecipitants are decorating the roof or on the floor of the blister. This provides much the same information as a "salt-split skin" specimen, without having to perform this additional, expensive procedure. Since perilesional skin is also included in the DIF specimen, the dermatopathologist will also distinguish immunoprecipitants at the dermoepidermal junction versus papillary dermis of nonblistered skin.[5,6]

ALOPECIA

Biopsies of the scalp are often performed for the evaluation of alopecia. Again, biopsy site selection is one of the most important steps in the process, though this is often challenging. While sampling the center of a lesion from a nonscarring process may yield helpful information, the active margin of a cicatricial alopecia usually is a better choice. Submission of two 4 mm punch biopsies, each extending into peribulbar fat, is recommended, so that one biopsy may be submitted for vertical sectioning, while the other is submitted for transverse sectioning.[9] The horizontal sections allow the pathologist to evaluate the density of hair follicles as well as the morphology of multiple follicles in a single section. For disease processes, such as lupus erythematosus (LE), vertical sections are ideal for evaluation of the dermoepidermal junction.[10]

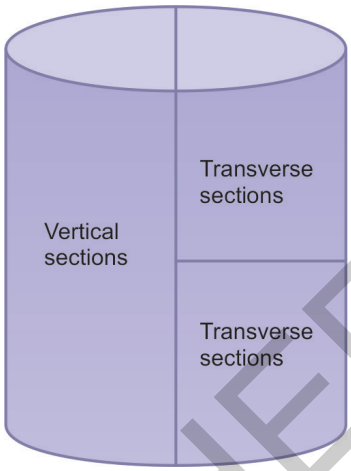

Fig. 2: The Tyler technique for efficient punch biopsy sampling of scalp alopecia.
Source: Adapted from reference 12.

Alternatively, there are two grossing techniques that allow both horizontal and vertical sections to be obtained from a single punch biopsy. The Tyler technique involves bisecting a punch biopsy vertically, then bisecting one of the two resulting halves transversely.[11] The vertical section is then submitted with the two transverse sections side-by-side in a single block with their new cut edges embedded down (Fig. 2). Each resulting slide level shows both progressively deeper and more superficial transverse sections alongside a vertical section. This technique is especially useful when the differential diagnosis includes entities that may require visualization

JAYPEE BROTHERS

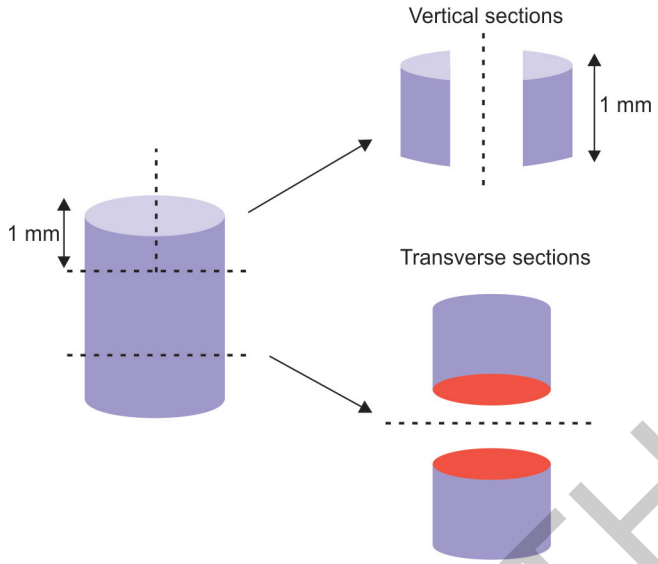

Fig. 3: The HoVert technique for efficient punch biopsy sampling of scalp alopecia.
Source: Adapted from reference 13.

of deep peribulbar fat as well as both vertical and transverse sections for diagnosis.

There are two grossing techniques which allow both horizontal and vertical sections to be obtained from a single punch biopsy: the Tyler and HoVert techniques.

The HoVert technique of preparing a punch biopsy is a three-step process (Fig. 3).[12] First, the most superficial 1 mm of the punch is removed, creating an "epidermal disk". The deep surface of the epidermal disk is inked, then the disk is bisected vertically and embedded for vertical sectioning. One-half of the epidermal disk may also be submitted for DIF studies, if needed. The lower portion of the biopsy is then bisected or trisected transversely and submitted for transverse sectioning. This method allows for vertical sections of the epidermis and upper dermis along with transverse sections of the lower dermis and peribulbar fat while minimizing the number of biopsies required.

POROKERATOSIS

Porokeratosis is a condition characterized by a small keratotic papule that slowly expands, producing plaques up to several centimeters in diameter.[13,14] Because variable, nonspecific findings (atrophy, acanthosis, verrucous hyperplasia, a lichenoid tissue reaction) are present at the centers of patches of porokeratosis, it is critical to appropriately biopsy the raised margin (cornoid lamella).[15]

A three-step technique ensures proper orientation of the punch biopsy to maximize the potential for a correct diagnosis (Figs. 4A to C).[16] First, after blotting the skin with an alcohol swab, a line is drawn with a skin marker across and perpendicular to the margin of the patch (cornoid lamella). Then, a 6 mm punch biopsy is performed centered on the intersection of the line and the cornoid lamella. Last, the biopsy is bisected at bedside along the skin marker line using a number 15 blade and a sawing motion. The requisition sheet should include instructions for the laboratory technician to embed the specimen with the cut surfaces down so that cross-sections of the cornoid lamella will be visible.

A critical step in this process is bisecting the punch biopsy specimen at the bedside.

A critical step in this process is bisecting the punch biopsy specimen at the bedside. The clinician cannot depend upon the laboratory to pro-

JAYPEE BROTHERS

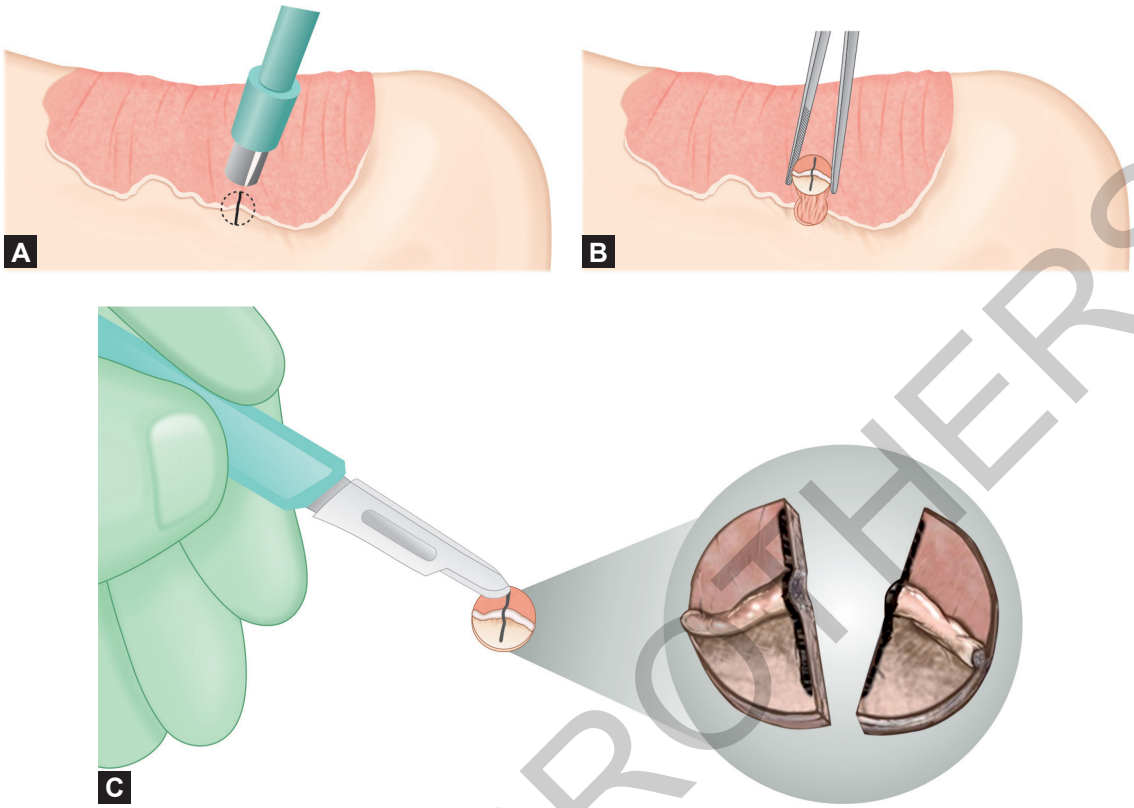

Figs. 4A to C: An efficient and effective approach to biopsy porokeratosis.
Source: Adapted from reference 17.

perly orient the punch specimen since it is likely the cornoid lamella will not be visible on the skin surface. Furthermore, a technician grossing the specimen may not be aware of the importance of properly oriented sectioning of the cornoid lamella.

DISCOID LUPUS

Lupus erythematosus is an autoimmune disease with myriad presentations affecting multiple organ systems. The disease may be limited to the skin, or it may lead to multiorgan dysfunction. Clinically, the disease is subdivided into systemic, subacute cutaneous, and discoid or chronic forms, each with its own characteristic skin manifestation. The diagnosis of systemic LE is made clinically, based on a well-established set of criteria.[10] However, the diagnosis of cutaneous LE may require the correlation of clinical findings with histopathology, occasionally with the aid of DIF.

Discoid LE is by far the most common form of cutaneous LE, representing up to 85% of cutaneous LE cases.[17] Classically, the lesions of discoid LE are well-circumscribed, erythematous plaques with thick, adherent scale and follicular plugging. Central scarring with hypopigmentation is characteristic of older lesions, while earlier lesions are erythematous due to active cutaneous inflammation.[18]

> The advancing margin of a scarred plaque is the optimal biopsy site for discoid LE.

The advancing margin of a scarred plaque is the optimal biopsy site for discoid LE.[19] This site is most likely to demonstrate active disease without nonspecific findings, such as scarring, which appear in the older, central areas of these lesions. Conversely, when submitting a specimen for DIF, the center of a scarred plaque will have the highest diagnostic yield, showing granular immunoglobulin G (IgG) deposition at the basement membrane.

JAYPEE BROTHERS

PIGMENTED LESIONS OF THE PALM OR SOLE

Acral skin is distinct from other areas of the body. It is characterized by a thick and compact stratum corneum, numerous eccrine glands, and lack of pilosebaceous units.[20] It is also the only area of skin which contains dermatoglyphs. These distinctive features of acral skin lead to similarly distinctive patterns of pigment deposition in benign and malignant lesions.[21] Typical patterns of benign melanocytic nevi may be observed by dermoscopy and include: parallel-furrow pattern, lattice-like pattern, and fibrillar pattern.[22] These patterns result from melanocytic nests located in the furrows rather than ridges of dermatoglyphs. In contrast, malignant lesions, such as acral lentiginous melanoma, tend to exhibit a parallel-ridge pattern or irregular diffuse pigmentation with melanocytic nests at the ridges of dermatoglyphs.[23]

Because the distinction between benign and malignant acral pigmented lesions lies in visualization of melanocytic nests and their location relative to the ridges and furrows of dermatoglyphs, correct preparation of biopsies is essential. If the shave or saucerization biopsy is bisected longitudinally (parallel to dermatoglyphs) the histopathology is difficult to interpret. Subsequent sections may or may not be sufficient to view the location of nests. To ensure that the nests are present on histology in the correct orientation, the biopsy may be bisected at bedside perpendicular to the dermatoglyphs visualized dermatoscopically. The requisition should include a note to the histology technician that the specimen should be imbedded with the cut surfaces down.

BIOPSY OF OTHER CONDITIONS

A quick reference (Table 1)[24-26] includes the tips and tricks mentioned above and other recommended approaches organized by physical findings. These include suggestions for palpable purpura (possible leukocytoclastic vasculitis), subdermal nodules (possible panniculitis), pearly plaques (possible basal cell carcinoma), and crusted warty plaques (possible squamous cell carcinoma).

Benefits of Using these Biopsy Approaches

Conventionally, when submitting a biopsy for either subepidermal blistering disease or for alopecia, two biopsies were required. In the case of blistering diseases, perilesional skin and lesional skin ideally are inspected microscopically to make a diagnosis. For alopecias, both vertical and transverse sections may be needed. Alternative techniques which allow for all the required information to be obtained from a single biopsy which has several distinct advantages. First, a single biopsy can be performed more quickly in a busy outpatient setting. Second, a single biopsy offers a cosmetic advantage. Third, a single biopsy is more cost-effective since the patient is billed for only one biopsy instead of two.

In the case of porokeratosis or discoid LE, biopsy site selection is a key. Including the cornoid lamella in the correct orientation allows the diagnosis of porokeratosis to be made correctly virtually every time. If a biopsy is taken from the center of porokeratosis, or if it is not prepared correctly, the chances of making a correct histopathologic diagnosis are greatly reduced. Similarly, if a biopsy is taken from the center of a discoid LE plaque, H&E sections will show only nonspecific changes, while if the advancing margin is biopsied, active disease can be identified and the correct diagnosis made.

In all of the techniques presented in this chapter, "grossing" of the specimen is a key factor. Both the dermatologist taking the biopsy and the pathologist or technician preparing the specimen must know the steps and the correct orientation for imbedding the tissue. If the correct procedure is followed, the likelihood of making an accurate diagnosis is greatly increased.

Risks and Limitations of these Techniques

The main limitation associated with a new biopsy technique is incorrect handling of the specimen. Each specimen must be taken from the correct location, prepared in the correct way and embedded in the correct orientation. If any of these steps is performed incorrectly, the resultant

JAYPEE BROTHERS

Table 1: Summary of skin biopsy tips and tricks.

Physical findings	*Biopsy technique*	*Location*	*Comments*
Tense blister	8 mm punch biopsy	Either an entire small (1–2 mm) blister or part of a large blister, including perilesional skin	See the above section
Flaccid blister	3 mm or 4 mm punch biopsy	Early, small blister	Take care to preserve the dermal-epidermal attachment; refrigerant spray may be used prior to biopsy[23]
Palpable purpura (possible leukocytoclastic vasculitis)	Deep punch biopsy including subcutaneous fat	Well-established lesion	A more acute lesion may be chosen for DIF evaluation[24]
Tender subdermal nodules (possible panniculitis)	Deep incisional biopsy or ≥6-mm punch biopsy	Nonulcerated area; subcutaneous fat must be included for the evaluation of panniculitis	If a necrotic focus is present, the edge of this focus should be submitted for culture and special stains
Scarred plaque	Punch biopsy	Active border of lesion for H&E; center of lesion for DIF, if LE is suspected	See the above section
Scarring alopecia	≥4 mm punch biopsy	Erythematous area with visible hair shafts	See above section; if an area of complete scarring is chosen, only nonspecific changes will be present on histopathology[25]
Nonscarring alopecia	≥4 mm punch biopsy	Established area for suspected telogen effluvium or pattern alopecia; newer area for suspected alopecia areata or syphilis[24]	See the above section; transverse sections are important in evaluating the anagen-to-telogen and terminal-to-vellus hair ratios[24]
Pearly eroded plaque (possible basal cell carcinoma)	Shave or punch biopsy	Entire lesion, if possible, or area without necrosis	A conservative excisional biopsy may be performed for evaluation of margins and invasion
Crusted warty plaque (possible squamous cell carcinoma)	Shave or punch biopsy	Entire lesion, if possible, or area without necrosis; if possible, sample base of lesion	A conservative excisional biopsy may be performed for evaluation of margins and possible invasive growth
Atypical pigmented lesion (possible melanoma)	Shave or saucerization	Entire lesion, if possible	A maximal view of the dermoepidermal junction aids in diagnosis and determination of Breslow depth requires sampling of the dermis below the lesion

(H&E: Hematoxylin and eosin; DIF: Direct immunofluorescence; LE: Lupus erythematosus).

histopathology may be nondiagnostic. Communication between all levels of providers—from the dermatologist to the laboratory technician to the dermatopathologist—is key.

Conflict of Interest

Robert T Brodell discloses the following potential conflicts of interest: honoraria have been received from presentations for Allergan, Galderma, and PharmaDerm, a division of Nycomed US Incorporation. Consultancy fees have been received from Galderma Laboratories, LP. Clinical trials have been performed for Genentech and Janssen Biotech, Incorporation. Jeremy Jeremy Jackson discloses the following potential conflicts of interest: honoraria have been received from presentations for Abbvie, Celgene, Actelion, and Sun Pharmaceuticals. Caitlyn Reed and Jennifer Schulmeier have no conflicts of interest.

REFERENCES

1. Fernandez EM, Helm T, Ioffreda M, et al. The vanishing biopsy: the trend toward smaller specimens. Cutis. 2005;76(5):335-9.
2. Comfere NI, Sokumbi O, Montori VM, et al. Provider-to-provider communication in dermatology

JAYPEE BROTHERS

and implications of missing clinical information in skin biopsy requisition forms: a systematic review. Int J Dermatol. 2014;53(5):549-57.
3. Cockerell CJ. How can dermatologists help dermatopathologists work "smarter" for them? Cutis. 2015;95(4):190-1.
4. Mihai S, Sitaru C. Immunopathology and molecular diagnosis of autoimmune bullous diseases. J Cell Mol Med. 2007;11(3):462-81.
5. Yeh SW, Ahmed B, Sami N, et al. Blistering disorders: diagnosis and treatment. Dermatol Ther. 2003;16(3):214-23.
6. Habif TP. Vesicular and bullous diseases. In: Clinical Dermatology: A Color Guide to Diagnosis and Therapy, 5th edition. Edinburg, Scotland: Mosby; 2010. pp. 635-70.
7. High WA. Blistering diseases. In: Elston DM, Ferringer T (Eds). Requisites in Dermatology: Dermatopathology, 1st edition. Edinburgh, Scotland: Saunders-Elsevier; 2009. pp. 161-72.
8. Braswell MA, McCowan NK, Schulmeier JS, et al. High-yield biopsy technique for subepidermal blisters. Cutis. 2015;95(4):237-40.
9. Elston D, McCollough ML, Angeloni VL. Vertical and transverse sections of alopecia biopsy specimens: combining the two to maximize diagnostic yield. J Am Acad Dermatol. 1995;32(3):454-7.
10. Crowson AN, Magro C. The cutaneous pathology of lupus erythematosus: a review. J Cutan Pathol. 2001;28(1):1-23.
11. Elston D. The 'Tyler technique' for alopecia biopsies. J Cutan Pathol. 2012;39(2):306.
12. Nguyen JV, Hudacek K, Whitten JA, et al. The HoVert technique: a novel method for the sectioning of alopecia biopsies. J Cutan Pathol. 2011;38(5): 401-6.
13. Pierson D, Bandel C, Ehrig, et al. Benign epidermal tumors and proliferations. In: Bolognia J, Jorizzo J, Rapini R, Horn T, Mascaro J, Saurat J, Mancini A, Salasche S, Stingl G (Eds). Dermatology. Edinburgh, Scotland: Elsevier; 2003. pp. 1707-9.
14. Richard G, Irvine A, Traupe H, et al. Ichthyosis and disorders of other cornification. In: Schachenr L, Hansen R, Krafchik B, Lucky A, Paller A, Rogers M, Torrelo A (Eds). Pediatric Dermatology. Philadelphia, PA, USA: Elsevier; 2011. pp. 640-3.
15. De Simone C, Paradisi A, Massi G, et al. Giant verrucous porokeratosis of Mibelli mimicking psoriasis in a patient with psoriasis. J Am Acad Dermatol. 2007;57(4):665-8.
16. Reed C, Reddy R, Brodell RT. Diagnosing porokeratosis of Mibelli every time: a novel biopsy technique to maximize histopathologic confirmation. Cutis. 2016;97(3):188-90.
17. Bharti S, Dogra S, Saikia B, et al. Immunofluorescence profile of discoid lupus erythematosus. Indian J Pathol Microbiol. 2015;58(4):479-82.
18. Winfield H, Jaworsky C. Connective tissue diseases. In: Elder DE, Elenitas R, Murphy GF, Johnson BL, Xu X (Eds). Lever's Histopathology of the Skin, 10th edition. Philadelphia, PA, USA: Lippincott Williams & Watkins; 2009. pp. 329-64.
19. Sina B, Kao GF, Deng AC, et al. Skin biopsy for inflammatory and common neoplastic skin diseases: optimum time, best location and preferred techniques. A critical review. J Cutan Pathol. 2009; 36(5):505-10.
20. Lian CG, Murphy GF. Chapter 3. Histology of the skin. In: Elder DE, Elenitsas R, Rosenbach M, Murphy GF, Rubin AI, Xu X. Lever's Histopathology of the Skin, 11th edition. Philadelphia, PA, USA: Lippincott Williams & Wilkins; 2015. pp. 8-75.
21. Thomas L, Phan A, Pralong P, et al. Special locations dermoscopy: facial, acral, and nail. Derm Clin. 2013;31(4):615-24.
22. Saida T, Oguchi S, Ishihara Y. In vivo observation of magnified features of pigmented lesions on volar skin using videomicroscope: usefulness of epiluminescence technique in clinical diagnosis. Arch Dermatol. 1995;131:298-304.
23. Phan A, Dalle S, Touzet S, et al. Dermoscopic features o facral lentiginous melanoma in a large series of 110 cases in a white population. Br J Dermatol. 2010;162(4):765-71.
24. Wu H, Allan AE, Harrist TJ. Chapter 9. Noninfectious vesiculobullous and vesiculopustular diseases. In: Elder DE, Elenitsas R, Rosenbach M, Murphy GF, Rubin AI, Xu X. Lever's Histopathology of the Skin, 11th edition. Philadelphia, PA, USA: Lippincott Williams & Wilkins; 2015. pp. 276-328.
25. Elston DM, Stratman EJ, Miller SJ. Skin biopsy: Biopsy issues in specific diseases. J Am Acad Dermatol. 2016;74(1):1-16.
26. Elentsas R, Ming ME. Chapter 2. Biopsy techniques. In: Elder DE, Elenitsas R, Rosenbach M, Murphy GF, Rubin AI, Xu X. Lever's Histopathology of the Skin, 11th edition. Philadelphia, PA, USA: Lippincott Williams & Wilkins; 2015. pp. 6-7.

JAYPEE BROTHERS

for detailed information on dermatology books, visit our website **www.jaypeebrothers.com,** for detailed information on dermatology books, visit our webs

Tips & Tricks in Procedural DERMATOLOGY

This unique compendium of practical *Tips and Tricks in Procedural Dermatology* highlights techniques designed to enhance common dermatologic tests and surgeries. The goal of these innovations is to maximize outcomes by providing simple, quick, efficient, effective, almost "fail-safe" office surgeries that minimize expense and risk for the benefit of our patients.

Careful descriptions, clinical photographs and artistic renderings are utilized to demonstrate:

- Optimal methods for performing common office dermatologic tests: potassium hydroxide, scabies, and Tzanck preparations
- Proper choice of biopsy location
- Improvements in routine surgical procedures including shave and punch biopsies, curettage, and suturing techniques
- Techniques involving chemical destruction of appropriate lesions
- Novel enhancements of complex procedures in dermatologic surgery including Mohs surgery, elliptical excisions, nail procedures, flaps and grafts
- Cryotherapy and cryosurgery tips to improve outcomes
- New approaches to light-based therapy including photodynamic therapy, vascular lesion laser, pigmented lesion laser, fractionated CO_2 laser, and intense pulsed light (IPL) technologies.

Robert T Brodell MD is Professor and Chairman of the Department of Dermatology and Professor and Interim Chairman of the Department of Pathology, University of Mississippi Medical Center in Jackson, Mississippi, USA and Instructor in Dermatology at the University of Rochester School of Medicine and Dentistry in Rochester, New York, USA. He has published many tips and tricks in procedural dermatology emphasizing his interest in surgery for the medical dermatologist.



Stephen E Helms MD is Professor and Interim Vice Chairman of the Department of Dermatology at the University of Mississippi Medical Center in Jackson, Mississippi, USA. His subspecialty interest is contact dermatitis and other interests include office (bedside) dermatologic testing and patient safety.



Michael T Cosulich MD is Instructor in Dermatology at the University of Mississippi Medical Center in Jackson, Mississippi, USA. He has a special interest in surgical dermatology and increasing office efficiency.



Jeremy D Jackson MD is Associate Professor of Dermatology at the University of Mississippi Medical Center in Jackson, Mississippi, USA. He is double boarded in Internal Medicine and Dermatology and has subspecialty interests in the areas of cutaneous lymphoma, complex medical dermatology, hospitalist dermatology and photodynamic therapy.



Ashish C Bhatia MD is Associate Professor of Clinical Dermatology at Northwestern University Feinberg School of Medicine in Chicago, Illinois, USA. He is a fellowship-trained dermatologic surgeon with extensive experience in Mohs surgery and reconstruction, cosmetic surgery, and laser applications.



William Abramovits MD FAAD is Professor of Dermatology, Department of Internal Medicine, Baylor Scott & White University Hospital and Assistant Clinical Professor (Dermatology) at the University of Texas Medical School, Dallas, Texas, USA. He has numerous publications and teaching experience in the field of cold as therapy and co-edited a textbook on Dermatological Cryosurgery and Cryotherapy.



Jennifer Schulmeier MD is Clinician Educator at the University of Mississippi Medical Center in Jackson, Mississippi, USA. She is board certified in pathology and dermatopathology and has an interest in clinical-pathologic correlation in dermatology and techniques to provide optimal sampling for dermatopathology diagnosis.



Available at all medical bookstores or buy online at www.jaypeebrothers.com

JAYPEE

JAYPEE BROTHERS Medical Publishers (P) Ltd.

www.jaypeebrothers.com

Join us on facebook.com/JaypeeMedicalPublishers

Shelving Recommendation
DERMATOLOGY

ISBN 978-93-86107-04-6

9 789386 107046