& gynecology books, visit our website **www.jaypeebrothers.com,** for detailed information on obstetrics & gynecology books

2nd Edition

Practical Manual of
GYNECOLOGY

GYNECOLOGY



Amitava Pal
Rupali Modak

JAYPEE

Contents

1. Gynecological Specimens **1**

- *Fibroid Uterus 1*
- *Cervical Fibroid Polyp 5*
- *Uterine Polyp 7*
- *Cervical Fibroid 8*
- *Adenomyosis 9*
- *Bicornuate Uterus 11*
- *Dermoid Ovary 12*
- *Specimen of Cysts in Ovary 14*
- *Pseudomucinous Cystadenoma of Ovary 16*
- *Cancer Cervix 19*
- *Endometrial Cancer 24*
- *Specimen of Choriocarcinoma 33*
- *Ovarian Carcinoma 37*
- *Krukenberg Tumor 41*
- *Malignant Germ Cell Tumor 42*
- *Specimen of Radical Vulvectomy 44*
- *Specimen of Uterine Prolapse 49*
- *Specimen of Hydrosalpinx 52*

2. Instruments **55**

- *Female Metal Catheter 55*
- *Speculum 57*
- *Ferguson's Speculum 58*
- *Auvard's Self-retaining Weighted Vaginal Speculum 59*
- *Landon's Vaginal Retractor 59*
- *Mayo's Scissors 60*
- *Bent on Flat Scissors 60*
- *Dissecting Forceps and Plain Forceps 61*
- *Scalpel 61*
- *Needle Holder 61*
- *Suture Needles 62*
- *Towel Clip 63*
- *Morris Retractor (Small) 63*
- *Morris' Retractor (Large) 64*
- *Gosset's Self-retaining Abdominal Retractor 64*
- *Balfour's Self-retaining Retractors 65*
- *Bonney's Myomectomy Clamp 65*
- *Myoma Screw 66*
- *Berkeley-Bonney Vaginal Clamp 67*
- *Straight Long Clamp Forceps 67*
- *Curve Long Clamp Forceps 68*
- *Maingot's Clamp 68*
- *Kocher's Clamp 69*
- *Round Ligament Forceps 69*
- *Leech Wilkinson's Cannula 70*

Prelims.indd 11 06-12-2016 17:40:26

- *Punch Biopsy Forceps 70*
- *Spatula 73*
- *Rubber Ring Pessary 74*
- *IUCD Removal Hook 76*
- *Novak's Endometrial Biopsy Curette 77*
- *Sharman's Uterine Biopsy Curette 77*
- *Hulka's Uterine Manipulator for Normal Sized Uterus 78*
- *Silastic Ring, Ring Applicator and Introducer 78*
- *Shirodkar's Forceps 79*
- *Sterilization of Instruments 80*
- *Suture Materials 80*
- *Instruments for Laparoscopy 83*
- *Instruments for Hysteroscopy 84*

3. Gynecological Operations 86

- *Hysterectomy 86*
- *Myomectomy 94*
- *Wertheim's Operation (Radical Hysterectomy with Pelvic Node Dissection) 99*
- *Strassman Utriculoplasty 103*
- *Jone's Utriculoplasty 105*
- *Tompkins Metroplasty 105*
- *Operation for Ectopic Pregnancy 106*
- *Tubal Microsurgery 107*
- *Surgical Treatment of Ovarian Tumors 111*
- *Dilatation and Curettage Operation 114*
- *Operation on Congenital Absence of Vagina 116*
- *Anterior Colporrhaphy (Repair of Cystocele) 118*
- *Posterior Colpoperineorrhaphy 120*
- *Vaginal Repair of Enterocele 121*
- *Manchester (Fothergill's) Operation 122*
- *Vaginal Hysterectomy with Pelvic Floor Repair 123*
- *Operation on Vault Prolapse (Post-hysterectomy) 125*
- *Surgical Treatment of Stress Incontinence (Marshall-Marchetti-Krantz Operation) 129*
- *Burch's Colposuspension 130*
- *Newer Technique (Transobturator Approach) 131*
- *Conservative Simple Vulvectomy 134*
- *Radical Vulvectomy 135*
- *Laparoscope 136*
- *Hysteroscope 144*

4. Contraception 149

- *Combined Oral Contraceptive Pill 149*
- *Progesterone Only Pill 155*
- *Emergency Contraception 156*
- *Injectable Progesterone Contraception 159*
- *Vaginal Ring (NuvaRing) 161*
- *Intrauterine Contraceptive Device 162*
- *Mirena (LNG-IUS) 168*
- *Barrier Contraception (Condom) 170*
- *Female Condom 172*

- *Vaginal Diaphragm 173*
- *Cervical Cap 174*
- *Vaginal Spermicides 174*
- *Newer Formulation 175*
- *Female Sterilization-Tubectomy (Permanent Method of Contraception) 177*
- *Essure Device and Adiana 180*
- *Implants 181*

5. X-rays in Gynecology 185
- *Skiagram of Normal Hysterosalpingography 185*
- *Skiagram of HSG with Isthmic Block 188*
- *Skiagram of HSG with Cornual Block 189*
- *Skiagram of HSG with Bilateral Hydrosalpinx 191*
- *Unicornuate Uterus 194*
- *Bicornuate and Septate Uterus 195*
- *X-ray of Abdomen and Pelvis to Locate the IUCD 200*

6. Ultrasonography and Other Imaging in Gynecology 204
- *Ultrasonography in Gynecology 204*
- *Cervical Fibroid 206*
- *Adenomyosis 206*
- *Endometriosis 207*
- *Polycystic Ovarian Syndrome 208*
- *Chronic/Ruptured Ectopic Pregnancy 210*
- *Uterine Anomaly 212*
- *Saline Sono-hysterography Or Saline Infusion Sonography 214*
- *CT and MRI in Gynecological Malignancies 222*

7. Gynecological Cases 226
- *History Taking 226*
- *Physical Examination 227*
- *Gynecological Examination 228*
- *Pelvic Examination 231*
- *Pelvic or Abdominopelvic Lump 235*
- *Ovarian Tumor (Benign) 237*
- *Ovarian Cancer 240*
- *Fibroid Uterus 249*
- *Genital Prolapse 259*
- *Genitourinary Fistula 270*
- *Old Complete Perineal Tear 277*
- *Rectovaginal Fistula 280*
- *Amenorrhea 282*
- *Secondary Amenorrhea 288*
- *Turner's Syndrome 292*
- *Mullerian Agenesis (Mayer-Rokitansky-Kuster-Hauser Syndrome) 294*
- *Testicular Feminization Syndrome 296*
- *Imperforate Hymen 297*
- *Transverse Septum of Vagina 299*
- *Hyperprolactinemia 300*
- *Premature Ovarian Failure 306*
- *Polycystic Ovarian Syndrome 309*
- *Hirsutism 319*

Prelims.indd 13 06-12-2016 17:40:27

- *Abnormal Uterine Bleeding 324*
- *Post-menopausal Bleeding 335*
- *Cancer Cervix 337*
- *Questions on Early Cancer Cervix 345*
- *Colposcope 349*
- *HPV Vaccine 350*
- *Infertility 352*
- *Luteal Phase Defect 358*
- *Clomiphene Citrate 360*
- *Aromatase Inhibitors (Letrozole) 361*
- *Gonadotropins 362*
- *Urinary Incontinence 370*
- *Swelling of Vulva 385*

8. Flying Questions Related to Long Cases 390

- *Adnexal Mass 390*
- *Endometriosis 393*
- *Menopause 401*
- *Vaginal Discharge, RTIs and STIs 408*
- *Chronic Pelvic Pain 414*
- *Dysmenorrhea 419*
- *Premenstrual Syndrome 421*
- *Genital Tuberculosis 424*
- *Acute Pelvic Inflammatory Disease 432*
- *Vulvodynia 436*
- *Assisted Reproductive Technology 439*
- *IVF (Most Common ART) 441*

Appendices 451

Appendix 1: Proforma for Examination of Victim of Sexual Offences 451

Appendix 2: Tanner Staging of Breast Development and Pubic Hair 455

Appendix 3: Anatomy of Genitourinary System, Embryology, Reproductive Physiology in Gynecology and Micturition 456

Index 467

3
CHAPTER

Gynecological Operations

HYSTERECTOMY

Q. 1. What is hysterectomy?
Ans. Operative removal of uterus.

Q. 2. What are the different types of hysterectomy?
Ans.
a. Abdominal – Total
– Subtotal
b. Vaginal
c. Laparoscopic-assisted vaginal hysterectomy (LAVH) and Total laparoscopic hysterectomy (TLH).

Q. 3. What is total hysterectomy?
Ans. Removal of uterus and cervix.

Q. 4. What is total hysterectomy and bilateral salpingo-oophorectomy?
Ans. Body of uterus, cervix, fallopian tubes and ovaries removed.

Q. 5. What is subtotal hysterectomy?
Ans. The body of the uterus is removed leaving the cervix in place.

Q. 6. What is radical hysterectomy?
Ans. Total hysterectomy with bilateral salpingo-oophorectomy with removal of parametrium, upper half of vagina and pelvic lymph glands like common iliac, internal iliac, external iliac and obturator commonly).

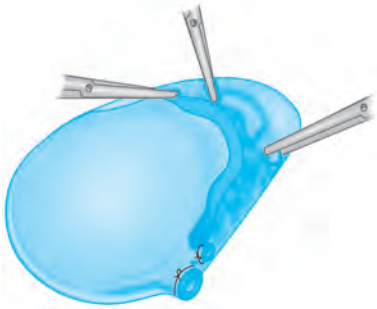

Fig. 3.1: Subtotal hysterectomy—removal of body of uterus but cervix is conserved in body

JAYPEE BROTHERS

Q. 7. What are the indications of subtotal hysterectomy?

Ans. A. Obstetric indications
- a. Rupture of uterus
- b. In severe PPH where all measures fail and adherent placenta with uterus

B. Gynecological indications
- a. Total hysterectomy is difficult
  - i. Endometriosis
  - ii. Extensive PID
  - iii. Ovarian malignancy.

Q. 8. What is the disadvantage of subtotal hysterectomy?

Ans. Chances of cervical carcinoma is high (1–2%). If it is kept, the woman must continue to have cervical smear tests afterwards.

Q. 9. What are the common indications of TAH (Total abdominal hysterectomy)?

Ans. Gynecological indications:

A. Benign: Fibroid uterus, adenomyosis, endometriosis, DUB, PID and bilateral T-O mass

B. Malignant: Postmenopausal bleeding—endometrial carcinoma, choriocarcinoma, CIN, ovarian carcinoma, tubal carcinoma.

Q. 10. What are the steps of abdominal hysterectomy?

Ans. Written consent of operation followed by the steps:

1. Position of the patient—Supine.
2. IV drip with ringer lactate.
3. Anesthesia - GA/spinal/epidural.
4. Bladder is evacuated and catheter is kept in situ throughout the operation.
5. Antiseptic dressing and draping.
6. Abdomen is opened by infraumbilical right/left paramedian or midline incision or pfannenstiel incision.
7. Skin, subcutaneous tissue, anterior layer of rectus sheath are incised and rectus muscles are splitted and retracted laterally by separating it from rectus sheath.

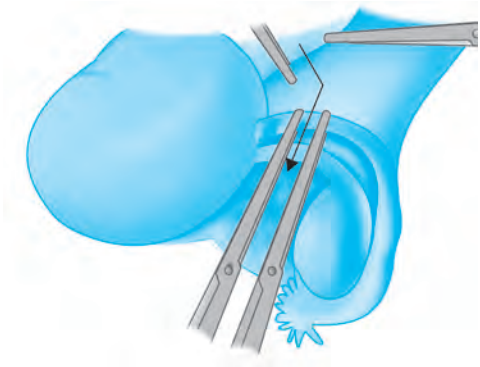

Fig. 3.2: The ovarian ligament, fallopian tubes, and round ligament are divided

JAYPEE BROTHERS

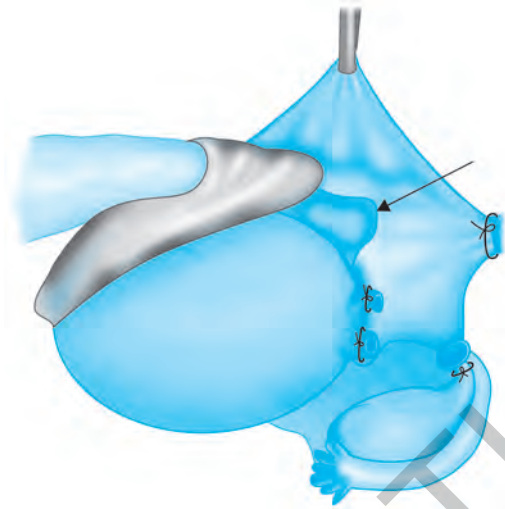

Fig. 3.3: Vesicouterine peritoneum is opened and bladder being dissected off cervix

8. The peritoneum is cut opened and Devar's retractor is introduced.
9. The uterine fundus is pulled by vulsellum and intestines are packed and patient is kept in Trendelenberg position.
10. **First pair of clamps:** Include the round ligament, cut and transfixed on both sides.
11. **Second pair of clamps:** The clamps are placed on the infundibulo-pelvic ligaments if salpingo-oophorectomy is planned (>45 years) and if ovary is preserved then place the two clamps side-by-side on the fallopian tubes, ovarian ligament, mesosalpinx near the cornu and the structures are divided in between the clamps and the lateral clamps are replaced by transfixation sutures. This procedure is done on the other side.
12. The bladder peritoneum is divided from one cut end of the round ligament to the other and the bladder is pushed down by sponge swab taken on a sponge forceps.
13. **Third pair of clamps** is placed on the uterine vessels close to the uterus (ureter lies 1.5 cm lateral to the uterus at this level), it is cut and sutured.
14. **Fourth pair of clamp** is straight and it is placed on the uterosacral ligament, on both sides by pulling the uterus forwards and the ligaments are divided between the clamps and cervix. The clamps are replaced by sutures.
15. Pull the uterus vertically and **fifth pair of clamps** are curved and put on the paracervical tissues and angle of the vagina and divide the tissues in between the clamp and cervix.
16. The uterus is out and the clamps are replaced by sutures.
17. The anterior and posterior vaginal wall is hold by Allis' forceps and closed by sutures from one vaginal angle to the other (but some prefer to keep open the vaginal vault and undermine the vaginal margins).

JAYPEE BROTHERS

18. Round ligaments and uterosacral ligaments of one side are tied with the lateral angle of the vagina of same side. This elevation is done to prevent the vault prolapse.

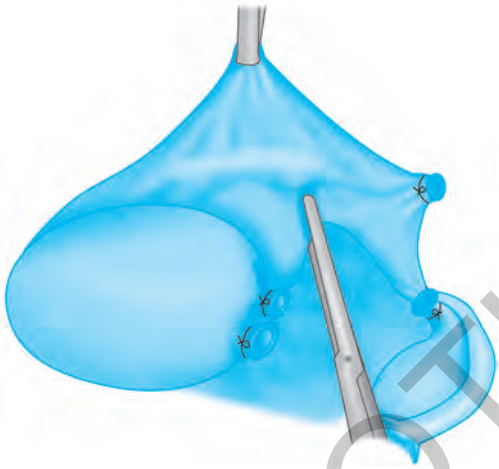

Fig. 3.4: Parametrium containing the uterine artery is clamped and divided

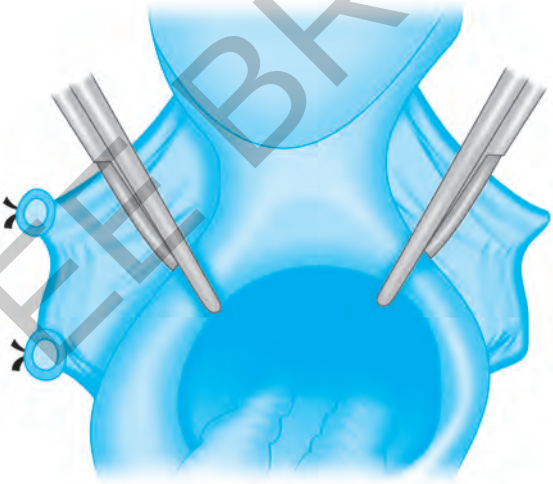

Fig. 3.5: The uterosacral ligaments are clamped and divided

19. Proper hemostasis is needed before closing abdomen, abdominal packs are removed and abdomen is closed in layers.
20. Vaginal toileting done and catheter is taken out to see the color of urine.

Q. 11. What is the advantage of keeping vault open?

Ans. When the vaginal vault is opened the internal bleeding if occurs after operation is easy to diagnose and the incidence of cuff cellulitis, abscess and hematoma formation is reduced.

JAYPEE BROTHERS

Q. 12. What are the indications of conservation of ovary during hysterectomy?

Ans. If the ovary is healthy and patient's age is less than or equal to 45 years.

Q. 13. What are the advantages and disadvantages of bilateral oophorectomy?

Ans. A. *Advantages:*

a. Reduces the risk of ovarian cancer and incidence of residual ovary syndrome.
b. Effective treatment for PMS (Premenstrual tension syndrome) and endometriosis.
c. May improve efficacy of treatment if pelvic pain is included in the symptoms.

B. *Disadvantages:*

Premature menopause due to estrogen withdrawal and mortality/morbidity rises due to two-fold increase in CHD (coronary heart disease) incidence and also due to osteoporotic fracture.

Q. 14. When do you go for TAH +BSO or when to offer bilateral oophorectomy with abdominal hysterectomy?

Ans. 1. Therapeutic—(a) Endometrial malignancy, (b) Ovarian malignancy, (c) Invasive cancer disease in late age, (d) When ovaries are severely involved by tumor cyst, infection, adhesion or endometriosis or when blood supply is compromised.

2. Prophylactic—Early bilateral salpingo-oophorectomy (usually after 35 years at the completion of child bearing age and certainly by age of 40 years) is generally performed for those who have genetic high risk of breast and ovarian cancer (presence of BRCA1 or BRCA2 gene) or strong family history of breast and ovarian carcinoma and estrogen receptor positive (ER+) breast cancer. So, RRSO (risk reducing salpingo-oophorectomy) reduces the risk of ovarian cancer and primary ovarian cancer if surgery is done in premenopausal period.

NB. *In bilateral oophorectomy the use of HRT is needed (see menopause) if BSO is done in women under the age of 45 years.*

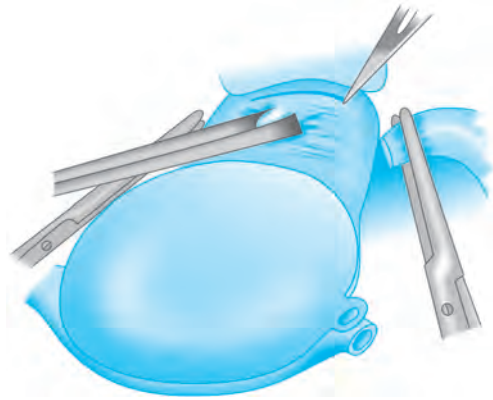

Fig. 3.6: The top of the vagina is now clear of bladder and uterus can be opened to allow excision of uterus and cervix

JAYPEE BROTHERS

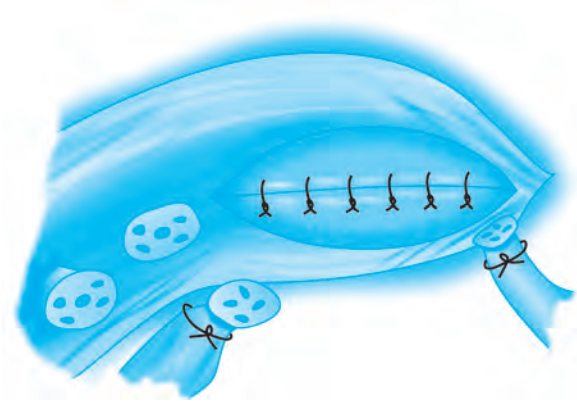

Fig. 3.7: Closure of the vault

Q. 15. What happens to the ovary if ovary is preserved during hysterectomy?

Ans. The incidence of ovarian failure varies between 25–57% after hysterectomy and can develop at any time but usually 2–5 years after surgery. The compromised ovarian vascular supply resulting from surgery is the most likely mechanism.

Q. 16. Why many surgeons prefer to conserve ovary less than or equal to 45 years during hysterectomy operation nowadays?

Ans. Those who carry out castration opine that the conserved ovaries do not function, increases the chances of ovarian cancer and residual ovary syndrome (pain). However none of the arguments are evidence based. The incidence of ovarian cancer in the life time is less than 1.8% and women under the age of 55 years fall in the low risk groups. Careful screening helps in early detection of ovarian cancer. Improved surgical skill can reduce the residual ovarian syndrome. On the other hand mortality rate is increased due to high rise in CHD (incidence 2 fold raised) and morbidity increases due to osteoporotic fracture. So ovarian resection should be discouraged unless it is indicated (as mentioned above). The risk increases if BSO is performed at earlier age.

NB. *Surgical castration may also decrease the libido of women. The majority of OCs (ovarian carcinomas) originates in the fallopian tube and this should be removed at the time of hysterectomy irrespective of ovarian conservation.*

Q. 17. What are the complications of hysterectomy operation?

Ans. During operation:

a. Operative injury of intestine, bladder omentum, ureter, rectum
b. Anesthetic complications
c. Hemorrhage and shock

JAYPEE BROTHERS

After operation:

a. Reactionary hemorrhage and shock
b. Abdominal distension—due to acute dilatation of the stomach, paralytic ileus, peritonitis
c. Pulmonary complications
d. Deep vein thrombosis
e. Genitourinary fistula
f. Rectus sheath hematoma.

Late complications: Secondary hemorrhage, vault prolapse, incisional hernia, vault granuloma, postmenopausal syndrome (due to surgical castration), psychiatric problem, vaginal cuff dehiscence (2 months after surgery) due to coitus.

NB. *Reactionary hemorrhage occurs within 24 hours of operation due to slipping of ligatures; Secondary hemorrhage starts following 7–10 days of operation if infection occurs.*

Q. 18. What are the sites of ureteric injury during TAH?

Ans. (a) Infundibulopelvic ligament, (b) uterine artery site, (c) at the base of the bladder when bladder is not adequately pushed down, (d) during clamping of uterosacral ligament.

Types of injury—Crushing or incision of the ureter.

NB. *Anatomical relation of uterine artery and ureter at the level of internal os – Uterine artery crosses the ureter (artery is above the ureter) at 1.5 cm of internal os.*

Q. 19. How do you prevent ureteric injury at infudibulopelvic ligament?

Ans. Open the lateral peritoneum by dividing round ligament, identify the ureter on medial flap of peritoneum and clamp the infundibulopelvic ligament safely.

The distance between this ligament clamp and ureter may be 1 cm or less. Generally in practice after cutting round ligament a window is made on posterior wall of peritoneum and clamp is placed on infundibulopelvic ligament just below and close to ovary for prevention of ureteric injury

Q. 20. How do you prevent ureteric injury during clamping of uterine artery?

Ans. (a) Wide mobilization and displacement of bladder base, from the cervix, (b) Traction on the uterine corpus, (c) The uterine vessels are completely skeletonized, and the lowest clamp is placed first at the level of internal os and at right angle to the uterine isthmus, (d) Avoidance of blind clamping.

For Postgraduates

Q. 21. What is the management of ureteric injury?

Ans. Injuries recognized at operation

a. High up ureteric injury (End-to-end anastomosis). The circumferences of fresh cut ends of the ureter is increased by

JAYPEE BROTHERS

1 cm vertical incision and are joined by fine chromic catgut or polyglycolic acid 3/0 or 4/0 sutures over a ureteric splint or stent. The upper end of the stent is kept in the renal pelvis and lower end into the bladder. A suction drain is kept near the anastomotic site and removed after 4/5 days. The ureteric splint is removed after 4 weeks under cystoscopic guidance.

b. Injury to the distal ureter—Reimplant the ureter in the bladder (if injury is within 5 cm of uretero-vesical junction) with a reflux preventing procedure on to the lateral and posterior wall. This involves creating a tunnel between the muscular layer and the mucosa of the bladder. The length of the tunnel is approximately 3 times the diameter of the ureter. If there is any tension, the bladder should be mobilized by separating it from the symphysis pubis and mobilized towards the ureter by psoas hitch or developing a 'Boari-Ockerblad flap'.

Injuries recognized at postoperative period: The *signs and symptoms* are non-specific and consist of fever, ileus, flank or abdominal pain, persistent hematuria, or appearance of mass that is usually suspected by surgeon as hematoma but actually it is urinoma which needs biochemical analysis.

Diagnosis:

i. Abdominal USG or CT scanning to locate hydroureter and hydronephrosis.
ii. If there is obstruction at the site of ureteric injury IVP urogram shows some dilatation of ureter and calyces on the affected side. If there is no obstruction above the fistula the ureter and kidney may look normal.
iii. Cystoscopic observation: Presence of efflux from the ureteric orifice of the intact side and absence of efflux on the injured side.
iv. On ureteric catheterization by cystoscopic guidance it is found that failure to pass the catheter up the ureter due to arrest at the site of injury.
v. Nephrostogram or retrograde ureterogram should be done.
vi. Double dye test—Methylene blue is introduced into the bladder and phenazopyridine hydrochloride (pyridium) is injected intravenously. An orange stained swab in the vagina confirms the fistula is uretero-vaginal, while a blue stained swab confirms VVF.

Treatment:

a. Small fistula diagnosed very early may allow a ureteric drainage with a 'Double J stent' to heal.
b. If the ureter is completely obstructed percutaneous drainage of the renal pelvis as an interim measure.
c. Repair of the damage to the ureter can be carried out once the patient has returned to biochemical and hematological normality. Reconstruction and reimplantation with or without Boari's flap by extraperitoneal approach.

JAYPEE BROTHERS

Q. 22. What is LAVH? What are the indications of LAVH?

Ans. In laparoscopic assisted vaginal hysterectomy (LAVH) the pedicles (a) Round ligament, (b) Infundibulopelvic ligaments are desiccated by bipolar forceps and transacted abdominally if ovaries are removed and Fallopian tubes, ovarian ligament and mesosalpinx if ovaries are preserved, but not ligation of the uterine vessels. The uterosacral ligaments and the uterine arteries are cut from below by opening the anterior and posterior pouch and the uterus is removed vaginally and vaginal vault is closed per vagina. Advantage – Short hospital stay.

Indications: Prior pelvic surgery, PID, endometriosis, limited uterine mobility pelvic mass, narrow pubic area, constricted vagina with no prolapse.

Q. 23. What is TLH?

Ans. It is a laparoscopic guided hysterectomy where all the pedicles are desiccated by bipolar forceps and transacted abdominally and uterus is removed through the vagina. The vaginal cuff is sutured and closed laparoscopically by incorporating the uterosacral ligament for pelvic support by ligature guide or laparoscopically placed suspension suture. It has no vaginal component.

Advantage – Better visualization, small incision (only ports), risk of hernia is less, short hospital stay and recovery is good.

Complications: Infection, hemorrhage, ureter, bladder and bowel injury.

Long-term complications: Bowel obstruction from adhesions, pelvic pain.

Q. 24. What are the discharge instructions after hysterectomy?

Ans.
a. Avoid strenuous activity.
b. Avoid heavy weight lifting, sexual activity, douching in first 3 months.
c. Bathing in pond should be prohibited.
d. Maintain regular diet.
e. Avoid constipation.
f. Consult with doctor if for heavy bleeding and fever.
g. To come after 4 weeks for check up.

MYOMECTOMY

Q. 1. What are the indications of myomectomy?

Ans.
1. Young healthy woman who desires of menstruation and reproductive function.
2. Symptomatic myoma: Menorrhagia, metrorrhagia, infertility, and repeated abortion when other causes of infertility have been ruled out.
3. Symptom free myoma but if a. size is >12 weeks of pregnant uterus, b. Subserus myoma with a long pedicle and c. myoma when rapidly grows.

JAYPEE BROTHERS

Q. 2. What are the contraindications of myomectomy operation?

Ans. (a) Patient's age is > 40 years, (b) Diffuse adenomyosis, (c) Malignancy of any type in the uterus or the ovaries, (d) Sarcomatous change of myoma, (e) If the tubes are closed and if they have been removed previously, (f) Endometrial or pelvic tuberculosis or bilateral severe ovarian endometriosis, (g) Pregnancy, (h) Situations where removal of myoma results in significant reduction of the endometrial surface causing the uterus not to be functioned.

Q. 3. What are the prerequisites of myomectomy operation?

Ans.

1. Minimum 2 bottles of compatible blood are to be arranged.
2. Prior consent for hysterectomy operation along with consent for myomectomy.
3. Cervical cytology – Normal.
4. Exclusion of endometrial carcinoma and submucous polyp.
5. Counseling of the fact that menorrhagia may persist even after removal of myoma or it may recur in certain percentage of cases.

Q. 4. How do you minimize the blood loss during myomectomy operation?

Ans. a. Compression of uterine and ovarian blood vessels to make the myoma avascular, b. The capsule of myoma should be incised vertically, c. Enucleation of the myoma should be in proper plane, d. Repair of feeder blood vessels should be ligated and the myoma bed should be sutured meticulously, e. Ligation of uterine arteries, f. Limiting the number of uterine incision.

NB. *In laparoscopic or conventional myomectomy following laparotomy vasopressin can be used intramurally as well as perivascularly. Diluted vasopressin (1 ml of 20 U vasopressin with 19 ml of normal saline) is injected perivascularly into the broad ligament at the junction of the anastomosis of ovarian and uterine blood supply. This is done under direct vision to avoid intravascular injection of the solution. Some solution is also injected beneath the peritoneum along the line of proposed incision lines. This results in an immediate blanching of the uterus, with no effect on ovaries and fallopian tubes. Vasopressin is an antidiuretic hormone causing constriction of smooth muscles in the wall of capillaries, small arterioles, and venules. Synthetic vasopressin causes mechanical occlusion of uterine and ovarian vessels. It may rarely cause bradycardia or cardiovascular collapse.*

Q. 5. What are the steps of myomectomy operation?

Ans.

a. Steps from 1–8 as in abdominal hysterectomy.
b. The uterus is delivered through the abdominal opening and see the size, numbers and location of myoma.
c. Rubber guarded sponge holding forceps are applied to the infundibulopelvic ligaments.

JAYPEE BROTHERS

d. Bonney's clamp or a rubber catheter is passed through the holes made in the broad ligament and is kept as a tourniquet around the isthmus. Procedure of (c) and (d) produce less vascular field.

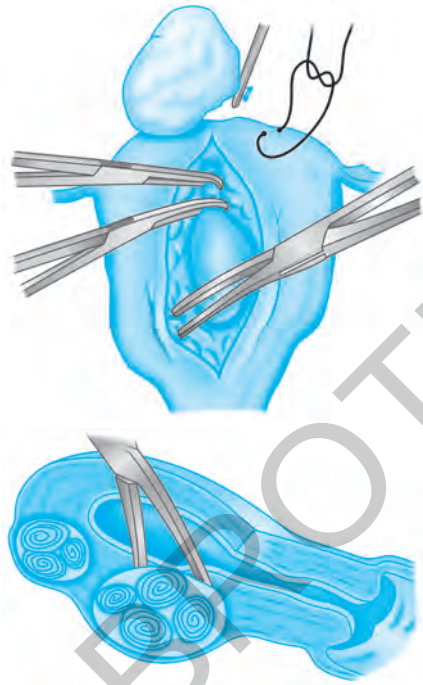

Fig. 3.8: Removal of subserous, intramural, submucous and posterior fibroid through a single anterior incision

1. *For anterior myoma:* For a big fibroid uterus it is fixed by myoma screw and taken out of the abdomen. The capsule is incised vertically in the midline to avoid blood loss and a cleavage is made between the tumor and capsule. The tumor is enucleated by fingers or by end of the scalpel blade from its bed by a strong traction of vulsellum or Allis' tissue forceps.If a large feeder vessel is found it is divided and ligated. Multiple fibroids are removed on the anterior wall by tunnelling procedure from the primary incision.
2. *For posterior myoma*
   i. No primary incision on the posterior wall due to fear of adhesion.
   ii. Transcavitary approach.
   iii. If it is too large, it is removed by transverse incision posterior to the line of attachment of fallopian tubes. The portion of the uterus which covers the myoma hangs down just like a hood of a monk.
   iv. Posterior low subserous myoma requires primary incision from posterior aspect for its removal.

JAYPEE BROTHERS

e. If the clamp articulated for hemostasis exceeds 20 minutes before myomectomy it should be removed for 5 minutes and reapplied again and by that time the uterus is wrapped with hot mop.
f. Repair of bed:
   i. Bleeding from the feeder vessels should be ligated
   ii. Cavity is to be occluded by deep interrupted tire stitches
   iii. Redundant portion of the uterine wall is removed
   iv. The serosa is repaired with 2-0 polyglycolic acid suture material
   v. If uterine cavity is opened a careful approximation of muscle layer by excluding uterine endometrium
   vi. Bonney's hood repair is done as shown in the Figure 3.9A to C. A-A, B-B, C-C, D-D, resulting the hood being drawn over the original incision onto the anterior surface of the uterus.
g. Hemostasis is confirmed after removal of the hemostatic appliances.
h. Additional sutures may be required.

Q. 6. What is the postoperative management and advice?

Ans.
1. Watch for pallor/P/R/T/BP and P/V bleeding.
2. Some vaginal bleeding is expected when cavity is opened.
3. Pregnancy is to be avoided for 3 months after operation by OCP or barrier methods of contraception.
4. All future pregnancies are treated by elective LSCS if cavity is opened.

Q. 7. What are the complications of the operation?

Ans.
1. Perioperative hemorrhage—Sometimes, it is so severe that it may end in hysterectomy.

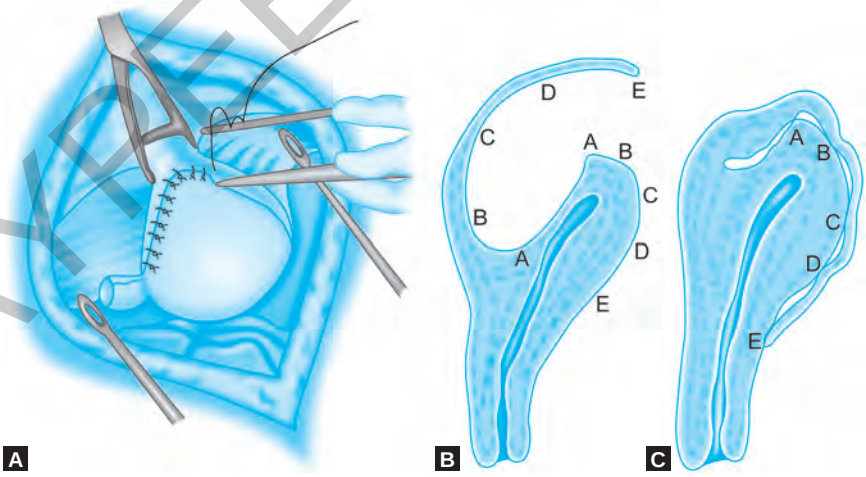

Figs 3.9A to C: (A) Closure of the myomectomy wound through transverse incision using Bonney's hood operation showing anterior suture line, (B and C) showing Bonney's hood after enucleation of myoma

JAYPEE BROTHERS

for detailed information on obstetrics & gynecology books, visit our website **www.jaypeebrothers.com,** for detailed infor

Practical Manual of
GYNECOLOGY

Salient Features

- An easy-to-use resource in handbook form
- Deals mainly with the practical aspects of gynecology
- Documents the practical section, including pathological specimens, gynecological instruments used daily, contraception, ultrasonogram and radiography
- Presents quite comprehensively the case discussions and the oral questions
- Discusses in detail with diagrams, the operations, which are asked commonly in examinations
- Helpful for the students who appear in the oral and practical examinations of MBBS, DGO, DNB, MS equivalents of any university as well as for the nursing papers.

Amitava Pal MBBS (Hons) DGO MS DNB FICMCH is a Professor, Department of Obstetrics and Gynecology, Burdwan Medical College, Burdwan, West Bengal, India. He has an excellent teaching experience in obstetrics and gynecology. He is a good academician and clinician too. He is also paper setter and examiner of different universities. He has a lot of publications in many national and international journals. He is the author of the books *Practical Manual of Obstetrics* and *Manual of Standard Drugs and Evidence-based Approach to Obstetrics and Gynecology*.



Rupali Modak MBBS (Hons) MD (Gold Medalist) is an Assistant Professor, Department of Obstetrics and Gynecology, RG Kar Medical College, Kolkata, West Bengal, India. She is an excellent teacher, good academician and has excellent expertise in dealing with the clinical cases in the field of obstetrics and gynecology. She is the co-author of the books *Practical Manual of Obstetrics* and *Manual of Standard Drugs and Evidence-based Approach to Obstetrics and Gynecology*. She has a lot of publications in many national and international journals.



Available at all medical bookstores
or buy online at www.jaypeebrothers.com

JAYPEE BROTHERS
Medical Publishers (P) Ltd.
www.jaypeebrothers.com

Join us on facebook.com/JaypeeMedicalPublishers

Shelving Recommendation
GYNECOLOGY

ISBN 978-93-86150-93-6