, visit our website **www.jaypeebrothers.com,** for detailed information on obstetrics & gynecology books, visit our website **www.jaypeebrothers.com**

Essentials of Gynecologic Pathology

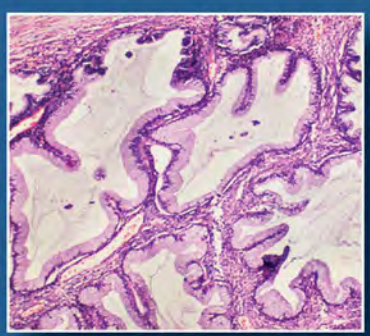
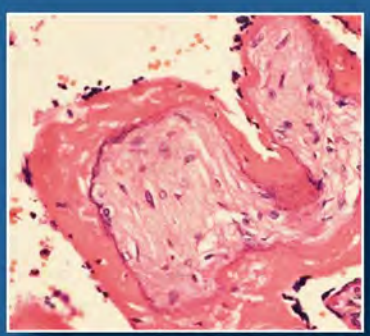
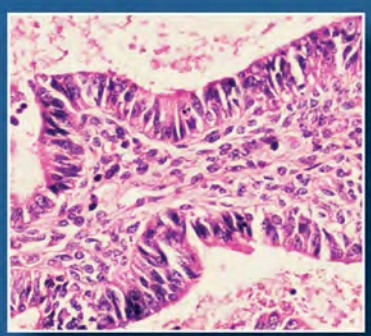

Pranab Dey

JAYPEE

Contents

Chapter 1: Embryology and Developmental Defects in Female Genital Tract 1–7
- Gonadal Development 1
- Primordial Germ Cells 2
- Reproductive Tract Development 3
- Molecular Genetics in the Development of the Gonads and Reproductive Tract 4
- External Genitalia Development 4
- Disorders of Gonadal and Genital Tract Development 4

Chapter 2: Inflammatory and Benign Neoplastic Lesions of Vulva 8–23
- Anatomy 8
- Infectious Diseases of Vulva 8
- Non-infectious Inflammatory Diseases of Vulva 12
- Bullous Lesions of Vulva 16
- Vulvodynia 17
- Benign Diseases of Vulva 17
- Miscellaneous Conditions of Vulva 22

Chapter 3: Premalignant and Malignant Tumors of Vulva 24–36
- World Health Organization Classification of Tumors of Vulva 2014 24
- Squamous Tumors 24
- Squamous Cell Carcinoma of Vulva 27
- Paget Disease of Vulva 31
- Malignant Melanoma of Vulva 33
- Other Uncommon Malignant Tumors of Vulva 34

Chapter 4: Benign and Malignant Diseases of Vagina 37–49
- WHO Classification of Tumors of Vagina (2014) 37
- Developmental Disorders of Vagina 37
- Infectious Inflammatory Disorders 38
- Noninfectious Inflammatory Diseases of Vagina 40
- Traumatic, Surgery and Radiation-induced Lesions 40
- Postoperative Spindle Cell Nodule 41
- Vaginal Cysts 41
- Müllerian Cyst 41
- Vaginal Adenosis 42
- Vaginal Intraepithelial Neoplasia 43
- Neoplasms of Vagina 44

Chapter 5: Benign Diseases of Cervix 50–60
- Anatomy 50
- Histology 50
- Squamous Epithelium 50
- Columnar Epithelium 51
- Stroma 51

- Squamocolumnar Junction and Transformation Zone 51
- Changes in Normal Menstrual Cycle 53
- Pregnancy-induced Changes 53
- Arias-Stella Reaction 53
- Squamous Metaplasia 53
- Immature Squamous Metaplasia 54
- Tubal Metaplasia 54
- Transitional Cell Metaplasia 54
- Inflammation of Cervix 55
- Hyperplasia of Cervix 56
- Deep Endocervical Glands and Cysts 59
- Endocervical Polyp 59
- Cervical Cysts 59
- Tunnel Clusters 59

Chapter 6: Preneoplastic and Neoplastic Lesions of Cervix **61–77**
- WHO Classification of Tumors of the Uterus Cervix 61
- The Human Papilloma Virus 62
- Terminology of Preneoplastic Lesions of Cervix 64
- Cervical Intraepithelial Neoplasm Grade 1 or Low Grade Squamous Intraepithelial Lesion 65
- High Grade Squamous Intraepithelial Lesions 66
- Squamous Cell Carcinoma 71
- Variants of Squamous Cell Carcinoma 74

Chapter 7: Glandular and Miscellaneous Lesions of Cervix **78–95**
- Preneoplastic Lesion of Cervical Adenocarcinoma 78
- Early Invasive Adenocarcinoma (Microinvasive Adenocarcinoma) 80
- Adenocarcinoma 81
- Endometrioid Adenocarcinoma 84
- Clear Cell Carcinoma 85
- Serous Adenocarcinoma 85
- Mesonephric Carcinoma 85
- Adenosquamous Carcinoma 86
- Glassy Cell Carcinoma 86
- Adenoid Cystic Carcinoma (ADC) 87
- Adenoid Basal Cell Carcinoma (ABC) 88
- Neuroendocrine Carcinoma 88
- Small Cell Carcinoma of Cervix 88
- Carcinoid and Atypical Carcinoid of Cervix 89
- Large Cell Neuroendocrine Carcinoma 89
- Metastatic Carcinoma in Cervix 89
- Mesenchymal Tumors 90
- Lymphoma of Cervix 92
- Mixed Mesodermal Tumor 92
- Adenomyoma 94

Chapter 8: Endometrium: Benign Lesions **96–115**
- Anatomy and Histology of the Uterus 96
- Cyclic Endometrium 97
- Endometrial Dating and Biopsy 102
- Postmenopausal Endometrium 102
- Pregnancy-induced Changes 103
- Artifacts in Endometrium 104

- Dysfunctional Uterine Bleeding 105
- Hormone-induced Changes 107
- Endometritis 108
- Endometrial Polyp 109
- Adenomyomatous Polyp 110
- Atypical Polypoid Adenomyoma (APAM) 110
- Endometrial Metaplastic and Reactive Changes 111
- Asherman's Syndrome 113
- Endometriosis 113

Chapter 9: Uterus: Preneoplastic Lesions and Carcinoma 116–139
- WHO Classification of the Tumors of the Uterine Corpus 116
- Endometrial Hyperplasia 117
- Endometrial Intraepithelial Neoplasia 119
- Endometrial Carcinoma 120
- Variants of Endometrioid Carcinoma 125
- Serous Carcinoma 129
- Clear Cell Adenocarcinoma 131
- Mixed Types of Carcinoma 133
- Squamous Cell Carcinoma 133
- Transitional Cell Carcinoma 133
- Small Cell Carcinoma 133
- Ovarian Carcinoma along with Uterine Carcinoma 133
- Tumors of the Epithelial and Mesenchymal Component (Mixed Müllerian Tumor) 135

Chapter 10: Mesenchymal Tumor of Uterus 140–156
- Endometrial Stromal Tumors 140
- Smooth Muscle Tumors 144
- Leiomyosarcoma 149
- Myxoid Variant 151
- Epithelioid Leiomyosarcomas 151
- Uterine Smooth Muscle Tumors of Uncertain Malignant Potential 152
- Perivascular Epithelioid Cell Tumors 153
- Adenomatoid Tumor 153
- Adenomyosis and Adenomyoma 154
- Uterine Tumors Resembling Ovarian Sex Cord-like Elements 155

Chapter 11: Anatomy, Histology and Non-neoplastic Lesions of Ovary 157–168
- Anatomy of the Ovary 157
- Histology 157
- Follicle and Derivatives 157
- Infections of Ovary 160
- Non-neoplastic Lesions of the Follicular and Stromal Elements 161
- Polycystic Ovarian Syndrome (PCOS) 163
- Stromal Hyperplasia and Stromal Hyperthecosis 165
- Hilus Cell Hyperplasia 165
- Massive Stromal Edema and Fibromatosis 165
- Pregnancy Luteoma 166
- Ovarian Decidua (Ectopic Decidua) 166
- Ovarian Torsion and Infarction 166
- Ovarian Failure 167
- Congenital Lesions of Ovary 167

Chapter 12: Ovarian Tumor: General Aspect **169–178**
- Classification of Ovarian Tumors 169
- Classification 171
- Clinical Features 171
- Etiology and Risk Factors 171
- Pathogenesis and Precursor Lesions of Ovarian Carcinoma with Molecular Pathology 171
- Diagnosis and Screening 175
- Staging 176
- Prognostic Factors 176
- Treatment 177

Chapter 13: Epithelial Carcinoma of Ovary **179–208**
- Serous Tumor 179
- Serous Carcinoma 184
- Mucinous Tumor of Ovary 186
- Endometrioid Carcinoma of Ovary 192
- Malignant Müllerian Mixed Tumor (Carcinosarcoma) 195
- Endometrioid Stromal Sarcoma 197
- Clear Cell Tumors of Ovary 198
- Transitional Cell Tumor 201
- Mixed Epithelial Tumor 204
- Squamous Cell Carcinoma 205
- Undifferentiated Carcinoma 205
- Neuroendocrine Carcinoma of the Ovary 205

Chapter 14: Sex Cord Tumors of Ovary **209–227**
- Granulosa Cell Tumor 209
- Sertoli–Leydig Cell Tumor 219
- Sertoli Cell Tumor 224
- Gynandroblastoma 225
- Sex Cord Tumor with Annular Tubules 225
- Steroid Cell Tumors 225

Chapter 15: Germ Cell Tumor of Ovary **228–244**
- Dysgerminoma 228
- Yolk Sac Tumors 230
- Embryonal Carcinoma 234
- Polyembryoma 235
- Choriocarcinoma 235
- Teratoma 236
- Mixed Malignant Germ Cell Tumors 243
- Gonadoblastoma 243

Chapter 16: Metastatic and Miscellaneous Tumors of Ovary **245–250**
- Metastatic Tumors of Ovary 245
- Miscellaneous Tumors of Ovary 248

Chapter 17: Fallopian Tube **251–261**
- Anatomy 251
- Histology 251
- Blood Supply and Lymphatics 252
- Non-neoplastic Lesions of Fallopian Tube 252
- Salpingitis Isthmica Nodosa 253
- Tubal Pregnancy 254

- Infections 254
- Torsion 256
- Tumors of the Fallopian Tube 256
- Cysts 259
- Female Adnexal Tumor of Probable Wolffian Origin 260

Chapter 18: Pathology of Placenta **262–277**
- Normal Development 262
- Microscopy 263
- Placenta Gross 264
- Indications of Placental Examination 264
- Abnormalities of the Shape of Placenta 264
- Abnormal Adherence of Placenta 265
- Multiple Gestations 266
- Placental Inflammation and Intrauterine Infections 268
- Circulatory Disorders of Placenta: Maternal Circulatory Disorder 271
- Chorangiosis 274
- Placenta in Maternal and Fetal Disorders 274
- Pathology of Membranes 275
- Non-trophoblastic Tumors 275
- Umbilical Cord Pathology 276

Chapter 19: Gestational Trophoblastic Disease **278–287**
- Hydatidiform Mole 278
- Invasive Hydatidiform Mole 280
- Choriocarcinoma 280
- Placental Site Trophoblastic Tumor 283
- Epithelioid Trophoblastic Tumor 285
- Exaggerated Placental Site Reaction 286
- Placental Site Nodule 286

Chapter 20: Gross Examination of the Samples and Synoptic Reporting Format **288-295**
- Essential Things Required before Grossing 288
- Grossing Room 288
- Individual Specimen 288
- Vulvectomy Specimen 292
- Salpingectomy Specimen 292
- Oophorectomy 293
- Examination of the Placenta 293
- Synoptic Reporting of Gynecological Lesions 294

Index *297*

Premalignant and Malignant Tumors of Vulva

3

WORLD HEALTH ORGANIZATION CLASSIFICATION OF TUMORS OF VULVA 2014[1]

Epithelial tumors

Squamous cell tumors and its precursors

- Squamous intraepithelial lesions
  - Low grade squamous intraepithelial lesion
  - High grade squamous intraepithelial lesions
  - Differentiated-type vulvar intraepithelial lesions
- Squamous cell carcinoma
  - Keratinizing
  - Non-keratinizing
  - Basaloid
  - Warty
  - Verrucous
- Basal cell carcinoma
- Benign squamous lesions
  - Condyloma accuminatum
  - Vestibular papilloma
  - Seborrheic keratosis
  - Keratoacanthoma
- Glandular tumors
  - Paget disease
  - Tumors arising from Bartholin and other specialized anogenital glands
    - Adenocarcinoma
    - Squamous cell carcinoma
    - Adenosquamous cell carcinoma
    - Adenoid cystic carcinoma
    - Transitional cell carcinoma
  - Adenocarcinoma of other types
  - Benign tumors and cysts
- Neuroendocrine tumors
  - High grade neuroendocrine carcinoma
  - Markel cell tumor

Neuroectodermal tumors

Soft tissue tumors:

- Benign tumors
  - Lipoma
  - Fibroepithelial stromal polyp
  - Superficial angiomyxoma
  - Superficial myofibroblastoma
  - Aggressive angiomyxoma
  - Leiomyoma
- Malignant tumors
  - Rhabdomyosarcoma
  - Leiomyosarcoma
  - Epithelioid sarcoma
  - Alveolar soft part sarcoma

Melanocytic tumors

- Melanocytic naevi
- Malignant melanoma
- Germ cell tumors
- Lymphoid and myeloid tumors
- Secondary tumors.

SQUAMOUS TUMORS

Condyloma Accuminata

Condyloma accuminata (CA), a preneoplastic condition, is related with HPV 6 and HPV 11.[2] CA is usually multifocal and affects vulva, perineal region, vagina and cervix. The lesion in the vulva appears as white maculopapular lesion, papillary or verrucous type. CA is associated with sexual promiscuity, immunosuppression and diabetes mellitus.

Histopathology (Figures 3.1 to 3.3)

The lesion shows multiple papillae like structures that are lined by squamous cells. The lining epithelium shows hyperkeratosis, acanthosis, and parakeratosis along with basal cell hyperplasia. The characteristic finding in CA is koilocytotic changes in the superficial epithelium. Koilocytosis is characterized by perinuclear halo with central pyknotic or enlarged nucleus. The superficial cells may show mild nuclear atypia and binucleation.

JAYPEE BROTHERS

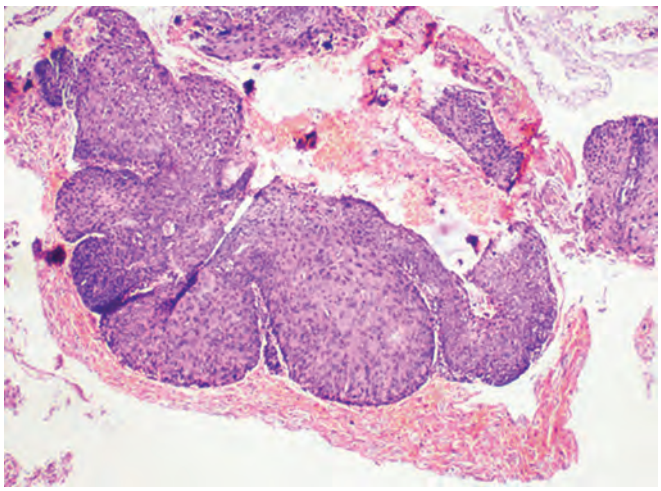

Figure 3.1: Condyloma: Papillary projections

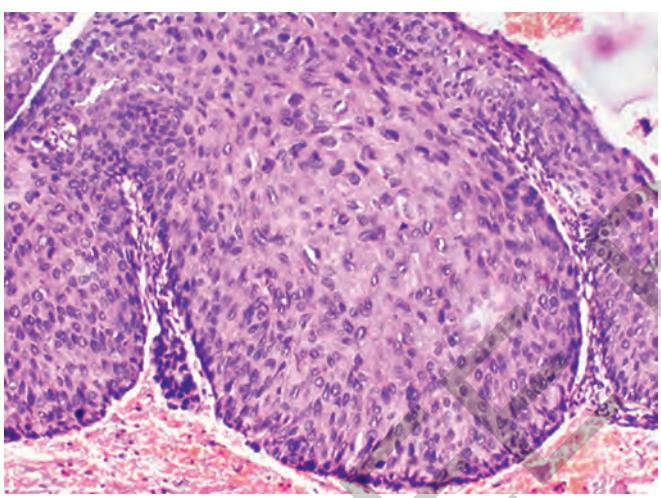

Figure 3.2: Condyloma: High power view showing papillary structure

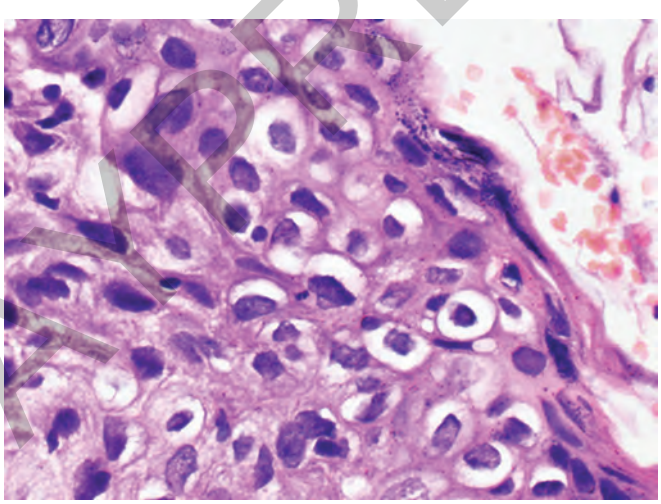

Figure 3.3: Condyloma: Koilocytic cells show central nucleus surrounded by clear halo

Differential Diagnosis

- *Vulval intraepithelial neoplasia (VIN)*: Condyloma accuminata is differentiated from VIN by the presence of parabasal hyperplasia, koilocytosis and absence of mitosis.
- *Fibroepithelial mucosal polyp*: Fibroepithelial mucosal polyp lack any koilocytotic change.

Natural History and Management

Majority of the CA regresses slowly and in a minority of cases the lesions persist. Occasional cases of CA may progress to VIN to squamous cell carcinoma.[3] Small lesions can be treated with topical application of Podophylin and the larger lesions are treated by surgical resection, laser ablation, electrocauterization, etc.[4]

Vulval Intraepithelial Neoplasia

The term vulval intraepithelial neoplasia (VIN) is often noted along with cervical intraepithelial neoplasia (CIN). Strong correlation is observed with cigarette smoking, immunosuppression, sexually transmitted disease and VIN.[5] HPV 16 is isolated in nearly 70% of VIN cases.[6]

Clinical Features

Vulval intraepithelial neoplasia is usually seen in older patient and the mean age is about 40 years. The patient complains of pruritus and irritation. However, most of them are asymptomatic. The lesions are usually multifocal (2/3rd) and commonly appear as white or pigmented maculopapular raised lesion in the labia minora and perineum.

Terminology

In 2014, World Health Organization (WHO) classified vulval precursor lesion in three categories LSIL, HSIL, and differentiated type vulvar intraepithelial lesion (Table 3.1).[1] ISSVD, in 2004, classified VIN as usual VIN (u-VIN) and differentiated VIN (d-VIN) (Table 3.2).[7] u-VIN is also known as classic VIN. It includes both VIN-2 and VIN-3 (high grade lesions). These lesions are more common, multifocal; HPV associated and occur in relatively younger patient than d-VIN group. The other group d-VIN is already considered as high grade lesion and is HPV-independent.

Histopathology: VIN shows nuclear enlargement, hyperchromasia, and pleomorphism of the epithelial cells (Figures 3.4 and 3.5). Nuclear chromatin is coarse. Mitotic activity is noted in all layers of epithelium. Abnormal mitotic figures are also seen.

Classic or Usual Type of VIN

There are two histological types of u-VIN:

1. Warty type and
2. Basaloid type.

JAYPEE BROTHERS

Table 3.1: WHO classification of vulval intraepithelial neoplasia

Low-grade squamous intraepithelial lesion	High-grade squamous intraepithelial lesion	Differentiated-type vulvar intraepithelial lesion
• It is a synonym of vulval intraepithelial neoplasia (VIN) grade 1 • It shows the features of productive HPV infection	It is a synonym of Vulval intraepithelial neoplasia (VIN) grade 2 and 3. The lesion involves lower third to full thickness of epithelium. It includes basaloid and warty type of lesion	• The lesion is HPV negative. • It shows atypia of the basal cells and abnormal differentiation of keratinocytes

Table 3.2: ISSVD terminology

VIN-1	VIN-2 and VIN-3	
This terminology is omitted • Flat condyloma accuminatum • Or HPV effect	**ISSVD Terminology**	
	Usual VIN (u-VIN)	**Differentiated VIN as (d-VIN)**
	• Includes both VIN-2 and VIN-3 • Warty, basaloid or mixed type • Multifocal • More common • Lower age group • HPV dependent	• High grade differentiated lesion • Unifocal • Less common • Post-menopausal • HPV independent

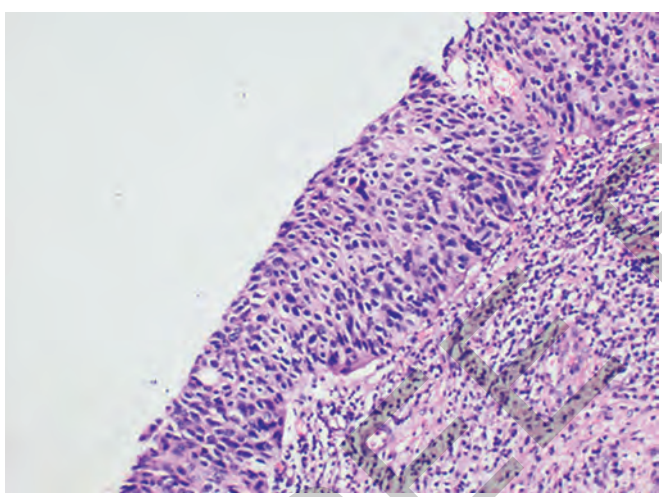

Figure 3.4: Vulval intraepithelial neoplasia 3: Full thickness involvement in usual type of VIN

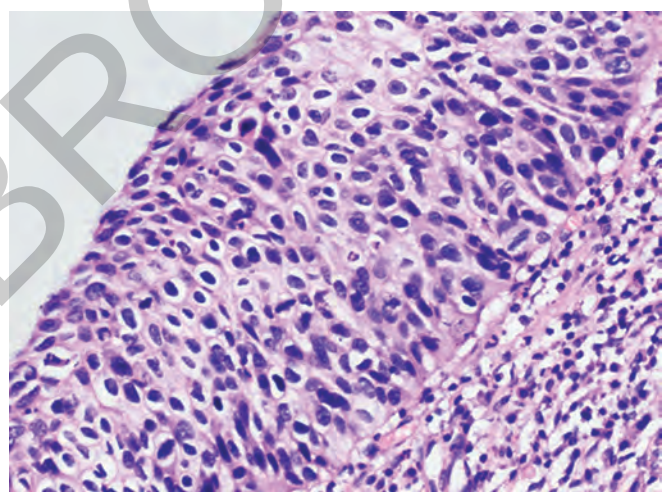

Figure 3.5: Vulval intraepithelial neoplasia 3: High powered view shows disoriented cells with enlarged pleomorphic nuclei

Warty type: In low power examination warty type of VIN gives a striking papillary appearance. The epithelium shows hyperkeratosis, parakeratosis along with prominent acanthosis. The rete ridges are wide and extend deep in the dermis. Individual cell keratinization is also noted. The epithelial cells show koilocytotic changes characterized by hyperchromatic nuclei and perinuclear halo.

Basaloid type: It presents as flat type of lesion. The epithelial cells are relatively small, uniform with high nucleo-cytoplasmic ratio and coarse chromatin. The cells resemble basal cells. Koilocytes are uncommon in this type of lesion.

Differentiated (Simplex) Type of VIN

Abnormalities of d-VIN are subtle and may be missed by routine pathological examination. d-VIN is characterized by epithelial thickening with elongated anastomosing rete pegs and parakeratosis.

The basal and parabasal cells show marked nuclear atypia. The nuclei are large, moderately pleomorphic having vesicular chromatin and prominent nucleoli. The upper part of the epithelium shows normal appearing differentiated cells. Dyskeratotic cells are seen in the whole thickness of the epithelium. These cells are parabasal cells with premature maturation characterized by increased eosinophilia of the cells. Mitotic activities are more frequent in the parabasal and basal cells.

Differential Diagnosis (Table 3.3)

- *Reactive nonspecific atypia*: P-16 immunostain is always negative in reactive atypia whereas VIN cases are positive for p-16.[8]

JAYPEE BROTHERS

Table 3.3: Differential diagnosis of vulval intraepithelial neoplasia

Lesions	Histopathology	Immunocytochemistry				
		CK7	CEA	CAM5.2	HMB 45	Melan A
VIN	Atypical epithelial cells	–	–	–	–	–
Paget's disease	Large cell with pale cytoplasm	+	+	+		
Melanoma	Melanin containing cells	–	–	–	+	+

Table 3.4: Ancillary studies in different types of vulval intraepithelial neoplasia

Lesions	HPV infection	p16	p53	Ki 67 index
Usual (classical) VIN	HPV 6 and 11	Intense nuclear p-16	Negative	High
Differentiated (simplex) VIN	Independent of HPV	Usually negative	Strongly positive in immature basal and parabasal cells	High

- *Paget's disease of vulva*: Paget cells are positive for CK 7, CEA, CAM 5.2 and GDFP-15.[9]
- *Superficial spreading malignant melanoma*: Melanomas are positive for HMB-45, Melan A and S-100 protein.
- *Multinucleated atypia of vulva*: This entity does not show any nuclear atypia.

The differential diagnoses of differentiated VIN (d-VIN) are:

- *Squamous hyperplasia*: Orderly maturation of the hyperplastic epithelial cells in squamous hyperplasia helps to distinguish it from d-VIN.
- *Lichen sclerosis*: Lack of nuclear atypia helps in distinguishing LS from u-VIN.

Ancillary Studies (Table 3.4)

- HPV: HPV virus (HPV 16) is demonstrated in majority of the cases of u-VIN by molecular studies and rarely seen in d-VIN.[10]
- p-16: Intense nuclear p-16 is seen in the entire paraneoplastic epithelium of u-VIN. In contrast, p-16 immunostain is negative in d-VIN cases[11]
- Ki 67: Ki 67 index is a reliable proliferation marker and its expression is increased in VIN.[12] However, Ki 67 is more useful in grading of VIN than its diagnosis.
- p53: p53 staining is strongly positive in immature basal and parabasal cells of d-VIN.

Prognosis and Treatment

There is substantial risk if VIN 3 cases are not treated as they may develop invasive carcinoma within 8 years after the primary diagnosis.[13] Small proportion of high grade VIN regresses spontaneously. The following treatment protocol is available for VIN lesions:

Surgery: Complete local excision is the treatment of choice. The resection margins should be free of any tumor.

Laser excision, laser vaporization and loop electrosurgical excision procedure (LEEP): Laser excision helps in the removal of the lesion along with histopathological examination, whereas, laser vaporization destroys the tissue. LEEP is an alternative technique of laser vaporization.

Medical treatment: Local application of 5-flurouracil may eradicate the lesion. However, the occult invasion may be missed as no histopathological study could be done.

SQUAMOUS CELL CARCINOMA OF VULVA

Carcinoma of vulva accounts for 5–8% of all gynecological malignancies worldwide.[14] Approximately 90% of vulval cancers are squamous cell carcinoma. The mean age of vulval carcinoma is 65 years. The risk factors for vulval carcinoma include HPV infection, sexual promiscuity, cigarette smoking, immunodeficiency, and vulval dermatosis such as lichen sclerosis, squamous hyperplasia, etc.[15] HPV 16 is commonly related with vulval squamous cell carcinoma (VSCC) and less commonly other HPV types (HPV 18, 31, 33, 45) are related with VSCC.[16] Most of the vulval carcinomas develop from VIN lesion. Probably, there are two distinct groups of vulval carcinoma cases (Figure 3.6):

- *HPV associated*: The patients are associated with HPV and VIN lesions (30% of vulval carcinoma cases).
- *HPV independent*: The large majority of the patients has various vulval dermatosis and are not related with HPV.

Clinical Features

The patient presents with ulcer, black macule, nodule or pedunculated mass. The patient may complaints of pruritus, bleeding, dyspareunia, or foul smell. The tumor is usually solitary and is located in the labia majus or minus (Figure 3.7). Less than 10% of VSCCs are multifocal in origin.

JAYPEE BROTHERS

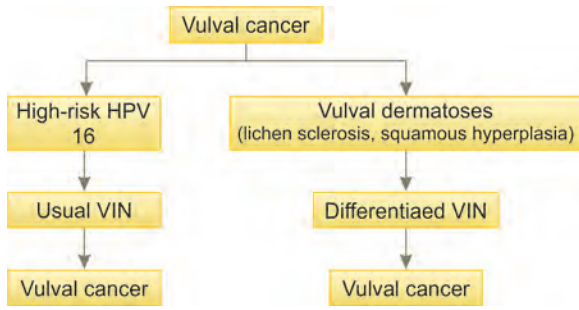

Figure 3.6: Two distinct etiological origin of vulval cancer



Figure 3.7: Squamous cell carcinoma: Large ulcerated swelling over the right labia major of vulva

Histology of Squamous Cell Carcinoma of Vulva

Nonkeratinizing Squamous Cell Carcinoma

Here the individual cells show keratinization but the tumor lacks squamous pearl (Figures 3.8 to 3.10).

Keratinizing Squamous Cell Carcinoma

This is the most common variety of squamous cell carcinoma. The tumor shows multiple squamous pearls (Figures 3.11 and 3.12). The tumor cells infiltrate in the deeper stromal tissue with desmoplastic reaction. The malignant cells are large and contain abundant eosinophilic cytoplasm having moderate nuclear enlargement and pleomorphism.

Basaloid Carcinoma

It consists of nests of small monomorphic cells having scanty cytoplasm. The nuclei show granular chromatin. The cells resemble basal cells (Figure 3.13). Keratin pearls are not usually not seen in this carcinoma, however focal keratinization may be seen. Basaloid carcinoma usually shows HPV 16 DNA.

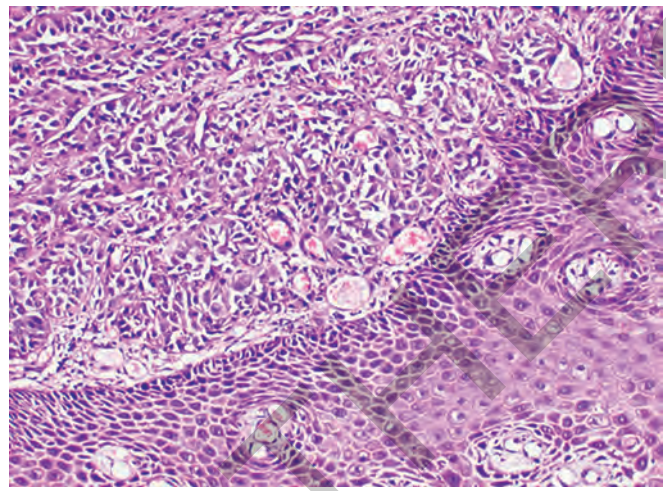

Figure 3.8: Nonkeratinizing squamous cell carcinoma: Diffuse sheet of cells

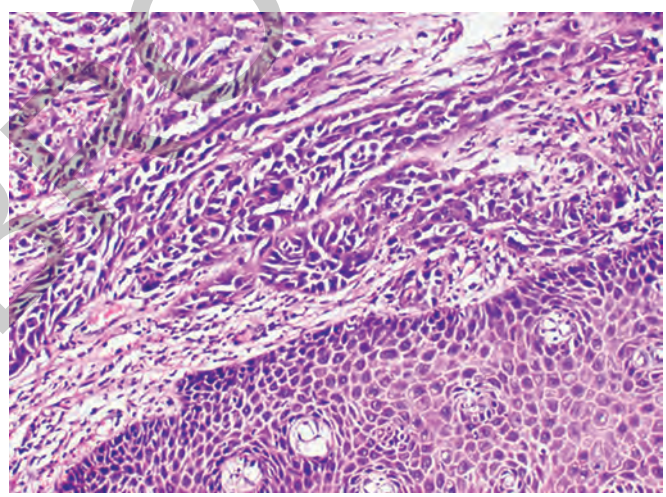

Figure 3.9: Nonkeratinizing squamous cell carcinoma: Nest and diffuse sheets of cells

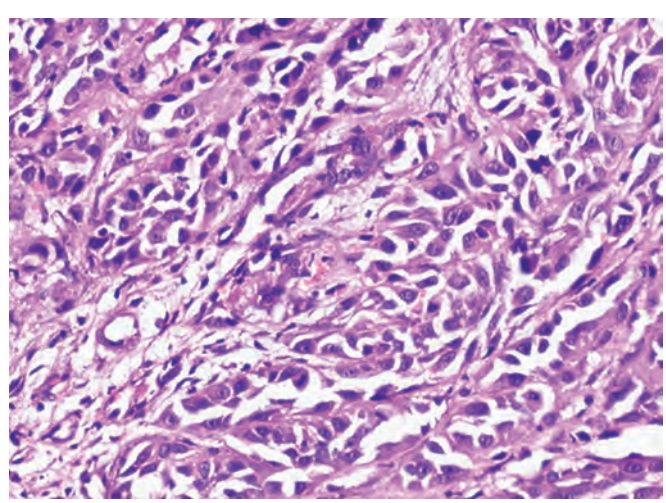

Figure 3.10: Non keratinizing squamous cell carcinoma: Oval to polyhedral cells with intracellular keratinization

JAYPEE BROTHERS

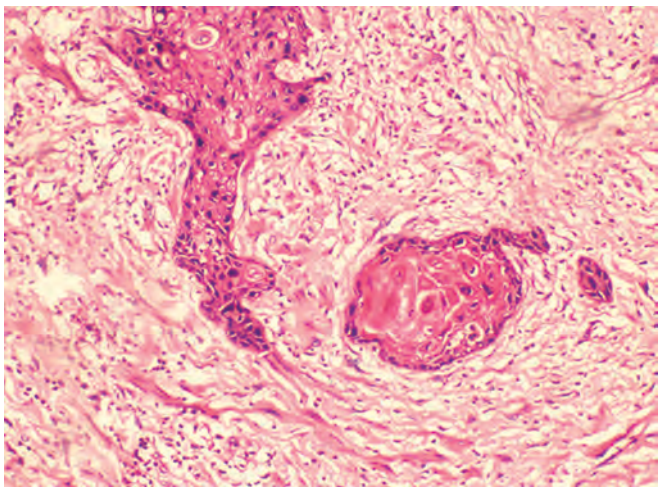

Figure 3.11: Keratinizing squamous cell carcinoma: Squamous pearl

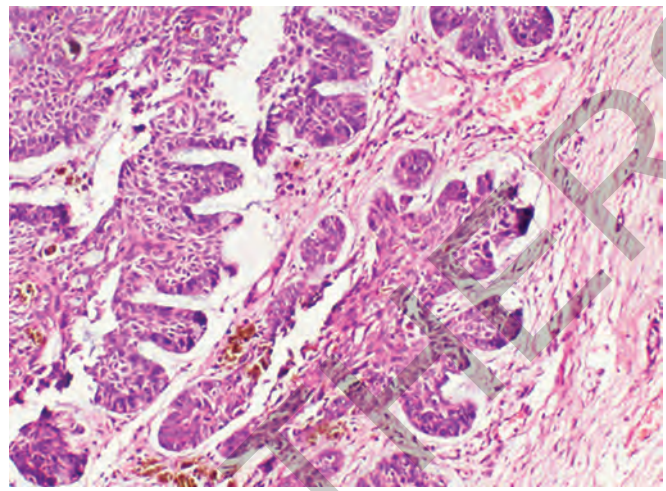

Figure 3.13: Basaloid squamous cell carcinoma: Basaloid arrangement of cells in the periphery of cell cluster

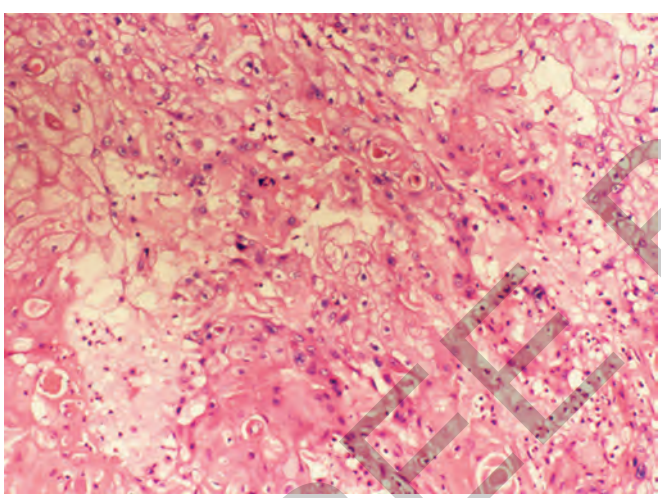

Figure 3.12: Keratinizing squamous cell carcinoma: Intracellular keratinization

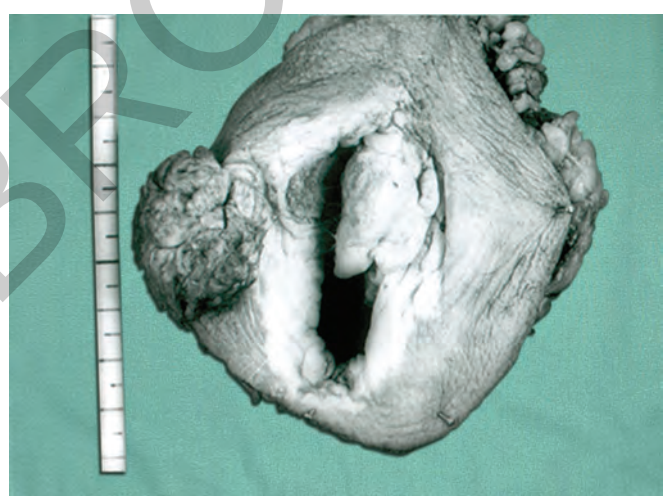

Figure 3.14: Verrucous carcinoma: Papillary exophytic growth in the right labia majora of vulva

Warty Carcinoma

The tumor shows warty surface consists of multiple papillary projections with fibrovascular core. The papillae are lined by squamous cells. The individual tumor cells show nuclear enlargement and pleomorphism along with increased mitotic activity. Many cells show koilocytoctic changes. Warty carcinoma also frequently associated with HPV 16 infection.

Verrucous Carcinoma (Figures 3.14 to 3.17)

It is a well-differentiated type of squamous cell carcinoma characterized by broad based papillary growth that pushes the stroma downwards by bulldozer like pattern. This broad pushing margin of the malignant cells is difficult to recognize as invasion. Hyperkeratosis and parakertosis are seen. The individual cells have abundant cytoplasm. Nuclear atypia and mitotic activity are nil to absent.

The tumor may recur after local excision however metastasis in the regional lymph node is extremely uncommon and re-evaluation of the tumor should be done in such cases.

Keratoacanthoma Like Carcinoma

The tumor resembles keratoacanthoma and is included in VSCC by WHO. The tumor is characterized by central crater filled with proliferating squamous cells and keratin. The tumor is self-limiting and complete remission of the tumor may occur spontaneously due to unknown immune mechanism.

JAYPEE BROTHERS

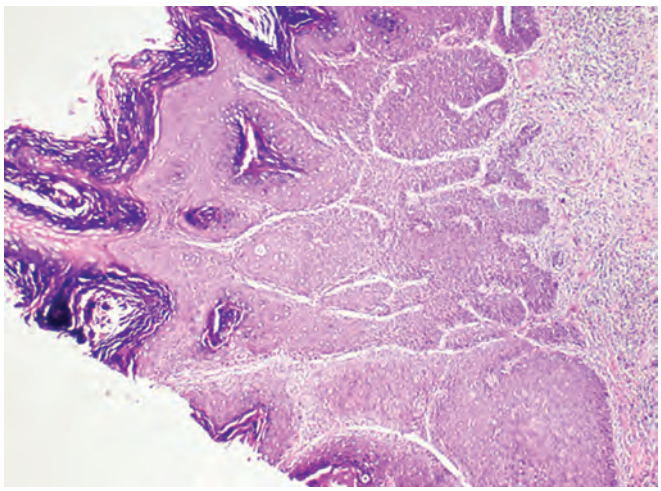

Figure 3.15: Verrucous carcinoma: Broad based bulbous growth of tumor cells

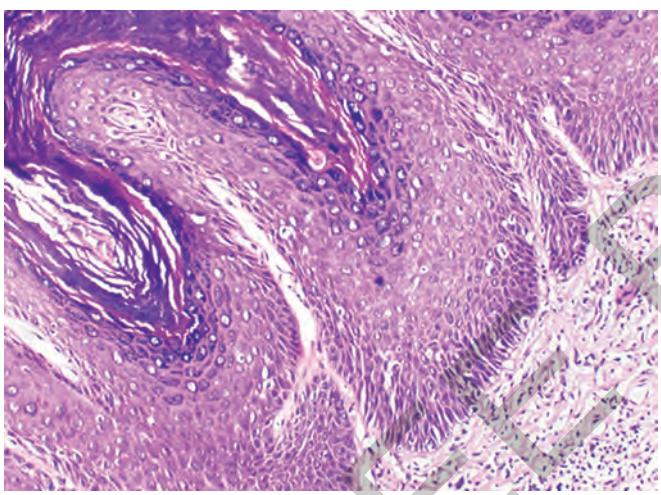

Figure 3.16: Verrucous carcinoma: Broad based bulbous growth of tumor cells with pushing margin

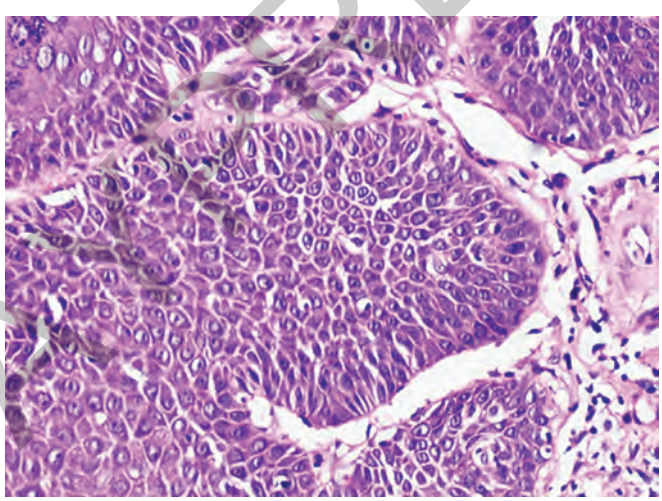

Figure 3.17: Verrucous carcinoma: The tumor cells show minimal nuclear atypia and scanty mitotic activity

Differential Diagnosis (Table 3.5)

- **Verrucous carcinoma versus other lesions:**
  - Keratinizing squamous cell carcinoma
  - Warty carcinoma, condyloma accuminatum
- **Amelanotic melanoma versus squamous cell carcinoma (SCC) with multinucleated giant cells:** The presence of adjacent VIN or focal squamous differentiation may be helpful morphological features of SCC. In case of difficulty immunostaining such as HMB 45 and Melan A may be helpful to confirm the diagnosis of melanoma.
- **Basaloid squamous cell carcinoma versus small cell carcinoma, Merkel cell carcinoma, and basal cell carcinoma:** Frequent molding and the absence of any squamoid differentiation help in identification of small cell carcinoma. The cells of Merkel cell carcinoma is small round monomorphic and arranged in diffuse sheet or in trabecular pattern. The cells show NSE, chromogranin and CK20 positivity. The cells of basal cell carcinoma are monomorphic, bland and show characteristic peripheral palisading pattern.

Tumor Spread and Staging

The staging of vulvar carcinoma is recommended by Federation of Gynecology and Obstetrics (FIGO) in 2014 (Table 3.6).[17]

The depth of invasion is defined as the measurement of the tumor from the epithelialstromal junction of the adjacent most superficial dermal papilla to the deepest point of invasion.

It is important to provide necessary information in the surgical pathology report of vulva as recommended by college of American Pathologist and Royal College of Australian Pathologist[18] (Box 3.1) (Figure 3.18).

Prognosis

Prognosis of VSCC is dependent on the FIGO stage of the tumor (Box 3.2). The overall 5 year survival of Stage 1 tumor is as high as 98% in comparison to 29% in case of stage IV tumors.[19] The various other factors related with prognosis are tumor size, depth of invasion, lymph node involvement, lymphovascular invasion and the presence of high grade VIN along the margin of the tumor.

Treatment

The main treatment of vulval carcinoma is surgical resection. The operative procedure may be partial vulvectomy or radical vulvectomy. In case of partial vulvectomy a part of vulva is removed. In case of total vulvectomy, the whole vulva along with appropriate integument is removed.

JAYPEE BROTHERS

Table 3.5: Differential diagnosis of verrucous carcinoma

Features	Verrucous carcinoma	Keratinizing squamous cell carcinoma	Warty carcinoma	Condyloma accuminatum
Growth pattern	Broad based papillary growth pushing the stroma	Small islands or isolated cells	Irregular and exophytic growth	Vascular papillary growth
Nuclear atypia	Absent	Present: Moderate to marked	Present: Moderate	Mild atypia
Mitosis	Absent	Present:	Present	Absent
Koilocytosis	Absent	Absent	Present	Present

Table 3.6: FIGO staging of carcinoma of vulva

Stage	Description
Sage I	• Tumor confined to the vulva • IA Lesions ≤ 2 cm in size, confined to the vulva or perineum and with stromal invasion, ≤1.0 mm[a], no nodal metastasis • IB Lesions > 2 cm in size or with stromal invasion >1.0 mm[a], confined to the vulva or perineum, with negative nodes
Stage II	Tumor of any size with extension to adjacent perineal structures (lower third of urethra, lower third of vagina, anus) with negative nodes
Stage III	Tumor of any size with or without extension to adjacent perineal structures (lower third of urethra, lower third of vagina, anus) with positive inguinofemoral nodes • IIIA (i) with 1 lymph node metastasis (≥5 mm), or (ii) with 1–2 lymph node metastasis(es) (<5 mm) • IIIB (i) with 2 or more lymph node metastases (≥5 m), or (ii) with 3 or more lymph node metastases (<5 mm) • IIIC with positive nodes with extracapsular spread
Stage IV	Tumor invades other regional (upper 2/3 urethra, upper 2/3 vagina), or distant structures • IVA tumor invades any of the following: - (i) upper urethral and/or vaginal mucosa, bladder mucosa, rectal mucosa, or fixed to pelvic bone, or - (ii) fixed or ulcerated inguinofemoral lymph nodes • IVB Any distant metastasis including pelvic lymph nodes

Box 3.1: Microscopy report of vulval carcinoma

- The gross diameter of the tumor in surgical specimen
- The number of primary tumors
- The exact depth of invasion of the tumor and the method of measurement
- The diameter of tumor on histopathology section
- The presence of vascular invasion
- The presence of any perineural invasion
- The status of tumor margins and deep resection plane
- Associated VIN, if any
- Total number of lymph nodes and their involvement with location
- The size of metastatic lymph node

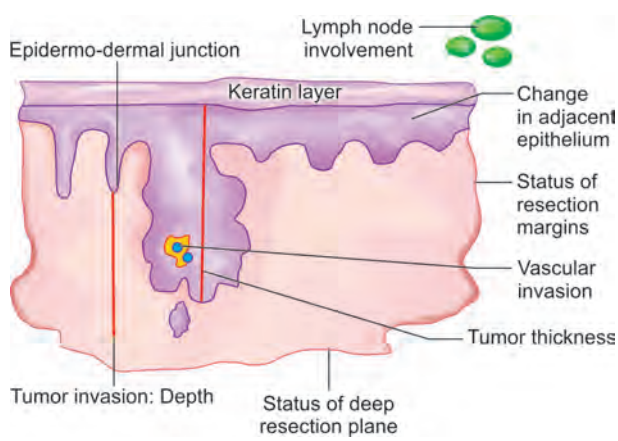

Figure 3.18: Vulval carcinoma: Reporting the various microscopic features

PAGET DISEASE OF VULVA

Paget disease is an intraepithelial adenocarcinoma of vulva with eccrine or apocrine differentiation. This represents only 1% of vulval carcinoma. The lesion occurs in post-menopausal woman. Approximately 10–20% vulval Paget disease is accompanied by invasive adenocarcinoma. The patients usually complain of pruritus or pain along with red to pink eczematous plaque-like lesion.

Box 3.2: Prognostic factor of vulval carcinoma

- **Main prognostic factor (by multivariate analysis)**
  - FIGO staging
- **Other prognostic factors (by univariate analysis)**
  - Tumor size
  - Depth of invasion
  - Lymph node involvement
  - Lymphovascular invasion

JAYPEE BROTHERS

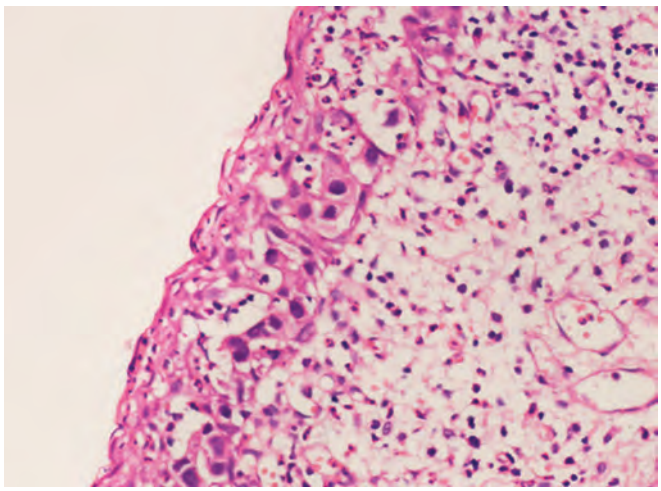

Figure 3.19: Paget's disease: The epidermis shows many Paget's cells

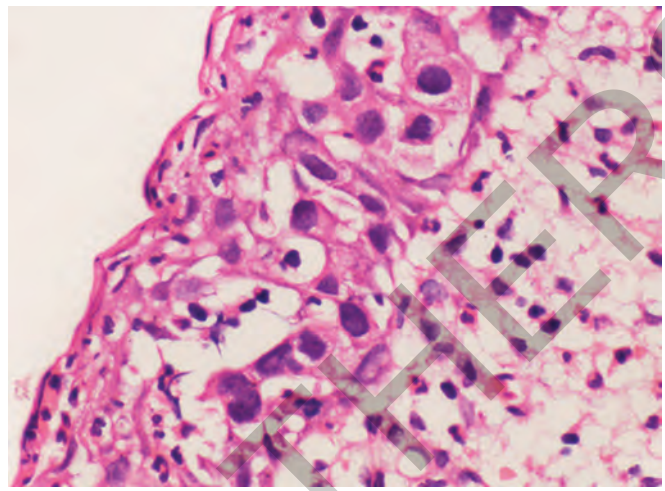

Figure 3.20: Paget's disease: Paget's cells show large hyperchromatic nuclei with clear cytoplasm

Table 3.7: Differential diagnosis of Paget disease

Lesion	Simulating features	Distinguishing features
In situ and invasive squamous cell carcinoma (pagetoid Bowen disease)	• Single dispersed tumor cells in the epidermis	• Tumor cells are located in the suprabasal region of the epidermis with intact keratinocytes • Intracellular mucin • Signet ring cells • Glandular structures
Superficial spreading malignant melanoma	• Single dispersed cells in the epidermis • Occasional cases show melanin within the Paget cell	• Cells of melanoma are collected as a nest in dermoepidermal junction • Intracellular mucin and acini • HMB 45 and Melan A positivity
Mycosis fungoides	• Single large cells in the epidermis	• Large convoluted cerebriform cells • Intraepidermal collection of lymphoid cells • T-cell marker (CD 3) positive

Histopathology

The tumor shows single or nests of Paget cells in the epidermis predominantly located in the basal or parabasal region. The individual Paget cells are large and contain abundant pale vacuolated cytoplasm (Figures 3.19 and 3.20). The nuclei of the cells are central in position and large with vesicular having prominent nucleoli. Uncommonly glands or acini like structures are seen. Infrequent mitotic activity may also be noted. Occasionally, the Paget cells may contain melanin pigment due to transfer of melanin from melanocytes to Paget cell.

Special Stains

Paget cells are positive for Periodic acid Schiff (PAS) stain and resistant to diastase. The cells contain mucin and therefore positive for Alcian blue and mucicarmine. The cells are also positive for mucin core protein (MUC) 1 and MUC 5. On immunohistochemistry, Paget cells are positive for CEA, epithelial membrane antigen (EMA), low-molecular weight cytokeratin and gross cystic disease fluid protein 15 (GCDFP-15). Immunocytochemistry is particularly helpful in distinguishing primary intraepidermal Paget's disease and Paget's disease that developed from an associated internal adenocarcinoma.

Differential Diagnosis

The differential diagnosis and detailed immunohistochemistry of Paget's disease have been mentioned in Tables 3.7 and 3.8 respectively.

- In situ and invasive squamous cell carcinoma (pagetoid Bowen disease).
- Superficial spreading malignant melanoma.
- Mycosis fungoides and Paget's disease.

Prognosis and Treatment

The prognosis of Paget disease depends on the extent of the lesion. The prognosis of totally intraepithelial Paget disease without any invasion is much better than invasive Paget

JAYPEE BROTHERS

Table 3.8: Immunohistochemistry of extra-mammary Paget disease

Lesion	Immunohistochemistry				
	CK7	CK20	GCDFP15	Uroplakin	CEA
Primary Paget	+	–	+	–	+
Paget due to underlying anorectal carcinoma	–	+	–	–	+
Paget due to underlying urothelial carcinoma	+	+	–	+	–

Gross cystic disease fluid protein (GCDFP-15)

disease. The primary intraepithelial Paget progresses slowly and has an indolent course. The disease is often multifocal and the normal appearing skin around the Paget disease may also show involvement. Therefore, the recurrence of Paget is common even after successful resection margin free tumor removal.

The treatment of Paget disease of vulva is surgical resection of the tumor. There should be at least 1 cm tumor free margin of the skin.[20] In case of invasive Paget disease ipsilateral inguinal–femoral lymphadenectomy is recommended.

MALIGNANT MELANOMA OF VULVA

Malignant melanoma represents 10% of all malignant tumors of vulva.[21] The disease predominantly occurs in elderly white woman and rarely seen under 30 year of age.

Clinical features: The patients complain vulval bleeding, pruritus and dysuria. They usually present with pigmented nodule or polypoid mass and rarely as ulcerated lesion. Approximate one-third of vulval melanoma may be amelanotic. The vulval melanomas are often multifocal with satellite nodules around the main tumor (20%).

Histopathology (Figures 3.21 and 3.22)

There are three histological pattern of malignant melanoma of vulva:

1. **Mucosallentiginous melanoma:** Mucosal lentiginous melanoma is the commonest type in the vulval region. The tumor may show both radial and vertical growth pattern. The large atypical melanocytes are spread singly or nest-like pattern in the epidermis. The cells in the invasive epidermo-dermal zone are elongated spindle-shaped and invade the dermis in small fascicles or nests. The atypical cells in the intra-epidermal region are large. The tumor cells contain abundant cytoplasm with round nuclei and prominent nucleoli.
2. **Nodular melanoma:** Nodular melanoma usually does not show any radial growth pattern. The neoplastic cells may be present within the epidermis with an invasive component. The tumor cells are large polygonal with abundant cytoplasm having enlarged nuclei with prominent nucleoli. The other cell types are spindle-shaped and dendritic cells with oval to elongated nuclei. The cells are arranged in small fascicles. The dendritic cells contain elongated cytoplasmic process simulating nerve cells. The cells show moderate nuclear pleomorphism.

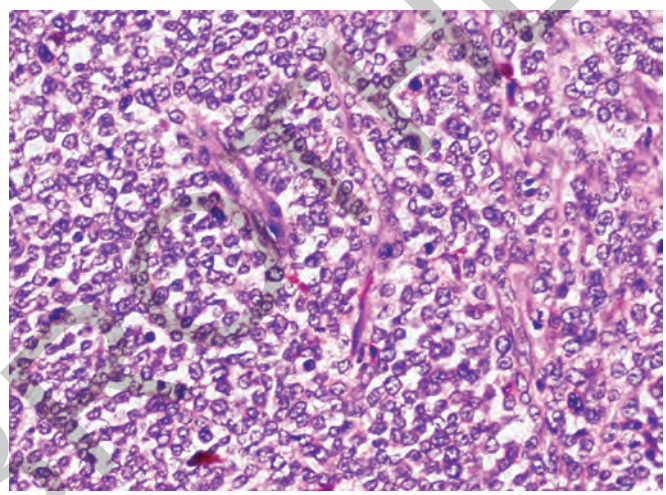

Figure 3.21: Melanoma of vulva: Diffuse sheets of cells with malignant cells

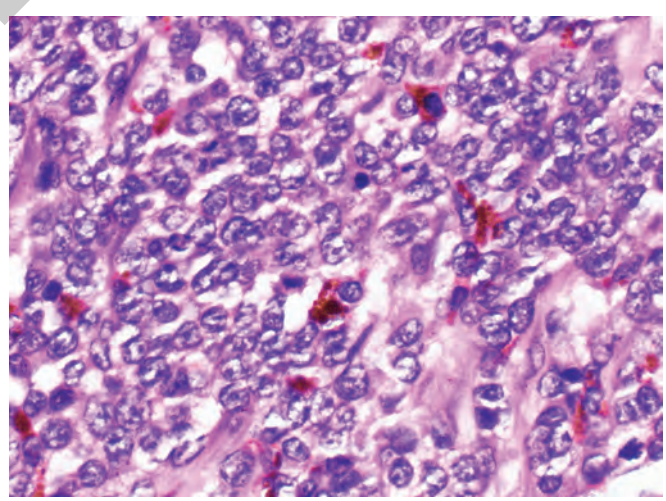

Figure 3.22: Melanoma of vulva: Higher magnification shows cells with enlarged nuclei and prominent nucleoli. The cells contain brownish melanin pigment

JAYPEE BROTHERS

3. **Superficial spreading melanoma:** Superficial spreading melanoma predominantly shows radial pattern of growth. There is evidence of invasion. The malignant cells are large polygonal with abundant cytoplasm having centrally placed nuclei. Nuclei are relatively monomorphic with prominent nucleoli.

Differential Diagnosis

The differential diagnoses of malignant melanoma of vulva are:

- Vulval Paget disease: Discussed before
- VIN: Discussed before
- Poorly differentiated squamous cell carcinoma: Poorly differentiated squamous cell carcinoma with spindle cell component may be mistaken as malignant melanoma.
- Spindle cell tumor of soft tissue origin: The presence of melanin in the spindle cells and immunocytochemistry (HMB 45 and Melan A) may be helpful in confirmation of melanoma.

Prognosis

The main prognostic factors of melanoma are: (1) depth of tumor invasion, (2) tumor thickness.

Tumor thickness: The tumor thickness is measured by Breslow's thickness measurement. The tumor thickness is measured from the lower border of the granular layer of the epithelium to the deepest point of tumor invasion.[22] According to the depth of invasion the tumor is classified from T1 to T4 (Table 3.9). The 5 year survival rate in T1 Breslow's grade of invasion (less than 1 mm) is much higher (near about 90%).

Tumor invasion: Clark classified melanoma in five levels depending on the involvement of the various anatomic compartments of the skin[23] (Table 3.10). Prognosis of melanoma is excellent when melanoma is less than Clark 2 level.

Other prognostic factors: The other adverse prognostic factors of melanoma are: (1) surface ulceration, (2) lymphovascular invasion, (3) tumor necrosis and, (4) high dermal mitotic activities.

Treatment

The treatment of melanoma of vulva is complete surgical excision of the lesion. There should be at least 2 cm free margins and 1–2 cm free deep resection plane. Melanoma with more than 4 mm invasion needs wide resection with removal of deep fascia and inguinal lymph nodal dissection.

Table 3.9: Breslow's classification of melanoma invasion

Classification	Depth of tumor invasion
T1	Less than 1 mm
T2	1–2 mm
T3	2–4 mm
T4	More than 4 mm

Table 3.10: Clark's classification

Classification	Tumor invasion into the different anatomic subdivision
Level 1	Intraepithelial involvement of melanoma or in situ melanoma
Level 2	Involvement into the superficial papillary dermis
Level 3	Melanoma extensively involves the papillary dermis
Level 4	Reticular dermis is involved
Level 5	Tumor invasion into the subcutaneous tissue and fat

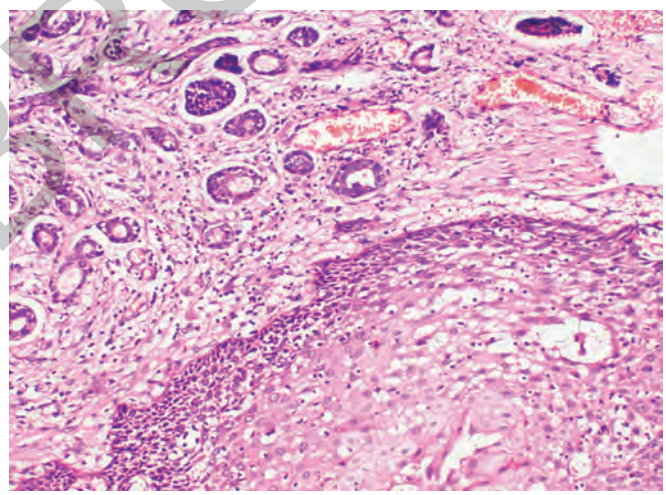

Figure 3.23: Adenoid cystic carcinoma: Tumor underneath the epidermis

OTHER UNCOMMON MALIGNANT TUMORS OF VULVA

Vulva is rarely involved by various other malignant tumors such as adenoid cystic carcinoma (Figures 3.23 to 3.25), Markel cell carcinoma, endodermal sinus tumor and non-Hodgkin lymphoma.

Metastatic Tumors of Vulva

Metastatic tumor comprises of 8% of vulval tumors. The common primary sources of metastasis are cervix, uterus and ovary. The other uncommon primary sites are breast, kidney and gastrointestinal tract.

JAYPEE BROTHERS

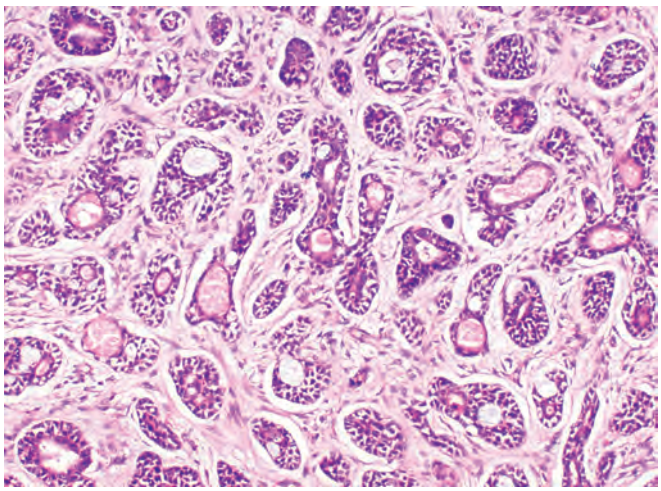

Figure 3.24: Adenoid cystic carcinoma: Typical pattern of adenoid cystic carcinoma

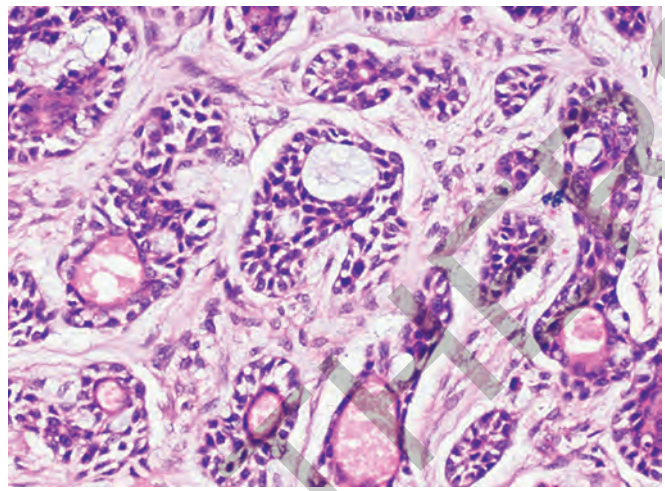

Figure 3.25: Adenoid cystic carcinoma: Higher magnification shows gland-like arrangement of cells around central luminal structure

REFERENCES

1. Kurman RJ, Carcangiu ML, Herrington S, Young RH. Tumors of vulva. WHO classification of tumors of female genital reproductive organs. 4th Edition, International Agency for Research on Cancer, Lyon; 2014.
2. Kondi-Paphitis A, Deligeorgi-Politi H, Liapis A, Plemenou-Frangou M. Human papilloma virus in verrucus carcinoma of the vulva: an immunopathological study of the cases. Eur J Gynaecol Oncol. 1998; 19:319-20.
3. Traiman P, Bacchi CE, De Luca LA, Uemura G, Nahas Neto J, Nahas EA, et al. Vulvar carcinoma in young patients and its relationship with genital warts. Eur J Gynaecol Oncol. 1999; 20: 191-4.
4. Congilosi SM, Madoff RD. Current therapy for recurrent and extensive anal warts. Dis Colon Rectum. 1995;38:1101-7.
5. Mabuchi K, Bross DS, Kessler, II. Epidemiology of cancer of the vulva. A case-control study. Cancer. 1985;55(8):1843-8.
6. Haefner HK, Tate JE, McLachlin CM, Crum CP. Vulvar intraepithelial neoplasia: age, morphological phenotype, papillomavirus DNA, and coexisting invasive carcinoma. Hum Pathol. 1995;26(2):147-54.
7. Sideri M, Jones RW, Wilkinson EJ, et al. Squamous vulvar intraepithelial neoplasia:2004 modified terminology, ISSVD. Vulvar Oncology Subcommittee. J Reprod Med. 2005;50:807-10.
8. Rufforny I, Wilkinson EJ, Liu C, Zhu H, Buteral M, Massoll NA. Human papillomavirus infection and p16(INK4a) protein expression in vulvar intraepithelial neoplasia and invasive squamous cell carcinoma. J Low Genit Tract Dis. 2005;9(2): 108-13.
9. McCluggage WG. Recent advances in immunohistochemistry in gynaecological pathology. Histopathology. 2002;40(4): 309-26.
10. Skapa P, Zamecnik J, Hamsikova E, Salakova M, Smahelova J, Jandova K, et al. Human papillomavirus (HPV) profiles of vulvar lesions: possible implications for the classification of vulvar squamous cell carcinoma precursors and for the efficacy of prophylactic HPV vaccination. Am J Surg Pathol. 2007;31(12):1834-43.
11. Santos M, Montagut C, Mellado B, Garcia A, Ramon y Cajal S, Cardesa A, et al. Immunohistochemical staining for p16 and p53 in premalignant and malignant epithelial lesions of the vulva. Int J Gynecol Pathol. 2004;23(3):206-14.
12. Brustmann H, Naude S. Expression of topoisomerase IIalpha, Ki-67, proliferating cell nuclear antigen, p53, and argyrophilic nucleolar organizer regions in vulvar squamous lesions. Gynecol Oncol. 2002;86(2):192-9.
13. Jones RW, Rowan DM. Vulvar intraepithelial neoplasia III: a clinical study of the outcome in 113 cases with relation to the later development of invasive vulvar carcinoma. Obstet Gynecol. 1994;84(5):741-5.
14. Parkin DM, Whelan SL, Ferlay J, et al. Cancer incidence in five continents VII. Lyon, France, IARC, 1997.
15. Moore TO, Moore AY, Carrasco D, Vander Straten M, Arany I, Au W, Tyring SK. Human papillomavirus, smoking, and cancer. J Cutan Med Surg. 2001;5(4):323-8.
16. Bonvicini F, Venturoli S, Ambretti S, Paterini P, Santini D, Ceccarelli C, et al. Presence and type of oncogenic human papillomavirus in classic and in differentiated vulvar intraepithelial neoplasia and keratinizing vulvar squamous cell carcinoma. J Med Virol. 2005;77(1):102-6.
17. FIGO staging for carcinoma of the vulva, cervix, and corpus uteri. FIGO Committee on Gynecologic Oncology. Int J Gynaecol Obstet. 2014;125 (2):97-8. Epub 2014 Feb 22.
18. Wilkinson EJ. Protocol for the examination of specimens from patients with carcinomas and malignant melanomas of the vulva: a basis for checklists. Cancer Committee of the College of American Pathologists. Arch Pathol Lab Med. 2000;124:51-56: Revised 2005.

JAYPEE BROTHERS

19. Homesley HD, Bundy BN, Sedlis A, et al. Assessment of current international federation of gynecology and obstetrics staging of vulvar carcinoma relative to prognostic factors for survival (a gynecologic oncology group study). Am J Obstet Gynecol. 1991;164:997-1004.
20. DeVita VT, Jr, Hellman S, Rosenberg SA. Cancers of the skin. Cancer, principles and practice of oncology. New York: Lippincott Raven, 1997:1565-6.
21. Irvin PW, Legallo RL, Stoler MH, Rice LW, Taylor PT Jr, Andersen WA. Vulvar melanoma: a retrospective analysis and literature review. Gynecol Oncol. 2001;83:457-65.
22. Breslow A. Tumor thickness, level of invasion and node dissection in stage I cutaneous melanoma. Ann Surg. 1975; 182:572-5.
23. Clark WH Jr, Elder DE, Guerry D 4th, et al. Model predicting survival in stage I melanoma based on tumor progression. J Natl Cancer Inst. 1989;81:1893-904.

JAYPREE BROTHERS

for detailed information on obstetrics & gynecology books, visit our website **www.jaypeebrothers.com,** for detailed information on obstetrics & gyne

Essentials of
Gynecologic Pathology

Salient Features

- Simple and concise book with all recent and relevant informations.
- Describes various lesions in Gynecology and Obstetrics.
- Discusses in depth etiology, clinical features, macroscopy, histopathology, immunohistochemistry, molecular pathology and treatment of each gynecological lesions.
- Includes large numbers of tables, boxes and microscopical figures to illustrate the lesions.
- Immensely useful to both the students and practicing pathologists, who are interested in gyencologic pathology.
- Useful book to practitioners of Gynecology.

Pranab Dey MBBS MD MIAC FRCPath is a well-reputed cytologist and gynecological pathologist who is engaged in diagnosis, research and teaching in Cytology and Gynecologic Pathology for the last three decades. Presently, he is Professor, Department of Cytology and Gynecologic Pathology, Postgraduate Institute of Medical Education and Research, Chandigarh, India.



Available at all medical bookstores
or buy online at www.jaypeebrothers.com

JAYPEE BROTHERS
Medical Publishers (P) Ltd.
www.jaypeebrothers.com
Join us on facebook.com/JaypeeMedicalPublishers

Shelving Recommendations
GYNECOLOGY, PATHOLOGY

ISBN 978-93-86261-20-5
9 789386 261205