& gynecology books, visit our website **www.jaypeebrothers.com,** for detailed information on obstetrics & gynecology books

GYNECOLOGY

3rd Edition

Celebrating 50 Years
Passion, Quality and Innovation in Healthcare Publishing

Essentials of GYNECOLOGY



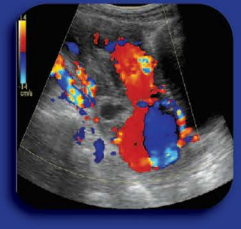



Editors
Sabaratnam Arulkumaran
V Sivanesaratnam
Alokendu Chatterjee
Pratap Kumar



Foreword
Shirish S Sheth

JAYPEE

Contents

SECTION 1: GENERAL GYNECOLOGY

1. Embryology and Development of the Female Genital Tract 3

Nozer Sheriar

Indifferent Embryo 3
Female Gonadal Differentiation 4
Female Genital Duct Differentiation 5

2. Disorders of the Development of Müllerian System 7

Pratap Kumar, Sapna Vinit Amin

Anomalies of the Female Reproductive Tract 7

3. Ovulation and Menstruation 13

AP Manjunath, Pratap Kumar, Jayaraman Nambiar

Ovulation and Menstruation 13
Feedback Oscillation of the Hypothalamo-pituitary Ovarian System 17

4. Gynecological History and Examination 19

Anna Gracia Perez-Bonfils, Edwin Chandraharan

History-Taking 20
Menstrual History 21
Contraceptive History 22
Past Obstetric History 22
Past Gynecological History 22
Past Medical/Surgical History 22
Drug History/Allergies 22
Sexual History 22
Social History 23
Family History 23
General Examination 23
Abdominal Examination 23
Gynecological Examination 24
Position 24
Technique of Bimanual Examination 24
Bimanual Examination of the Uterus and the Adnexae 26
Rectal Examination 26
Rectovaginal Examination 27

5. Pediatric Gynecology **28**
Pratap Kumar, Shyamala Guruvare, Arun Nagrath, Rupinder Kaur Ruprai
Normal Anatomy and Physiology 28
Disorders of Sexual Differentiation and Sexual Ambiguity 30
Vulvovaginal Disorders 33
Vaginal Discharge 35
Viral Infections 35
Urethral Prolapse 36
Foreign Bodies 36
Imperforate Hymen 36
Precocious Puberty 36
Ovarian Cysts 39

6. Adolescent Gynecology **42**
Rupinder Kaur Ruprai
Puberty 42
Clinical Evaluation of the Adolescent Girl 44
Conditions Affecting the Adolescent Girl 46
Delayed Sexual Development 46
Turner's Syndrome 47
Congenital Adrenal Hyperplasia 47
Cystic Fibrosis 51
Menstrual Disorders 52
Amenorrhea 56
Hyperandrogenism in Adolescent Girls 58
Functional Ovarian Hyperandrogenism 61
Premenstrual Syndrome 62
Pelvic Pain and Recurrent Abdominal Pain 63
Dysmenorrhea 63
Endometriosis 65
Ovarian Enlargements in Adolescent Girl 68
Vulvovaginal Complaints 70
Cervical Cytology, Histology, and Human Papillomavirus 70
Müllerian Abnormalities 71
Eating Disorders 71
Athletic Adolescents 72
Epilepsy 72
Childhood Cancer Survivors 72
Adolescent Pregnancy 72
Termination of Pregnancy 72
Sexual Abuse 73
Female Cosmetic Genital Surgery 73

7. Dysmenorrhea **77**
PK Shah, Keshav Pai
Definition 77
Incidence 77

Risk Factors for Dysmenorrhea 77
Classification or Types 78
Recent Advances 82

8. Abnormal Uterine Bleeding **84**
PK Sekharan
Normal Menstrual Bleeding 84
The New Classification of AUB 84
Salient Features of PALM-COEIN Classification 86
Evaluation of Abnormal Uterine Bleeding 86
Management 88
Danazol and Gestrinone 90

9. Amenorrhea and Oligomenorrhea **93**
B Kanchana Devi, N Pandiyan
Physiology of Menstruation 93

10. Reproductive Health **101**
WC Maina, Sambit Mukhopadhyay
Adolescent Health 101
Female Genital Mutilation 102
Overweight and Obesity 103
Unsafe Abortion 105
Pelvic Inflammatory Disease and Sexually Transmitted Infections 106
Childbirth and Maternal Mortality 107

11. Endometriosis and Adenomyosis **109**
Siti Zawiah Omar
Occurrence 109
Etiology 109
Clinical Manifestations 110
Investigations 110
Staging 111
Management 111
Other Options 113
Surgical Treatment 113
Endometriosis and Infertility 114
Adenomyosis 114

12. Pelvic Inflammatory Disease **117**
Siya Sharan Sharma, Sucheta Jindal
Natural Barriers to PID 117
Vulnerability to PID 117
Etiological Factors of PID 117
Clinical Features of PID 119
Treatment 121

13. Sexually Transmitted Infections (Formerly Known as Sexually Transmitted Diseases) 125
Siya Sharan Sharma, Sucheta Jindal

Defense Mechanism of Female Genital Tract 125
Sexually Transmitted Infections 126
Chlamydial Infection 127
Gonorrhea 128
Acute Gonorrhea 129
Trichomonas Vaginitis 130
Vulvovaginal Candidiasis (Moniliasis) 131
Chronic Vulvovaginal Candidiasis 132
Genital Ulcerative Diseases 133
Herpes in Pregnancy 134
Syphilis 135
Chancroid 139
Lymphogranuloma Venereum 139
Granuloma Inguinale 140
Genital Warts (Condyloma Acuminata) 141

14. Human Immunodeficiency Virus in Women (Including in Pregnancy) 144
Siya Sharan Sharma, Sucheta Jindal

Epidemiology 144
Pathophysiology 144
Clinical Progression of HIV 145
Diagnosis 145
Prevention of Spread 146
Gynecological Problems due to HIV 146
Clinical Assessment after Initial Diagnosis 147
Prevention of Mother-to-Child Transmission 148

15. Benign Lesions of the Genital Tract 150
K Jayakrishnan, P Manjula

Benign Lesions of Vulva 150
Benign Tumors of Vulva 151
Benign lesions of the Vagina 152
Benign Lesions of the Cervix 152
Benign Tumors of Uterus 152
Uterine Polyps 156
Benign Tumors of Ovary 156

16. Contraception and Sterilization 162
K Jayakrishnan, P Manjula

Definition 162
Classification of Contraceptive Agents 163
Traditional Methods 163
Barrier Methods 165
Hormonal Contraceptives 166
Progesterone only Pills (Mini Pills) 169

Transdermal Patch 169
Vaginal Ring 169
Injectable Contraception 169
Contraceptive Implants 170
Emergency Contraception (Postcoital Contraception) 171
Intrauterine Devices 171
Surgical Sterilization 175
Newer Methods 179

17. Psychosexual Problems and Sexual Dysfunction **181**
Claudine Domoney

Presentation of Sexual Difficulties 182
Definitions of Sexual Disorders in Women 183
Management 184
Investigations 185
Treatment 185
Partners 189
Phases of Life 189

18. Pelvic Organ Prolapse **193**
Pralhad Kushtagi

Definition and Incidence 193
Classification 193
Etiology 194
Anatomy of the Pelvic Floor 196
Secondary Anatomical Changes 197
Symptoms 198
Clinical Evaluation 199
Differential Diagnosis 200
Treatment of Pelvic Organ Prolapse 200
Conservative Management 204

19. Urinary and Fecal Incontinence (Including Fistulae) **206**
Deeksha Pandey

Background 206
Etiology and Risk Factors 207
Urinary Incontinence 207
Fecal Incontinence 212
Genital Fistulae 213

20. A Simplified Approach to Breast Diseases for Obstetricians and Gynecologists **216**
SS Prasad

Relevant Anatomy and Physiology 216
Common Breast-related Symptoms 216
Investigations for Breast Diseases 217
Common Benign Breast Diseases 218
Breast Cancer 219
Breast Problems in Pregnancy and Lactation 220

21. Instruments Used in Obstetrics and Gynecology **221**

Rajesh Bhakta

Sim's Vaginal Speculum 221
Cusco's Vaginal Speculum 221
Sim's Anterior Vaginal Wall Retractor 222
Uterine Sound 222
Vulsellum Forceps 222
Tenaculum 222
Cervical Dilators 223
Uterine Curette 223
Suction Cannula 224
Manual Vacuum Aspirator 224
Ayer's Spatula 224
Punch Biopsy Forceps 225
Endometrial Biopsy Curette 225
Red Rubber Catheter 225
Foley's Catheter 225
Leech Wilkinson's Cannula 226
Shirodkar's Hook 226
Pessary (Hodge, Smith or Ring Pessary) 226
Doyen's Retractor 227
Richardson's Tetractor 227
Episiotomy Scissors 227
Umbilical Cord Cutting Scissor 227
Kocher's Artery Forceps 227
Green-armytage's Forceps 228
Babcock's Forceps 228
Forceps 228
Vacuum Delivery (Ventouse) 229
Malmstrom Cup 229
Vacuum Extractor 229
Sponge Holding Forceps 229
Pinard's Fetal Stethoscope 230
Lamineria Tent 230

22. Ultrasound and Color Doppler in Gynecology **231**

Neharika Malhotra Bora, Rishabh Bora, Narendra Malhotra, Jaideep Malhotra, Sonal Panchal

Ultrasonography in Gynecology *231*
Normal Female Pelvis 232
Uterus 232
Ovaries 232
Folliculogenesis 232
Fallopian Tubes 233
Pouch of Douglas 233
Ultrasound of the Uterus 234
Diseases of the Myometrium 234

Diseases of the Endometrium 236
Diseases of the Uterine Cavity 236
Sonohysterography 240
Ultrasound and Puerperium 240
Diseases of Cervix 241
Vagina 242
Ovarian Sonography 242
Evaluation of an Ovarian Mass 248
Gestational Trophoblastic Disorders 248
Pelvic Kidney 249

3D Ultrasound in Gynecology 251
Uterine Lesions 252
3D of Endometrium 252
Endometrial Volume 252
Endometrial Perfusion 252
Ovarian Lesions 254
Other Adnexal Lesions 256
Endometriosis 258
Paraovarian Cysts 258
Ovarian Dermoid Cysts 258
Other Ovarian Masses 258

23. Gynecological Operations **261**
AP Manjunath, Jayaraman Nambiar

Abdominal Hysterectomy 261
Laparoscopy 273
Hysteroscopy 276

24. General Surgical Problems in Gynecology **279**
Krishnendu Mukherjee

Categories of General Surgical Problems in Gynecology 279

25. Genital Tuberculosis **285**
Prashanth K Adiga, Pratap Kumar

Incidence 285
Pathology 285
Clinical features 286

26. Uterine Displacements including Retroversion and Uterine Inversion **290**
Akhila Vasudeva, Pratap Kumar

Upward Displacement of the Uterus 290
Lateral Displacement of the Uterus 291
Retroversion 291
Symptoms of Retroversion 291
Diagnosis 292
Management 292
Retroverted Gravid Uterus 293

Uterine Inversion 293
Acute Inversion 293
Prevention of Puerperal Inversion 294
Management 294
Chronic Inversion 295

27. Endoscopy in Gynecology 298
Rajesh Bhakta
Indications of Laparoscopic Surgery 298
Contraindications 298
Technique of Laparoscopy 301
Complications of Laparoscopy 302
Hysteroscopy 302

SECTION 2: REPRODUCTIVE ENDOCRINOLOGY AND ASSISTED CONCEPTION

28. Puberty 307
Vani Ramkumar
Physiology of Puberty 307
Factors Influencing Puberty 308
Definitions 308
Physical Changes of Puberty 309
Puberty in Boys 310
Psychologic Changes of Puberty 310
Problems Associated with Adolescence 310
Recent Trends 311

29. Disorders of Ovulation 312
Nuguelis Razali
Classification 312
History 314
Investigations 314
Management 315
Ovulation Induction 315

30. Polycystic Ovarian Syndrome 318
Pratap Kumar, Alok Sharma
Pathophysiology 318
Puberty and PCOS 319
Diagnosis 319
Approach to Infertility in a Patient with PCOS 320

31. Hirsutism 323
Muralidhar V Pai
Definition 323
Hypertrichosis 323
Pathophysiology 323

Etiology 324
Diagnosis 324
Treatment 325

32. Disorders of Sexual Differentiation and Development (Intersex) **328**
Muralidhar V Pai

Sexual Differentiation of the Fetus 328
Other Intersex Syndromes 334
Diagnosis of Intersex (Disorders of Sexual Development) 335
Management of Intersex 335
Gender Assignment 336

33. Infertility **337**
Prashant Nadkarni

Causes of Infertility 337
Assessment of the Infertile Couple 338
Investigation of the Infertile Couple 339
Treatment Options 340
Future Directions 341

34. Menopause and Hormone Therapy **343**
Premitha Damodaran

Endocrinology 345
Signs and Symptoms of Menopause 345
Early Menopausal Problems 345
Medium-Term problems 346
Late Menopausal Problems 347
Hormone Therapy Delivery Systems 351
Action of Estrogen 351
Prescribing Hormone Therapy 351
Hormone Therapy and Cancers 352
Ovarian Cancer 353
Colorectal Cancer 354
Lung Cancer 354
Hormone Therapy and Diabetes 354
Hormone Therapy and Gallbladder Disease 354
Other Effects of Hormone Replacement Therapy 355
Duration of Use 355
Recommendations 356

SECTION 3: GYNECOLOGIC ONCOLOGY

35. Gynecological Cancer Screening **363**
V Sivanesaratnam

Cervical Cancer 364
Ovarian Cancer 368
Endometrial Cancer 369

36. Preinvasive and Invasive Cancer of the Cervix **372**
V Sivanesaratnam
Preinvasive Lesions of the Cervix *373*
Adenocarcinoma in situ *377*
Invasive Carcinoma of the Cervix *377*

37. Ovarian Cancer **383**
V Sivanesaratnam, Lim Boon Kiong
Epidemiology *383*
Anatomy *384*
Etiological Factors *384*
Screening for Ovarian Cancer *385*
Prevention of Ovarian Cancer *385*
Classification of Ovarian Neoplasms *385*
Diagnosis *386*
Examination *387*
Preoperative Evaluation *387*
Stages of Ovarian Cancer *387*
Treatment of Ovarian Carcinoma *388*

38. Uterine Malignancy **393**
Christina Portelli, Tim Duncan
Epidemiology and Risk Factors *394*
Histopathology *394*
Leiomyosarcoma *395*
Patterns of Spread *396*
Risk Factors *396*
Clinical Features *396*
Diagnosis and Investigations *397*
Revised FIGO Staging 2009 *397*
Prognostic Factors *398*
Management *398*

39. Vulvar Cancer **401**
V Sivanesaratnam
Etiology *401*
Squamous Cell Carcinoma *402*
Diagnosis *403*
Pattern of Spread *403*
Management *404*
Special Situations *405*
Lymphatic Mapping *407*
Other Vulvar Malignancies *407*

40. Gestational Trophoblastic Neoplasia **411**
V Sivanesaratnam
Hydatidiform Mole *412*
Prophylaxis Against Choriocarcinoma *414*

Placental Site Trophoblastic Tumor 415
Epithelioid Trophoblastic Tumor 415
Choriocarcinoma 415

41. Radiotherapy and Systemic Anticancer Therapy in Gynecological Malignancy **421**
Robert Wade

Radiotherapy 421
Systemic Anticancer Cancer Therapy 422
Oncological Treatment of Specific Cancers 423
Cervical Cancer 423
Endometrial Cancer 424
Ovarian Cancer 424
Vulval Cancer 425
Vaginal Cancer 425
Trophoblastic Tumors 425

42. Palliative Care **426**
Claire Stewart, Onnig Tamizian

Symptom Management 426

Index ***437***

CHAPTER 2

Disorders of the Development of Müllerian System

Pratap Kumar, Sapna Vinit Amin

Overview

- Development of genital system is interesting and intricating.
- The etiology of this developmental abnormality, though not very clear, is controlled by genetic, hormonal and environmental factors.
- Müllerian duct fusion defect causes different kinds of uterus like the bicornuate uterus, unicornuate uterus, etc. The defective resorption may lead to septae.
- Absence of vagina or complete septa in the vagina can lead to collection of blood beyond causing hematocolpos. Uterus also may be totally absent.
- Surgical correction may be as simple as cruciate incision for hematocolpos to complex one done for vaginoplasty and corrective surgery for obstetric indications, is rarely required.
- Müllerian anomalies are second most common cause for primary amenorrhea, next only to Turner's syndrome.
- Functionally urogenital systems are two different components, however embryologically and anatomically they are intimately interconnected. Hence may be associated with renal anomalies in 20–30% of cases or vice versa.
- Various surgical and nonsurgical procedures are available to reconstruct vagina when there is absence of the same.

ANOMALIES OF THE FEMALE REPRODUCTIVE TRACT

Female genital tract anomalies incidence:1–3% of the female population, and 5% of infertile women.

Anomalies of the female reproductive tract can result from agenesis or hypoplasia, fusion and/or canalization defects, duplication abnormalities, or failure of resorption, resulting in septa.

Arrest in the normal development of the Müllerian ducts can cause several anomalies:

1. Aplasia— in which the organs fail to develop.
2. Hypoplasia—in which the organs are rudimentary.
3. Atresia—in which there is partial or complete failure of canalization of these ducts leading to varying degrees of gynatresia.
4. Müllerian duct anomalies like:
   - Unicornuate uterus (asymmetrical development) (Fig. 2.1) with or without rudimentary horn.

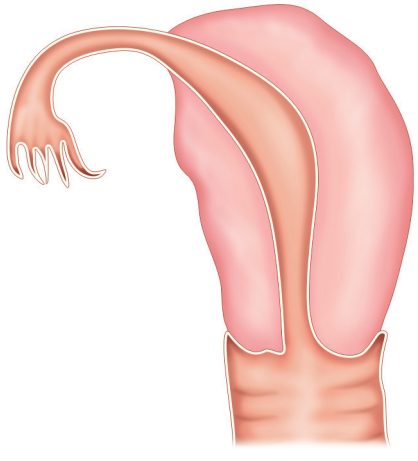

Fig. 2.1: Unicornuate uterus.

   - Failure of fusion in part or whole may lead to duplication of the genital tract uterus didelphys (two separate uterus, two cervix; or a bicornuate uterus

JAYPEE BROTHERS

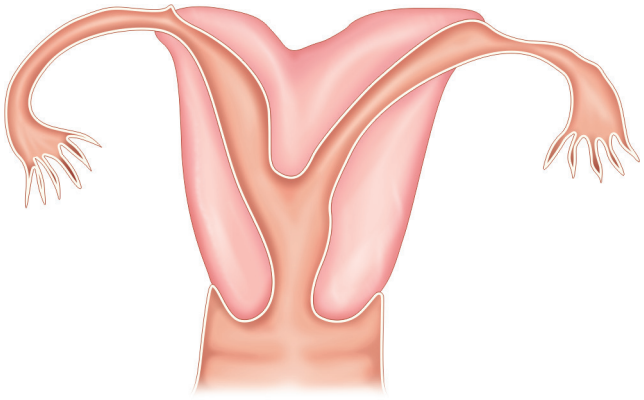

Fig. 2.2: Bicornuate uterus.

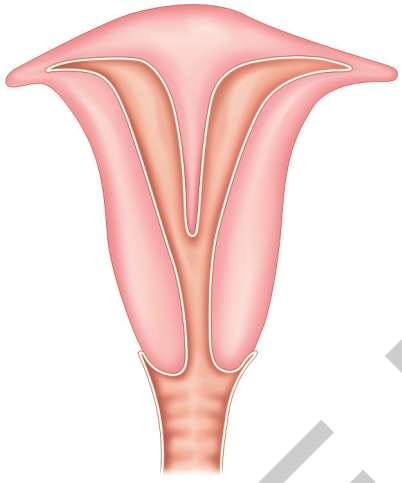

Fig. 2.3: Uterus subseptus.

(Fig. 2.2). When the Müllerian ducts incompletely fuse at the level of the uterine fundus, a bicornuate uterus is formed. In this anomaly, the lower uterus and cervix are completely fused, resulting in 2 separate but communicating endometrial cavities with a single-chamber cervix and vagina. Failure of disappearance of the intervening septum leads to septate or subseptate uterus (Fig. 2.3).

- Failure of vaginal recanalization of vagina leads to absence of vagina/imperforate hymen.

Classification

Mullerian anomalies have been classified in various ways.

- Jones classification
  - Agenesis/Aplasia: Agenesis of vagina, cervix, uterus, or of the complete reproductive tract
- Fusion, canalization and resorption of septum abnormalities (vertical and lateral fusion defects)

Table 2.1: Classification of Müllerian anomalies according to American Society for Reproductive Medicine (American Fertility Society, 1988).

I. Segmental Müllerian hypoplasia or agenesis a. Vaginal b. Cervical c. Uterine d. Tubal e. Combined
II. Unicornuate uterus a. Rudimentary horn with cavity, communicating to unicornuate uterus b. Rudimentary horn with cavity, not communicating to unicornuate uterus c. Rudimentary horn with no cavity d. Unicornuate uterus without a rudimentary horn
III. Uterine didelphys
IV. Bicornuate uterus a. Complete bifurcation (bicollis) b. Partial bifurcation (unicollis)
V. Septate uterus a. Complete septation b. Partial septation
VI. Arcuate uterus
VII. Diethylstilbestrol- related anomalies (1938–1975)

Clinical Problems (General)

- Gynecological
  - Primary amenorrhea
  - Out-flow tract obstruction
  - Dysmenorrhea
  - Infertility
  - Endometriosis.
- Obstetric: 5–10% in women with recurrent miscarriages
  - Recurrent pregnancy loss (mid trimester)
  - Rupture of rudimentary horn
  - Preterm labor.
- Malpresentations (breech, transverse lie)
- Fetal growth restriction
- Dystocia
- Ruptured uterus
- Operative delivery
- Retained placenta
- Postpartum hemorrhage
- Subinvolution of the uterus.

Problems connected to each of the anomalies can be as follows:

1. **Ovary:** Ovarian absence is called as ovarian agenesis/dysgenesis and this leads to Turner's syndrome (chromosomes will be 45XO) and this will present a primary amenorrhea, and has special characters like short stature web neck.

JAYPEE BROTHERS

2. **Uterus:** Uterine anomalies described above usually does not cause problems. However, in obstetrics, it may cause increased incidence of abortions, preterm labors, malpresentations.
3. **Vagina:** Noncanalization of vagina leads to crypto menorrhea (hidden menses) and may present during adolescent age as primary amenorrhea. There will be cyclical pain (because of menses which is collected above the noncanalized vagina). If there is only imperforate hymen then the bulge is at the exterior. At this stage, there can be retention of urine also along with primary amenorrhea.

Diagnosis in Infancy or Childhood

Occasionally, diagnosis is possible in infancy. The infant may present with a bulging yellow-gray mass at or beyond the introitus. The presence of an abdominal mass can occur in association with urinary obstruction.

Diagnosis in utero can be done with obstetric ultrasonography. Ultrasonography is an essential first step in diagnosis.

Hymenal Obstruction

Usually, the problems are seen only at puberty when they present with primary amenorrhea. Unfortunately, the typical findings at diagnosis include a large collection of blood within the uterus (hematometra) and an even larger collection of blood within the distensible vagina (hematocolpos) (Fig. 2.4). Additional findings may include blood-filled fallopian tubes (hematosalpinges) and signs of retrograde menses, occasionally to the point of the development of intra-abdominal endometriosis and severe adhesions. An imperforate hymen must be corrected surgically. Surgical decision-making should focus on appropriate diagnosis and timing of surgical repair.

- Pelvic and abdominal ultrasound/MRI
  - A pelvic ultrasound is the essential initial diagnostic test to confirm, and a transabdominal route is needed. Renal anomalies should be ruled out when other Müllerian defects of the uterus and vagina are suspected
  - Pelvic and abdominal MRI: If the diagnosis of imperforate hymen is not absolutely certain based on physical examination or pelvic ultrasound findings, MRI is indicated to clearly define the anatomy prior to any planned surgical procedure.

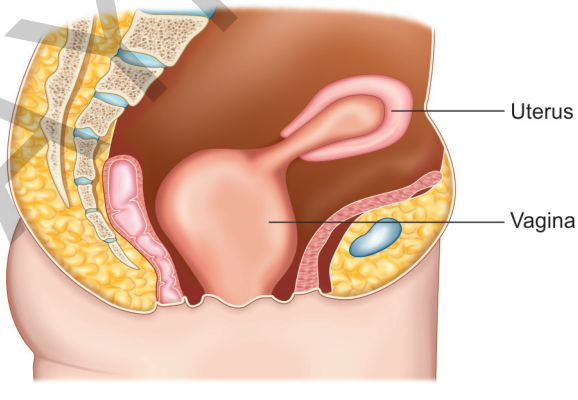

Fig. 2.4: Hematocolpos (distended vagina filled with blood).

Surgical Procedure for Imperforate Hymen

A cruciate incision along the diagonal diameters of the hymen, rather than anterior to posterior, avoids injury to the urethra directly anteriorly and can be enlarged by removal of excess hymenal tissue. In either approach, the vaginal epithelium then is sutured to the hymenal ring using interrupted stitches with fine absorbable suture (e.g. 4-0 polyglycolic acid suture). The application of 2% lidocaine jelly to the suture line to provide postoperative analgesia is suggested.

Aspiration or puncture of the mucocolpos or hematocolpos without definitive enlargement of the vaginal orifice should be avoided because a pyocolpos or ascending infection may develop. Pelvic examination should not be done since it will cause ascending infection.

Surgical Management of Vaginal Agenesis

Surgical and nonsurgical methods of treatment have been utilized. The nonsurgical approach relies on the use of graduated dilators (Frank's dilation) and may take several months or a few years before a functional vagina is formed. Surgery remains the most effective method of treatment for vaginal agenesis.

Choosing the proper time to perform a vaginoplasty is of paramount importance. Surgical treatment should be considered only when the patient wishes to become sexually active and is highly motivated to use a vaginal prosthesis for several months postoperatively.[1]

Preoperative Evaluation

Routine preoperative evaluation should include an intravenous pyelogram (IVP) and renal ultrasound to exclude urinary tract anomalies. Discovery of a pelvic kidney is important in planning corrective surgery since its presence may limit the amount of potential space.

Surgical Techniques for Vaginal Agenesis

McIndoe operation: The aim of surgical treatment is to create a neovagina. The modified McIndoe's procedure remains the most common surgical approach to vaginoplasty for vaginal agenesis. Obtaining a satisfactory

JAYPEE BROTHERS

split-thickness graft is one of the most important steps in performing the modified McIndoe's procedure. A space is created between the bladder and the rectum.

- **Prosthesis assembly:** The stent should be made from material that can maintain patency of the vaginal cavity. A foam rubber form measuring 10 cm by 2 cm works well. The prosthetic device is sterilized, and the size is customized to fit the patient's vagina. The prosthetic material is cut to twice the desired size of the vagina, folded in half, and compressed by the placement of 2 condoms over the surface. The condoms are tied at the open end.
- **Graft attachment to prosthesis:** The skin graft is placed over the stent, dermal aspect out, and sutured over the form using 5-0 synthetic absorbable sutures. The graft-covered prosthesis is carefully inserted into the vaginal canal. The edges of the graft are sutured to the previously cut edges of the mucosal margins of the vaginal introitus. This contact is often adequate, rendering sutures unnecessary. If the contact between the graft and the vaginal space is too tight, serum may collect and compromise the engraftment. The labia minora are sutured around the stent using nonreactive sutures.

Patient education regarding the importance of continuous, prolonged dilatation as well as stent care during the healing phase is essential. The foam is worn continuously for 6 weeks and is removed only for urination and defecation. Low-pressure douches with warm water are performed daily. At the same time, the form is cleaned with a povidone-iodine solution, covered with a fresh condom, lubricated, and reintroduced into the neovagina. After 6 weeks, a silicone form that is inserted nightly for the next 12 months replaces the original stent. In most cases, the vagina is functional 6–10 weeks postoperatively.[2,3]

Williams vulvovaginoplasty is an alternative to the McIndoe procedure. This procedure is particularly useful for patients with previously failed vaginoplasty. It utilizes full-thickness skin flaps from the labia majora to create a vaginal pouch. Unlike the McIndoe procedure, vaginal dilation is required for only 3–4 weeks. The vagina created by this approach is not anatomically similar to a normal vagina or the neovagina created by the McIndoe procedure. Instead, the vaginal pouch axis is directly posterior and horizontal to the perineum; however, the vagina is functional and well-received by patients. Fistula formation, which can occur with the McIndoe procedure, is rare.[4]

Sigmoid vaginoplasty in which sigmoid colon is used to create neovagina, is another operative option. It provides good vaginal length, adequate secretion allowing lubrication, less incidence of vaginal stenosis, also does not need prolonged neovaginal dilatation. More importantly has short recovery time with good patient satisfaction.

In the recent decades, novel vaginoplasty techniques like Vecchietti and Davydov procedures are becoming popular (both open and laparoscopic techniques).[5]

Uterus Didelphys, Nonobstructed (Fig. 2.5)

Women with nonobstructed didelphys uterus usually are not candidates for surgical unification. The decision to perform metroplasty should be individualized, and only selected patients may benefit from surgical reconstruction. Metroplasty using the Strassman procedure[6] deals with the method of unification of the uterine cavities at the fundus while the cervices are left intact. This is not done in modern gynecology, since unification was causing higher incidence of rupture of uterus during subsequent pregnancy. Rarely, they can present with double uterus and double vagina (Fig. 2.6).

Bicornuate Uterus

Bicornuate uterus is considered an incidental finding. Patients usually have no difficulty becoming pregnant and usually do not have much of obstetrical problem except rarely it may be the cause of preterm labor. At times they have one rudimentary horn (Fig. 2.7).

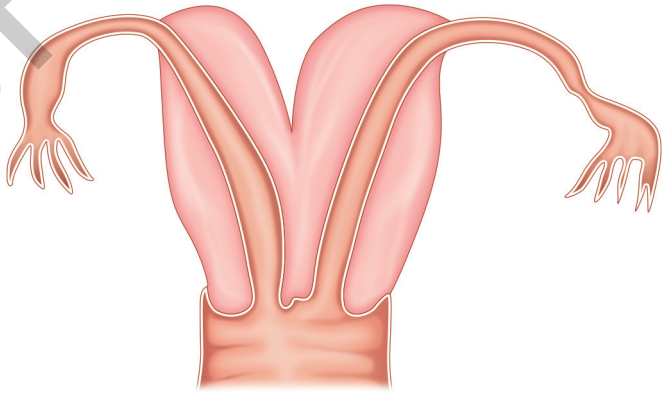

Fig. 2.5: Double uterus with single vagina.

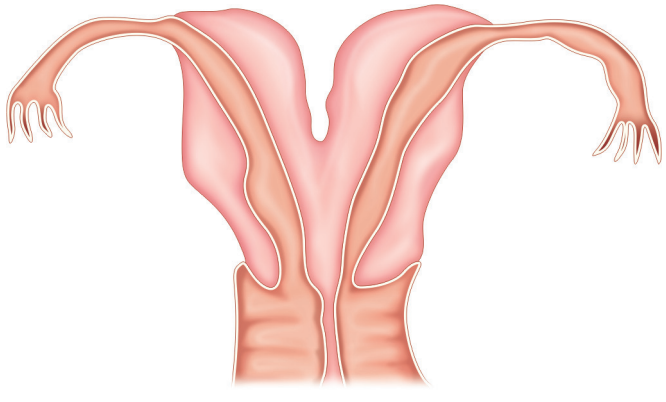

Fig. 2.6: Double uterus with double vagina.

JAYPEE BROTHERS

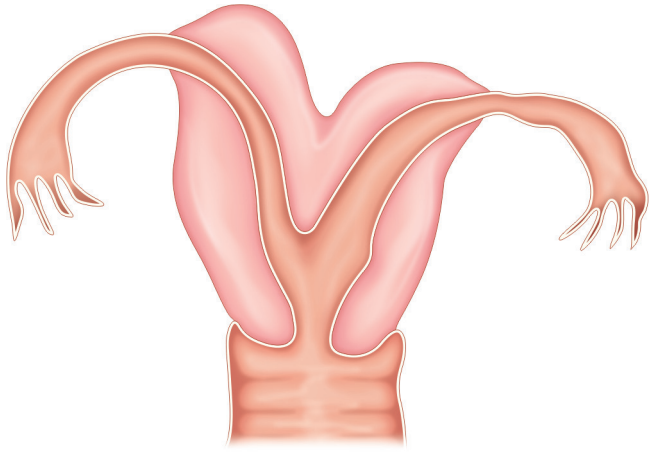

Fig. 2.7: Bicornuate uterus with rudimentary left horn.

Surgical Techniques for Bicornuate Uterus

Although, a number of metroplasty procedures are available, the Strassman procedure was the surgical treatment of choice for bicornuate uterus and didelphys uterus. This approach involves the removal of the septum by wedge resection with subsequent unification of the 2 cavities. Since, it causes a weak uterus, this procedure is not recommended in recent times.

Septate Uterus (Fig. 2.3)

The septum is considered complete if it extends to the internal os, thus dividing the endometrial cavity, and partial if it does not. In addition, septa may be segmental, which results in partial communication between the endometrial cavities. Although, fertility does not appear to be significantly compromised its presence alone is not an indication for surgery.

Transvaginal ultrasound is a useful aid in diagnosing septate uterus, with one study demonstrating a sensitivity of 100% and a specificity of 80%.[7]

Surgical Management of Septate Uterus

Surgical techniques: As the surgical procedure of choice, transabdominal Tompkin's metroplasty has been replaced by operative hysteroscopy. Currently, surgical correction of septate uterus is rendered through hysteroscopic division of the septum.[8–10] The surgical approach utilizes concurrent laparoscopy and hysteroscopy. Laparoscopy is essential to the success of the surgery; it helps confirm the diagnosis of septate uterus as opposed to bicornuate uterus, and it helps reduce the risk of uterine perforation during septal incision.[9,10]

Postoperative Management

Postoperative placement of a Lippes Loop intrauterine device for a month is controversial.[9] Some think that it may prevent intrauterine adhesion formation, while others maintain that this procedure is unnecessary and may provoke local inflammation with subsequent synechiae.[11] Currently, no unanimity exists for this practice.

Conjugated estrogens (1.25 mg/d for 25 days) and progesterone (10 mg/d added on days 21–25) are frequently prescribed postoperatively to assist epithelialization. At present, there is no consensus on this practice. Some experts believe that hormonal therapy has not been proven necessary and can often be withheld.[12]

A 1 month postoperative follow-up examination is recommended. Either hysteroscopy or hysterosalpingography can be performed to assess the uterine cavity. Ultrasound can also be performed.

The risk of pelvic adhesions is limited, and recovery is rapid with no prolonged postoperative delay in conception. Hysteroscopic metroplasty allows vaginal delivery, obviating the need for subsequent cesarean section as was recommended using the transabdominal approach.

CONCLUSION

Müllerian duct anomalies are a morphologically diverse group of congenital disorders involving the female reproductive tract.[13] Establishing an accurate diagnosis is essential for patient management and planning treatment strategies. Uterine shape or anomalies do not require active measures of surgery most often, except for the wide uterine septum. Vaginal reconstruction operations have a place in those whose vagina is absent.

REFERENCES

1. Coney P. Effect of vaginal agenesis on the adolescent: prognosis for normal sexual and psychological adjustment. Adolesc Pediatr Gynecol. 1992; 5:8.
2. Rock JA. Surgery for anomalies of the müllerian ducts. In: Thompson JD, Rock JA (Eds). Telinde's Operative Gynecology, 7th ed. Philadelphia: JB Lippincott; 1992:603-46.
3. Mc Indoe. The treatment of congenital absence and obliterative condition of the vagina. Br J Plast Surg. 1950; 2:254-67.
4. Williams EA. Congenital absence of the vagina: a simple operation for its relief. J Obstet Gynecol Br Commonwealth. 1964; 71:511.

JAYPEE BROTHERS

5. Ismail IS, Cutner AS, Creighton SM. Laparoscopic vaginoplasty: alternative techniques in vaginal reconstruction. BJOG. 2006; 113:340-3.
6. Strassman EO. Fertility and unification of the pregnant uterus. Fertil Steril. 1966; 17:165.
7. Pellerito JS, McCarthy SM, Doyle MB. Diagnosis of uterine anomalies: relative accuracy of MR imaging, endovaginal sonography, and hysterosalpingography. Radiology. 1992; 183(3): 795-800.
8. DeCherney AH, Russell JB, Graebe RA. Resectoscopic management of mullerian fusion defects. Fertil Steril. 1986; 45(5):726-28.
9. Donnez J, Nisolle M. Hysteroscopic surgery. Curr Opin Obstet Gynecol. 1992; 4(3):439-46.
10. Israel R, March CM. Hysteroscopic incision of the septate uterus. Am J Obstet Gynecol. 1984; 149(1):66-73.
11. Vercellini P, Fedele L, Arcaini L. Value of intrauterine device insertion and estrogen administration after hysteroscopic metroplasty. J Reprod Med. 1989; 34(7):447-50.
12. Propst AM, Hill JA 3rd. Anatomic factors associated with recurrent pregnancy loss. Semin Reprod Med. 2000; 18(4): 341-50.
13. ESHRE Mullerian duct anomalies classification 2013, Hum Reprod. 2013 Oxford university Press.

JAYPEE BROTHERS

for detailed information on obstetrics & gynecology books, visit our website **www.jaypeebrothers.com,** for detailed informa

Essentials of GYNECOLOGY

Salient Features

- This multi-authored book, where each chapter has been written by well-recognized experienced professionals well known nationally and internationally
- Contains 42 chapters and covers from the basic embryology, anatomy, physiology and extends to inflammatory conditions and benign and malignant lesions. Psychosomatic gynecology, operative procedures, contraception, breast diseases and other important areas are also covered
- Each chapter is well illustrated and easy to read
- Covers entire spectrum of gynecology and hence little additional reading is required by the students.

Sabaratnam Arulkumaran DCH FRCS FRCOG FAMS MD PhD Hon FACOG FSLCOG FSOGC is Emeritus Professor, Department of Obstetrics and Gynecology, St George's University of London, London, United Kingdom. He was former President of the International Federation of Gynecology and Obstetrics—FIGO (2012–2015); the British Medical Association (2013–2014), and Royal College of Obstetricians and Gynaecologists (2007–2010). He is the author/editor of 28 books. He is a Knight Bachelor in Recognition of Services to Medicine and Health Services by Her Majesty the Queen's Birthday Honours List—June 2009.

V Sivanesaratnam MBBS (S'pore) FRCOG FICS FACS FAMM FAOFOG is Emeritus Professor, Department of Obstetrics and Gynecology, University of Malaya, Kuala Lumpur, Malaysia. Formerly, he was Professor (Chair), Head and Senior Consultant, Department of Obstetrics and Gynecology, University of Malaya. Currently, he is Consultant Gynecologist/Gynecologic Oncologist at University of Malaya Specialist Centre, Kuala Lumpur. He has published extensively on various aspects of obstetrics and gynecology in refereed journals, including chapters in several textbooks. He has extensive experience in managing various gynecological and oncological problems. He was the Past President of the Asia and Oceania Federation of Obstetrics and Gynecology.

Alokendu Chatterjee FRCOG FICS was formerly Head, Department of Obstetrics and Gynecology, NRS Medical College and Hospital, Kolkata, West Bengal, India; Member, National Human Rights Commission (Health), India; International Examiner of MRCOG; President, SAFOG (2013–2015) and FOGSI (1999–2000); Chairman, AICC RCOG (2004–2009), and Vice-President, National Board of Examination (2004–2009).

Pratap Kumar MD DNB is Professor, Department of Obstetrics and Gynecology, Kasturba Medical College, Manipal University, Manipal, Karnataka, India. He is Head, Division of Reproductive Medicine, Manipal University, Manipal. He was National Vice-President of the Federation of Obstetrics and Gynecology for the year 1999. He is the editor of 12 books. He has more than 250 publications and presented more than 500 presentations in national and international congresses. He was President, Karnataka State Obstetric and Gynecological Societies of FOGSI (2011–2012) and awarded Dr Kutty Lifetime Achievement Award for 2011–2012.

Available at all medical bookstores
or buy online at www.jaypeebrothers.com

JAYPEE BROTHERS
Medical Publishers (P) Ltd.
www.jaypeebrothers.com

Join us on facebook.com/JaypeeMedicalPublishers

Shelving Recommendation
OBSTETRICS & GYNECOLOGY

ISBN 978-93-86261-69-4