pathology books, visit our website **www.jaypeebrothers.com,** for detailed information on pathology bo

CASE-BASED APPROACH IN EXFOLIATIVE CYTOLOGY

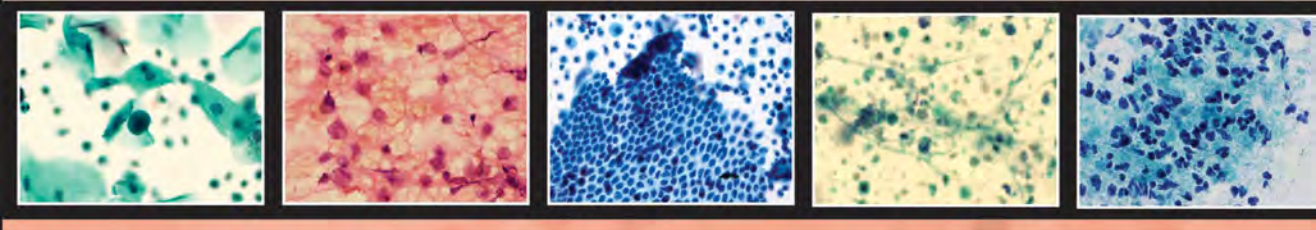

PRANAB DEY

JAYPEE

CONTENTS

1. General Cytology **1**

2. Cervical Cytology **31**

3. Effusion Cytology **124**

4. Respiratory Cytology **188**

5. Gastrointestinal Tract **241**

6. Urine Cytology **264**

7. Cerebrospinal Fluid **300**

8. Miscellaneous Areas **316**

Index *361*

CHAPTER 4

Respiratory Cytology

JAYPEE BROTHERS

Introduction

The cytological examination of the respiratory tract is very helpful in the detection of both infective organisms and various neoplastic lesions. Carcinoma of the lung is the most common cancer in the world. The common complaints of the patient are progressive shortness of breath, chest pain, cough, dyspnea, and hemoptysis. World Health Organization (WHO) classified lung cancer as mentioned in the Box 4.1.[1]

Box 4.1: WHO classification of lung tumors, 2015[1]

- Epithelial tumors
  - Adenocarcinoma
    - Lepidic adenocarcinoma
    - Acinar adenocarcinoma
    - Papillary adenocarcinoma
    - Solid adenocarcinoma
    - Invasive mucinous adenocarcinoma
    - Minimally invasive adenocarcinoma
    - Colloid adenocarcinoma
  - Squamous cell carcinoma
    - Keratinizing squamous cell carcinoma
    - Nonkeratinizing squamous cell carcinoma
    - Basaloid squamous cell carcinoma
  - Neuroendocrine tumors
    - Small cell carcinoma
    - Large cell neuroendocrine carcinoma
    - Carcinoid tumors
    - Typical carcinoid
    - Atypical carcinoid
  - Large cell carcinoma
  - Adenosquamous carcinoma
  - Pleomorphic carcinoma
  - Giant cell carcinoma
  - Carcinosarcoma
  - Pulmonary blastoma

Contd...

Contd...

- Salivary gland type tumor
  - Adenoid cystic carcinoma
  - Mucoepidermoid carcinoma
  - Pleomorphic adenoma
- Papillomas: Squamous cell papilloma and glandular papilloma

- Mesenchymal tumor
- Lymphohistiocytic tumor
- Tumors of ectopic origin
- Metastatic tumors

Squamous Cell Carcinoma[2]

The tumor shows polyhedral cells with eosinophilic cytoplasm. Cytoplasmic orangeophilia indicates intracellular keratin. The nuclei are round, hyperchromatic and moderately pleomorphic. Many fiber cells and tadpole cells are also seen. The tumor often shows background necrosis and granular debris.

Immunocytochemistry

Positive for CK 5/6, p40 and p 63. The tumor cells are negative for TTF and napsin and CK 7.

Genetic Profile

Squamous cell carcinoma shows gene amplification of the following chromosomes

- 3q : SOX2, TP 63
- 7p: EGFR

The frequent gene mutations are seen in: TP 53, CDKN2A, and PTEN.

Adenocarcinoma[2]

Adenocarcinomas of the lung are the most common subtype in females. The various subtypes of adenocarcinoma includes: Lepidic adenocarcinoma, acinar adenocarcinoma, papillary adenocarcinoma, solid adenocarcinoma, invasive mucinous adenocarcinoma, minimally invasive adenocarcinoma and colloid adenocarcinoma. The cytological features of adenocarcinoma depend on the subtypes. Overall, the cells show glandular or acinar arrangement along with honeycomb like sheets and discrete cells. Many three-dimensional cell balls of malignant cells are also seen. The background mucinous material may also be noted in a small number of cases. The cytoplasm of the cell is moderate to abundant and often contains large vacuoles filled with mucin. Large vacuoles may push the nucleus to the periphery of the cell causing indented margin of the nucleus. The nuclei are vesicular having prominent nucleoli.

Immunocytochemistry

Adenocarcinomas of lungs are positive for CK 7, napsin A, and TTF-1. The tumor cells are negative for p40, p63 and CK 5/6.

Genetic Profile

- Epidermal growth factor receptor (EGFR) mutation: Point mutation of codon 858 and in frame deletions in exon 19 (90% cases) are seen. EGFR mutation is specific for adenocarcinoma

JAYPEE BROTHERS

and it also acts as a prognostic factor. It is a predictor of response to EGFR tyrosine kinase inhibitor treatment. EGFR mutation is related with TTF-1 positivity.

- KRAS mutation
- Anaplastic lymphoma kinase (ALK) rearrangement: ALK rearrangement is predictive of response to ALK inhibitor treatment, however it is not a prognostic factor.

Small Cell Carcinoma[2]

Small cell carcinoma (SCC) accounts for 20% of lung cancer and 90% of these tumors are centrally located. SCC is classified as:

- Pure small cell carcinoma
- Combined small cell carcinoma with other carcinomas such as squamous cell carcinoma, adenocarcinoma, large cell carcinoma, etc.

The cytology smears of SCC show a predominant discrete population of the small round cells about one and half times larger than mature lymphocytes. The tumor cells show nuclear threading and crushing artifact due to the fragile nature of the cells. The nuclei are relatively monomorphic hyperchromatic with indistinct nucleoli. Nuclear molding is characteristic of small cell carcinoma.

Immunocytochemistry

The small cell carcinoma is positive for CD 56, chromogranin, synaptophysin, cytokeratin and TTF-1.

Carcinoid[2]

Carcinoid tumor is classified as (a) typical carcinoid and (b) atypical carcinoid.

Typical carcinoid: Cytology smears of the carcinoid tumor usually show dissociated cells. Occasional rosette like structures may be seen. Individual cells have small to moderate amount of cytoplasm with fine reddish granules. The nuclei are relatively monomorphic with finely stippled chromatin giving the characteristic salt and pepper appearance.

Atypical carcinoid: Cells of atypical carcinoid show large nuclei with moderate pleomorphism. The individual cells have moderate to abundant reddish granular cytoplasm.

Immunocytochemistry

Carcinoid tumors are positive for chromogranin A, synaptophysin and CD 56. The tumor cells are also positive for pancytokeratin. The carcinoid tumors are usually negative for TTF-1.

Large Cell Neuroendocrine Carcinoma

These tumors are difficult to recognize as they have overlapping cytological features with neuroendocrine tumors and adenocarcinomas. The cells are large with moderate amount of cytoplasm, monomorphic hyperchromatic nuclei having irregular nuclear margin and prominent nucleoli.

The differentiating features of SCC, typical and atypical carcinoid and large cell neuroendocrine carcinomas are highlighted in the Table 4.1.

JAYPEE BROTHERS

Table 4.1: Distinguishing features of various neuroendocrine tumors of lung

Features	*Small cell carcinoma*	*Carcinoid*	*Atypical carcinoid*	*Large cell neuroendocrine carcinoma*
Mitosis	High	High	Frequent	High
Necrosis	Present	No	Occasionally	Present
Nucleus	Hyperchromatic	Salt and pepper chromatin	Salt and pepper chromatin	Salt and pepper chromatin
TTF-1	Positive	Negative	Negative	Positive
CD 56	Positive	Positive	Positive	Positive
Chromogranin	Positive	Positive	Positive	Positive

Large Cell Anaplastic Tumor[2]

The large cell carcinoma (LCC) accounts for 10% of all lung carcinomas. These are undifferentiated large cell carcinomas without any particular evidence of differentiation towards squamous or adenocarcinoma. Majority of large cell carcinomas are located in the peripheral part of lung. WHO recommended that this specific entity should be labelled as non-small cell carcinoma, not otherwise specified on cytology smear. On cytology smear the tumor shows discrete and syncytial clusters of cells. No glandular differentiation is seen. The individual cells have moderate to abundant dense cytoplasm with ill-defined margins. Nuclei show marked pleomorphism, nuclear margin irregularity, irregular coarse chromatin and multiple enlarged prominent nucleoli. Many large mono/multinucleated tumor giant cells are also noted. The characteristic feature of large cell carcinoma is sticking of polymorphs with the malignant cells. Giant cell carcinoma is one of the varieties of the undifferentiated large cell carcinoma. Here, the smear shows many large multinuclear and mononuclear tumor giant cells along with heavy polymorphonuclear leucocytes infiltration.

References

1. Travis WD, Brambilla E, Burke AP, Marx A, Nicholson AG. WHO Classification of tumors of the lung, pleura, thymus and heart. Lyon: International Agency for Research on Cancer, 2015.
2. Dey P. Fine Needle Aspiration Cytology: Interpretation and Diagnostic Difficulties. Second Edition, Jaypee Brothers Medical Publishers (P) Ltd, New Delhi, 2014.

JAYPEE BROTHERS

QUESTIONS

Problem 4.1

Match the following (Fig. 4.1)

A	1. Hyperplastic bronchial cells
B	2. Curschmann's spiral
C	3. Ciliated columnar cells
D	4. Alveolar macrophages
E	5. Atypical cells

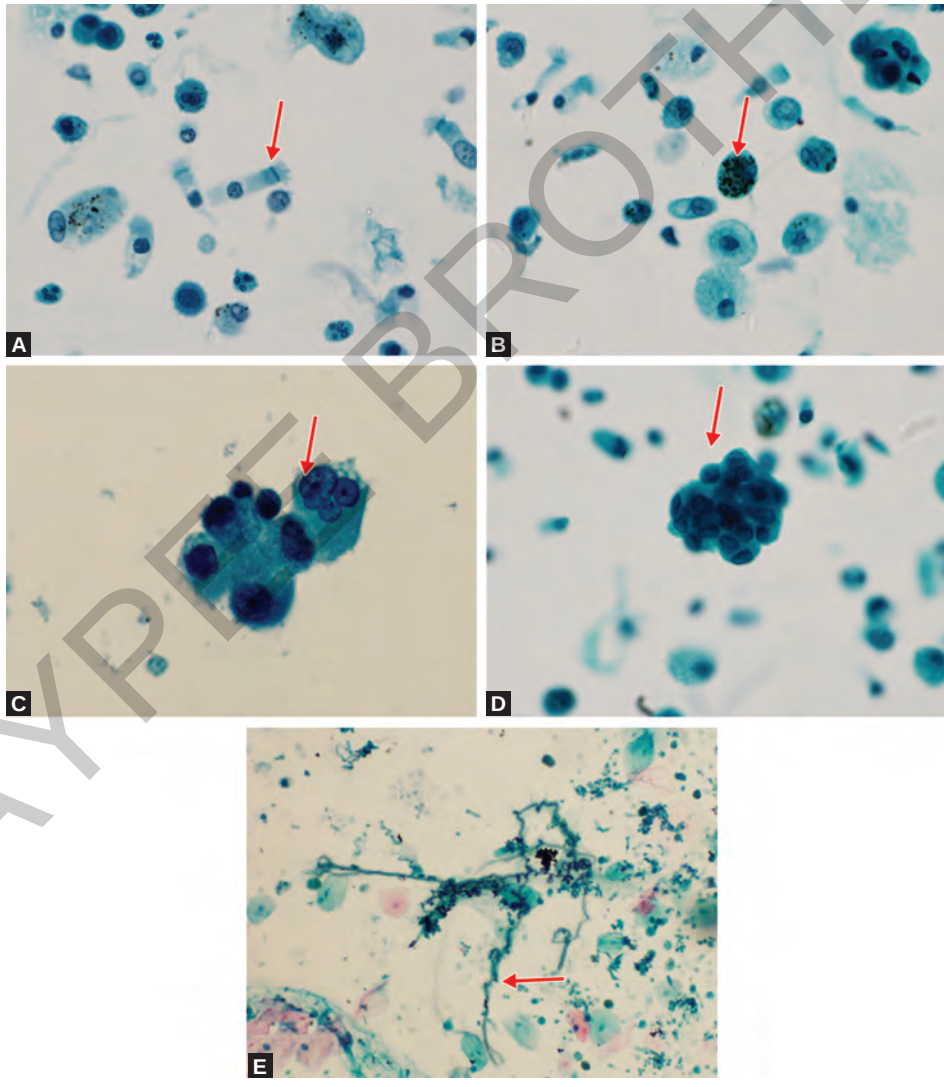

Figures 4.1A to E

JAYPEE BROTHERS

Problem 4.2

A 41-year-old female had cough, fever and chest pain for 3 months. She had pallor and loss of weight. Chest radiograph showed upper left lobe consolidation. Bronchoalveolar lavage cytology was done and the microphotographs of the SurePath preparation are displayed in the Figure 4.2. The most likely diagnosis is:

A. Squamous cell carcinoma
B. Reactive bronchial cells
C. Small cell carcinoma
D. Adenocarcinoma

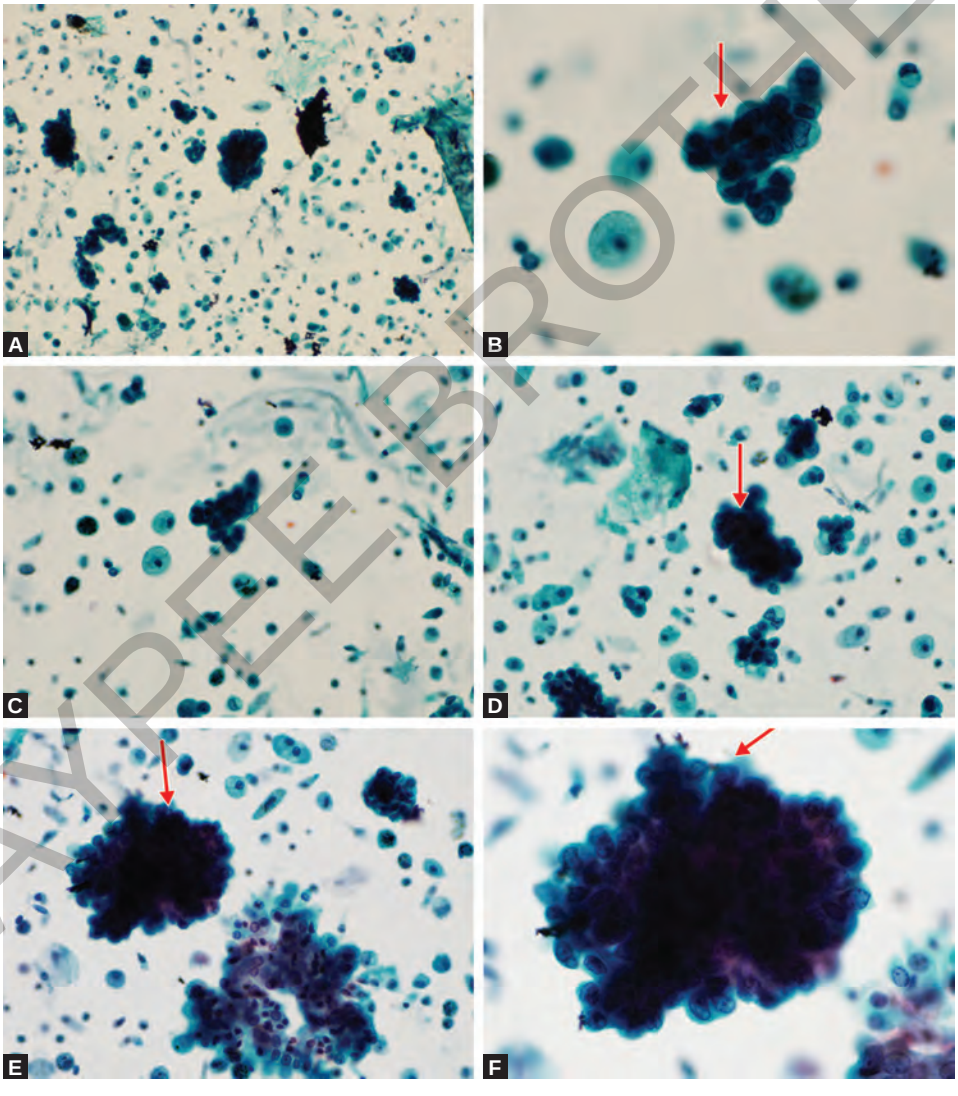

Figures 4.2A to F

JAYPEE BROTHERS

Problem 4.3

A 39-year-old male patient recipient of renal transplant patient presented with respiratory distress and lung consolidation. The most likely diagnosis from Figure 4.3 is:

A. Carcinoma
B. Viral infection
C. Aspergillosis
D. Acute inflammation

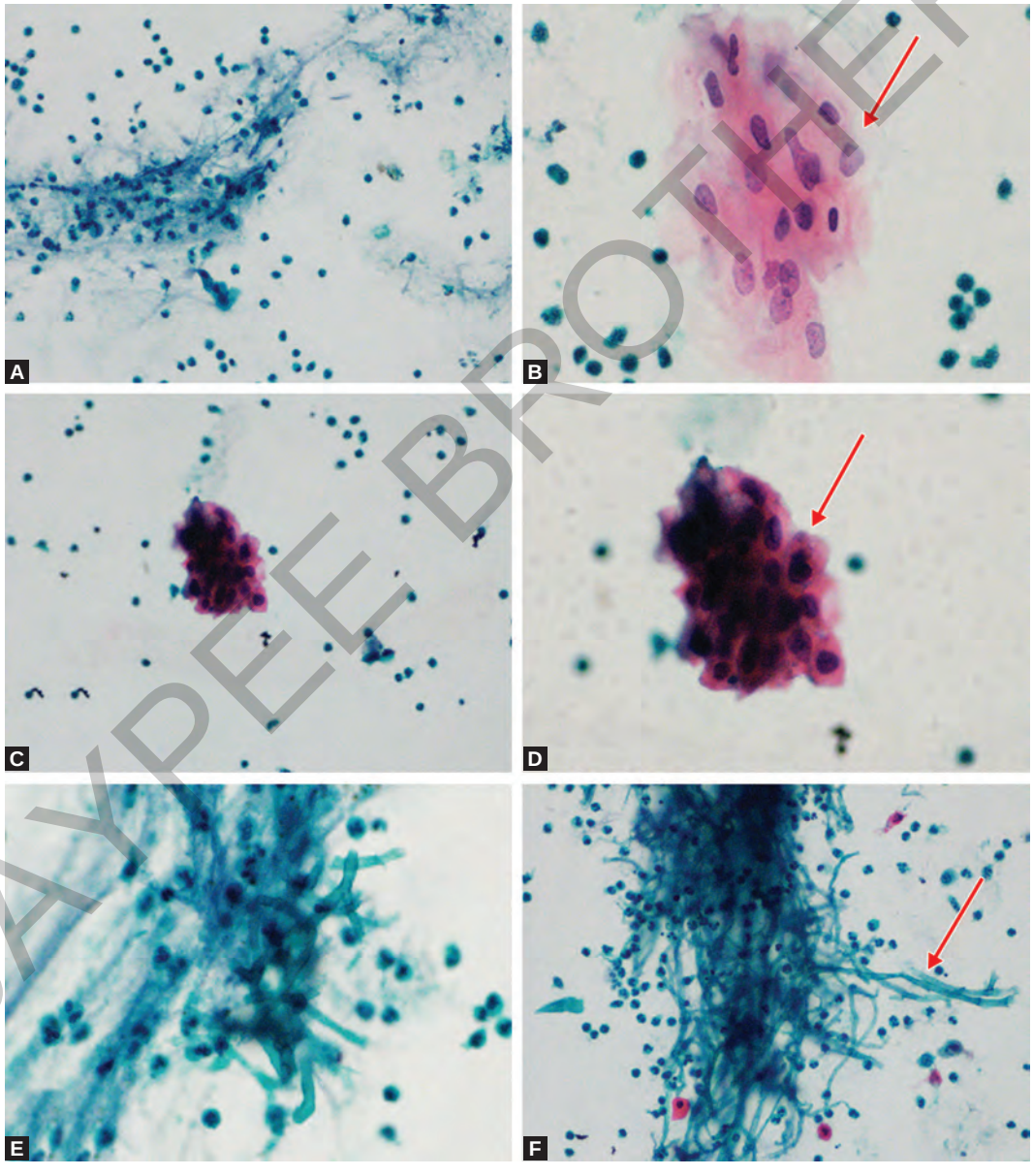

Figures 4.3A to F

JAYPEE BROTHERS

Problem 4.4

A 46-year-old male presented with cough, respiratory distress for 3 months. The bronchoalveolar lavage was done and microphotographs are shown in Figure 4.4. The most likely diagnosis is:

A. Adenocarcinoma
B. Hyperplastic bronchial cells
C. Squamous cell carcinoma
D. Small cell carcinoma

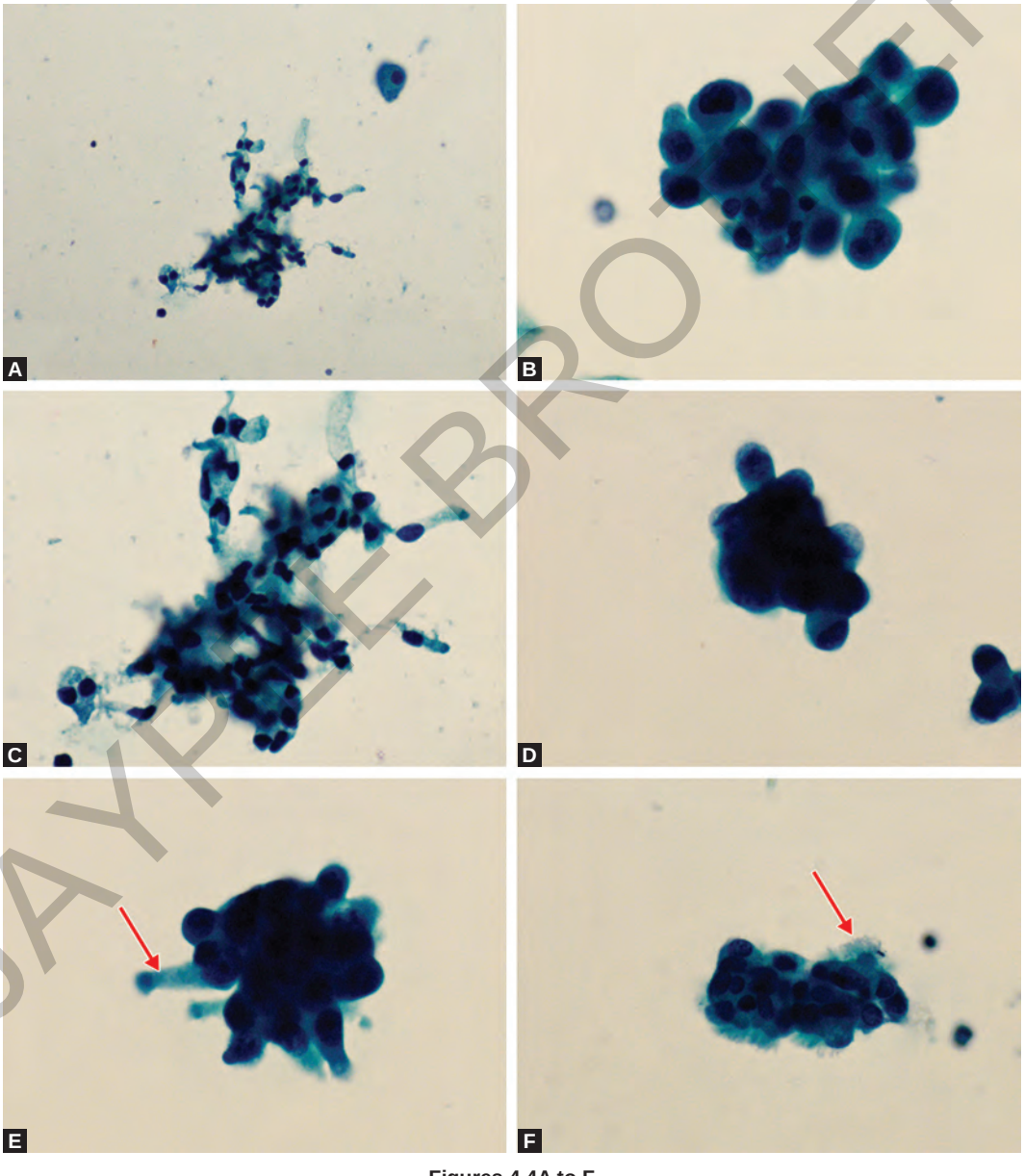

Figures 4.4A to F

JAYPEE BROTHERS

Problem 4.5

A 55-year-old male presented with dry cough, hemoptysis and chest pain for 3 months. Chest radiograph showed bilateral upper lobe ground glass opacities. His mediastinal lymph node was enlarged. Endoscopic ultrasound guided transbronchial needle aspiration (EUS TBNA) was done. The most likely diagnosis from Figure 4.5 is:

A. Granulomatous inflammation
B. Reactive lymphoid hyperplasia
C. Non-Hodgkin lymphoma
D. Small cell carcinoma

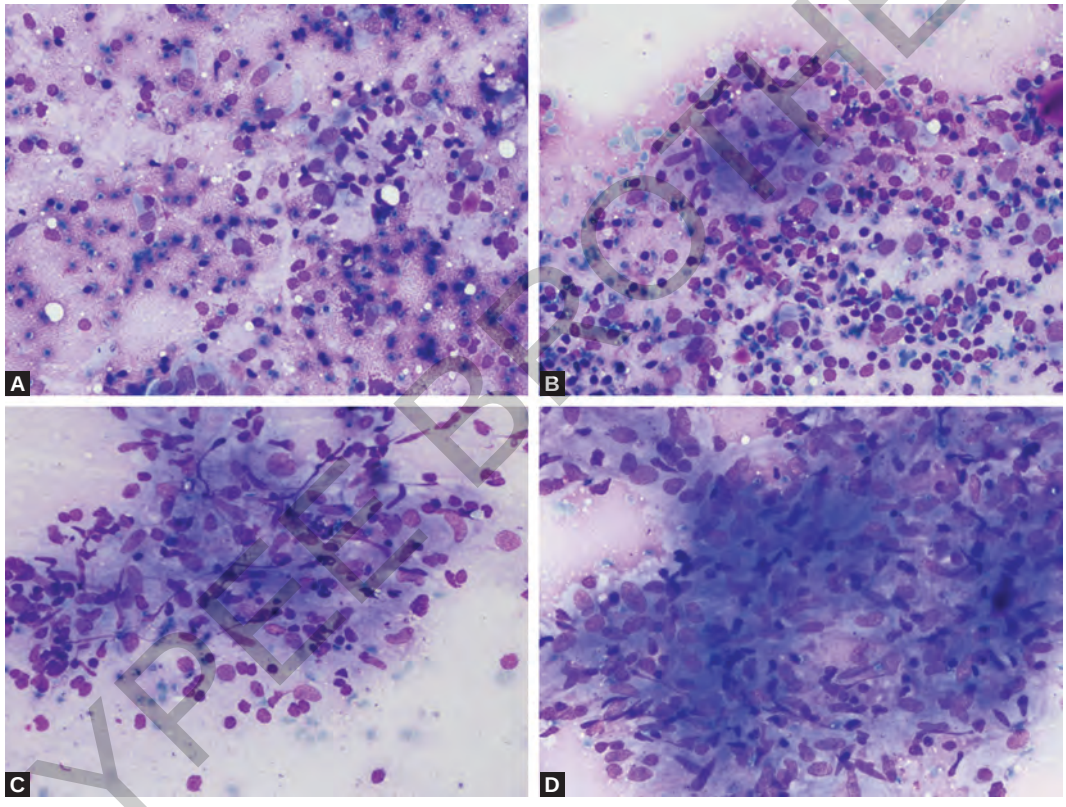

Figures 4.5A to D

JAYPEE BROTHERS

Problem 4.6

A 37-year-old female had renal transplantation 2 year back. Presently the patient developed fever, and jaundice along with pruritus for 4 months. On chest radiograph the patient had bilateral ground glass opacity. Her bronchoalveolar lavage (BAL) was done. The most likely diagnosis from Figure 4.6 is:

A. Herpes viral infection
B. No abnormality
C. CMV positive
D. Pneumocystis infection

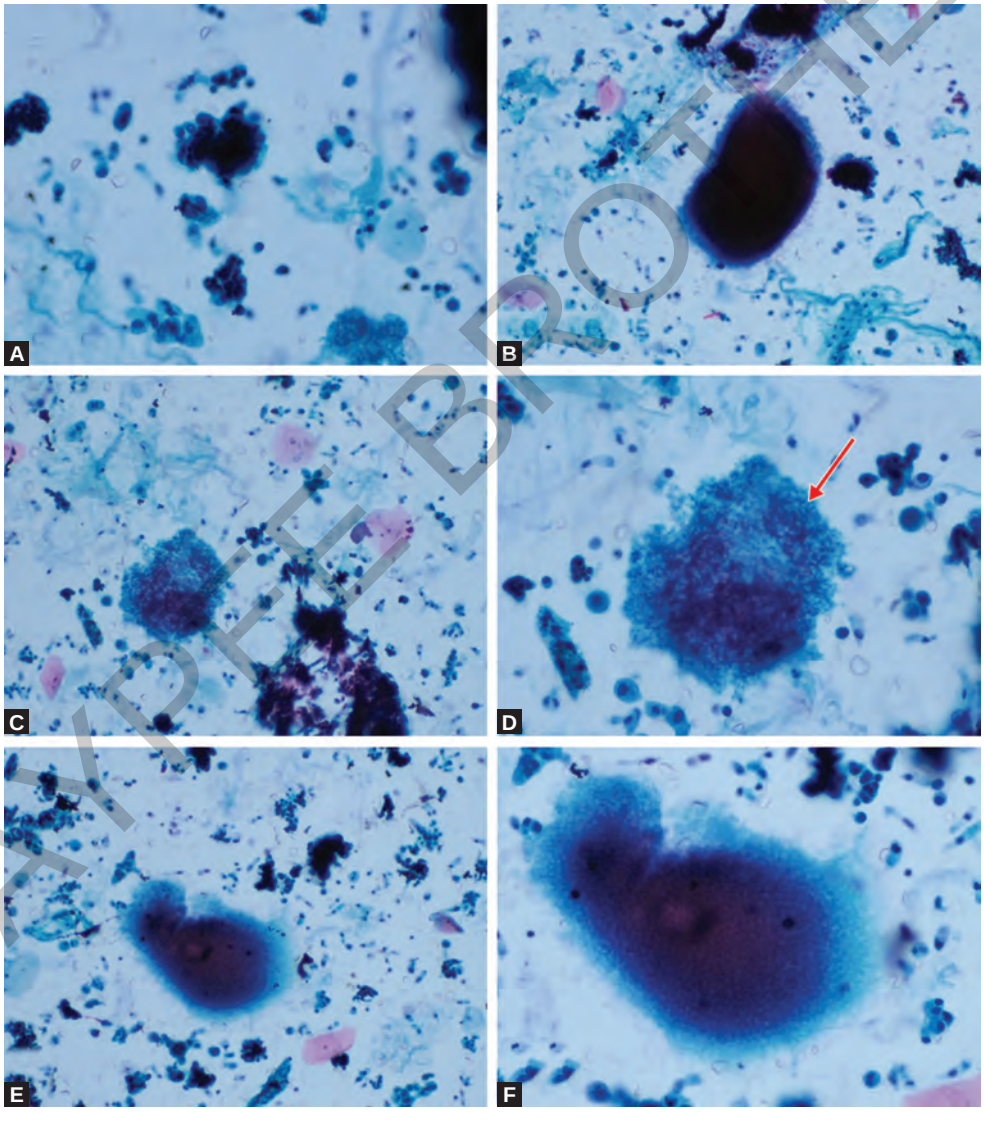

Figures 4.6A to F

JAYPEE BROTHERS

Problem 4.7

A 49-year-old male complaints of hemoptysis and chest pain for 2 months. His chest radiograph shows right upper lobe consolidation. BAL was done. The microphotographs of the smears are shown in Figure 4.7. The most likely diagnosis is:

A. Squamous cell carcinoma
B. Reactive bronchial cells
C. Small cell carcinoma
D. Adenocarcinoma

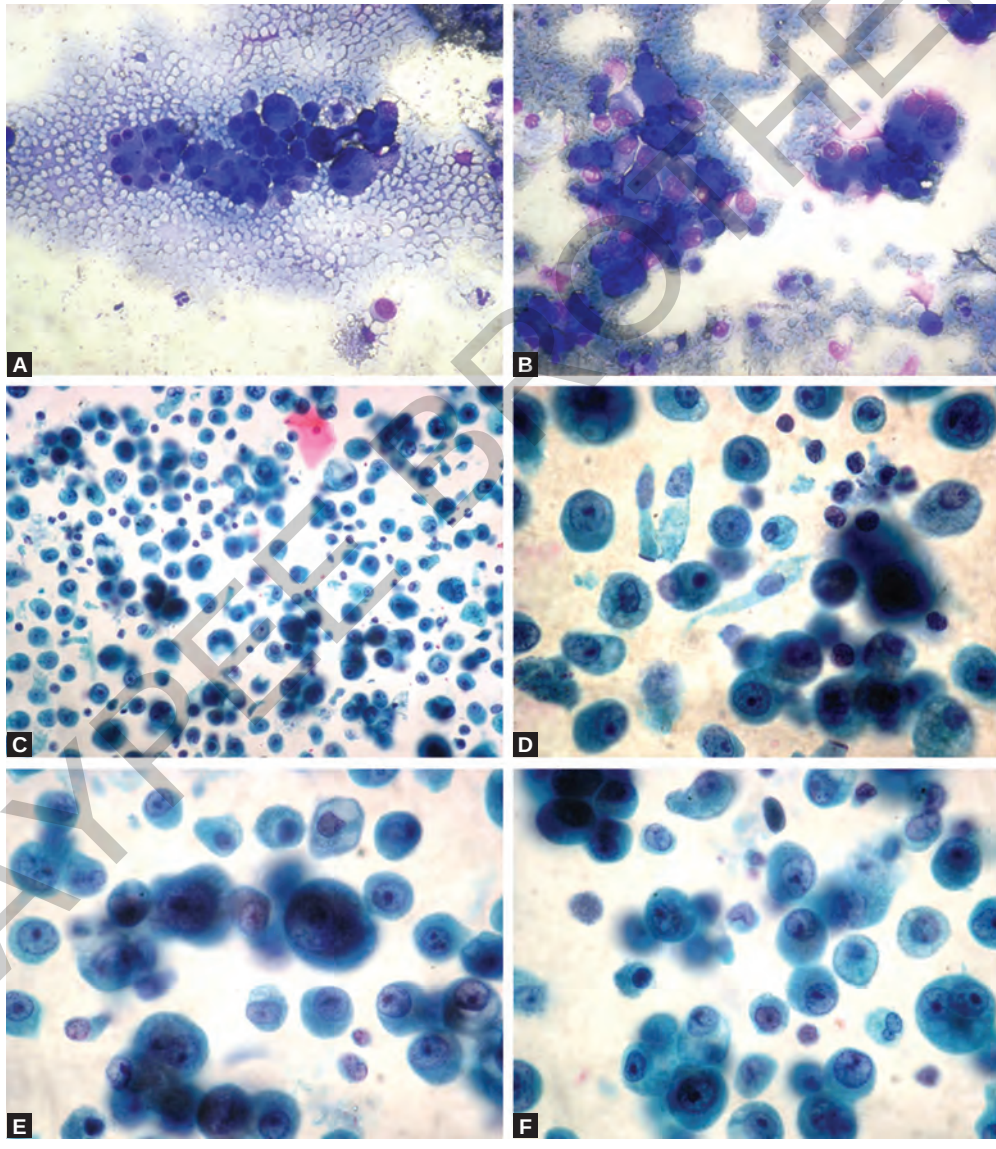

Figures 4.7A to F

JAYPEE BROTHERS

Problem 4.8

A 55-year-old male presented with respiratory distress, cough and loss of weight for 2 months. He has lower lung space occupying lesion. The microphotographs of BAL are shown in Figures 4.8A to J. The most likely diagnosis is:

A. Adenocarcinoma
B. Squamous cell carcinoma
C. Small cell carcinoma
D. Reactive atypia

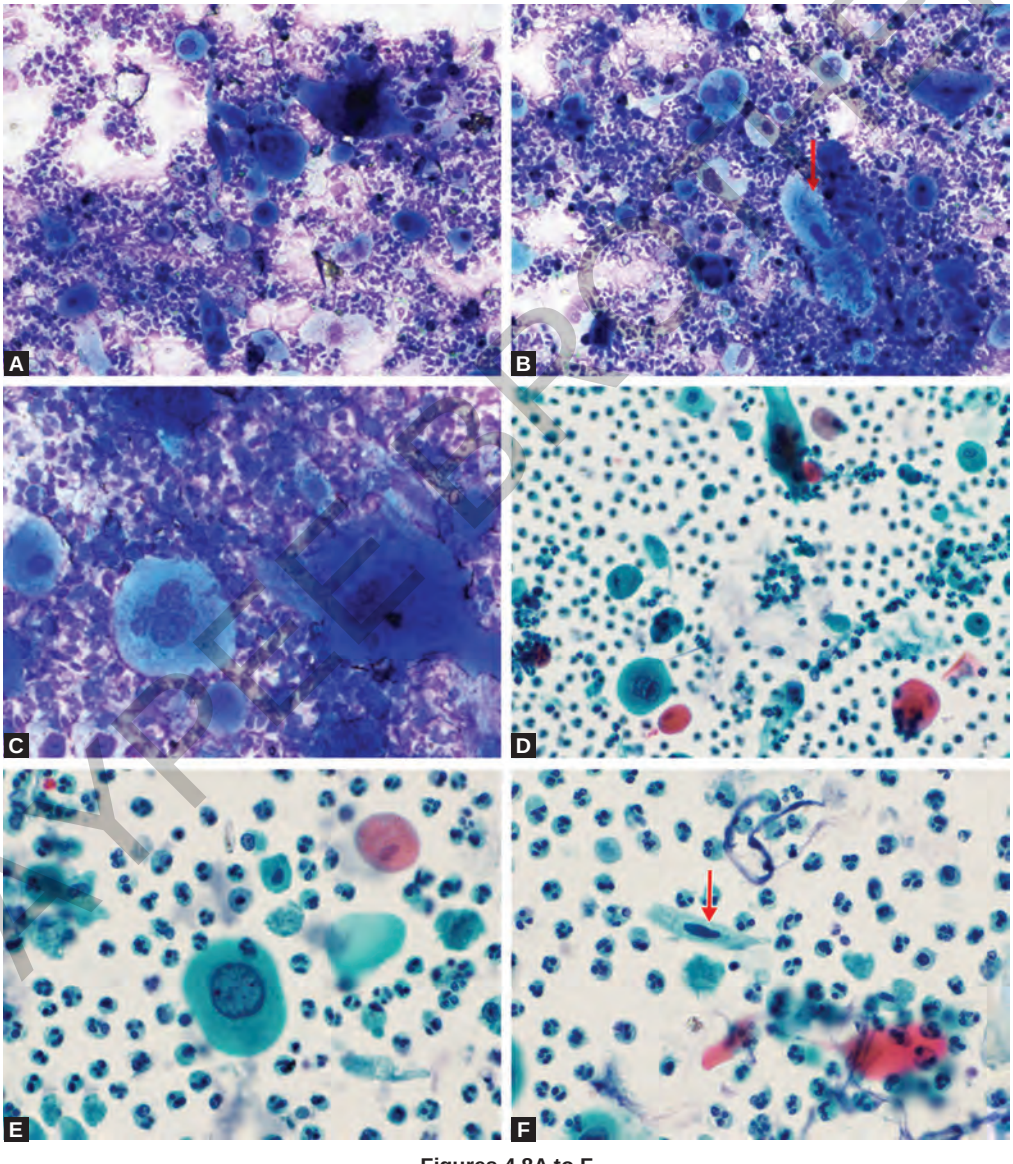

Figures 4.8A to F

JAYPEE BROTHERS

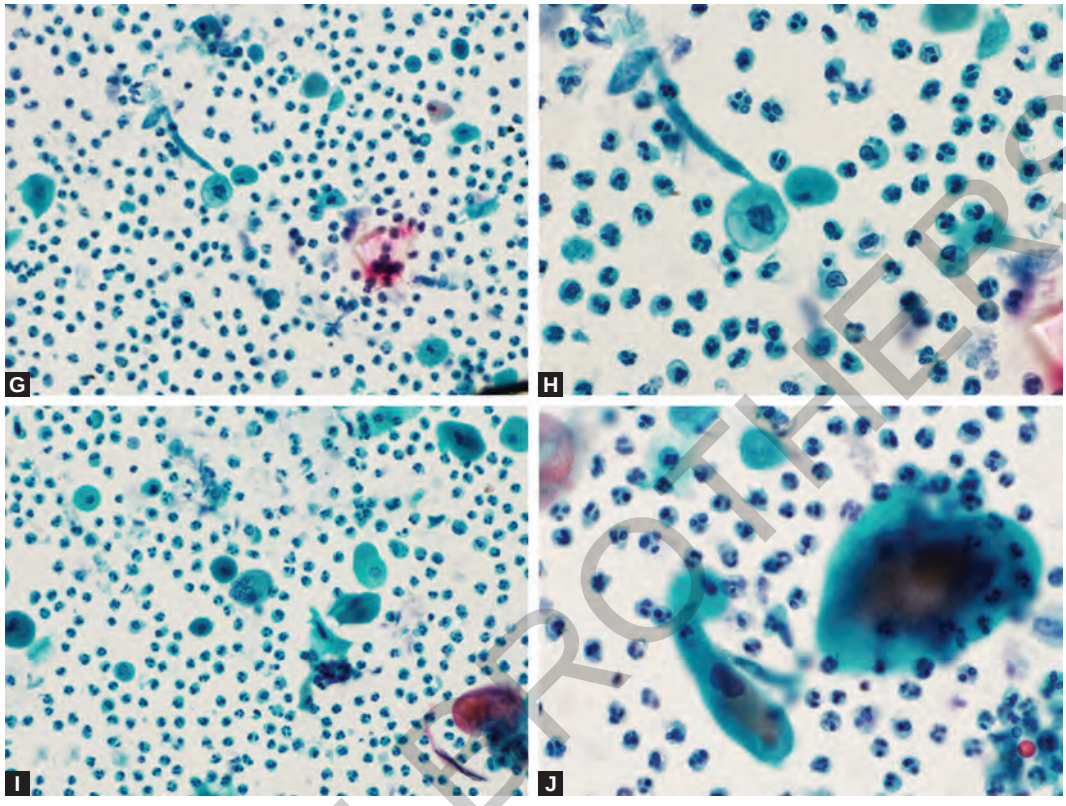

Figures 4.8G to J

JAYPEE BROTHERS

for detailed information on pathology books, visit our website **www.jaypeebrothers.com,** for detailed i

Case-based Approach in Exfoliative Cytology

Salient Features

- Case-by-case learning of exfoliative cytology
- Useful for cytology students and practitioners
- Provides 215 real cases of exfoliative cytology supplemented with clinical details and multiple microphotographs
- Discusses diagnostic features as well as differential diagnosis
- Special emphasis on cervical cytology and abundant microphotographs of liquid-based cytology (LBC)
- Includes recent classification of lung tumors and urinary cytology.



Pranab Dey MBBS MD MIAC FRCPath is a Professor, Department of Cytology and Gynecologic Pathology, Postgraduate Institute of Medical Education and Research, Chandigarh, India. He is a well-reputed cytologist and gynecologic pathologist, engaged in diagnosis, research and teaching for more than 25 years. He has also authored *Fine Needle Aspiration Cytology: Interpretation and Diagnostic Difficulties, Diagnostic Cytology* and *Case-based Approach in Fine Needle Aspiration Cytology*.

Available at all medical bookstores
or buy online at www.jaypeebrothers.com

JAYPEE BROTHERS
Medical Publishers (P) Ltd.
www.jaypeebrothers.com

Join us on facebook.com/JaypeeMedicalPublishers

Shelving Recommendations
CYTOLOGY, PATHOLOGY

ISBN 978-93-86261-89-2