te www.jaypeebrothers.com, for detailed information on anatomy books, visit our website www.jaypeebrothers.co

14th Edition

MANNAN'S REGIONAL DISSECTION AND SURFACE ANATOMY

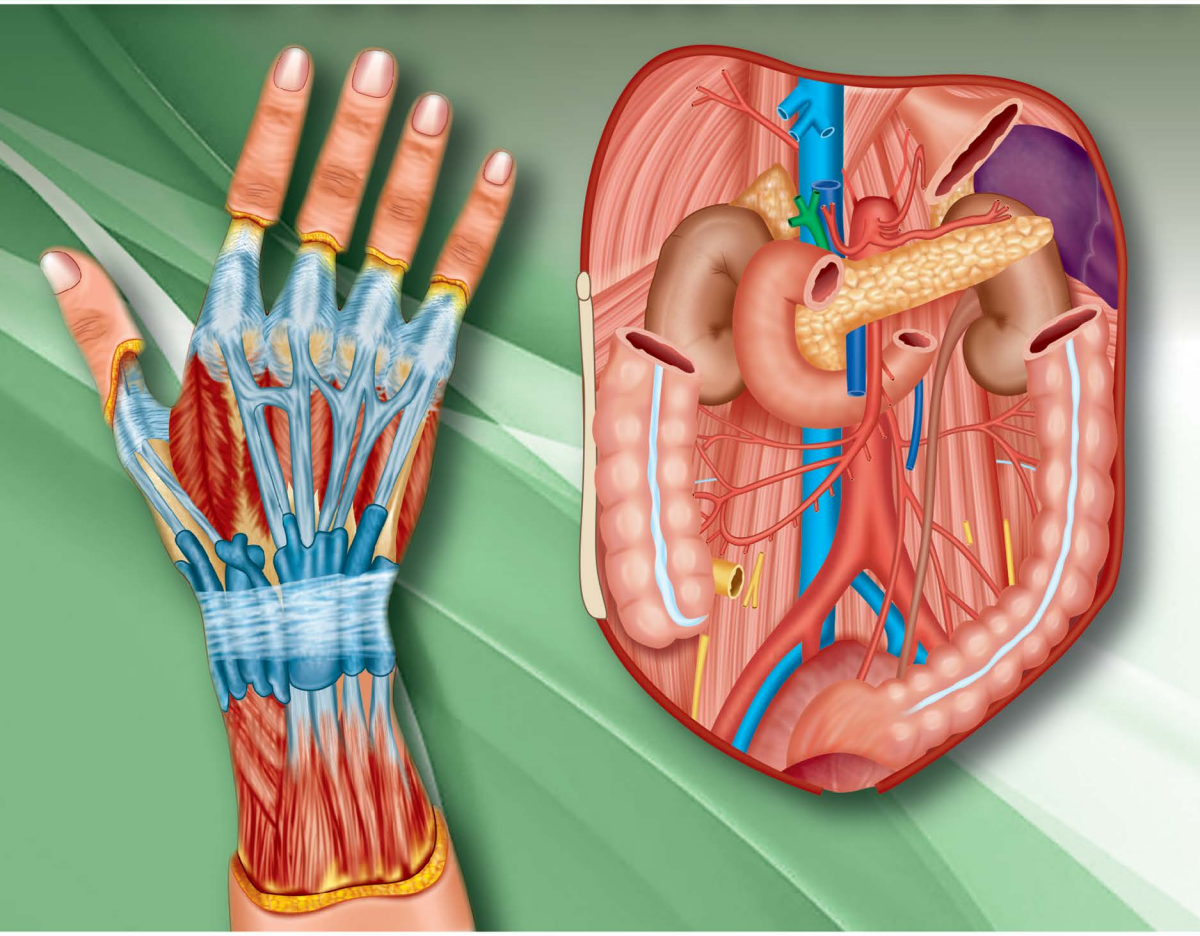

Md Ali Noor

JAYPEE

Contents

SECTION 1: REGIONAL DISSECTION

1. Introduction to Regional Dissection **3**
Advice to the Dissectors 3
Steps of Dissection 4

2. Head, Neck and Face **8**

- **Scalp and Temporal Region 8**
  Scalp 8
  Temporal Region (Temple) 8
  Layers of the Scalp 9
  Muscles of the Scalp 11
  Layers of the Temporal region 11
  Nerve Supply of the Scalp and Temporal Region 12
  Artery supply of the Scalp and Temporal region 14
  Veins of the Scalp and Temporal region 16
  Muscles of the Eyeball 18
- **Face 21**
  Skin Incisions 21
  Vessels and Nerves of the Face 22
  Facial Muscles 31
  Parotid Gland 38
- **Anterior Triangle 42**
  Boundary 42
  Skin Incisions 43
  Platysma 44
  Muscular Triangle 50
  Thyroid Gland 51
  Larynx or Voice box 54
  Cartilages of the Larynx 54
  Carotid Triangle 56
  Digastric Triangle 70
  Submental Triangle 74
- **Posterior Triangle 81**
  Boundaries 81
  Skin Incisions 82
  Occipital Triangle 83
  Supraclavicular Triangle 84
  Suboccipital Triangle 87
  Articulation of the Head, Neck and Vertebral Column 97
  Cranial Nerves 98
  Cervical Plexus 99

3. Superior Extremity 102

- **Clavipectoral Fascia 102**
  Skin Incisions 102
- **Quadrangular and Triangular Spaces 108**
  Skin Incisions 108
  Quadrangular Space 108
  Triangular Space 110
- **Axilla 112**
  Skin Incision 112
  Applied Anatomy 120
- **Front of the Arm 125**
  Skin Incisions 125
- **Back of the Arm 132**
  Skin Incisions 132
- **Cubital Fossa 137**
  Skin Incisions 137
- **Front of the Forearm 141**
  Skin Incisions 141
- **Back of the Forearm 153**
  Skin Incisions 153
- **Palm of the Hand 161**
  Skin Incisions 161
  Applied Anatomy 177
  Muscles of the Hand 179
- **Dorsum of the Hand 181**
  Skin Incision 181
- **Superficial Dissection of the Back and Scapular Region 191**
  Skin Incision 191
- **Deep Dissection of the Back 195**
  Joints of the Upper Limb 195

4. Inferior Extremity 201

- **Femoral Triangle 201**
  Skin Incisions 201
  Lymphatic Drainage of the Lower Limb 215
  Superficial Lymph Nodes 216
  Deep Lymph Nodes 216
  Lymph Vessels or Lymphatics 217
- **Adductor Canal 219**
  Skin Incisions 219
- **Gluteal Region 224**
  Skin Incisions 224
  Clinical Importance of Gluteal Muscles 226
  Structures Lie Deep to the Gluteus Maximus 226
- **Back of the Thigh 239**
  Skin Incisions 239
- **Popliteal Fossa 244**
  Skin Incisions 244

- **Front of the Leg 254**
  Skin Incisions 254
  Anterior Crural Muscles 255
  Lateral Crural Muscles 259
- **Back of the Leg 261**
  Skin Incisions 261
- **Flexor Retinaculum of the Foot 269**
  Skin Incisions 269
- **Dorsum of the Foot 271**
  Skin Incisions 271
- **Sole of the Foot 279**
  Skin Incisions 279
  Muscles of the 1st Layer 281
  Muscles and Tendons of the 2nd Layer 286
  Muscles of the 3rd Layer 288
  Muscles and Tendons of the 4th Layer 291
  Lumbricals 296

5. Abdomen 305

- **Rectus Sheath 305**
  Skin Incisions 305
  Rectus Sheath Formation 307
  Umbilicus 313
- **Inguinal Region 314**
  Skin Incisions 314
  Superficial Inguinal Ring 316
  Deep Inguinal Ring 317
  Inguinal Canal 318
  Spermatic Cord 320
  Hernia 326
- **Anterolateral Wall of the Abdomen 328**
  Skin Incisions (for the Whole Region) 328
- **Kidney from the Back 333**
  Kidney 333
- **Perineum 343**
  Perineum—Position and Shape 343
- **Anal Triangle (Anal Region) 345**
  Skin Incisions 345
  Ischiorectal Fossa 346
  Urinary Bladder 351
- **Urogenital Triangle in Male 352**
  Skin Incisions 352
  Superficial Perineal Muscles 355
  Perineal Membrane 357
  Deep Perineal Muscles 358
- **Urogenital Triangle in Female 361**
  Skin of this Region 361
  Clitoris 366
  Vagina 367

Perineal Membrane (in Female) 368
Uterus 369
- **Male Genital Organs 371**
Scrotum 372
Testes 373
Epididymis 375
Penis 376
Male Urethra 378
Female Urethra 379
Duodenum, Jejunum and Ileum 379
Pancreas 381
Spleen 382
Large Intestine 383
Liver 385
Stomach 387

6. Thorax 392
- **Anatomy 392**
Shape of the Thorax 392
Boundaries of the Thorax 392
Apertures of the Thorax 392
- **Thoracic Wall 395**
Anterior Wall 395
Lateral Wall 396
Posterior Wall 397
Dissection of the Intercostal Space 397
Intercostal Nerves 400
Intercostal Arteries 402
Posterior Intercostal Veins 403
Anterior Intercostal Arteries 404
Anterior Intercostal Veins 404
Transversus Thoracic 406
Levatores Costorum 407
Serratus Posterior Superior 407
Serratus Posterior Inferior 407
- **Female Breast 410**
Normal Anatomy 410
Male Breast 414

7. Neurovascular and Lymphatic System 415
- **Arterial System 415**
Ascending Aorta 415
Heart 415
Coronary Artery 417
Arch of the Aorta 418
Diaphragm 431
- **Venous System 433**
Cardiac Veins 433
Veins of the Upper Limbs (Venous Drainage of the Upper Limb) 434
Veins of the Head, Face and Neck (Venous Drainage of the Head, Face and Neck) 436

The Veins of the Thorax 443
Veins of the Lower Limbs (Venous Drainage of the Inferior Extremity) 447
Veins of the Abdomen and Pelvis (Venous Drainage of the Abdomen) 450

- **Lymphatic Drainage 454**
  Lymphatic Drainage of the Head and Neck 454
- **Nervous System 463**
  Cranial Nerve 464
  Sympathetic System of the Body 486
  Vascular Branches 489
  Brain 490

SECTION 2: SURFACE ANATOMY

8. Introduction to the Surface Anatomy 505

9. Surface Anatomy of the Thorax 507
Heart 507
Median Plan 509
Sternal Angle 509
Xiphisternal Junction 509

10. Surface Anatomy of the NecK 515
Thyroid Gland 515
Carotid Artery 515
Jugular Vein 516
Facial Artery (in the Neck) 516
Nerves in the Neck 516

11. Surface Anatomy of the Face 518
Artery and View 518
Parotid Gland 518
Parotid Duct 519
Palatine Tonsil 519
Supraorbital Notch (by a Point) 520
Condylar Process of the Mandible 520

12. Surface Anatomy of the Head 521
Anatomical Points 521
Central Sulcus 522
Lateral Sulcus 522
Motor Area 522
Sensory Area 522

13. Surface Anatomy of the Abdomen 523
Anatomical Points 523
Stomach 525
Duodenum 525
Pancreas 526
Spleen 526
Liver 526
Fundus of the Gallbladder (by a Point) 526
Bile Duct 527
Portal Vein 527

Cecum 527
Ileocolic Orific and Valve 527
McBurney's Point 527
Vermiform Appendix 527
Colon 528
Kidney 528
Ureter 529

14. Surface Anatomy of the Superior Extremity 532
Arteries 532
Anatomical Snuff Box 533
Arches 533
Nerves 533

15. Surface Anatomy of the Inferior Extremity 537
Key Features 537
Muscles Required for Surface Marking 543

16. Surface Anatomy of Small Bones 544
- **Identification and Anatomical Position of the Small Bones 544**

Carpal Bones 544
Tarsal Bones 545
Metacarpal and Metatarsal Bones 546
Phalanges 547
Patella 548

Appendices 549
Appendix 1: Relations 551
Appendix 2: Levels 561
Appendix 3: Dimensions 564
Appendix 4: Length 571
Appendix 5: Weights 573
Appendix 6: Capacities 574
Appendix 7: Units of Measurement 575

Glossary 577

Index 615

4 Inferior Extremity

FEMORAL TRIANGLE

It is a triangular depression that occupies the greater part of the upper third of the thigh (it is also called the Scarpa's triangle).

SKIN INCISIONS

1. An oblique incision from the anterior superior iliac spine to the top of the symphysis pubis along the inguinal ligament.
2. A transverse incision at the junction of the upper third and lower two-thirds of the front of the thigh.
3. A longitudinal incision joining the medial ends of the lst and 2nd incisions along the medial side of the thigh.
   Skin—Reflect laterally.

Superficial fascia

It is disposed here in two layers, the *superficial fatty* and the *deep membranous*.

Both the layers are continuous above with the corresponding layers in the anterior abdominal wall. The *superficial fatty layer* is continued downwards with the superficial fascia of the thigh but the *deep membranous layer* is intimately adherent to the fascia lata a little below the inguinal ligament.

(The portion of the membranous layer which covers the saphenous opening is known as the cribriform fascia, as it is perforated by the superficial blood-vessels and lymph-vessels like a sieve, cribrum = sieve).

Now, carefully reflect the *fatty layer of the superficial fascia* and find out the following *cutaneous structures* within and under cover of it—

1. **Superficial branches of the femoral artery**—
   a. *Superficial epigastric artery*—It comes out by piercing the femoral sheath and the cribriform fascia, then it runs upwards over the inguinal ligament to the abdomen between the two layers of the superficial fascia (only a small part at the beginning of the artery will be seen in this dissection; for the rest portion, see the inguinal region).

JAYPEE BROTHERS

b. *Superficial external pudendal*—It comes out by piercing the femoral sheath and the cribriform fascia, then runs medially crossing in front of the spermatic cord or the round ligament of the uterus to supply the skin of the suprapubic region and the skin of the external genital organs.

It anastomoses with the branches of the internal pudendal artery.

c. *Superficial circumflex iliac*—It comes out by piercing the femoral sheath and the fascia lata a little lateral to the saphenous opening, then runs laterally lying a little below and almost parallel to the inguinal ligament towards the iliac crest and supply the skin, subcutaneous tissue of the groin and the superficial inguinal lymph nodes.

It anstomoses with the deep circumflex iliac, superior gluteal and lateral circumflex femoral arteries.

Veins corresponding to these arteries—Without opening into the femoral vein, open into the great (long) saphenous vein just before it picrces the cribriform fascia (a similar arrangement is present in the case of the veins corresponding in the branches of the acromiothoracic artery, which separately open into the cephalic vein before it pierces the clavi-pectoral fascia).

2. **Great (long) saphenous vein**—It is the longest vein in the body.
   - *Formation*—It is formed by the union of the medial marginal vein with the medial end of the dorsal venous arch.
   - *Course*—It ascends in front of the medial malleolus and along the medial side of the leg to the posteromedial aspect of the knee, from where it runs upwards along the medial side of the thigh to the saphenous opening; there it passes through the cribiform fascia and about $1^1/_2$″ below the inguinal ligament it pierces the femoral sheath and *ends in the femoral vein*.
   - *Relation*—It is accompanied by the saphenous nerve in the foot and leg; by the saphenous branch of the descending geniculate artery at the knee and by some branches of the medial femoral cutaneous nerve in the thigh. It has got about 15 valves.
   - *Tributaries*—
     a. Superficial epigastric
     b. Superficial circumflex iliac
     c. Superficial external pudendal
     d. Accessory saphenous vein of the thigh
     e. Some cutaneous veins of the leg
     f. Some cutaneous veins of the sole of the foot.

> *Note*: Only the proximal part of the long saphenous vein will be found in the dissection of the femoral triangle.

3. **Cutaneous nerves**—
   a. Ilioinguinal nerve—It emerges through the lateral part of the superficial inguinal ring and is distributed to the skin of the external genital organs (mostly to the scrotum or to the labium majus) and to the upper and medial part of the thigh.

JAYPEE BROTHERS

b. Femoral branch of the genitofemoral nerve (lumboinguinal nerve)—From the abdomen it enters the femoral sheath at first lying lateral to the femoral artery and about an inch below the inguinal ligament, it pierces the anterior wall of the femoral sheath and then fascia lata and supplies the skin over the upper part of the femoral triangle. It gives a twig to the femoral artery.
c. Lateral femoral cutaneous nerve (lateral cutaneous nerve of the thigh)—It escapes from the abdomen behind the inguinal ligament medial to the anterior superior iliac spine and after a short course divides into two branches—
   - *Anterior branch*—It pierces the fascia lata about 4″ below the anterior superior iliac spine and runs downwards up to the knee suppling skin of the front and lateral aspects of the thigh.
   - *Posterior branch*—It pierces the fascia lata about 2″ below the anterior superior iliac spine and supplies the skin over the back of the thigh and lower lateral part of the gluteal region (show this branch in the dissections of the back of the thigh and in the gluteal region).
d. *Intermediate femoral cutaneous nerve* (intermediate cutaneous nerve of the thigh)—It is a branch from the anterior division of the femoral nerve. It divides into *lateral* and *medial branches*, which pierce the fascia late about 3″ below the inguinal ligament and supply the skin of the middle of the front of the thigh down to the knee. The lateral branch sometimes pierces the sartorius, to which it may give a twig of supply.
e. *Medial femoral cutaneous nerve* (medial cutaneous nerve of the thigh)—While this nerve passes downwards deep to the fascia lata, it gives off minute twigs which pierce the facia lata and are distributed to the skin of the neighborhood of the great saphenous vein (see adductor canal).

4. **Superficial inguinal lymph nodes**—These are placed between the two layers of the superficial fascia and are arranged in two groups—
   a. The upper or horizontal group (5 or 6 in number) are placed immediately below the inguinal ligament.
   b. The lower or vertical group (4 or 6 in number) are place along the upper end of the great saphenous vein).

Dissection note: Romove all the superficial lymph nodes except one or two which may be conveniently preserved at a place. Then, reflect the *membranous layer of the superficial fascia* laterally detaching it from the facia lata.

Clean the surface of the fascia lata and define the outline of the *saphenous opening* by removing the cribriform fascia from it and the structures passing through the opening, specially—The great saphenous vein, the superficial epigastric and the superficial external pudendal arteries. The *superficial circumflex iliac artery* will be found to pierce the fascia lata just lateral to the saphenous opening. Observe here that the saphenous opening has no definite medial margin.

Then, by giving a vertical incision to the *fascia lata* from the midpoint of the inguinal ligament, reflect it on either side without injury to the cutaneous arteries and nerves. Try to preserve the *falciform margin of the saphenous opening* in the reflected layer of the fascia lata.

JAYPEE BROTHERS

Saphenous Opening

It is an oval aparture in the fascia lata a little below the medial part of the inguinal ligament. It is about 1½″ long and ½″ wide. Its center lies 1½″ below and lateral to the pubic tubercle.

It is *bounded* above, laterally and below by the falciform margin and medially by the public part of the fascia lata, which forms a sloping surface than a margin.

It is *covered* by the cribriform fascia which is derived from the deep layer of the superficial fascia, being attached laterally to the falciform margin and medially it becomes continuous with the pubic part of the fascia lata.

The cribriform fascia is *pierced by the following structures* passing through the saphenous opening—

1. Great saphenous vein
2. Superficial epigastric artery
3. Superficial external pudendal artery
4. Efferent lymph vessels from the superficial lymph nodes
5. A filament from the medial femoral cutaneous nerve.

Fascia Lata

It is the *deep fascia of the thigh*. It is termed "lata" because of its extensive distribution. It envelops the whole thigh and also covers the gluteal region.

It is attached above as follows—

a. *In front* to the—(1) Inguinal ligament, (2) pectineal line (pecten pubis) and (3) body of the pubis.
b. *Medially to the*—(1) Everted medial margin of the inferior ramus of the pubis, (2) lower border of ramus and tuberosity of the ischium and (3) lower border of the sacrotuberous ligament.
c. *Laterally to the*—(1) Outer lip of the iliac crest.
d. *Behind to the*—(1) Back of the sacrum and coccyx.

It is attached below to the—

1. Condyles of the femur and tibia
2. Head of the fibula
3. Medial and lateral margins of the patella and ligamentum patella
4. Tubercle of the tibia (tibial tuberosity)
5. Capsule of the knee joint.

   Behind the knee, it forms *popliteal fascia*, which is continuous below with the *fascia cruris* or the deep fascia of the leg.

Special Feature

On the medial side of the thigh, the fascia lata is very thin but laterally it is specially thickened to form a strong band, called the *ilio-tibial tract* which extends from the anterior part of the iliac crest to the lateral condyle of the tibia.

JAYPEE BROTHERS

As the ilio-tibial tract receives the insertions of the tensor fascia lata and of the greater superficial fibers of the gluteus maximus, it acts as the tendon for these two muscles.

Distribution of the Fascia Lata

From its attachment to the iliac crest it descends over the gluteus medius as a single layer to the upper border of the gluteus maximus, where it splits into two layers (superficial and deep) which enclose the gluteus maximus and at the lower border of this muscle the two layers re-unite to form a single layer which is continued downwards as the posterior layer of the fascia lata.

Above the gluteus maximus, the anterior part of the fascia lata which covers the gluteus medius, splits to become continuous with the two layers that envelope tensor fascia lata and the layer deep to this muscle blends with the capsular ligament of the hip joint.

At the upper and front part of the thigh, the fascia lata consists of two portions—*Superficial or iliac* and *deep* or pubic, which extend only up to the lower margin of the saphenous opening.

The iliac portion—It lies on the lateral side of the saphenous opening and is attached to the iliac crest, the anterior superior iliac spine, the inguinal ligament, the pectineal line along with the lacunar ligament and the pubic tubercle. Its medial limit is concave and forms an arched *falciform margin*, which has got two cornua—Superior and inferior. The *superior cornu* passes upwards and medially to be attached to the lacunar ligament (pectineal part of the inguinal ligament) and the *inferior cornu* becomes continuous behind the great saphenous vein with the deep portion of the fascia lata.

The pubic portion or the pectineal fascia lies on the medial side of the saphenous opening. It covers the adductor longus and pectineus and is attached above to the pectineal line. Traced laterally, it passes behind the femoral sheath and becomes continuous with the fascia iliaca which covers the iliopsoas muscle.

From the above distribution, it is now evident that the iliac portion of the fascia lata lies in front of the femoral sheath and the pubic portion behind the sheath.

Three intermuscular septa are given off from the deep surface of the fascia lata. They are attached to the linea aspera and to its upwards and downward prolongations, (a) The *medial septum* separates the extensors from the adductors, (b) the *lateral septum* separates the extensors from the flexors and (c) the *posterior septum*, thinnest of all, separates the adductors from the flexors. These septa divide the thigh into *three osteofascial compartments* for the three groups of muscles of the thigh, each associated with separate nerve supply—

a. *Anterior compartment*—It contains the "*extensors*" supplied by the femoral nerve.
b. *Medial compartment*—It contains the "*adductors*" supplied by the obturator nerve.
c. *Posterior compartment*—It contains the "*flexors*" or hamstring muscles, supplied by the sciatic nerve.

JAYPEE BROTHERS

Surgical Importance of the Fascia Lata

The fascia lata is firmly fixed above and behind to the hip bone, sacrum and coccyx and below to the bony prominences of the front and sides of the knee but it is continuous behind the knee with the popliteal fascia, which is again continuous below with the fascia cruris; so any collection of pus under the fascia lata in the gluteal region or in the thing may track down under cover of the popliteal fascia and fascia cruris as far as the heel.

Boundaris of the Femoral Triangle

a. *Laterally*—Medial border of the sartorius.
b. *Medially*—Medial border of the adductor longus.
c. *Base* (above)—Inguinal ligament.
d. *Apex* (below)—Meeting point of the sartorius and the adductor longus. (The apex is continuous with the adductor canal).
e. *Floor*—Formed by the iliacus, psoas major, pectineus and adductor longus (from lateral to the medial side).
f. *Roof*—Formed by the skin and fascia (superficial fascia and fascia lata with cribriform fascia).

Contents (Fig. 4.1)

1. Femoral sheath, including the femoral canal.
2. Femoral artery with its superficial and deep branches.
3. Lateral and medial circumflex femoral branches of the arteria profunda femoris.
4. Femoral vein with its tributaries.
5. Femoral nerve with its branches.
6. Lateral femoral cutaneous nerve.
7. Three or four deep inguinal lymph nodes.
8. Lumboinguinal nerve.
9. Some amount of fat.

Femoral Sheath

- *Shape and extension*—It is a funnel-shaped, fascial tube which encloses the femoral vessels for a length of 1½″ extending from the inguinal ligament to the lower margin of the fossa ovalis.
- *Direction*—The upper wide mouth of the funnel is directed towards the abdominal cavity and its lower conical end fuses with the external coats of the femoral vessels.
- *Formation*—It is formed *anteriorly* by the downward prolongation of the fascia transversalis from the anterior abdominal wall behind the inguinal ligament and *posteriorly* by the fascia iliaca. Both the fascia are united on the lateral and medial sides of the femoral vessels.

Pierced by—The lateral wall of the sheath is vertical and is pierced by the lumbo-inguinal nerve; the medial wall is oblique and is pierced by the great saphenous vein and some lymph-vessels.

JAYPEE BROTHERS

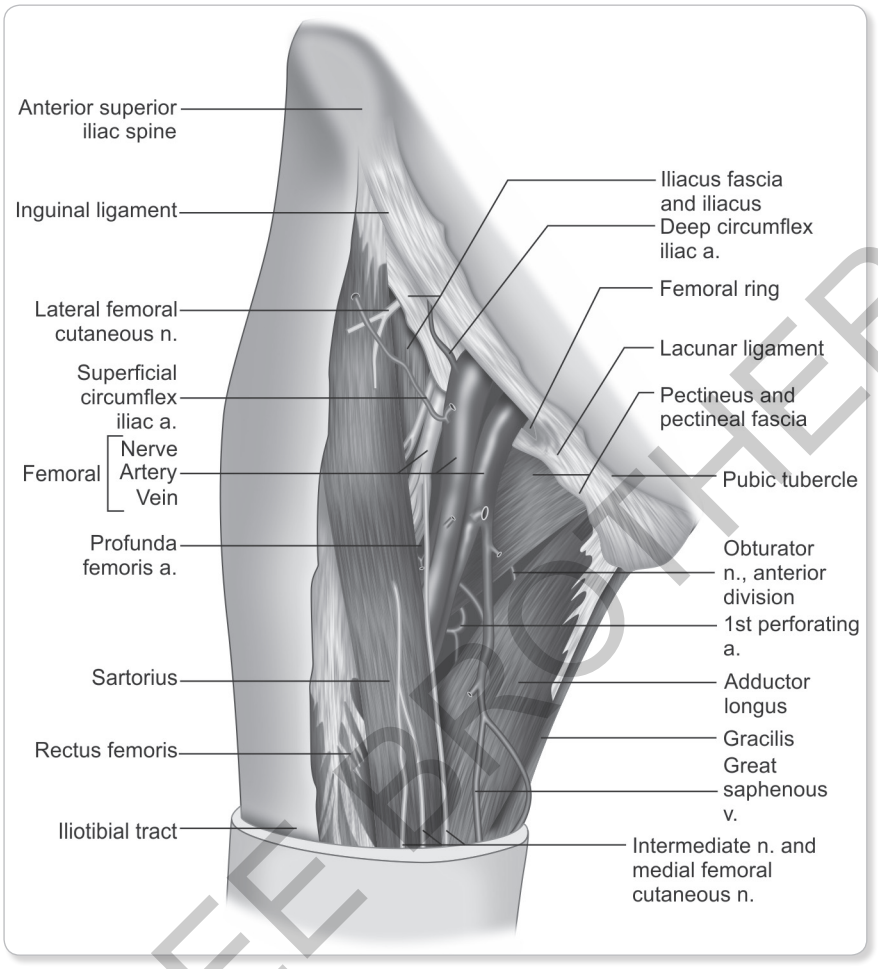

Fig. 4.1: Femoral triangle *(for color version, see Plate 12)*

JAYPEE BROTHERS

Compartments and their Contents

The interior of the sheath is divided into three compartments by the antero-posterior vertical fibrous septa—

1. *Lateral compartment*: Contains the femoral artery and the lumbo-inguinal nerve (the nerve lying lateral to the artery).
2. *Intermediate compartment*: Contains the femoral vein.
3. *Medial compartment*: It is called the femoral canal.

Femoral Canal

It is the medial compartment of the femoral sheath. It is conical in shape and measures about ½″ in length and ½″ in diameter at its base.

It contains—
1. One lymph node
2. Few lymph-vessels
3. Small amount of areolar tissue.

> ***Note***: Femoral canal is the weak point of the abdominal wall through which femoral hernia may occur. This type of hernia more common in female.

Femoral Ring

The base or the upper end of the femoral canal is known as the *femoral ring*, which is directed upwards to the abdominal cavity.

Boundaries of the ring:
a. *In front*—Inguinal ligament.
b. *Behind*—Pectineus muscle with its covering fascia.
c. *Medially*—Concave base of the lacunar ligament (pectineal part of the inguinal ligament).
d. *Laterally*—Femoral vein, separated by the septum.

Relation of the ring:
a. *Above and in front*—The spermatic cord or round ligament
b. *Above and laterally*—The inferior epigastric vessels.

It is closed by the condensation of the extra peritoneal tissues, named the *femoral septum*, which is pierced by some lymph-vessels. The upper surface of the septum is covered by the parietal peritoneum and presents a slight depression, called the *femoral fossa*.

> ***Note***: Owing to the greater breadth of the pelvis and the smaller size of the femoral vein. Femoral ring is larger in female than in male and as such the femoral hernia is more common in females.

Femoral Hernia?

Protrusion of any contents of the abdominal cavity when occurs through the femoral canal into the thigh, is known as the 'femoral hernia'.

Coverings of the femoral hernia (from within outwards) are as follows—
1. Peritoneus, forming the hernial sac
2. Fermoral septum
3. Anterior wall of the femoral sheath
4. Cribriform fascia
5. Superficial fascia
6. Skin.

> ***Dissection note***: To make a thorough exposure of the contents of the triangle, the femoral sheath may now be removed in pieces. First, look for the three superficial branches of the femoral artery, which have been already dissected. Then, clean the femoral artery and secure its other branches in the triangle.

Contd...

JAYPEE BROTHERS

Contd...

The *deep external pudendal artery* will be found to pass medially deep to the femoral vein and the *profunda artery*, passing downwards behind the femoral vessels through the muscles and fat; secure its two large branches—lateral and medial circumflex femoral arteries and follow them as far as possible.

Clean the *profunda vein* removing all other smaller clumsy veins from the area; then, it will be found lying in front of the profunda artery.

Then, clean the femoral nerve and trace the mascular and cutaneous branches from its anterior and posterior divisions. Next, secure the *nerve to the pectineus* which runs medially, behind the femoral sheath. *Saphenous nerve* will be found descending on the lateral side of the femoral artery; it is thicker than the other cutaneous branches of the femoral nerve, moreover, it is unbranched in this region.

Lastly, (though not now strictly required) secure the *anterior branch of the obturator* nerve in the gap between the pectineus and the adductor longus, as it descends behind them in front of the adductor brevis.

Femoral Artery

- *Course*—It is the direct continuation of the external iliac artery. It begins behind the mid-point of the inguinal ligament, then passes downwards and medially and ends opposite the junction of the middle with the lower third of the thigh, from where it passes through the lowest opening in the adductor magnus to become the popliteal artery. The *upper part* lies in the femoral triangle and the *lower part* in the adductor canal.
- *Relation* (in the femoral triangle)—
  a. Anteriorly—Skin, superficial fascia containing the superficial inguinal lymph nodes and superficial circumflex iliac vein (the vein crossing the artery from lateral to medial); fascia lata, anterior wall of the femoral sheath; the lumboinguinal nerve lying at first lateral and then in front of the artery; the medial femoral cutaneous nerve crosses the artery from lateral to the medial side at the apex of the triangle.
  b. *Posteriorly*—Posterior wall of the femoral sheath, the nerve to the pectineus, psoas major, pectineus, adductor longus, femoral vein at the lower part, profunda vessels and the capsule of the hip joint separated by the psoas major.
  c. *Laterally*—Femoral nerve and its branches.
  d. *Medially*—Femoral vein at the upper part.

Branches (in the femoral triangle)

1. Superficial epigastric
2. Superficial circumflex iliac
3. Superficial internal pudendal
4. Deep external pudendal
5. Arteria profunda femoris
6. Muscular.

Note: Femoral arterial pulsation felt in the mid inguinal point against the head of the femur and the tendon of psoas major.

JAYPEE BROTHERS

Deep external Pudendal Artery

By piercing the femoral sheath it passes medially over the pectineus and adductor longus but deep to the fascia lata which it pierces at the medial side of the thigh and supplies the scrotum in the male and the labium majus in the female. It anastomoses with the scrotal or labial branches of the internal pudendal artery.

Arteria Profunda Femoris

It is the largest branch of the femoral artery.

- *Course*—It arises about 1½″ below the inguinal ligament from the posterolateral aspect of the femoral artery, it then curve backwards and medially behind the femoral artery and vein, descends under cover of the adductor longus and by piercing the adductor magnus it terminates as the *fourth perforating artery*.
- *Relation*—
  - *In front*—Femoral vessels, profunda vein and adductor longus.
  - *Behind*—Iliacus, pectineus, adductor brevis and adductor magnus (from above downwards).
  - *Laterally*—Vastus medialis.
- *Branches*—
  1. Lateral circumflex femoral
  2. Medial circumflex femoral
  3. Perforating
  4. Muscular.

Lateral Circumflex Femoral Artery

It arises from the profunda artery near its origin. It runs laterally behind the sartorius and rectus femoris through the branches of the femoral nerve and divides into three branches.

1. *Ascending branch* anastomoses with the superior gluteal and the deep circumflex iliac arteries.
2. *Descending branch* anastomoses with the superior lateral genicular branch of the popliteal artery.
3. *Transverse branch* joins the "cruciate anastomosis" at the back of the thigh.

Medial Circumflex Femoral Artery

It arises at about the same level of the lateral circumflex. It passes backwards between the pectineus and psoas major and then between the obturator externus and adductor brevis and finally divides into three branches—

1. *Ascending branch*—It anastomoses with the superior gluteal artery.
2. *Transverse branch*—It joins the "cruciate anastomosis".
3. *Acetabular branch*—It enters the hip joint in company with the acetabular branch of the obturator artery below the transverse acetabular ligament and supplies the fat in the acetabular fossa.

JAYPEE BROTHERS

Perforating Arteries

Four in number, of these three are the branches of the profunda femoris and the 4th one is its terminal part. They are so named as they reach the back of the thigh by perforating the adductor magnus (see back of the thigh).

Femoral Vein

- *Course*—It begins as the continuation of the popliteal vein at the opening in the adductor magnus and ends by becoming the external iliac vein behind the inguinal ligament.
- *Relation* (in the femoral triangle)—At the apex of the triangle, it is directly behind the femoral artery and at the upper part it lies medial to the artery.
- Tributaries—
  1. Great (long) saphenous vein
  2. Vena profunda femoris
  3. Lateral and medial circumflex femoral veins
  4. Several muscular tributaries.

> *Note*: The veins corresponding to the superficial branches of the femoral artery terminate in the long saphenous vein and not in the femoral vein.

The following structures would be injured if a "stab" is made at the apex of the femoral triangle from before backwards—

1. Femoral artery
2. Femoral vein
3. Adductor longus
4. Profunda vein
5. Profunda artery.

> *Note*: A stab wounds at the apex of the femoral triangle causes cutting of large femoral vessels.

Femoral nerve—It is the largest branch of the lumbar plexus.

Course and relation—It arises from the dorsal branches of the ventral (anterior primary) rami of the 2nd, 3rd and 4th lumbar nerves.

In the abdomen, it descends through the fibers of the psoas major and appears at the lower and lateral border of the muscle. Then it passes in the groove between the psoas major and iliacus lying deep to the iliac fascia and enters the femoral triangle behind the inguinal ligament.

In the femoral triangle, it descends on the lateral side of the femoral artery, intervened by a small portion of the psoas major muscle and the femoral sheath. It ends about an inch below the inguinal ligament by spliting into anterior and posterior divisions.

a. Anterior division gives off—
   1. *Muscular branches*—To the sartorius
   2. *Cutaneous branches*—

JAYPEE BROTHERS

i. Intermediate cutaneous nerve of the thigh
ii. Medial cutaneous nerve of the thigh.

b. Posterior division gives off—
1. *Muscular branches*—To the quadriceps femoris and to the articularis genu, through the nerve to the vastus intermedius.
2. *Cutaneous branch*—The saphenous nerve.
3. *Articular branches*—To the hip joint, through the nerve to the rectus femoris and to the knee joint, through the nerves to all the three vasti.

Saphenous nerve—It is the *longest cutaneous* nerve in the body. It descends on the lateral side of the femoral artery and enters the adductor canal.

In the femoral triangle, it is much thicker than other cutaneous branches of the femoral nerve and it does not give any branch here.

Nerve to the pectineus—It arises from the femoral nerve before its division just below the inguinal ligament. It passes medially behind the femoral sheath and enters the muscle through its anterior surface.

Nerve to the sartorius—It usually arises in common with the intermediate cutaneous nerve of the thigh or it may arise separately from the anterior division of the femoral nerve.

Sartorius—It is the *longest muscle* in the body.

- *Origin*—
  1. From the anterior superior iliac spine
  2. From the upper half of the notch below it.
- *Insertion*—Into the upper part of the medial surface of the shaft of the tibia, in front of the gracilis and semitendinosus. Its insertion is inverted J-shaped. It is separated from gracilis and semitendinosus by a bursa anserina.
- *Nerve supply*—By a branch from the anterior division of the femoral nerve (2nd and 3rd lumbar).
- *Action*—
  1. It flexes the hip joint and also abducts and rotates it laterally.
  2. It flexes the knee joint and rotates it medially.

Note: Thus, when both the muscles act. the limbs are brought into such a position that the tailor generally adopts while at work (sartor = a tailor).

Iliacus—Major part of this muscle lies in the abdomen; only a small part is seen laterally in the floor of the femoral triangle.

- *Origin*—
  1. From the upper two-thirds of the iliac fossa.
  2. From the inner lip of the iliac crest.
  3. From the ventral (anterior) sacroiliac and iliolumbar ligaments.
  4. From the anterolateral aspect of the upper surface of the lateral part (mass) of the sacrum.
- *Insertion*—
  1. Mainly into the lateral side of the tendon of the psoas major.

JAYPEE BROTHERS

for detailed information on anatomy books, visit our website **www.jaypeebrothers.com,** for detailed information on

MANNAN'S REGIONAL DISSECTION AND SURFACE ANATOMY

Salient Features

- A book of great importance in the field of anatomy
- Presents an in-depth understanding of the human body and sectional procedures
- Describes various internal structures of human body that course beneath the skin, i.e. nerves, arteries, veins, etc.
- Focuses on the head, neck and face, abdomen, thorax, extremities, bones, nerves and vessels of the human body
- Includes 23 Color Plates for better understanding of the regional structures
- Also includes Appendices and Glossary to enhance the readers' learning
- Useful for the students and teachers of anatomy.

Md Ali Noor MBBS is currently working as an Estate Medical Officer at Deanston Division, Finlay Tea, Sreemangal, Dhaka, Bangladesh.



Available at all medical bookstores or buy online at www.jaypeebrothers.com

JAYPEE BROTHERS
Medical Publishers (P) Ltd.
www.jaypeebrothers.com

Join us on facebook.com/JaypeeMedicalPublishers

Shelving Recommendation
ANATOMY

ISBN 978-93-86322-11-1