our website www.jaypeebrothers.com, for detailed information on otolaryngology books, visit our website www.jaypeebrothers.com

VOLUME 6

RECENT ADVANCES IN OTOLARYNGOLOGY

HEAD & NECK SURGERY

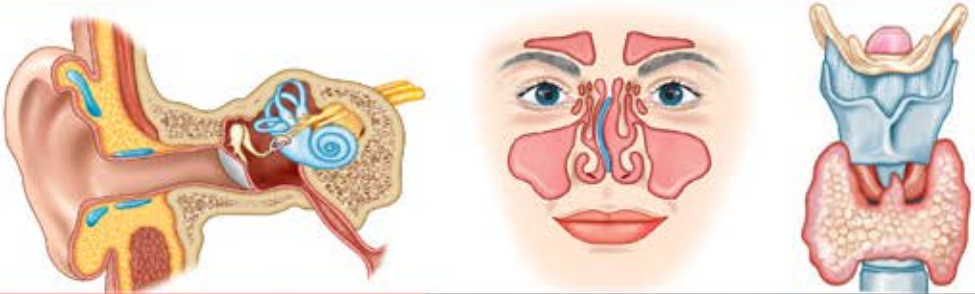

ANIL K LALWANI
MARKUS HF PFISTER

JAYPEE

Recent Advances in OTOLARYNGOLOGY Head and Neck Surgery

Vol. 6

Editors

Anil K Lalwani MD
Professor and Vice-Chair for Research
Director, Division of Otology, Neurotology and Skull Base Surgery
Director, Columbia Cochlear Implant Center
Columbia University College of Physicians and Surgeons
Medical Director of Perioperative Services
New York Presbyterian—Columbia University Medical Center
New York City, New York, USA

Markus HF Pfister MD MBA
Associate Professor of Otolaryngology—Head and Neck Surgery
Affiliated with Klinik St Anna, Lucerne, Hirslanden Group
HNO Sarnen, Switzerland
Swisstinnitus, Switzerland
Kantonsspital Obwalden
Hirslanden Klinik Meggen
Meggen, Switzerland

JAYPEE BROTHERS

JAYPEE *The Health Sciences Publisher*
New Delhi | London | Panama

Contents

1. Endoscopic Ear Surgery **1**
Nicholas Jufas, Nirmal Patel

- Endoscopic Anatomy of the Middle Ear *1*
- Indications and Applications *10*
- Advantages of Endoscopic Ear Surgery *27*
- Disadvantages and Limitations of Endoscopic Ear Surgery *30*
- Instrumentation in Endoscopic Ear Surgery *31*
- Learning Endoscopic Ear Surgery and Introduction to Practice *33*

2. Round Window Membrane as a Portal for Inner Ear Therapy **39**
Hirobumi Watanabe, Jeffrey W Kysar, Anil K Lalwani

- Background *39*
- Intracochlear Delivery—The Problem *40*
- Round Window Membrane *41*
- Changes in Drug Transport with Microperforations/Microinjection *43*

3. Gait Disturbance in the Elderly **57**
Erin Marie Mamuyac, Damiano Zanotto, Ashwini K Rao, Sunil K Agrawal, Anil K Lalwani

- Epidemiology of Falls in the Elderly *57*
- Gait Parameters *59*
- Wearable Systems for Gait Analysis *62*

4. The Microbiome in Rhinology **75**
Emily K Cope, Andrew N Goldberg

- Human Microbiome *75*
- Airway Microbiome *79*
- Airway Microbiome in Lung Disease *82*
- Sinus Microbiome and Rhinosinusitis *82*
- Host-Microbe Interactions in the Airways and Mechanisms that Perpetuate Inflammation *89*
- Future Directions *91*

JAYPEE BROTHERS

5. Current Aspects on Septal Perforations: Update on Surgical Techniques **101**
Fazil Apaydin, Markus HF Pfister
- Epidemiology *101*
- Nasal Septal Prosthesis: Individually Fitted (3D) Alloplastic Button for Closing off a Septal Perforation *116*

6. Preoperative and Postoperative Objective Diagnostic Approach in Functional Rhinosurgery **123**
Gunter Mlynski, Georgi Gogniashvili, Achim Georg Beule
- Background *123*
- Material and Methods *124*
- Results *130*
- Case 1: A 28-Year-Old Male Patient *130*
- Case 2: A 31-Year-Old Male Patient *134*
- Case 3: A 19-Year-Old Female Patient *137*
- Case 4: A 41-Year-Old Female Patient *141*
- Case 5: A 34-Year-Old Female Patient *145*
- Case 6: A 40-Year-Old Male Patient *149*
- Discussion *153*

7. Management of Cerebrospinal Fluid Rhinorrhea **159**
Jameson K Mattingly, Vijay R Ramakrishnan
- Etiology *159*
- Clinical Presentation *162*
- Evaluation *162*
- Medical Treatment *169*
- Surgical Treatment *171*

8. Minimally Invasive Concept in Transnasal Endoscopic Skull Base Surgery **181**
Anne-Katrin Hickmann, Marton Eördögh, Hans Rudolf Briner, Robert Reisch
- Introduction and Historical Background *181*
- Indications for Transnasal Skull Base Surgery *184*
- Preoperative Evaluation *184*
- Concept of Tailored Approaches *185*
- Surgical Steps toward the Sphenoid Sinus—How We do It? *186*
- Possible Intraoperative Complications and How to Manage Them? *194*

JAYPEE BROTHERS

9. Botulinum Toxin in the Treatment of Facial Synkinesis 199
Boris Paskhover, Jacqueline Diels, Anna Lyubchik, W Matthew White
- Synkinesis *199*
- Botulinum Toxin *201*
- Evaluation *202*
- Therapeutic Options *203*
- Alternative Treatments *209*

10. Options in Chin Augmentation 213
Sameep Kadakia, Jeffrey Cranford, Yadranko Ducic
- Alloplastic Chin Augmentation *213*
- Advancement Osseous Genioplasty *215*
- Soft-Tissue Augmentation *218*

11. Robotic Head and Neck Surgery 221
Steven S Hong, David W Schoppy, Meijin Nakayama, F Christopher Holsinger
- Technology and Otolaryngology *221*
- Current Application of Surgical Robots in Head and Neck Surgery *223*
- Future Application of Surgical Robotics in Head and Neck Surgery *231*

12. Advances in Radiation Therapy for Posterior Skull Base Tumors 237
Heva Jasmine Saadatmand, Cheng-Chia Wu, Tony JC Wang, Simon K Cheng
- Introduction to Posterior Skull Base Tumors *237*
- Introduction to Acoustic Neuromas *237*
- Introduction to Paragangliomas *249*

13. Advances in the Management of Pediatric Laryngotracheal Stenosis 257
Sohit Paul Kanotra, Steven Hernandez
- Causes of Pediatric Laryngotracheal Stenosis *257*
- Management of Pediatric Laryngotracheal Stenosis *258*
- Role of Laryngotracheal Stenting in Open Airway Reconstruction *262*
- Role of 3D Printing and Bioprinting in Airway Reconstruction *275*
- Role of Tissue Engineering in Airway Reconstruction *277*

Index *281*

JAYPEE BROTHERS

Chapter 1

Endoscopic Ear Surgery

Nicholas Jufas, Nirmal Patel

INTRODUCTION

In recent years, a number of key technological advances have allowed the field of endoscopic ear surgery (EES) to progress significantly. These include the development of cooler light-emitting diode (LED) light sources, high-definition three charge-coupled device (3-CCD) cameras and improved optics in compact narrow scopes. The unique advantage of the endoscope is in the placement of the objective lens into the middle ear space, giving a broad width and depth of field to the visualization of middle ear structures. This view allows a better understanding of traditionally hidden anatomical recesses of the middle ear such as the sinus tympani, anterior epitympanum and protympanum. This anatomical knowledge, in turn, has allowed a more in depth analysis of the pathophysiology of middle-ear disease. The surgeon can then redefines and reimagine the surgical anatomy with a greater appreciation for the disease/anatomy interface during the procedure.

With more experience, EES allows a more comprehensive, directed surgical clearance in the middle ear in a less-invasive manner. The technique has also demonstrated itself as ideal for teaching, with simultaneous view of the operative field by the surgeon and trainee. Conversely, when the trainee is performing the surgery, the surgical mentor can closely supervise and follow their progress with the same view. In fact, all operating room staffs have the same image, encouraging interest and engagement throughout the operation.

In this chapter, endoscopic anatomy of the middle ear will be discussed, along with indications, advantages, disadvantages and instrumentation of the EES approach. Furthermore, suggestions for introduction of the technique into practice will be offered, as well as pitfalls and pearls.

ENDOSCOPIC ANATOMY OF THE MIDDLE EAR

The classic subdivisions of the middle ear are based on the medial projection of the tympanic membrane onto the medial wall of the

JAYPEE BROTHERS

middle ear, which is known as the mesotympanum. All surrounding areas are confluent with the mesotympanum: the protympanum is anterior, the epitympanum superior, retrotympanum posterior and hypotympanum inferior (Fig. 1.1).

In the last 10 years, these areas have been studied in depth with the visualization afforded by the endoscope. Key regions and structures contained within have been classified, and knowledge of these areas is essential to confident progression with the technique.

Mesotympanum

The defining feature of the mesotympanum is the promontory, covering the basal turn of the cochlea. The tympanic branch of the glossopharyngeal (Jacobson's) nerve leaves the inferior ganglion above the jugular foramen, traverses the inferior tympanic canaliculus to enter the middle ear through or just anterior to the finiculus and travels on the promontory. The nerve is the main contributing nerve to the tympanic plexus, which lies on the promontory. The plexus is usually

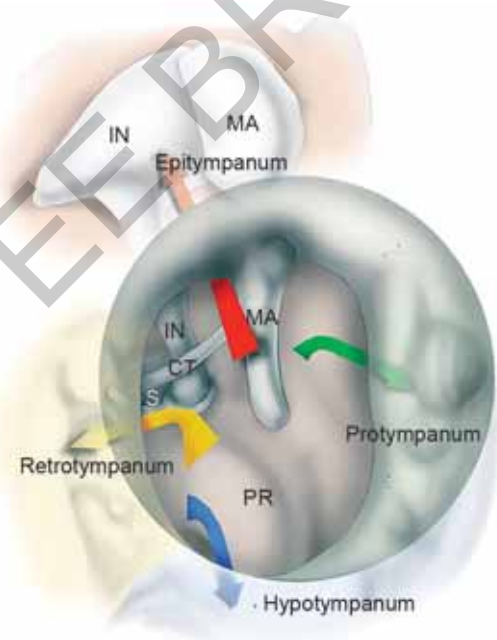

Fig. 1.1: Schematic diagram of mesotympanum, showing the confluent regions in a right ear. (CT: Chorda tympani; S: Stapes; IN: Incus; MA: Malleus; PR: Promontory)
Source: Prof Daniele Marchioni, University of Verona, Italy. Endoscopic Ear Surgery: Principles, Indications & Techniques (Presutti & Marchioni, Thieme, 2016).

JAYPEE BROTHERS

submucosal, however, the nerves may lie deeper and groove the bone and rarely are embedded in the bone of the promontory. Jacobson's nerve provides sensation to the protympanum and Eustachian tube (ET) as well conveying parasympathetic fibers that arise in the inferior salivary nucleus to the parotid gland via the otic ganglion.[1]

Epitympanum

The epitympanum contains the head of the malleus as well as the body and short process of the incus. The malleus and incus form the epitympanic diaphragm, a concept introduced by Chatellier and Lemoine in 1946,[2] building on the 19th century work of Prussak.[3] The diaphragm also contains the three malleal ligamental folds (anterior, lateral and posterior) the posterior incudal ligamental fold, the tensor fold and the lateral incudomalleal fold. The latter two are duplicate folds and have variable position and orientation dependent on outgrowth of the sacci from the ET in utero, while the other composite folds envelop fixed ligaments limiting their variability[4] (Fig. 1.2).

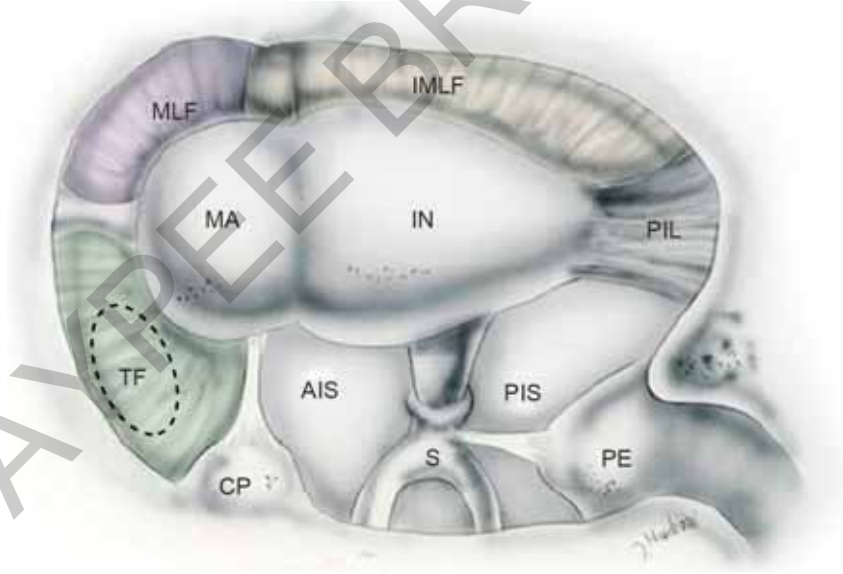

Fig. 1.2: The epitympanic diaphragm—with the main ventilation pathway through the anterior isthmus (AIS) and accessory pathways through the posterior isthmus (PIS). An alternate pathway exists in 25% of cases through an incomplete tensor fold (TF, dashed ellipse).
(S: Stapes; CP: Cochleariform process; MA: Malleus; IN: Incus; PIL: Lateral and medial posterior incudal ligaments; MLF: Lateral malleal fold; IMLF: Lateral incudomalleal fold; PE: Pyramidal eminence)
Source: Prof Marchioni—Endoscopic Ear Surgery: Principles, Indications & Techniques (Presutti & Marchioni, Thieme, 2016).

JAYPEE BROTHERS

The ventilation route primarily travels through the epitympanic diaphragm via the isthmus. The main anterior isthmus is situated between the tensor tympani tendon anteriorly and the stapes posteroinferiorly, with a variable diameter between 1 mm and 3 mm. The accessory posterior isthmus is between the short process of the incus and the stapedial muscle (Fig. 1.3).

The tensor fold occupies a strategic position, separating the anterior epitympanic space of the epitympanum from the supratubal recess of the protympanum. This provides an alternate ventilation pathway from the middle ear to the mastoid, if present, however, studies have shown that it is only incomplete and therefore able to do so in around 25% of cases.[5]

There are two described configurations of the anterior epitympanic space: (1) type I (around 80%) consists of an oblique (and occasionally vertical) tensor tympani fold that creates a smaller anterior epitympanic space and the presence of a supratubal recess; (2) type II (around 20%) consists of a more horizontally placed tensor fold, which does not allow for the presence of a supratubal recess.[6]

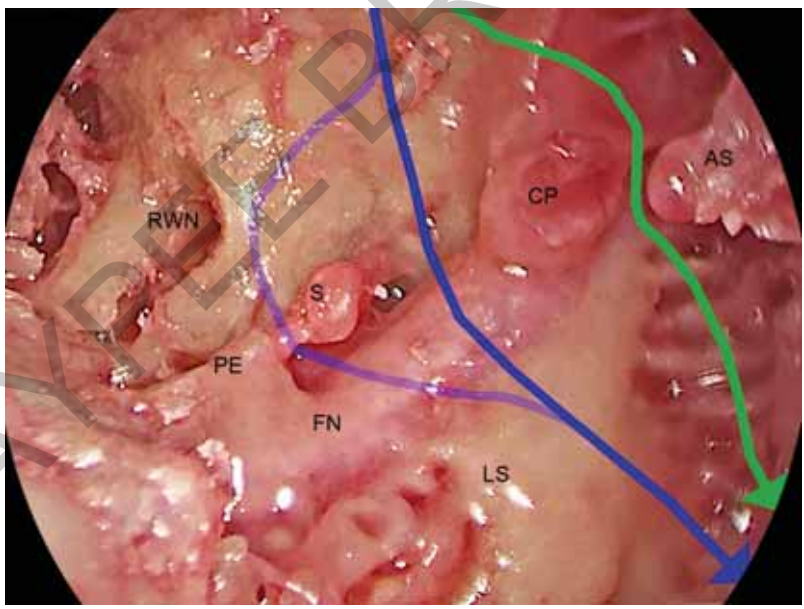

Fig. 1.3: Endoscopic view of left ear, with incus and malleus removed. Blue arrow indicates the main ventilation pathway from the Eustachian tube into the mastoid through the isthmus—with the dominant anterior pathway (solid blue) and accessory posterior pathway (faded blue) indicated. The alternate ventilation pathway through the tensor fold if incomplete is shown in green.
(S: Stapes; CP: Cochleariform process; PE: Pyramidal eminence; LS: Lateral semicircular canal; RWN: Round window niche; FN: Facial nerve; AS: Anterior spine)

JAYPEE BROTHERS

Retrotympanum

The retrotympanum is the region posterior to the mesotympanum, confluent inferiorly with the hypotympanum and superiorly with the epitympanum. The retrotympanum is divided into superior and inferior divisions by the subiculum (Fig. 1.4). The region is best viewed with angled endoscopes either in the conventional-operating position or standing on the opposite side of the patient and rolling the patient toward the surgeon.

Except where indicated, the bony structures of the retrotympanum occur as a complete ridge of bone (type A), a bridge (type B) or are absent (type C), while the spaces have variable pneumatization (Figs. 1.5 and 1.6A to C).

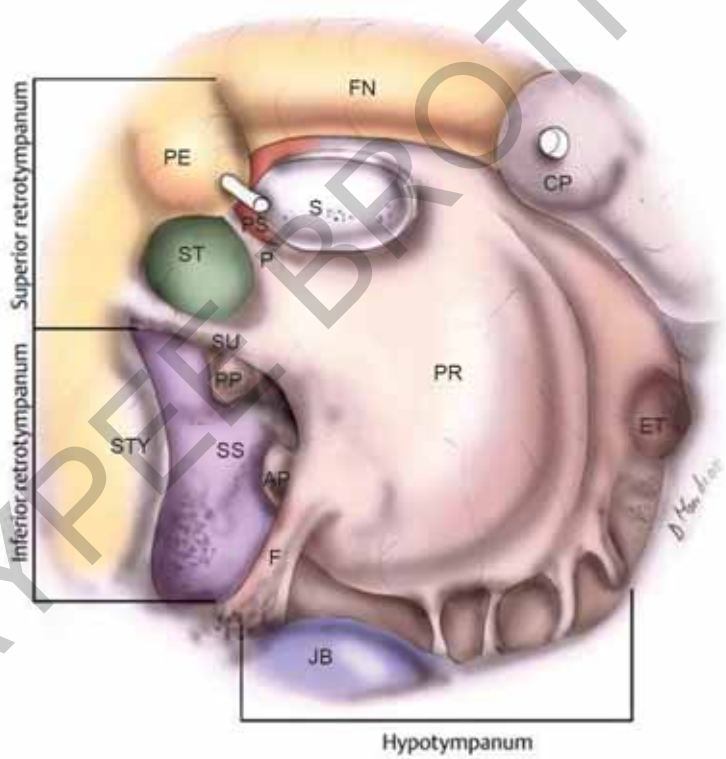

Fig. 1.4: Schematic diagram of the divisions of the retrotympanum with surrounding spaces also shown.
(PR: Promontory; S: Stapes; ET: Eustachian tube; F: Finiculus; AP: Anterior pillar; PP: Posterior pillar; JB: Jugular bulb; SS: Sinus subtympanicus; STY: Styloid complex; SU: Subiculum; P: Ponticulus; ST: Sinus tympani; PS: Posterior sinus; PE: Pyramidal eminence; FN: Facial nerve; CP: Cochleariform process)
Source: Prof Marchioni—Endoscopic Ear Surgery: Principles, Indications & Techniques (Presutti & Marchioni, Thieme, 2016).

JAYPEE BROTHERS

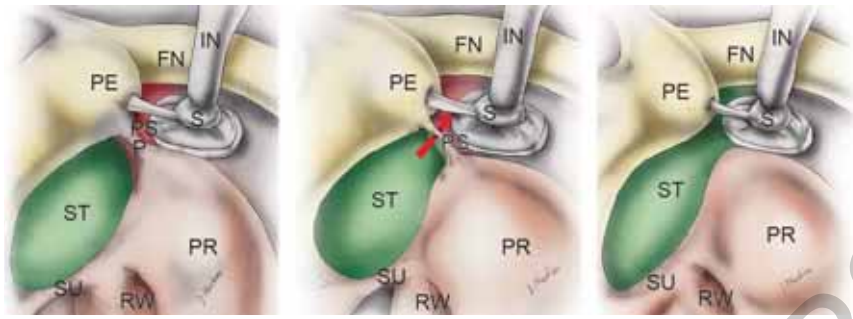

Fig. 1.5: Conformational variations on the ponticulus—type A (ridge), type B (bridge), type C (absent). Other bony ridges, such as the subiculum, finiculus and protiniculum all share the same classification.
(S: Stapes; IN: Incus; FN: Facial nerve; PE: Pyramidal eminence; ST: Sinus tympani; P: Ponticulus; PS: Posterior sinus; PR: Promontory; SU: Subiculum; RW: Round window)
Source: Prof Marchioni—Endoscopic Ear Surgery: Principles, Indications & Techniques (Presutti & Marchioni, Thieme, 2016).

Superior Division

Ponticulus: A bony structure from the pyramidal eminence to promontory.

Subiculum: A bony structure extending from the styloid eminence to the posterior pillar region of the round window (RW), separating both the superior and inferior retrotympanum and the sinus tympani from sinus subtympanicum.

Posterior sinus: A space medial to the stapedial tendon, posterior to the posterior crus of stapes, and separated from the sinus tympani by the ponticulus.

Subpyramidal space: A space medial to the pyramidal eminence and contiguous with the sinus tympani and/or posterior sinus.

Sinus tympani: A space between the ponticulus and subiculum, classified relative to pneumatization medial to the facial nerve (Figs. 1.6A to C):

- *Type A*: Anterior to the facial nerve
- *Type B*: Medial to the facial nerve
- *Type C*: Posterior to the facial nerve (inaccessible via totally endoscopic methods).[7]

Inferior Division

Fustis: A thick club-like bony prominence, extending from the styloid eminence to the RW niche, forming the basal turn of the cochlea, with two conformations (Figs. 1.7A and B):

- *Type A*: Points directly to RW membrane, leads directly to scala tympani
- *Type B*: Points inferior to RW membrane, becomes floor of scala tympani.[8]

JAYPEE BROTHERS

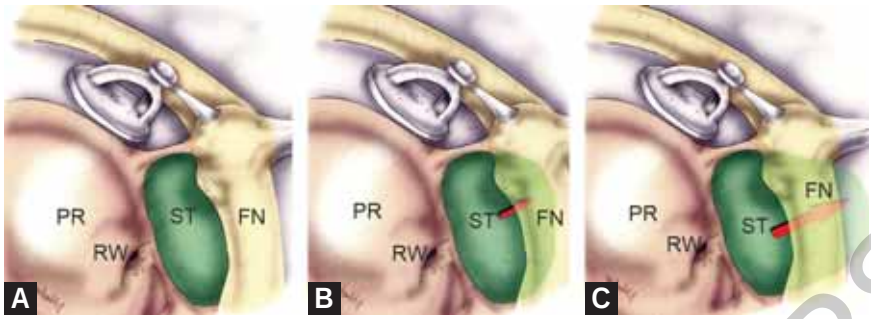

Figs. 1.6A to C: Conformational variations of the sinus tympani depth—(A) type A, shallow; (B) type B, deep; and (C) type C, very deep.
(PR: Promontory; RW: Round window; ST: Sinus tympani; FN: Facial nerve)
Source: Prof Marchioni—Endoscopic Ear Surgery: Principles, Indications & Techniques (Presutti & Marchioni, Thieme, 2016).

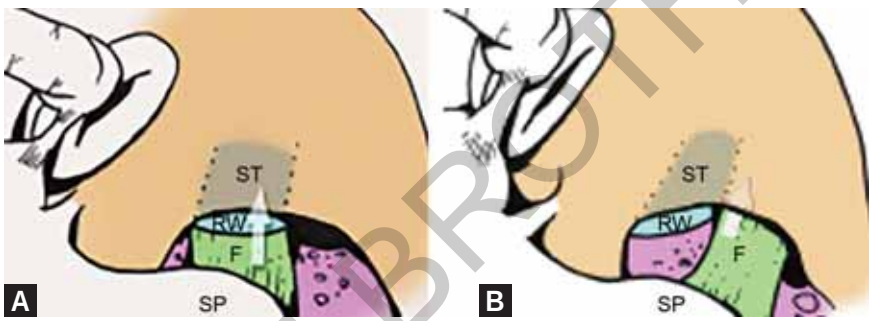

Figs. 1.7A and B: Schematic diagram depicting the two conformations of fustis (A) type A, and (B) type B.
(F: Finiculus; RW: Round window; ST: Scala tympani; SP: Styloid prominence).
Source: Marchioni D, Soloperto D, Colleselli E, Tatti MF, Patel N, Jufas N. Round window chamber and fustis: endoscopic anatomy and surgical implications. Surg Radiol Anat. 2016;38:1013-9.

Round window niche: A space covered by a bony tegmen that connects the posterior and anterior pillars, creating a niche in front of the RW membrane, which separates the middle ear from the scala tympani.

Finiculus: A bony structure variably containing Jacobson's nerve and/or the inferior tympanic artery, extending from the anterior pillar region to the floor of the hypotympanum and the region of the jugular bulb. This structure defines the inferior limit of the retrotympanum and separates it from the hypotympanum.[9]

Sinus subtympanicus: A space medial to the facial nerve and styloid prominence, contained by the subiculum superiorly and finiculus inferiorly.

Subcochlear canaliculus: A space of variable pneumatization extending between the fustis and anterior pillar/finiculus region toward the petrous apex (Figs. 1.8A to C).

JAYPEE BROTHERS

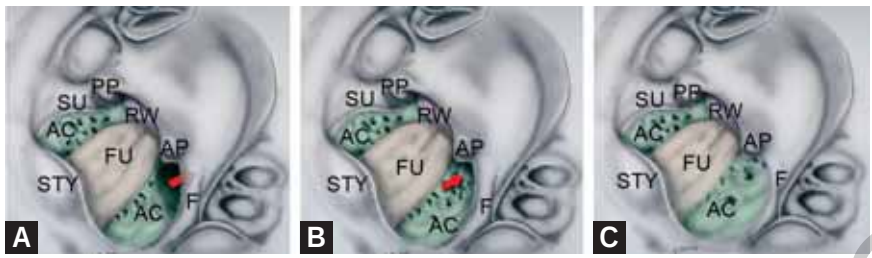

Figs. 1.8A to C: Conformational variations of the subcochlear canaliculus—(A) type A, deep; (B) type B, shallow; and (C) type C, absent.
(AC: Aria concamerata; F: Finiculus; FU: Fustis; AP: Anterior pillar; PP: Posterior pillar; RW: Round window; STY: Styloid complex; SU: Subiculum).
Source: Prof Marchioni, from Marchioni D, Alicandri-Ciufelli M, Pothier DD, Rubini A, Presutti L. The round window region and contiguous areas. Eur Arch Otorhinolaryngol. 2015;272:1103-12.

- *Type A*: Deep tunnel extending inferiorly to the petrous apex
- *Type B*: Shallow tunnel easily accessible endoscopically
- *Type C*: No tunnel.[10]

Protympanum

The protympanum, previously referred to as the bony portion of the ET, is anterior to the mesotympanum, and confluent with the epitympanum superiorly, hypotympanum inferiorly and the cartilaginous ET anteriorly. It is bound by the tegmen tympani, tensor canal and supratubal recess superiorly, and the protiniculum inferiorly. The medial boundary is the lateral wall of the carotid canal, and the lateral boundary, the protympanic recess, is a bony wall separating it from the mandibular fossa (Fig. 1.9). Carotid canal dehiscence on the medial wall of the protympanum has been identified in up to 7% of temporal bones.[11]

The protympanum can have a quadrangular or triangular conformation, when viewed in a plane perpendicular to the long axis of the ET. Demarcation between the two types is based on whether the inferior wall is more (quadrangular) or less (triangular) than half the length of the superior wall in equivalent transverse dimension.

The tensor tympani canal either sits flat or rises on the superior boundary. When an area of pneumatization is inferomedial to the tensor tympani canal is called the subtensor recess (SbTR):

- *Type A*: Flat tensor canal and absent SbTR
- *Type B*: Raised tensor canal, shallow SbTR and easily visible fundus
- *Type C*: Raised tensor canal, deep SbTR, difficult to see limits of fundus.

Demarcation between a Type B and Type C SbTR is when the fundus of the SbTR extends superior to the midpoint of the tensor tympani canal.

JAYPEE BROTHERS

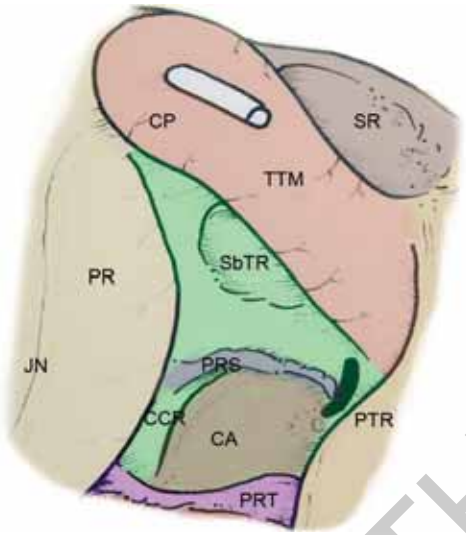

Fig. 1.9: Schematic overview of the protympanum in a right ear showing the relevant anatomical features.
(JN: Jacobson's nerve; PR: Promontory; CCR: Caroticocochlear recess; CA: Carotid artery canal; PRT: Protiniculum; PRS: Protympanic spine; PTR: Pretympanic recess; TTM: Tensor tympani canal; CP: Cochleariform process; SbTR: Subtensor recess; SR: Supratubal recess).
Source: Jufas N, Marchioni D, Tarabichi M, Patel N. Endoscopic anatomy of the protympanum. Otolaryngol Clin North Am. 2016;49:1107-19.

The protiniculum is a bony ridge commonly found extending from the promontory on the medial wall, across the inferior wall and merging with the lateral wall. It separates the hypotympanum from the protympanum and has three conformations (A: ridge, B: bridge and C: absent), similar to the bony ridges of the retrotympanum.[12]

The caroticotympanic nerves and arteries exit through channels in the bone overlying the carotid canal on the medial aspect of the protympanum. The caroticotympanic nerves carry sympathetic fibers posteriorly and cross the caroticocochlear recess, between the anterior aspect of the promontory and the carotid canal, to reach the tympanic plexus.

Occasionally, a rough spine of bony ridges or spicules is seen over the carotid artery prominence, called the protympanic spine. It is likely related to a fusion of the two laminae of the carotid canal in embryological development. If so, it may be indicative of a decreased likelihood of carotid canal dehiscence in the protympanum.[12]

Hypotympanum

The hypotympanum lies between the finiculus posteriorly and protiniculum anteriorly. It has variable pneumatization with air cells,

JAYPEE BROTHERS

which can track through into the petrous apex. The hypotympanic space can be restricted or even obliterated by a high-riding jugular bulb, which occurs in around 25% of cases.[13]

INDICATIONS AND APPLICATIONS

The endoscope should be considered an essential visualization tool for otologic surgery, complimentary to the microscope. Endoscopic and microscopic visualization should be utilized on a spectrum, which is dependent on patient, surgeon and disease factors. A proposed classification for EES, to facilitate comparison and discussion is:

- *Class 0*: Microscope only and no endoscope
- *Class 1*: Endoscopic used for inspection only
- *Class 2*: Mixed microscopic or endoscopic case
  - *Class 2a*: Endoscope used for less than 50% of dissection
  - *Class 2b*: Endoscope used for more than or equal to 50% of dissection
- *Class 3*: Endoscope only and no microscope [transcanal EES (TEES)].[14]

Cholesteatoma

Cholesteatoma of the middle-ear spaces represents the ideal situation to demonstrate the strengths of the endoscopic method. Cholesteatoma is usually subdivided into congenital and acquired forms (Boxes 1.1 and 1.2).

Box 1.1: Preoperative assessment for endoscopic ear cholesteatoma surgery.

- The lateral meatus and bony canal relative to disease location should be assessed to determine the largest endoscope size that can be used and whether a canal widening procedure (meatoplasty or canaloplasty) is required.
- The status of middle ear—whether inflamed or not will help to assist the surgeon in determining the need for preoperative topical therapy and microscopy during some of the middle ear work.
- Fine cut computed tomography of the temporal bones is essential in preoperative evaluation of cholesteatoma to determine the extent of disease. With the limitations of current instrumentation, a mastoidectomy will be required, if disease extends into the mastoid well beyond the posterior aspect of the lateral semicircular canal or into a deep type C sinus tympani.
- A non-echo-planar diffusion-weighted magnetic resonance imaging (non-EPI DWI MRI) is useful to determine mastoid, intralabyrinthine and intracranial spread. Caution is required regarding negative prediction rates in discharging ears and with disease less than 4 mm.

JAYPEE BROTHERS

Box 1.2: Optimal disease and patient characteristics for endoscopic ear surgery.

- Congenital cholesteatoma.
- Acquired cholesteatoma in mesotympanum and confluent areas (especially retrotympanum, protympanum and anterior epitympanum), with minimal mastoid extension.
- Sclerotic mastoid.
- Low tegmen.

The congenital form, in general, is more common in children and usually presents in a subspace of the mesotympanum, the most common site being anterosuperior. Using an angled endoscope the surgeon can directly visualize and elevate an inferior based tympanomeatal flap in the restricted confines of a pediatric external ear canal. Furthermore, the surgeon can directly see the disease in front of the handle of the malleus and anterior tensor tympani tendon, where this is typically blind dissection with the microscope. In most cases, little to no bone removal is required.

Acquired cholesteatoma most commonly arises in Prussak's space, the attic or mesotympanum. In all these instances, the disease, as it spreads from its origin tends to migrate into the subspaces of the middle ear including difficult to visualize regions. The endoscope allows the surgeon to trace the disease, with direct and complete visualization, from its origin to endpoint (Figs. 1.10A to F). This provides a different mindset to the microscopic approach, which in these scenarios requires drilling a significant amount of normal external canal and mastoid bone to access the disease from posterior to anterior.[15] Often with the combination of carbon dioxide (CO_2) or potassium titanyl phosphate (KTP) laser, ossicular-preserving surgery is possible with minimal to no bone removal.[16]

Visual access to certain regions of the middle ear, such as the retrotympanum, protympanum and lateral anterior epitympanum, is difficult using the microscope.[17] Using the endoscope nearly all the spaces and subspaces of the middle ear can be completely visualized with the exception of a very deep type C sinus tympani and type A subcochlear recess, allowing the surgeon a greater confidence with disease removal (Figs. 1.11 and 1.12).

Tympanoplasty

The visualization that the endoscope offers can be used to significant advantage in myringoplasty and ossicular reconstruction. Total or subtotal perforations often have an anterior margin that is difficult to see

JAYPEE BROTHERS

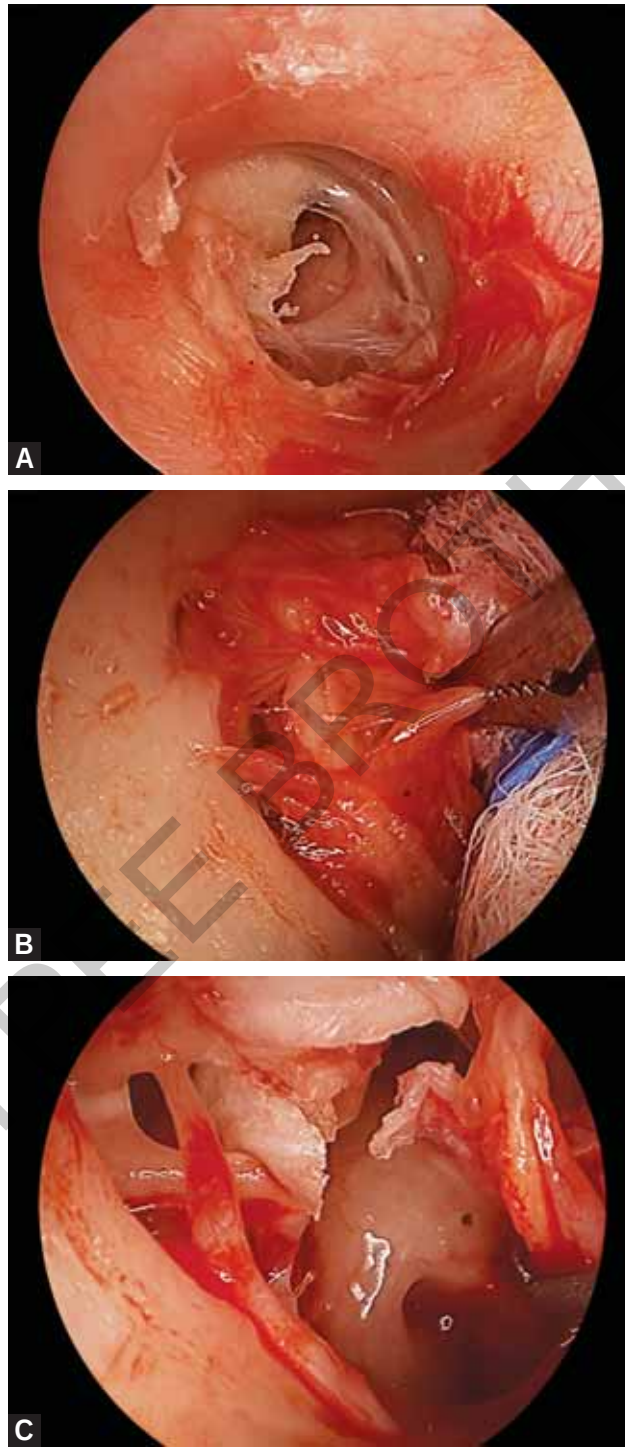

Figs. 1.10A to C: Endoscopic dissection of en plaque cholesteatoma in a right ear. (A) Initial endoscopic transcanal view. (B) Lifting and separating the tympanomeatal flap. (C) Cholesteatoma visible on the incus.

JAYPEE BROTHERS

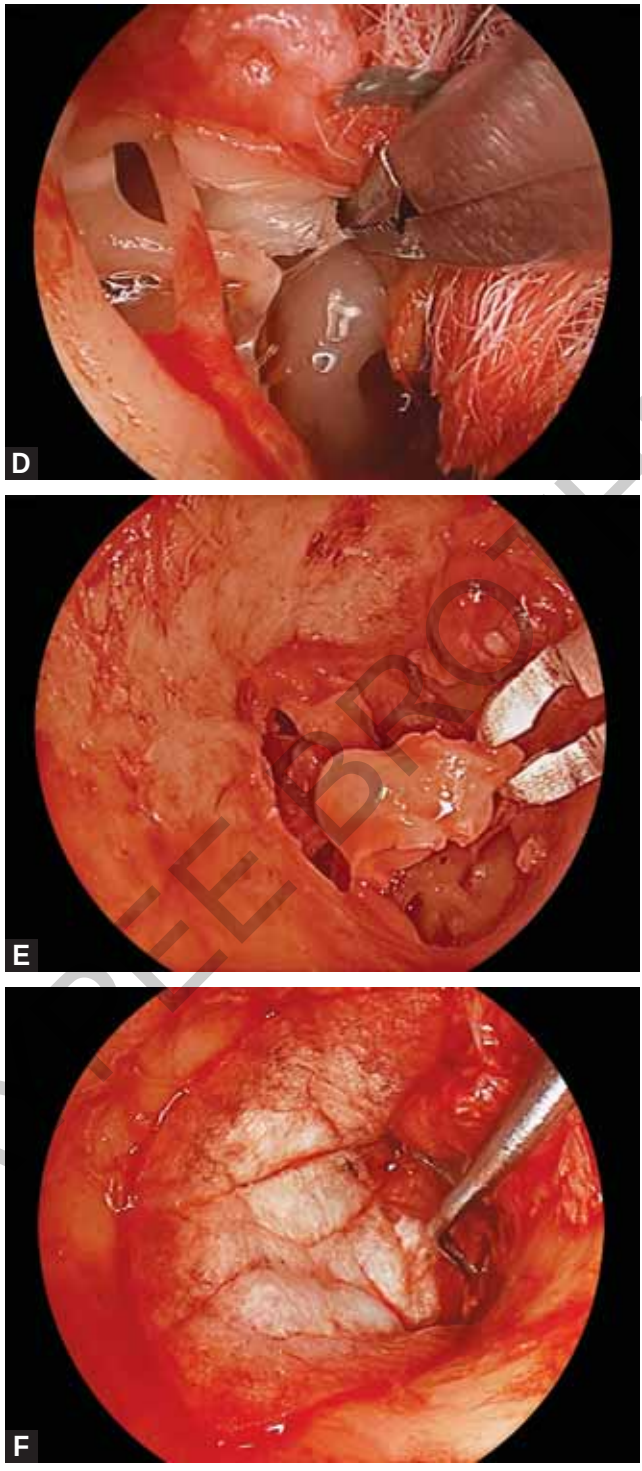

Figs. 1.10D to F: (D) Dissecting cholesteatoma off the incus. (E) Removal of the malleus head. (F) Laying in the biodesign graft.

JAYPEE BROTHERS

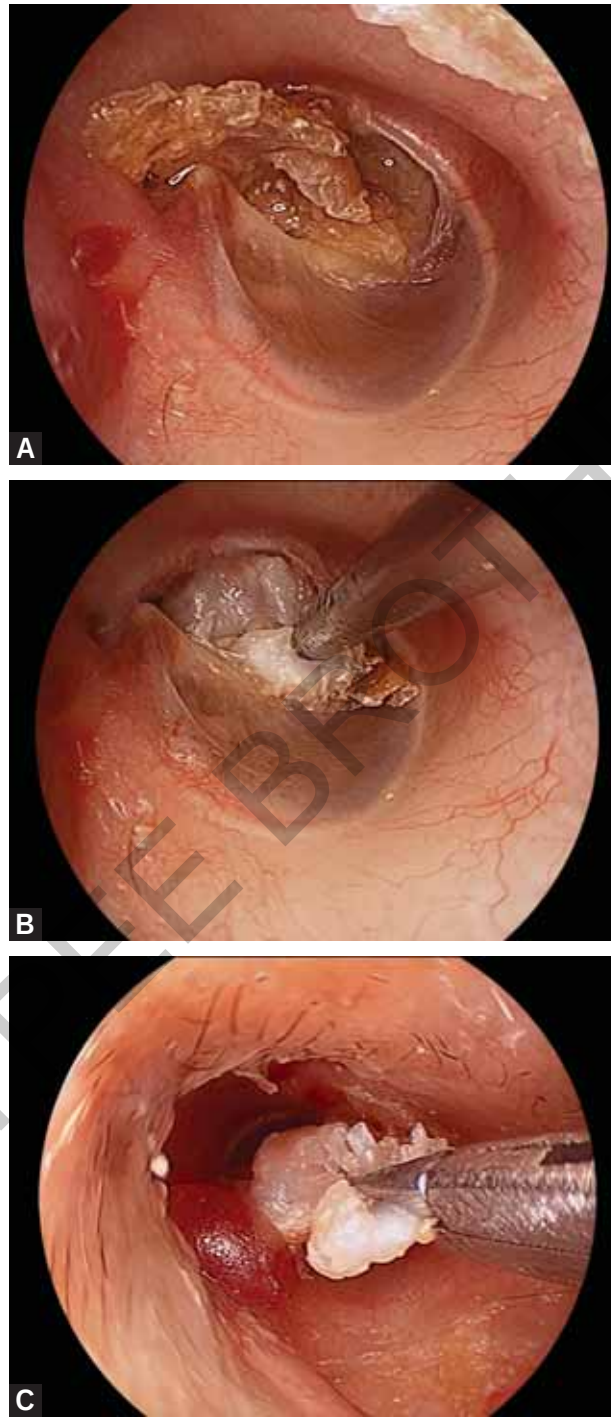

Figs. 1.11A to C: Endoscopic protympanic cholesteatoma removal in a right ear. (A) Initial endoscopic transcanal view. (B) Decompression of cholesteatoma with suction. (C) Removal of further cholesteatoma sac contents with forceps.

JAYPEE BROTHERS

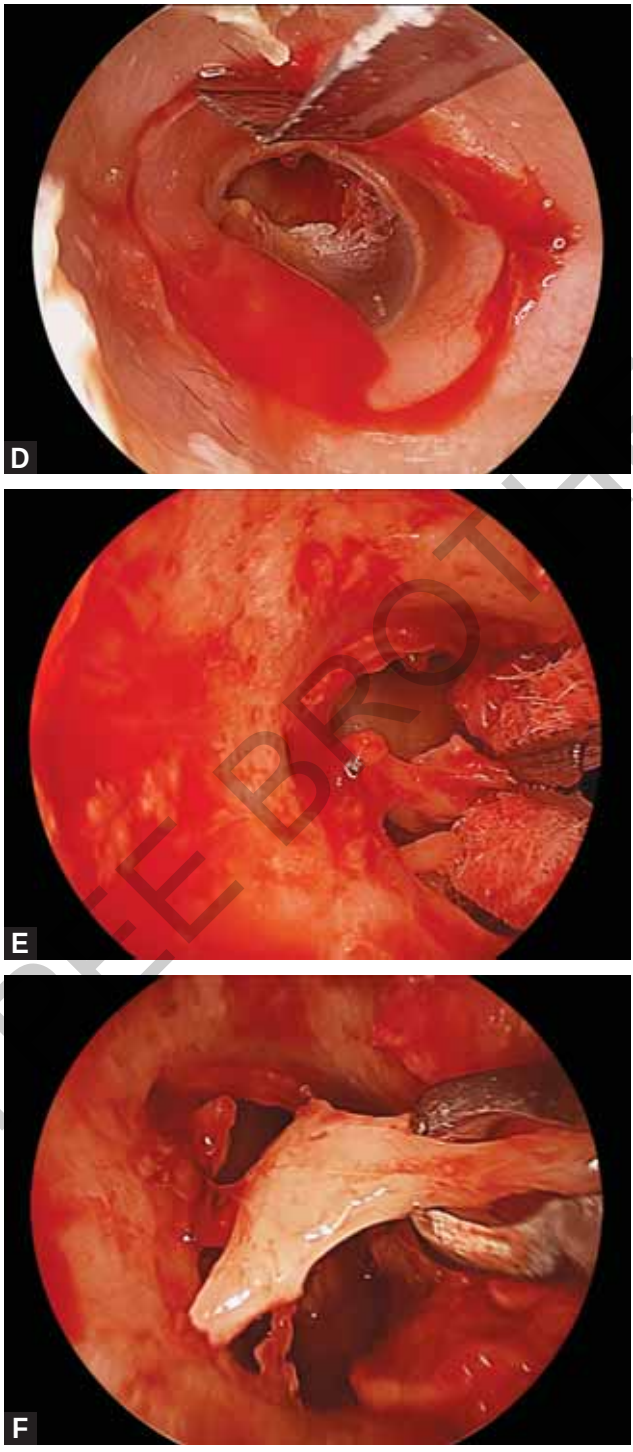

Figs. 1.11D to F: (D) Transcanal incision to raise tympanomeatal flap. (E) View of mesotympanic and protympanic spaces. (F) Removal of incus.

JAYPEE BROTHERS

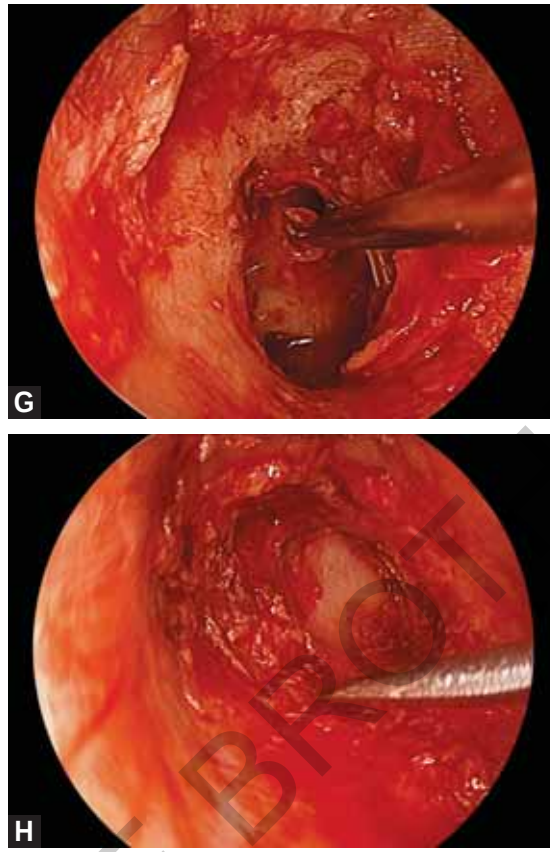

Figs. 1.11G and H: (G) Removal of protympanic cholesteatoma. (H) Replacement of tympanomeatal flap after graft.

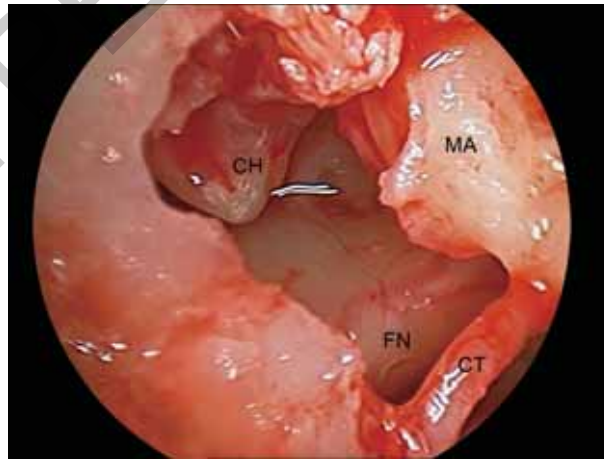

Fig. 1.12: Endoscopic view of cholesteatoma sac in right ear medial to ossicles in epitympanum after atticotomy and removal of incus.
(CH: Cholesteatoma; MA: Malleus head; FN: Facial nerve; CT: Chorda tympani)

JAYPEE BROTHERS

for detailed information on otolaryngology books, visit our website www.jaypeebrothers.com, for detailed information on otolaryngolog

Recent Advances in OTOLARYNGOLOGY Head & Neck Surgery

The 21st-century Otolaryngologist is fortunate to practice in an era of technological and technical advancement, unprecedented in the history of medicine. The pace of new knowledge very quickly leaves our prior training obsolete; the half-life of medical knowledge is now under five years. From the newest techniques for the treatment of sudden sensorineural hearing loss, medical and surgical management of pediatric airway, chin augmentation, robotics in head and neck surgery, the use of endoscope to facilitate complex surgical procedures to treat ear disease, CSF rhinorrhea or skull base surgery, the Otolaryngologist is struggling to stay abreast of innovations that directly impact patient care.

Recent Advances in Otolaryngology—Head and Neck Surgery, 6th volume has been designed to meet the need of the busy practicing clinician to efficiently keep current with what is new in each of the subspecialties of Otolaryngology. All of the chapters have been contributed by leading experts in the field. Due to its rapid publication cycle, the material is current, topical, and immediately relevant to the clinician.

Key Features

(i) New techniques

- Endoscopic Ear Surgery
- Round Window Membrane as a Portal for Inner Therapy
- Microbiome in Rhinology
- Management of CSF Rhinorrhea
- Chin Augmentation
- Robotic Head and Neck Surgery

(ii) What is different in this book as compared to its competitors?

- It covers all the subspecialties of Otolaryngology.
- Rapid publication cycle — less than 6 months from the submission of manuscript to the publication to ensure that the content is latest.
- Clear artwork rendered in color to convey new concepts and surgical approaches.
- Outstanding international editorial board.



Anil K Lalwani MD is Professor and Vice-Chair for Research in the Department of Otolaryngology at Columbia University College of Physicians and Surgeons, where he is the Director of Division of Otology, Neurotology and Skull Base Surgery, and also the Director of the Columbia Cochlear Implant Program. In addition, he is the Medical Director of Perioperative Services at New York Presbyterian—Columbia University Medical Center, leading the clinical team to achieve the best patient outcomes, higher patient satisfaction, better patient flow, and operational efficiencies. He is the Immediate Past-President of the *American Neurotology Society* and is also the President-Elect of the *American Auditory Society*.

His basic research has focused on two key areas—identifying genes that are critical for hearing through the use of molecular genetic and molecular biologic methods, and developing and investigating gene transfer technology for the treatment of hearing disorders. More recently, he has focused on the development of microneedles for inner ear therapy via the round window membrane.

Dr Lalwani's clinical interests in otology include cochlear implantation, chronic ear disease, facial nerve disorders, cerebellopontine angle tumors, and skull base surgery. He is considered one of the leading experts on hearing loss in children and adults and its surgical treatment. Dr Lalwani is the author of over 200 peer-reviewed articles, numerous book chapters, and a textbook defining the subspecialty of Pediatric Otology and Neurotology. He served as the editor of *Sataloff's Comprehensive Textbook of Otolaryngology*. The 4th edition of his second book, *Current Diagnosis & Treatment in Otolaryngology—Head & Neck Surgery* is currently in press.



Markus HF Pfister MD is an Otolaryngologist with subspecialization in Otology and Neurotology. He has been trained at the University of Tuebingen, Germany, University of California, San Francisco and Stanford University, USA, and he is academically affiliated with the University of Tuebingen, Germany. Dr Pfister has been responsible for the molecular genetics unit of hereditary hearing impairment at the Department of Otolaryngology, University of Tuebingen, and has been a member of the European Work Group on Genetics of Hearing Impairment. His interests include innovative approaches in the diagnosis and therapy of disorders in otolaryngology and head and neck surgery, particularly in otology and neurotology. Dr Pfister is considered a leading expert on hereditary hearing loss and has contributed to several international studies on hereditary hearing impairment. He is author of more than 80 peer-reviewed articles and numerous book chapters.

Available at all medical bookstores or buy online at www.jaypeebrothers.com

JAYPEE BROTHERS
Medical Publishers (P) Ltd.
www.jaypeebrothers.com

Join us on facebook.com/JaypeeMedicalPublishers

Shelving Recommendation
OTOLARYNGOLOGY

ISBN 978-93-86322-12-8