our website **www.jaypeebrothers.com,** for detailed information on orthopedic books, visit our website **www.jaypeebrothers.com**

OSCE in Orthopedics

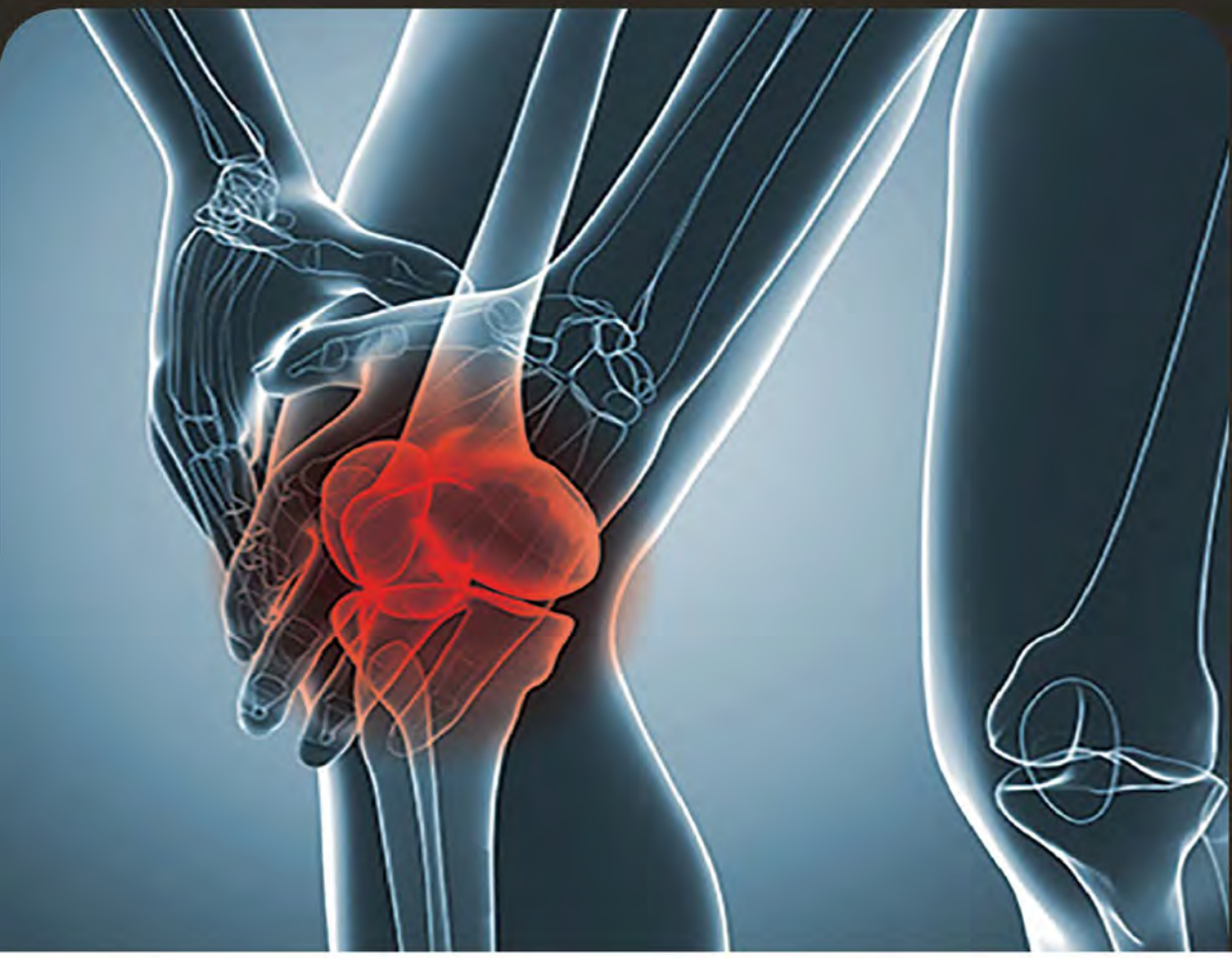

S Kumaravel

JAYPEE

Contents

Chapter 1: Basics of OSCE 1

Chapter 2: Model OSCE Problems Part 1 11

Chapter 3: Model OSCE Problems Part 2 86

Chapter 3

Model OSCE Problems Part 2



Instructions given to the Candidate

What is this plaster?
1 ½ hip spica.

What is the region that can be immobilized with this?
Upper femur injury like
- Neck of femur fractures
- Trochanteric fractures, and femoral shaft fractures



Instructions given to the Candidate

What is this appliance?
BB Splint or Bohler–Braun splint.

How will you select the length of this splint?
It has a limb rest with a genu corresponding to the knee.

What is the procedure done here?
The limb is kept in BB splint with calcaneal pin traction.

JAYPEE BROTHERS



This 45-year-old man had diffuse pain on the medial two fingers and the adjoining part of hand and distal medial forearm. He also has a swelling on the medial side of the arm which moves side-to-side and not longitudinally. There is no specific deformity of fingers.

What is the possible diagnosis of this swelling?

Nerve sheath tumour of ulnar nerve.

Why it has caused this finding?

There is possibly pressure on sensory fibers only.

Why there is no specific deformity of fingers?

Since the ulnar nerve lesion is high there may not be prominent clawing.



This boy had sudden deformity after a surgery over arm. He also had numbness over the dorsum of hand.

What is the diagnosis?

Postoperative wrist drop.

What are the components of the affected structure?

Sensory and motor.

Ability

→ Checks the autonomous region of sensory supply of this nerve.

JAYPEE BROTHERS

GECU

Exposes entire upper limbs.

Explains test in the normal limb.

Asks the patient to tell 'one' or 'yes ' if he feels the sensation of touch.

Tests the sensation of the affected side.

Tests for anesthesia present over 1st web space over the dorsal aspect and compares with the other.
Palpates the entire course of radial nerve to look for tenderness
(Radial nerve ends at the level of lateral condyle and continues as Posterior Interosseous nerve to midpoint of wrist).
Motor
Power of wrist extensor and finger and thumb extensor.

What is the treatment of this condition?
Initial – Splinting in volar cock-up splint, Nerve conduction tests if the recovery is not there, then tendon transfer



Instructions given to the Candidate

This 45-year-old smoker had severe swelling of left calf?
What are the differential diagnosis?
Deep vein thrombosis, thrombo angitis obliterans

How will you investigate?
Arterial and venous Doppler.
D-dimer ultrasound scan of popliteal region to look for intactness of the popliteal sac.





Instructions given to the Candidate

What is done to the right lower limb?
Syme's amputation.

JAYPEE BROTHERS

Name two other similar procedures at this level.
Pirogoff's amputation
Chopart's amputation.



Instructions given to the Candidate

This 14-year-old boy came with this finding, what is the diagnosis.
What he able to do in the first snap?
Flex both the elbows.

What is he is trying to do in the second snap?
Abducting the left shoulder **The undressed view of the same attempt seen from behind. What he is trying to do?**
Abducting the shoulder.



Instructions given to the Candidate

These are the clinical pictures of an adolescent boy who had pain over the tibial tuberosity. How will you examine?

In Manned Station
Look for swelling, prominence and tenderness over the tibial tuberosity.
Look for range of movement.

Flexion almost full except mild restriction in the extreme flexion.

In Unmanned Station
1. **What is the diagnosis?**
2. **What will you see in the X-ray?**
3. **What is the treatment?**

Answers

1. Osgood Schlatter's disease
2. Fragmentation of the tibial tuberosity apophysis.

3a. Extension splints, NSAIDs
3b. Excision of the fragment.

JAYPEE BROTHERS



Instructions given to the Candidate

This 40-year-old lady had pain and numbness in her hand and outer fingers of her left hand.

What is the arrow pointing in the 1st picture?
Thenar muscle wasting in the left side.

What is the arrow pointing in the 2nd picture? What is released?
The flexor retinaculum is being released.

What structure is being released as the arrow pointing in the 3rd picture?
Median nerve.

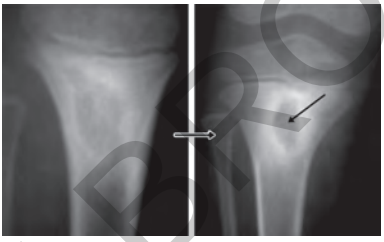

An 8-year-old girl was brought for pain in her knee joint after a dance program in her school.
The first picture showed her initial X-ray. She was diagnosed and was put on specific medication. The result was pain relief and the fresh X-ray revealed in the second picture.

What was possible diagnosis?
TB osteomyelitis.

What was the possible medication?
Anti-tuberculous medication.

In follow-ups of the child how will you assess the activity of the disease?
Periodic ESR.

What is the finding in the second X-ray that shows healing of the disease?
Sclerosis.

JAYPEE BROTHERS

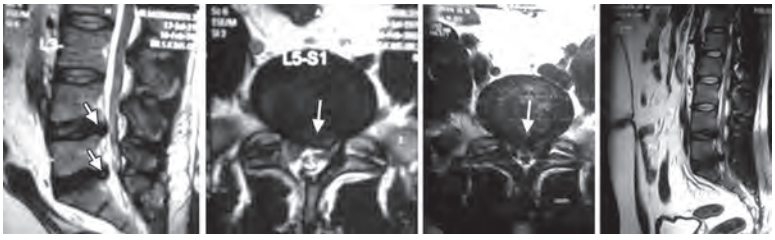

Instructions given to the Candidate

From the first MRI picture even without an X-ray LS spine lateral view can you tell if there will be sacralization or not?
There cannot be sacralization.

Why?
If so, then L5 S1 disc will be rudimentary and L5 S1 disc would have not prolapsed.

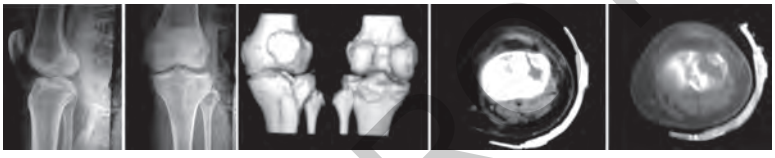

Instructions given to the Candidate

What is the diagnosis?
Split fracture of the lateral condyle.

How will you manage it?
Percutaneous cannulated cancellous screw fixation of the fracture.



Pain in the left hip since 6 months. Patient is having a persistent limp.
What is the diagnosis?
Perthe's disease.

What is the prognosis?
The entire head is involved, hence poor prognosis.

JAYPEE BROTHERS

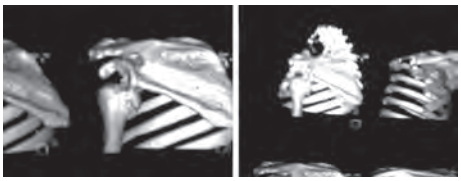

Instructions given to the Candidate

The above is the reconstruction CT of a left shoulder of a 70-year-old post-menopausal lady who had a fall 7 months back.
What is the diagnosis?
Neglected dislocation of left shoulder.

How will you manage her?
Accept the dislocation and mobilize her.



What is the scar?
Scar of an anteromedial incision.

What are the possible surgeries with this incision?
Fixation of intraarticular fragments, e.g. Tibial spine avulsion, synovectomy, arthrolysis.



A 40-year old presented with a draining sinus.
What is being done in these steps in figures 1, 2 and 3?
1. The sinus site is swabbed with antiseptic to prevent contamination
2. The sinus is milked.
3. The swab is placed in the site of the sinus to take the swab.

JAYPEE BROTHERS

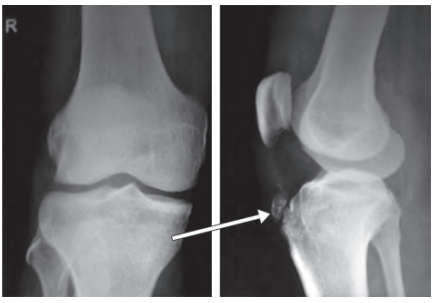

What is the possible diagnosis?

Calcification of ligamentum patella near the Tibial tuberosity.



This man has lost right arm below the shoulder level and lost his right thigh above the knee level.

He also had a fractured left distal femur

How is the patient made to raise and walk? What are pointed with the brown blue and black arrows?

His left lower limb fracture was treated with Ilizarov fixation. (left side arrow)

He was given an artificial limb (right lower arrow) for his right amputated stump.

He was made to weight bear with a support of a person.

Right upper arrow shows the amputated right upper limb.

Kumaravel S. Technique of Treating Fractures in Long Bones of Lower Limb with Associated Simultaneous Loss of Limbs in the Same Injury Complicating Their Treatment. Res J Pharmaceut Biol Chem Sci. 2015 6(4): 558-62.



This is a 45-year-old patient with renal failure. He had pain over left groin and fever. What is the procedure being done?

Hip aspiration.

JAYPEE BROTHERS

What is the landmark for the procedure?

Femoral pulse is palpated and the needle is put perpendicular to the skin, lateral to the pulsation.



Is there a deformity in the left elbow? Is there a valgus? See the X-ray also before answering?

The forearm appears in line with the arm.

There is no valgus.

How can this elbow be called?

Cubitus rectus.

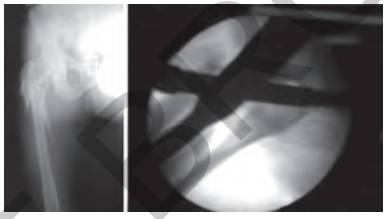

What is the fracture and the C-arm picture shown near?

Proximal femur fracture.

Proximal femoral nailing with zig.



What is the fracture?

Calcaneal fracture.

What is the problem here?

Intra-articular fracture.

What is the difficulty in treating this fracture operatively?

It is difficult to fix these fractures.

JAYPEE BROTHERS

What is the long-term result of a malunion of this fracture?
Subtalar arthritis
Peroneal tendon irritation.

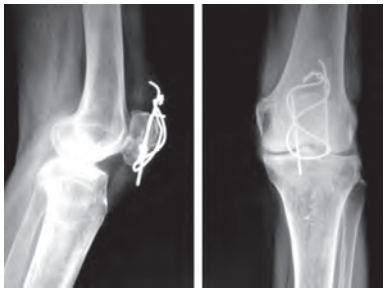

When will you mobilize the knee after this surgery?
Immediately after surgery

When it will affect the apposition of the fracture?
No, it will only compress the fracture.



What is the possible condition?
Osteoarthritis of the both knees

What is the option if pain is unbearable with conservation like drugs and physiotherapy?
Total knee replacement.

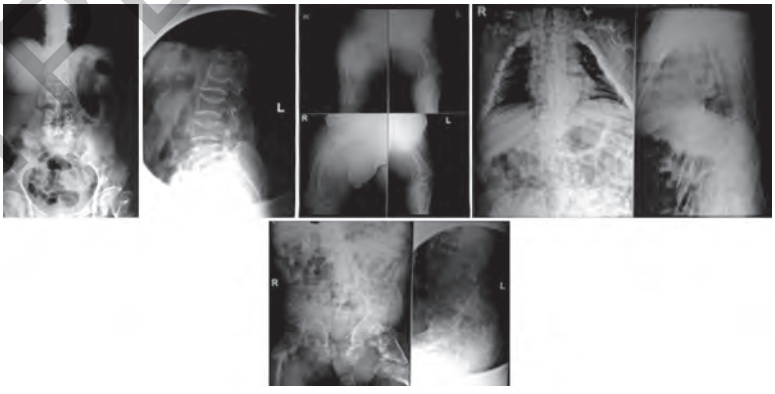

This 60-year-old gentleman had repeated fractures and came for deformity of the lower limb. He was brought in a wheelchair.

JAYPEE BROTHERS

With pain right thigh on 20-1-2011. He is a known patient of a childhood disease. Earlier in 1990 he had a hip fracture and in 1998 he had a stroke. One year later he had a fall and had a left thigh fracture. He also has increased renal parameters now.

He has right femur fracture and left distal femur fracture. What is the diagnosis?

Osteogenesis imperfecta.



These are is a clinical pictures of a 20-year-old boy.

He had a surgery done 7 years back for a crush injury of the upper limb. In the 1st picture he is asked to flex the elbow and in the 2nd he is asked to extend.

What is the surgery?

Split thickness skin grafting for crush injury and raw area

What is your diagnosis after seeing these movements?

Post-traumatic stiffness of elbow joint.

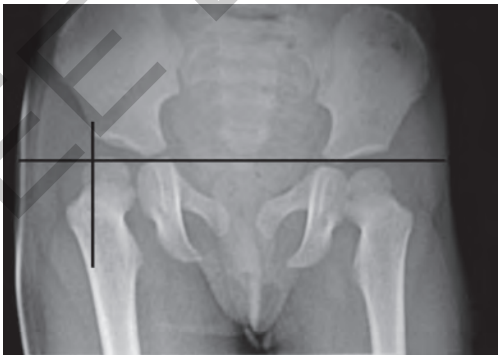

What are these lines?

Vertical lines are Perkin's lines and Horizontal lines are Hilgenreiner's lines.

What is your inference after seeing the lines?

The hip is in situ.

JAYPEE BROTHERS

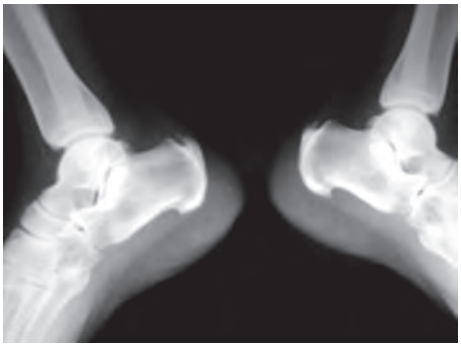

What is the view?
Lateral view of both the heels.

What are the two common indications of this view?
Retro calcaneal bursitis, plantar fasciitis.

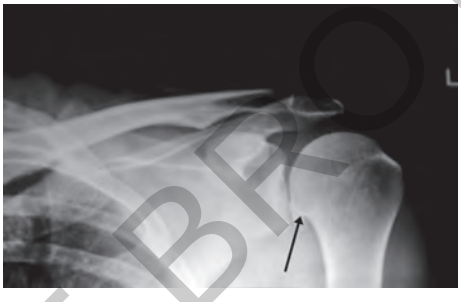

In the glenohumeral joint what is pointed? Is it coomon to see this here?
An osteophyte.
No, it is not common.

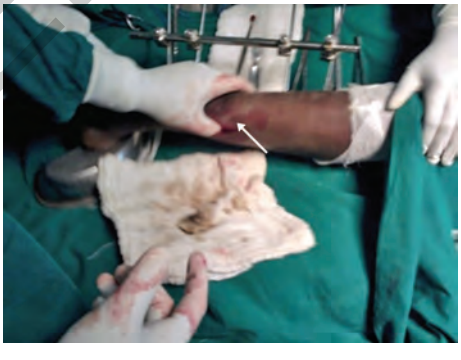

This 30-year-old trauma victim had an external fixation done 1 month back. He was taken for a surgery to improve his chances of union. The incision pointed is on the lateral side. A material which was harvested is seen on a pad.

JAYPEE BROTHERS

for detailed information on orthopedic books, visit our website www.jaypeebrothers.com. for detailed information on orthopedic

OSCE in Orthopedics

Salient Features

- A simple workbook on OSCE pattern of examination in orthopedics
- Includes more than 400 clinical cases with different type of questionnaires
- Provides answers either as written by the candidates or what is expected from them in such a situation. Both forms are presented together
- For the surprise factor which is normally seen in these type of examinations, the problems are mixed up so that the mind of the student gets itself prepared
- The onus in OSCE is on the examiners to set up an ideal OSCE with clean questioning. In that aspect, this book will be useful for them also
- Useful in examinations like the PG-NEET, entrance exams, and in institutions where OSCE like problem-oriented cases are discussed
- Effective in regular theory examinations, especially writing a crisp short note both for undergraduates and postgraduates.



S Kumaravel MS (Ortho) D (Ortho) DNB (Ortho) PhD (Biomed Instrument) is an orthopedic surgeon. He is a researcher orthopedic surgeon, Thanjavur Medical College, Thanjavur, Tamil Nadu, India. He has extensive experience in research work and has a proven record in organizing good clinical trials. He has more than 100 scientific papers. He has many awards to his credit, including the Best Research Paper award of the Indian Orthopaedic Association and the Best Doctor award of The Tamil Nadu Dr MGR Medical University.

He is in the editorial board of many journals, including the South Asian Society Technology and Research Community journal, International Journal of Applied Science and Mathematical Theory and Journal of Orthopaedic Management. He is also Reviewer for many journals, including the medical journal of DY Patil University and The Tamil Nadu Dr MGR Medical University.

He has authored *Short Cases in Orthopedics for PG Practical Examination* published by Jaypee Brothers Medical Publishers. He has conducted seven CMEs. He was part of a team organizing one international conference, three state conferences and one Indian Orthopaedic Association.

Available at all medical bookstores or buy online at www.jaypeebrothers.com

JAYPEE BROTHERS Medical Publishers (P) Ltd.
www.jaypeebrothers.com
Join us on facebook.com/JaypeeMedicalPublishers

Shelving Recommendation
ORTHOPEDICS

ISBN 978-93-86322-13-5
9 789386 322135