our website www.jaypeebrothers.com, for detailed information on dermatology books, visit our website www.jaypeebrothers.com



# DERMOSCOPY in Darker Skin

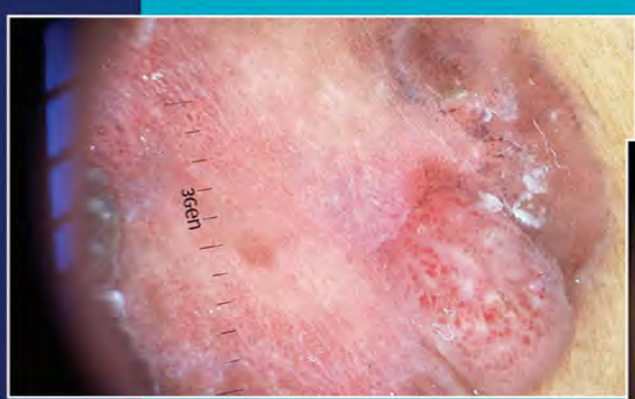

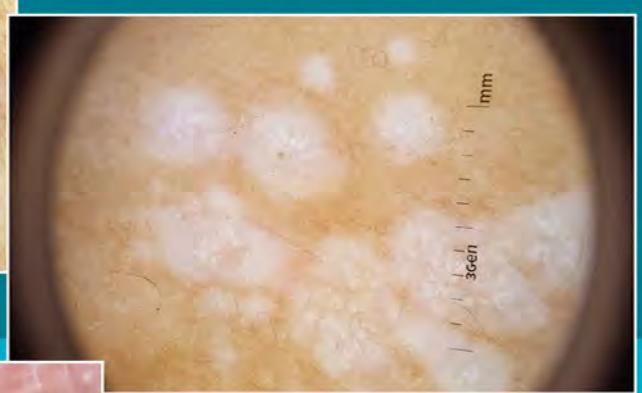

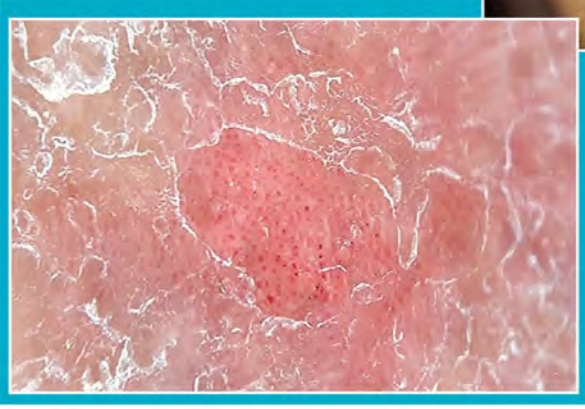

*Editors-in-Chief*
**Manas Chatterjee**
**Shekhar Neema**
**Subrata Malakar**

*Assistant Editors*
**Biju Vasudevan**
**Disha Dabbas**

*Foreword*
**Thomas Ruzicka**

JAYPEE

# Contents


## Section 1 Basics of Dermoscopy
*Subrata Malakar*

**Chapter 1. Introduction to Dermoscopy** 3
*Biju Vasudevan, Shekhar Neema*
How Does a Dermoscope Work? *3*
Principles of Dermoscopy *4*
Basis of Dermoscopic Study *4*
Uses and Advantages of Dermoscopy *5*
Limitations of the Dermoscope *5*

**Chapter 2. Types of Dermoscope** 7
*Shekhar Neema, Manas Chatterjee*
Polarizing vs Nonpolarizing Dermoscope *7*
Handheld Dermoscope or Video Dermoscope *7*
Dermlite Dermoscopes *7*
Heine Dermoscopes *8*
Other Handheld and Video Dermoscopes *8*
Which One to Buy? *8*
How to Click Best Dermoscopic Images: Tips and Tricks *9*
How to Archive Dermoscopic Images *9*

**Chapter 3. Basic Patterns on Dermoscopy** 12
*Purva Mehta, Subrata Malakar, Barnali Chowdhury, Protibha Pradhan*
**Vascular Patterns 12**
Vascular Patterns *12*
**Melanocytic Patterns 20**
Colors *20*
Pigmented Network *20*
Parallel Patterns or Acral Patterns *20*
Dots and Globules *20*
Cobblestone Morphology *21*
Starburst Pattern *21*
Homogenous Blue Pigmentation *21*
Warning Signals of Melanoma *21*

## Section 2 Disorders of Pigmentation
*Manas Chatterjee*

**Chapter 4. Melasma** 25
*Shekhar Neema, Manas Chatterjee*
Melasma *25*

**Chapter 5. Nonmelasma Facial Melanoses** 27
*Shekhar Neema, Manas Chatterjee*
Lichen Planus Pigmentosus *27*
Pigmented Contact Dermatitis or Riehl-like Melanosis *28*

Erythema Dyschromicum Perstans or Ashy Dermatoses *29*
Maturational Dyschromia or Maturational Hyperpigmentation *29*
Acanthosis Nigricans *30*
Pigmentary Demarcation Line *30*

**Chapter 6. Other Disorders of Hyperpigmentation** **31**
*Shekhar Neema*
Primary Cutaneous Amyloidosis *31*
Acanthosis Nigricans *32*
Dowling-Degos Disease *32*
Acropigmentation of Kitamura *33*
Fixed Drug Eruption *33*

**Chapter 7. Vitiligo and Other Disorders of Hypopigmentation** **35**
*Shekhar Neema, Niti Khunger*
Vitiligo *35*
Differentiating Vitiligo from Idiopathic Guttate Hypomelanoses *36*

**Chapter 8. Differentiation of Nevus Depigmentosus, Ash Leaf Macules and Nevus Anemicus** **39**
*Surit Malakar, Samipa Mukherjee*
Normal Pigmentary Pattern on Skin *39*

**Section 3 Papulosquamous Disorders**
*Shekhar Neema*

**Chapter 9. Papulosquamous Disorders** **45**
*Shekhar Neema*
Psoriasis *45*
Lichen Planus *49*
Pityriasis Rosea and Pityriasis Rubra Pilaris *51*

**Section 4 Infectious Disorders**
*Manas Chatterjee*

**Chapter 10. Infectious Disorders** **55**
*Shekhar Neema, Manas Chatterjee*
Scabies *55*
Pediculosis *55*
Viral Infection *56*
Fungal Infections *56*

**Section 5 Autoimmune and Granulomatous Disorders**
*Subrata Malakar*

**Chapter 11. Autoimmune Diseases** **63**
*Rahul Arora, Shekhar Neema*
Discoid Lupus Erythematosus *63*
Lichen Sclerosus Et Atrophicus *64*
Morphea *65*
Systemic Sclerosis *65*

**Chapter 12. Dermoscopy of Granulomatous Disorders** **67**
*Uday Khopkar, Shubhangi Mahajan*
Lupus Vulgaris *67*
Tuberculosis Verrucosa Cutis *67*
Post-kala-azar Dermal Leishmaniasis *68*
Borderline Lepromatous Hansen's Disease *68*

## Section 6 Skin Tumors

*Subrata Malakar*

**Chapter 13. Benign and Premalignant Tumors of Skin** **75**
*Subrata Malakar*
Dermatofibroma *75*
Angiokeratoma *76*
Bowen's Disease *77*
Keratoacanthoma *77*
Seborrheic Keratosis *78*
Sebaceous Hyperplasia *79*

**Chapter 14. Dermoscopy of Malignant Cutaneous Tumors** **81**
*Lakshmisha Chandrashekhar, Biswanath Behera*
Dermoscopy of Basal Cell Carcinoma *81*
Dermoscopy of Squamous Cell Carcinoma and Keratoacanthoma *82*
Dermoscopy of Malignant Melanoma *82*
Dermoscopy of Bowen's Disease *84*
Dermoscopy of Actinic Keratosis *84*

## Section 7 Onychoscopy

*Nirmal B*

**Chapter 15. Onychoscopy** **89**
*Nirmal B*
Relevant Anatomy of Nail Unit *89*
Indications of Onychoscopy in Dermatology *89*
Subungual Hematoma *90*
Pseudomonas Superinfection *90*
Onychomycosis *90*
Psoriasis *90*
Nail Melanonychia *90*
Nailfold Capillaroscopy *90*

## Section 8 Trichoscopy

*BS Chandrashekhar*

**Chapter 16. Trichoscopy** **97**
*BS Chandrashekhar, Samipa S Mukherjee*
**Normal Scalp 97**
Hair *97*
Interfollicular Space *97*
Pigmentary Pattern *97*
Vascular Pattern *98*
Scales *99*
**Trichoscopy of Nonscarring Alopecias 100**
Patterned Hair Loss *100*
Alopecia Areata *100*
Alopecia Areata Incognito *102*
Telogen Effluvium: Acute and Chronic *104*
Trichotillomania *104*
Nutritional Deficiency *105*
Congenital Atrichia with Papular Eruption *106*
Congenital Triangular Alopecia *106*

**Trichoscopy of Scarring Alopecias 108**
Lichen Planopilaris *108*
Frontal Fibrosing Alopecia *108*
Discoid Lupus Erythematosus *108*
Tractional Alopecia *111*
Folliculitis Decalvans *112*
Pseudopelade of Brocq *112*
**Trichoscopy of Scaly Scalp Conditions 113**
Seborrhea Capitis or Pityriasis Sicca *113*
Scalp Psoriasis *114*
Seborrheic Dermatitis *114*
Pityriasis Amiantacea *114*
Scale Mimickers: Hair Color Residue and Nits *114*
**Tinea Capitis 117**
Classification *117*

## Section 9 Miscellaneous
*Shekhar Neema*

**Chapter 17. Disorder of Vessels 121**
*Shekhar Neema*
Vascular Anomalies (Malformations and Hemangioma) *121*
Pyogenic Granuloma *122*
Lymphangioma Circumscriptum *124*
Vasculitis, Venous Disorders and Pigmented Purpuric Dermatoses *124*

**Chapter 18. Dermoscopy in Nevoid Disorders 127**
*Nilendu Sarma, Balachandran Ankad*
Nevus Depigmentosus *127*
Congenital Melanocytic Nevus *128*
Nevus Spilus *129*
Becker's Nevus *130*
Nevus Sebaceous *131*
Epidermal Nevi *132*
Shagreen Patch *132*

**Chapter 19. Dermoscopy of Miscellaneous Disorders 134**
*Sukesh MS*
Phrynoderma *134*
Keratosis Pilaris *134*
Trichostasis Spinulosa *137*
Follicular Lichen Planus *138*
Follicular Eczema *139*
Sebaceous Hyperplasia *141*
Rosacea *141*
Human Papillomavirus Infections *142*
Porokeratosis *142*
Arsenic Keratosis *143*
Terra Firma-Forme Dermatosis *143*

***Index* *147***

# 2 SECTION

# Disorders of Pigmentation

*Manas Chatterjee*

## *Section Outline*

- Melasma
- Nonmelasma Facial Melanoses
- Other Disorders of Hyperpigmentation
- Vitiligo and Other Disorders of Hypopigmentation
- Differentiation of Nevus Depigmentosus, Ash Leaf Macules and Nevus Anemicus

JAYPEE BROTHERS

4

CHAPTER

# Melasma

*Shekhar Neema, Manas Chatterjee*

JAYPEE BROTHERS

## INTRODUCTION

Melasma is an acquired hypermelanosis of uncertain etiology that occurs exclusively in sun-exposed areas, mostly on face and rarely on neck and forearms.[1] It is more common in women and in Asians. Exact pathogenesis is unknown, however, genetic predisposition and ultraviolet light exposure seems to play an important role.[2]

## MELASMA

Diagnosis of melasma remains clinical and aided by Wood's lamp examination. Melasma needs to be differentiated from other causes of facial hypermelanoses like pigmented contact dermatitis, lichen planus pigmentosus and erythema dyschromicum perstans. Histopathology is not performed routinely for diagnosis of facial hypermelanoses because of reluctance on part of the patient and physician, alike, as there is a risk of development of unsightly scar or postinflammatory dyschromia.

Dermoscopy of normal facial skin shows opening of sweat glands and hair follicles on the background of diffuse pigmentation creating a pseudo-network pattern. Melanin is the main chromophore in pigmented skin lesions, and anatomical location of melanin determines color perceived on dermoscopy. Melanin present in stratum corneum appears as black, dermoepidermal junction appears as brown and dermis appears as blue to gray.[3] Dermoscopy of pigmented lesions of face can be used for diagnosis as well as prognosis of the clinical condition. Color of the pigment on dermoscopy can determine depth of pigment and has obvious therapeutic implications as dermal pigment is difficult to treat by conventional therapy. Dermoscopic pattern in melasma has been described as reticuloglobular pattern, perifollicular brown black globules, arcuate and honeycomb-like pattern (Figs 1 to 5).[4-6]

Dermoscopy is also useful for detection of adverse effects of therapy. It is useful for detection of exogenous ochronosis and steroid-induced telangiectasia and atrophy of skin. Dermoscopic features of exogenous ochronosis have been described as blue-gray, brown-gray, amorphous areas obliterating follicular openings; a "worm-like" pattern has also been described.[7-9]

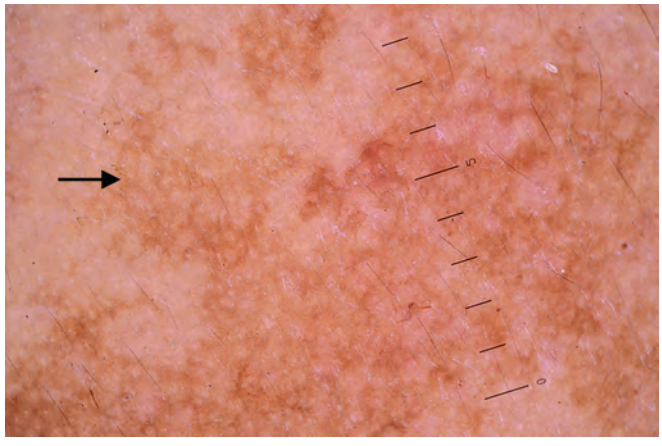

**Fig. 1**: Reticuloglobular pattern—reticular pigmented pattern accentuated with globules of pigment and network of pigment is broken with acrosyringium (black arrow)



**Fig. 2**: Granular pigment on background of reticular pigment suggestive of dermal component of melasma

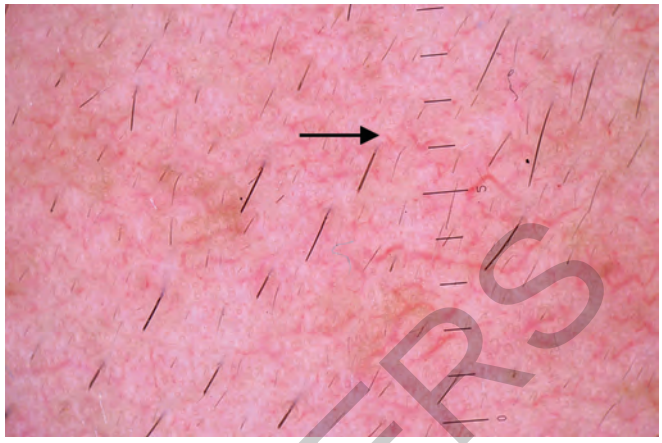

**Fig. 5**: Telangiectasia in partially treated case of melasma with triple combination suggestive of steroid damaged face. Dermoscopy can be used for rapid screening of patients prior to prescribing them triple combination therapy as many patients come after self-medication with topical steroid containing cream



**Fig. 3**: Unpatterned or nonspecific pattern

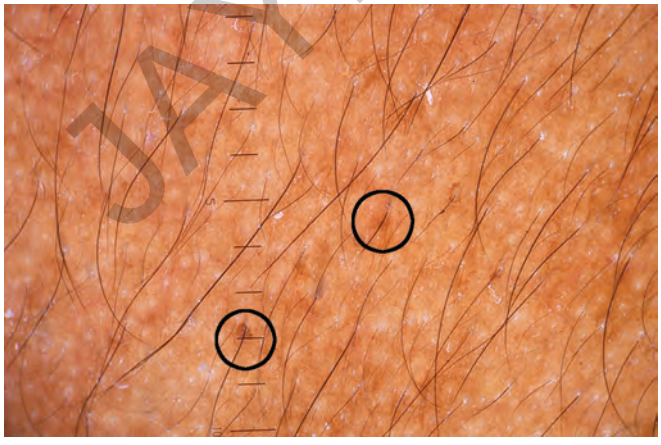

**Fig. 4**: Perifollicular accentuation of pigmentation on background of reticular pigmentation (black circle)

## CONCLUSION

Dermoscopy is a useful tool for diagnosis and prognosis of melasma. It can be used as a screening tool in all cases of melasma before starting steroid-based triple combination therapy as first-line agent and during follow-up, as many patients come after self-medicating with topical steroid cream and early signs of steroid damage may not be detectable with naked eye examination alone.

## REFERENCES


1. Bandyopadhyay D. Topical treatment of melasma. Indian J Dermatol. 2009;54:303-9.
2. Handel AC, Miot LD, Miot HA. Melasma: a clinical and epidemiological review. An Bras Dermatol. 2014;89:771-82.
3. Mahajan SA. Melasma. In: Khopkar U (Ed). Dermoscopy and Trichoscopy in Diseases of Brown Skin, 1st edition. New Delhi: Jaypee; 2012. pp. 50-9.
4. Li Y, Liu J, Sun QN. Characteristic Dermoscopic Features of Melasma. Zhongguo Yi Xue Ke Xue Yuan Xue Bao. 2015,37:226-9.
5. Tamler C, Fonseca RMR, Pereira FBC, Barcauí CB. Classificação do melasma pela dermatoscopia: estudo comparativo com lâmpada de Wood. Surg Cosmetic Dermatol. 2009;1(3):115-9.
6. Stolz W. Color Atlas of Dermoscopy, 2nd edition. Berlin: Blackwell Wissenschafts-Verlag G; 2002. pp. 121-31.
7. Charlín R, Barcaui CB, Kac BK, Soares DB, Rabello-Fonseca R, Azulay-Abulafia L. Hydroquinone-induced exogenous ochronosis: A report of four cases and usefulness of dermoscopy. Int J Dermatol. 2008;47:19-23.
8. Gil I, Segura S, Martínez-Escala E, Lloreta J, Puig S, Vélez M, et al. Dermoscopic and reflectance confocal microscopic features of exogenous ochronosis. Arch Dermatol. 2010;146:1021-5.
9. Khunger N, Kandhari R. Dermoscopic criteria for differentiating exogenous ochronosis from melasma. Indian J Dermatol Venereol Leprol. 2013;79:819-21.


JAYPEE BROTHERS

for detailed information on dermatology books, visit our website www.jaypeebrothers.com, for detailed information on dermatolog

# DERMOSCOPY in Darker Skin

***Salient Features***

- Dermoscopy relevant to clinical practice in the Indian subcontinent and similar skin worldwide
- Stress on a wide gamut of diffuse pigmentary disorders of face and other parts of the body
- Emphasis on nonpigmentary conditions which look different in pigmented skin
- Highly illustrative with annotated images and relevant highly concise text ideal for day-to-day in-clinic use
- Maximum stress on chapters based on conditions most commonly seen in countries of relevance
- Ideal for both beginners and regular users of dermoscopy.



**Manas Chatterjee** graduated from AFMC with distinction and the OP Malhotra Gold Medal in Medicine. He completed MD from the same institution and DNB thereafter. He has served the Indian Armed Forces since the past 26 years, earning the Chief of Army Staff Commendation for distinguished service. He has been past Associate Professor at his alma mater and is presently Senior Adviser, Professor and Head (Dermatology), Institute of Naval Medicine, INHS Asvini, Mumbai, Maharashtra, India. He is postgraduate examiner at six universities. He is immediate past Chairman of IADVL Academy of Dermatology. He is the present President of Association of Cutaneous Surgeons in India and co-founder of the ACSI Dermatosurgery Registry. He has conducted multiple dermatosurgery workshops and is an accomplished quizmaster. He is Managing Editor and Associate Editor of Indian Journal of Dermatology, past and present editorial board member, associate and section editor of 7 journals and has been invited as orator and guest speaker more than 250 times in India and abroad with more than 55 indexed publications and chapters in 15 textbooks to his credit in addition to being editor of two books. He is the winner of several fellowships, scholarships and research grants in his speciality and has been involved in the design and conduct of 5 multicentric trials. His interests include dermatosurgery, pigmentary disorders and photography in dermatology.



**Shekhar Neema** is an alumnus of Armed Forces Medical College, Pune, Maharashtra, India. He excelled in MBBS with ten distinctions to his name and was awarded President Gold Medal for best academic record in the year 2006. He was awarded gold medal from Maharashtra University of Health Sciences (MUHS) in MD Dermatology. He has done ISD fellowship at Ludwig Maximilian University of Munich, Germany. He has more than 20 publications in indexed journals and has authored 4 chapters in various textbooks. Immunodermatology, dermatotherapeutics, dermatosurgery and dermoscopy are his special interest areas. He is presently an Assistant Professor, Department of Dermatology, Command Hospital, Kolkata, West Bengal, India.



**Subrata Malakar** is the Director of Rita Skin Foundation, Kolkata, West Bengal, India. He is the author of *An Approach to Dermatosurgery* which was published in the year 1996. He has around 85 published papers to his credit. He was invited nationally and internationally as a guest speaker and to conduct workshops in dermatosurgery.

**Available at all medical bookstores**
**or buy online at www.jaypeebrothers.com**

JAYPEE BROTHERS
Medical Publishers (P) Ltd.
www.jaypeebrothers.com

Join us on facebook.com/JaypeeMedicalPublishers

Shelving Recommendation
**DERMATOLOGY**

ISBN 978-93-86322-67-8