nformation on orthopedics book, visit our website www.jaypeebrothers.com, for detailed information on orthopedics book, visit our website www.jaypeebrothers

Get Full Access
with added features at
emedicine360.com

Celebrating 50 Years
Passion, Quality and Innovation in Healthcare Publishing

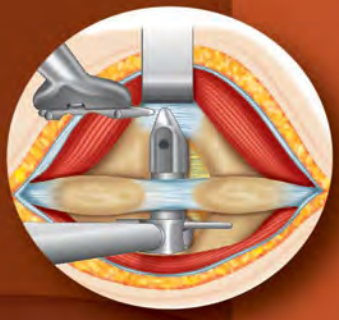

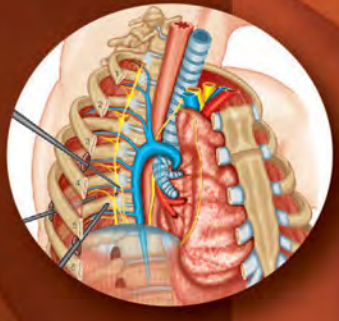





SURGICAL ATLAS *of* SPINAL OPERATIONS

2nd Edition

Jason C Eck • Alexander R Vaccaro

JAYPEE

Contents

SECTION 1: SURGICAL ANATOMY

1. **Surgical Anatomy of theTransoral Approach** 3
Kerry A Vaughan, Bradley C Lega, Jason G Newman, William C Welch, John YK Lee
- Anatomic Considerations During Surgical Planning 3
- Pharyngeal and Retropharyngeal Surgical Anatomy of the Transoral Approach 4
- Spinal Anatomy at the Craniovertebral Junction 6
- Intradural Anatomy Visible Via Transoral Approach 7
- Novel Developments 8

2. **Transmaxillary Approach to the Clivus and Upper Cervical Spine** 12
Douglas G Orndorff, Jim A Youssef, Michael A Finn, Catherine A Patty, ST DeBauche, MA Scott
- Surgical Indications *12*
- Surgical Technique Step-by-Step *13*
- Potential Complications *16*

3. **High Retropharyngeal Approach to the Upper Cervical Spine** 17
Vincent C Traynelis, Ricardo BV Fontes, Andrew J Grossbach
- Indications *17*
- Description *18*
- Postoperative Care *20*
- Potential Complications *20*

4. **Far Lateral Approach to the Craniocervical Junction** 22
Biagia La Pira, Thomas Sorenson, Pietro d'Urso, Giuseppe Lanzino
- General Considerations *22*
- Surgical Steps *23*
  - Preoperative Considerations *23*
  - Positioning *23*
  - Incision *24*
  - Muscle Dissection *24*
  - Extradural Stage *25*
  - Dural Opening and Intradural Exposure *26*
  - Closure *28*
- Complications *28*

5. **Posterior Approach to the Craniocervical Junction and Posterior Spine** 31
Chase C Woodward, Harvey E Smith
- Anatomic Considerations *31*
  - Patient Positioning and Preparation *32*
- Posterior Approach to the Upper Cervical Spine *34*
- Posterior Approach to the Subaxial Cervical Spine *35*

6. Anterior Approach to the Midcervical Spine **37**
Daniel D Bohl, Jonathan N Grauer
- Surgical Indications *39*
- Surgical Technique Step-by-Step *39*
- Potential Complications *42*

7. Anterior Approach to the Cervicothoracic Junction **44**
Eve Gail Hoffman, Brian Shiu,Tristan B Weir, Steven C Ludwig
- Low Cervical-Supraclavicular Approach *44*
  - Background *44*
  - Positioning *46*
  - Approach *46*
  - Closure *46*
- Transclavicular- Transmanubrial Approach *46*
  - Background *46*
  - Positioning *49*
  - Approach *49*
  - Closure *50*
- Transsternal-Transthoracic Approach *50*
  - Background *50*
  - Positioning *50*
  - Approach *50*
  - Closure *52*
- Complications *52*

8. Anterior Transthoracic Approach to the Cervicothoracic Junction **54**
Samuel K Cho, Sheeraz A Qureshi, Andrew C Hecht
- Anatomy *54*
- Surgical Indications *56*
- Surgical Technique Step-by-Step *56*
- Thoracic Discectomy *57*
- Thoracic Vertebrectomy *58*
- Potential Complications *58*

9. Posterolateral Approach to the Cervicothoracic Junction and Thoracic Spine **60**
Manish K Kasliwal, John E O'Toole, Vincent C Traynelis
- Surgical Indications *60*
- Surgical Technique Step-by-Step *61*
  - Transpedicular Approach *61*
  - Costotransversectomy *62*
  - Lateral Extracavitary Approach *63*
  - Parascapular Extrapleural Approach *64*
- Complications *65*

10. Thoracoabdominal Approach to the Spine **67**
Michael J Vives, John D Koerner
- Anatomy *67*
  - Diaphragm *67*
  - Nerves *68*
- Indications *68*
- Contraindications *68*

- Procedure *68*
  - Positioning *68*
  - Thoracic Approach *69*
  - Diaphragm *70*
  - Closure *72*
  - Postoperative Care *72*
- Intraoperative Complications *72*
- Postoperative Complications *72*

11. Anterior Retroperitoneal Approach to the Lumbosacral Spine **74**
Milan Bajmoczi, William P Robinson
- Approach to Lumbosacral Spine *74*
  - Preoperative Assessment *74*
  - Relevant Surgical Anatomy *75*
- Technique of Anterior Retroperitoneal Approach to the Lumbosacral Spine *75*
  - Incision and Entry into the Retroperitoneal Space *75*
  - Exposure of Specific Spinal Levels *77*
- Special Circumstances *79*
  - Reoperative Cases *79*
  - Calcified Arteries *79*
- Results and Potential Complications *79*

12. Posterior Midline and Posterolateral (Wiltse) Surgical Approach to the Lumbar Spine **82**
Christian P DiPaola, Jacob Furey
- Posterior Midline Approach to the Lumbar Spine *82*
  - Anatomy *82*
  - Indications *82*
  - Surgical Technique *82*
  - Potential Complications *83*
- Posterolateral (Wiltse) Approach to the Lumbar Spine *83*
  - Anatomy *83*
  - Indications *84*
  - Surgical Technique *84*
  - Potential Complications *85*

SECTION 2: CERVICAL SPINE TECHNIQUES

13. Anterior Cervical Diskectomy and Fusion **89**
Brian Blackburn, Swastik Sinha, Lee H Riley III
- Indications *89*
- Surgical Technique Step-by-Step *89*
- Postoperative Rehab and Restrictions *91*
- Potential Complications *91*

14. Cervical Disk Arthroplasty **93**
Bruce V Darden II, Thomas Kesman
- Surgical Indications *93*
- Surgical Technique Step-by-Step *94*
- Potential Complications *96*
- Outcomes *97*

15. Anterior Cervical Corpectomy **99**
Kelley Banagan, Howard An
- Surgical Anatomy *99*
- Indications *100*
- Technique: Anterior Cervical Corpectomy and Fusion *100*
- Case Example *101*
- Potential Complications *103*

16. Transoral Odontoid Excision **104**
David M Neils, Yazhini Gnanasambanthan, Daniel R Fassett
- Anatomy *104*
- Indications *104*
- Treatment Alternatives *104*
- Preoperative Planning *104*
- Operative Techniques *106*
  - Set-Up *106*
  - Placement of Oropharyngeal Retractors *107*
  - Opening *108*
  - Odontoidectomy *109*
  - Closure *109*
- Posterior Stabilization and Arthrodesis *109*
- Postoperative Considerations *109*
- Special Considerations/Complication Avoidance *110*
- Future Directions *110*
  - Image Guidance *110*
  - Minimal Access Surgery: Endoscopic Surgery and Robot-assisted Surgery *110*

17. Odontoid Screw Fixation **113**
Adrian T Harvey, Yazhini Gnanasambanthan, Daniel R Fassett
- Surgical Indications *114*
  - Indications *114*
  - Contraindications *114*
- Surgical Technique Step-by-Step *115*
- Postoperative Management *119*
- Potential Complications *119*

18. Occipitocervical Fusion **121**
Justin W Miller, Rick C Sasso
- Anatomy *122*
- Surgical Indications *124*
- Surgical Technique Step-by-Step *124*
  - C1 Lateral Mass Fixation *125*
  - C2 Pedicle Fixation *125*
  - C2 Translaminar Fixation *126*
  - Occipital Fixation *126*
  - Occipital Condyle Fixation *127*
  - Fusion Preparation *127*
- Potential Complications *127*

19. Posterior Atlantoaxial Arthrodesis Techniques **129**
William Ryan Spiker, Alpesh A Patel
- Anatomy and Biomechanics *129*
- Surgical Indications *129*
- Surgical Technique Step-by-Step *130*
  - Autograft Harvest *131*
  - Wiring *131*
  - Transarticular Screws *131*
  - C1–2 Segmental Fixation *132*
- Postoperative Care *133*
- Potential Complications *134*

20. Posterior Cervical Foraminotomy **136**
Meghan E Murphy, Michelle J Clarke, Mark A Pichelmann, William E Krauss
- Surgical Indications *136*
- Surgical Approach *136*
  - Anesthesia Considerations and Patient Positioning *136*
  - Exposure and Localization *137*
  - Foraminotomy *137*
  - Root Decompression *138*
  - Closure *139*
- Postoperative Care *139*
- Potential Complications *139*
- Anterior versus Posterior *140*
- Minimally Invasive versus Open *140*

21. Minimally Invasive Posterior Cervical Foraminotomy **142**
Victor G Williams, Michael J Dorsi, Langston T Holly
- Introduction *142*
  - Anatomy *142*
- Surgical Indications *142*
- Surgical Technique Step-by-Step *143*
- Potential Complications *146*

22. Posterior Cervical Laminectomy **148**
Robert F Heary, Antonios Mammis, John C Quinn
- Anatomy *148*
  - Indications and Surgical Considerations *149*
  - Location of Compressive Pathology *149*
  - Sagittal Alignment *150*
- Indications *151*
- Surgical Technique Step-by-Step *151*
- Complications *153*

23. Posterior Cervical Fusion and Lateral Mass Screw Fixation **155**
Chris Cornett, Gregory Grabowski, James Kang
- Introduction *155*
  - Anatomy *155*
  - Biomechanics *156*

- Surgical Indications *156*
- Surgical Technique Step-by-Step *157*
  - Imaging *157*
  - Anesthesia and Monitoring *158*
  - Positioning *158*
  - Draping or Prepping *158*
  - Surgical Approach or Exposure *158*
  - Instrumentation *159*
  - Preparation of Facet Joints *162*
  - Bone Grafting *162*
  - Closure *162*
- Postoperative Care and Rehabilitation *162*
- Potential Complications *163*

24. Minimally Invasive Cervical Lateral Mass Instrumented Fusion **164**
Brian Hood, Faiz Ahmad, Allan D Levi
- Indications *164*
- Advantages *164*
- Surgical Technique Step-by-Step *165*
- Potential Complications and Challenges *166*

25. Cervical Pedicle Fixation **170**
Brian W Su, Robert H Byers, Abumi Kuniyoshi
- Introduction *170*
- Anatomy *170*
- Indications *171*
- Surgical Technique *171*
  - Preoperative Planning *171*
  - Positioning and Exposure *173*
  - Identifying the Pedicle Starting Point *175*
  - Creating the Pedicle Path and Placing the Screw *175*
- Complications *177*

26. Laminoplasty **179**
John M Rhee
- Introduction *179*
  - Anatomy and Biomechanics *179*
- Indications for Procedure *179*
  - Procedure *179*
- Potential Complications *186*
  - Axial Neck Pain *186*
  - Loss of Lordosis *186*
  - Wound Complications *186*
  - Neurologic Injury *186*

27. Posterior Cervicothoracic Osteotomy **188**
Justin K Scheer, Vedat Deviren, Sang-Hun Lee, Christopher P Ames
- Introduction *188*
  - Anatomy and Biomechanics *188*
- Surgical Indications *188*
  - Smith-Petersen Osteotomy *191*
  - Cervicothoracic Junction PSO *191*

- Surgical Technique Step-by-Step *192*
- SPO with Controlled Anterior Osteoclasis *192*
- Cervicothoracic Junction PSO *193*
- Potential Complications *195*

SECTION 3: THORACIC SPINE TECHNIQUES

28. Posterior Thoracic Diskectomy Techniques **201**
Ameet Chitale, George Ghobrial, Srinivas Prasad
- Introduction *201*
- Anatomy *201*
- Surgical Indications *202*
  - Indications for Posterior Thoracic Diskectomy *202*
  - Localization of Correct Thoracic Level *204*
- Surgical Technique Step-by-Step *204*
  - Transpedicular Approach *204*
  - Costotransversectomy *205*
  - Lateral Extracavitary Approach *206*
- Complications *207*

29. Anterolateral Open Thoracotomy Approach for Thoracic Diskectomy **209**
Patricia Zadnik, Daniel Sciubba
- Introduction *209*
- Surgical Indications *209*
- Surgical Technique Step-by-Step *210*
- Potential Complications *213*

30. Anterior Thoracic Corpectomy and Fusion **215**
Jason W Savage, Thomas A Zdeblick
- Indications *215*
- Preoperative Planning *215*
- Surgical Technique Step-by-Step *217*
  - Patient Positioning *217*
  - Surgical Approach *217*
  - Corpectomy and Fusion *218*
- Complications *221*

31. Anterior Release and Fusion for Thoracic Scoliosis **223**
Jonathan Mason, Vincent Arlet
- Introduction *223*
  - Anatomy *223*
- Indications *223*
- Surgical Technique Step-by-Step *224*
- Potential Complications *227*

32. Thoracic Extreme Lateral Interbody Fusion **229**
Jordan M Komisarow, Vijay Agarwal, Robert E Isaacs
- Introduction *229*
- Indications for Approach/Procedure *230*
- Surgical Technique Step-by-Step *231*
  - Set-Up *231*

- Approach to the Thoracic Spine *231*
- Approach to the Thoracolumbar Spine *232*
- Closure *233*

- Potential Complications *234*

33. Posterior-only Correction of Adult Thoracolumbar Scoliosis **236**
Manish K Kasliwal, Lee A Tan, Justin S Smith, Christopher I Shaffrey
- Introduction *236*
- Indications *237*
- Preoperative Planning *238*
- Surgical Technique and Steps *240*
  - Coronal Plane Deformity Techniques *241*
  - Sagittal Plane Deformity Techniques *242*
  - Case Example *244*
- Complications *244*

34. Percutaneous Pedicle Screws and Rods for Deformity Reduction **249**
Neel Anand, Jason Cohen, Ryan B Cohen, Eli M Baron
- Introduction *249*
- Indications *249*
- Techniques Step-by-Step *250*
  - Additional Considerations *256*

35. Smith-Petersen and Pedicle Subtraction Osteotomies **258**
Ahmad Nassr, Quanqi Cui, Michael J Yaszemski
- Introduction *258*
- Anatomy and Biomechanics *258*
- Surgical Indications *260*
- Surgical Technique Step-by-Step *260*
  - Intraoperative Setup *260*
  - Smith-Petersen Osteotomy and Polysegmental (Zielke/Ponte) Osteotomies *260*
  - Pedicle Subtraction Osteotomy *262*
- Potential Complications *264*

36. Posterior Thoracic Vertebral Column Resection **266**
Marco Ferrone, Hai Le, Christopher M Bono
- Introduction *266*
- Anatomy *266*
- Surgical Indications *267*
- Surgical Technique Step-by-Step *267*
- Potential Complications *270*

SECTION 4: LUMBOSACRAL SPINE TECHNIQUES

37. Lumbar Microdiscectomy **275**
Jason C Eck
- Introduction *275*
  - Anatomy *275*
- Surgical Indications *276*
- Surgical Technique Step-by-Step *277*
- Potential Complications *280*

38. Tubular Microdiscectomy **281**
Ibrahim Hussain, Roger Härtl, Ali A Baaj
- Introduction *281*
- Indications *282*
- Surgical Technique Step-by-Step *282*
- Potential Complications *285*

39. Far Lateral Disk Herniations **289**
Scott D Hodges
- Introduction *289*
- Indications *290*
- Surgical Technique Step-by-Step *291*
  - L2-L5 *291*
  - L5-S1 *294*
- Potential Complications *296*

40. Posterior Lumbar Decompression **298**
Robert Eastlack, Payam Moazzaz
- Introduction *298*
- Surgical Technique Step-by-Step *298*
  - Exposure *298*
  - Decompression *299*
- Pitfalls *302*

41. Minimally Invasive Posterior Lumbar Decompression **304**
Justine Pearl, Zame Tymchak, Daryl R Fourney
- Introduction *304*
- Surgical Indications *305*
- Surgical Technique Step-by-Step *306*
- Potential Complications *308*

42. Posterior Lumbar *in situ* Fusion **310**
Scott D Daffner
- Introduction *310*
  - Anatomy *310*
- Indications *311*
- Surgical Technique Step-by-Step *311*
- Complications *313*

43. Posterior Lumbar Facet Fusion **315**
Joseph K Lee, Brian W Su
- Introduction *315*
- Anatomy *315*
- Indications *317*
- Surgical Technique Step-by-Step *317*
- Complications *321*

44. Anterior Lumbar Interbody Fusion with Fixation **322**
Raj J Gala, Benjamin Geddes, Peter G Whang
- Introduction *322*
  - Anatomy *322*
- Surgical Indications *324*

- Surgical Technique Step-by-Step *325*
- Potential Complications *329*

45. Anterior Lumbar Arthroplasty **331**

Richard D Guyer, Issada Thongtrangan

- Introduction *331*
- Anatomy *331*
- Surgical Indications *332*
- Surgical Technique Step-by-Step *332*
  - Access to Retroperitoneal Space *332*
  - Disk Preparation or Discectomy *334*
  - Sizing and Trialing *335*
  - Implant Insertion *336*
- Risks and Complications *337*
- Postoperative Management *338*

46. Anterior Lumbar Corpectomy **341**

Jacob Fennessy, Michael S Weinstein, Murray J Cohen, Jeff A Rihn

- Introduction *341*
- Indications *341*
- Surgical Technique Step-by-Step *342*
  - Surgical Approach *342*
  - Corpectomy *347*
  - Reconstruction and Stabilization *348*
- Complications *349*

47. Posterior Lumbar Interbody Fusion **353**

Carmen Petraglia, Paul Justin Tortolani, David Alexander Stroh

- Introduction *353*
- Pathophysiology *353*
- Indications *354*
- Patient Evaluation *354*
- Surgical Technique Step-by-Step *356*
- Postoperative Management *359*
- Complications *359*

48. Open Transforaminal Lumbar Interbody Fusion **362**

Ravi K Ponnappan, James E Dowdell

- Introduction 362
- Anatomy 363
  - General *363*
  - Surgical *363*
- Surgical Indications 364
- Surgical Technique Step-by-Step 365
  - Positioning *365*
  - Surgical Approach *365*
  - Transforaminal Lumbar Interbody Fusion Window *366*
  - Disk Space Preparation *367*
  - Cage Selection *368*
  - Bone Grafting or Cage Insertion *368*
  - Posterior Spinal Stabilization with Pedicle Screw Placement *368*

- Postoperative Care *369*
- Potential Complications *370*

49. Minimally Invasive Transforaminal Lumbar Interbody Fusion **372**
Raul J Cardenas, Kevin T Foley
- Introduction *372*
- Indications and Preoperative Assessment *372*
- Surgical Technique Step-by-Step *373*
  - Patient Positioning and Operating Room Setup *373*
  - Initial Incision and Pedicle Identification *373*
  - Pedicle Cannulation *374*
  - Facetectomy, Laminotomy, and Diskectomy *375*
- Complications *379*
- Illustrative Case *379*

50. Spondylolisthesis Reduction and Fixation Techniques **383**
Scott I Lee, Richard Todd Allen, Steven Garfin
- Introduction *383*
- Clinical Findings and Physical Examination *385*
- Anatomy/Biomechanics *385*
- Surgical Indications *386*
- Surgical Technique *387*
- Potential Complications *388*

51. Lateral Lumbar Interbody Fusion Surgical Technique **390**
Isaac L Moss, Scott S Mallozzi, Frank M Phillips
- Introduction *390*
- Anatomy *390*
- Biomechanics *391*
- Surgical Indications *392*
- Surgical Technique Step-by-Step *393*
  - Preparation, Positioning and Skin Marking *393*
  - Retroperitoneal Access *394*
  - Intervertebral Disk Exposure *395*
  - Discectomy and Placement of Interbody Implant *396*
  - Anterior Column Realignment *397*
  - Closure and Postoperative Care *398*
- Complications *398*

52. Interspinous Spacers **401**
Stephanie Hsu, Joshua Abrams, James Zucherman
- Anatomy *401*
- Surgical Indications *401*
- Implantation of Specific Surgical Technique *404*
  - General Technical Considerations *404*
  - Technical Approaches *405*
- Postoperative Care *413*
- Complications *413*

53. Oncologic Sacrectomy **416**
Peter S Rose, Robert A Waldrop
- Introduction *416*

- Anatomy *416*
  - General *416*
  - Bony *416*
  - Neurologic *418*
- Surgical Indications *419*
- Patient Evaluation *419*
- Surgical Technique Step-by-Step *420*
  - Anterior Approach *420*
  - Posterior Approach *421*
- Reconstruction *423*
- Postoperative Care *424*
- Complications *424*
- Outcomes *425*

54. Spinopelvic Fixation Techniques **427**

Mostafa H El Dafrawy, Khaled M Kebaish

- Introduction *427*
- Anatomy and Biomechanics *427*
  - Lumbosacral Pivot Point *427*
  - Zones of Sacropelvic Fixation *427*
  - Spinopelvic Balance *427*
- Surgical Indications *429*
- Spinopelvic Fixation Options *430*
  - S1 Pedicular Screws *430*
  - Sacral Alar Screws *430*
  - Iliosacral Screws *430*
  - Galveston Technique *431*
  - Iliac Screws *431*
  - Transiliac Bar *431*
  - S2 Alar Iliac Screws *432*
- Surgical Technique Step-by-Step *433*
  - Tricortical S1 Pedicle Screw Technique *433*
  - Iliac Screws Technique *433*
  - S2 Alar Iliac Technique *434*
- Potential Complications *435*
  - Misplacement and Injuries to Adjacent Structures *435*
  - Implant Prominence and Loosening *436*
  - Wound Complications and Infection *436*
  - Nonunion and Implant Failure *436*

SECTION 5: OTHER TECHNIQUES

55. Anterior and Posterior Iliac Crest Bone Graft Harvest **441**

Anthony Lapinsky, Jacob Furey

- Introduction *441*
- Benefits and Advantages of Iliac Crest Bone Grafting *441*
- Surgical Technique Step-by-Step *441*
  - Anterior Iliac Crest Bone Graft *441*
  - Posterior Iliac Crest Bone Graft *443*
- Risks, Complications and Disadvantages of Iliac Crest Bone Grafting *444*

56. Vascular Rib Graft Harvest **446**
Rishi M Kanna, Ajoy P Shetty, Mark Dekutoski, S Rajasekaran
- Introduction *446*
- History *446*
- Anatomy of Rib Vasculature *446*
- Indications *447*
- Surgical Technique Step-by-Step *447*
  - Approach *447*
  - Choice of Rib to Be Harvested *448*
  - Harvesting the Graft *448*
  - Anterior Placement of Rib Graft *449*
  - Posterior Placement of Rib Graft *450*
- Complications *452*

57. Lumbar Discography **454**
Mark S Kaplan
- Introduction *454*
- Modified Dallas Discogram Scale *455*
- Anatomy *455*
- Indications *456*
- Discography Technique Step-by-Step *456*
- Potential Complications *458*

58. Vertebral Body Augmentation Therapy **460**
Larry Shay Richardson
- History *460*
- Epidemiology *460*
- Social Impact *460*
- Diagnosis *461*
- Treatment *462*
- Surgical Technique Step-by-Step *462*
- Complications *466*

Index *467*

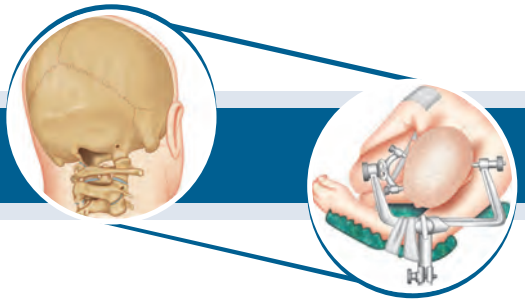

Chapter

4

Far Lateral Approach to the Craniocervical Junction

Biagia La Pira, Thomas Sorenson, Pietro d'Urso, Giuseppe Lanzino

JAYPEE BROTHERS

INTRODUCTION

The far lateral approach is essentially a lateral suboccipital craniotomy or craniectomy that is directed behind the sternocleidomastoid muscle and vertebral artery (VA) and medial to the atlanto-occipital joint and the occipital and atlantal condyles. This procedure can be performed with or without resection of the occipital condyle in order to gain exposure to the ventrolateral surface of the craniocervical junction and the lower clivus, depending on the pathology considered. [1-3] Currently, the many variations of the far lateral approach permit an adequate exposure of the lower cerebellopontine angle, ventral lateral brainstem and spinal cord in order to allow the neurosurgeon to address a wide variety of vascular, neoplastic and degenerative diseases (Table 4.1). In this chapter, we describe the basic steps of this procedure, its variations, and potential complications.

Table 4.1: Prevalence of lesions of the craniocervical junction in adults treated with a far lateral approach.

Lesions of the craniocervical junction	*Percentage*
Meningioma	35%
Chordoma and chondrosarcoma	17%
VA-BA junction aneurysms	17%
Paraganglioma	10%
Schwannoma and neurofibroma	7%
Other vascular lesions (condylar vein varix, VA kinking by bone, dural fistula)	4%
Cystic lesions (neuroenteric and epidermoid cysts)	3%
Osteochondroma	1%
Metastatic carcinoma	1%
Hemangiopericytoma	1%
Granuloma	1%

(VA: Vertebral artery; BA: Basilar artery).
Source: Adapted from Ivo D'Urso P, Giuseppe L. Far Lateral Approach to the Craniocervical junction. New Delhi: Jaypee Brothers Medical Publishers (P) Limited; 2013.

GENERAL CONSIDERATIONS

For lesions located on the anterolateral margin of the foramen magnum, a basic far lateral approach, without any condyle resection is usually satisfactory. The advantages of this approach include: familiar anatomy, rapid exposure of the craniocervical junction, proximal control of the ipsilateral VA, and adequate exposure of the ventral lateral brainstem and lower cerebellopontine angle with little or no need for retraction.

For tumors in this region, the approach is dictated by the location and size of the mass. In cases where tumor mass is primarily located on one side with contralateral extension in front of the brainstem, it is pertinent to note that resection of the tumor often creates enough progressively increasing exposure to reach all the way to the contralateral side. For accessible pathology, a basic far lateral approach is often sufficient. If needing a more lateral angle of approach, numerous extensions of the basic far lateral approach (Table 4.2) have been described.[4-14]

Table 4.2: Summary of the modifications and indications of the far lateral approach.

Approach	*Indications*	*Description*
Retrocondylar approach	Lateral and/or anterolateral intradural lesions	Not required occipital condyle removal
Partial transcondylar	Anterior lesions of the spinal-medullary area	VA mobilization. Posterior third of occipital condyle and partial superior facet of C1 removal (anterior limit of condylar resection: hypoglossal canal)
Complete transcondylar	Extradural lesions	Medial VA mobilization. Following condyle removal, exposure of mid-clival area. Following removal of lateral mass and lateral portion of anterior arch of C1, exposure of lower-clivus. Craniocervical fixation required
Transjugular approach	Jugular foramen lesions	Mastoidectomy. VA mobilization. Removal of the posterolateral third of the condyle
Transtubercular approach	Complex aneurysms of vertebra-basilar system. Allowed a better exposition of ipsi- and contralateral VA, and VB junction	Removal of the posteromedial third of condyle and C1 lateral mass. Extradural removal of jugular tubercle above the hypoglossal canal
Transfacet approach	Extra- and intradural lesions anterior to the upper cervical spinal cord	Medial VA mobilization. C1–C2 hemilaminectomy; C1–C2 facet joints and condyle drilling. No need for craniectomy.

(VA: Vertebral artery; VB: Vertebrobasilar).
Source: Adapted from Ivo D'Urso P, Giuseppe L. Far Lateral Approach to the Craniocervical Junction. New Delhi: Jaypee Brothers Medical Publishers (P) Limited; 2013.

SURGICAL STEPS

Preoperative Considerations

The far lateral approach is the author's preferred surgical approach for vascular lesions and tumors involving the ventrolateral surface of the craniovertebral junction (CVJ) and lower clivus. The most common lesions treated include aneurysms of the distal vertebral and proximal basilar arteries and extradural and intradural neoplasms of the lower clivus and the CVJ.

The preferential lateral extension of the pathology in questions, dictates the side of the approach. For lesions centered in the midline, other factors, such as the surgeon's dominant hand and neurovascular anatomy should be considered. Intraoperative electrophysiological monitoring of involved and adjacent nerves, as well monitoring of brainstem, sensory and motor function is indicated depending on the type of pathology and the structures at risk.

Endoscopic far lateral approaches have been performed successfully on cadavers and may be soon integrated into clinical practice. Potential advantages of a predominant endoscopic approach include decreased morbidity rates, reduced postoperative discomfort and faster recovery times.[15] More commonly at the present stage, the endoscope is used as an adjunctive tool to "check" behind corners after microsurgical resection of tumors or aneurysm clipping.

Positioning

Positioning is of critical importance in order to maximize exposure of the CVJ with the far lateral approach. We prefer a modified park-bench position, which requires dropping the contralateral shoulder while increasing the amount of cranial flexion and extension (Fig. 4.1). The patient is placed in the lateral position, with the lower arm below the level of the body, padded and taped to the Mayfield's holder. The upper shoulder is gently pulled toward the feet to open the angle between the head and the shoulder itself, increasing the range of movement of the microscope. The head is held in a three-point Mayfield skull clamp and rotated about 15–20° below the horizontal plane with the noise pointing at 60° angle towards the floor, in such that the mastoid process is the highest part of the surgical field. The neck should be flexed with the chin 1 cm from the sternum and rotated

JAYPEE BROTHERS

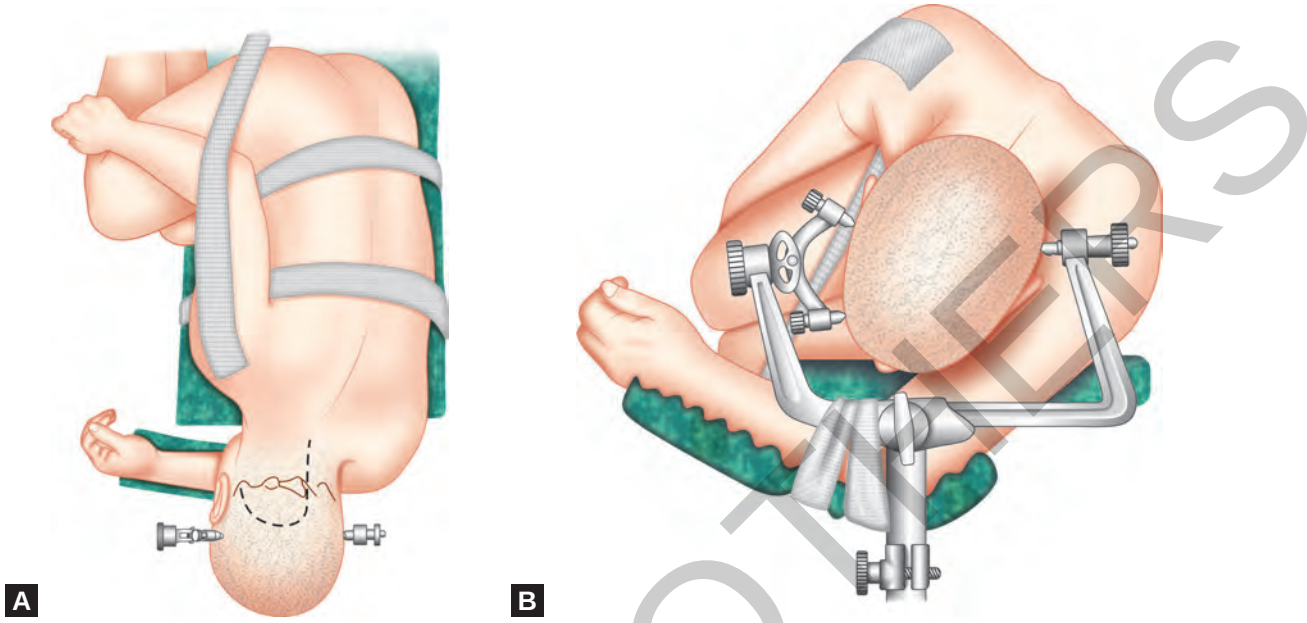

Figs. 4.1A and B: Modified park-bench position. (A) Overall view; (B) Details of the positioning of the contralateral arm, positioned below the level of the body, padded and taped to the Mayfield's holder; the head is flexed and rotated contralaterally to the lesion.
Source: Adapted from Ivo D'Urso P, Giuseppe L. Far Lateral Approach to the Craniocervical Junction. New Delhi: Jaypee Brothers Medical Publishers (P) Limited; 2013.

contralaterally to the lesion in order to maximally increase the angle between the atlas and the foramen magnum (Fig. 4.1B). Next, lateral flexion of approximately 30° toward the contralateral shoulder further opens the head-shoulder angle to increase the viewing angle. A roll of tape should be placed between the dependent axilla, and a pillow should be placed between the knees. This position improves venous return and minimizes brachial plexus injuries. Lastly, the body should be fixed to the table with surgical tape, so that the table can be rotated safely during the surgical procedure.[2]

Incision

Various skin incisions have been described and can be used.[16-18] To simplify the description of the various phases, we describe the surgical steps after a "hockey stick" incision which starts at the tip of the ipsilateral mastoid, continues above the superior nuchal line, then curves to the midline above the external occipital protuberance, and down to the level of C3 (Figs. 4.1A and 4.2). A gentle curved angle is preferred to avoid wound complications, such as a necrotic eschar. Important anatomical skin landmarks for making the incision include: the external occipital protuberance, the mastoid tip and the transverse process of C1. Additionally, palpating the spinal processes of the upper cervical vertebra during incision is recommended to maintain midline orientation.

Recently, a minimally invasive far lateral approach has been described which improves postoperative comfort and could potentially be associated with lower rates of cerebrospinal fluid (CSF) leak and pseudomeningocele. This approach utilizes a 3 cm vertical incision centered over the CVJ, 3.5 cm lateral to midline and muscle splitting to gain access to the CVJ.[19]

Muscle Dissection

Following elevation of the skin flap adjacent to the horizontal portion of the incision, a suprafascial dissection is performed and then the muscles are incised leaving a fascia "cuff" located inferiorly to the level of the superior nuchal line to facilitate approximation of the fascia and the muscle during closure. This is an important step to minimize the chance of postoperative CSF leakage. Although a detailed knowledge of the individual suboccipital muscles and planes is essential, we prefer to perform the muscle dissection in one single layer to ease closure. After taking down the suboccipital muscles in one flap, the flap should be rotated anteroinferiorly and

JAYPEE BROTHERS

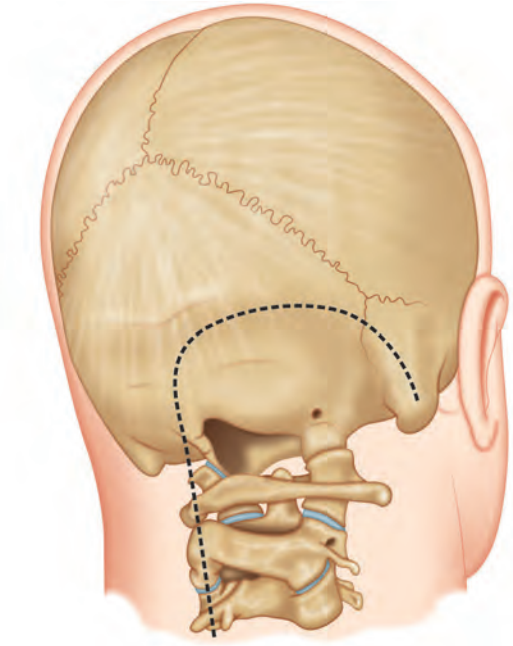

Fig. 4.2: The skin incision starts at the tip of the ipsilateral mastoid, continues above the superior nuchal line and curves to the midline down to the level of C3.
Source: Adapted from Ivo D'Urso P, Giuseppe L. Far Lateral Approach to the Craniocervical Junction. New Delhi: Jaypee Brothers Medical Publishers (P) Limited; 2013.

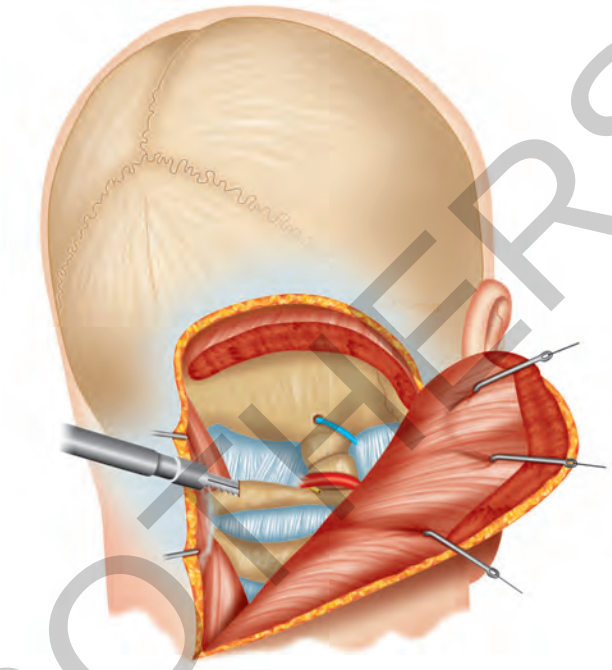

Fig. 4.3: Removal of portion of the ipsilateral posterior arch of the atlas after identification of the sulcus arteriosus and the VA.
Source: Adapted from Ivo D'Urso P, Giuseppe L. Far Lateral Approach to the Craniocervical Junction. New Delhi: Jaypee Brothers Medical Publishers (P) Limited; 2013.

retracted with fishhooks attached to rubber bands (Fig. 4.3). Rubber bands are suggested because they provide a dynamic form of retraction that can be adjusted as the dissection proceeds and also flatten the edges of the wound while decreasing the depth of the operating field.[2]

Extradural Stage

Once the skin and the muscle flaps are taken down and retracted with fishhooks, several landmarks must be identified in order to avoid injuries to important structures. Spinal processes and laminae of the atlas (C1) and axis (C2) can be palpated and identified, keeping in mind that the transverse process of the atlas projects more laterally compared to the transverse process of the lower vertebrae. The posterior arch of C1 is followed from medially to laterally and then up to the sulcus arteriosus, which represents the landmark for the vertebral artery and its surrounding venous plexus. A redundant vertebral artery with a more medial course can be found in some elderly patients and must also be avoided. It is important to identify the VA (without mobilizing it) and surrounding venous plexus in order to protect these structures while drilling the occipital condyle. A subperiosteal dissection with a dissector rather than Bovie cautery will minimize the risk of injuring the artery. Although not necessary, the intraoperative ultrasound probe can be used to insonate and locate the artery.

Once the vertebral artery and its sulcus arteriosus are identified, the ipsilateral posterior arch of C1 is removed (Fig. 4.3). Drilling of the atlas posterior arch should stay within the 10 millimeter safe distance from the midline to the vertebral artery groove of the atlas to avoid complications. If a vertebral artery transposition is required, it is necessary to open the transverse foramen of C1 and mobilize the artery inferomedially, away from the atlantooccipital joint, to fully expose the occipital condyle. This maneuver, which makes the condylar drilling easier and safer, is not required for a "simple" far lateral approach. A suboccipital craniotomy is then performed, from the inferior nuchal line superiorly to the rim of the foramen magnum inferiorly and from the midline medially to the occipital condyle laterally (Figs. 4.4 and 4.5A). If necessary, a variable extent of drilling of the occipital condyle then can be performed (Fig. 4.5B). For tumors of the ventrolateral

JAYPEE BROTHERS

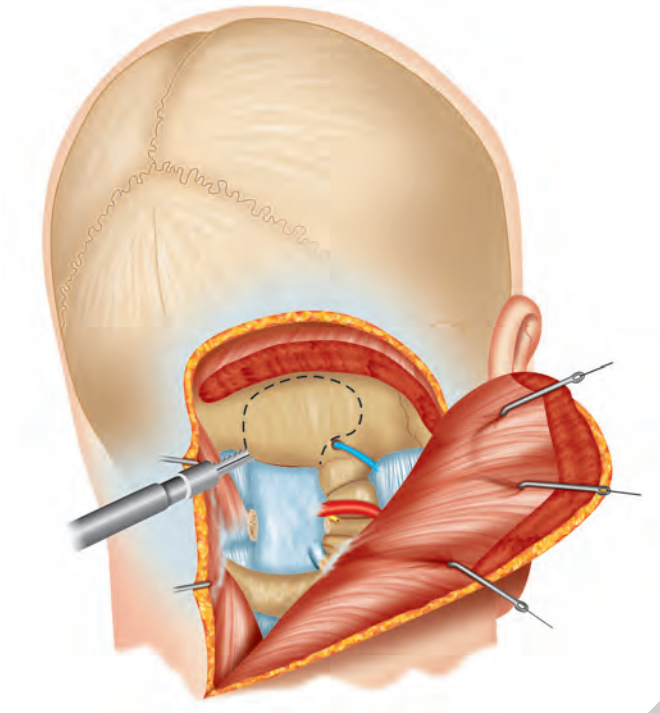

Fig. 4.4: The craniotomy is extended as far laterally as possible, including the inferior rim of the foramen magnum and medially reaching the midline.
Source: Adapted from Ivo D'Urso P, Giuseppe L. Far Lateral Approach to the Craniocervical Junction. New Delhi: Jaypee Brothers Medical Publishers (P) Limited; 2013.

brainstem and upper cervical cord, minimal condyle removal is required because the tumor itself has already created a corridor and displaced surrounding neurovascular structures. For aneurysms of the distal VA, drilling of the posterior third of the condyle affords a flat angle of exposure after dura opening (Figs. 4.5C and 4.6). When drilling the occipital condyle, the change from cancellous bone to cortical bone indicates that the hypoglossal canal has been exposed and removal should cease.

Additional extensions or modifications of this basic approach must be tailored to the specific needs of the lesion and the surgeon's level of comfort. Based on these factors, three extensions may be considered at this point. The transcondylar extension offers access to the lower clivus and premedullary area, the supracondylar approach provides better exposure of the hypoglossal canal and jugular tubercle, and the paracondylar extension provides exposure of the posterior part of the jugular foramen and the posterior aspect of the facial nerve. Though research has suggested that unilateral occipital condylectomy does not lead to long-term CVJ instability, care should still be maintained to preserve as much condyle as possible.[20]

Dural Opening and Intradural Exposure

The dura is usually opened in a curvilinear incision fashion with the incision centered over the area of interest (Fig. 4.5C). As much as possible we prefer to open the dura separately from the underlying arachnoid. Typically, the dura opening extends approximately from the sigmoid sinus to the C2 lamina. Following incision, the dura is reflected and held medially and laterally with sutures. Additional perpendicular incisions can be made to facilitate increased intracranial and intraspinal exposure. The exposure obtained by this incision includes the lower cranial nerves and upper spinal roots to C2. Extension of this original approach superiorly allows exposure of upper extension of lesions to the internal auditory meatus. For the transcondylar exposure, we suggest leaving a narrow dural cuff on the vertebral artery to facilitate mobilization. Possible sources of bleeding during dural opening are the posterior meningeal artery, the occipital sinus and the marginal sinus. Bleeding should be controlled with a combination of hemoclips, bipolar cauterization and suture ligation.

Opening the arachnoid around the cisterna magna allows cerebellar relaxation so that no fixed retraction is usually necessary. Important neurovascular structures can be recognized from superior to inferior: the tonsil, the lower cranial nerves (X, XII, XI), the posterior inferior cerebellar artery (PICA) (between the X and XII), the intradural part of the VA crossed by the XI nerve, the roots of C1 and C2 below the VA, and the dentate ligament (Fig. 4.7). The roots of C1 and C2 are divided into a dorsal ramus and a ventral ramus. The ventral rami of both C1 and C2 nerve roots pass behind the vertebral artery. The dorsal ramus of C2 gives rise to the greater occipital nerve, while the dorsal ramus of C1, also known as the suboccipital nerve, runs between the posterior arch of the atlas and the vertebral artery. The intradural segment of the VA, after piercing the dura, ascends in front of the rootlets of the hypoglossal nerve to the medulla oblongata. The dentate ligament can be easily recognized by its white color (whiter than the nerves) and can be divided to allow further mobilization of neurovascular structures. Width of exposure depends on the size of craniotomy and the amount of occipital condyle removal, and must

JAYPEE BROTHERS

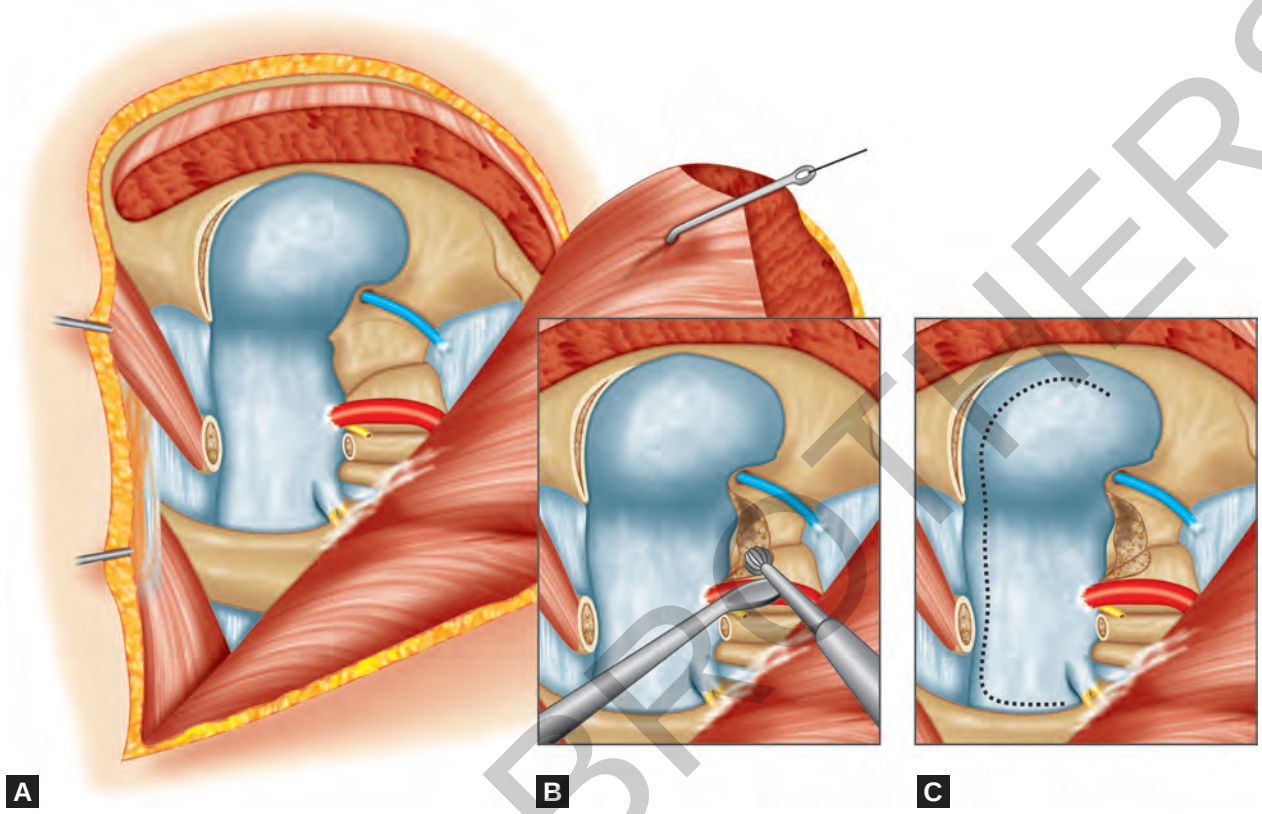

Figs. 4.5A to C: (A) Surgical exposure after craniotomy and removal of the ipsilateral posterior arch of the atlas, before drilling of the condyle; (B) Partial drilling of the condyle and articular mass of C1 when required, with protection of the VA during drilling; (C) Opening of the dura in a curvilinear fashion.
Source: Adapted from Ivo D'Urso P, Giuseppe L. Far Lateral Approach to the Cranialcervical Junction. New Delhi: Jaypee Brothers Medical Publishers (P) Limited; 2013.

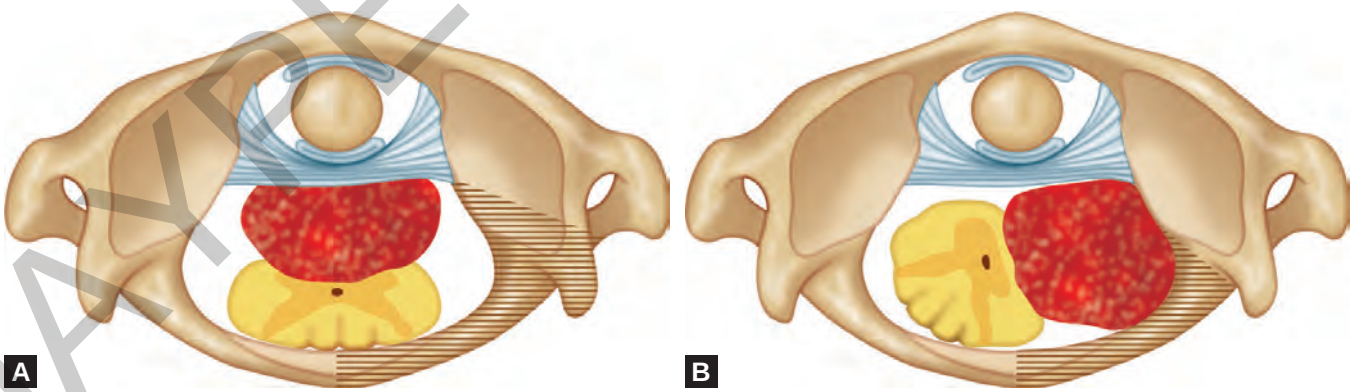

Figs. 4.6A and B: Extension of bone drilling (dashed areas) for lesions (A) Anteriorly located; (B) Laterally located Lesions anteriorly located require drilling of the posterior third of the condyle, to obtain a flat angle of exposure, while lesions laterally located can be easily exposed and excised removing the ipsilateral posterior arch of the atlas.
Source: Adapted from Ivo D'Urso P, Giuseppe L. Far Lateral Approach to the Cranialcervical Junction. New Delhi: Jaypee Brothers Medical Publishers (P) Limited; 2013.

JAYPEE BROTHERS

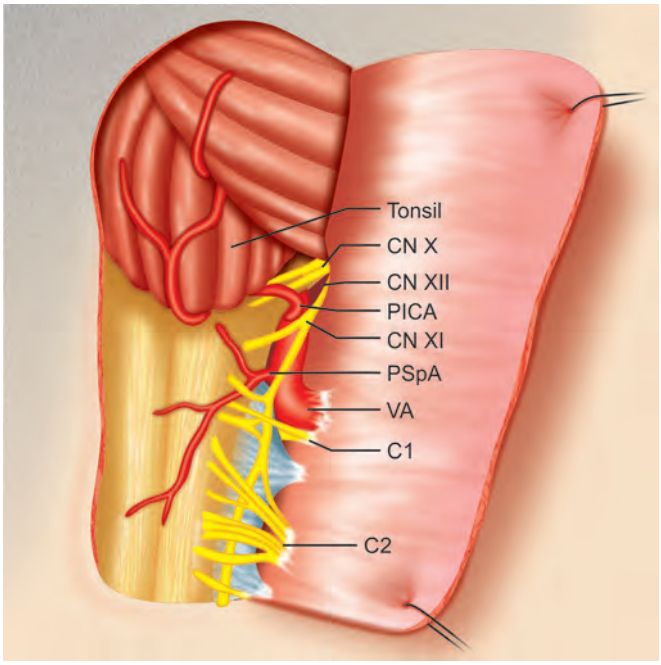

Fig. 4.7: View of the cervicomedullary junction, lower cranial nerves, PICA and first two nerve roots after dura opening.
(PICA: Posterior inferior cerebellar artery; PSpA: Posterior spinal artery; VA: Vertebral artery).
Source: Adapted from Ivo D'Urso P, Giuseppe L. Far Lateral Approach to the Cranialcervical Junction. New Delhi: Jaypee Brothers Medical Publishers (P) Limited; 2013.

be individualized according to the lesion position and extension.

For neoplastic lesions, from this point on the surgical technique must be specific to the mutual relationships between the tumor and surrounding neurovascular structures, specifically the cranial nerves, the VA, the PICA and their perforating vessels.[7,21]

Closure

A watertight dura closure, either primarily or with a dura patch, is necessary to prevent CSF leakage and postoperative pseudomeningocele, which are the most common complications related to the approach itself. If the dura around the VA entrance has been removed because of tumor invasion, then the dural graft can be loosely sutured to the adventitia or to the periadventitial tissues of the VA. The dural closure is often augmented with fibrin glue, and, if mastoid air cells have been violated, these must be sealed with bone wax. The craniotomy flap is replaced with miniplates, and, if the ipsilateral portion of the posterior arch of atlas was removed during the procedure, it can be reconstructed at the end of the procedure with miniplates. Tight closure of the muscular layer decreases the incidence of postoperative subcutaneous fluid collection. The skin is then closed with sutures or clips. If the dura closure is not watertight, a lumbar drainage catheter placed postoperatively may be useful to allow sealing of the different layers and possible decreasing the risk of pseudomeningocele formation.[4]

COMPLICATIONS

Complications can arise from any of the steps of a far lateral approach. These include: infection, injury to the neurovascular structures, brainstem and spinal cord, CSF leakage, and pseudomeningocele formation.[22] Occasionally, in the event of large (>70%) occipital condyle drilling, CVJ instability may occur.

To minimize the risk of neurovascular injury, electrophysiological monitoring is helpful to alert the surgeon as to potential ongoing issues and respond appropriately.[23] For extradural pathology, it is important to consider that the neurovascular structures run inside the arachnoidal layer. Therefore, in these cases, the arachnoid should be used as a protective barrier, and its integrity preserved as much as possible.

A CSF leak due to a CSF fistula is the most common local postoperative complication, reported in 6–25% of patients.[14,24-28] The best prevention of a postoperative CSF leakage is meticulous and watertight dura closure, with a dural patch when it is necessary and augmented with fibrin glue. In cases, where a watertight dural closure is not possible, careful approximation of the muscle and fascial planes to minimize "dead spaces" is essential. In patients with a postoperative CSF leak or a symptomatic pseudomeningocele, lumbar drainage along with acetazolamide to reduce the production of CSF can be a valid first therapeutic option. In case of recurrence after these measures, surgical re-exploration and repair may be necessary. However, hydrocephalus must be ruled out before considering re-exploration in refractory cases. If hydrocephalus is present, a ventriculoperitoneal shunt will usually resolve the problem. As mentioned in the incision section, reducing the invasiveness of the exposure, with resulting decrease of the "dead space", may also be helpful in reducing the risk of this complication.

JAYPEE BROTHERS

Another complication that has received a lot of attention is CVJ instability following condylectomy. This debate has been fueled by many factors, but possibly the most important is the difficultly in defining joint instability at the CVJ. Unlike the subaxial cervical spine, instability in the CVJ may not occur in the immediate postoperative period but may develop overtime. However, resection of the occipital condyle does not guarantee joint instability.[20] Postoperative instability of the CVJ depends on preservation of the occipital condyle, the C1 lateral mass, and the attachment of the alar and transverse ligaments to the anterior one-third of the occipital condyle and the anterior one-third of the lateral mass. In general, as long as 50% of the condyle is preserved, fusion is not necessary providing that the contralateral joint is not involved by tumor. Some authors have suggested that even patients who have had up to 70–75% of the ipsilateral condyle removed do not experience instability.[20,29,30]

CONCLUSION

The far lateral approach and its variations are versatile options to address lesions of the anterior brainstem, as they provide optimal exposure for a variety of vascular, neoplastic and degenerative diseases of lower clivus and CVJ. When performing the procedure, the surgeon should maintain a few key considerations. Preservation of 50% of the occipital condyle does not create postoperative instability as long as the contralateral joint is not involved in the underlying lesion. If CVJ stability is compromised, cervical fusion should be performed in the same sitting to minimize potential damage. Additionally, meticulous care should be maintained to avoid potential complications, especially during dura, muscle and fascia planes closure to prevent CSF leakage. In the case that watertight dura closure is not possible, a prophylactic lumbar drain should be placed.

REFERENCES

1. Heros RC. Lateral suboccipital approach for vertebral and vertebrobasilar artery lesions. J Neurosurg. 1986;64(4):559-62.
2. Lanzino G, Paolini S, Spetzler RF. Far-lateral approach to the craniocervical junction. Neurosurg. 2005;57(4 Suppl):367-71; discussion 367-71.
3. Rhoton AL Jr. The far-lateral approach and its transcondylar, supracondylar, and paracondylar extensions. Neurosurg. 2000;47(3 Suppl):S195-209.
4. Salas E, Sekhar LN, Ziyal IM, et al. Variations of the extreme-lateral craniocervical approach: anatomical study and clinical analysis of 69 patients. J Neurosurg. 1999;90(2 Suppl):206-19.
5. Baldwin HZ, Spetzler RF, Wascher TM, et al. The far lateral/combined supra- and infratentorial approach. A human cadaveric prosection model for routes of access to the petroclival region and ventral brain stem. J Neurosurg. 1994;81(1):60-8.
6. Bertalanffy H, Seeger W. The dorsolateral, suboccipital, transcondylar approach to the lower clivus and anterior portion of the craniocervical junction. Neurosurg. 1991;29(6):815-21.
7. George B, Lot G. Anterolateral and posterolateral approaches to the foramen magnum: technical description and experience from 97 cases. Skull Base Surg. 1995;5(1):9-19.
8. Muhlbauer M, Knosp E. The lateral transfacetal retrovascular approach for an anteriorly located chordoma originating from the second cervical vertebra. Acta Neurochir (Wien). 2001;143(4):369-76.
9. Samii M, Klekamp J, Carvalho G. Surgical results for meningiomas of the craniocervical junction. Neurosurg. 1996;39(6):1086-94; discussion 1094-5.
10. Sen CN, Sekhar LN. An extreme lateral approach to intradural lesions of the cervical spine and foramen magnum. Neurosurg. 1990;27(2):197-204.
11. Sen CN, Sekhar LN. Surgical management of anteriorly placed lesions at the craniocervical junction—an alternative approach. Acta Neurochir (Wien). 1991;108(1-2):70-7.
12. Wen HT, Rhoton AL Jr, Katsuta T, et al. Microsurgical anatomy of the transcondylar, supracondylar, and paracondylar extensions of the far-lateral approach. J Neurosurg. 1997;87(4):555-85.
13. Karam YR, Menezes AH, Traynelis VC. Posterolateral approaches to the craniovertebral junction. Neurosurg. 2010;66(3 Suppl):135-40.
14. Margalit NS, Lesser JB, Singer M, et al. Lateral approach to anterolateral tumors at the foramen magnum: factors determining surgical procedure. Neurosurg. 2005;56(2 Suppl):324-36; discussion 324-36.
15. Komatsu F, Komatsu M, Di Ieva A, et al. Endoscopic far-lateral approach to the posterolateral craniovertebral junction: an anatomical study. Neurosurg Rev. 2013;36(2):239-47; discussion 247.
16. Moscovici S, Umansky F, Spektor S. "Lazy" far-lateral approach to the anterior foramen magnum and lower clivus. Neurosurg Focus. 2015;38(4):E14.
17. Beer-Furlan A, Ikeda DS, Lonser RR, Prevedello DM. Letter to the Editor: Far-lateral approach with the "transverse-S" skin incision and conservative muscle dissection: a pragmatic surgical route. Neurosurg Focus. 2016;40(1):E8.
18. Lutjens G, Barlocher CB, Krauss JK. A modified "far-lateral" approach for safe resection of retroodontoid dural cysts. Eur Spine J. 2011;20 Suppl 2:S262-5.

JAYPEE BROTHERS

19. Kryzanski JT, Robertson JH, Heilman CB. A minimal access far-lateral approach to foramen magnum lesions. J Neurol Surg B Skull Base. 2014;75(4):236-42.
20. Shiban E, Török E, Wostrack M, Meyer B, Lehmberg J. The far-lateral approach: destruction of the condyle does not necessarily result in clinically evident craniovertebral junction instability. J Neurosurg. 2016;125(1):196-201.
21. Bruneau M, George B. Foramen magnum meningiomas: detailed surgical approaches and technical aspects at Lariboisiere Hospital and review of the literature. Neurosurg Rev. 2008;31(1):19-32; discussion 32-3.
22. Menezes AH. Surgical approaches: postoperative care and complications "transoral-transpalatopharyngeal approach, to the craniocervical junction. Childs Nerv Syst. 2008;24 (10):1187-93.
23. Gugino V, Chabot RJ. Somatosensory evoked potentials. Int Anesthesiol Clin. 1990;28(3):154-64.
24. Borba LA, de Oliveira JG, Giudicissi-Filho M, Colli BO. Surgical management of foramen magnum meningiomas. Neurosurg Rev. 2009;32(1):49-58; discussion 59-60.
25. Arnautovic KI, Al-Mefty O, Husain M. Ventral foramen magnum meninigiomas. J Neurosurg. 2000;92(1 Suppl): 71-80.
26. Bassiouni H, Ntoukas V, Asgari S, et al. Foramen magnum meningiomas: clinical outcome after microsurgical resection via a posterolateral suboccipital retrocondylar approach. Neurosurg. 2006;59(6):1177-85; discussion 1185-7.
27. Kandenwein JA, Richter HP, Antoniadis G. Foramen magnum meningiomas–experience with the posterior suboccipital approach. Br J Neurosurg. 2009;23(1):33-9.
28. Wu Z, Hao S, Zhang J, et al. Foramen magnum meningiomas: experiences in 114 patients at a single institute over 15 years. Surg Neurol. 2009;72(4):376-82; discussion 382.
29. Bejjani GK, Sekhar LN, Riedel CJ. Occipitocervical fusion following the extreme lateral transcondylar approach. Surg Neurol. 2000;54(2):109-15; discussion 115-6.
30. Shin H, Barrenechea IJ, Lesser J, et al. Occipitocervical fusion after resection of craniovertebral junction tumors. J Neurosurg Spine. 2006;4(2):137-44.

JAYPEE BROTHERS

for detailed information on orthopedics book, visit our website www.jaypeebrothers.com, for detailed information on orthopedics book, visit our website www.jayp

Surgical Atlas of Spinal Operations

Salient Features

- This atlas is a comprehensive review of spine surgery, discussing traditional and new techniques. Divided into five sections, the first part introduces surgical anatomy.
- The following sections focus on procedures for different parts of the spine – cervical, thoracic and lumbosacral, to present expanded coverage of all aspects of spine surgery.
- Each section presents numerous disorders and different surgical techniques for their management. Highly illustrated, each chapter discusses indications for a surgical approach, the most common surgeries, pertinent anatomy, postoperative care and potential complications.
- Key points are summarized for each chapter.

Jason C Eck DO MS graduated from Catholic University of America in 1993 with a BS in Biomedical Engineering. He then received an MS in Biomedical Engineering from Marquette University in 1996 with a thesis titled "A Three-Dimensional, Non-Invasive, in vivo Motion Analysis of the Cervical Spine." He completed medical school in 2002 with a DO degree from University of Health Sciences. He completed an orthopedic surgery internship and residency in 2007 at Memorial Hospital and an orthopedic spine surgery fellowship at Mayo Clinic in 2008. He has 109 peer-reviewed and 13 non-peer-reviewed publications. He has published 20 book chapters and edited 5 other textbooks. He works as an orthopedic spine surgeon in Chattanooga, Tennessee, USA.

Alexander R Vaccaro MD PhD MBA has graduated Summa Cum Laude from Boston College in 1983 with a BS in Biology. He received his MD degree from Georgetown University School of Medicine where he was promoted with "Distinction". He completed a year of Surgical Internship at Cedars-Sinai Medical Center in Los Angeles, California and his Orthopedic Surgery Residency was at Thomas Jefferson University where he graduated in 1992. Dr Vaccaro completed a Spine Fellowship at the University of San Diego, California, USA. He earned a PhD in 2007 in the field of Spinal Trauma and a MBA in 2015. Dr Vaccaro is the Richard H Rothman Professor and Chairman, Department of Orthopedic Surgery and Professor of Neurosurgery at Thomas Jefferson University in Philadelphia, Pennsylvania, USA. He has over 730 peer-reviewed and 200 non-peer-reviewed publications. He has published over 340 book chapters and is the Editor of over 58 textbooks and Co-Editor of OKU-Spine I and editor of OKU-8. Dr Vaccaro is the President of Rothman Institute, Chairman of the Department of Orthopedic Surgery, Co-Director of the Regional Spinal Cord Injury Center of the Delaware Valley and Co-Director of Spine Surgery at Thomas Jefferson University Hospital where he instructs current fellows and residents in the diagnosis and treatment of various spinal problems and disorders.

Available at all medical bookstores
or buy online at www.jaypeebrothers.com



JAYPEE BROTHERS
Medical Publishers (P) Ltd.
www.jaypeebrothers.com

Join us on facebook.com/JaypeeMedicalPublishers

Shelving Recommendation
ORTHOPEDICS

