sit our website **www.jaypeebrothers.com,** for detailed information on neurosurgery books, visit our website **www.jaypeebrothers.com**

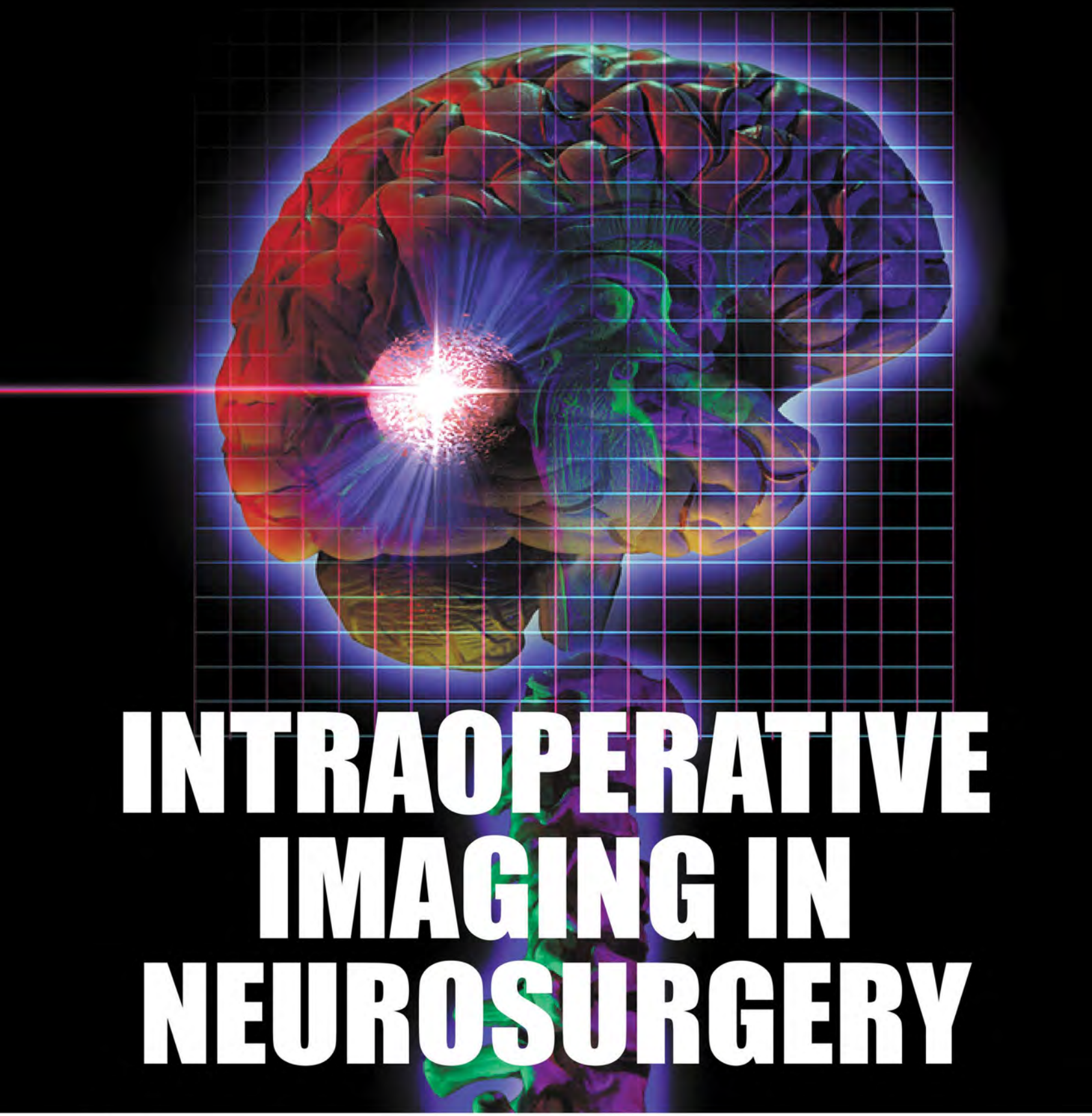

INTRAOPERATIVE IMAGING IN NEUROSURGERY

Editors
Karanjit Singh Narang
Ajaya Nand Jha

Foreword
Michael Schulder

JAYPEE

Contents

1. History of Neuroimaging **1**
Karanjit Singh Narang, Rishabh Kedia, Ajaya Nand Jha
Genealogy of Neuroimaging *1*

2. Intraoperative Imaging in Neurosurgery **7**
Michael Schulder, Ami Raval
Clinical Benefits of Intraoperative Neuronavigation *10*
Limitations of Intraoperative Neuronavigation *12*
Overall Costs with Neuronavigation *13*
Intraoperative Imaging *13*
Optimization of Costs of Intraoperative Navigation and Imaging *20*

3. Intraoperative Magnetic Resonance Imaging **26**
Christopher Nimsky
Intraoperative Magnetic Resonance Imaging Beyond Standard Imaging *26*

4. Intraoperative Magnetic Resonance Imaging: Changing Face of Neurosurgery **31**
Anshu Mahajan, Vipul Gupta
Intraoperative Magnetic Resonance Imaging and its Origin *31*
Anesthesia for Intraoperative Magnetic Resonance Imaging *32*
Safety of Contrast Agent *33*
Safety of Intraoperative Magnetic Resonance Imaging *33*
Infection Control in the Intraoperative Magnetic Resonance Imaging Suite *34*
American College of Radiology: MRI Safe Practice Guidelines *34*
Intraoperative Use of Contrast Agents *34*
Surgical Devices and Instruments *34*
Intraoperative Imaging and Neuronavigation *35*
Impact on Length of Operation *35*
Intraoperative Magnetic Resonance Imaging-guided Neurosurgery Application *35*
Imaging in Intraoperative Magnetic Resonance Imaging *35*
Localization of the Signal *36*
Normal Signal Intensity *37*
Selection of Sequence in Open Neurosurgery *37*
Dynamic Susceptibility-weighted Contrast-Enhanced Perfusion-MRI *38*
Scan Protocol *40*
Brain Shift *40*
Magnetic Resonance Spectroscopy–guided Brain Biopsy *41*
Intraoperative Magnetic Resonance Imaging Guidance to Ventricle and Cyst *41*
Role of Intraoperative Magnetic Resonance Imaging in Deep Brain Stimulation *41*
Intraoperative Magnetic Resonance Imaging *41*

5. Low-field Intraoperative Magnetic Resonance Imaging **47**
Christian Senft
Glioma Surgery and Neuronavigation *47*
The Need for Intraoperative Imaging *47*

Influence of Intraoperative Magnetic Resonance Imaging 49
Integration of Intraoperative Magnetic Resonance Imaging into the Neurosurgical Routine 49
Evidence of Intraoperative Magnetic Resonance Imaging Use 50
Future Perspectives 50

6. Two Room vs Single Room Intraoperative Magnetic Resonance Imaging Setup **53**
Karanjit Singh Narang, Ratnadip Bose, Ajaya Nand Jha
Advantages of Two-room Intraoperative MRI System over One-room IMRI System 56

7. Anesthesia for Intraoperative Magnetic Resonance Imaging **58**
Harsh Sapra
Physics behind Magnetic Resonance Imaging 58
Superconductivity 58
Equipment Classification [American Society for Testing and Materials (ASTM) International, 2006] 59
Anesthetic Implications 59
Ferromagnetism: Magnetic Resonance Imaging and Implanted Metallic Devices 61
Miscellaneous Issues 61

8. Intraoperative Computed Tomography **63**
Alessandro Olivi
Intraoperative Imaging 63
Intraoperative Computed Tomography Instead of Fluoroscopy, MRI and Ultrasonography 64
Clinical Uses 64
Safety and Efficacy 66
Complications 66
Future Directions 67

9. CT-based Navigation in Brain and Spine Surgery **69**
Ivan Ng Hua Bak
Neuronavigation 69
Brain Surgery: Indications 72
Spine Surgery: Indications 74

10. Intraoperative Ultrasound **79**
Gavin Quigley
Clinical Use 80
Suggested Steps Prior to Use 80
Image-guidance Integration 81
Ventricular Cannulation with Burr Hole Probe 82
Ultrasound Features of Intracranial Structures 82

11. ALA Dye in High-grade Gliomas **88**
Gord Von Campe
Principles of Fluorescence 88
5-aminolevulinic Acid and Protoporphyrin IX 88
5-aminolevulinic Acid: General Applications 89
5-aminolevulinic Acid and Photodynamic Detection of High-grade Gliomas 90
5-aminolevulinic Acid: Adverse Reactions 92
5-aminolevulinic Acid and Photodynamic Therapy 92
Perspectives 93

12. Intraoperative Imaging in Epilepsy Surgery **96**
Aditya Gupta, Rishabh Kedia, Pawan Goyal
Who Needs Surgery? *96*
Intraoperative Magnetic Resonance Imaging *96*
Intraoperative Ultrasound *96*
Intraoperative Computed Tomography *97*
Extratemporal Epilepsy *97*
Temporal Epilepsy *97*

13. Impact of Intraoperative Magnetic Resonance Imaging on Extent of Resection **102**
Moritz Scherer
Impact of Intraoperative Magnetic Resonance Imaging in Glioma Surgery *102*
Impact of Intraoperative Magnetic Resonance Imaging Guidance on Extent of Resection *103*
Impact of Intraoperative Magnetic Resonance Imaging upon the Resection Process *105*
Intraoperative Impression of Extent of Resection *106*
Limitations of Intraoperative Magnetic Resonance Imaging: Research and Future Considerations *107*
Definition of Tumor Dimension and Target Resection Volume *107*
Delineation of Residual Tumor on Intraoperative Magnetic Resonance Imaging *107*
Unintended Incomplete Resections *108*
Patient Selection and Need for Randomization in Outcome Studies *108*
Summary and Outloop *109*

14. Intraoperative Imaging in Pituitary Surgeries **111**
Sudhir Dubey, Deepak Bhangale
Intraoperative Magnetic Resonance Imaging *112*
Transsphenoidal Resection of Pituitary Adenomas *112*
Role of Navigation *113*
Operative Technique *114*
Postoperative Plan *118*
Our Experience *118*
Patient-related Characteristics *123*
Limitations *123*
Pearls *124*

15. Intraoperative Imaging in Skull Base Surgeries **127**
Michael R Chicoine
Intraoperative Imaging Techniques *128*
Intraoperative Imaging for Skull Base Tumors *129*
Author Commentary *139*

16. Role of Intraoperative Imaging in Cerebrovascular Surgeries **144**
Peter Nakaji
Basic Principles of Neuronavigation and Intraoperative Imaging in Cerebrovascular Surgery *144*
Preoperative Cerebrovascular Imaging Evaluation *144*
Preoperative Surgical Rehearsal *145*
Aneurysm Microsurgery *146*
Arteriovenous Malformation Microsurgery *148*
Dural Arteriovenous Fistula Microsurgery *150*
Intracerebral Hemorrhage Evacuation *150*
Supratentorial Cavernous Malformation Microsurgery *153*
Brainstem and Deep-seated Cavernous Malformation Microsurgery *154*

17. Multimodality Image-guided Neurosurgery **158**
Olutayo Olubiyi, Roy Torcuator, Alexandra J Golby
General Considerations in Brain Surgery *158*
Image-guided Surgery *158*
Intraoperative Image-guided Neurosurgery *161*
Magnetic Resonance Therapy to Advanced Multimodality Image-guided Operating (MRI to AMIGO) *162*
Challenges, Limitations and Future Directions *165*

18. Future of Navigation and Intraoperative Imaging **168**
Richard Bucholz
Preoperative Imaging *168*
Intraoperative Tracking *171*
Visualization *172*
System Control *173*
Effectors *174*
Intraoperative Imaging *175*

Index *185*

2

Intraoperative Imaging in Neurosurgery

Michael Schulder, Ami Raval

INTRODUCTION

History of Neuroimaging and Stereotaxy

For the past century and half, neurosurgeons have been attempting to localize lesions within the brain using various techniques. Given its intricate and delicate nature, the ability to noninvasively understand the anatomical and functional regions within the nervous system was essential to neurosurgeons. While the field of neuronavigation has developed significantly due to the parallel strides made in neuroradiology, the ability to find tumors, and other intracranial targets was present even earlier when Zernov developed the encephalometer, a device that fixed onto the skull in order to localize structures intracranially based on surface landmarks using an arc device.[1]

Imaging of the skull and its contents began shortly after Roentgen discovered the X-ray in 1895.[2] Calcified areas, such as the pineal gland, choroid plexus, and basal ganglia could now be identified, and even certain pathologies such as craniopharyngiomas and calcified meningiomas could be localized. The next revolutionary development in neuroimaging was air ventriculography, which was described by Walter Dandy after he demonstrated that injection of air into the lateral ventricles or into the spinal canal could provide even further information. Shortly thereafter, Egas Moniz introduced cerebral angiography, in order to diagnose vascular pathologies, but also to demonstrate large intracranial lesions causing sufficient mass effect that they displaced cerebral blood vessels.[1-3] Combining ventriculography and stereotaxis, neurologists and neurosurgeons learned that certain periventricular regions such as the basal ganglia and thalamus could be localized due to their association to stable deep structures such as the third ventricle. Using the fundamentals of this technique, the first frame to treat trigeminal neuralgia was applied onto a human, and subsequently, Ernest A Spiegal and Henry T Wycis attached a frame to a patient's head, and then performed a pneumoencephalogram. Using a brain atlas along with major internal landmarks that were identified using pneumoencephalography, the first human thalamotomy was performed. Following this pioneering work, Lars Leksell developed an arc-centered stereotactic frame, which used pins in order to fixate the frame to the skull, and used polar coordinates.[4,5] Since then, many other variations of the stereotactic frame system have been developed for intracranial surgery using different devices in order to fixate the frame to the skull **(Figure 2.1)**.[6-12]

The early 1980s were a fruitful time for technology in general, with strides made in radiology, imaging, robotics, and computers. After the development of computed



Figure 2.1 Modern version of a Leksell stereotactic frame for intracranial biopsy
Courtesy: Elekta AB Publication, Stockholm, Sweden.

JAYPEE BROTHERS

tomography (CT) scans by Hounsfield and Cormack, Shalit was one of the first to describe the use of intraoperative CT scans for brain tumors.[13,14] In 1987, Young et al. demonstrated that stereotactic coordinates could be derived from CT images, and then translated into a CT robotic stereotactic system; this allowed direct utilization of the CT images in the operating room for localization and targeting of deep intracranial structures.[9] Unfortunately, despite its potential applicability, use of the intraoperative CT was not common initially, mainly because of its cost and the difficulties of incorporating it into the operating room infrastructure.[15] Today, it mainly continues to be used for spinal and functional neurosurgery **(Figure 2.2)**.[15-19]

While frame-based stereotaxy was found to be highly accurate, the frame itself limited the range of surgical approaches. Additionally, early on, only one type of imaging data set could be used for localization and of course, required the physical placement of a frame onto a patient's skull, which does cause discomfort to the patient **(Figure 2.1)**. In response to these constraints, the "frame-based" stereotactic system started to evolve into frameless ones. Roberts et al. was one of the first to describe utilizing an operating microscope with ultrasound emission and recording microphones that can allow the surgeon to correlate his microscope location with that of predefined targets on CT or magnetic resonance (MR) using a sonic digitizer. Using this concept of emission of signals from a variety of sources and then processing the data using digitizers so that the "source of the signal emission" can be localized with reference to a three-dimensional (3D) reconstructed imaging study, others created various neuronavigation systems utilizing ultrasonic, magnetic, and infrared-based sources.[20]

Once it was demonstrated that intraoperative imaging was logistically possible, it was imperative to be able to combine that with frameless stereotaxy in order to allow "real-time" intraoperative localization. In 1995, Black et al. performed the first neurosurgical procedure using an [intraoperative magnetic resonance imaging (MRI) (ioMRI)].[21] This revolutionized the field of neuronavigation in that by combining intraoperative imaging with neuronavigation, updated images could be acquired and then incorporated into the navigation dataset, thereby allowing surgeons access to "near real-time" imaging. With this technology, two neurosurgeons had the ability to operate in the same room with the ioMRI without mobilizing the patient or the magnet. Imaging, surgical and stereotactic spaces were unified in this device.

Initial disadvantages of the ioMRI, however, included a small working space of 56 cm between the coils, lower quality images due to lower magnetic field strength and increased costs of obtaining new MRI compatible equipment.[22] Since then, many more models of ioMRI have been introduced, including ones where the machine can be moved in and out of the operative field **(Figures 2.3 and 2.4)**. Conversely, an ioMRI operating suite can be constructed where patients can be wheeled into and out of an MRI that has been built into the operating room **(Figure 2.5)**. These systems have varying ergonomic and imaging advantages, although none achieve the unity of concept that the original double donut design provided.



Figure 2.2 Intraoperative cone-beam computed tomography (CT) scanner. Patients can be positioned on a standard operating room table, with the scanner moved under and around the patient without significant interruption of operating room workflow. This can be utilized for both cranial and spinal neurosurgical procedures
Courtesy: O-arm® Surgical imaging with StealthStation® navigation system, Medtronic Inc,. Minneapolis, MN.



Figure 2.3 Operating room set-up with microscope and navigational camera in background with intraoperative low field magnetic resonance imaging (MRI). Magnet is elevated up on both sides of the head that is resting on a standard operating room table
Courtesy: PoleStar® Surgical MRI system, Medtronic Inc., Minneapolis, MN.

JAYPEE BROTHERS

Perhaps with the introduction of the ioMRI, the concept of intraoperative imaging came to a forefront in neurosurgery, and served as an impetus for the development of not only other advanced modalities of intraoperative imaging, but also for higher quality technological improvements in the existing ones. Software systems for intraoperative CT (iCT) became significantly faster, more user friendly, and less expensive than the ioMRI systems so that image acquisition was better and more rapid. Therefore, intracranial hemorrhages could be detected sooner than ioMR imaging. Additionally, it provided better bony resolution than MRI and its use was expanded to complex spinal, orthopedic, and sinus surgeries.[23]

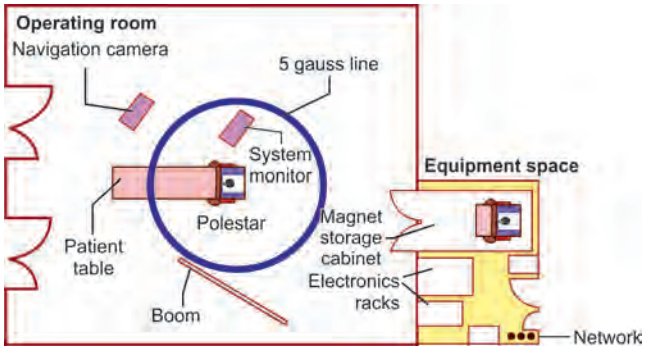

Figure 2.4 Architectural setup of operating using low field intraoperative magnetic resonance imaging (MRI). When not in use, the MRI is kept in a storage cabinet and brought out to behind and under the head when needed
Courtesy: PoleStar® Surgical MRI system, Medtronic Inc., Minneapolis, MN.

Other methods of utilizing intraoperative neuroimaging with neuronavigation include fusing preoperative images with 3D ultrasonography. This bypasses much of the logistical limitations of the ioMRI and offers a quick and useful way of pinpointing a lesion and visualizing it prior to durotomy and brain tumor resection. It can also be used by the surgeon to account for brain shift and other anatomic changes that may have occurred during surgery **(Figure 2.6)**. While it has been shown to be less effective in assessing the extent of tumor resection, it provides an inexpensive, more accessible means for surgeons to compare anatomic data before and after tumor resection. Interactive neuronavigation systems have now been developed that utilize not only CT and MR images, but can incorporate intraoperative 3D ultrasonography data, functional MRI (fMRI), and diffusion tensor imaging (DTI) mapping data so that the surgeon has the maximal information possible when approaching a brain tumor **(Figures 2.6 to 2.8)**.[24-27] Additionally, in the past 15 years, frameless neuronavigation has expanded to incorporating intraoperative MRI with other operative tools, such as a navigational microscope, so that margins of tumor, the planned surgical approach and functional data can all be displayed within the surgeon's microscope viewing field. Surgical instruments can also be registered to the neuronavigation dataset so that the distal tips of catheters and endoscopes can be tracked.



Figure 2.5 Intraoperative magnetic resonance imaging (MRI) suite. During surgery, patients can be moved into and out of a fixed MRI unit that was constructed directly within the operative suite or in an alcove adjacent to the operating suite
Courtesy: Brainlab® Inc., Westchester, IL.

JAYPEE BROTHERS

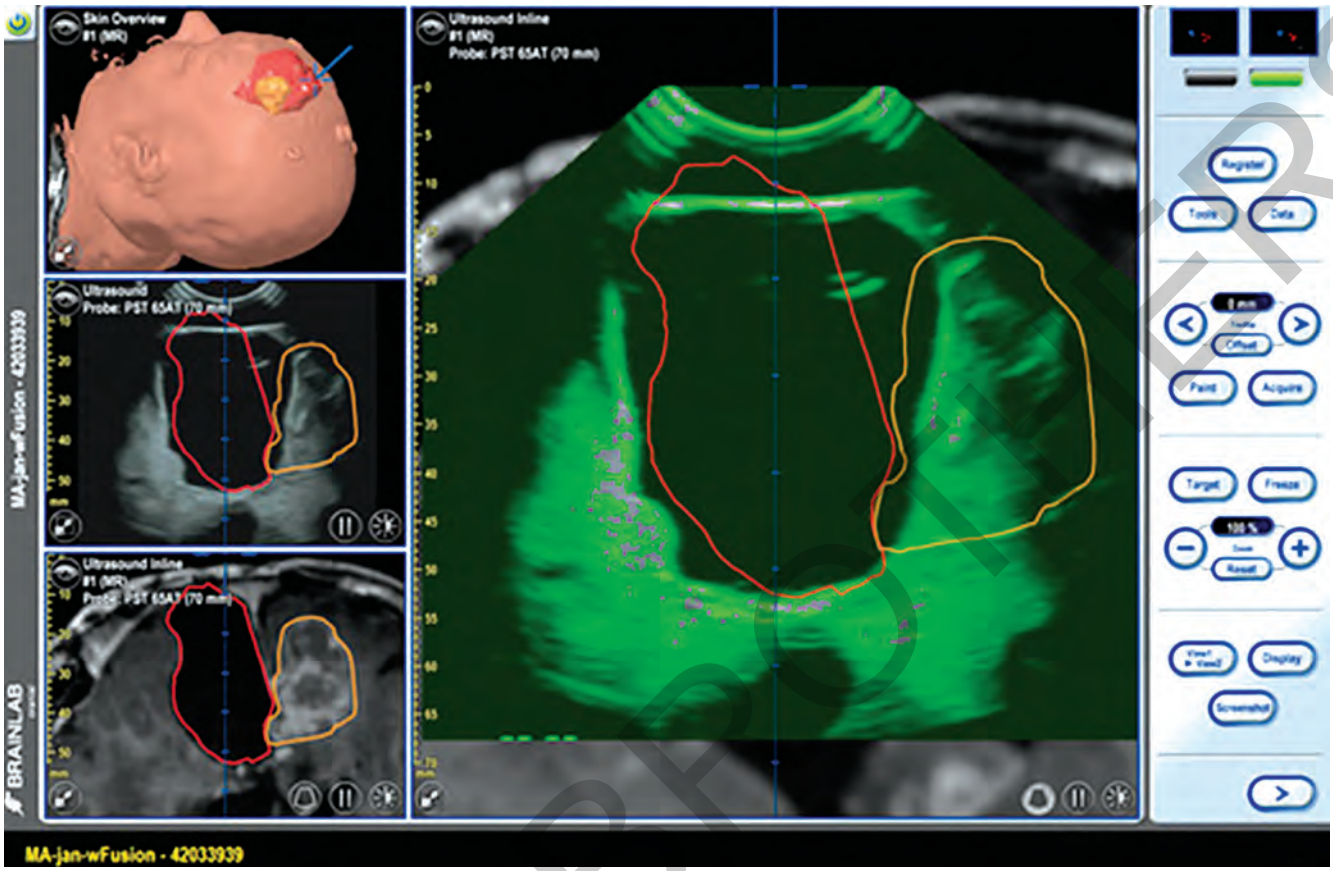

Figure 2.6 Preoperative magnetic resonance imaging (MRI) images have been integrated with the brainlab intraoperative ultrasound neuronavigational platform that can allow for real-time high resolution 3D ultrasound data
Courtesy: Brainlab® Inc., Westchester, IL.

CLINICAL BENEFITS OF INTRAOPERATIVE NEURONAVIGATION

Until the 1980s, cranial localization of the lesion, surgical planning of the extents of the craniotomy and incision were done using measurements taken from standard preoperative CT and MR images. This inevitably led to larger craniotomies, longer incisions and increased operative time. With the advent of neuronavigation, surgeons were able to identify where the intracranial lesion should be, thereby making a shorter incision, smaller craniotomy and thus, decreasing the overall surgical time for the patient.[1,28,29]

Multiple studies have shown the benefit of surgical navigation in intracranial surgery. In 2006, Willems et al. compared the patients that underwent surgery using intraoperative navigation with patients that underwent standard surgery using preoperative images alone. Outcomes they looked at included the duration of surgery, extent of resection and patient's functional status. In this study, it was demonstrated that the number of patients that had residual tumor postoperatively was approximately half of those patients that underwent standard surgery.[30,31] In 2000, Paleologos published a study evaluating the clinical utility of patients that underwent image-guided craniotomy compared with conventional craniotomy.[29] While this study cited similar "operative times" between standard surgery and intraoperative image-guided surgery, there was a statistically significant shorter "surgical time" for the latter group ($p = 0.02$). In this study, "operative time" included the time from which the patient was under anesthesia to reversal of anesthesia while "surgical time" was from incision time to reversal of anesthesia. Likely, the reason operative times were similar in both cohorts was the increased surgical time in the standard surgery group due to longer incisions, larger craniotomies and increased time needed for surgeons to cautiously perceive and avoid anatomic structures was in exchange for the time needed to set up and register the image guidance system prior to incision time.

The aforementioned study showed that image-guided neurosurgery leads to decreased overall patient morbidity

JAYPEE PROOFERS

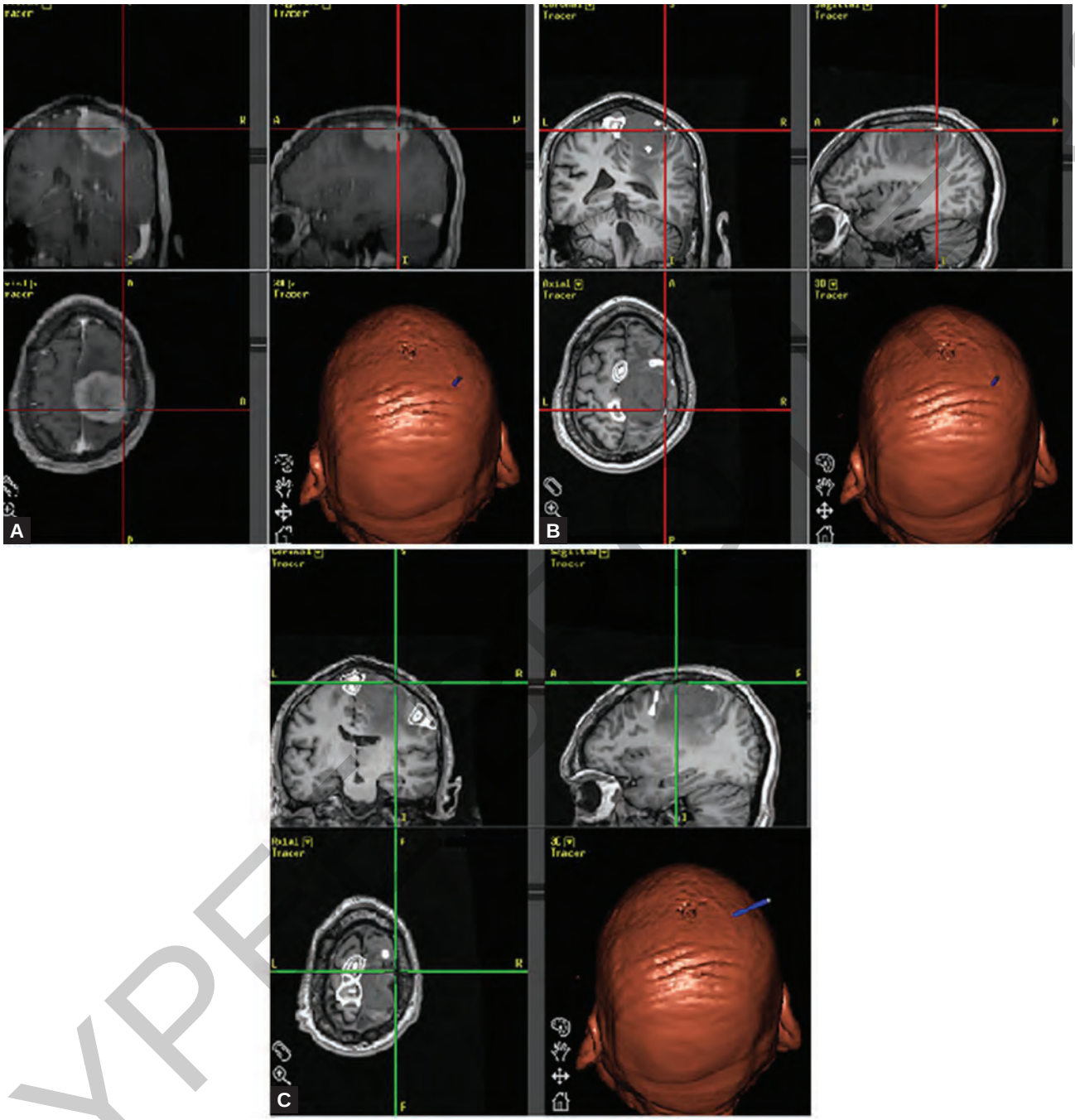

Figures 2.7A to C Series of medtronic stealth neuronavigation screenshot images that demonstrate a left frontoparietal mass. (A) The exact margins of the tumor can be visualized with a three-dimensional model reconstructed from thin cut magnetic resonance (MR) images; (B and C) Functional magnetic resonance imaging (fMRI) data has been incorporated into the neuronavigational plan in order to visualize areas of eloquence in relationship to the mass

and shorter postoperative inpatient hospital stays.[29,32,33] Complication rates in cases of standard surgery were significantly higher than that of cases where intraoperative image guidance was used (14% vs 6%, P = 0.019). Mean hospital stays were also reduced from 13.5 days to 8.5 days in cases where intraoperative image guidance was utilized (P = 0.017). Lastly, more cases of standard surgery patients required blood transfusions perioperatively than intraoperative image

JAYPEE BROTHERS

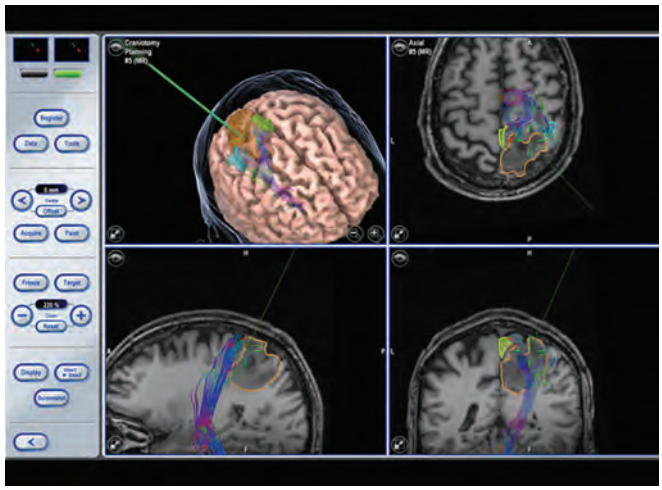

Figure 2.8 Cranial navigation software demonstrating tumor outlined and adjacent diffusion tensor imaging (DTI) fiber tracts of eloquent areas *Courtesy:* Brainlab® Inc., Westchester, IL.

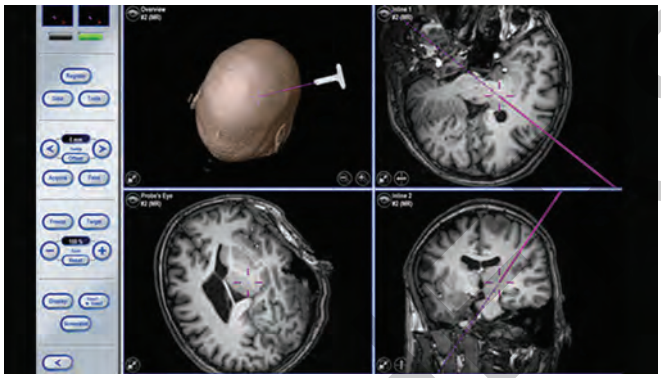

Figure 2.9 Computer screen shot taken during a frameless intracranial stereotactic biopsy using three-dimensional reconstructions from preoperative magnetic resonance imaging (MRI) images. The exact trajectory of the planned biopsy to a left thalamic lesion can be visualized in three-dimensional planes so that eloquent structures may be avoided *Courtesy:* Brainlab® Inc., Westchester, IL.

guidance system (P = 0.03). In another British study from the same year that looked mainly at the use of image guidance in patients undergoing craniotomy for meningioma resection. These results also demonstrated statistically significant shorter surgical times, shorter postoperative times in the intensive care unit and shorter overall length of hospital stay for patients in whom image-guided surgery was performed compared with standard surgery.[32,34]

Another benefit of neuronavigation is the ability to display 3D locations of instruments, with their orientations and trajectories in a precise manner **(Figure 2.9)**. For example, being able to plan a direct approach to a tumor or a catheter pass into a dysmorphic ventricle not only decreases overall operative time, but also decreases patient morbidity by decreasing brain manipulation and trauma. Vital structures such as dural venous sinuses and cranial nerves can also be avoided as 3D reconstructions of imaging data give precise feedback to the surgeon regarding their location. This, in turn, increases surgeon confidence and perception of safety, and thereby shortens surgical time.[29,35,36]

Interestingly, Schackert et al. retrospective analysis demonstrated neuronavigational devices allow not only a targeted approach, but allow multiple tumors to be excised in one session without increasing the patient's hospital stay.[33] Therefore, it is feasible that if a patient presents with multiple metastases that could be accessible via one single craniotomy, using intraoperative neuronavigation allows the surgeon to be able to resect more than a single lesion, and thereby decrease tumor burden and avoid the patient further invasive treatments, which may include additional craniotomies.

LIMITATIONS OF INTRAOPERATIVE NEURONAVIGATION

As with learning any new technique, there is a learning curve that is encountered when initially using neuronavigation. For the generation of neurosurgeons that were trained prior to age of neuronavigation, this learning curve is more apparent than perhaps with recently trained neurosurgeons and current neurosurgical residents. As neuronavigational techniques and system platforms become increasingly sophisticated, so does the time needed in order to learn how to use the navigational operating system, software and its updates. Even so, as neurosurgeons and the various technicians gain experience in the systems and its various features, the learning curve becomes easier and ultimately, the time spent in preoperative registration and planning is made up by the potential time taken in order to localize a lesion intraoperatively without guidance.[22,32] Therefore, as surgeons become comfortable with a particular navigational system and have foresight to counter the various nuances that each system has, they can utilize the navigational system to their benefit in the operating room.

One of the main limitations is intraoperative brain distortion, or brain shift. Studies have cited that brain shift can occur up to much as 2.4 cm during tumor resection.[37,38] Even subtle shifts in the brain can compromise placements of probes into deep intracranial structures or even inaccurate biopsies of deep lesions. In addition, older patients with cerebral atrophy have larger extra-axial cerebrospinal fluid (CSF) spaces and patients that have undergone previous

JAYPEE BROTHERS

surgery and/or radiation can increase scarring requiring more brain manipulation at the time of surgery.[39] Several papers have addressed this issue, and recommended techniques aimed to minimize brain distortion by minimizing use of mannitol, hypertonic saline and CSF drainage as well as the avoidance of pneumocephalus.[29,40-43] In addition, tracing around tumor margins with neuronavigation and subsequent dissection around cystic tumors without breaching the cyst wall, whenever possible, may help to decrease brain shift.[39] However, the most obvious way to avoid intraoperative errors in navigation due to shift is with updated imaging with ioMR, iCT, or intraoperative ultrasound (iUS), as will be discussed here.

The use of neuronavigation in surgery for the posterior fossa has been debated. Given the size and well-defined borders of the posterior fossa, some would argue against the necessity for it.[32] The limitations encountered with acquiring an adequate 3D registration model can be overcome by using surface fiducial markers that can be placed over the occiput prior to obtaining the preoperative images. In these cases, neuronavigation is invaluable when trying to access a deep-seated cerebellar arteriovenous malformation (AVM), a pineal tumor, or a small, deep cerebellar metastasis.

Lastly, the concept of intraoperative neuronavigation relies on adequate imaging capabilities. Thin cut preoperative CT images or MRI images must be acquired and in order to construct a 3D model, the technique with which they are acquired must be of good quality, with no significant movement of the patient, appropriate timing of contrast injection, and avoidance of gantry tilt.

OVERALL COSTS WITH NEURONAVIGATION

Neuronavigation systems are expensive and costs of acquiring one, including software, equipment, operative instruments ranges anywhere from $250,000 to just under $1 million dollars.[29] Based on one study, approximately 200 image-guided craniotomies would need to be performed in order to recover the cost of acquiring a neuronavigation system. The mean total cost per procedure was approximately 20% less for patients that underwent image-guided surgery compared with standard surgery, i.e. $14.480 versus $17, 360, P = 0.03. This includes additional preoperative scans needed for the neuronavigation system.[29] Additionally, Paleologos' study also demonstrated that increased hospital stays in cohorts that underwent standard surgery reflected the higher complication rates of these patients. Therefore, lower complication rates in patients that undergo image-guided surgery, and subsequent lower hospital stays for patients would lead to lower overall costs of the treatment. It must also be recognized that added costs of prolonged hospitalization secondary to increased complications ultimately translate to increased healthcare costs both for the patient and for society in general, in that these patients have a faster recoveries with earlier return to work time, decreased morbidities, shorter follow-up time with decreased chance of needing adjuvant therapy.

INTRAOPERATIVE IMAGING

Intraoperative Ultrasonography

Intraoperative ultrasound (iUS) has been used in neurosurgery for many years.[27,44,45] While there is an abundance of evidence that ioMRI increases the extent of resection and improves overall outcomes, it is mainly available at larger tertiary care centers and therefore, is not widely available. Intraoperative ultrasonography, therefore, offers a more practical and cost-efficient alternative when iCT and ioMRI systems are not available. While conventional 2D-US have their inherent limitations, advances in the field of ultrasonography now allow 3D images to be integrated with neuronavigation platforms that can allow for high-resolution 3D ultrasound data that some authors claim is comparable to image quality of ioMRI **(Figure 2.6)**.[46] Also, because ultrasonographic devices are less expensive than iCT and ioMRI, their use does not necessitate any special requirements or place any restrictions in an operative room.

The largest reported experience with 3D ultrasonography has been in Norway, where Unsgaard et al. evaluated biopsies performed from tumor margins that were visible in US images and compared them with preoperative MR T1 and MR T2 images that were registered on neuronavigation. In their cohort of patients with low-grade gliomas (LGGs), biopsy results done using navigated 3D US correlated had equivalent results to those done using navigated preoperative T1 images.[46] While this study reported a high specificity and positive predictive value for resection of gliomas, there was a low negative predictive value as well; that is, even when iUS was negative, there was a possibility of tumor still present within the margins of the surgical cavity. The results of this study indicated that US does underestimate the extent of glioma infiltration, but that prior to resection, reformatted 3D US images are as helpful as MR images in localizing and delineating solid components of tumors and metastases.[46]

Additional studies demonstrated that image fusion between preoperative MR imaging and intraoperative 3D ultrasonography into an ultrasonography neuronavigation system is also possible **(Figure 2.6)**.[47,48] Solheim et al. looked at the use of the SonoWand system in their cohort of patients with high-grade gliomas. Their rate of gross total resection (GTR) was 63% in patients in whom the tumor was deemed "resectable". This indicates that while there is a learning curve as with most technologies, iUS is a relatively "user-friendly" and widely applicable technology.[49] Moiyadi et al. also reviewed their series of patients that underwent surgery using 3D navigable iUS for gliomas. In their cohort of malignant gliomas, GTR was achieved in 47% of the cases, with a GTR

JAYPEE BROTHERS

rate of 88% for the resectable group. In 59% of their cases, further resection was prompted by intraoperative images.[50]

Ultrasonography can also be used in conjunction with advanced image processing, such as DTI or functional MR data. In order to visualize fiber tracts and their relationship to tumors during resection, Coenen et al. described their technique of fusing preoperative DTI data with MR T1 data. This data was then coregistered into a 3D ultrasonography navigation system and used simultaneously with intraoperative 3D US images to visualize brain shift during tumor resection and associated deformation of the fiber tracts. Using fixed and shifting landmarks near fiber tracts adjacent to tumors, image data was sequentially updated during surgery, allowing for intraoperative identification and avoidance of eloquent intracranial areas.[24]

Rasmussen et al. reported on their series of 12 patients where preoperative fMRI and DTI images were obtained and imported into an US-based navigation system. iUS was used to update preoperative fMRI and DTI data. Navigation based on fMRI data was found to be beneficial for preoperative planning in all 12 cases. In five of the cases, DTI data was found to be useful for planning with the navigation system and in two cases, was important during the resection. The authors felt that while fMRI is beneficial for preoperative planning, DTI was helpful during the resection itself. This study demonstrated that the ability to update preoperative MRI data for brain shift using iUS-based neuronavigation was feasible and advantageous during surgery.[27]

In addition to intra-axial tumors, ultrasonography can be used for spinal surgery such as syrinx surgery, spinal tumors, hemangioblastomas, vascular malformations and even for pituitary surgery.[51-55] The Doppler capability of the US allows surgeons to obtain significant angiographic data intraoperatively, such as verifying complete resection of vascular lesions and visualization of major vessels in the vicinity of the tumor.[55] Using specific probes, it can also be used to guide catheters into ventricles as well as cystic lesions such as abscesses, metastases and arachnoid cysts.

Limitations of the iUS include the learning curve involved in getting oriented to US imaging. The inability to visualize the entire cranium can lead to difficulties with orientation. Additionally, as the Unsgaard group demonstrated, imaging artifacts created by blood products, hemostatic agents implanted within the resection cavity, and even the handling of the adjacent tissue can decrease the image quality and ultimately, its usefulness during surgery. Meticulous attention to these details can overcome these obstacles.[56] Moiyabi et al. suggest that using the merged images initially with both preoperative MR scans and iUS images initially facilitates the limitations encountered when initially learning the technology. Once the user becomes proficient with maneuvering the US, direct intraoperative ultrasonography can be used.[50]

Thus, while ioMRI may ultimately be better in terms of image quality, ioUS is a practical, cost-efficient modality of intraoperative imaging that can be utilized in a versatile manner. It can be used by both trained surgeons and residents, and does not require any significant changes to operative workflow or operating room infrastructure. When one becomes adept at the capabilities of the technology, ultrasonography offers a cost-efficient method to ioMRI in settings where resources are limited. With future improvements in image resolution and increasing the variety of different imaging modalities with which to merge ultrasonography data to, the scope of this technique can continue to expand.

Intraoperative Angiography

The question of performing intraoperative angiography remains a controversial one in that while it does allow for early identification of residual AVM, stenosis or occlusion of critical vessels, confirms aneurysm obliteration, it does increase operative time, and imaging quality is suboptimal in most cases.[57-59] Studies have shown that injection of intraoperative fluorescein during aneurysm surgery provided significant clinical utility by demonstration flow within the parent vessels and more importantly, in perforating vessels, thereby ultimately preventing unexpected stroke postoperatively.[60] Limitations in using intraoperative fluorescein are that it demonstrates visualization of vascular anatomy only that which has been dissected and exposed. Therefore, in cases where clipping of an aneurysm has been performed where the dome of aneurysm has not been completely exposed, intraoperative fluorescein is less useful in providing sufficient information as to whether the flow in the dome of the aneurysm has stopped. Nevertheless, intraoperative angiography is a simple method that provides real-time information in detecting the patency of parent, branching, perforating arteries and residual aneurysm and may be used in adjunct to other modalities such as Doppler US in order to prevent any unforeseen complications or avoid further surgery.[61,62]

Intraoperative Computed Tomography

The first iCT was used in early 1980s. With this first model, the gantry was immobile and patients had to be positioned on the scanner table and moved into the gantry. Therefore, only certain positions were possible and patients could not be placed in a head clamp during the scan. In the early 1990s, a mobile CT scanner was developed, where the scanner was installed on a gantry carrier and therefore, the scan could be performed with the patient on a regular operating table with the CT being moved over the patient.[63-65] Given the image

JAYPEE BROTHERS

quality of the early scanners, along with the cost, modification to the operating room workflow, and the novelty of the concept, it was mainly used in stereotactic and functional neurosurgery initially.

Today, the modern iCT scanner has the spatial resolution that surpassed most ioMRI systems. The same scanner hardware inside the gantry as a standard non-intraoperative scanner is used so that high quality, multiplanar, 3D reconstructions can be obtained and these images can also be coregistered with preoperative MR images in order to gain better resolution of the soft tissue contrast (Figure 2). Most importantly, the radiation exposure can be filtered and reduced for both the patient and staff using special automated dose modulation software.[63,66] Additionally, it can be argued that the overall radiation exposure is not increased because both the usual pre and postoperative CT scans are replaced by the iCT scan.[63]

One of the major advantages of iCT over ioMRI is that with neuronavigational software, cranial as well as spinal neurosurgery can be performed, with continuous updates available for navigation. Because virtually any part of the body can be scanned, it can be used by a number of surgical subspecialties and therefore increases its applicability and cost-effectiveness for the institution purchasing the scanner **(Figure 2.2)**. Normal operating room tables and surgical instruments can be used without significant interruption of operating room workflow. It is particularly useful for complex spinal instrumentations and spinal trauma. Intraoperative scans can be obtained once the patient is in the final position, after correction of the subluxation and bony decompression has been achieved, prior to and after placement of instrumentation, reducing the rate of misplaced hardware and revision surgery.[63,67]

While iCT has demonstrated to be beneficial in contrast enhancing lesions, it has been proven to be less helpful in non-contrast enhancing lesions, such as low-grade gliomas as well as tumors at the skull base. Margins of the tumor cannot be readily identified with these tumors due to similar contrast density compared to normal brain parenchyma or bony artifacts. Additionally, while the radiation dose of iCT can be modulated, it must still be used with caution in children. Lastly, similarly to ioMRI, specific head holders and pins must be utilized in order to minimize metal imaging artifact.[63]

Intraoperative Magnetic Resonance Imaging

Neurosurgeons have long been using some form of intraoperative imaging, both for spine and cranial surgery. Since the advent of X-ray, fluoroscopy has been used for both spinal and cranial neurosurgery. Intraoperative CT scans provided much needed real-time feedback that surgeons often needed.[12] However, performing repeated CT scans for a patient undergoing craniotomy not only exposed the patient to significant ionizing radiation, but the quality of the images acquired were not ideal when operating on lesions that were not well visualized on CT imaging to begin with, such as LGGs, cortical dysplasias, or hamartomas.

The ability to update the stereotactic neuronavigation system with the newly acquired, high quality intraoperative imaging is the most salient feature of the ioMRI system. Given that the ioMRI system can acquire such standard sequences as T1, T2 and post-contrast T1 weighted scans, surgeons are able to obtain highly sensitive images that can not only account for the brain shift that has occurred during surgery, but also can allow surgeons to determine their tumor margins and extent of resection **(Figures 2.10A to D)**.[21,22]

Initial ioMRI systems were low field units with a 0.5 Tesla (T) magnet with a "double donut" design. Patients are positioned and fixed inside the scanner and the surgeons had to stand between the coils in order to access the patient and more importantly, they had a limited operative field, with a 56 cm space between the coils of the magnet. With this ioMRI unit, an infrared LED-based neuronavigational system was also integrated within the vertical space between the coils.[21] Newer models allowed the magnet to be "mobile"; the MRI unit could either be moved away from the patient when not scanning **(Figures 2.3 and 2.4)** or the patient could be moved into and out of a fixed MRI unit that was constructed directly within the operative suite or in an alcove adjacent to the operating suite **(Figure 2.5)**. Studies have demonstrated that movement of either entity did not risk surgical sterility or affect patient safety.[68]

Generally, low-field strength refers to ioMRI systems of 0.5 T or less, but other unique "ultra-low field" models emerged in order to overcome the obstacles of size, restrictive operative access and minimizing patient movement. These systems were 0.2 T strength or less and can usually be used with a regular operating room staff team **(Figures 2.3 and 2.4)**.[69] The benefits of the compact nature of the model are counterbalanced by the reduced image quality and limited imaging modalities available such as spectroscopy, angiography, or diffusion-weighted imaging when comparing with higher strength systems. On the other hand, while the high-field systems (1.5 T and greater) enable acquisition of higher quality images with more "advanced" techniques, these systems come at higher costs and the work of integrating the system not only into the operating room workflow, but also involve reorganizing the operating suite's infrastructure **(Figure 2.5)**. In addition, additional instruments and especially trained personnel may be needed. Lastly, the extent to which this affects the neurosurgeon's overall routine and overall surgical time varies between the different systems.

Low-field Intraoperative MRI for Resection of High-grade Glioma

While ioMRI has multiple applications, many studies have demonstrated that one of the main benefits of using ioMRI has

JAYPEE BROTHERS

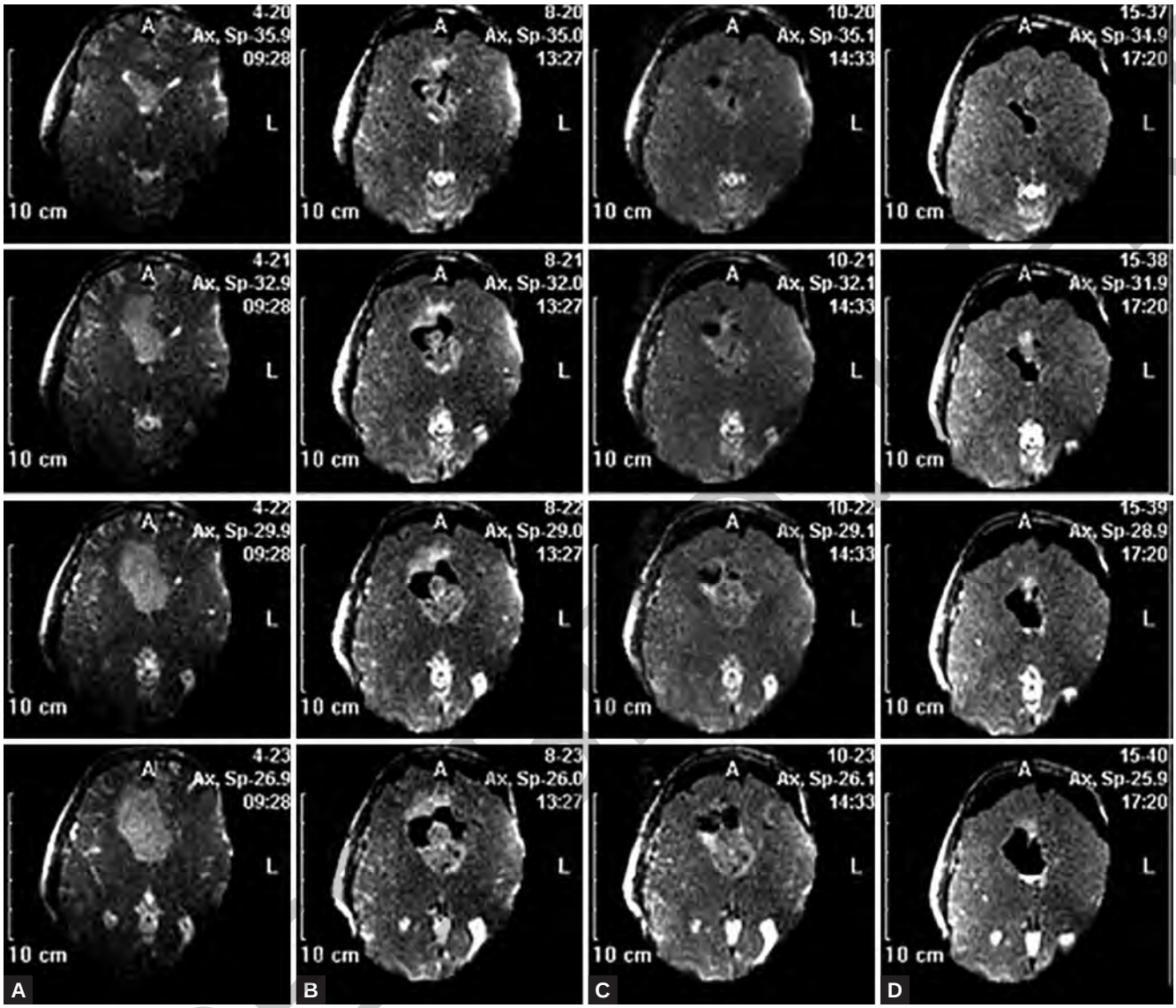

Figures 2.10A to D Intraoperative MRI (ioMRI) images obtained on a patient with an intraventricular mass using low field ioMRI. (A) Preoperative axial T1 postcontrast images; (B) First intraoperative magnetic resonance (MR) images performed demonstrating partial resection of mass; (C) Second intraoperative MR images demonstrating residual tumor; (D) Final intraoperative MR images confirming gross total resection of tumor
Courtesy: Odin PoleStar® N-20 ioMRI system.

been to increase the extent of resection of glial tumors.[38,70-72] In 2011, Kubben and colleagues performed a systemic review evaluating the added value of ioMRI in surgical resection of high-grade gliomas.[73] They reviewed 12 non-randomized cohort studies that matched selection criteria from 1999–2010. In this meta-analysis, they compared extent of tumor resection, quality of life and survival within these studies. Knauth et al. was one of the first groups to evaluate, in 1999, whether low-field ioMRI with neuronavigation use increased the extent of tumor resection in patients with high-grade gliomas compared with neuronavigation alone. In 22/38 cases (53.7%), ioMRI use demonstrated residual tumor. In 17 of the 22 cases, resection of residual tumor was resumed after updating the neuronavigation system. Early postoperative imaging demonstrated that eight patients had residual tumor, which had been seen on intraoperative imaging as well. Therefore, 14 of the 22 patients ultimately had GTRs using ioMRI, increasing the GTR rate from 36.6% to 75.6% (P = 0.004).[70]

Shortly, thereafter, two additional studies were published looking at extent of resection in high grade gliomas. Wirtz and colleagues report on 66 cases of high-grade glioma that underwent surgery. Intraoperative scans demonstrated residual enhancing tumor in 41/66 patients (62.1%), no

contrast enhancement in 18/66 patients (27.2%), and inconclusive in 7/66 patients (10.6%). For 43 of these cases, there was additional resection of tumor based on intraoperative MR imaging. Early postoperative imaging demonstrated GTR in 37 of the 66 patients (56%), and residual tumor in 22/66 patients (33%). This study indicated that ioMRI use increased the GTR rate from 27.2% to 56%. The median survival for patients that underwent GTR was 13.3 months compared to those that underwent subtotal resection, which was 9.2 months; these results were statistically significant (P = 0.0035).[71] Bohinski and colleagues also reported on their cohort of 30 patients with high-grade glioma. Nine patients did not require additional resection, and ultimately had GTR on postoperative imaging. About 17 patients had intraoperative scans for which additional resection was needed after ioMRI. Of the patients who had additional resection, 13 ultimately had GTR, significantly increasing the GTR rate from 30% to 73%.[68]

Schneider and colleagues performed a retrospective analysis on 31 primary glioblastoma multiforme (GBM) patients on a 0.5 T scanner. They performed volumetric analysis of tumor preoperatively and postoperatively. First ioMRI scan demonstrated GTR in two of the 31 patients while last ioMRI scan demonstrated GTR in 11 of the 31 patients, thereby increasing the GTR rate from 6.5% to 35.5%. Median survival for patients with subtotal resection was 237 days compared with 537 days for patients that underwent GTR (P = 0.004).[73,74] Lenaburg et al. in their retrospective analysis of 35 GBM cases using a 0.2 T scanner, cite that 25 of the 35 cases led to additional resection, and last ioMRI scan in 27 of the 35 cases showed tumor resection of greater than 95%.[73,75]

Senft et al. published a study in 2010 (Technol Canc Res Treat) that retrospectively examined 41 primary GBM cases on a 0.15 T scanner. Ten patients underwent surgery with ioMRI where 31 patients underwent conventional surgery with neuronavigation. All 10 cases that utilized ioMRI demonstrated GTR on postoperative MRI performed within 72 hours of surgery, whereas 19 of the 31 cases that underwent conventional surgery had evidence of GTR. In addition, median survival for the ioMRI group was 88 weeks compared to 68 weeks in the cohort that underwent conventional surgery (P = 0.07).[76]

This report was followed up by the same authors with a prospective, randomized and controlled trial in 2011. In this study, patients were randomized to a treatment arm that underwent ioMRI-assisted surgery while those in the control group had surgery with neuronavigation only. The primary endpoint was extent of resection on early postoperative MRI within 72 hours of surgery; secondary endpoints were volume of residual tumor on postoperative MRI and progression-free survival at 6 months. Gross total resections were achieved in 23 (96%) of the 24 patients that had ioMRI assisted surgery compared to 17 (68%) of 25 patients in the control group (P = 0.023). Median postoperative volume of contrast enhancing tumor was 0 cm^3 in the intraoperative MRI group and 0.03 cm^3 in the conventional group (P = 0.0015). At 6 months, 16/24 (67%) patients in the ioMRI group had stable disease compared to 9/25 (36%) (P = 0.046). Lastly, the ioMRI group had a median progression free survival of 226 days compared to 154 days in the conventional surgery group, but this was not statistically significant (P = 0.083). This study was the first Level I evidence that demonstrated that ioMRI improved the extent of resection of high-grade gliomas.[77]

Senior Author's Experience

In the senior author's experience with low-field ioMRI (PoleStar N20), 531 neurosurgical procedures were performed using the ioMRI between the years of 2000 and 2013. Of these cases, 162 cases (31%) were for glioma and 102 cases (19%) were for resection of pituitary adenoma. In the LGG cohort (n = 68), use of the ioMRI affected the course of surgery in 44 patients (64.7%). 35 of the 44 patients' tumors (79.5%) were deemed to be "resectable", given its location and relationship to eloquent cortex and vital structures, and therefore, had a craniotomy for either intended subtotal resection or GTR. Nine patients had an "unresectable" tumor and therefore, underwent a stereotactic biopsy. In the patients that underwent a craniotomy for LGG resection, ioMRI affected the course of surgery in 24 patients (69%) by demonstrating residual tumor, which led to additional tumor resection. In 10 patients (23%), ioMRI confirmed that the surgical goals had been reached, thereby avoiding further dissection and surgery that could have led to new neurological deficit. In one patient, a post-resection hemorrhage was demonstrated within the surgical bed, which led to evacuation of the hematoma intraoperatively. Intraoperative MRI was helpful in patients that underwent stereotactic biopsy in that it confirmed the cannula placement within radiographically lesional tissue, and therefore avoided further passes of the stereotactic cannula. In three patients, intraoperative MRI led to change in position of the cannula as neuronavigation from preoperative images was inaccurate. In the high-grade glioma cohort, intraoperative MRI affected surgery in 56/94 patients (60%). About 49 patients underwent craniotomy while seven underwent a stereotactic biopsy given the location of the tumor. In the patients who underwent resection for HGG, intraoperative MR imaging led to additional tumor resection in 37 patients (39%) **(Figure 2.10)**. In 12 patients, ioMRI confirmed intended extent of resection, avoided further dissection, and/or demonstrated the surgical bed's relationship to eloquent brain (13%). In five of the seven patients that underwent stereotactic biopsy, cannula placement was readjusted either based on ioMR images demonstrating less optimal placement of cannula or due to inconclusive or negative frozen biopsy.

One hundred and nine patients underwent surgery for resection of pituitary adenoma. In this cohort, ioMRI affected surgery in 53 cases (49%). In 37/53 (70%) patients, ioMRI led to additional tumor removal and dissection. In 13 patients,

JAYPEE BROTHERS

ioMRI demonstrated adequate decompression of the optic chiasm with no evidence of residual tumor. Therefore, in these patients, further dissection was avoided (25%). In one case, ioMRI demonstrated that the initial transphenoidal approach was too low given abnormal transnasal anatomy; trajectory was then redirected more superiorly afterwards. In three additional cases, ioMRI guidance was utilized to drain a multilobulated cyst associated with craniopharyngioma, place a ventricular catheter in another large cyst within a craniopharyngioma and lastly, to confirm decompression of the optic chiasm from a suprasellar cyst.

High-field Intraoperative MRI for Resection of High-grade Glioma

Much less data is available regarding the use of high-field ioMRI, likely due to the fact that their utilization and incorporation into surgery is much less compared to the lower field ioMRI systems given the increased costs and required changes to operating room infrastructure. In 2006, Nimsky et al. reviewed their cohort of 137 patients that underwent resection of tumors using intraoperative high-field MRI in an operative suite utilizing functional neuronavigation. Utilization of the ioMRI increased the GTR rate from 27% to 40%.[38]

In 2009, Hatiboglu and colleagues published one of the first series looking at volumetric measurement of extent of resection of gliomas using high-field ioMRI (1.5 T). 21 patients in their cohort of 44 underwent further resection of residual tumor based on ioMRI results, with resultant complete resection of tumor in 15 (70%) of the 21 patients. GTR for the entire cohort as a result of utilizing ioMRI was achieved in 15 (24%) of the 44 patients. In patients with GBM, extent of resection increased from 83% to 98% after ioMRI scan, with resultant GTR in 12 (92%) of 13 patients ($P < 0.001$).[72]

Most recently, Haydon et al. reported their results of resection of glioma using high-field 1.5 T ioMRI. Preoperative, intraoperative and postoperative volumetric extents of resection were determined using manual segmentation. Use of ioMRI resulted in further extent of resection in 113 (60%) of their glioma cases, with higher frequency of additional resection in their high-grade glioma group compared with their LGG group (65% vs 54%). In the high-grade glioma cohort, the number of complete resections increased from 24% to 57% with use of ioMRI leading to additional resection. The additional resection after ioMRI led to increased mean extent of resection from 94% to 98%.[78]

Intraoperative MRI for Resection of Low-grade Glioma

In the past, surgical management for LGGs has been under debate. Management of patients with presumed LGGs would be to perform a biopsy and then treat with radiation. However, several large prospective studies have demonstrated that chemotherapy and radiation have been unsuccessful as primary treatment for these tumors.[79]

Claus et al. reviewed their series of patients at Brigham and Women's Hospital, evaluating the utilization of ioMRI for patients with gliomas. Complete resection was achieved in 56 (36%) of 156 patients with LGGs. In this study, patients who underwent partial resection of tumor were 1.4 times more likely than patients with total resection to develop recurrence. Additionally, patients who underwent partial resection were at 4.9 times the risk of death as patient who underwent total resection. This was one of the first studies to suggest an association between surgical resection and survival for patients who underwent surgery for LGG with ioMRI.[80] Following this study, additional retrospective studies have demonstrated that surgical resection increased survival in patients with LGGs.[81-83]

In the Hatiboglu et al. study from MD Anderson Cancer Center, extent of resection (EOR) of LGGs was examined using high-field 1.5 T ioMRI. The EOR increased from 63% to 100% for patients with nonenhancing World Health Organization (WHO) grade I gliomas. In the group that had nonenhancing tumors that were WHO grade II glioma on pathology, performing an ioMRI scan led to an increase in the percentage of tumor resected from 69% to 78%. While these results were not statistically significant due to limited number of patients in both cohorts, these implied that for low-grade nonenhancing tumors, ioMRI did lead to increased tumor resection.[72]

Pamir et al. published their series of patients using an ultra-high field ioMRI with a 3 T magnet utilizing MR spectroscopy. In this study, 56 patients underwent surgery using the ioMRI. At first ioMRI imaging, GTR was achieved in 31 (55.4%) of cases, with residual tumor remaining in 25 (44.6%). What was interesting about this study was that intraoperative sonography was also used to localize tumor, and then concurrently with the ioMRI scans to detect residual tumor. Only in four (16%) of the 25 cases was sonography able to detect the residual tumor. This was compared to 21 (37.5%) patients that had tumor that was not appreciated by gross examination or via ultrasonography that was picked up via ioMRI. There was additional surgical resection of tumor in 21 of the 25 cases, with ultimately, GTR achieved in 41 (73.2%) of the 56 patients, increasing the overall GTR rate from 55.4% to 73.2%. This study also showed that while intraoperative ultrasonography is useful for localization of tumor and determination of EOR, it has decreased sensitivity for detecting residual tumor when compared with ioMRI. In addition, proton MR spectroscopy was a capability that was used intraoperatively with the high-field ioMRI in order to differentiate residual tumor tissue from peritumoral changes that would not be possible with ultrasonography or even low-field ioMRI.[84,85]

While the aforementioned study used high-field ioMRI, Senft et al. evaluated their results for gliomas using low-field MRI and compared contrast-enhancing tumors with

JAYPEE BROTHERS

nonenhancing tumors. In this cohort of 21 cases with nonenhancing tumors, 14 (66.7%) patients' intraoperative scans demonstrated residual tumor, leading to further resection in 10 patients (47.6%). In this cohort of 10 patients with residual tumor, the intended goal for GTR was in two patients and this was achieved using ioMRI. In the remaining eight patients, additional resection was continued until the surgeon deemed it not possible due to relationship of tumor to eloquent cortex. Therefore, while the GTR rate was not as high for the cohort of patients with nonenhancing lower grade tumors compared with enhancing tumors, the surgical goal of maximal subtotal tumor resection could be achieved utilizing ioMRI. While there was an increased rate of complete tumor resection in patients with contrast enhancing tumors, the authors noted that intraoperative visualization of complete resection is less specific with non-contrast enhancing tumors. They suggested that when using low-field ioMRI systems, sequences such as intraoperative T2 or fluid attenuation inversion recovery (FLAIR) sequences may more helpful in delineating tumor margins for nonenhancing tumors. To date, there has not been any study that has directly compared low-field ioMRI with high-field ioMRI in EOR for gliomas.[69]

Intraoperative MRI for Transphenoidal Surgery

Intraoperative MRI has been used for transphenoidal surgery to treat sellar and suprasellar tumors since 2000.[86-95] The ability to detect residual tumor via ioMRI can increase the rate of complete tumor removal, and prevent injury to vital structures such as optic chiasm and carotid arteries. For nonfunctioning macroadenomas, ioMRI has demonstrated to be useful as once the tumor has been partially decompressed, anatomical shifts may occur such as the bowing down of the diaphragm sella and CSF leak and egress which can prove preoperative imaging used for neuronavigation less sensitive. Wu et al. study demonstrated that low-field ioMRI use resulted in additional tumor resection in 17 (49%) of 55 cases, and increased the rate of complete resection from 58% to 84%.[95] Nimsky et al. also looked at their cohort of nonfunctioning macroadenomas and using a high-field ioMRI, showed that their rate of complete tumor resection increased from 58% to 82%.[92] Both these studies demonstrated that while ioMRI does increase the rate of complete resection, the strength of the magnetic field was not a factor in transphenoidal surgery for nonfunctioning macroadenomas.

Berkmann et al. evaluated the correlation between visual improvement and optic nerve decompression detected by ioMRI in patients that underwent transphenoidal resection of pituitary lesions. Intraoperative MR imaging was performed after the surgeon felt that complete resection or surgical goals, (i.e. decompression of optic chiasm) had been achieved, if complete tumor removal was not safely possible. About 32 patients underwent surgery, and complete resection was achieved in 17 patients (53%), as demonstrated by initial ioMRI scan. Eight patients (25%) of the total cohort underwent further resection, and in four of these eight patients, suprasellar remnants of tumor were detected with subsequent decompression of the optic chiasm. Improvement of visual acuity was noted in 24 of the 32 patients (86%) one month postoperatively. In addition, ioMRI demonstrated residual tumor in the suprasellar or parasellar region in two patients that required transcranial procedures at a later time. This study implied that use of ioMRI may allow for early detection of symptomatic, compressive suprasellar remnants that may not otherwise detected until postoperatively.[96]

For functioning pituitary adenomas, ioMRI use has been less reported. This may be because most functioning adenomas present earlier, and are often smaller at diagnosis. For functioning adenomas, complete tumor resection is crucial for long-term endocrine remission.[86,97-99] In Fahlbusch et al. study, high-field ioMRI increased the rate of endocrine remission from 33% to 44% during the first 3 months postoperatively while ultra-low-field ioMRI increased the remission rate by 5.1% during the first postoperative month.[87,100] While the aforementioned studies demonstrated a relatively small increase in the remission rate and short term follow up, Tanei et al. study evaluating the use of high-field 1.5 T ioMRI for transphenoidal surgery for functioning adenomas with a follow up of 13–54 months demonstrated a long-term remission rate increase from 57% to 79%.[86] Additionally, postoperative imaging is difficult to interpret many times given that postoperative changes, including sellar floor reconstruction may distort anatomy.[99] Utilization of ioMRI may detect tumor remnants that may otherwise be difficult to appreciate on standard postoperative MRI.[86]

Adjunctive Techniques with Intraoperative MRI

While intraoperative imaging provides real-time anatomical information, what is at least equally important is the ability to identify functional tissue so that neurological function may be preserved during surgery. Studies evaluating cortical mapping for glioma surgery have demonstrated that infiltrative tumors can have functional tissue contained within the tumor substance.[101] Therefore, being able to obtain a complete resection may be at the expense of causing a catastrophic neurological deficit. Utilizing other techniques such as intraoperative monitoring, awake cortical mapping and subcortical mapping can provide significant information about the relationship of the tumor and its margins to functional brain. Hatiboglu et al. study from MD Anderson Cancer Center demonstrated that intraoperative cortical mapping is feasible with intraoperative MR imaging, providing the capability of maximizing extent of resection and minimizing postoperative neurological deficit.[26]

Leuthardt et al. described their technique of performing awake craniotomies with intraoperative cortical mapping and high-field ioMRI .They performed 12 awake craniotomies

JAYPEE BROTHERS

and demonstrated 11 of the 12 ioMRI scans demonstrated residual tumor. Five of the tumors were in eloquent areas, while in six cases, further surgical resection was performed, with an ultimate GTR in five of the 12 patients.[102] Weingarten et al. also report their series of patients that underwent awake cortical mapping and ioMRI. Their GTR rate was 70%, with no patients having a permanent postoperative deficit.[103] These studies demonstrate that using both techniques proved to be complementary as it maximized tumor resection while identifying those patients in which further surgery would have caused a neurological deficit.

Other functional imaging modalities such as fMRI, positron emission tomography (PET), magnetic source imaging, cortical and subcortical mapping, and using DTI are now being used in order to identify these functional areas so that they can be avoided during surgery **(Figures 2.7 and 2.8)**.[84,104] Nimsky et al. performed fMRI intraoperative DTI sequences using high-field ioMRI in 37 patients undergoing glioma surgery. Using intraoperative MR tractography, the authors were able to show that white matter tracts shift from −8 mm to +15 mm and that their position in relation to the tumor resection cavity margin also changed. In deep-seated tumors near eloquent areas of the brain, intraoperative DTI plays a valuable role **(Figure 2.8)**.[104]

A more recently used method for intraoperative tumor visualization is utilizing fluorescence guidance and 5-aminolevulenic acid (5-ALA). 5-ALA is orally administered preoperatively, and is systemically metabolized and promotes accumulation of fluorescent protoporphyrin IX into high-grade gliomas. Studies have demonstrated that higher grade gliomas accumulate more protoporphyrin IX compared to lower grade gliomas because of increased proliferation and blood-brain barrier permeability.[105-108] Given the selective accumulation of this agent into tumors, using an operating microscope with the appropriate filter allows the surgeon to delineate normal tissue and tumor tissue. Initial studies by Stummer et al. and Koc et al. demonstrated significant differences in rates of GTR between 5-ALA fluorescein-guided resection versus control.[107-111] While there was a statistically significant increase in progression free survival for the 5-ALA group compared with the control group, there was no significant difference in overall survival times between the two groups.

Tsugu and colleagues published a study in 2011 that compared ioMRI-guided resection with resection guided by 5-ALA and ioMRI. Of the 21 patients that were 5-ALA induced fluorescence positive, surgery with ioMRI was performed in 10 with an average resection rate of 92.6% versus 92.8% in patients who underwent surgery without ioMRI. 5-ALA fluorescence was not detected in 12 patients with gliomas, and in this cohort, surgery with ioMRI was performed in nine, with the average resection rate of 89.2% versus 68.7% average resection rate in patients without ioMRI. Therefore, in patients that were 5-ALA fluorescence negative, ioMRI was beneficial for achieving a better resection rate. It must be noted, however, that the group that was 5-ALA negative had greater percentage of patients with WHO grade II and III gliomas (75%) compared with the group that was 5-ALA positive, of which the majority was WHO grade IV (81%).[112]

Eyupoglu et al. also evaluated ioMRI in combination with 5-ALA, with superimposed functional neuronavigation. Tumor resection was carried out using the 5-ALA signal with functional neuronavigation guidance in order to avoid eloquent areas. Once 5-ALA signal was no longer seen, an ioMRI was performed. If residual tumor was identified on ioMRI scans, decision to continue with additional resection was made if functional neuronavigation demonstrated a good margin between residual tumor and functional brain tissue. In all cases, the 5-ALA signal was redetected once surgery was continued. In their cohort of 37 patients, all of whom had WHO grade III or IV gliomas, 21 ioMRI scans confirmed complete resection performed with 5-ALA fluorescence. In the remaining subgroup where patients that had tumors adjacent, but not within eloquent brain areas, the combination of 5-ALA, and ioMRI increased the extent of tumor resection from 61.7% to 100%. Only one patient had a decrease in their postoperative Karnofsky performance score by 20%. Additionally, in patients that had tumors within eloquent brain areas, ioMRI in combination with functional neuronavigation proved to be superior to 5-ALA resection technique.[113]

OPTIMIZATION OF COSTS OF INTRAOPERATIVE NAVIGATION AND IMAGING

Given the mounting need for delivery of "cost-effective" medical care, well-designed studies assessing the value of integrating intraoperative imaging and neuronavigation will need to be conducted. The biggest obstacle in the implementation of these technologies is the cost. A modern high-field ioMRI system costs approximately US $3,000,000. In addition, surgical and anesthetic equipment used in the operating room, shielding of the operating room, and software and MR equipment upgrades and maintenance ultimately costs the hospital over US $3,000,000. If this cost cannot be matched by the number of cases for which it is used for, centers now have justified the cost by using the high-field (1.5 T) MRI for generalized diagnostic purposes for the hospital during operating room "off-time".[114]

There is sufficient evidence at this point that the use of neuronavigation and intraoperative imaging can reduce costs by decreasing reoperation rates, increasing patient safety and decreasing neurological morbidity. Furthermore, by increasing the extent of resection of tumors while preserving neurological function, these technologies are decreasing not only the likelihood of recurrence but also overall survival. Hall et al. published a study in 2003 comparing the costs and benefits of brain tumor resection in a conventional operating

JAYPEE BROTHERS

room versus ioMRI suite. In this study, ioMRI surgery had a shorter length of stay, lower total hospital costs and lower cost-to-charge ratio compared to conventional operating room surgery, suggesting that ioMRI surgery was correlated with improved net health outcomes. This study, however, was a retrospective, nonrandomized, case-controlled study with a small patient cohort.[115]

Makary et al. recently compared the clinical effectiveness and costs of using a low-field ioMRI compared with a conventional MRI for brain tumor surgery. Intraoperative MRI patients tended to have shorter hospital length of stay (LOS) compared with the conventional surgery group; however, this was not statistically significant. Patients undergoing ioMRI-guided surgery had fewer postoperative complications than the conventional cohort. While EOR was not analyzed between the two cohorts, repeat resection occurred at a longer time interval than for the conventional group (P = 0.02). This study also performed a feasibility analysis for a low-field ioMRI system and concluded that the ioMRI had substantially greater capital costs compared to the average capital cost of ultrasonography and CT. Based on the author's institutional experience, the total implementation and operation cost for a low-field ioMRI's 5 year useful life was over $3.8 million while the depreciation cost per ioMRI procedure increased threefold over the machine's lifetime because its usage actually decreased over this same time period. On the other hand, their cost effectiveness analysis demonstrated that ioMRI was increasingly cost-effective for each added repeat "resection free year" for the patient when compared with a conventional MRI. Even though both ioMRI and conventional MRI patients had similar repeat resection rates, the longer resection-free postoperative interval for the ioMRI cohort was associated with a more cost-effective outcome.[116]

So, why is the utilization of ioMRI not increasing more rapidly in an age when technological advances in medicine and society are readily embraced in other ways? Perhaps it is because neurosurgeons are learning that this technology is more useful for subsets of patients with certain tumors such as LGGs, a disease with a relatively low incidence. Much data have been published about the role of ioMRI in surgery for infiltrative glioma and pituitary adenoma; however, its role in other neoplasm types has not been fully clarified.[116,68,71,88,117-120] In comparison to high-field ioMRIs, intraoperative low-field systems have longer scanning times, with lower resolution due the low signal to noise ratio obtainable. The imaging quality secondary to image artifacts has led to misinterpretation of intraoperative imaging with a high false-positive rate of up to 16%. This can lead to incomplete resections or unnecessary resections with an increasing risk of neurological morbidity. Also, low-field ioMRI is limited to basic T1, T2 and FLAIR-weighted imaging, thereby limiting the ability to acquire such "advanced" studies as fMRI, DTI, and MR spectroscopy. These systems are, however, much more compact, mobile and open bore, allowing the surgeon the greatest access to patients with limited OR modifications and less disruption to workflow.[121] High-field ioMRI systems offer shorter scanning time and better image quality with the ability to perform the above-mentioned advanced studies, but their use requires special infrastructural modifications in order to allow better imaging quality and improve surgical access.[69,122]

In today's era of evidence and outcomes-based medicine, the ioMRI must be able to significantly affect LOS, repeat resection rates and overall increased institutional utilization, the latter likely being most significant in term of justifying its high "up-front" financial cost. Hall's study, among others evaluating the economic feasibility of high-field ioMRI has demonstrated that the ability to offset the high capital costs of a high-field ioMRI is by utilizing it for routine diagnostic imaging.[68,72,115,116,123-125] Ultimately, the feasibility of incorporating intraoperative MR imaging into a practice for brain tumor surgery may require well-designed studies that analyze the medical outcomes and economic value of implementation of these technologies into day-to-day neurosurgical practice. However, as technological advances in the fields of neurosurgery and neuroradiology continue to mount, the field of neurosurgery must embrace the incorporation of these advances into routine practice, so that ultimately, just as neuronavigational systems have now become a standard of practice, utilization of intraoperative imaging will become customary and current obstacles encountered will be overcome by striving to improve the current systems.

REFERENCES

1. Enchev Y. Neuronavigation: geneology, reality, and prospects. Neurosurg Focus. 2009;27(3):E11.
2. Leeds NE, Kieffer SA. Evolution of diagnostic neuroradiology from 1904 to 1999. Radiology. 2000;217(2):309-18.
3. Dandy WE. Rontgenography of the brain after the injection of air into the spinal canal. Ann Surg. 1919;70(4):397-403.
4. Spiegel EA, Wycis HT, Marks M, et al. Stereotaxic apparatus for operations on the human brain. Science. 1947;106(2754):349-50.
5. Leksell L. The stereotaxic method and radiosurgery of the brain. Acta Chir Scand. 1951;102(4):316-9.
6. Riechert T, Wolff M. A new directive apparatus for the coagulation of the ganglion Gasseri and other intracerebral procedures. Acta Neurochir (Wien). 1952;2(3-4):405-7.
7. Wells TH, Cosman ER, Ball RE. The Brown-Roberts-Wells (BRW) arc: its concept as a spatial navigation system. Appl Neurophysiol. 1987;50(1-6):127-32.
8. Heilbrun MP, Roberts TS, Apuzzo ML, et al. Preliminary experience with Brown-Roberts-Wells (BRW) computerized tomography stereotaxic guidance system. J Neurosurg. 1983;59(2):217-22.
9. Young RF. Application of robotics to stereotactic neurosurgery. Neurol Res. 1987;9(2):123-8.
10. Benabid AL, Lavallee S, Hoffmann D, et al. Potential use of robots in endoscopic neurosurgery. Acta Neurochir. Suppl (Wien). 1992;54:93-7.

JAYPEE BROTHERS

11. Apuzzo ML, Chen JC. Stereotaxy, navigation and the temporal concatenation. Stereotact Funct Neurosurg. 1999;72(2-4):82-8.
12. Apuzzo ML, Sabshin JK. Computed tomographic guidance stereotaxis in the management of intracranial mass lesions. Neurosurgery. 1983;12(3):277-85.
13. Hounsfield GN. Computerized transverse axial scanning (tomography). 1. Description of system. Br J Radiol. 1973;46(552):1016-22.
14. Shalit MN, Israeli Y, Matz S, et al. Intra-operative computerized axial tomography. Surg Neurol. 1979;11(5):382-4.
15. Gasiński P, Zieliński P, Harat M, et al. Application of intraoperative computed tomography in a neurosurgical operating theatre. Neurol Neurochir Pol. 2012;46(6):536-41.
16. Holly LT, Foley KT. Intraoperative spinal navigation. Spine (Phila Pa 1976). 2003;28(15):S54-61.
17. Hum B, Feigenbaum F, Cleary K, et al. Intraoperative computed tomography for complex craniocervical operations and spinal tumor resections. Neurosurgery. 2000;47(2):374-80.
18. Beck M, Mittlmeier T, Gierer P, et al. Benefit and accuracy of intraoperative 3D-imaging after pedicle screw placement: a prospective study in stabilizing thoracolumbar fractures. Eur Spine J. 2009;18(10):1469-77.
19. Tormenti MJ, Kostov DB, Gardner PA, et al. Intraoperative computed tomography image-guided navigation for posterior thoracolumbar spinal instrumentation in spinal deformity surgery. Neurosurg Focus. 2010;28(3):E11.
20. Roberts DW, Strohbehn JW, Hatch JF, et al. A frameless stereotaxic integration of computerized tomographic imaging and the operating microscope. J Neurosurg. 1986;65(4):545-9.
21. Black PM, Moriarty T, Alexander E, et al. Development and implementation of intraoperative magnetic resonance imaging and its neurosurgical applications. Neurosurgery. 1997;41(4):831-42.
22. Liang D, Schulder M. The role of intraoperative magnetic resonance imaging in glioma surgery. Surg Neurol Int. 2012;3(4):S320-7.
23. Lee CC, Lee ST, Chang CN, et al. Volumetric measurement for comparison of the accuracy between intraoperative CT and postoperative MR imaging in pituitary adenoma surgery. Am J Neuroradiol. 2011;32(8):1539-44.
24. Coenen VA, Krings T, Weidemann J, et al. Sequential visualization of brain and fiber tract deformation during intracranial surgery with three-dimensional ultrasound: an approach to evaluate the effect of brain shift. Neurosurgery. 2005;56(1):133-41.
25. Gasco J, Tummala S, Mahajan NM, et al. Simultaneous use of functional tractography, neuronavigation-integrated subcortical white matter stimulation and intraoperative magnetic resonance imaging in glioma surgery: technical note. Stereotact Funct Neurosurg. 2009;87(6):395-8.
26. Hatiboglu MA, Weinberg JS, Suki D, et al. Utilization of intraoperative motor mapping in glioma surgery with high-field intraoperative magnetic resonance imaging. Stereotact Funct Neurosurg. 2010;88(6):345-52.
27. Rasmussen IA, Lindseth F, Rygh OM, et al. Functional neuronavigation combined with intra-operative 3D ultrasound: initial experiences during surgical resections close to eloquent brain areas and future directions in automatic brain shift compensation of preoperative data. Acta Neurochir (Wien). 2007;149(4):365-78.
28. Orringer DA, Golby A, Jolesz F. Neuronavigation in the surgical management of brain tumors: current and future trends. Expert Rev Med Devices. 2012;9(5):491-500.
29. Paleologos TS, Wadley JP, Kitchen ND, et al. Clinical utility and cost-effectiveness of interactive image-guided craniotomy: clinical comparison between conventional and image-guided meningioma surgery. Neurosurgery. 2000;47(1):40-7.
30. Willems PW, Taphoorn MJ, Burger H, et al. Effectiveness of neuronavigation in resecting solitary intracerebral contrast-enhancing tumors: a randomized controlled trial. J Neurosurg. 2006;104(3):360-8.
31. Willems PW, van der Sprenkel JW, Tulleken CA, et al. Neuronavigation and surgery of intracerebral tumours. J Neurol. 2006;253(9):1123-36.
32. Garber ST, Jensen RL. Image guidance for brain metastases resection. Surg Neurol Int. 2012;3(2):S111-7.
33. Schackert G, Steinmetz A, Meier U, et al. Surgical management of single and multiple brain metastases: results of a retrospective study. Onkologie. 2001;24(3):246-55.
34. Weiss L, Gilbert HA, Posner JB. Brain metastasis. Boston: GK Hall; 1980.
35. Wadley J, Dorward N, Kitchen N, et al. Pre-operative planning and intra-operative guidance in modern neurosurgery: a review of 300 cases. Ann R Coll Surg Engl. 1999;81(4):217-25.
36. Roessler K, Ungersboeck K, Dietrich W, et al. Frameless stereotactic guided neurosurgery: clinical experience with an infrared based pointer device navigation system. Acta Neurochir (Wien). 1997;139(6):551-9.
37. Nabavi A, Black PM, Gering DT, et al. Serial intraoperative magnetic resonance imaging of brain shift. Neurosurgery. 2001;48(4):787-97.
38. Nimsky C, Ganslandt O, Buchfelder M, et al. Intraoperative visualization for resection of gliomas: the role of functional neuronavigation and intraoperative 1.5 T MRI. Neurol Res. 2006;28(5):482-7.
39. Benveniste RJ, Germano IM. Correlation of factors predicting intraoperative brain shift with successful resection of malignant brain tumors using image-guided techniques. Surg Neurol. 2005;63(6):542-8.
40. Dorward NL, Alberti O, Velani B, et al. Postimaging brain distortion: magnitude, correlates, and impact on neuronavigation. J Neurosurg. 1998;88(4):656-62.
41. Golfinos JG, Fitzpatrick BC, Smith LR, et al. Clinical use of a frameless stereotactic arm: results of 325 cases. J Neurosurg. 1995;83(2):197-205.
42. Sipos EP, Tebo SA, Zinreich SJ, et al. In vivo accuracy testing and clinical experience with the ISG viewing wand. Neurosurgery. 1996;39(1):194-202.
43. Yamasaki T, Moritake K, Takaya M, et al. Intraoperative use of doppler ultrasound and endoscopic monitoring in the stereotactic biopsy of malignant brain tumors. Technical note. J Neurosurg. 1994;80(3):570-4.
44. Gronningsaeter A, Kleven A, Ommedal S, et al. SonoWand: an ultrasound-based neuronavigation system. Neurosurgery. 2000;47(6):1373-9.
45. Koivukangas J, Louhisalmi Y, Alakuijala J, et al. Ultrasound-controlled neuronavigator-guided brain surgery. J Neurosurg. 1993;79(1):36-42.
46. Unsgaard G, Selbekk T, Brostrup Müller T, et al. Ability of navigated 3D ultrasound to delineate gliomas and metastases:

JAYPEE BROTHERS

comparison of image interpretations with histopathology. Acta Neurochir (Wien). 2005;147(12):1259-69.
47. Lindseth F, Kaspersen JH, Ommedal S, et al. Multimodal image fusion in ultrasound-based neuronavigation: improving overview and interpretation by integrating preoperative MRI with intraoperative 3D ultrasound. Comput Aided Surg. 2003;8(2):49-69.
48. Lindseth F, Langø T, Bang J, et al. Accuracy evaluation of a 3D ultrasound-based neuronavigation system. Comput Aided Surg. 2002;7(4):197-222.
49. Solheim O, Selbekk T, Jakola AS, et al. Ultrasound-guided operations in unselected high-grade gliomas: overall results, impact of image quality and patient selection. Acta Neurochir (Wien). 2010;152(11):1873-86.
50. Moiyadi AV, Shetty PM, Mahajan A, et al. Usefulness of three-dimensional navigable intraoperative ultrasound in resection of brain tumors with a special emphasis on malignant gliomas. Acta Neurochir (Wien). 2013;155(12):2217-25.
51. Bonsanto MM, Metzner R, Aschoff A, et al. 3D ultrasound navigation in syrinx surgery: a feasibility study. Acta Neurochir (Wien). 2005;147(5):533-40.
52. Gläsker S, Shah MJ, Hippchen B, et al. Doppler-sonographically guided resection of central nervous system hemangioblastomas. Neurosurgery. 2011;68(2):267-75.
53. Kolstad F, Rygh OM, Selbekk T, et al. Three-dimensional ultrasonography navigation in spinal cord tumor surgery. Technical note. J Neurosurg. Spine. 2006;5(3):264-70.
54. Solheim O, Selbekk T, Løvstakken L, et al. Intrasellar ultrasound in transsphenoidal surgery: a novel technique. Neurosurgery. 2010;66(1):173-85.
55. Unsgaard G, Ommedal S, Rygh OM, et al. Operation of arteriovenous malformations assisted by stereoscopic navigation-controlled display of preoperative magnetic resonance angiography and intraoperative ultrasound angiography. Neurosurgery. 2005;56(2):281-90.
56. Selbekk T, Jakola AS, Solheim O, et al. Ultrasound imaging in neurosurgery: approaches to minimize surgically induced image artefacts for improved resection control. Acta Neurochir (Wien). 2013;155(6):973-80.
57. Barrow DL, Boyer KL, Joseph GJ. Intraoperative angiography in the management of neurovascular disorders. Neurosurgery. 1992;30(2):153-9.
58. Derdeyn CP, Moran CJ, Cross DT, et al. Intraoperative digital subtraction angiography: a review of 112 consecutive examinations. Am J Neuroradiol. 1995;16(2):307-18.
59. Payner TD, Horner TG, Leipzig TJ, et al. Role of intraoperative angiography in the surgical treatment of cerebral aneurysms. J Neurosurg. 1998;88(3):441-8.
60. Suzuki K, Kodama N, Sasaki T, et al. Confirmation of blood flow in perforating arteries using fluorescein cerebral angiography during aneurysm surgery. J Neurosurg. 2007;107(1):68-73.
61. Li J, Lan Z, He M, et al. Assessment of microscope-integrated indocyanine green angiography during intracranial aneurysm surgery: a retrospective study of 120 patients. Neurol India. 2009;57(4):453-9.
62. Ma CY, Shi JX, Wang HD, et al. Intraoperative indocyanine green angiography in intracranial aneurysm surgery: Microsurgical clipping and revascularization. Clin Neurol Neurosurg. 2009;111(10):840-6.
63. Uhl E, Zausinger S, Morhard D, et al. Intraoperative computed tomography with integrated navigation system in a multidisciplinary operating suite. Neurosurgery. 2009;64(5 Suppl 2):231-9.
64. Okudera H, Kobayashi S, Sugita K. Technical note: mobile CT scanner gantry for use in the operating room. Am J Neuroradiol. 1991;12(1):131-2.
65. Okudera H, Kobayashi S, Kyoshima K, et al. Development of the operating computerized tomographic scanner system for neurosurgery. Acta Neurochir (Wien). 1991;111(1-2):61-3.
66. Hundt W, Rust F, Stäbler A, et al. Dose reduction in multislice computed tomography. J Comput Assist Tomogr. 2005;29(1):140-7.
67. Kosmopoulos V, Schizas C. Pedicle screw placement accuracy: a meta-analysis. Spine (Phila Pa 1976). 2007;32(3):E111-20.
68. Bohinski RJ, Kokkino AK, Warnick RE, et al. Glioma resection in a shared-resource magnetic resonance operating room after optimal image-guided frameless stereotactic resection. Neurosurgery. 2001;48(4):731-42.
69. Senft C, Seifert V, Hermann E, et al. Usefulness of intraoperative ultra low-field magnetic resonance imaging in glioma surgery. Neurosurgery. 2008;63(4 Suppl 2):257-66.
70. Knauth M, Wirtz CR, Tronnier VM, et al. Intraoperative MR imaging increases the extent of tumor resection in patients with high-grade gliomas. Am J Neuroradiol. 1999;20(9):1642-6.
71. Wirtz CR, Knauth M, Staubert A, et al. Clinical evaluation and follow-up results for intraoperative magnetic resonance imaging in neurosurgery. Neurosurgery. 2000;46(5):1112-20.
72. Hatiboglu MA, Weinberg JS, Suki D, et al. Impact of intraoperative high-field magnetic resonance imaging guidance on glioma surgery: a prospective volumetric analysis. Neurosurgery. 2009;64(6):1073-81.
73. Kubben PL, ter Meulen KJ, Schijns OE, et al. Intraoperative MRI-guided resection of glioblastoma multiforme: a systematic review. Lancet Oncol. 2011;12(11):1062-70.
74. Schneider JP, Trantakis C, Rubach M, et al. Intraoperative MRI to guide the resection of primary supratentorial glioblastoma multiforme: a quantitative radiological analysis. Neuroradiology. 2005;47(7):489-500.
75. Lenaburg HJ, Inkabi KE, Vitaz TW. The use of intraoperative MRI for the treatment of glioblastoma multiforme. Technol Cancer Res Treat. 2009;8(2):159-62.
76. Senft C, Franz K, Blasel S, et al. Influence of iMRI-guidance on the extent of resection and survival of patients with glioblastoma multiforme. Technol Cancer Res Treat. 2010;9(4):339-46.
77. Senft C, Bink A, Franz K, et al. Intraoperative MRI guidance and extent of resection in glioma surgery: a randomised, controlled trial. Lancet Oncol. 2011;12(11):997-1003.
78. Haydon DH, Chicoine MR, Dacey RG. The impact of high-field-strength intraoperative magnetic resonance imaging on brain tumor management. Neurosurgery. 2013;60 Suppl 1:92-7.
79. Shaw EG, Wisoff JH. Prospective clinical trials of intracranial low-grade glioma in adults and children. Neuro Oncol. 2003;5(3):153-60.
80. Claus EB, Horlacher A, Hsu L, et al. Survival rates in patients with low-grade glioma after intraoperative magnetic resonance image guidance. Cancer. 2005;103(6):1227-33.
81. Berger MS, Deliganis AV, Dobbins J, et al. The effect of extent of resection on recurrence in patients with low grade cerebral hemisphere gliomas. Cancer. 1994;74(6):1784-91.
82. Keles GE, Lamborn KR, Berger MS. Low-grade hemispheric gliomas in adults: a critical review of extent of resection as a factor influencing outcome. J Neurosurg. 2001;95(5):735-45.

JAYPEE BROTHERS

83. Smith JS, Chang EF, Lamborn KR, et al. Role of extent of resection in the long-term outcome of low-grade hemispheric gliomas. J Clin Oncol. 2008;26(8):1338-45.
84. Pamir MN, Ozduman K, Dincer A, et al. First intraoperative, shared-resource, ultrahigh-field 3-Tesla magnetic resonance imaging system and its application in low-grade glioma resection. J Neurosurg. 2010;112(1):57-69.
85. Pamir MN, Özduman K, Yildiz E, et al. Intraoperative magnetic resonance spectroscopy for identification of residual tumor during low-grade glioma surgery: clinical article. J Neurosurg. 2013;118(6):1191-8.
86. Tanei T, Nagatani T, Nakahara N, et al. Use of high-field intraoperative magnetic resonance imaging during endoscopic transsphenoidal surgery for functioning pituitary microadenomas and small adenomas located in the intrasellar region. Neurol Med Chir (Tokyo). 2013;53(7):501-10.
87. Bellut D, Hlavica M, Schmid C, et al. Intraoperative magnetic resonance imaging-assisted transsphenoidal pituitary surgery in patients with acromegaly. Neurosurg Focus. 2010;29(4):E9.
88. Bohinski RJ, Warnick RE, Gaskill-Shipley MF, et al. Intraoperative magnetic resonance imaging to determine the extent of resection of pituitary macroadenomas during transsphenoidal microsurgery. Neurosurgery. 2001;49(5):1133-43.
89. Gerlach R, du Mesnil de Rochemont R, Gasser T, et al. Feasibility of Polestar N20: an ultra-low-field intraoperative magnetic resonance imaging system in resection control of pituitary macroadenomas: lessons learned from the first 40 cases. Neurosurgery. 2008;63(2):272-84.
90. Martin CH, Schwartz R, Jolesz F, et al. Transsphenoidal resection of pituitary adenomas in an intraoperative MRI unit. Pituitary. 1999;2(2):155-62.
91. Pergolizzi RS, Nabavi A, Schwartz RB, et al. Intra-operative MR guidance during trans-sphenoidal pituitary resection: preliminary results. J Magn Reson Imaging. 2001;13(1):136-41.
92. Nimsky C, von Keller B, Ganslandt O, et al. Intraoperative high-field magnetic resonance imaging in transsphenoidal surgery of hormonally inactive pituitary macroadenomas. Neurosurgery. 2006;59(1):105-14.
93. Schwartz TH, Stieg PE, Anand VK. Endoscopic transsphenoidal pituitary surgery with intraoperative magnetic resonance imaging. Neurosurgery. 2006;58(1):ONS44-51.
94. Vitaz TW, Inkabi KE, Carrubba CJ. Intraoperative MRI for transphenoidal procedures: short-term outcome for 100 consecutive cases. Clin Neurol Neurosurg. 2011;113(9):731-5.
95. Wu JS, Shou XF, Yao CJ, et al. Transsphenoidal pituitary macroadenomas resection guided by PoleStar N20 low-field intraoperative magnetic resonance imaging: comparison with early postoperative high-field magnetic resonance imaging. Neurosurgery. 2009;65(1):63-70.
96. Berkmann S, Fandino J, Zosso S, et al. Intraoperative magnetic resonance imaging and early prognosis for vision after transsphenoidal surgery for sellar lesions. J Neurosurg. 2011;115(3):518-27.
97. Campbell PG, McGettigan B, Luginbuhl A, et al. Endocrinological and ophthalmological consequences of an initial endonasal endoscopic approach for resection of craniopharyngiomas. Neurosurg Focus. 2010;28(4):E8.
98. Minniti G, Jaffrain-Rea ML, Esposito V, et al. Evolving criteria for post-operative biochemical remission of acromegaly: can we achieve a definitive cure? An audit of surgical results on a large series and a review of the literature. Endocr Relat Cancer. 2003;10(4):611-9.
99. Zirkzee EJ, Corssmit EP, Biermasz NR, et al. Pituitary magnetic resonance imaging is not required in the postoperative follow-up of acromegalic patients with long-term biochemical cure after transsphenoidal surgery. J Clin Endocrinol Metab. 2004;89(9):4320-4.
100. Fahlbusch R, Keller Bv, Ganslandt O, et al. Transsphenoidal surgery in acromegaly investigated by intraoperative high-field magnetic resonance imaging. Eur J Endocrinol. 2005;153(2):239-48.
101. Ojemann JG, Miller JW, Silbergeld DL. Preserved function in brain invaded by tumor. Neurosurgery. 1996;39(2):253-8.
102. Leuthardt EC, Lim CC, Shah MN, et al. Use of movable high-field-strength intraoperative magnetic resonance imaging with awake craniotomies for resection of gliomas: preliminary experience. Neurosurgery. 2011;69(1):194-205.
103. Weingarten DM, Asthagiri AR, Butman JA, et al. Cortical mapping and frameless stereotactic navigation in the high-field intraoperative magnetic resonance imaging suite. J Neurosurg. 2009;111(6):1185-90.
104. Nimsky C, Ganslandt O, Hastreiter P, et al. Preoperative and intraoperative diffusion tensor imaging-based fiber tracking in glioma surgery. Neurosurgery. 2007;61(1):178-85.
105. Krammer B, Plaetzer K. ALA and its clinical impact, from bench to bedside. Photochem Photobiol Sci. 2008;7(3):283-9.
106. Panciani PP, Fontanella M, Schatlo B, et al. Fluorescence and image-guided resection in high grade glioma. Clin Neurol Neurosurg. 2012;114(1):37-41.
107. Stummer W, Pichlmeier U, Meinel T, et al. Fluorescence-guided surgery with 5-aminolevulinic acid for resection of malignant glioma: a randomised controlled multicentre phase III trial. Lancet Oncol. 2006;7(5):392-401.
108. Stummer W, Reulen HJ, Novotny A, et al. Fluorescence-guided resections of malignant gliomas--an overview. Acta Neurochir Suppl. 2003;88:9-12.
109. Stummer W, Novotny A, Stepp H, et al. Fluorescence-guided resection of glioblastoma multiforme by using 5-aminolevulinic acid-induced porphyrins: a prospective study in 52 consecutive patients. J Neurosurg. 2000;93(6):1003-13.
110. Stummer W, Stepp H, Möller G, et al. Technical principles for protoporphyrin-IX-fluorescence guided microsurgical resection of malignant glioma tissue. Acta Neurochir (Wien). 1998;140(10):995-1000.
111. Koc K, Anik I, Cabuk B, et al. Fluorescein sodium-guided surgery in glioblastoma multiforme: a prospective evaluation. Br J Neurosurg. 2008;22(1):99-103.
112. Tsugu A, Ishizaka H, Mizokami Y, et al. Impact of the combination of 5-aminolevulinic acid-induced fluorescence with intraoperative magnetic resonance imaging-guided surgery for glioma. World Neurosurg. 2011;76(1-2):120-7.
113. Eyüpoglu IY, Hore N, Savaskan NE, et al. Improving the extent of malignant glioma resection by dual intraoperative visualization approach. PLoS One. 2012;7(9):e44885.
114. Ramina R, Coelho Neto M, Giacomelli A, et al. Optimizing costs of intraoperative magnetic resonance imaging. A series of 29 glioma cases. Acta Neurochir (Wien). 2010;152(1):27-33.
115. Hall WA, Kowalik K, Liu H, et al. Costs and benefits of intraoperative MR-guided brain tumor resection. Acta Neurochir Suppl. 2003;85:137-42.

JAYPEE BROTHERS

116. Makary M, Chiocca EA, Erminy N, et al. Clinical and economic outcomes of low-field intraoperative MRI-guided tumor resection neurosurgery. J Magn Reson Imaging. 2011;34(5):1022-30.
117. Darakchiev BJ, Tew JM, Bohinski RJ, et al. Adaptation of a standard low-field (0.3-T) system to the operating room: focus on pituitary adenomas. Neurosurg Clin N Am. 2005;16(1):155-64.
118. Fahlbusch R, Ganslandt O, Buchfelder M, et al. Intraoperative magnetic resonance imaging during transsphenoidal surgery. J Neurosurg. 2001;95(3):381-90.
119. Oh DS, Black PM. A low-field intraoperative MRI system for glioma surgery: is it worthwhile? Neurosurg Clin N Am. 2005;16(1):135-41.
120. Jolesz FA. Future perspectives for intraoperative MRI. Neurosurg Clin N Am. 2005;16(1):201-13.
121. Ronkainen J, Tervonen O. Cost analysis of an open low-field (0.23T) MRI unit: effect of procedure shares in combined imaging, interventional, and neurosurgical use. Acta Radiol. 2006;47(4):359-65.
122. Blanco RT, Ojala R, Kariniemi J, et al. Interventional and intraoperative MRI at low field scanner: a review. Eur J Radiol. 2005;56(2):130-42.
123. Nimsky C, Ganslandt O, Von Keller B, et al. Intraoperative high-field-strength MR imaging: implementation and experience in 200 patients. Radiology. 2004;233(1):67-78.
124. Hall WA, Liu H, Martin AJ, et al. Safety, efficacy, and functionality of high-field strength interventional magnetic resonance imaging for neurosurgery. Neurosurgery. 2000;46(3):632-41.
125. Lewin JS, Metzger A, Selman WR. Intraoperative magnetic resonance image guidance in neurosurgery. J Magn Reson Imaging. 2000;12(4):512-24.

JAYPEE BROTHERS

for detailed information on neurosurgery books, visit our website **www.jaypeebrothers.com,** for detailed information on neurosurgery

INTRAOPERATIVE IMAGING IN NEUROSURGERY

Karanjit Singh Narang is an Associate Director (Neurosurgery), Institute of Neurosciences; and Head, Image-guided Neurosurgery, Medanta—The Medicity, Gurugram, Haryana, India. He has been trained at All India Institute of Medical Sciences (AIIMS), New Delhi. He has been working at Medanta—The Medicity since 2009. His current interests include image-guided brain and spinal surgeries.



Ajaya Nand Jha is the Chairman, Institute of Neurosciences, Medanta—The Medicity, Gurugram, Haryana, India since 2009. He is a pioneer in getting intraoperative MRI (iMRI) for brain tumor surgeries in India. He graduated (1976) from the Armed Forces Medical College, Pune, Maharashtra, and has done his FRCS in surgical neurology from UK. His interests cover entire neurosurgery, but his current focus is on intrinsic tumors of the brain.



Available at all medical bookstores
or buy online at www.jaypeebrothers.com

JAYPEE BROTHERS
Medical Publishers (P) Ltd.
www.jaypeebrothers.com

Join us on facebook.com/JaypeeMedicalPublishers

Shelving Recommendation
NEUROSURGERY

ISBN 978-93-86322-90-6