ailed information on otolaryngology books, visit our website **www.jaypeebrothers.com,** for detailed information on otolaryngology books, visit our website **www.jaypeebrothers.com**

# Textbook of Voice & Laryngology





**KK Handa**

*Foreword*
**Markus Hess**

JAYPEE

# Contents


**1. Clinical Anatomy** 1
*KK Handa, Dhananjay Kumar*
Anatomy of the Larynx *1*
Laryngeal Cartilages *2*
Laryngeal Ligaments *3*
Laryngeal Musculature *4*
Laryngeal Joints *5*
Laryngeal Innervation *6*

**2. Voice Evaluation** 9
*KK Handa, Karan Aggarwal*
Problems in Voice Evaluation *9*
Voice Test Battery *9*
Voice Material *9*
Voice Testing in Detail *10*
Acoustic and Electrolaryngographic Voice Evaluation *14*
Aerodynamic Measures *15*

**3. Imaging of Benign Laryngeal Pathology: Expanding Horizons** 17
*Smita Manchanda, Ashu Seith Bhalla*
Imaging Techniques in the Study of the Larynx *17*
Laryngeal Obstruction in the Pediatric Age Group *18*
Stenosis (Noncongenital) *19*
Cysts and Laryngoceles *20*
Benign Tumors or Mass Lesions of Larynx *20*
Vocal Cord Paralysis *23*
Trauma *24*

**4. Laryngopharyngeal Reflux** 27
*KK Handa, Aru Chhabra Handa, Ashutosh Hota*
Pathophysiology *27*
Mechanism of Symptoms *28*
Signs and Symptoms *29*
Effects of Reflux in Aerodigestive Tract *30*
Investigations *31*
Diagnosis *34*
Treatment *34*

**5. Spasmodic Dysphonia** 39
*KK Handa*
Etiopathogenesis *39*
Management *40*
Surgery for Spasmodic Dysphonia *41*


JAYPEE BROTHERS

**6. Care of Singing Voice** 45
*Jaya Kumar Menon*
Voice Production *45*
Assessing the Breath Support *46*
Assessment of Singing Voice *47*
Management *47*
Vocal Hygiene *48*

**7. The Aging Voice** 50
*Joseph P Bradley, Michael M Johns*
Geriatric Dysphonia *50*
History and Examination *51*
Rejuvenation of the Aging Voice *51*
Professional Vocalist *52*
Future Directions *52*
Case Studies *53*

**8. Voice Therapeutic Approaches** 56
*Usha Rani*
Symptomatic Voice Therapy *56*
Physiological or Holistic Voice Therapy *59*

**9. Voice and Medicines** 65
*KK Handa*
Steroids in Acute Laryngeal Conditions *65*
Sex Hormones *65*
Drugs Used for Gastroesophageal and Laryngopharyngeal Reflux *65*
Drugs Used for Cough and Thick Mucus *66*
Drugs Used In Allergic Rhinitis *66*
Drugs Acting on Autonomic Nervous System *67*
Psychotropic Agents *67*

**10. Vocal Fold Immobility** 69
*Mausumi N Syamal, Michael S Benninger*
Etiology *69*
Clinical Presentation *70*
Evaluation or Workup *71*
Unilateral Vocal Fold Immobility Management *72*
Bilateral Vocal Fold Immobility Management *75*

**11. Laryngeal Framework Surgery** 80
*KK Handa*
Advantages of the Laryngeal Framework Surgery *80*
Procedures under Local Anesthesia *80*

JAYPEE BROTHERS

**12. Pediatric Voice Disorders** 84
*KK Handa, M Haq*
Pediatric Larynx *84*
Specific Disorders *85*

**13. Office-based Laryngeal Procedures** 91
*KK Handa*
Anesthesia and Patient Selection for Office Procedures *91*
Airway Evaluation *92*
Vocal Cord Injections *94*
Laryngeal Biopsy *95*
Secondary Tracheoesophageal Puncture *95*
Superficial Vocal Cord Injection *96*
Botox Injection *96*
Transnasal Esophagoscopy *96*

**14. Recurrent Respiratory Papillomatosis** 99
*KK Handa, Anup Singh Yadav*
Epidemiology *99*
Etiology *99*
Pathophysiology *100*
Mode of Transmission and Risk Factors of Disease *101*
Presenting Symptomatology *101*
Tracheostomy in Recurrent Respiratory Papillomatosis *102*
Extralaryngeal Spread *102*
Patient Evaluation *102*
Management *103*
Surgical Techniques *105*
Adjuvant Treatment Modalities *106*
Antireflux Therapy in Recurrent Respiratory Papillomatosis *109*
New Frontiers in Recurrent Respiratory Papillomatosis *110*
Recurrent Respiratory Papillomatosis Resources *111*

**15. Lasers in Phonosurgery and Laryngology** 116
*KK Handa*
Laser Safety Protocol *116*
Vocal Cord Cysts and Polyps *117*
Abductor Cord Paralysis *117*
Leukoplakia and Keratosis *117*
Recurrent Respiratory Papillomatosis *117*
Early Laryngeal Cancer *118*
Vocal Cord Polyps *119*
Vascular Lesions *119*
Laryngotracheal Stenosis *119*

JAYPEE BROTHERS

**16. Adult Laryngotracheal Stenosis** 121
*KK Handa, Dhananjay Kumar*
Etiology *121*
Classification of Laryngotracheal Stenosis *122*
Diagnosis *123*
Management *124*
Various Operative Techniques for Laryngotracheal Stenosis *126*

**17. Reconstruction Techniques for the Treatment of Anatomical Upper Respiratory Tract Anomalies in Children** 133
*Ravindhra G Elluru*
Overview *133*
Pediatric versus Adult Upper Airway Anatomy *133*
Laryngomalacia *134*
Vocal Cord Paralysis *134*
Posterior Laryngeal Clefts *137*
Vascular Compression *139*
Tracheomalacia *139*
Complete Tracheal Rings *139*

**18. Pediatric Dysphagia** 142
*J Paul Willging, Aliza P Cohen*
Maturational Changes in Swallowing *142*
Normal Swallowing Physiology *143*
Mechanics of Swallowing *144*
Clinical Presentation *144*
Etiologies *144*
Overall Evaluation *145*
Diagnostic Workup *146*
Management Approaches *149*

**19. Effects of Swallow Therapy in Oropharyngeal Dysphagia** 151
*Divya Chandrasekhar*
Indirect Therapeutic Strategies *151*
Direct Therapeutic Strategies *154*

**20. Laryngeal Management in Sleep Apnea Patients** 160
*Claudio Vicini, Filippo Montevecchi, Mohamed Rashwan, Marco Barbieri, Valeria Roustan, Fabiola Incandela, Giorgio Peretti*
Drug-induced Sedation Endoscopy *160*
Surgical Treatment Options *161*
Postoperative Management *164*

*Index* 165

JAYPEE BROTHERS

CHAPTER

# 15

# Lasers in Phonosurgery and Laryngology

*KK Handa*

JAYPEE BROTHERS

## INTRODUCTION

Laser is another technologically advanced tool in the armamentarium of ENT (ear, nose, and throat) surgeons in general and laryngologists in particular. The types of lasers used in laryngology include carbon dioxide ($CO_2$) laser, Nd:YAG (neodymium: yttrium-aluminum-garnet), diode and KTP (potassium-titanyl-phosphate) laser. $CO_2$ laser is rod delivery laser while the rest are fiber lasers. However, recently, even $CO_2$ laser has come in a fiber mode, e.g. omniguide and waveguide.

Carbon dioxide laser is the best accepted international standard for precise work in the larynx. The laser scores over the cold instrumentation in precision, better healing, hemostasis and less scarring. The $CO_2$ laser induces very little collateral thermal tissue interaction when compared with other wavelengths used in the medical field, e.g. Nd:YAG laser, argon laser, or KTP laser. The $CO_2$ thermal penetration ranges in microns, whereas that of other wavelengths ranges in millimeters.[1] These features make the $CO_2$ laser the surgical workhorse when tissue incision or vaporization with minimum concomitant collateral damage is required.[1] The wavelength of $CO_2$ laser (10.6 μm) lies outside the visible spectrum and therefore an aiming beam of helium neon/diode is required. The latest generation $CO_2$ laser is equipped with the robotic scanner and AcuBlade. The AcuBlade is a scanner software which allows the beam to travel across the target as a straight or curved line. Various lengths 0.5–3.5 mm and various depths 0.2–2.0 mm are programmable.

Before starting a laser program in laryngology with $CO_2$ laser it is important that the surgeon checks the compatibility of the microscope, micromanipulator, and the laser machine (Fig. 1).



**Fig. 1** Use of carbon dioxide Lumenis system with micromanipulator and robotic scanner

Also required are certain specific instruments including jet black laryngoscopes to prevent reflection and having a smoke evacuator (Fig. 2).

## LASER SAFETY PROTOCOL

Before any laser surgery, an exhaustive laser safety protocol needs to be followed and includes:

- Wearing of protective eyewear for the surgeon, personnel around, and the patient
- Avoidance of inflammable gases like nitrous oxide. Air-oxygen mixture is preferred and fraction of inspired oxygen ($FiO_2$) needs to be less than 30



**Fig. 2** Use of Steiner adjustable flange laryngoscope with a smoke evacuator

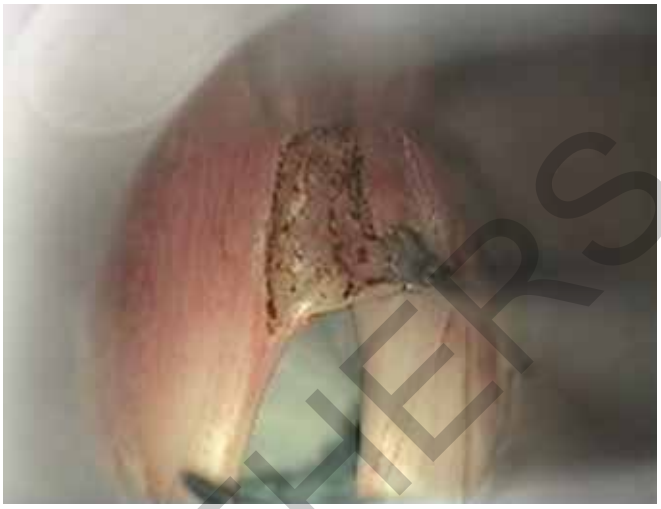

**Fig. 3** Raising of a microflap with carbon dioxide laser

- Any combustible materials like charred tissue, gauze, etc. must be away from the beam
- It is preferable to use laser protective endotracheal tubes.
- Display of warning board outside the operation theater.

## VOCAL CORD CYSTS AND POLYPS

Carbon dioxide laser can be used very successfully for intracordal cysts using the mini microflap technique (Fig. 3). The vocal cord cysts are of two types: mucus retention cyst and the epidermoid cysts. The vocal cord cysts lie very close to the vocal ligament; hence high degree of precision is required in dealing with them. The use should only be in expert hands and a beginner should use phonomicrosurgical techniques. An epithelial cordotomy 1 mm lateral to the cyst is done and the cyst is grasped with Bouchayer forcep and separated medially from the epithelium and laterally from the vocal ligament. In case the cyst ruptures care must be taken to remove the entire epithelium. The epithelium needs to be redraped. $CO_2$ laser gives the right amount of precision required in dealing with a lesion as delicate as an epidermoid cyst. The AcuBlade system has been shown to be a better alternative in this setting.[2]

Carbon dioxide laser is also useful for removing benign lesions like polyps and is especially useful for hemorrhagic or telangiectatic polyps (Fig. 4).

## ABDUCTOR CORD PARALYSIS

Carbon dioxide laser is a very effective tool for the management of bilateral abductor cord paralysis. Posterior transverse laser cordotomy (PTLC) was first described by Dennis and Kashima[3] as a technique for providing an airway at the posterior glottis without preoperative tracheotomy; they



**Fig. 4** Carbon dioxide laser for a laryngeal polyp

reported it as a successful method with satisfactory functional results. The other procedures include posterior cordectomy with or without partial arytenoidectomy, suture lateralization with longitudinal laser cordotomy.

## LEUKOPLAKIA AND KERATOSIS

Carbon dioxide laser is a very effective tool for dealing with leukoplakia and keratotic lesions of the vocal cords (Fig. 5).

## RECURRENT RESPIRATORY PAPILLOMATOSIS

Recurrent respiratory papillomatosis is another suitable condition for microsurgery using $CO_2$ laser. The laser may be

JAYPEE BROTHERS

used alone or along with a soft-tissue shaver (microdebrider). The soft-tissue shaver is used to debulk the papillomas and $CO_2$ laser is used for fine work. The use of $CO_2$ laser is likely to produce very little damage to the vocal cords. This is a very important aspect as these patients need to undergo repeat surgeries because of the biological behavior of the papillomas and once vocal cords are scarred cannot be corrected.

## EARLY LARYNGEAL CANCER

Transoral laser surgery for early laryngeal cancer is an accepted modality today. The benefits are of short treatment duration, lower costs, oncological control similar to radiotherapy and possibility of successive treatments. The argument of better voice results with radiotherapy may not be entirely true today. Endoscopic laser surgery offers overall voice quality equivalent to that of radiotherapy for patients with T1a midcord glottic carcinoma. In lesions beyond T1a, the voice improves with speech therapy or primary or secondary vocal cord reconstruction can be done with autologous fat or other materials.

A retrospective cohort study[4] was conducted of all individuals who received either radiation therapy (RT) or transoral laser microsurgery (TLM) for the treatment of Tis or T1a glottis squamous cell carcinoma (SCC) between 2004 and 2009 at the London Regional Cancer Program.[5] The primary outcome measure was voice-related quality of life (V-RQOL), as assessed by the V-RQOL questionnaire. Secondary outcomes included local control, overall survival, and laryngectomy-free survival. 57 patients were eligible for this study; 34 received RT and 23 received TLM. 40 (70.2%) of the 57 patients completed the V-RQOL. No statistically significant difference in total V-RQOL score was observed between the RT and TLM cohorts (p = 0.228). There was, however, a trend toward higher scores (i.e. less voice disability) in the physical function domain of the V-RQOL for the RT group (90.0%) as compared to the TLM group (80.2%) (p = 0.05). No significant differences were observed in recurrence or overall survival between the two groups. The study concluded that both oncologic outcomes and self-rated V-RQOL are similar in patients treated with RT and TLM for early-glottic carcinoma.

Another study by Peretti et al.[6,7] did a cost analysis, comparison of voice results and the curative results between external beam radiation and laser surgery for early cancer larynx (Figs 6A and B). The study concluded that cure rates are equal; voice results are comparable and the total cost of external radiotherapy significantly higher as compared to the laser surgery for early cancer larynx and the author



**Fig. 5** Keratosis of vocal cords; carbon dioxide laser being used in an ablative mode

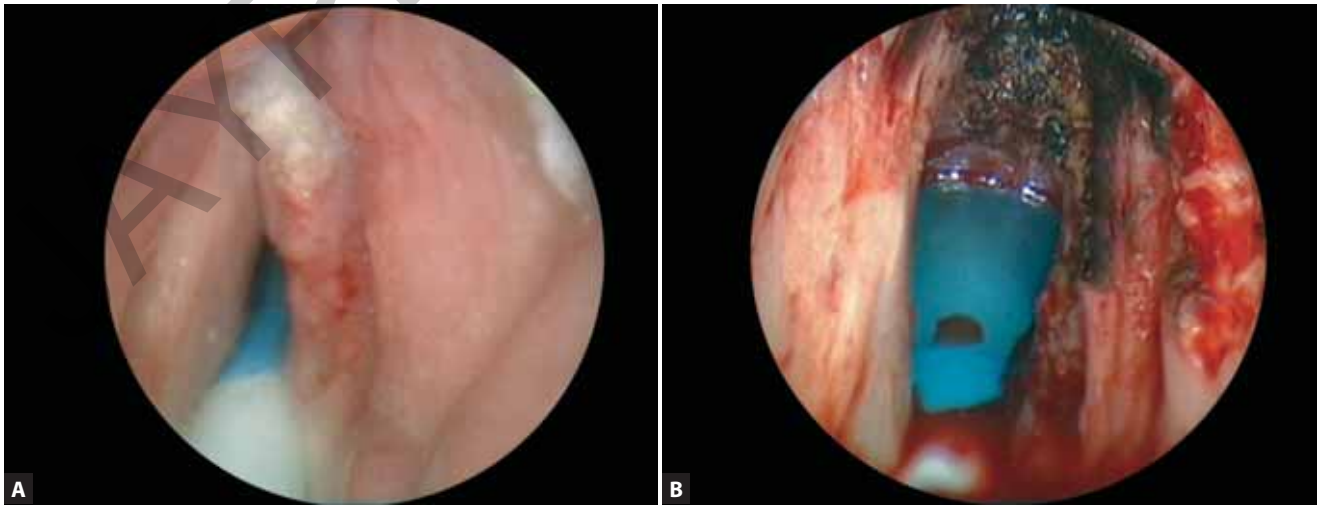


**Figs 6A and B** Laser excision of early cancer larynx confined to one cord: Intraoperative picture

AYPEE BROTHERS

recommended laser surgery over external beam radiotherapy. Peretti et al.[7,8] also confirmed good surgical outcomes for T1, Tis and selected T2 and T3 glottic tumors with laser. They also achieved high rates (65%) of rescue endoscopic retreatment in case of early detected local failure, achieving an ultimate local control with laser alone of 93.4%, 95%, 85.6%, and 71.6% for Tis, T1, T2, and T3, respectively. Another study[8] from the same center concluded that selected recurrences after primary RT for T1 and T2 glottic carcinoma are eligible for endoscopic salvage surgery with oncologic results comparable to those with open neck procedures but with a lower complication rate and a favorable functional outcome.

## VOCAL CORD POLYPS

Carbon dioxide laser has been advocated for the treatment of benign vocal fold lesions since Benninger's 2000 randomized trial[9] demonstrated the absence of difference in outcomes on blinded comparisons of stroboscopy, voice quality or recovery between cold instruments and laser in the treatment of benign superficial vocal fold lesions. With improvement introduction of the AcuBlade system the results are getting better.

Laser is of benefit in vascular polyps where it scores over conventional instruments in terms of hemostasis and precision.

## VASCULAR LESIONS

Vascular lesions, like hemangiomas of larynx, subglottic hemangioma in children, are very suitably dealt with the $CO_2$ laser.

## LARYNGOTRACHEAL STENOSIS

Most commonly used in the airway for laryngotracheal stenosis are $CO_2$, Nd:YAG and the KTP laser. The $CO_2$ laser has been the mainstay in the management of most airway lesions because of surgeon's familiarity and its precise cutting properties. Its main drawback is difficulty with delivery of the beam through the subglottiscope or bronchoscope. The development of microsubglottoscopy with specially designed scopes and more sophisticated micromanipulators has overcome this problem to a large degree. The Nd:YAG laser has the advantage of transmission through flexible fibers and delivery by either contact or noncontact mode. This greatly facilitates its use via the bronchoscope when addressing tracheal stenosis. Nd:YAG laser also offers good hemostatic properties, but its heat diffusion characteristics may cause surrounding thermal damage. KTP is a better hemostat because of it preferential absorption by hemoglobin.[9]

Laser is useful for limited stenosis of larynx and trachea. Stenosis of the supraglottic and glottic larynx may be approached with standard suspension microlaryngoscopy while exposing stenosis of the subglottis or upper trachea may require the rigid bronchoscope or specially designed subglottiscopes.[10] As described by Ossoff et al.,[11] the subglottiscope modification of the Dedo laryngoscope provides access to the subglottis with a port for jet ventilation, while still allowing the use of the microscope and the $CO_2$ laser aiming system. Laser is also useful for managing postoperative granulations and webs in the glottis.

### Laryngomalacia

It is normally a self-limiting condition in children and here $CO_2$ laser can be very effectively used if the condition does not improve.

### Sleep Surgery

With surgery for sleep disorders and snoring gaining more acceptance lasers are being commonly used for palate procedures, such as LAUP (laser-assisted uvulopalatoplasty), uvulopalatal flap, tonsillectomies and for base of tongue reduction.

### Office-based Laser Surgery

Kaufmann et al.[12] have described good results with unsedated office-based laser surgery (UOLS) of the larynx and trachea for laryngotracheal pathology including recurrent respiratory papillomas, granulomas, leukoplakia, and polypoid degeneration. UOLS delivered by flexible endoscopes has dramatically impacted office-based surgery by reducing the time, costs, and morbidity of surgery. Of the 443 cases, 406 were performed with the pulsed-dye laser, 10 with the $CO_2$ laser, and 27 with the thulium: yttrium-aluminum-garnet laser. There were no significant complications in this series. Use of office-based laser procedure is gaining popularity, especially in USA because of avoidance of general anesthesia, shorter duration, and cost advantage.

### Laser Use with Robotic Systems

Now with the popularization of transoral robotic surgery lasers using Da Vinci robots laser systems, which are compatible with the robotic arms, are being developed as laser cutting is more precise and heals with less scarring than commonly used diathermy-based cutting or coagulation instruments. Thulium and $CO_2$ fibers have been used in some centers with good success.[13]

JAYPEE BROTHERS

## CONCLUSION

Laser is a useful tool which scores over conventional instrumentation in terms of better precision, better hemostasis, and less surrounding tissue damage resulting in less postoperative scarring. However, a proper case selection, proper laser safety precautions, and surgeons and personnel properly trained are a prelude to running a proper laser program.

## REFERENCES


1. Remacle M, Hassan F, Cohen D, et al. New computer-guided scanner for improving $CO_2$ laser-assisted microincision. Eur Arch Otorhinolaryngol Head Neck. 2005;262(2):113-9.
2. Matar N, Amoussa K, Verduyckt I, et al. $CO_2$ laser-assisted microsurgery for intracordal cysts: technique and results of 49 patients. Eur Arch Otorhinolaryngol. 2010;267(12):1905-9.
3. Dursun G, Gökcan MK. Aerodynamic, acoustic and functional results of posterior transverse laser cordotomy for bilateral abductor vocal fold paralysis. J Laryngol Otol. 2006;120(4):282-8.
4. Sjögren EV, van Rossum MA, Langeveld TP, et al. Voice outcome in T1a midcord glottic carcinoma: laser surgery vs radiotherapy. Arch Otolaryngol Head Neck Surg. 2008;134(9):965-72.
5. Osborn HA, Hu A, Venkatesan V, et al. Comparison of endoscopic laser resection versus radiation therapy for the treatment of early glottic carcinoma. J Otolaryngol Head Neck Surg. 2011;40(3):200-4.
6. Brandenburg JH. Laser cordotomy versus radiotherapy: an objective cost analysis. Ann Otol Rhinol Laryngol. 2001;110(4);312-8.
7. Peretti G, Piazza C, Cocco D, et al. Transoral $CO_2$ laser treatment for T(is)-T(3) glottic cancer: the University of Brescia experience on 595 patients. Head Neck. 2010;32(8):977-83.
8. Puxeddu R, Piazza C, Mensi MC, et al. Carbon dioxide laser salvage surgery after radiotherapy failure in T1 and T2 glottic carcinoma. Otolaryngol Head Neck Surg. 2004;130(1):84-8.
9. Benninger MS. Microdissection or microspot $CO_2$ laser for limited vocal fold benign lesions: a prospective randomized trial. Laryngoscope. 2000;110(2 Pt 2 Suppl 92):1-17.
10. Bhattacharya N, Fried MP. Operative techniques in otolaryngology. Head Neck Surg. 1999;10(4):290-3.
11. Ossoff RH, Duncavage JA, Dere H. Microsubglottoscopy: An expansion of operative microlaryngoscopy. Otolaryngol Head Neck Surg. 1991;104:842-8.
12. Koufman JA, Rees CJ, Frazier WD, et al. Office-based laryngeal laser surgery: a review of 443 cases using three wavelengths. Otolaryngol Head Neck Surg. 2007;137(1):146-51.
13. Handa KK. Lasers in laryngology: Current status. Int J Phonosurg Laryngol. 2011. pp. 6-8.


JAYPEE BROTHERS

for detailed information on otolaryngology books, visit our website **www.jaypeebrothers.com,** for detailed information on otolaryngology books, visit our website **www.jaypeebrothers.**

# Textbook of Voice & Laryngology

Field of voice and laryngology has evolved a lot since the first visualization of his own vocal cord by Manuel Garcia, the Spanish singing teacher, in the year 1894. This textbook is an attempt to provide the information on different aspects of laryngology—from basic information on applied anatomy, imaging, and voice evaluation to topics such as laryngopharyngeal reflux, spasmodic dysphonia, care of singing voice, aging voice, voice therapy, swallow therapy, pediatric voice disorders, recurrent laryngeal papillomatosis, pediatric and adult laryngotracheal stenosis to advances in the field, like office-based surgery, laryngeal framework surgery, lasers in laryngology, and laryngeal obstructive sleep apnea. This book is based on the author's vast clinical experience supported by the chapters provided by experts, including the international ones.



**KK Handa** is the Director and Head of the Department of ENT and Head Neck Surgery at Medanta—The Medicity, Gurugram, Haryana, India, since 2009. He is an eminent laryngologist and voice surgeon. He has set up the department of ENT and Head Neck Surgery at Medanta—The Medicity with a state-of-the-art laryngology unit, including diagnostic and operative facility. Prior to that, he worked as a faculty (Assistant Professor, from 1996 to 2003; and Associate Professor, from 2003 to 2009) at the All India Institute of Medical Sciences (AIIMS), New Delhi, India. He did 1-year fellowship in lasers in laryngology from the Glasgow Royal Infirmary, United Kingdom, in the year 2004.

He graduated from the Armed Forces Medical College, Pune, Maharashtra, India, and did his residency and senior residency from PGIMER, Chandigarh, India.

He was the Founder Secretary of the Association of Phono Surgeons of India, from 2003 to 2006; Vice President, from 2006 to 2009; and President of the Association of Phono Surgeons of India, from 2009 to 2012. He is also the Organizing Chairman of the World Phonocon–2017 (Joint meeting of the International Association of Phonosurgery and the Indian Association of Phonosurgeons).

He has been an invited faculty and speaker for many international and national meetings and workshops on phonosurgery and laryngology, and has conducted several such workshops himself.

**Available at all medical bookstores**
**or buy online at www.jaypeebrothers.com**

JAYPEE BROTHERS
Medical Publishers (P) Ltd.
www.jaypeebrothers.com
Join us on facebook.com/JaypeeMedicalPublishers

Shelving Recommendation
**OTOLARYNGOLOGY**

ISBN 978-93-86322-92-0
9 789386 322920