Principles of Respiratory Medicine

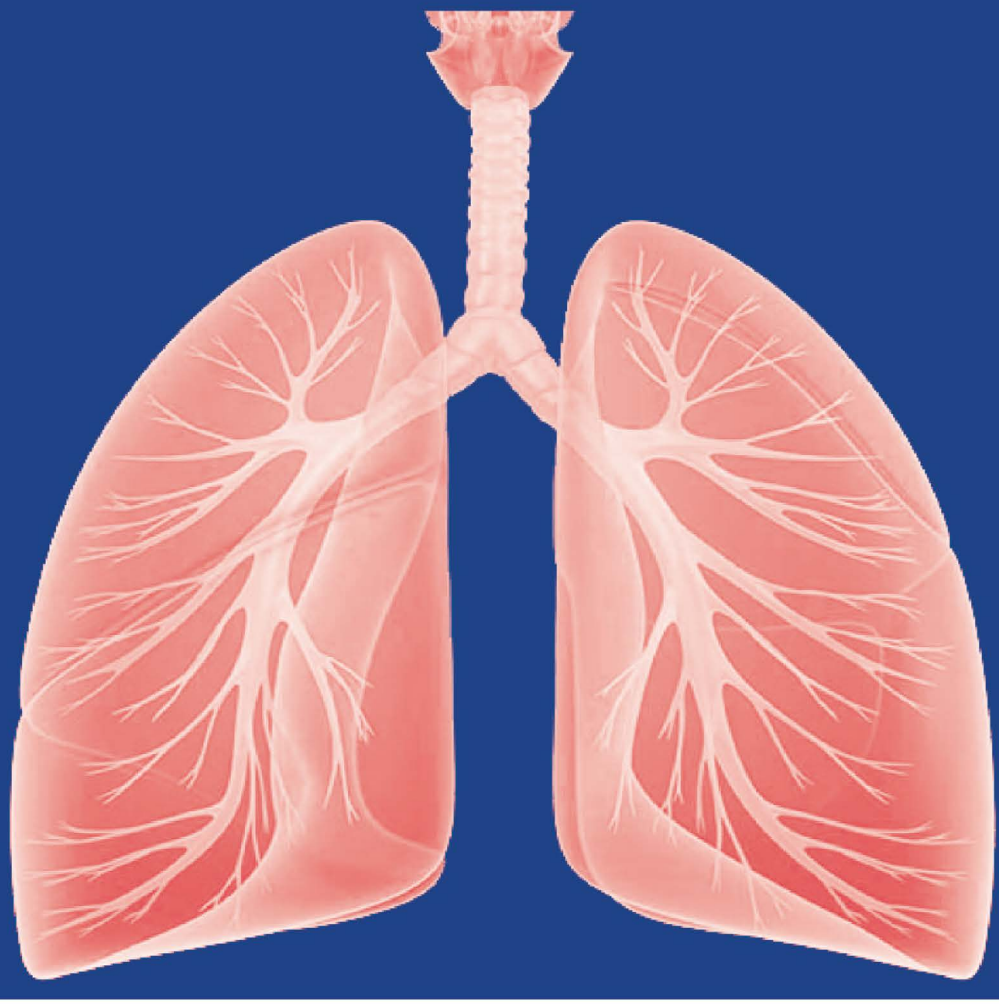

Farokh Erach Udwadia
Zarir F Udwadia
Anirudh F Kohli
Khyati Shah

2nd Edition

JAYPEE

Contents

1. Introduction to Nursing 1

- Nursing Concept 1
- Nursing: Definition 2
- Scope of Nursing 3
- Nature of Nursing 3
- Functions of Nurse 4
- History of Nursing 5
- The Emergence of Professional Nursing 9
- Ethics in Nursing, Roles and Responsibilities of a Nurse 13
- **Types of Healthcare Agencies/Services 18**
- Types of Healthcare Agencies 18
- Major Hospital Health Services Departments 19
- Nursing Unit 22
- Rehabilitation Center 22
- Healthcare Teams 23
- Modern Approaches to Nursing Care 23
- Health and Disease 23
- Definition of Health 23
- Determinants of Health 24
- Dimensions of Health 25
- Maslow's Hierarchy of Needs 25
- Health Illness Continuum 26
- Factors Influencing Health 26
- Causes and Risk Factors for Developing Illness 27
- Effect of Hospitalization 28

2. Nursing Care of the Patient 29

- Emotional Needs of Patients 33
- Common Emotional Responses to Illness and Nursing Implications 34
- **Admission, Transfer, and Discharge Procedures 35**
- Hospital Admission and Discharge 35
- Room Preparation 36
- Admission of Patient to an Emergency Department 37
- Internal Transfer of Patients 39
- Discharge from the Hospital 39
- **Basic Nursing Skills 40**
- Communication 40
- Factors Influencing the Communication Process 44
- Nurse-Patient Relationship 50
- Recording and Reporting 51
- Types of Client Records 52
- Methods/Systems of Documentation/Recording 54
- Reporting 55
- Nursing Process 56
- Historical Prospective of Nursing 56
- Steps in the Nursing Process 57
- Benefits of the Nursing Process 57
- A Framework for Accountability 57
- Process of Assessment 57
- Nursing Diagnosis 59
- Planning 61

3. Meeting the Basic Needs of a Patient 70

- Comfort, Rest, and Sleep 71
- Body Mechanics 73
- Range of Motions 73
- Beds and Bed Making 81
- Elimination Needs 95
- Nutritional Needs 109
- Psychological and Spiritual Needs 120
- Care of Terminally ill and Dying Patient 120

4. Assessment of Patient/Client 125

- Health Assessment 125
- Physical Examination and Assessment 126
- Specific Areas of Examination 129
- Physiological Assessment 137
- Pulse 143
- Respiration 145
- Blood Pressure 148
- Collection of Specimen 151
- Venipuncture (Venous Blood) 152
- Specimen Collection 159
- Cervical Scrape 159
- Ear Swab 159
- Eye Swab 160
- Collecting a Stool Specimen 160
- Nasal Swab 162
- Penile Swab 162
- Rectal Swab 163
- Semen 163
- Throat Swab 164
- Urine 164
- Vaginal Swab 165
- Wound Swab 165
- Psychological Assessment 166

5. Infection Control 170

- Nature of Infection 170
- Hospital Acquired Infection (Nosocomial Infection) 173
- Introductory Concept of Asepsis, Medical, and Surgical Asepsis 175
- Medical Asepsis 178
- Surgical Asepsis (Sterile Technique) 180
- Aims of Standard Precautions Against Hospital-Acquired Infection 181
- Biomedical Waste Management 182

6. Therapeutic Nursing Care 183

- Patients with Upper Respiratory Airway Infection 183
- Patients with Pulmonary Diseases 185
- Care of Patient with Altered Body Temperature 189
- Care of Patient with Fluid and Electrolytes Imbalance 190
- Care of Unconscious Patient 193
- Care of the Patient in Traction 197
- Care of Patient with Pain 199
- Planning 201
- Care of Patients with Body Elimination Deviation 202

7. Introduction to Clinical Pharmacology 208

- **Administration of Medication: General Principles, Considerations, Purpose of Medication 209**
- General Principles 209
- Purpose of Medication 209
- Drug Nomenclature 209
- Drugs Forms 211
- Routes of Administration of Medication 211
- Parenteral Administration 213
- System of Drug Measurement 221
- Topical Administration, Types, Purpose, Site, Equipment, Procedure 223
- Ear Irrigation and Instillation of Ear Drops 226
- Application of Drugs in Other Forms (Tropical Drugs) 227
- Inhalation 227
- Meaning of Parenteral Route of Epidural, Intrathecal, Intraosseous, Intraperitoneal, Intrapleural, Intra-arterial 232
- Important Dates in Nursing 232
- World Nursing Organization History 233
- World History of Nursing Journal 234

8. First Aid 236

- Definition of First Aid 237
- Aims of First Aid 237
- General Principles of First Aid 237
- Concept of Emergency 239
- **Procedures and Techniques in First Aid 239**
- Preparation of First Aid Kit 239
- Dressing, Bandaging and Splinting 239
- Cardiopulmonary Resuscitation: External Cardiac Massage 248
- **First Aid In Emergency 256**
- Hemorrhage 256
- Shock 256
- Drowning 259
- Injuries to the Bones, Joints, and Muscles 260
- First Aid for Accident 264
- First Aid for Burns and Scalds 265
- First Aid for Poisoning 267
- First Aid for Food Poisoning and Poisonous Plants 269
- First Aid for Bleeding 270
- First Aid for an Insect Bite 272
- **Community Emergencies 274**
- Community Emergencies and Community Resources 274
- Types of Disaster 275

Index 279

UNIT 4

Assessment of Patient/Client

LEARNING OBJECTIVES

After completing this unit, learner will be able to:

- Discuss physical assessment
  - Importance, principles, and methods of assessment
  - Height, weight, and posture
  - Head to toe examination
- Explain physiological assessment
  - Vital signs, normal-abnormal characteristics, and factors influencing the variations
  - Observation and collection of specimen: urine, stool, vomitus, and sputum
- Describe psychological assessment

HEALTH ASSESSMENT

Interview Technique

Collecting patient data is a core step in the nursing process. Often referred to as a nursing health assessment interview, nurses must systematically collect patient information so patients can receive the care they need. Health assessment in nursing is so much more than asking questions, it is the gateway to building an effective nurse-patient relationship that will make patient feel at ease, supported, and empowered.

Essential elements of a nursing health assessment is expressing to the patient that you are committed or dedicated to his or her wellness.

The respect model, which is widely used to promote nurse's awareness of their own cultural bases and develop their rapport with patient from different cultural backgrounds.

Elements of interview technique:

- Establish rapport
- Respect patient privacy
- Empathy
- Support
- Partnership
- Explanations
- Cultural competence
- Do not use medical terminology

Communication skills are the fundamental link between the nurse and the patient. Although, communication with patients may seem like a simple task, it actually takes practice and knowledge.

Observation Techniques

Observation is the process of watching someone or something. Often, observation is an informal action, but it can also be formal and involve data collection. An observation can also be the collected information itself.

Observation techniques involve observing actual behaviors, which are subsequently scored. There are many types of observations, covert and overt observation and participant and nonparticipant, which all have their strengths and weaknesses.

Observational learning is a major component of Bandura's social learning theory. He also emphasized that four conditions were necessary for any form of observing and modeling behavior, attention, retention, reproduction, and motivation.

Observation is way of gathering data by watching behavior, events, or nothing but physical characteristics in their natural setting. Observations can be overt (everyone knows they are being observed) or covert (no one knows they are being observed and observer is concealed).

Importance of Observation Technique

Observation provides the most accurate information about people, their tasks, and their needs. Since healthcare providers need to know their client's behavior, observing is

JAYPEE BROTHERS

the most important because it provides the most accurate information about client's problems and needs.

Observations, often perceived as a basic routine, are a vital part of the information gained to ensure safer patient care and early recognition, of clinically deteriorating condition.

Importance of Health Assessment

- To obtain base line data about the client's functional activities.
- To supplement, confirm, or refuse data obtained in the nursing history.
- To identify disease in its early stage.
- Determine the cause and extent of the disease
- To obtain data that determines the nature of the treatment or nursing care needed for the patient.
- To find out whether the person is medically fit or not for a particular task.
- To screen for the presence of disease.

Process of Health Assessment

There are several types of nursing assessment; each one is conducted at different times and for different purposes.

- **Initial assessment:** This is aimed at providing a complete database for identifying problems and planning care. It also provides the baseline data for comparison when evaluating the effectiveness of care. It is, therefore, performed as close to the time of admission as possible. It includes taking a comprehensive nursing history and performing a physical examination.
- **Focused assessment:** This is aimed at providing data about a specific problem. It may be carried out at the time of the initial assessment, once a problem is identified or as part of the ongoing assessment after problems are confirmed.
- **Time lapse assessment:** This provides current data to compare with the baseline data collected previously. It is undertaken sometime after the initial assessment.
- **Emergency assessment:** This is used to identify life-threatening problems that may occur whenever a physiological or psychological crisis presents itself. These assessments are carried out as and when needed.

Basic Skills for Assessment

The basic skills needed for assessment are:

- Good communication skills.
- **Accurate observation skills:** These enable the nurse to secure objective and subjective data needed to identify nursing problems and to plan, provide, and evaluate care. They have been the focus for learning fundamentals of nursing.
- Examination skills are also needed to obtain objective physical data and these skills will be the focus of this unit.

PHYSICAL EXAMINATION AND ASSESSMENT

Physical examination or physical assessment is an integral part of the nursing assessment. It is performed following the health history. A complete health assessment is generally conducted from the head to the toe; however, the procedure can vary in many ways according to the age of the client/individual, severity of the illness, the preference of the nurse and the agency's priorities and procedures regardless of what procedure is used, and the patient's energy and time need to be considered. The health assessment is, therefore, conducted in a systematic and efficient manner that requires the fewest position change for the patient.

Definition

Physical examination or physical assessment is a thorough investigation of the entire body or some parts of the body to determine the general physical or mental condition of the body (client).

Techniques of Physical Examination

The nurse depends on his/her own senses and uses them in five examination techniques that enable her to collect a broad range of physical data about the patients. These are:

1. **Inspection (using sight)**
2. **Palpation (using touch)**
3. **Percussion (using hearing and touch)**
4. **Auscultation (using hearing)**
5. **Olfaction (using smell).**

Inspection

Inspection is a visual examination, i.e., assessing using the sense of sight. The nurse inspects with the naked eye and with a lighted instrument such as an otoscope (used to view the ear). Nurses frequently use this technique to assess color, rashes, scars, body shape, facial expressions that may reflect emotions, and body structures, e.g., the inner eye. Inspection is an active process, not a passive one. The nurse must know what to look for and where. Inspection should be systematic, so that nothing is missed. Lighting must be sufficient; either natural or artificial light can be used.

Palpation

Palpation is the examination of the body using the sense of touch. The pads of the fingers are used because their concentration of nerve endings makes them highly sensitive to tactile discrimination.

- Texture, e.g., of the hair
- Temperature, e.g., of a skin area
- Vibration, e.g., of a joint
- Position, size, consistency, and mobility of organs or masses
- Distention, e.g., of urinary bladder
- Presence and rate of peripheral pulses
- Tenderness or pain.

There are two types of palpation: (1) Light and (2) Deep. Light (superficial) palpation should always precede deep palpation, because heavy pressure on the fingertips can dull the sense of touch. Deep palpation is a technique used more

JAYPEE BROTHERS

commonly by nurse practitioners and clinical specialists than by nurses in general practice.

The effectiveness of palpation depends largely on the patient's relaxation. Nurses can assist a patient to relax by:

- Gowning and/or draping the patient appropriately.
- Positioning the patient comfortably.
- Ensuring that their own hands are warm before beginning, e.g., running them under warm water, if they are cold.
- Commencing palpation with areas that are not painful.
- During palpation, the nurse should be sensitive to the patient's verbal and facial expressions indicating discomfort.

Percussion

Percussion is an assessment method in which the body surface is struck to elicit sounds that can be heard or vibrations that can be felt.

Purposes

Percussion is used to determine the size and shape of internal organs by establishing their borders. It indicates whether tissue is fluid-filled, air-filled, or solid. Percussion elicits five types of sound; flatness, dullness, resonance, hyper resonance, and tympany.

- Flatness is an extremely dull sound produced by very dense tissue, such as muscle or bone.
- Dullness is a thud-like sound produced by those tissues, such as the liver, spleen, or heart.
- Resonance is a hollow sound such as those produced by lungs filled with air.
- Hyper resonance is not produced in the normal body. It is described as booming and can be heard over an emphysematous (pathological distention of lung tissues by air) lung.
- Tympany is a musical or drum-like sound produced from an air-filled abdomen.

Types of percussion

There are two types of percussion: (1) Direct percussion and (2) Indirect percussion. In direct percussion, the nurse strikes the areas to be percussed directly with the pads of two, three, or four fingers or with the pad of the middle finger. The strikes are rapid and the movement is from the wrist. This technique is not generally used to percuss the thorax but is useful in percussion an adult's sinuses.

The second type, indirect percussion, is the striking of an object (e.g., a finger) held against the body area to be examined. This technique is generally used to percuss the thorax.

Auscultation

Auscultation is the process of listening to sounds produced within the body. Auscultation may be direct or indirect.

- Direct auscultation is done by the use of the unaided ear, e.g., to listen to a respiration wheeze or the grating of a moving joint.
- Indirect auscultation is done by the use of stethoscope, which amplifies the sounds and conveys them to the nurse's ear. A stethoscope is used primarily to listen to sounds from within the body, e.g., heart, lungs, and bowel sounds.

Olfaction

Olfaction is the sense of smell. Certain alterations in the body function create characteristic body odors. The sense of smell can detect abnormalities that go unrecognized by any other means (**Table 4.1**).

Table 4.1: Example of odors.

Odor	*Site or source*	*Potential causes*
Alcohol	Oral cavity	Ingestion of alcohol
Ammonia	Urine	Urinary tract infection
Halitosis	Oral cavity	Poor dental and oral hygiene, gum disease
Sweet fruity, ketones	Oral cavity	Diabetes ketoacidosis

Preparation for examination patient and unit

Before beginning a physical assessment, the nurse should make necessary arrangements to properly prepare the examination room, equipment, and patient. Poor preparation may result in a haphazard examination that yields incomplete or inaccurate assessment findings.

Preparing the environment: To promote the patient's comfort and ensure an efficient examination, the examination room should have the following features:

- Privacy of the patient
- Curtains or dividers to enclose the patient's bed
- A warm comfortable temperature
- Proper examination clothing for the patient
- Adequate lighting
- Control of outside noises
- Precautions to prevent interruptions by visitors or other healthcare personnel
- A bed or table set at examiner's waist level.

Preparing the equipment: The nurse uses a variety of equipment throughout the assessment process. To facilitate the examination, the equipment should be readily accessible, in proper working order, and warmed. The following is a list of equipment and supplies for general physical examination. There may be a need for specific instruments in a special examination.

Equipment and supplies needed for performing a physical examination (**Table 4.2**).

Preparing the patient: To ensure an accurate assessment and physical examination, the patient must be properly prepared physically and psychologically. A tense, anxious patient will not go through any of the physical maneuvers required during examination or cooperate with the nurse's instructions. To prepare the patient properly, the nurse will:

JAYPEE BROTHERS

Table 4.2: List of equipment and supplies for general physical examination.

Equipment	*Functions*
Incontinent sheet	Protects bed linen from getting soiled
Drapes	Ensures privacy for the client
Forms	Documents pertinent information
Gloves	Prevents cross-infection
Gown for patient	For easy access of different body parts of the client
Paper towel	Dry hands and arms, and to wipe equipment
Percussion hammer	Test various reflexes of the body
Height-weight scale	Measures body weight and height of the client
Specimen containers	Collect specific sample for laboratory evaluation
Sphygmomanometer and cuff	Measures blood pressure
Stethoscope	Auscultate different body sound, e.g., heart sound
Measuring tape	Measures body parts, e.g., abdominal girth
Thermometer	Measures body temperature
Tongue depressor	Facilitates visualizing pharynx or to test gag reflex
Wristwatch with second hand	Records time of examination and used when checking vital signs
Cotton applicators	Examine superficial sensations of the skin including corneal reflex
Eye chart (e.g., Snellen's chart)	Test visual acuity
Flashlight	Facilitates visualization of ear, nose and throat and to check pupil reaction
Lubricant	Lubricant instrument is used in rectal and vaginal examination
Ophthalmoscope	Examines fundus of the eye
Otoscope	Examines outer ear and the tympanic membrane
Sterile safety pin	Examines deep sensation of the skin
Tuning fork	Test hearing acuity
Vaginal speculum	Facilitates vaginal examination
Proctoscope	Facilitates rectal examination

- Provide for patient's physical comfort by allowing the opportunity to empty the bowel or bladder (a good time to collect the needed specimens).
- Provide privacy while the patient changes into a gown and gives the patient time to undress, assisting, if necessary.
- Drape body parts that need not be exposed.
- Help the patient assume proper positions during examination so that body parts are accessible and the patient stays comfortable. The nurse adjusts drapes accordingly.
- Thoroughly explain what will be done, what the patient should expect to feel, and how the patient can cooperate.
- Use simple terms when describing steps of the examination.
- Encourage the patient to ask questions and mention discomfort felt during the examination.
- Have a witness or third person present in the examination room during examination of genitalia when patient and nurse are of opposite genders. The witness is a third person to the examiner's proper conduct.
- Pace or time of the examination process according to the patient's physical and emotional tolerance.

It is difficult to examine patients on beds or stretchers. Special examination tables make patients easily accessible and help them assume special positions. The tables are high and narrow, so the nurse must carefully assist patients so that they do not fall while getting on and off the tables. Confused or noncooperative patients should not be left on an examination table without supervision. A patient can be made comfortable by raising the head of the table to a position of 30 degree and by offering a small pillow.

General survey

The general survey is a study of the whole person, covering the general health state, and any obvious physical characteristics. It is an introduction to the physical examination that will follow. It should give an overall impression of the person. Objective parameters are used in the general survey, but these apply to the whole person, not just to one body system.

Start a general survey at the moment you first encounter the person. Does the person respond promptly when his or her name is used? Does he or she walk easily to meet you? Or does the person look sick, rising slowly, or with effort, with shoulders slumped? Is the hospitalized person conversing with visitors, involved in reading or television, or lying perfectly? Even as you introduce yourself and shake hands, you collect data. Does the person fully extend the arm, shake your hand firmly, make eye contact or smile? Are the palms dry or wet and clammy? As you proceed through the health history, the measurements, and the vital signs, note the following points that will add up to the general survey. Consider these four areas:

1. **Physical appearance:**
   - **Age**—Is the appearance congruent with stated age?
   - **Sex**—Is development appropriate for age?
   - **Level of consciousness**—Is he/she alert, oriented responding appropriately to questions?
   - **Skin color**—What is the color tone, is there any pigmentation or lesions?
   - **Facial features**—Is there symmetry with movement?

JAYPEE BROTHERS

2. **Body structure:**
   - **Stature**—Is height within normal limits for age?
   - **Nutrition**—Does weight appear to be within normal range?
   - **Symmetry**—Do the body parts look equal bilaterally and in proportion?
   - **Posture**—How does the person stand?
   - **Position**—Are there any signs of discomfort, is the person relaxed?
   - **Build and contor**—Do proportions appear normal, are there any deformities?
3. **Behavior:**
   - **Facial expression**—Is there eye contact, what expressions are evident?
   - **Mood and affect**—Is the person comfortable, cooperative?
   - **Speech**—Is speech clear and understandable?
   - **Dress**—Is it appropriate according to the climate and culture, clean, well fitting?
   - **Personal hygiene**—Is the person clean and well groomed?

   All data should be judged against expected normal findings and any deviation from normal should be noted. The **Table 4.3** gives examples of some of the general survey observations and their comparison to normal findings.
4. **Vital signs:**

   Establishing baseline data for the patient's temperature, pulse, respiration and blood pressure, are part of the general physical survey.

Detailed Physical Examination

This is often referred to as a "head-to-toe" examination but may be carried out system-by-system. Whichever way it is approached it should be systematic, comprehensive, and appropriate to the nurse's competence. A detailed physical examination will require the nurse to use all the skills already covered to collect objective physical data, which is then weighed against his/her knowledge base. Abnormalities are detected and from them health problems are identified.

Students in this course will be required to complete physical examinations with an emphasis or inspection and observation of the client's health indicators. This will include examination of:

- **Sensory perception:** Sight, hearing, taste, smell, and touch
- Skin and other body surfaces and features such as mucous membranes, hair, nails
- Respiration
- Circulation
- Nutrition
- Elimination
- Neurological responses
- Immune system responses
- Sexual health

SPECIFIC AREAS OF EXAMINATION

Frequently, nurses assess a specific body area instead of the entire body. These specific assessments are made in relation to patient's complaints, the nurse's own observation

Table 4.3: General survey observations.

Assessment	*Normal findings*	*Deviation from normal*
Observe body build, height and weight	Varies with lifestyle	Excessively thin or obese
Listen to relevance and organization of thoughts	Logical sequence. Makes sense or has sense of reality	Illogical sequence. Flight of ideas, confusion
Observe the client's posture and gait	Relaxed, erect posture, coordinated movement	Tense, bent posture, uncoordinated movement, tremors
Observe the client's overall hygiene and grooming	Clean, neat	Dirty, unkempt
Note body and breath odor in relation to activity level	No body odor or minor body of odor related to work	Foul body odor, ammonia odor, acetone breath odor, foul breath
Observe for signs of distress in posture	Relaxed, erect posture	Tense, slouched, bent posture
Note obvious signs of health or illness	Healthy appearance	Pallor, weakness, obvious illness
Mental status		
Assess the client's attitude	Cooperative	Negative, hostile, withdrawn
Note the client's mood	Relaxed and happy	Tensed and sad
Assess orientation to self, place, and time	Oriented	Disoriented
Listen to relevance and organization of thoughts	Logical sequence. Makes sense has sense of reality	Illogical sequence. Flight of ideas, confusion

JAYPEE BROTHERS

Table 4.4: Examples of specific situations and assessments.

Situation	*Physical assessment*
Patient complains of abdominal pain	Inspect, palpate, and auscultate the abdomen; assess vital signs
The nurse administers a cardio tonic drug to a patient	Assess apical pulse and compare with baseline data
The nurse administers postural drainage	Auscultate lungs before and after the procedure
The patient has just had a cast applied to the lower leg	Assess peripheral perfusion of toes, capillary blanch test, pedal pulse if able and vital signs
The patient's fluid intake is minimal	Assess tissue turgor, fluid intake and output, and vital signs

of problems, the patient's presenting of problems, nursing intervention provided, and medical therapies.

Table 4.4 shows some examples of these situations and assessments.

Assessment

1. Note if the client has had any acute distress: Difficulty in breathing, pain, anxiety, if such signs are present.
   Rationale: Signs establish priorities regarding what part of the examination has to be conducted first.

Critical Decision Point

Findings may change the direction of the examination. Any client in acute distress will require an immediate assessment of the body system(s) affected.

2. Review graphic sheet for temperature, pulse, respirations, and blood pressure and consider factors or conditions that may alter reading of vital signs.
   Rationale: Provides baseline and historical data regarding client's signs.
3. Reconfirm (after reviewing history) the primary reason why the client has sought health care or take the health history, if not already completed.
   Rationale: Keeps assessment focused on client to ensure that client's expectations are addressed.
4. Identify client's normal height and weight. If a sudden gain or loss in weight has occurred, determine the amount of weight change and period of time in which it has occurred.
5. Assess if client has recently been dieting or following exercise program.
   Rationale: Generally, weight of 15–20% above standard indicates excess body fat; however, fluid retention is one factor that must be ruled out. A person's weight can fluctuate, cause of fluid loss or retention.
6. Review client's past fluid intake and output (I and O) records.
   Rationale: Fluid and electrolyte balance maintains health and functions of all body systems. Intake includes all liquids taken orally by feeding tube, and parenteral. Liquid output includes urine, diarrhea stool, fistulas, vomitus, drainage from gastric suction, and drainage from postsurgical tubes, such chest tubes or drains.
7. Identify client's general perceptions about personal health.
   Rationale: Assessment of client's general appearance coupled with client's own perceptions may reveal specific problems.

Implementation

1. **Prepare the client:** Tell the client that you will be doing a routine process to check for areas of concern. Ask client to tell you, if any area you examine hurts when touched.
   Rationale: Behaviors may reflect specific physical or psychological abnormalities. Dementia and level of consciousness influences ability to cooperate. Timing of recent medications, especially pain medication and sedatives, may alter assessment data.
   a. If a client's responses are inappropriate, ask short, answer to-the-point questions regarding the information the client should know, e.g., "Tell me your name". "What is the name of this place?" "Tell me, where you live?" "What day is this?" "What month is this?" or "What season of the year is this?"
      Rationale: Measure client's orientation to person, place, and time. This may be noted in documentation as "Oriented × 3". If disoriented in any way, include subjective or objective data rather than just documenting disorientation.
   b. If client is unable to respond to questions or orientation, offer simple commands, e.g., "squeeze my fingers" or "move your toes".
      Rationale: Levels of consciousness exist along the continuous including full responsiveness, inability to consciously initiate meaningful behaviors, and unresponsiveness to stimuli.
2. **Observe the appearance of the client**: Gender, race, and age. Note the client's physical features.
   Rationale: Gender influences the type of examination performed and manner in which assessments are made. Different physical characteristics and predisposition to illnesses are related to gender and race.
3. **Assess posture, movement, and position**, noting alignment of shoulders and hips while client stands and sits. Observe whether the client has a slumped, erect, or bent posture.
   Rationale: May reveal musculoskeletal problem, mood, or presence of pain.
   a. Body movements: Are they purposeful? Are there tremors of the extremities? Are any body parts immobile?

JAYPEE BROTHERS

b. Note if movements are coordinated or uncoordinated.
Rationale: May indicate neurological or muscular problem or emotional stress.

Psychological Preparation

Clients are easily embarrassed when forced to answer sensitive questions about bodily functions or when body parts are exposed and examined. The possibility that the examiner will find something abnormal also creates anxiety. The nurse should convey an open, receptive professional approach; nurse should first explain the examination in general terms. For example, nurse can tell the client—I am going to do a complete physical examination so that I can have a good idea of whether you have any health problems as we go along.

Mental Status and Speech

The assessment regarding mental status and speech can begin during the client's health history. An observation can be made regarding grooming, dress, and hygiene, you may ask yourself—is the person clean and well kept? Is the person's hair, skin, and nails clean and well groomed? Is the clothing appropriate for the present weather condition?

Nutritional Status

The person's nutritional status can reflect the level of general health.

Judgment

A person's judgment can be affected by the level of intelligence, education level, socioeconomic level, and cultural orientation.

Orientation

An assessment is made of a person's orientation to time, place, and person.

Memory

When assessing memory, you need to test the person's immediate, recent, and remote memories. Immediate memory is tested by asking, telephone number, or digits such as code number. Recent memory is tested by asking about events of the day, like breakfast, weather condition of the day. Remote memory is tested by asking about past events, like birthdays, anniversaries.

Affect

Affect is on emotional state such as fear, anger, depression, elation, and frustration.

Consciousness

Assess consciousness with noting whether the client is awake and alert. Note whether the person is able to answer your questions.

Speech

Need to note the characteristics of the person's speech, speech is assessed for quantity (talkative or silent) rate (fast or slow), loudness.

Integumentary System (Skin)

Assessment of the skin reveals a variety of conditions including changes in oxygenation, circulation, nutrition, local tissue damage, and hydration (**Fig. 4.1**).

Cyanosis (bluish discoloration) is best observed on the lips and nail beds. The best site to inspect for jaundice (yellow or orange discoloration) is the client sclera. Erythema (red discoloration) may indicate circulatory changes, e.g., an area of erythema may be due to sun burn or fever.

Color

Inspect the skin color hues seen in the palm, soles of the feet, lips, tongue, and nail beds. Increased color (hyperpigmentation) and decreased color (hypopigmentation) are common.

Moisture

The hydration of skin and mucous membranes helps to reveal body fluids imbalance. Skin surface is lightly rubbed; scaling involves fish-like scales that are easily rubbed off the skin surface. Dry skin includes lack of humidity exposure to skin, smoking, stress, excessive perspiration, and dehydration.

Temperature

Temperature is more accurately assessed by palpating the skin with the dorsum or back of the hand.

Texture

Localized changes may result from trauma, surgical wounds, or lesions. The nurse should ask if the client has had a recent injury to the skin.



Fig. 4.1: Nurse assesses skin.

JAYPEE BROTHERS

Turgor

Turgor is the skin's elasticity, which can be diminished by edema or dehydration. To assess the skin's turgor, fold of skin on the back of forearm or sternal area is grasped with the fingertips and released.

Edema

Areas of skin became swollen or edematous from a build up of fluids in the tissue.

Hair and Scalp

The nurse begins the inspection by noting the color distribution, quality, thickness, and lubrication of the body hair. Note hair loss (alopecia) or thinning of the hair, pediculus humans' capitis (body lice), pediculus corporis (body lice), and pediculus pubis (crab lice). The discovery of lice requires immediate treatment.

Nails

The condition of the nails can reflect general health, state of nutrition and a person's occupation. Before assessing the nails, the nurse asks if the client has had any recent trauma, or asks the client to describe his or her nail care practice.

Head and Neck

An examination of the head and neck includes assessment of the head, eyes, nose, ears, mouth, pharynx, and neck (lymph nodes, carotid arteries, thyroid glands, and trachea).

Head

History of intracranial injury and local or congenital deformities. The examination continues with nurse noting the size, shape of the skull, hydrocephalus, and acromegaly (disorder caused by excessive secretion of growth hormone).

Eyes

Examination of the eyes includes assessment of visual acuity, visual field, extraocular movement, and external and internal structure of the eye.

Visual Acuity

The assessment of visual acuity includes the ability to see small details. Assessment of distant vision requires use of Snellen chart. The client sits or stands 20 feet (6.1 m) away from the chart and tries to read it.

Extraocular Movement

Small skin muscles guide the movement of each eye. The client keeps the head in a fixed position facing the nurse and follows the movement of the fingers (six movements), i.e., lateral rectus, medial rectus, inferior rectus, superior rectus, inferior oblique, and superior oblique.

External Eye Structure

Inspect external eye structure

Position and alignment

The nurse assesses the position of the eyes in relation to one another.

Eyebrow

Inspect for size, extension texture of hair alignment, and movement.

Eyelids

The nurse inspects the eyelids for position, color, condition of the surface, condition and direction of the eye lashes, papillary reaction. Test for eye reaction to light, dilatation, or construction.

Ears

Inspection and palpation are the techniques used to examine the ears. Ear area to be assessed is the external (auricle) and ear canal, internal ear canal, and tympanic membrane (by performing an otoscopic examination).

Auricle

Inspect the auricle for color, size configuration, location, and angle of attachment to the head. The color of the ear should be same as that of the person's skin. Palpate the external ear for nodules and tenderness.

Otoscopic examination

An otoscope must be used to inspect the internal ear canal and tympanic membrane. Inspect the internal canal for impacted cerumen, foreign bodies, discharges, masses, redness, and swelling. Normally, you will view some cerumen, which varies in color (yellow, brown). Inspect the tympanic membrane, which is usually a shiny pearly gray or light pink.

Acoustic Nerve

The acoustic nerve is assessed by auditory acuity. Webber lateralization test, Rinne air, and bone conduction test. The watch assesses test auditory acuity. And in the whisper test, if abnormalities are detected, further testing using an audiometer is needed.

Webber lateralization: To perform the Webber lateralization, place the stem of a vibrating tuning fork in the center of the forehead (**Fig. 4.2**). Ask the person where the sound is heard well. Normally, sound is heard equally well in both ears as it is conducted through the bones. Note any lateralization of sound (sound heard better in one ear than the other). A person with a unilateral conductive hearing loss will hear the sound best in the impaired ear.

Rinne air condition and bone conduction test: The Rinne air and bone conduction test compares bone-conducted sound with air-conducted sound in one ear at a time.

JAYPEE BROTHERS



Fig. 4.2: Rinne test: Placing vibrating tuning fork 1–2 cm from ear canal.

Nose and Sinuses

Nose is assessed by inspection and palpitation. Inspect the external surface of the nose for symmetry in color, shape, and size. Palpate the external nares for tenderness to assess the patency. Ask the patient to occlude one ala nasi (one nostril) while breathing through the other.

Frontal and Maxillary Sinuses

Frontal and maxillary sinuses are palpated for tenderness, swelling, and thickening of secretions. Palpate the frontal sinuses by pressing up on the skull on either side of the nose under the eyebrows. Do not press on the eyes. Palpate the maxillary sinuses by pressing up over the lower part of the cheek bones on either side of the nose (**Fig. 4.3**).

Olfactory Nerve

To assess the sensory function of the olfactory nerve, instruct the person to close the eyes and occlude one ala nasi. Provide a familiar scent such as coffee or cinnamon for the person to smell. Test both nares. An absence of the sense of smell may result from excessive smoking, cocaine use, or sinus condition.

Mouth and Pharynx

The mouth and pharynx are assessed through inspection and palpation. Areas to be assessed include the lips, buccal mucosa, gums and teeth, tongue, soft and hard palate, and pharynx. Penlight tongue blade, gauze, and a pair of gloves will be needed.

Lips

Inspect the lips for symmetry, color, edema, and any surface abnormalities. Note that the lips are more pigmented than the facial skin. Common lesions associated with the lips are fissures, commonly seen with chapped lips and herpes simplex (cold sores). Using a gloved hand, palpate the lips for moistness, induration, intactness, and lesions (**Fig. 4.4**).

Gums and Teeth

Inspect the gums by placing your gloved hands in the lower lip and gently pulling it down to expose the gums. Normally, the gums are pink in color and free of lesions, inflammation, and bleeding.

The teeth should be clean, white, straight, firm, evenly spaced, and free of decay. Normally, there are 32 teeth, and inspect for caries, plaque, missing, or loose teeth. Inspection of the teeth can also provide information regarding the person's attitude toward general hygiene.

Tongue

Inspect and palpate the tongue using gloved hands and a piece of gauze. Note the symmetry movement, and color of the tongue. Normally, it should be pink, moist, and smooth. Ask the person to extend the tongue, so that you may palpate it from front to back. Wrap a piece of gauze around the tongue



Fig. 4.3: Palpation of maxillary sinuses.

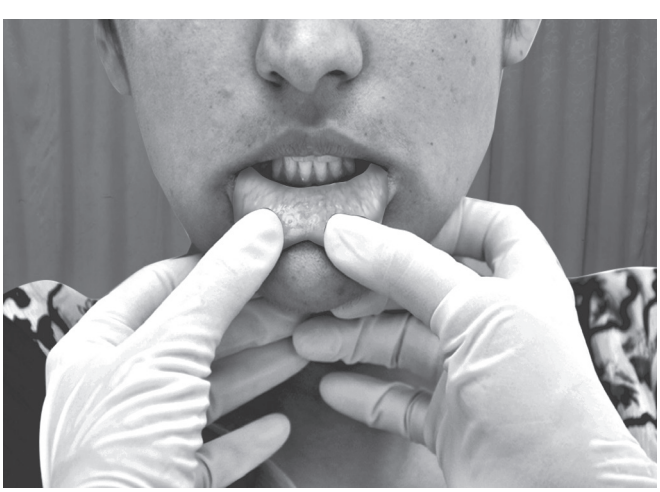

Fig. 4.4: Inspection of inner oral mucosa of lower lip.

JAYPEE BROTHERS

during palpation. The floor of the mouth is a common site for oral cancer.

Neck

Assessment is performed using the techniques of inspection and palpation. Upon examination, the person should be in an upright position to facilitate the rotation of the neck. Inspect the neck for color, symmetry, masses, enlargement of the thyroid, or lymph nodes, abnormal pulsation, impaired range of motion, lesions and scars.

Lymph nodes (one of the many small oval structure that filters the lymph and fights infection and in which there are formed lymphocytes, monocytes and plasma cells). Palpate the lymph nodes using the pads of your index finger and middle fingers. Move the skin over the node, gently palpate in sequence, bilaterally, the posterior auricular occipital tonsillar, submaxillary, and submental.

Thyroid

Inspect and palpate the thyroid gland for sizes, shape, and any masses by instructing person to swallow water while extending the neck normally. The thyroid gland and the cricoids cartilage will rise as the person is swallowing. The enlarged thyroid gland is called Goiter; you may palpate the thyroid gland by standing in front or behind the person. Ask the person to swallow. You will be able to feel the thyroid isthmus rise beneath your finger.

Trachea

Inspect and palpate the trachea for any deviation from the midline by placing two fingers. The trachea is present at the suprasternal notch (**Fig. 4.5**).

Carotid Arteries

Inspect and palpate the carotid arteries to assess symmetry, amplitude, rate, and rhythm of pulsation. Palpate only one carotid artery at a time, remembering that these arteries supply essential blood to the brain.



Fig. 4.5: Placement of the fingertips over the trachea to begin palpation of the thyroid gland.

Spinal Accessory Nerve (CN XI)

Innervates the major neck muscles (trapezes and sternocleidomastoid). Assess this nerve and muscle strength by asking the person to shrug the shoulder against the resistance of your hands and to turn the head from one side to the other as you try to resist these movements.

External Jugular Veins

Inspect the jugular veins for abnormal or unusual distention. The jugular veins are not normally distended.

Chest

Examination of chest involves assessment of respiratory system (lungs) and cardiovascular system (chest).

A thorough examination of the chest requires you to use the techniques of inspection, palpation, percussion, and auscultation. The posterior chest is examined first with the person in a sitting or supine position. During the assessment of the thorax, bear in mind the thoracic reference lines and familiar landmark, e.g., ribs, sternal documentation of the location of findings.

The posterior chest is inspected for any skeletal deformities that could affect the status of the respiratory system. Some common abnormalities are kyphosis (an exaggerated curvature of the thoracic vertebra), scoliosis (a lateral curvature of the spine), and lordosis (an exaggerated curvature of the lumbar vertebra) (**Fig. 4.6**).

- **Anterior thoracic reference line:**
  - Midstream line
  - Midclavicular line
  - Anterior axillary line
  - Midaxillary line
  - Posterior axillary line
- **Posterior thoracic reference line:**
  - Midspinal line
  - Midscapular line
  - Posterior axillary line



Fig. 4.6: Nurse locating the angle of Louis.

JAYPEE BROTHERS

- Midaxillary line
- Anterior axillary line

Lung Assessment

Assess history of tobacco, cough (productive, nonproductive), chest pain, shortness of breath, history of pneumonia, or bronchitis, HIV infection, persistent cough, hemoptysis, unexplained weight loss. Review family history of cancer, tuberculosis, and allergies.

Inspect lungs: Color, intercostals space, chest symmetry, rib space, respiratory rate, shape and position of sternum, position of trachea, and chest expansion.

Palpation

The posterior chest is palpated for costal space, intercostal space, and any tenderness. Masses palpate with the palmar surface of the hand. Assessing the chest and comparing the right side to the left side make the client take deep breath and observe their movement.

Vocal fremitus: During speech, the sound created by the vocal cords is transmitted through the lungs to the chest wall. The sound waves create vibration that can be palpated externally, these vibration are called tactile or vocal fremitus. The building of mucus secretions, the collapse of lung tissue, or the presence of lung lesions can block the vibrations from reaching the chest wall.

Palpate the vibrations with the palmar surface or ulnar side of the hand. Ask the person to repeat the words "ninety nine" or "one, one, one". Use only one hand to palpate fremitus to avoid any discrepancies, differing sensitivity between the hands. You will cover the entire chest by moving back and forth from one side to the other. Also note an increase in fremitus during an inflammatory process.

Percussion

The posterior chest is percussed to determine whether the underlying tissue is air-filled, fluid-filled, or solid. The normal lung should be air-filled producing resonance (loud low pitched).

Auscultation

Auscultation is useful in assessing airflow, the presence of fluid mucus, or obstruction in the surrounding lung and pleural space. Whole auscultation, instruct the person to take deep breaths through the mouth. Listen to at least one full breath in each location following the percussion sequence.

Normal breath sounds: Normal breath sounds are vesicular, bronchial, and bronchovesicular. Breath sounds are soft and low-pitched fine resulting sounds.

Adventitious breath sounds: These are superimposed over normal sounds. The four types of adventitious sounds include crackles, also called rales; ranchi also called gurgles; wheeze; and floral friction rub. Each sound is caused by a specific entity and is characterized by a typical auditory feature.

Anterior Chest

Inspection

The anterior chest is inspected for any skeletal deformities. Some common abnormalities are barrel chest, pigeon chest, and funnel chest.

Palpation

The anterior chest is palpated for areas of tenderness, respiratory excursion, and fremitus.

Percussion

Percuss the anterior and lateral chest.

Auscultation

Auscultation for vesicular, bronchial, and bronchovesicular breath sounds.

Heart

Assessment of heart function is closely compared with findings from the vascular examination. In adults, the heart is located at the center of chest behind and to left of the sternum.

Health history should focus on risk factors for heart disease. The nurse assesses the history of smoking, alcohol intake, caffeine intake, use of recreational drugs, exercise habits and dietary patterns, stressful lifestyle, medication for hypertension, chest pain, and discomfort, anginal pain radiating to one or both the arms history of heart disease.

Inspection, percussion, palpation, and auscultation are the techniques used in the examination of the heart to identify the precordial points. You must be familiar with the landmarks and the angle of Louis is palpated as a prominence on the upper third of the sternum. Palpate this area and move the fingers laterally to identify the second intercostal space. The aortic area is located from the second intercostal space to the right sternal border. The pulmonic area is located at the second intercostal space to the left sternal border. Erbs point is located at the third intercostal space to the left sternal border. The tricuspid area is located at the fourth or fifth intercostal space to the left sternal border the mitral (apical) area is located at the fifth intercostal space medial to the midclavicular line. The epigastric area is the area overlying the xiphoid process.

Inspection

Position the person in a supine position or lying with the head of the bed at a 30°–45° angle inspect the precordial points of the chest for any abnormal pulsation and the apical impulse. The apical impulse is a pulsation located over the apex of the heart at the fifth intercostals space medial to the midclavicular line.

Palpation

The precordial points of the chest are palpated for any abnormal pulsation, thrills, apical impulse and aortic pulsation. A thrill is a palpable cardiac murmur. To palpate

JAYPEE BROTHERS

the apical impulse, place the heel of the hand on the sternum with your fingers stretched across the chest just under the breast area. Palpate it with your fingertips.

Percussion

Cardiac dullness is located in the third to fifth intercostal space. The auscultation technique assess the normal heart sounds (s1–s4) and murmur. Auscultate over the precordial area with both the stethoscope diaphragm and bell; listen to each area through several breathe through the nose to decrease the interference of breath sounds.

First heart sounds

The first heart sounds (s1) is produced by the closure of the mitral and tricuspid heart valves. It is best heard at the apex of the heart.

Second heart sounds

The second heart sounds (s2) is produced by the closure of the aortic and pulmonic heart valve. It is best heard at the base of the heart (aortic area). Remember that heart is upside down with its apex located at the fifth intercostal space. Along the sternal border, sl and s2 are both high-pitched sounds.

Third heart sound

Third heart sound (s3) is a low-pitched sound heard in the cardiac cycle immediately after s2.

Fourth heart sounds

The fourth heart sounds (s4) is low-pitched sound heard in just before s1.

Heart murmur

This is a harsh rumbling, blowing sounds caused by blood flow across a defective valve.

Examination of Breasts

It is important to examine the breasts of female clients. A small amount of glandular tissue, a potential site for the growth of cancer cells is located in the middle breast. In contrast, the majority of the female breast is glandular.

Female breast

Breast cancer is secondary to lung cancer, the leading cause of death in women with cancer. Early detection is the key to cure. A major responsibility for nurses is to teach client health behavior such as breast self examination (BSE).

History: Factors that affects and increase the risk of developing breast cancer are:

- Null parity
- Late childbearing
- Early menarche
- Family history, especially first-degree relative
- Obesity in postmenopausal women
- Premenopausal exposure to ionizing radiation
- History of benign breast disease
- Previous breast cancer.

Factors still under evaluation

- Alcohol
- High fat diet
- Oral contraception and hormone replacement therapy.

About 80% of symptomatic breast carcinomas appear as a palpable mass. A mobile lump appears, most frequently, in the upper outer quadrant of the breast. There may or may not be pain. If no lump is present, attention may be drawn to a problem by localized discomfort such as burning, stinging, or aching. Less common presentations such as nipple discharge and retraction, Paget disease, dimpling, or orange-peel appearance of the skin may be observed.

BSE should be performed monthly by women aged 20 years and older. An examination by a physician should be performed over 3 years, from the ages of 20–40. Over 40 women a year with a family history of breast cancer should have a yearly physician examination.

Inspection: Inspect the breast and nipple of the patient in sitting position.

Palpation: When pressing deeply on the breast you may mistake a normal rib for hard breast mass. Nodules in the tail of the breast are sometimes mistaken for enlarged axillary lymph.

Breast and axillae examination

Put the client in a standing or sitting position, disrobed to the waist, with her arm at her side.

Inspect the breast:

- Size symmetry
- Contour, masses, dimpling (retraction sign), or flattening
- Appearance of the skin color, (orange peel) thickening, edema, or venous prominence.

Patient education, breast self-examination (BSE)

- **Step 1:**
  - Stand before mirror.
  - Check both breasts from the nipple, dimpling in the contour of the breasts. As you do them you should be able to feel your muscles tighten.
- **Step 2:**
  - Watch closely in the mirror as you clasp your hands behind your head and press your hands forward.
  - Note any change in the contour of your breasts.
- **Step 3:**

  Next, press your hands firmly on your hips and bow slightly toward the mirror as you pull your shoulders and elbows forward.

  Note any change in the contour of your breasts.

  Note: Women should do the next part of the examination in the shower. Your fingers will glide over soapy skin, so you can concentrate on feeling for change inside the breast.

JAYPEE BROTHERS

Principles of
Respiratory Medicine

Get Full Access
with added features at
emedicine360.com



Principles of Respiratory Medicine is a comprehensive text written by distinguished physicians who have practiced respiratory medicine for several decades in India. The authors have not compromised on the generally accepted description of respiratory diseases common to the affluent West and to poor developing countries. Their special emphasis is, however, on respiratory diseases peculiar to India and other tropical countries.

The text, divided into twenty-two sections and extremely well-illustrated, succeeds in giving a comprehensive view of different respiratory diseases as observed in India and other tropical countries. A highlight of the book is the discussion on the threat of pulmonary tuberculosis and its unsolved challenges. The epidemiology, the subtle variation in clinical presentation, and the natural history of respiratory diseases in regional contexts have been clearly emphasized. In these respects, this book differs significantly from the many books on respiratory diseases written by western authors, and is a landmark book not only in India but perhaps also in Southeast Asia.

The book should be of considerable interest to students, consultants, and pulmonologists in India, Southeast Asia, Africa, and to professional colleagues in the West.

Farokh Erach Udwadia is Emeritus Professor of Medicine, Grant Medical College, JJ Hospital, Mumbai, and Consultant Physician, Parsee General Hospital and Breach Candy Hospital, Mumbai, Maharashtra, India, where he also heads the intensive care unit. He has a number of national and international distinctions to his credit. As an established author, he has written several medical monographs, which include Bedside Clinics (OUP 2008), Principles of Critical Care (OUP 2004), and Man and Medicine—A History (OUP 2001).

Zarir F Udwadia is a Consultant Chest Physician, Hinduja Hospital, Breach Candy Hospital, and Parsee General Hospital, Mumbai, Maharashtra, India. He has written for several medical publications and has contributed to several international textbooks. He is actively involved in tuberculosis (TB) research in collaboration with partners across the globe and was invited by World Health Organization (WHO) to be on the "Guidelines Group", which formulated the current TB Guidelines published in 2010.

Anirudh F Kohli is Head of Imaging at Breach Candy Hospital, Mumbai, and Consultant Radiologist at the Jaslok Hospital, Mumbai, Maharashtra, India. He has been Joint Editor of Indian Journal of Radiology and Imaging and Founder of the Indian Imaging Academy. He has introduced numerous imaging technologies in India and has several national and international publications to his credit.

Khyati Shah is a Consultant Physician and Research Officer at Breach Candy Hospital, Mumbai, Maharashtra, India.

Available at all medical bookstores
or buy online at www.jaypeebrothers.com



JAYPEE BROTHERS
Medical Publishers (P) Ltd.
www.jaypeebrothers.com

Join us on facebook.com/JaypeeMedicalPublishers

Shelving Recommendation
MEDICINE

