rs.com, for detailed information on obstetrics & gynecology books, visit our website www.jaypeebrothers.com, for detailed information on obstetrics & gynecology books

Inter-University School of Medical Ultrasound
Ian Donald

Celebrating 50 years
Passion, Quality and Innovation in Healthcare Publishing

Donald School Textbook

CURRENT STATUS OF CLINICAL USE OF *3D/4D* ULTRASOUND IN OBSTETRICS AND GYNECOLOGY



Eberhard Merz
Asim Kurjak

3rd World Congress on 3D Ultrasound in Obstetrics and Gynecology
• 21-24 March 2019 • Dubrovnik • Croatia •

JAYPEE

Contents

1. 3D/4D Ultrasound for the Assessment of Ovarian Tumors 1

Juan Luis Alcázar

- Three-dimensional Grayscale Ultrasound *1*
- Three-dimensional Power Doppler Ultrasound *2*
- Four-dimensional Power Doppler Ultrasound *6*

2. Fetal Organ Volume Measurements 10

Edward Araujo Júnior, Liliam Cristine Rolo, Luciano Marcondes Machado Nardozza

- Methods Used for Volumetric Analysis of Fetal Organs using 3D Ultrasound *11*
- Evaluation of Fetal Cardiac Volume *13*
- Evaluation of Fetal Cerebellar Volume *13*
- Evaluation of Fetal Lung Volume *14*
- Assessment of Fetal Adrenal Gland Volume *14*
- Evaluation of Fetal Thymus Volume *14*
- Assessment of Fetal Limb Volume *15*

3. Ultrasound and Folliculogenesis 19

Fernando Bonilla-Musoles, Newton Osborne, Francisco Raga, Francisco Jose Bonilla Bartret

- Ultrasonographic Notions for Folliculogenesis Control *19*
- Folliculogenesis in Natural Cycle *22*
- Doppler in a Natural Cycle *27*
- Folliculogenesis in an Induced Cycle *30*
- Doppler in an Induced Cycle *31*
- New Ultrasound Modes *31*
- Study of the Endometrium *34*
- Ovarian Endocrinologic Pathologies *38*

4. Application of 3D in First Trimester 41

Marisa Borenstein Guelman, Guillermo Azumendi Pérez

- Surface Mode *41*
- Multiplanar Mode *45*
- Volume Calculation *48*
- Spatiotemporal Image Correlation *49*
- Telemedicine *51*

5. 3D Ultrasonography and 3D Power Doppler in the Evaluation of Placenta Accreta Spectrum 54
Giuseppe Calì, Francesco Forlani, Gabriella Minneci

- Placenta Accreta Spectrum and Ultrasound Diagnosis *54*
- Role of 3D Ultrasonography and 3D Power Doppler *55*

6. Nomenclature of Three-dimensional and Four-dimensional Ultrasound in Obstetrics, Gynecology, and Fetal Echocardiography 61
Jing Deng

- Dimensionality in Medical Imaging: 3D and 4D *62*
- Real-timeness *62*
- Online and Offline *63*
- Frame Rate and Volume Rate *65*
- Region of Interest versus Imaging Plane Size and Volume of Interest versus Imaging Volume Size *66*
- Multiplanar versus Multislice Reformatting/Display, Three-orthogonal Planes versus Triplanar Displays, Tomographic Display versus Parallel-Plane, and Omni-view versus Curved Plane *66*
- Inversion Mode/Negative Surface Display versus Virtual Casting/Digital Casting *69*
- Direct and Indirect Volume Scanning *72*

7. Direct Volume Scan or Indirect Volume Scan: Four Relativity Issues in Four-dimensional Ultrasonography (Applicable to Other Multidimensional Imaging Modalities) 75
Jing Deng

- Relativity between Temporal Resolution and Time Scale of Interest—How Fast is Fast Enough? *76*
- Relativity between Spatial Resolution and Structural Scale—How Fine is Fine Enough? *81*
- Relativity between Imaging Volume and Inseparable Entirety of the Volume of Interest—How Full is Full Enough? *84*
- Relativity between Maximal Facilitation of 4D Scanning and Minimal Restriction on the VOI Functioning—How Free is Free Enough? *89*

8. Three-dimensional/Four-dimensional Pelvic Floor Ultrasound 94
Hans Peter Dietz

- Basic Technique *95*
- Anterior Compartment Pathology *97*
- Anatomy of Stress Urinary Incontinence *97*
- Anterior Compartment Prolapse *97*
- Central Compartment *98*
- Posterior Compartment *99*
- Anal Sphincter *102*
- Synthetic Implants *104*
- Levator Ani *112*

9. How to Think in Three Dimensions? 119

Eldar Volpert, Liat Gindes

- 3D as Voxels *119*
- Multiplanar View and the Region of Interest *119*
- Movement of the ROI *120*
- Rotation of the Volume Around the X-, Y- or Z-Axis *121*
- Alignment of the Volume *122*
- Practical Examples of Volume Alignment *122*
- 3D Manipulation of the Fetal Cardiovascular System *123*
- Application of Multiplanar View to Identify Müllerian Anomalies *123*

10. Three-dimensional Examination of the Placenta 130

Erich Hafner

- Placental Volume *130*
- Three-Dimensional Color Doppler Ultrasound *131*
- Future *132*

11. HDlive Flow Silhouette Mode for Fetal Heart 137

Toshiyuki Hata, Uiko Hanaoka, Kenji Kanenishi

- HDlive Flow and HDlive Flow Silhouette Mode *137*
- Normal Fetal Heart *138*
- Structural Variant of the Fetal Heart *145*
- Congenital Heart Anomaly *147*

12. Three-dimensional Ultrasound Imaging in the Diagnosis of Ectopic Pregnancy 152

Ulrich Honemeyer

- Ectopic Pregnancy Locations *153*
- Tubal Ectopic Pregnancy *153*
- Ovarian Ectopic Pregnancy *154*
- Uterine Ectopic Pregnancy *155*
- Cornual/Interstitial Ectopic Pregnancy *155*
- Cesarean Scar Ectopic Pregnancy *157*
- Cervical Ectopic Pregnancy *158*
- Abdominal Ectopic Pregnancy *159*
- Diagnostic Hints and Pitfalls *161*

13. Recent Advances in 3D Assessment of Müllerian Anomalies 169

Ashok Khurana

- What is New and Different? *171*
- The ESHRE/ESGE Classification *171*
- Updates, Criticisms, and Recommendations *182*

14. Fibroids and Infertility: The Added Value of Three-dimensional Ultrasound **185**
Sanja Kupesic Plavsic

- Uterine Fibroids and Infertility *185*
- Uterine Fibroids and Pregnancy *186*
- Imaging *187*
- The Added Value of Three-dimensional Ultrasound *189*

15. Four-dimensional Ultrasound in Functional Studies of the Fetus **198**
Asim Kurjak, Panagiotis (Panos) Antsaklis

- Assessment of Fetal Behavior Over the Years *198*
- Clinical Results of Kurjak's Antenatal Neurodevelopmental Test *200*
- Discussion *207*

16. Anomalies of the Fetal Face **210**
Eberhard Merz, Sonila Pashaj

- Anomalies including the Forehead *210*
- Anomalies of the Orbits and the Eyes *212*
- Nose Abnormalities *213*
- Abnormalities of the Mouth *214*
- Chin Anomaly *215*

17. Artifacts and Pitfalls in 3D Ultrasound **218**
Danka Miric Tesanic, Eberhard Merz

- Motion Artifacts *218*
- Acoustic Shadowing *219*
- Amputation of Objects by the Volume Box *220*
- Unfavorable Threshold Adjustment *220*
- Defects Caused by the Electronic Scalpel *220*
- Artifacts due to Superimposed Objects *221*
- Sonographic Pitfalls *222*

18. Three-dimensional Ultrasound in Infertility and Ectopic Pregnancy **225**
Sonal Panchal

- 3D Ultrasound for Abnormalities of the Uterus *225*
- Endometrial Polyp *225*
- Sonohysterography Technique *226*
- Endometrial Hyperplasia *227*
- Intrauterine Device Placement *229*
- Adenomyosis *229*
- Fibroids *231*
- Adnexal Lesions *235*
- Tubal Patency Assessment *238*
- Polycystic Ovaries *240*
- Follicular Monitoring *242*
- Ectopic Pregnancy *246*

19. Advantage of 3D Ultrasound in Exact Diagnosis of Normal and Abnormal Fetal Corpus Callosum 252
Sonila Pashaj, Eberhard Merz

- Why is the Demonstration of the Corpus Callosum Important? *252*
- What is the Normal Sonographic Appearance of the Corpus Callosum and When can it be Displayed? *252*
- Advantages of Three-dimensional Ultrasound in the Demonstration of the Corpus Callosum *253*
- Scanning Techniques with Three-dimensional Ultrasound and Offline Analysis *253*
- How not to Render the Fetal Corpus Callosum? *256*
- Measurements of the Corpus Callosum *259*
- Pathologies of the Corpus Callosum *259*
- Complete Agenesis of Corpus Callosum *259*
- Partial Agenesis of Corpus Callosum *260*
- Hypoplasia of Corpus Callosum *260*
- Hyperplasia of Corpus Callosum *260*

20. Three-dimensional Ultrasound and Maternal Bonding 263
Leonid M Rovner, Katelyn T Horton, Mishella I Perez, Dolores H Pretorius

- Background of Ultrasound Technology *263*
- Two-dimensional Ultrasound *265*
- 2D US versus 3D US *266*
- Paternal Bonding *267*
- Confounding Factors *267*
- Public Opinion about 3D US *268*
- Negative Aspects of 3D US *269*
- Negative Aspects of 2D US *270*
- Controversy of Doing 3D for Entertainment versus Reassurance *271*

21. First-trimester Placenta Volume and Three-dimensional Vascularization 274
Giuseppe Rizzo, Victoria Bitsadze, Alessandro Quarto, Alexander Makatsarya

- Technique of Acquisition *274*
- Changes of Placental Volume and Vascularization in Abnormal Pregnancies *276*

22. Fetal Cognitive Functions and Three-dimensional/Four-dimensional Ultrasound 281
Aida Salihagić Kadić, Anja Šurina, Oliver Vasilj, Sanja Tomasović, Asim Kurjak

- Structural and Functional Brain Development and Cognitive Functions *281*
- Prenatal Neuromotor Development and Fetal Intentional Movements *283*
- Prenatal Neurosensory Development and Fetal Perception of Stimuli *285*
- Fetal Learning and Memory *287*
- Emotional Development of the Fetus *289*
- Role of Fetal Stress in Cognitive Development *290*

23. Three-dimensional Ultrasonographic Evaluation of the Fetal Posterior Fossa 296
Sertaç Esin, Ebru Tarım, Cihat Şen

24. Three-dimensional Sonography in Fetal Syndromes **300**
Lara Spalldi Barišić, Asim Kurjak, Ritsuko Kimata Pooh

- Defining a Syndrome and When to Suspect a Syndrome? *300*
- Clinical Application of Three-dimensional Ultrasound in the Prenatal Detection of Fetal Syndromes *302*
- Syndromes Featuring Primarily Craniofacial Anomalies *303*
- How to Distinguish What is Normal and What is not? *304*

25. Three- and Four-dimensional Ultrasound in Fetal Echocardiography: A New Look at the Fetal Heart **321**
Simcha Yagel, Sarah M Cohen, Israel Shapiro, Baruch Messing, Dan V Valsky

- Three- and Four-dimensional Techniques and their Application to Fetal Cardiac Scanning *321*
- Screening Examination of the Fetal Heart with Three- and Four-dimensional Ultrasound *331*
- Three- and Four-dimensional Ultrasound in the Diagnosis of Congenital Heart Disease *333*
- Potential Pitfalls of Three- and Four-dimensional Echocardiography *339*
- Accuracy *340*

Index *345*

CHAPTER

2

Fetal Organ Volume Measurements

Edward Araujo Júnior, Liliam Cristine Rolo, Luciano Marcondes Machado Nardozza

JAYPEE BROTHERS

INTRODUCTION

The initial studies on the volumetric analysis of fetal organs dates back to the mid-1980s and involve the use of two-dimensional (2D) ultrasound, then in which fetal organs presented a regular ellipsoid geometric shape (length × width × height × 0.52).[1] In the early 1990s, with the advent of three-dimensional (3D) ultrasound, the volumetric analysis of fetal organs became more accurate because this technique allowed delineating the irregular external surface of organs, in contrast with 2D ultrasound, which rendered them as regular geometric structures.[2] The study by Riccabona et al.[3] was the first to compare 2D and 3D ultrasound volumes with actual volumes. These authors observed that for objects with irregular shapes, the percentage error was significantly lower in 3D ultrasound than in 2D ultrasound, whereas for regular objects, there was no significant difference between these two methods.

The first studies on the volumetric analysis of fetal organs date back to the beginning of the 1990s. Reference curves were constructed for different organs, including the cerebellum, lung, liver, and adrenal glands, using the multiplanar method or planimetry.[4-7]

In the early 2000s, a new volume calculation method designated virtual organ computer-aided analysis (VOCAL) was developed, and reference curves were created for the lungs, heart, cerebellum, kidneys, and spleen.[8-11] VOCAL was used in several clinical applications, including volumetric analysis of the lungs to predict pulmonary hypoplasia in fetuses with congenital diaphragmatic hernia (CDH),[12,13] fetal adrenal glands to predict preterm labor,[14] and fetal bladder in pregnant women with diabetes mellitus.[15] In addition, VOCAL combined with spatiotemporal image correlation (STIC) allowed assessing fetal heart function.[16,17] VOCAL showed almost perfect intra- and interobserver agreement on the volume of fetal brain structures.[18]

Another volume calculation method developed in the mid-2000s was the eXtended Imaging VOCAL (XI VOCAL). This method was applied in the volumetric analysis of structures, including the embryo, yolk sac, and gestational sac, in the first trimester of pregnancy.[19-21] An in vitro study comparing the multiplanar method, VOCAL, and IX VOCAL with actual sizes indicated that IX VOCAL was superior to the others in assessing the size of structures with irregular shapes.[22] Reference curves were prepared for the fetal heart,[23] lateral ventricles of fetuses with malformations of the central nervous system,[24] cranial structures in fetal growth restriction (FGR),[25] and healthy and hydronephrotic kidneys.[26]

Another commercially available volume calculation method is sonography-based automated volume count (SonoAVC). The main applications include identifying and counting the number of follicles in controlled ovarian stimulation for human reproduction techniques,[27,28] but this method has also been used to evaluate the volume of fetal organs, including cardiac cavities[29] and renal pelvis.[30,31]

Another important application of the volumetric analysis of fetal organs is predicting birth weight and intrauterine nutritional status. Studies have shown that 3D ultrasound is more accurate than 2D ultrasound in predicting birth weight[32,33] and monitoring the nutritional status of fetuses at risk of growth disorders.[34,35]

The objective of this chapter is to describe the main techniques of volumetric analysis of fetal organs using 3D ultrasound and its potential clinical applications.

METHODS USED FOR VOLUMETRIC ANALYSIS OF FETAL ORGANS USING 3D ULTRASOUND

Multiplanar Method

This method consists of measuring the size of fetal organs in three orthogonal planes (axial, transverse, and coronal). It includes defining a plane on which the outer surface of the organ is delineated to determine an area; at the same time in another plane, a cursor moves along an axis to define new planes to be marked. The distance of the displacement of the cursor is measured by the operator and usually ranges from 0.5 mm to 3.0 mm; depending on the size of the fetal organ. At the end of the cursor movement on the analyzed structure, the device sums the delimited areas automatically and provides its size **(Figs. 2.1A and B)**.

Virtual Organ Computer-aided Analysis

This method allows the fetal organ to be analyzed to be rotated on an axis, and the consecutive planes that determine organ measurement are gradually shown on the screen of the equipment. The organ ends are demarcated using measurement calibrators, and the external surface of the structure is delimited either manually or in sphere mode. The angle of rotation can be 6°, 9°, 15°, or 30° with the delimitation of 30 planes at 6° and of six adjacent and sequential planes at 30°. The device calculates an area in each delimited plane and at the end of the rotation, the software automatically calculates the volume and makes a 3D reconstruction of the organ **(Figs. 2.2A and B)**.

eXtended Imaging Virtual Organ Computer-aided Analysis

This technique consists of delimiting areas in adjacent sequential planes arranged on the apparatus screen. The examiner defines the first and last planes and the number of intermediate planes between these limits (5, 10, 15, or 20). Each plane boundary determines an area; after scanning all planes, the equipment automatically provides the organ volume, the reconstructed 3D image, the distance between the intermediate planes, and the distance between the first and last planes **(Figs. 2.3A and B)**.

Sonography-based Automated Volume Count

This volumetric analysis method can be used in the following two modes—(1) SonoAVC follicle and (2) SonoAVC general. The former is used to determine follicular volume

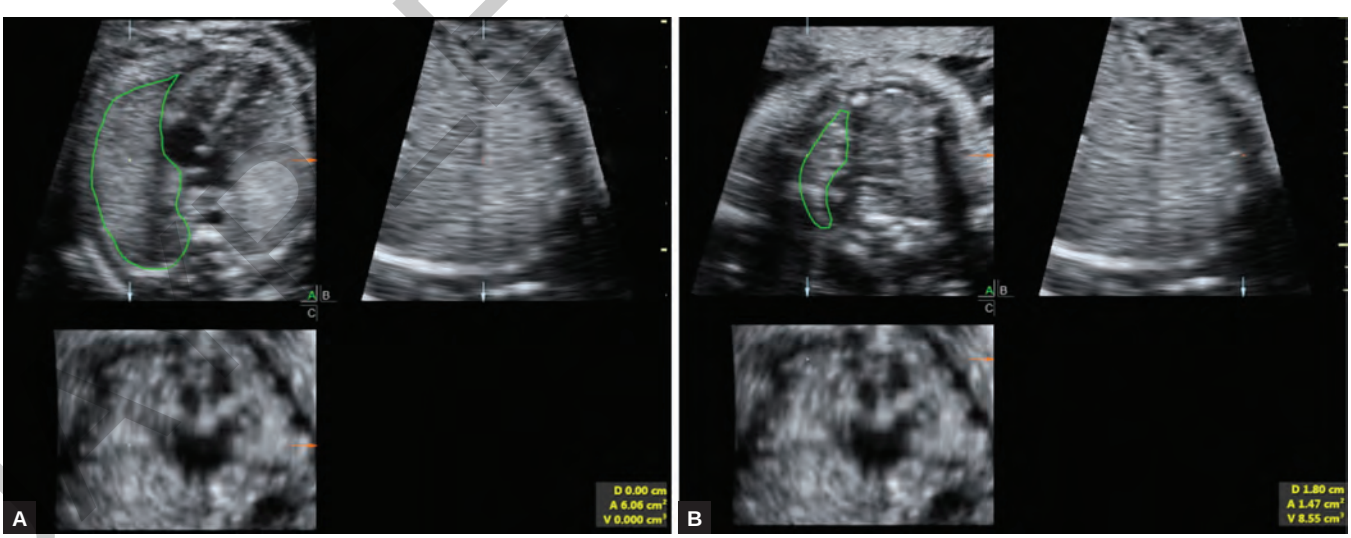

Figs. 2.1A and B: Calculation of fetal right lung volume measurement by multiplanar method. (A) Plane A (axial) is selected with reference, which is rotated about the z-axis so that the lung is positioned at 12 h. The B plane (sagittal) is selected and the cursor is arranged at the level of the mid-point of fetal diaphragm. The first area of the lung in the A plane is delimited manually, while in the B plane the cursor moves from the base to the lung apex at intervals of 3.0 mm; (B) When the cursor reaches the lung apex in plane B, the last area in plane A is delimited, with the apparatus automatically providing the organ volume.

JAYPEE BROTHERS

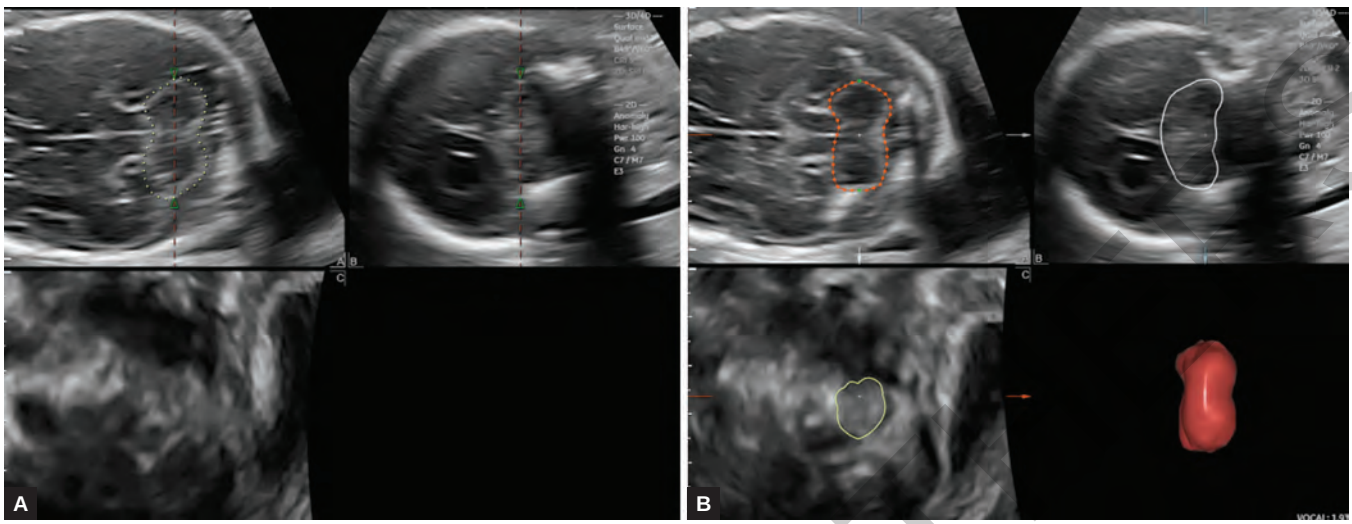

Figs. 2.2A and B: Fetal cerebellum volume measurement by the virtual organ computer-aided analysis (VOCAL) method. (A) Plane A is selected with reference, which is rotated about the z-axis so that the cerebellum is set in 12 h at the level of transverse cerebellum diameter measurement. Calipers are positioned at the extremities of the organ. The outer surface of the organ is delimited in a manual manner, and with each rotation (30°) a new area is delimited; (B) At the end of the rotational process (6 planes), the apparatus provides the rebuilt image of the structure with its volume.

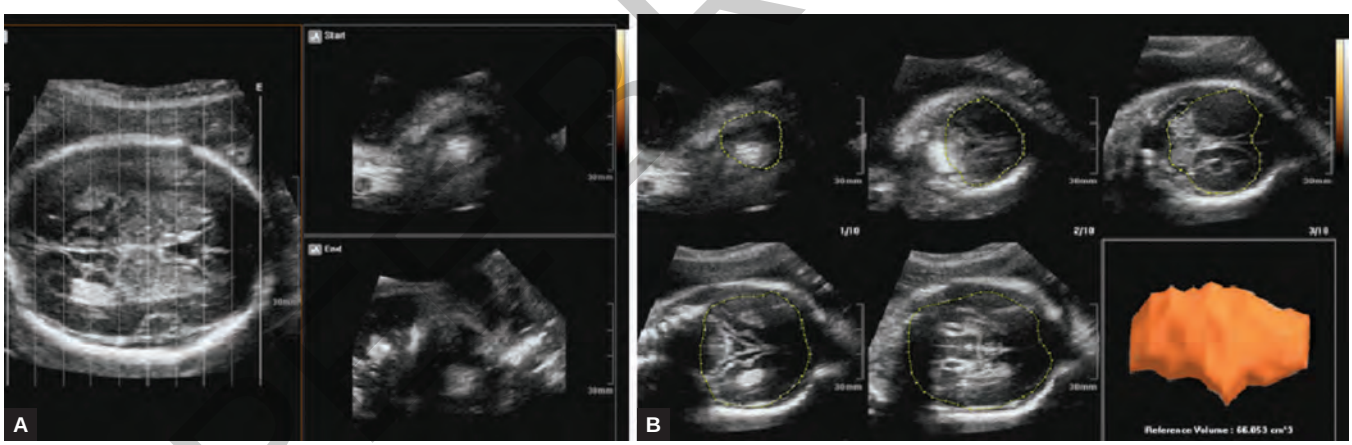

Figs. 2.3A and B: Fetal brain volume measurements by eXtended imaging virtual organ computer-aided analysis (XI VOCAL) method. (A) The initial and the last sectional planes are positioned at the proximal and distal cortex. Afterward, 10 sequential areas are delimited in the axial view; (B) Finishing the last area delimitation, the equipment automatically provides the 3D reconstructed image of the fetal brain with its volume.

and diameter and the latter is used to measure the overall volume, in this case, the fetal organs. The operator initially defines the region of interest, i.e. what part of the obtained volume will be analyzed. In SonoAVC follicle, the program determines the volume (V), three orthogonal diameters (dx, dy, and dz), the mean of these three diameters (md), and the volume-based diameter (vD) of all the anechoic structures in the region of interest. After determining the volume, the operator should assess whether all follicles were identified, the presence of nonfollicular structures identified as follicles, and the presence of gross errors when estimating follicular volume. In SonoAVC general, the size is not measured automatically, and the operator needs to click on the option corresponding to the desired volume, e.g. fetal heart chamber volume **(Fig. 2.4)**.

JAYPEE PROOFS

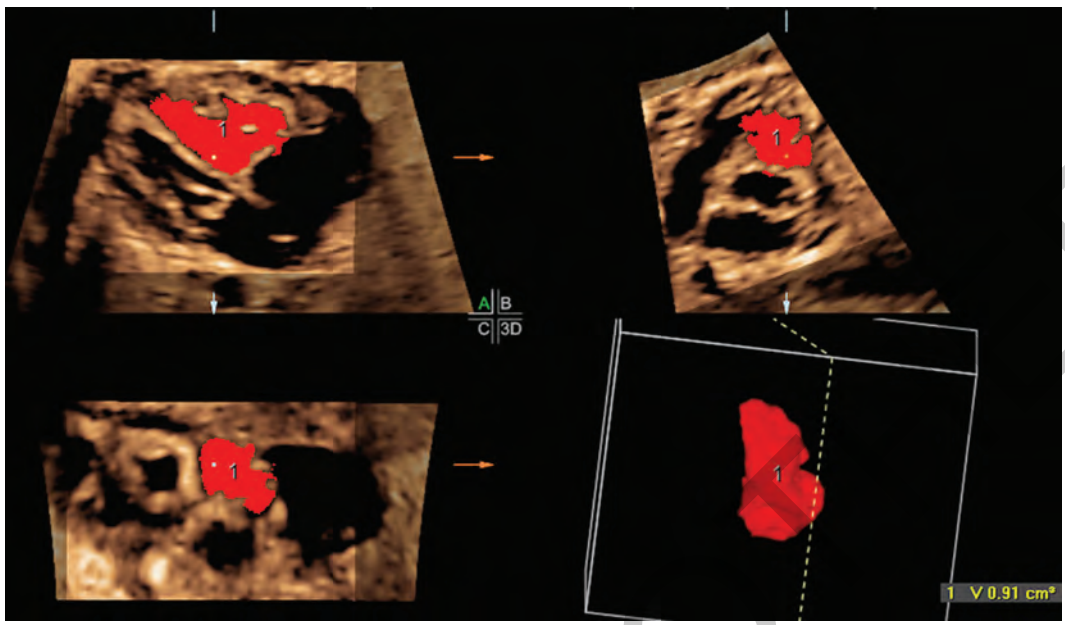

Fig. 2.4: Fetal heart right ventricle volume measurement during systole by sonography-based automated volume count (SonoAVC) method.

EVALUATION OF FETAL CARDIAC VOLUME

The study by Chang et al.[36] was the first to evaluate fetal cardiac volume using 3D ultrasound. The heart volume of 50 healthy fetuses was assessed at 20–30 weeks of gestation, and 2D ultrasound (length × width × height × 0.5233) and 3D ultrasound were compared with the multiplanar method. This method used a slice sequence of the four-chamber plane with a 1.0-mm interval. These authors observed that 3D ultrasound was more reproducible than 2D ultrasound, and the 2D ultrasound volumes were larger than those obtained using 3D ultrasound. The volumes obtained by 2D ultrasound were made equivalent to those obtained using 3D ultrasound by performing polynomial regression and obtaining a new 2D constant (0.4563). The 2D volumes calculated with this new constant did not differ from those obtained using 3D ultrasound.

Peralta et al.[8] found reference values for fetal cardiac volume using VOCAL. A total of 650 normal pregnancies were evaluated at 12–32 weeks of pregnancy using VOCAL with a rotation angle of 30°. The mean cardiac volume was increased significantly with gestational age from 0.6 mL at 12 weeks of gestation to 4.3 mL at 20 weeks and 26.6 mL at 32 weeks.

Barreto et al.[22] obtained reference values for fetal heart volume at 20–34 weeks of pregnancy using XI VOCAL with 10 sequential planes. Cardiac volume was increased with gestational age with mean values of 3.09 mL at 20 weeks of gestation, 9.18 mL at 26 weeks, and 24.89 mL at 34 weeks.

EVALUATION OF FETAL CEREBELLAR VOLUME

The study by Chang et al.[4] was the first to measure fetal cerebellar volume. Reference values were determined in 231 singleton pregnancies by the multiplanar method. Cerebellar volume was strongly correlated with gestational age and fetal biometric parameters.

Araujo Júnior et al.[37] performed a prospective longitudinal study with 52 healthy pregnant women at 20–32 weeks of pregnancy, and fetal cerebellar volume was calculated using VOCAL with a rotation angle of 30°. There was a correlation between cerebellar volume with gestational age and biometric parameters. Furthermore, the equation for fetal cerebellar volume formulated by Chang et al.[4] in the Chinese population of Taiwan may not apply to the Brazilian population because of the marked ethnic differences between these groups.

The VOCAL was used to measure the volume of intracranial structures, including the thalamus, frontal lobe, and cerebellum. Overall, 39 FGR fetuses and 39 appropriate-for-gestational-age (AGA) fetuses were

JAYPEE BROTHERS

evaluated. Cerebellar volume was significantly smaller in FGR fetuses than in AGA fetuses (6.0 ± 2.1 vs 5.0 ± 1.7; p = 0.001).[38]

EVALUATION OF FETAL LUNG VOLUME

The lungs have been the most investigated fetal organ using volumetric analysis because of the clinical applicability of predicting pulmonary hypoplasia in fetuses with CDH and other conditions, including skeletal dysplasias and preterm premature rupture of membranes.

Britto et al.[39] conducted a longitudinal study with 61 pregnant women at 24–32 weeks of gestation and obtained reference values for fetal lung volume using 3D ultrasound. The volume of each lung was calculated using VOCAL with a rotation angle of 30°. The mean right lung volume ranged from 12.5 ± 0.7 cm^3 at gestational week 24 to 31.8 ± 1.8 cm^3 at week 32. The mean left lung volume ranged from 9.2 ± 0.9 cm^3 at 24 weeks of pregnancy to 22.0 ± 1.6 cm^3 at 32 weeks. There was a strong correlation between lung volume and gestational age and estimated fetal weight.

In fetuses with CDH, fetal lung volumes (observed or expected total lung volume) were more accurate in predicting mortality than lung area measurements using 2D ultrasound. The accuracy of measuring fetal lung volume and area is approximately 80% and 70%, respectively.[40,41] Fetuses with isolated CDH with observed or expected total lung volumes smaller than 0.35 have a higher risk of death than those with larger volumes. This result is relevant because fetal endoscopic tracheal occlusion can be performed in these fetuses, and this procedure is associated with increased postnatal survival.[42,43]

Volumetric analysis of the lungs may also predict hypoplasia in risk conditions other than CHD, including preterm premature rupture of membranes, skeletal malformations, hydrothorax, and bilateral renal dysplasia. Gerards et al.[44] evaluated 33 pregnancies with different degrees of risk, and lung volume was measured by the multiplanar method. Of the 33 pregnancies, 16 presented pulmonary hypoplasia on clinical or radiological examination or necropsy. Volumetric analysis of the lungs using 3D ultrasound was more accurate than 2D ultrasound and had sensitivity and specificity of 94% and 82%, respectively. Barros et al.[45] analyzed the prediction of pulmonary hypoplasia in fetuses with skeletal dysplasias at 20–32 weeks of pregnancy. Skeletal dysplasia was lethal in 18 fetuses (75%). Lung volume was obtained using VOCAL at a rotation angle of 30°, and 3D ultrasound showed a sensitivity of 83.3%, specificity of 100%, positive predictive value of 100%, and negative predictive value of 66.7%.

ASSESSMENT OF FETAL ADRENAL GLAND VOLUME

The study by Chang et al.[7] was the first to evaluate the volume of fetal adrenal glands using 3D ultrasound. The volume was measured in 119 healthy fetuses at 21–40 weeks of gestation using the multiplanar method. Fetal adrenal gland volume was highly correlated with estimated fetal weight and gestational age, and reference values were obtained at each analyzed gestational age.

Helfer et al.[46] obtained reference values for fetal adrenal gland size in 204 normal singleton pregnancies at 24–37 weeks of pregnancy using VOCAL at a rotation angle of 30°. The mean size ranged from 0.179 cm^3 at gestational week 24 to 0.592 cm^3 at week 37. Size was strongly correlated with gestational age and fetal biometric parameters and presented good inter- and intraobserver reproducibility.

Turan et al.[47] measured fetal adrenal gland volume using VOCAL, fetal zone volume using 2D ultrasound, and cervical volume using transvaginal ultrasound for predicting delivery within 7 days in 74 pregnant women at 21–34 weeks of gestation. Adrenal gland size measured using 3D ultrasound and fetal zone size measured using 2D ultrasound were superior to uterine cervix size in predicting preterm delivery. In a similar study, Ibrahim et al.[48] compared fetal adrenal gland size measured using VOCAL, fetal zone size using 3D ultrasound, cervical size using transvaginal ultrasound, and cervicovaginal fetal fibronectin for predicting delivery within 7 days in 75 women at 28–36 weeks of pregnancy. Adrenal gland size and fetal zone size had the highest accuracy with sensitivity and specificity of 92.6% and 95.8%, and 92.6% and 89.6%, respectively.

EVALUATION OF FETAL THYMUS VOLUME

The size of the fetal thymus by 3D ultrasound was obtained in 28/37 cases (77.7%) using VOCAL at gestational weeks 12–35. There was a good correlation between fetal thymic size and gestational age. In 12 cases, the size was measured using STIC to assess the variability

JAYPEE BROTHERS

of adrenal gland volume during systole and diastole, which was minimal.[49] Tonni et al.[50] measured thymus volume in 100 fetuses from 18 weeks to 23 weeks and 6 days. The thymus was identified in the three vessels and trachea view, and color Doppler was performed to identify the internal mammary arteries. The thymic volume was obtained by VOCAL at a rotation angle of 30°; the mean volume ranged from 1.25 cm^3 at gestational week 18 to 2.62 cm^3 at week 23. Olearo et al.[51] determined the thymic size by VOCAL in small for gestational age (SGA) fetuses, FGR fetuses, and controls from 20 weeks to 37 weeks and 6 days. The thymic volume or abdominal circumference ratio was significantly lower in SGA fetuses than in controls and was significantly lower in FGR fetuses with umbilical artery Doppler changes than in SGA and FGR fetuses with normal umbilical artery Doppler.

ASSESSMENT OF FETAL LIMB VOLUME

The first studies that measured fetal limb volume using 3D ultrasound were performed in the early 2000s using the multiplanar method.[52,53] Chang et al.[52] conducted a cross-sectional study with 202 pregnant women at 20–40 weeks of gestation to determine reference values for fetal arm volume by the multiplanar method. The mean arm volume ranged from 6.31 mL at gestational week 20 to 74.63 mL at week 40, and there was a good correlation between the arm volume and gestational age. In 2003, the same research group performed a cross-sectional study with 204 pregnant women at 20–40 weeks of pregnancy to identify reference values for fetal thigh volume by the multiplanar method. The mean thigh volume ranged from 8.99 mL at 20 weeks of gestation to 128.89 mL at 40 weeks with a good correlation between thigh volume and gestational age and fetal biometric parameters.[53]

Lee et al.[54] proposed the term "fractional limb volume," which corresponded to the 50% portion of the limb diaphysis that contains the largest amount of soft tissues and is therefore the most relevant for the evaluation of nutritional disorders, besides being more feasible than the multiplanar method because it excludes the epiphyses of fetal limbs **(Figs. 2.5A and B)**.

Fetal limb volume was also assessed using XI VOCAL. Cavalcante et al.[55] conducted a cross-sectional study with 425 normal pregnancies at 20–40 weeks of pregnancy and evaluated fetal arm volume using XI VOCAL with 10 plane sequences. The mean arm volume ranged from 4.45 cm^3 at 20 weeks of gestation to 59.95 cm^3 at 40 weeks and was strongly correlated with gestational age. Araujo Júnior et al.[56] performed a cross-sectional study involving 425 normal pregnancies at 20–40 weeks of pregnancy and measured fetal thigh volume using XI VOCAL with 10 plane sequences; the mean thigh volume ranged from 7.34 cm^3 at 20 weeks of gestation to 115.68 cm^3 at 40 weeks and was strongly correlated with gestational age.

Studies from the mid-1990s reported that fetal limb volume measurements obtained using the multiplanar method were more accurate than those obtained using 2D ultrasound in predicting birth weight.[32,33] Chang et al.[32] examined 100 pregnant women between 32 and 42 weeks of pregnancy and measured fetal limb volume 48 h before delivery; 2D ultrasound formulae were compared with

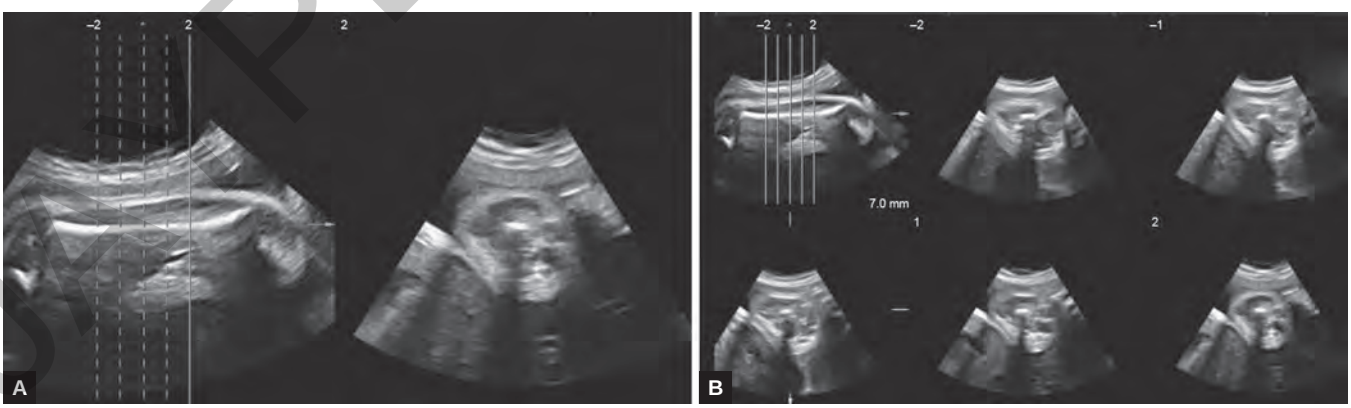

Figs. 2.5A and B: Fetal fractional thigh volume measurement. (A) The reference plane is placed in the mid-point of femur length and two equidistant right and left planes are formed; (B) After the delimitation of external surface of the fetal limb in the axial plane, the software provides the final volume.

JAYPEE BROTHERS

actual birth weights. The authors proposed a new equation [birth weight (g) = 1080.87350 + 22.44701 × thigh volume (mL)], and its error, percentage error, absolute error, and absolute percentage error were significantly lower than those of 2D ultrasound formulae. Liang et al.[33] analyzed 105 pregnant women at 32–43 weeks of gestation and measured fetal arm volume within 48 h before delivery. The 2D ultrasound results were compared with actual birth weights. The error, percentage error, and absolute error of the new equation [birth weight (g) = 1088.6 + 36.024 × arm volume (mL)] were significantly lower than those of 2D ultrasound equations.

Suboptimal fetal growth and nutrition may increase the risk of chronic diseases during adulthood. Catalano et al.[57] reported that measurements of body composition, lean body mass, and fat mass, may be an anthropometric refinement in fetal growth assessment. In addition, the fat mass of the newborn represents 14% of the total weight postpartum, and fetal subcutaneous fat and changes in lean body mass during pregnancy can be monitored by measuring the mean circumference of the arm and thigh. Fetal fat may be a more sensitive and specific marker of abnormal intrauterine growth compared with lean body mass index because of the increased rate of growth with advancing gestational age.

The diagnosis of fetal growth disorders cannot be based on cross-sectional studies because the fetuses present biological variations and distinct genetic growth potentials. For this reason, Lee et al.[34] proposed an individualized assessment of growth using fractional arm volume, arm circumference, and humeral diaphysis length as parameters. There was a linear increase in the three parameters up to 28 weeks of gestation, and accelerated deposition of subcutaneous tissue and muscle in fetuses with normal growth after this period. Therefore, fractional arm volume may detect early changes in soft tissues and serve as a good parameter for the early detection of fetal growth disorders.

CONCLUSION

Fetal organ volume measurements by 3D ultrasound is more reliable than 2D ultrasound, because of the irregular surface of fetal organs. Multiplanar, VOCAL, and XI VOCAL techniques are consistent and reproducible; however, multiplanar is more time-consuming. Fetal lung volume measurements show the main clinical applications, mainly in the prediction of pulmonary hypoplasia in cases of CDH. Fetal limb volume measurement shows applications in the prediction of birth weight and intrauterine status nutrition.

REFERENCES

1. Jeanty P, Romero R, Hobbins JC. Fetal limb volume: a new parameter to assess fetal growth and nutrition. J Ultrasound Med. 1985;4:273-82.
2. Riccabona M, Nelson TR, Pretorius DH, et al. Distance and volume measurement using three-dimensional ultrasonography. J Ultrasound Med. 1995;14:881-6.
3. Riccabona M, Nelson TR, Pretorius DH. Three-dimensional ultrasound: accuracy of distance and volume measurements. Ultrasound Obstet Gynecol. 1996;7:429-34.
4. Chang CH, Chang FM, Yu CH, et al. Assessment of fetal cerebellar volume using three-dimensional ultrasound. Ultrasound Med Biol. 2000;26:981-8.
5. Chang CH, Yu CH, Chang FM, et al. Volumetric assessment of normal fetal lungs using three-dimensional ultrasound. Ultrasound Med Biol. 2003;29:935-42.
6. Chang CH, Yu CH, Chang FM, et al. The assessment of fetal liver volume by three-dimensional. Ultrasound Med Biol. 2003;29:1123-9.
7. Chang CH, Yu CH, Chang FM, et al. Assessment of fetal adrenal gland volume using three-dimensional ultrasound. Ultrasound Med Biol. 2002;28:1383-7.
8. Peralta CF, Cavoretto P, Csapo B, et al. Lung and heart volumes by three-dimensional ultrasound in normal fetuses at 12-32 weeks' gestation. Ultrasound Obstet Gynecol. 2006;27:128-33.
9. Araujo Júnior E, Pires CR, Nardozza LM, et al. Correlation of fetal cerebellar volume with other fetal growth indices by three-dimensional ultrasound. J Matern fetal Neonatal Med. 2007;20:581-7.
10. Tedesco GD, Bussamra LC, Araujo Júnior E, et al. Reference range of fetal renal volume by three-dimensional ultrasonography using the VOCAL method. Fetal Diagn Ther. 2009;25:385-91.
11. You JH, Lv GR, Liu XL, et al. Reference ranges of fetal spleen biometric parameters and volume assessed by three-dimensional ultrasound and their applicability in spleen malformations. Prenat Diagn. 2014;34:1189-97.
12. Ruano R, Benachi A, Joubin L, et al. Three-dimensional ultrasonographic assessment of fetal lung volume as prognostic factor in isolated congenital diaphragmatic hernia. BJOG. 2004;111:423-9.
13. Ruano R, Aubry MC, Barthe B, et al. Three-dimensional ultrasonographic measurements of the fetal lungs for prediction of perinatal outcome in isolated congenital diaphragmatic hernia. J Obstet Gynaecol Res. 2009;35:1031-41.
14. Turan OM, Turan S, Buhimschi IA, et al. Comparative analysis of 2-D versus 3-D ultrasound estimation of the fetal adrenal gland volume and prediction of preterm birth. Am J Perinatol. 2012;29:673-80.

JAYPEE BROTHERS

15. Maged AM, Abdelmoneim A, Said W, et al. Measuring the rate of fetal urine production using three-dimensional ultrasound during normal pregnancy and pregnancy-associated diabetes. J Matern Fetal Neonatal Med. 2014;27:1790-4.
16. Molina FS, Faro C, Sotiriadis A, et al. Heart stroke volume and cardiac output by four-dimensional ultrasound in normal fetuses. Ultrasound Obstet Gynecol. 2008;32:181-7.
17. Simioni C, Nardozza LM, Araujo Júnior E, et al. Heart stroke volume, cardiac output, and ejection fraction in 265 normal fetuses in the second half of gestation assessed by 4D ultrasound using spatio-temporal image correlation. J Matern Fetal Neonatal Med. 2011;24:1159-67.
18. Albers MEWA, Buisman ETIA, Kahn RS, et al. Intra- and interobserver agreement for fetal cerebral measurements in 3D-ultrasonography. Hum Brain Mapp. 2018;39: 3277-84.
19. Araujo Júnior E, Nardozza LM, Rolo LC, et al. Reference range of embryo volume by 3-D sonography using the XI VOCAL method at 7 to 10 + 6 weeks of pregnancy. Am J Perinatol. 2010;27:501-5.
20. Araujo Júnior E, Nardozza LM, Rolo LC, et al. Assessment of yolk sac volume by 3D-sonography using the XI VOCAL method from 7 to 10 + 6 weeks of pregnancy. Arch Gynecol Obstet. 2011;283:1-4.
21. Nardozza LM, Rolo LC, Araujo Júnior E, et al. Comparison of gestational sac volume by 3D-sonography using planimetric, virtual organ computer-aided analysis and extended imaging virtual organ computer-aided analysis methods between 7 and 11 weeks of pregnancy. Acta Obstet Gynecol Scand. 2010;89:328-34.
22. Barreto EQ, Milani HJ, Araujo Júnior E, et al. Reliability and validity in vitro volume calculations by 3-dimensional ultrasonography using the multiplanar, virtual organ computer-aided analysis (VOCAL) and extended imaging VOCAL methods. J Ultrasound Med. 2010;29:767-74.
23. Barreto EQ, Milani HJ, Haratz KK, et al. Reference intervals for fetal heart volume from 3-dimensional sonography using the extended imaging virtual organ computer-aided analysis method at gestational ages of 20 to 34 weeks. J Ultrasound Med. 2012;31:673-8.
24. Haratz KK, Oliveira PS, Rolo LC, et al. Fetal cerebral ventricle volumetry: comparison between 3D ultrasound and magnetic resonance imaging in fetuses with ventriculomegaly. J Matern Fetal Neonatal Med. 2011;24: 1384-91.
25. Caetano AC, Zamarian AC, Araujo Júnior E, et al. Assessment of intracranial structure volumes in fetuses with growth restriction by 3-dimensional sonography using the extended imaging virtual organ computer-aided analysis method. J Ultrasound Med. 2015;34: 1397-405.
26. Nam KH, Cho A, Kwon JY, et al. Feasibility of measuring 3-dimensional renal parenchymal volume to predict postnatal renal function in near-term fetuses with congenital hydronephrosis: a preliminary study. J Ultrasound Med. 2012;31:955-62.
27. Raine-Fenning N, Jayaprakasan K, Clewes J, et al. SonoAVC: a novel method of automatic volume calculation. Ultrasound Obstet Gynecol. 2008;31:691-6.
28. Salama S, Arbo E, Lamazou F, et al. Reproducibility and reliability of automated volumetric measurement of single preovulatory follicles using SonoAVC. Fertil Steril. 2010; 93:2069-73.
29. Rizzo G, Capponi A, Pietrolucci ME, et al. Role of sonographic automatic volume calculation in measuring fetal cardiac ventricular volumes using 4-dimensional sonography: comparison with virtual organ computer-aided analysis. J Ultrasound Med. 2010;29:261-70.
30. Duin LK, Nijhuis JG, Scherjon SA, et al. Comparison of conventional versus three-dimensional ultrasound in fetal renal pelvis measurement and their potential prediction of neonatal uropathies. J Matern Fetal Neonatal Med. 2016;29:2494-9.
31. Duin LK, Willekes C, Vossen M, et al. Reproducibility of fetal renal pelvis volume assessed by three-dimensional ultrasonography with two different measurement techniques. J Clin Ultrasound. 2013;41:230-4.
32. Chang FM, Liang RI, Ko HC, et al. Three-dimensional ultrasound-assessed fetal thigh volumetry in predicting birth weight. Obstet Gynecol. 1997;90:331-9.
33. Liang RI, Chang FM, Yao BL, et al. Predicting birth weight by fetal upper arm volume with use of three-dimensional ultrasonography. Am J Obstet Gynecol. 1997;177:632-8.
34. Lee W, Deter RL, McNie B, et al. The fetal arm: individualized growth assessment in normal pregnancies. J Ultrasound Med. 2005;24:817-28.
35. Lee W, Balasubramaniam M, Deter RL, et al. Fractional limb volume—a soft tissue parameter of fetal body composition: validation, technical considerations and normal ranges during pregnancy. Ultrasound Obstet Gynecol. 2009;33: 427-40.
36. Chang FM, Hsu KF, Ko HC, et al. Fetal heart volume assessment by three-dimensional ultrasound. Ultrasound Obstet Gynecol. 1997;9:42-8.
37. Araujo Júnior E, Guimarães Filho HA, Pires CR, et al. Validation of fetal cerebellar volume by three-dimensional ultrasonography in Brazilian population. Arch Gynecol Obstet. 2007;275:5-11.
38. Benavides-Serralde A, Hernández-Andrade E, Fernández-Delgado J, et al. Three-dimensional sonographic calculation of the volume of intracranial structures in growth-restricted and appropriate-for-gestational age fetuses. Ultrasound Obstet Gynecol. 2009;33:530-7.
39. Werneck Britto IS, de Silva Bussamra LC, Araujo Júnior E, et al. Reference range of fetal lung volume by 3D-ultrasonography using the rotational method (VOCAL). J Perinatal Med. 2009;37:161-7.
40. Ruano R, Takashi E, da Silva MM, et al. Prediction and probability of neonatal outcome in isolated congenital diaphragmatic hernia using multiple ultrasound parameters. Ultrasound Obstet Gynecol. 2012;39:42-9.
41. Ruano R, Lazar DA, Cass DL, et al. Fetal lung volume and quantification of liver herniation by magnetic resonance

JAYPEE BROTHERS

imaging in isolated congenital diaphragmatic hernia. Ultrasound Obstet Gynecol. 2014;43:662-9.
42. Deprest J, Gratacos E, Nicolaides KH. Fetoscopic tracheal occlusion (FETO) for severe congenital diaphragmatic hernia: evolution of a technique and preliminary results. Ultrasound Obstet Gynecol. 2004;24:121-6.
43. Ruano R, Yoshisaki CT, da Silva MM, et al. A randomized controlled trial of fetal endoscopic tracheal occlusion versus postnatal management of severe isolated congenital diaphragmatic hernia. Ultrasound Obstet Gynecol. 2012; 39:20-7.
44. Gerards FA, Twisk JW, Bakker M, et al. Fetal lung volume: three-dimensional ultrasonography compared with magnetic resonance imaging. Ultrasound Obstet Gynecol. 2007;29:533-6.
45. Barros CA, Rezende Gde C, Araujo Júnior E, et al. Prediction of lethal pulmonary hypoplasia by means of fetal lung volume in skeletal dysplasias: a three-dimensional ultrasound assessment. J Matern Fetal Neonatal Med. 2016;29:1725-30.
46. Helfer TM, Rolo LC, Okasaki NA, et al. Reference ranges of fetal adrenal gland and fetal zone volumes between 24 and 37+6 weeks of gestation by three-dimensional ultrasound. J Matern Fetal Neonatal Med. 2017;30: 568-73.
47. Turan OM, Turan S, Funai EF, et al. Ultrasound measurement of fetal adrenal gland enlargement: an accurate predictor of preterm birth. Am J Obstet Gynecol. 2011;204:311.
48. Ibrahim MI, Sherif A, El-Kady M, et al. Can three-dimensional ultrasound measurement of fetal adrenal gland enlargement predict preterm birth? Arch Gynecol Obstet. 2015;292:569-78.
49. Re C, Bertucci E, Weissmann-Brenner A, et al. Fetal thymus volume estimation by virtual organ computer-aided analysis in normal pregnancies. J Ultrasound Med. 2015;34:847-52.
50. Tonni G, Rosignoli L, Cariati E, et al. Fetal thymus: visualization rate and volume by integrating 2D- and 3D-ultrasound during 2nd trimester echocardiography. J Matern Fetal Neonatal Med. 2016;29:2223-8.
51. Olearo E, Oberto M, Oggè G, et al. Thymic volume in healthy, small for gestational age and growth restricted fetuses. Prenat Diagn. 2012;32:662-7.
52. Chang CH, Yu CH, Chang FM, et al. Assessment of normal fetal upper arm volume by three-dimensional ultrasound. Ultrasound Med Biol. 2002;28:859-63.
53. Chang CH, Yu CH, Chang FM, et al. Three-dimensional ultrasound in the assessment of normal fetal thigh volume. Ultrasound Med Biol. 2003;29:361-6.
54. Lee W, Deter RL, Ebersole JD, et al. Birth weight prediction by three-dimensional ultrasonography: fractional limb volume. J Ultrasound Med. 2001;20:1283-92.
55. Cavalcante RO, Araujo Júnior E, Nardozza LM, et al. Nomogram of fetal upper arm volume by three-dimensional ultrasound using extended imaging virtual organ computer-aided analysis (XI VOCAL). J Perinat Med. 2011;39:717-24.
56. Araujo Júnior E, Cavalcante RO, Nardozza LM, et al. Fetal thigh volume by 3D sonography using XI VOCAL: reproducibility and reference range for Brazilian healthy fetuses between 20 and 40 weeks. Prenat Diagn. 2011;31:1234-40.
57. Catalano PM, Tyzbir ED, Allen SR, et al. Evaluation of fetal growth by estimation of neonatal body composition. Obstet Gynecol. 1992;79:46-50.

JAYPEE BROTHERS

for detailed information on obstetrics & gynecology books, visit our website **www.jaypeebrothers.com,** for detailed information on obstetrics & gynecology books, visit ou

Donald School Textbook

CURRENT STATUS OF CLINICAL USE OF *3D/4D* ULTRASOUND IN OBSTETRICS AND GYNECOLOGY

Three-dimensional (3D) ultrasound has become globally available since the First World Congress on 3D Ultrasound on September 5-6, 1997 in Mainz, Germany. Today this technique offers a broad spectrum of application options in prenatal and gynecologic diagnosis. It has become a valuable supplementary method to conventional 2D ultrasound and is used by skilled operators to clarify suspicious findings. The different visualization modes provide the operator with amazing 3D images that never can be achieved with 2D ultrasound. However, proper use of 3D ultrasound requires a learning curve, technical understanding, spatial perception and continuous training. This book will motivate doctors and sonographers to integrate this substantial technique as a useful tool in their daily routine.

Eberhard Merz MD PhD is Professor and Head, Center for Ultrasound and Prenatal Medicine, Frankfurt, Germany. He was appointed (1995) as the extraordinary Professor of Obstetrics and Gynecology, University of Mainz, Germany. Between 2000 and 2013, he was Professor and Director, Department of Obstetrics and Gynecology, Krankenhaus Nordwest (affiliated Teaching Hospital of Goethe, University of Frankfurt), Frankfurt/Main, Germany.

He is considered to be clinical pioneer of 3D ultrasound in obstetrics, gynecology, and breast diagnosis. He is an Author and Co-author of over 250 scientific papers in peer-reviewed literature and he has published several ultrasound books on Obstetrics and Gynecology. He is an Editor, the European Journal of Ultrasound and Co-editor, Donald School Journal of Ultrasound in Obstetrics and Gynecology. Since 2002, he served as the President, Fetal Medicine Foundation (FMF), Germany. Between 2006 and 2008, he was the President, German Society of Ultrasound in Medicine (DEGUM), and from 2008 to 2010, he was the Past President of the Society. He organized more than 25 national and international congresses. In 1997, he hosted the First World Congress on 3D Ultrasound in Obstetrics and Gynecology in Mainz, Germany.

He is School Director of Ian Donald Inter-University School of Medical Ultrasound, Vice President of the International Academy of Perinatal Medicine, and Visiting Professor of Dubrovnik International University. He has been awarded with the title "Honorary Professor" (2012) from the University of Buenos Aires. He is "Honorary Member" in several ultrasound societies and has received several awards.

Asim Kurjak MD PhD is the Professor, Obstetrics and Gynecology, Medical School Universities of Zagreb and Sarajevo, Croatia, and Professor Emeritus, University Sarajevo School of Science and Technology and Dubrovnik International University. He received his medical degree from Medical School University of Zagreb (1966). From 1971 to 1972, as a British scholar, he was a Research Assistant, Institute of Obstetrics and Gynecology, University of London. He became a Specialist in Obstetrics and Gynecology (1974) and he got his PhD degree (1977). He was awarded the position of a Professor (1980). From 1985 to 2002, he served as Head, Department of Obstetrics and Gynecology, Medical School University of Zagreb, Sveti Duh Hospital, Zagreb, Croatia.

He has published more than 500 papers in peer-reviewed literature. His papers have been cited more than 11,000 times in Google Scholar bases. He has authored, co-authored or co-edited 117 books.

He is a regular Fellow of World Academy of Art and Science, European Academy of Sciences and Arts, International Academy for Human Reproduction, Italian Academy of Science and Art of Reggio Puglia, and Academy of Medical Sciences of Catalonia. He is an Honorary Member of American Institute of Ultrasound in Medicine and Biology; and Foreign Member, Russian Academy of Medical Sciences. He is the President, International Academy of Perinatal Medicine and Founder & Director of Ian Donald Inter-University School of Medical Ultrasound, Zagreb, Croatia.

He received a doctorum honoris causa from the Universities in Banja Luka, Budapest, Barcelona, Bucharest, Athens, Montevideo, Tomsk, Buenos Aires, St Petersburg, Moscow, and Tirana.

Available at all medical bookstores
or buy online at www.jaypeebrothers.com



JAYPEE BROTHERS
Medical Publishers (P) Ltd.
www.jaypeebrothers.com

Join us on facebook.com/JaypeeMedicalPublishers

Shelving Recommendation
OBSTETRICS & GYNECOLOGY

