thers.com, for detailed information on radiology books, visit our website www.jaypeebrothers.com, for detailed information on radiology books

Celebrating 50 Years
Passion, Quality and Innovation in Healthcare Publishing

AIIMS-MAMC-PGI IMAGING SERIES



DIAGNOSTIC RADIOLOGY

Advances in Imaging Technology

Editors
Arun Kumar Gupta
Anju Garg
Manavjit Singh Sandhu

Associate Editors
Sanjay Sharma
Atin Kumar
Shivanand Gamanagatti

3rd Edition

JAYPEE

CONTENTS

SECTION 1

ADVANCES IN ULTRASOUND IMAGING

Chapter 1. Ultrasound Instrumentation: Practical Applications 3

Ujjwal Gorsi, Anmol Bhatia, Kushaljit Singh Sodhi, Akshay Kumar Saxena

- Parts of an Ultrasound Machine *3*
- Controls of Ultrasound Machine *3*
- Transducer *5*
- Frequency of Transducers *5*
- Modes of Scanning *6*

Chapter 2. Image Optimization in Ultrasound 19

Rashmi Dixit, Anju Garg, Alpana Manchanda, Anjali Prakash

- Grayscale Imaging *20*
- User Adjustable Parameters *20*
- Artifacts in B Mode Imaging *23*
- Spectral and Color Doppler Examination *31*
- Doppler Artifacts *36*
- Special Imaging Modes *39*

Chapter 3. Ultrasound Elastography: Principles and Application 44

Veenu Singla, Tulika Singh, Anindita Sinha

- Basic Physics *44*
- Different Elastography Methods *46*
- Elastography Applications *51*
- Other Applications *62*

SECTION 2

ADVANCES IN COMPUTED TOMOGRAPHY

Chapter 4. Computed Tomography Hardware including Dual Energy Computed Tomography: An Update 71

Smita Manchanda, Ashu Seith Bhalla, Priyanka Naranje

CT Hardware 71

- Basic Workflow of CT Scanner *71*
- Determinants of an Optimal Image *72*
- Advances in Hardware *74*
- Special CT Scanners *78*

Dual Energy CT 80

- Principle *80*
- Generations of DECT *83*

- Key Concepts in DECT *84*
- Processing of Data, Image Reconstruction and Image Display in DECT *86*
- Applications of DECT *88*
- Dose Considerations *96*
- Future Trends in DECT Imaging *97*

Chapter 5. Advanced Computed Tomography Applications and Software.....100

Mukesh Kumar Yadav, Priyanka Naranje, Ekta Dhamija

- Lung Nodule Evaluation Softwares *100*
- Lung Parenchyma Evaluation Softwares *101*
- Pulmonary Embolism Detection Softwares *102*
- CT Perfusion Advanced Softwares *103*
- Continuous Free-breathing Scans *103*
- Advanced CT Angiography Softwares *104*
- Advanced Cardiac Application Softwares *104*
- Computed Tomography Volumetry *107*
- Dentascan *108*
- Computed Tomography Cinematic Rendering *110*
- Fusion Imaging *111*
- Vertebral Labeling *113*
- Software for Oncological Imaging Interpretation *113*
- 3D Printing *114*
- Iterative Reconstruction *116*
- Computed Tomography Colonography *117*

SECTION 3

ADVANCES IN MAGNETIC RESONANCE IMAGING

Chapter 6. Magnetic Resonance Instrumentation and MRI Safety Issues: An Update 123

Anjali Prakash, Jyoti Kumar, Sapna Singh

- The Magnet Subsystem *124*
- Gradient Subsystem *130*
- Radio Frequency Subsystem *133*
- Computer Subsystem *138*
- Installation Footprint of MRI *139*
- Special Types of MRI Hardware and Applications *140*
- MR Safety *142*
- Medical Device and Implant Compatibility *146*
- MRI Safety Profile in Special Groups *148*
- MR Safety Guidelines and Regulations *149*
- MRI Emergencies *150*

Chapter 7. Image Optimization in Magnetic Resonance Imaging 154

Jyoti Kumar, Anjali Prakash, Rashmi Dixit, Gaurav Pradhan

- Signal-to-noise Ratio *154*
- Contrast-to-noise Ratio *156*
- Spatial Resolution *158*
- Scan Time *158*
- Artefacts *160*
- 3T Imaging: Advantages vs Limitations *173*

Chapter 8. Diffusion-weighted Magnetic Resonance Imaging 175
Devasenathipathy Kandasamy, Raju Sharma

- Basic Principle *175*
- B Value *176*
- ADC and Exponential Image *177*
- DWI Sequences and Optimization *177*
- Artifacts and Pitfalls *179*
- Advanced DWI Techniques *180*
- Clinical Applications of DWI *182*

Chapter 9. Perfusion MRI 195
Sameer Vyas, Pankaj Gupta, Paramjeet Singh, Niranjan Khandelwal

- Dynamic Contrast-enhanced Magnetic Resonance Imaging *207*
- Non-neurology Applications of DCE-MRI *207*

Chapter 10. Magnetic Resonance Angiography 219
Ajay Kumar, Sameer Vyas, Sreedhara B Chaluvashetty, Naveen Kalra

- History and Introduction *219*
- Flow Phenomena and Phase Effects in MRA *220*
- Flow-related Enhancement Dependent Noncontrast MRA Techniques *222*
- Phase Dependent Noncontrast MRA Techniques *226*
- Flow Independent Noncontrast MRA Techniques *230*
- Applications of MRA *234*
- Future Perspectives *237*

Chapter 11. Magnetic Resonance Imaging Pulse Sequences 242
Vikas Bhatia, Manphool Singhal, Mahesh Prakash

- Basic Terminologies *242*
- Sequence Types *243*
- Steady State Sequences *246*
- Fast Gradient Echo *249*
- MR Elastography *254*

SECTION 4

ADVANCES IN RADIOGRAPHY AND INTERVENTIONAL RADIOLOGY

Chapter 12. Digital Radiography: An Update 259
Alpana Manchanda, Rashmi Dixit, Sapna Singh, Radhika Batra

- Evolution of Digital Radiography *259*
- Physics Behind Digital Radiography *259*
- Principle of Digital Radiography *260*
- Digital Radiography Systems *260*
- Computed Radiography *261*
- Digital Radiography *265*
- Image Processing *268*
- Aspects of Image Quality *270*
- Radiation Exposure *273*
- Exposure Indicator for Digital Radiography *273*
- Digital Radiographic Artifacts *273*

Chapter 13. Digital Mammography 279

Smriti Hari, Surabhi Vyas, Chandrashekhara SH

- Digital Mammography *279*
- Basic Physics of Digital Mammography *279*
- Applications of Digital Mammography *283*

Chapter 14. Fluoroscopy and Digital Subtraction Angiography 287

Deep Narayan Srivastava, Kumble S Madhusudhan

- Overview *287*
- Fluoroscopy *287*
- Digital Subtraction Angiography *296*

Chapter 15. Tools and Drugs in Interventional Radiology 310

Atin Kumar, Chandan J Das

- Puncture Needles *310*
- Dilators *311*
- Sheaths *312*
- Catheters *312*
- Guidewire *316*
- FNAC and Biopsy Needle *317*
- Stent *317*
- Embolizing Agents *320*
- Drugs in Interventional Radiology *322*

SECTION 5

UPDATE IN CONTRAST MEDIA

Chapter 16. Magnetic Resonance Contrast Media 329

Anju Garg, Radhika Batra, Alpana Manchanda

- Basic Principles of MR Contrast Agents *329*
- Classification of MR Contrast Agents *330*
- Gadolinium-based Contrast Agents *331*
- Manganese-based Contrast Agents *339*
- Iron Oxide-based Contrast Agents *339*
- Oral Contrast Agents *340*
- Ongoing Research and Future Trends *342*

Chapter 17. Ultrasound Contrast Agents 345

Shashi B Paul, Manisha Jana

- Evolution of UCAs *345*
- Technique of CEUS *347*
- Safety of UCAs *347*
- Diagnostic Applications of UCA *348*
- Hepatic Applications *348*
- Non-hepatic Applications *360*
- Future Directions *364*

Chapter 18. Iodinated Contrast Media: An Update (To Include Reactions and Management) 373
Gaurav Pradhan, Swati Gupta, Jyoti Kumar, Anju Garg

- Desirable Properties of an Ideal Contrast Agent *373*
- History of Development of Iodinated Contrast Media *373*
- Basic Chemistry of ICM *374*
- Types of ICM *374*
- ICM Pharmacokinetics *375*
- Dosage of Iodinated Contrast Media Administration *376*
- Adverse Reactions *376*
- Acute Allergic Like Reaction *378*
- Management *379*
- Acute Physiologic 379
- Postcontrast Acute Kidney Injury *380*
- Safe Injection *382*
- Air Embolism *382*
- Extravasation *382*
- Delayed Adverse Reactions to Contrast Media *382*
- Contrast Media Warming *383*
- Contrast Administration in Patients on Metformin *383*
- Special Considerations and Risk Factors *383*
- Recommendations for the Departments Performing Contrast-related Investigations *384*
- Future Directions *385*

SECTION 6

MISCELLANEOUS

Chapter 19. Radiology Information System and Picture Archiving and Communication System 389
Devasenathipathy Kandasamy, Shivanand Gamanagatti, Arun Kumar Gupta

- Industry Standards *389*
- Radiology Information System *390*
- Picture Archiving and Communication System *391*

Chapter 20. Evidence-based Radiology and a Primer on Biostatistics 395
Sanjay Sharma, Ankur Goyal, Manisha Jana

- Background *395*
- Biostatistics Primer *402*

Chapter 21. Radiation Hazards and Radiation Units 407
Pratik Kumar, Anil Kumar Pandey

- The Biological Effects of Radiation *407*

Damage to DNA by the Radiation 408

- The Effect of Radiation *408*

Chapter 22. Radiation Protection 423
Sapna Singh, Gaurav Pradhan, Swati Gupta

- Historical Perspective *423*
- Regulatory Bodies for Radiation Protection *423*

- Protection Against Radiation Hazard *425*
- Cardinal Principles of Radiation Protection *425*
- Radiation Protection in Interventional Radiology *429*
- Safety of Radiographic Imaging During Pregnancy *430*
- Personnel Dosimetry *431*
- Computed Tomography (Radiation Exposure and Dose Modulations) *433*
- Factors Affecting Radiation Dose and Quality *434*
- Techniques for Controlling Radiation Dose at CT *436*
- Key Features of Pediatric CT Protocols *436*
- Steps to Ensure Minimum CT Radiation *436*

Chapter 23. Planning Modern Imaging Department with Regulatory Requirements in Radiology Practice.....439

Ajay Gulati, Nidhi Prabhakar, Uma Debi

- Planning and Organization *439*
- Divisions of the Radiology Department *440*
- Location *440*
- Layout *440*
- Regulatory Requirements *441*
- Equipments *442*
- Mammography *445*
- Dual-energy X-ray Absorptiometry *445*
- Computed Tomography *446*
- Ultrasound *447*
- Magnetic Resonance Imaging *448*
- Digital Subtraction Angiography *448*
- Nuclear Imaging Systems *450*
- Picture Archiving and Communication Systems *451*
- Teleradiology *452*
- Pre-conception and Pre-natal Diagnostic Technique (PC-PNDT) Act *452*
- Registration *453*
- Requirements at the Ultrasound Center *453*
- Record Keeping *454*

Chapter 24. Recent Advances in PET/CT and PET/MR 456

Rakesh Kumar, Madhavi Tripathi

- Positron Emission Tomography/Computed Tomography *456*
- Recent Advances in the Clinical Applications of PET/CT *457*
- Positron Emission Tomography/Magnetic Resonance *468*
- Clinical Applications of PET/MR *470*

Chapter 25. Ethical and Legal Issues in Radiology 480

Chirag Kamal Ahuja, Mandeep Kang, Manavjit Singh Sandhu

- Ethical Issues *481*
- Legal Issues *483*
- Laws/Legal Acts Applicable to Medicine *485*
- Teleradiology: Who is Responsible? *488*

Contents

Chapter 26. Basics of Radiomics, Texture Analysis and Radiogenomics 490
Chandan J Das, Devasenathipathy Kandasamy, Ankur Goyal, Raju Sharma
- Background and Workflow in Radiomics *490*
- Clinical Applications of Radiomics and Texture Analysis *492*
- Challenges *494*

Chapter 27. Artificial Intelligence in Radiology 497
Chirag Kamal Ahuja, Kushaljit Singh Sodhi, Mandeep Garg, Mandeep Kang
- Artificial Intelligence and Radiology *498*
- Artificial Intelligence: Characteristics and Importance *498*
- Applications of AI in Imaging *501*
- Challenges/Ethical Issues of AI in Medicine and Radiology *503*
- Artificial Intelligence: Existential Dilemma for a Radiologist? *504*

Chapter 28. Structured Reporting in Radiology 507
Ashu Seith Bhalla, Smita Manchanda, Manisha Jana
- Steps of Radiology Reporting *507*
- Types of Reports *508*
- Components of a Radiology Report *508*
- Components/Criteria of a Good Structured Report *508*
- Errors in Radiology Reports *508*
- Structured versus Prose Reports *509*
- Steps to Implementing Structured Reporting Formats *510*
- Common Structured Reporting Formats in Use/Available Resources *511*

Index 515

JAYPEE BROTHERS

CHAPTER 2

Image Optimization in Ultrasound

Rashmi Dixit, Anju Garg, Alpana Manchanda, Anjali Prakash

Ultrasound imaging with its inherent flexibility, low cost and real time display plays a vital role in diagnostics. Image formation in ultrasound depends on the physics behind ultrasound pulse formation, transmission and interaction with tissues. Acoustic energy undergoes essentially three different types of interactions in the tissues-reflection (specular and diffuse), refraction, and attenuation.

Diagnostic applications of ultrasound are based on detection and display of acoustic energy reflected from interfaces within the body. The amplitude of the reflected energy is used to generate ultrasound images while frequency shifts in backscattered ultrasound provide information relating to moving targets such as blood. Real time, grayscale, B-mode display, in which variations in display intensity or brightness are used to show signals of differing amplitude, is the mainstay of ultrasound imaging. Real time ultrasound produces an impression of motion by generating a series of 2D images several times per second or frames per second.

The *quality of an ultrasound image*[1-3] depends on its spatial resolution, temporal resolution, contrast resolution and freedom from certain artifacts. **Spatial resolution** has three components *axial, lateral and elevational or azimuthal resolution. Axial resolution* is the resolution along the axis of the ultrasound beam. It is also called longitudinal or depth resolution and depends on spatial pulse length, which is the product of wavelength and number of pulses, being equal to half the spatial pulse length. As frequency increases the pulse length decreases permitting resolution of smaller details. Hence, axial resolution improves with increasing frequency (which reduces wavelength). Best axial resolution at a frequency of 3.5 MHz is approximately 0.5–1.0 mm. It does not change significantly with depth. *Lateral resolution* refers to the ability to differentiate two structures lying side by side. The width of the main beam determines the lateral resolution of the ultrasound image as objects can be resolved separately only if the beam is thinner than the distance between them. Hence in modern systems transducers are focused to reduce the beam width. Focal zone is the area where the beam is 3–4 wavelengths wide and the area where lateral resolution is highest, deteriorating rapidly beyond it. The best lateral resolution equals the minimum beam width. Focusing in the elevation plane is also possible with current technology. Importantly ultrasound resolution depends not only on the frequency but also the transducer design.

Temporal resolution refers to the ability to locate the position of a particular moving structure in time. This increases as the frame rate increases. **Contrast resolution** is the ability to show very subtle difference in echo strength. Contrast resolution improves when a system can recognize and store a wide range of echo amplitudes.

New technical developments and remarkable improvement in image quality have marked several new applications for diagnostic ultrasound. The rise of state

JAYPEE BROTHERS

of the art, expensive equipment has greatly eased the sonologist's job. Nonetheless, it does not by itself guarantee high quality ultrasound images. Variables, many of which are under direct user control must be managed to guarantee the production of quality studies. An accurate ultrasound diagnosis relies heavily on the experience and skill of the examiner and requires adjustment of the equipment settings from patient to patient and organ to organ. Hence, image optimization is an essential prerequisite for diagnostic ultrasound imaging.

GRAYSCALE IMAGING

Basic Guidelines[2-5]

The patient should be positioned in such a way that the area of interest can be easily accessed and the patient is comfortable during the examination. Changing the patient position to better elucidate pathology is also important, e.g. an extended neck for thyroid examination, left lateral decubitus position for gallbladder calculi, etc.

A good acoustic window improves scanning accuracy and image quality. Solid organs like the liver or spleen or fluid filled structures, which do not attenuate the sound beam, e.g. full bladder or fluid filled stomach provide a good acoustic window to see deeper structures. Use of adequate amount of coupling gel is essential as air has high acoustic impedance.

USER ADJUSTABLE PARAMETERS

Factory Presets

The more complicated machine settings are saved as presets. Presets provide a useful starting point, however, these are settings which are optimized for patients of average body habitus and further optimization of the image by manual adjustments is invariably required in order to increase diagnostic confidence and avoid artifacts. A single touch image optimization is also available on some systems however this only resets the parameters to the chosen preset.

Transducer Selection

Choosing the appropriate transducer both in terms of frequency as well as footprint is extremely important for a good examination. Higher frequencies provide a better resolution but are attenuated much more as attenuation is proportional to the fourth power of frequency. Thus a trade off has to be made between the need for penetration and resolution.

While performing superficial scans as for the thyroid, musculoskeletal system or testicular examination a linear transducer with a high frequency (7–10 MHz or even 15–17 MHz) is suitable but for deeper structures a lower frequency such as 2.5–3 MHz is used. Currently many multifrequency and broad band width transducers are available. For inter- costal scanning or scanning the neonatal brain, transducers with a smaller footprint which fit into the small acoustic window are appropriate **(Figs. 1A and B)**. Sector transducers are thus useful to evaluate deeper structures through a small acoustic window, e.g. echocardiography. In sector scanning, however, resolution becomes poorer with increasing depth as the same echo lines are spread out over a wider area deeper in the tissue.

Overall Gain

Overall gain amplifies all the returning echoes/signals uniformly. An excessively high gain can result in a washed out image and can obscure many details.

Time Gain Compensation

Time gain compensation (TGC) is also referred to as distance gain compensation (DGC) or spatial time compensation (STC). Signals that arrive later, i.e. from greater depths, are amplified more than earlier signals to compensate for the attenuating effect of tissues. TGC controls permit the user to selectively amplify the signals from deeper structures or suppress signals from superficial tissues so that a smooth grayscale picture can be obtained **(Figs. 2A and B)**. Although most newer machines provide for some automatic TGC, manual adjustment by the user is one of the most important factors affecting image quality.

Depth Setting

This parameter selects the depth of the imaging field. If too much depth is selected the image will be small and the area of interest difficult to visualize, measurements may also be inaccurate. On the other hand, if the depth setting is too shallow the complete region or organ is not visualized and pathology at a deeper levels may be completely missed **(Figs. 3A and B)**. Practically, depth can be adjusted by starting at a higher depth, subsequently

JAYPEE BROTHERS

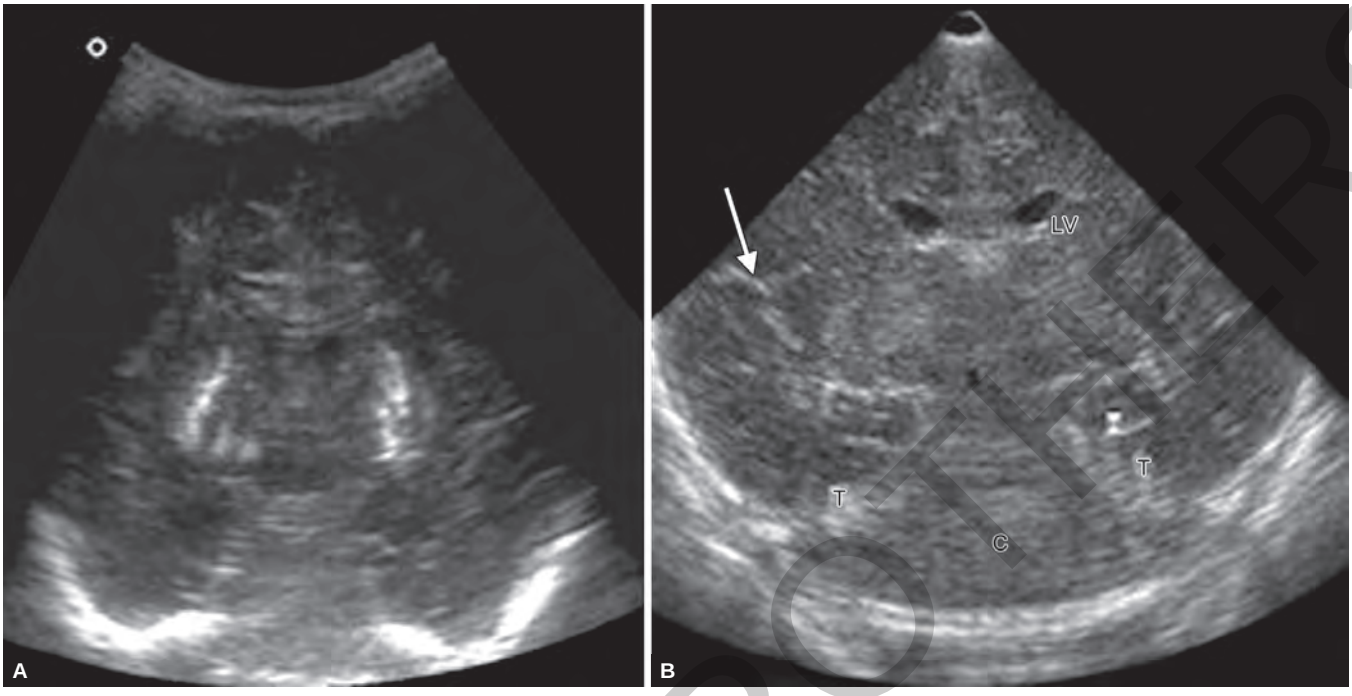

Figs. 1A and B: Cranial sonogram performed with a curvilinear array abdominal probe (A) shows shadowing obscuring the cerebral convexities on both sides due to mismatch between the large transducer footprint and acoustic window. The second scan (B) performed with a small foot print transducer shows good visualization of cerebral convexities. Arrow – sylvian fissure, T-tentorium, C-cerebellum.

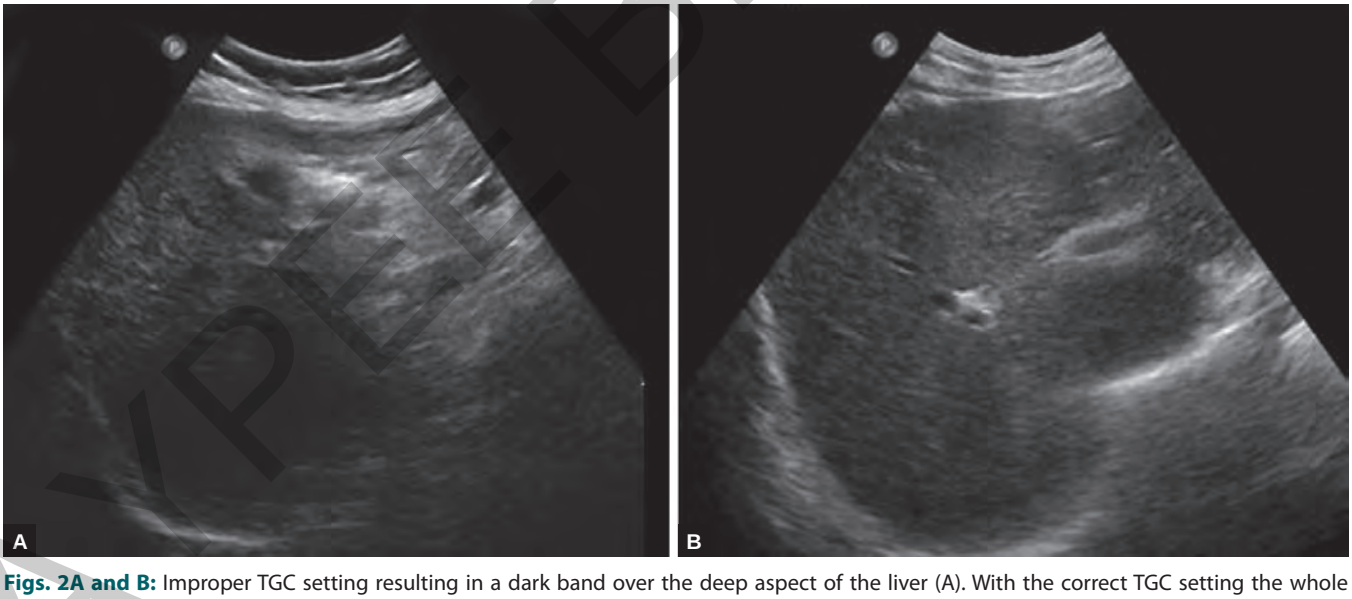

Figs. 2A and B: Improper TGC setting resulting in a dark band over the deep aspect of the liver (A). With the correct TGC setting the whole liver shows a uniform echopattern (B).

depths should be decreased so that the area of interest in at about three-fourths the depth of the screen. A small area should be available behind the area of interest to detect useful artifacts.

Focal Zone Setting

To improve resolution diagnostic transducers are focused electronically. As already discussed, resolution

JAYPEE BROTHERS

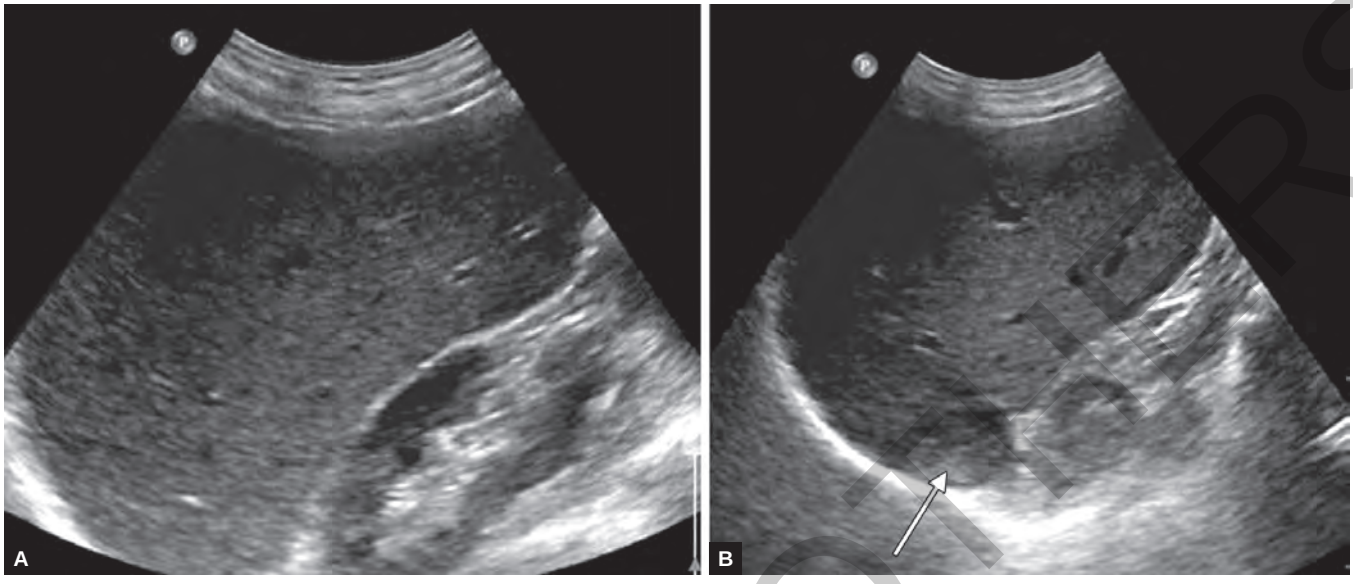

Figs. 3A and B: Improper depth setting in (A) results in non-visualization of posterior most portion of liver with consequently missed metastatic focus, which is easily appreciated (arrow) with proper depth setting in (B).

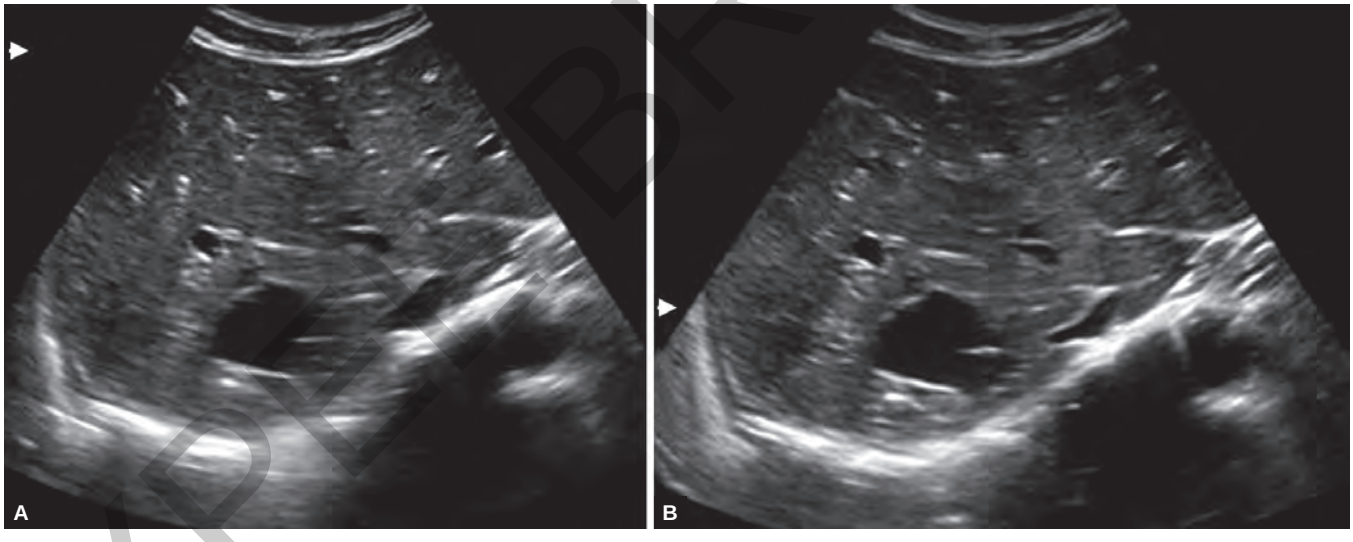

Figs. 4A and B: Effect of focal zone: In (A) the focal zone (denoted by the small arrowhead) is placed anteriorly resulting in a blurred appearance of the posteriorly placed hepatic cyst and diaphragm. These become more sharply defined with proper focal zone positioning over the area of interest (B).

of ultrasound is best in the focal zone. The focal zone should thus be set over the area of interest. A significant difference in image resolution depending on the focal zone setting is the hallmark of a well-focused beam **(Figs. 4A and B)**. Modern scanners allow the use of multiple focal zones however this may result in decreased frame rate and hence decreased temporal resolution.

Zoom

Zoom is used to magnify the area of interest. Zoom is extremely useful for accurate measurement of small structures as the CBD.

There are two types of zoom available. *Read zoom* is used to enlarge a frozen image whereas *write zoom*

JAYPEE BROTHERS

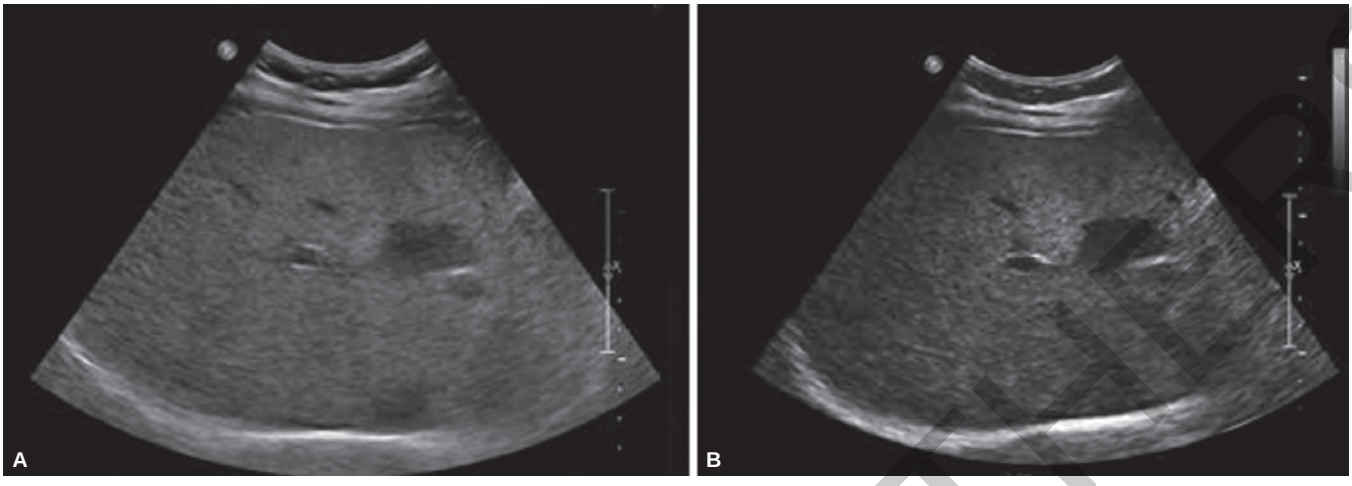

Figs. 5A and B: Images of the liver displayed at dynamic ranges of 70 and 36 dB are shown. The wide dynamic range (A) permits appreciation of subtle differences in echointensity between the diffusely fatty liver and a focal area of sparing. The narrow range (B) increases the conspicuity of larger echo differences with the area of focal sparing appearing darker and the diaphragm brighter than the wide dynamic range image.

is used to enlarge the display magnification, during scanning.

In *read zoom*, gray level values are read only from a small part of the computer memory and the pixels are enlarged while displaying, something like a magnifying glass. If the magnification factor is too large image matrix becomes obvious and renders the image grainy.

In *write zoom*, use is made of the fact that the echo samples are received fast enough for several samples to occur in each pixel. In this situation, the image scale can be enlarged to a point where only one sample occurs in each pixel. Each pixel, whose size remains unchanged, displays less tissue. Thus, there is magnification without loss of definition. Hence one should always try to use the *write zoom.* If the scale is increased further there is a larger space between scan lines so that further interpolation and smoothening may be required to maintain an acceptable image. More real scan lines can be introduced using sophisticated signal processing so that definition is improved. One such option is referred to as high density (HD) zoom. This magnifies the region of interest while increasing line density by redistributing and reformatting all scan lines for the defined region of interest.

Dynamic Range

Dynamic range is the ratio of the highest to the lowest amplitudes that can be displayed, expressed in decibels. Dynamic range adjustment changes the contrast. The widest dynamic range that permits accurate differentiation of minor differences in echo intensity is preferred for the most applications. The narrower ranges increase the conspicuity of larger echo differences **(Figs. 5A and B)**.

ARTIFACTS IN B MODE IMAGING[3,5-7]

Artifact is a term used to describe any unwanted information generated in the process of image formation. Most artifacts interfere with image interpretation while some artifacts which contain diagnostic information are referred to as friendly artifacts.

A number of artifacts may occur during scanning. Understanding how and why a particular artifact occurs is imperative to eliminate it and avoid errors in diagnosis **(Table 1)**.

The ultrasound machine depends on physical assumptions to determine the location and intensity of each received echo. The assumptions are:

- The echo detected arose from within the main US beam
- It has returned to the transducer after a single reflection
- The depth on an object is related only to the time taken by an ultrasound pulse to return as an echo to the transducer.
- Sound travels at a constant speed and in a straight line in human tissue
- The acoustic energy in an ultrasound field is uniformly attenuated.

While examining patients using ultrasound, these assumptions are often not maintained resulting in artifacts.

JAYPEE BROTHERS

Table 1: Common ultrasound artifacts

Artifact	*Cause*	*Appearance*	*Correction technique/Reduction*
Beam width	Poor lateral resolution due to wide beam	Lateral blurring of tiny objects, aberrant echoes from adjacent highly echogenic structures	Focal Zone (FZ) placement
Section thickness	Poor elevational resolution (beam thickness > section thickness)	Debris/internal echoes in anechoic structures, vessels	Positioning the area of interest in FZ 1.5D/2D transducer arrays allowing focusing in elevational plane
Secondary lobe Side lobes Grating lobes	Strong echoes from off axis primary beam are reflected back to transducer	Mimics debris in anechoic structures	Using tissue harmonics, decreasing gain, changing angle of insonation using multiple windows
Speckle noise	Acoustic interference causing granular appearance	Gives tissues their characteristic image texture however degrades spatial and contrast resolution	Can be reduced by SRI, SCI, THI
Reverberation	Reflections between highly reflective interfaces in parallel	Multiple bright parallel lines, mimic debris in cystic structures	Use of THI, decreasing gain, using a different window/angle of insonation
Comet tail	Reverberations from very closely placed highly reflective interfaces	Inverted echogenic triangle seen posterior to adenomyomatosis, colloid nodules, calcifications, foreign bodies	Using SCI
Ring down	Resonant vibrations in tiny air bubbles	Streak or parallel bands deep to a focus of gas Dirty shadowing	Using SCI
Mirror image	Reflections off a strong specular reflector produce a mirror image of an object	Mimics consolidated lung above diaphragm , pseudothickened bowel wall	May be reduced by decreasing gain, using a different window/ angle of insonation
Speed displacement artifact	Variability of speed of sound among different tissues	Inaccurate locations and measurements of structures	Some modern US units permit manual speed of sound correction
Increased through transmission	Overcorrection of sound attenuation posterior to low attenuation structures	Increased brightness of echoes distal to a low-attenuating structure	Using SCI
Acoustic shadowing	Undercorrection of sound attenuation posterior to high attenuation structures	Decrease in echo strength distal to a highly attenuating or reflective object	Reduction with inappropriate FZ placement, and SCI

SRI: speckle reduction imaging techniques; SCI: spatial compound imaging; THI: tissue harmonic imaging.

Artifacts due to Physical Characteristics of Ultrasound Beam

Beam Width Artifact

The real ultrasound beam is not of a consistently narrow, laser-like configuration which would be ideal for image resolution. A typical focused beam is of the same width as the transducer when it exits the transducer, gradually narrowing to a focus after which it spreads out rapidly in the far field, where it may be wider than the transducer width. A highly reflective object situated within the widened beam beyond the transducer edges may produce detectable echoes. The system assumes that these echoes arose from within the imaging plane and displays them accordingly **(Fig. 6)**. The more intense the reflection the further off axis its echoes will be received.

During scanning this artifact is recognized when a structure which should be anechoic has peripheral echoes. It is generally most obvious when a bony or gaseous object lies adjacent to a fluid collection **(Fig. 7)**.

This also means that a strong reflector will continue to give detectable echoes further from the central axis than a weak reflector. Hence, the resolution is better for weak reflectors than strong reflectors which tend to blur laterally and are therefore seen as cigar shaped smears or streaks so that the width is exaggerated. It also results in a tendency to fill in small anechoic regions, such as ducts producing slightly reduced measurements.

JAYPEE BROTHERS

This can be rectified and image quality improved by adjusting the focal zone to the area of interest and placing the transducer over the center of the object of interest.

Slice Thickness Artifact

Beam width artifacts also occur in the orthogonal plane, i.e. in the slice thickness or elevation plane. With circular transducers, either simple disc or annular array types, the beam is symmetrical in all planes but for linear and phased array transducers the beam is wider in the orthogonal plane resulting in information from adjacent planes being depicted in the image.

The beam width may be wider than a fluid collection. Some of the sound energy may hit structures outside the plane of intersection and may be projected into it. This can simulate a layer of sludge causing a simple fluid collection to appear complicated **(Fig. 8)**. Since the reflector which has caused the artifact is not visualized in the image it is more difficult to recognize it as artifactual than the same artifact occurring in the scanned plane. However, with the latest 2 D and X-matrix transducers it is possible to focus the beam in the elevation plane as well, providing a uniformly focused ultrasound beam.

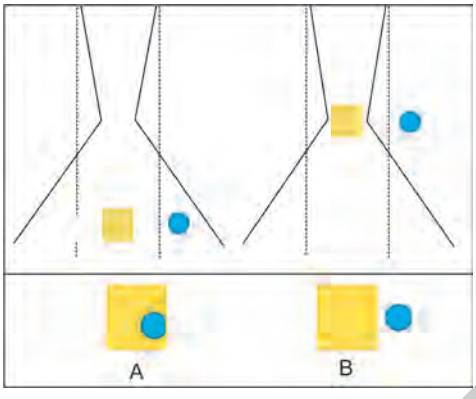

Fig. 6: Mechanism of beam width artifact. Dotted lines represent the imaging plane. Echoes from the circle are assumed to arise from within the imaging plane in A and displayed within the square. This is rectified with proper focal zone setting in B.

Side Lobe and Grating Lobe Artifacts

These are low energy beams directed at angles away from the central line due to vibration of the edges of the transducer. The latter occur only in array transducers **(Fig. 9)**.

Highly reflective objects located in the path of these low intensity off axis beams may generate echoes detectable by the transducer. These are displayed as having originated from within the main beam usually within an anechoic structure. They often have a convex shape and are also referred to as *Chinese hat artifacts*.

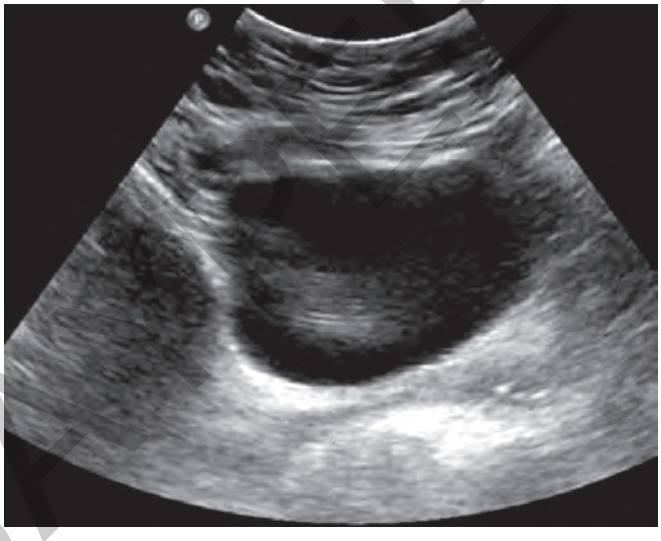

Fig. 7: Beam width artifact: strong echoes arising from a gas filled bowel loop in the pelvis smear across the bladder.

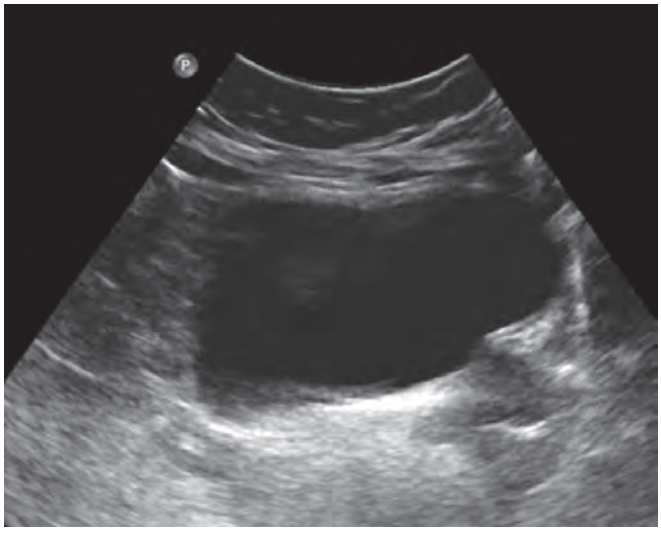

Fig. 8: Low level echoes are seen in the bladder not from debris but due to slice thickness artifact arising from gas present in the bowel in the adjacent planes.

JAYPEE BROTHERS

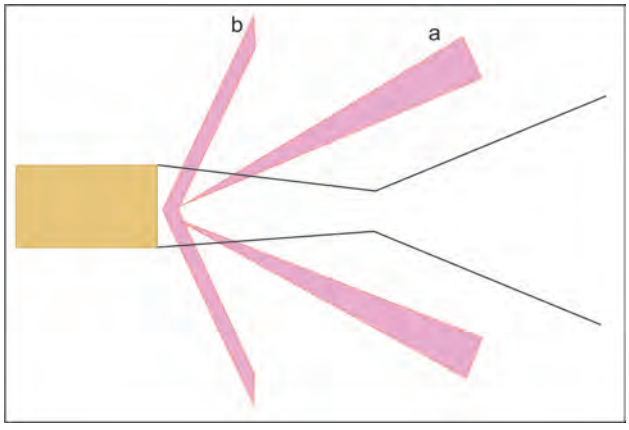

Fig. 9: Off axis beams: side lobes (a) and grating lobes (b).

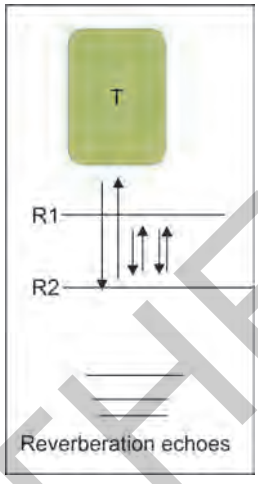

Fig. 10: Mechanism of reverberation artifact: T transducer, R1 R2 reflecting surfaces.

Artifacts Associated with Multiple Echoes

Reverberation Bands

A very important assumption in pulse echo ultrasound imaging is that an echo returns to the transducer after a single reflection and that the depth is related to the time taken for the echo to return. If two highly reflective surfaces lie parallel to each other, the echoes generated may be reflected back and forth before they reach the transducer. The first echo returning after a single reflection is displayed in its proper position. The later echoes returning after multiple reflections are presumed to be arising deeper to the original structure (due to the delay) and are displayed as equally spaced linear reflections in a striped pattern called *reverberation artifact* **(Figs. 10 and 11)**. The deeper echoes are weaker than the superficial ones due to loss of sound energy due to attenuation by intervening tissues and incomplete reflection so that the bands become narrower and less intense with depth.

The distance between the reverberation bands depends on the gap between the reflectors, if the reflectors are very closely placed the sequential echoes may be so close that individual bands cannot be seen. The resulting artifact is triangular with a tapered shape resembling a comet with its bright tail hence referred to as a *comet tail artifact*. This artifact is commonly seen deep to calcifications, surgical clips, IUCD and in colloid cysts of goiter. The artifact is also diagnostic of adenomyosis of gallbladder. It is presumed that the many small fluid spaces like the Aschoff-Rokitansky sinuses in gallbladder wall in this pathology cause repeated reflections from the walls of the fluid spaces producing the comet tail artifact **(Fig. 12)**.

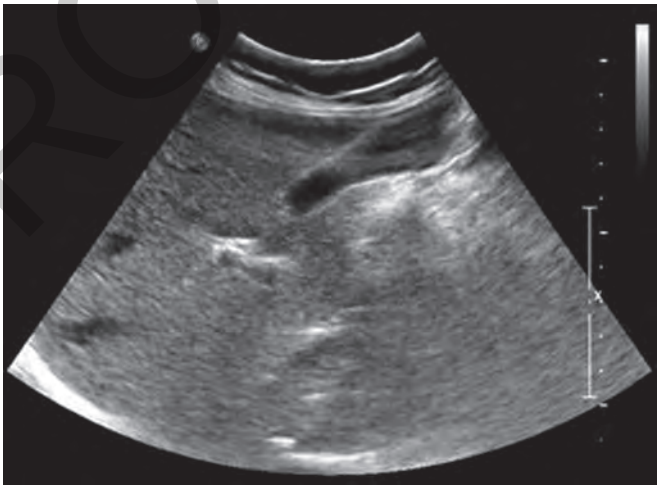

Fig. 11: Multiple equally spaced lines are seen within the gallbladder due to multiple reflections originating in the anterior abdominal wall.

Another artifact, the *ring down* artifact was previously thought to be a variant of comet tail artifact because of the similar appearance of the two, however, this has a separate mechanism. The ultrasound energy is believed to cause vibrations in fluid trapped between air bubbles. These vibrations produce a continuous sound wave that is transmitted back to the receiver. This is seen as a line or series of parallel bands extending posterior to a gas collection. Ring-down artifact contributes to the occurrence of "dirty shadowing" **(Fig. 13)**. This artifact may suggest underlying pathology, such as pneumoperitoneum, portal venous gas and emphysematous (gas-

JAYPEE BROTHERS

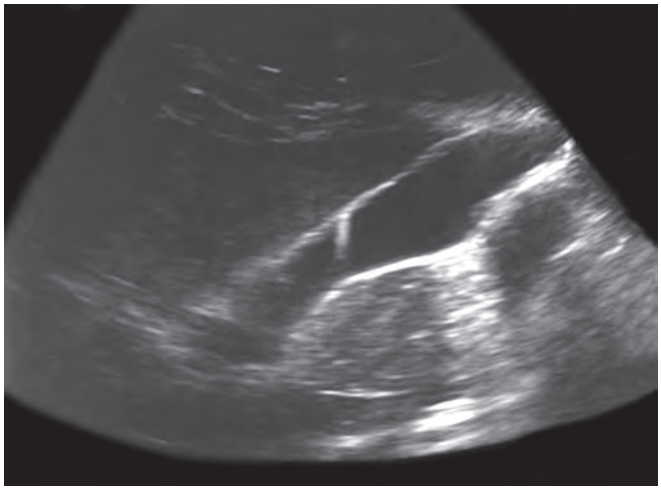

Fig. 12: Adenomyosis of the anterior wall of gallbladder producing a typical comet tail artifact.

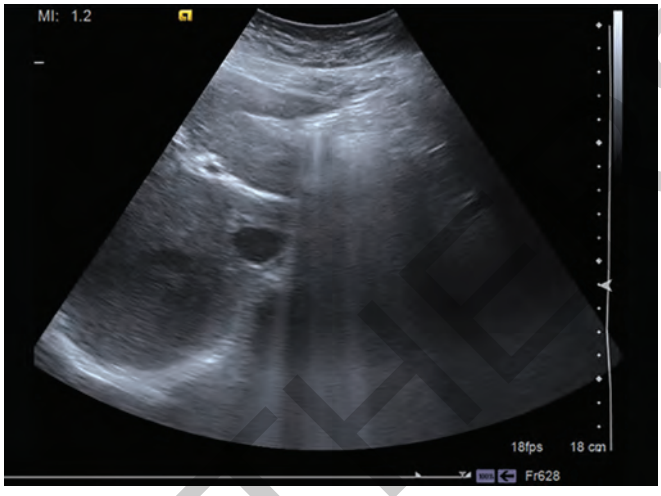

Fig. 13: Ring down artifact from the duodenum.

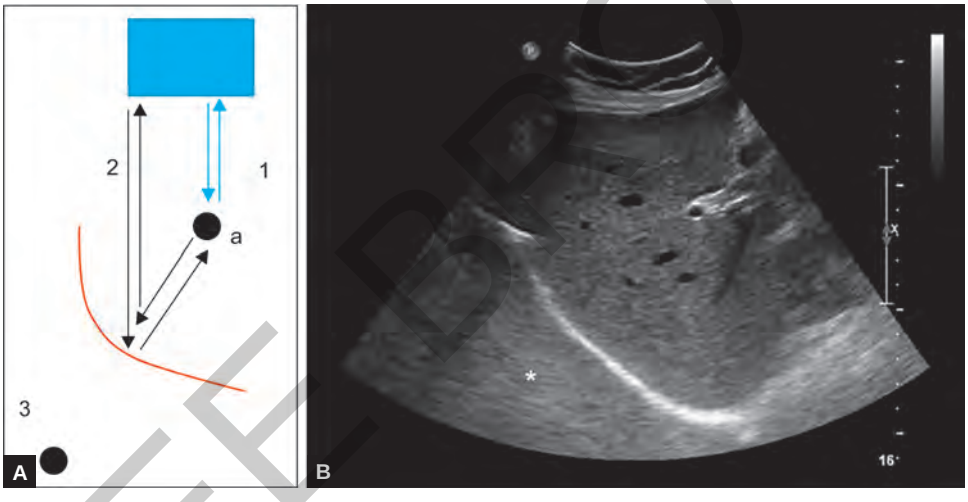

Figs. 14A and B: (A) Mirror image artifact due to a strong specular reflector: Without reflection (blue arrows) the beam directly encounters the target and it is appropriately imaged in the correct location. When the transmitted ultrasound beam (black arrows) reflects off the specular reflector (curved red line) and reaches the target (black circle (a), from where it is reflected back along its transmitted course and then to the transducer, because of the delay in the returning echo, the image (circle 3) appears to be deep to the reflector but at the same distance. The result is a mirror image appearance across the specular reflector; (B) Mirror reflection of the liver is seen above the diaphragm in this patient (asterix).

forming) infections. Ring-down artifacts (B-lines) have been used in lung US for the diagnosis of interstitial conditions.

Mirror Image Artifact

This artifact is also generated by a repeat echo. It is sometimes also referred to as a multipath artifact. When the ultrasound beam encounters a highly reflective surface. The reflected echoes then reach the target on their way back and are again reflected back towards the reflective interface before being reflected to the transducer, where they are detected. This causes a delay in the return of echoes to the transducer thus the display shows a replicated structure equidistant but deep to the strongly reflective interface **(Fig. 14A)**. This artifact is commonly seen at the diaphragm with the air-pleural interface acting as a strong reflector. It is recognized as hepatic parenchyma seen in the expected position of the lung which should not be mistaken for consolidated lung **(Fig. 14B)**. There may also be apparent duplication of a focal hepatic lesion **(Fig. 15)**.

JAYPEE BROTHERS

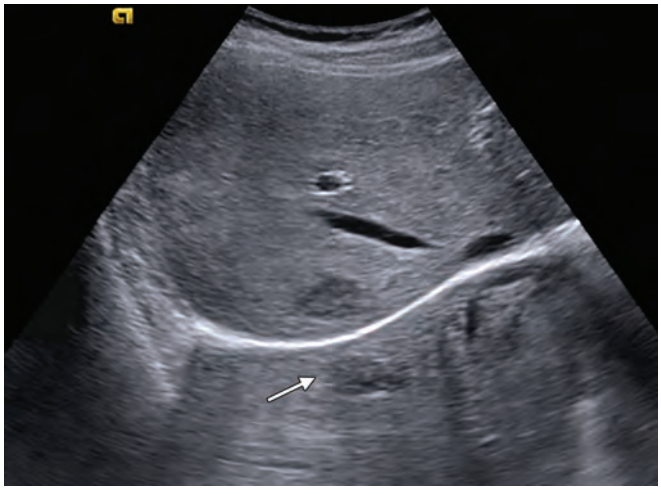

Fig. 15: Mirror image of a focal hepatic lesion seen behind the diaphragm (arrow).

At this level it generally does not cause any diagnostic problem, in fact may be useful, e.g. increased through transmission behind a peripheral cyst may be seen in the mirror image which would otherwise be obscured by the hyperechoic reflection of air in the lung. However, mirror image artifact may result in pseudothickened bowel wall due to gas acting as a specular reflector. It can also produce a pelvic pseudomass at times.

Artifacts Associated with Velocity Errors

An important assumption in ultrasound imaging is that the speed of US in soft tissues is constant (1540 m/s). This is not an absolute truth in clinical sonography. Fat, for example conducts sound about 15 percent slower than most other soft tissues **(Table 2)**.

When sound travels through a tissue with a velocity significantly lower than the assumed constant of 1540 m/sec the returning echo takes longer to return to the transducer. Scanners use the amount of delay to calculate the depth of the echo (0.13 microsecond delay corresponding to ~1 cm depth on final image). The processor presumes that the delay is due to increased distance traveled by the echo and thus the object is displayed deeper on the image than it actually is. This is called *speed displacement artifact* or *propagation velocity artifact*. This geometric distortion does not affect the lateral dimension of the image as this is determined by the scanning action of the transducer rather than by the speed of sound but axial dimension may be affected. In clinical practice, this artifact is most commonly seen when

Table 2: Velocity of ultrasound in biological materials.[3]

Tissue	*Velocity (m/s)*
Air	330
Fat	1450
Water	1480
Brain	1565
Muscle	1580
Liver	1600
Lens of eye	1650
Soft tissue average	1540

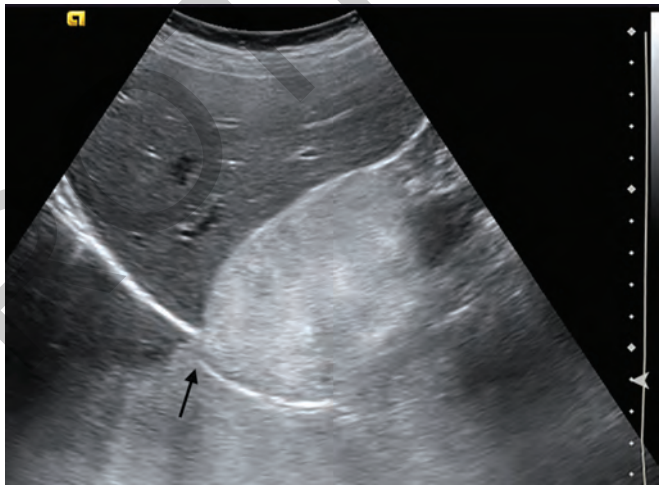

Fig. 16: Discontinuous appearance of the diaphragm (arrow) due to speed displacement artifact caused by fat in an adrenal myelolipoma.

an area of focal fat is encountered, e.g. areas of focal fat in the subdiaphragmatic region of the liver can result in a discontinuous appearance of the diaphragm because of fallacious posterior displacement of diaphragmatic segments behind the fatty change **(Fig. 16)**. Usually, imaging through tissues that differ significantly from the assumed velocity gives rise to misregistration of targets. When imaging targets through a uniform layer of fat, such as a large amount of subcutaneous fat or breast tissue, boundary distortion does not occur but the depth of all targets will be overestimated. Although minor differences in size or location are not generally important in image interpretation and may in fact provide diagnostic clues to the presence of fat within lesions, they may be important in applications such as US-guided interventions and radiation therapy, where small differences in size or location are critical.

JAYPEE BROTHERS

In ophthalmic ultrasound too, where great accuracy is required distortion caused by the higher velocity in the lens can be important. The speed of sound in the lens of the eye is 1620 m/s (vs 1540 of average soft tissues) so portions of the retina imaged through the lens appear nearer than the portions imaged through the sclera producing a shelf-like anterior distortion called *Baum's bumps*.

Refractory Errors

Differences in velocity between tissues also produce refractory errors. When an obliquely incident ultrasound beam encounters an interface between two substances with different speeds of sound, it changes direction. The degree of this change and the direction depends both on the angle of incidence and the difference in velocity between the two media. If the incident beam is at 90° to the interface, no refraction will occur. The scanner working on the assumption that the US beam travels in a straight line misplaces the echoes to the side of their true location. This situation may become important clinically during transabdominal pelvic scans due to refraction occurring deep to the junction of medial margin of rectus abdominis muscle and fat in the midline. This can cause misregistration of targets and lateral stretching of pelvic structures and obstetric measurements made under these conditions may be erroneous. In more extreme cases, it may cause apparent duplication of structures, the so called ghosting. Repositioning the transducer eliminates this artifact.

Attenuation Errors

As an ultrasound beam traverses through the tissues its energy gets attenuated due to combined effect of absorption, scattering and reflection. The greater distance the ultrasound beam travels through the tissues the more the attenuation for a beam of similar energy. To compensate for this attenuation, machines incorporate a processing technique for compensatory amplification of echoes that take longer to return i.e. arising in the deeper tissues. Attenuation also varies with different tissues depending on the attenuation coefficient which measures the loss of ultrasound intensity per unit distance travelled **(Table 3)**.

Table 3: Attenuation coefficients for selected tissues.[6]

Material	*Attenuation coefficient (dB/cm)*
Water	0.0002
Soft tissue	0.3–0.8
Lipid	0.5–1.8
Osseous	13–26
Air	40

Acoustic Shadowing

Acoustic shadowing implies reduction in the strength of echoes distal to a markedly attenuating or reflective object. When the ultrasound beam traverses a tissue that attenuates sound more than the majority of the tissue in the beam, shadowing occurs. This is because the gain compensation is only set to a standard value, thus an inadequate correction will be applied to this region. Both this region and tissues deeper to it, are depicted as less echogenic than they actually are. This is visible as a dark band called an acoustic or distal shadow **(Fig. 17)**. Shadowing can also be caused by highly efficient reflectors such as gas bubbles or calcification where 99% and 80% of the incident sound beam, respectively, is reflected back. This is because very little of the sound energy passes through to insonate deeper tissues, also, any echoes from the deeper structures are unlikely to cross the reflective layer as they return, since they would be re-reflected distally. Shadowing can be of diagnostic significance and, is usually seen with calculi, calcifications, bone, and gas, and appears as clean, partial, or dirty shadowing Clean shadowing usually occurs posterior to large calculi



Fig. 17: Acoustic shadows: Seen as dark bands posterior to multiple gallbladder calculi.

JAYPEE BROTHERS

and bone and is seen as a dark anechoic band. Partial shadowing is visualized as a hypoechoic band and occurs posterior to highly attenuating tissues, like fat, or small stones, especially when the width of the beam is greater than the size of the calculus. Dirty shadowing is seen distal to a highly reflecting surface like gas, where multiple secondary reflections cause low-level echoes within the shadow, appearing similar to ring-down artifact. Incorrect focal zone placement, large beam widths, and spatial compound imaging decrease shadowing thus it is important to turn off spatial compounding when imaging calculi. On the other hand imaging with higher frequency probes and using tissue harmonics increase shadowing.

Edge Shadowing

Shadowing is also sometime seen deep to the edges of strongly curved surfaces, such as cyst walls, fetal skull and vessels. Fine dark lines can be seen extending deep to such edges and become even more striking in the case of a cyst due to the increased through transmission posterior to the cyst itself.

Two explanations have been offered for this: *refraction* of the ultrasound beam as it strikes a curved surface and *increased attenuation* at the edges because the ultrasound beam passing through the edge travels a larger distance through the cyst wall than that passing through the diameter of the cyst. Since, the cyst wall is presumed to be more attenuating than the surrounding tissues, the beam is attenuated more resulting in shadowing. Although acoustic shadows have diagnostic significance and are useful for diagnosis of calcification or calculi, edge shadows do not have this significance **(Figs. 18A and B)**. Edge shadowing frequently occurs in areas where shadowing may erroneously suggest calcification, e.g. vessel walls within renal sinus and Coopers ligaments in the breast. It is important to recognize them as artifactual and dismiss them.

Increased Through Transmission or Distal Bright Up

Attenuation errors also occur if a tissue attenuates less than its surrounding tissues (e.g. a full bladder or a simple cyst). In this situation the echoes from it and the tissues posterior to it are overcorrected appearing as a bright band often termed *'distal enhancement'* however since enhancing effect is also described with ultrasound contrast agents it is probably better referred to as *increased through transmission or distal bright up* **(Fig. 19)**. This artifact can be advantageously employed to diagnose cystic nature of a focal lesion, although some solid lesions such as lymphoma nodes and hepatic hemangiomas can also show posterior acoustic enhancement.

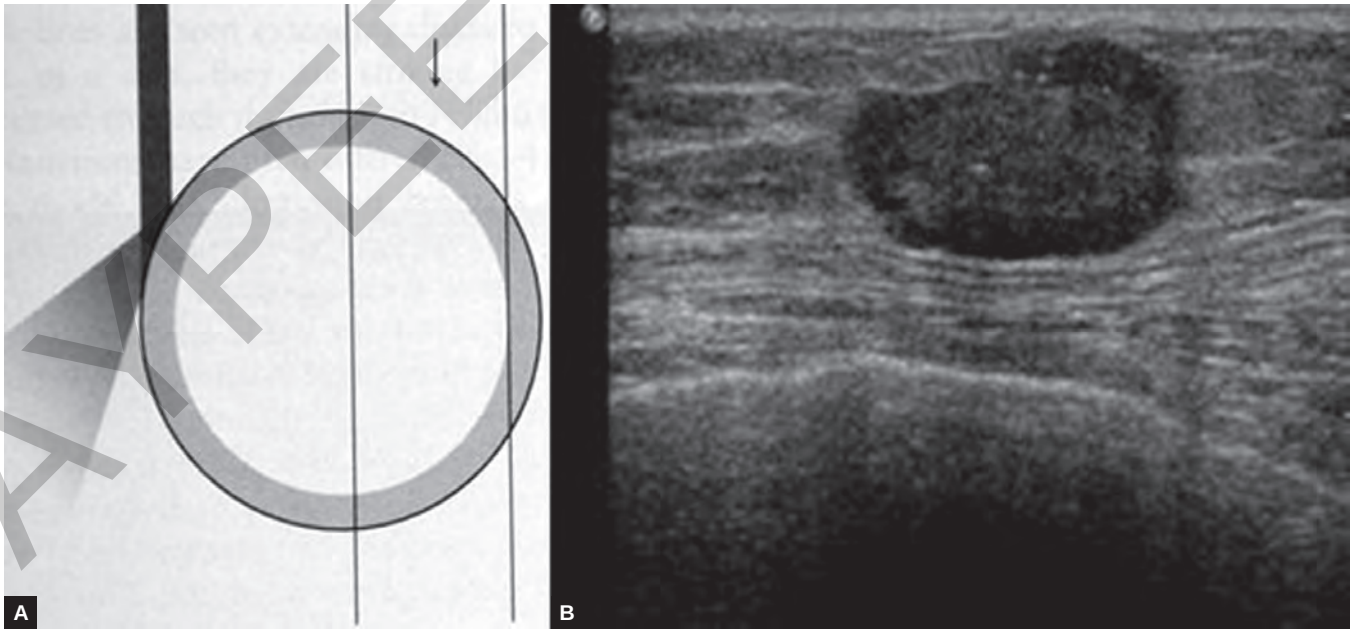

Figs. 18A and B: Refractive and attenuation model to explain mechanism of edge shadowing (A). Subtle edge shadowing seen along the edges of fibroadenoma breast (B).

JAYPEE BROTHERS

for detailed information on radiology books, visit our website **www.jaypeebrothers.com,** for detailed information on radiology books, visit our w



AIIMS-MAMC-PGI IMAGING SERIES

DIAGNOSTIC RADIOLOGY

Advances in Imaging Technology

A sense of déjà vu prevails in presenting this book *Advances in Imaging Technology* (3rd Edition) as we trace the journey of AIIMS-MAMC-PGI courses backwards into 1996. With every such course that has been conducted over past two decades covering practically all aspects of radiology, a companion textbook has been published to guide the contemporary practice. We feel humbled as this historic joint initiative of all three premier academic institutes that has proved very rewarding and academically full-filling experience, especially when we look at the scale of popularity that these books (and courses) have come to enjoy amongst its readership. This book is a sequel to its 2nd edition that went by the name, *Recent Advances and Applied Physics in Imaging* (2nd Edition), that was published back in the year 2013.

Given that our specialty is progressing at an exponential pace, revisiting the advances in modern imaging is not only timely but also imperative. All 28 chapters have been thoroughly revised to give most current knowledge of the topics as this edition goes into press. It not only provides an update on all main imaging modalities, viz. CT, MRI, Ultrasound and Digital Radiography, but also the trending topics such as 'artificial intelligence' and 'deep learning'. Furthermore, we have chosen to retain the popular topics such as ethical and legal issues in Radiology including PC-PNDT, radiation protection, contrast media, evidence-based radiology with a primer on biostatistics and structured reporting among others. The breadth of knowledge that it offers is vast.

We earnestly hope that this edition will prove to be a useful resource to radiologists and technologists at all levels of training and experience.



Arun Kumar Gupta



Anju Garg



Manavjit Singh Sandhu

Available at all medical bookstores
or buy online at www.jaypeebrothers.com

JAYPEE BROTHERS
Medical Publishers (P) Ltd.
www.jaypeebrothers.com

Join us on facebook.com/JaypeeMedicalPublishers

Shelving Recommendation
RADIOLOGY

ISBN 978-93-89034-92-9