others.com, for detailed information on anatomy books, visit our website www.jaypeebrothers.com, for detailed information on anatomy books

diginerve
A Jaypee Initiative
Your Guide at Every Step
Video Lectures | Notes | Self-Assessment
Scan code to check out courses

Complimentary Online Student Resource

Inderbir Singh's Textbook of ANATOMY

As per the Competency Based Medical Education Curriculum (NMC)

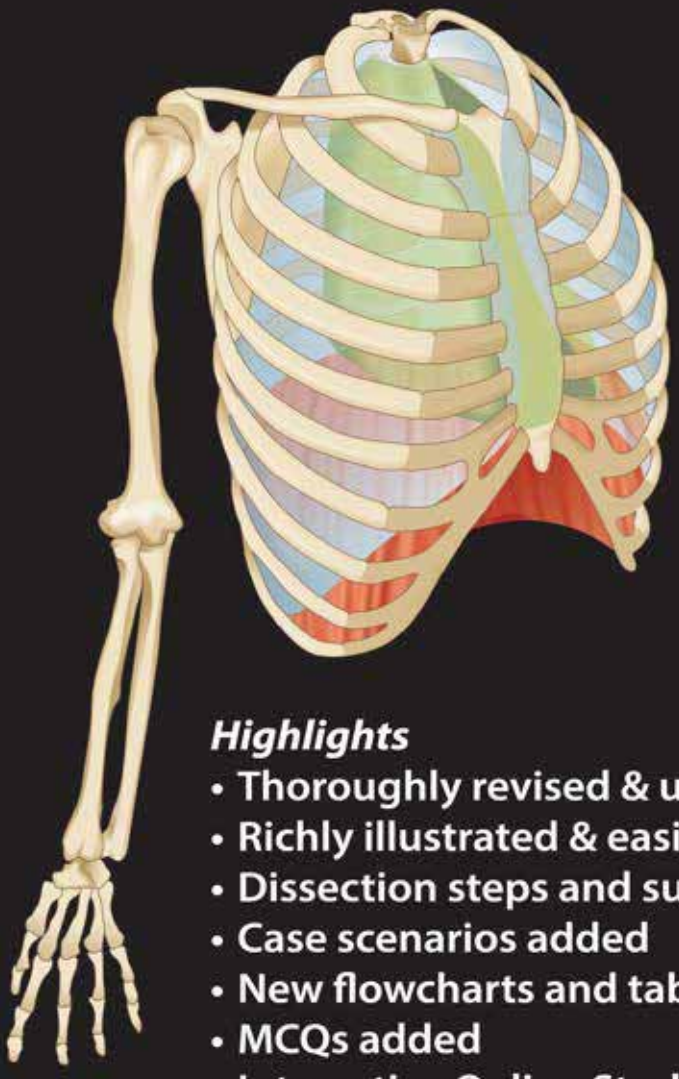

Volume One
Upper Limb
Thorax

SEVENTH EDITION

Revised and Edited by
V Subhadra Devi

Highlights
- Thoroughly revised & updated
- Richly illustrated & easily reproducible figures
- Dissection steps and surface anatomy included
- Case scenarios added
- New flowcharts and tables included
- MCQs added
- Interactive Online Student Resource

Revised Reprint

JAYPEE

Contents

Section 1 Upper Limb

1. Introduction to Upper Limb 3
2. Bones of Upper Limb 10
3. Brachial Plexus and Major Nerves of Upper Limb 55
4. Arteries of Upper Limb 88
5. Venous Drainage of Upper Limb 109
6. Lymphatic Drainage of Upper Limb 115
7. Pectoral Region and Mammary Gland 123
8. Axilla 143
9. Back and Scapular Region 149
10. Arm 173
11. Forearm 194
12. Hand 217
13. Joints of Upper Limb 246
14. Multiple Choice Questions: Upper Limb 288

Section 2 Thorax

15. Introduction to the Thorax 297
16. Vertebral Column 307
17. Bones of Thorax 327
18. Joints of the Thorax 346
19. Walls of the Thorax 356
20. Mediastinum 383
21. Trachea, Bronchi and Esophagus 394
22. Pleura 408
23. Lungs 420
24. Heart and Pericardium 438
25. Blood Vessels of Thorax 472
26. Lymphatics of the Thorax 493
27. Nerves of the Thorax 504
28. Multiple Choice Questions: Thorax 519

Index *523*

CHAPTER 2

Bones of Upper Limb

Learning Objectives

- Identification of the various bones of the upper limb
- Determination of side of each bone
- General features of each bone
- Muscular and ligamentous attachments of each bone
- Important nerves and vessels related to the bones
- Articulations contributed by the bones
- Clinical importance of each bone
- Clinical application of anatomical knowledge of bones of upper limb

INTRODUCTION

- Adoption of upright posture and bipedal locomotion brought changes in the bones of lower and upper limbs.
- Appendicular skeleton of upper limb is connected to sternum of the axial skeleton through clavicle.
- Bones of limbs were modified for carrying weights and for movement in quadrupeds. With the evolution of erect posture in man the function of weight-bearing was less for upper limb when compared to lower limb. The upper limb has been evolved for performing manipulative and finer skills especially with hands with the support of forearm, arm, and shoulder girdle.

BONES OF UPPER LIMB

The bones of upper limb can be classified as follows:

- **Bones of pectoral (shoulder) girdle**—attaching the free upper limb to trunk (Fig. 2.1):
  - Clavicle
  - Scapula.
- **Bones of free limb:**
  - Arm—humerus
  - Forearm—radius and ulna
  - Hand—carpals, metacarpals, and phalanges.

CLAVICLE

General Description of Clavicle (Figs. 2.2 and 2.3)

- ***Meaning and synonyms*:** The word clavicle is derived from Latin ***meaning key***. When the shoulder is abducted the clavicle rotates along its long axis like a key or the italic letter ***f***. It is also called ***collar bone***.
- ***Type*:** It is the only long bone in the body that is placed horizontally.
- ***Location*:** It is located at the junction of neck and thorax on the anterior aspect (between the posterior triangle of neck and pectoral region).
- ***Palpation*:** It is a subcutaneous bone and can be felt easily in the living.
- ***Connections and articulations*:** By means of attachment for muscles and ligaments it is connected with the following bones:
  - Scapula
  - Humerus
  - Skull
  - Sternum
  - 1st rib.
- It forms ***articulations*** at its medial and lateral ends:
  - Medial end—it articulates with the:
    - Sternum forming ***sternoclavicular joint***
    - 1st rib through costoclavicular ligament

JAYPEE BROTHERS

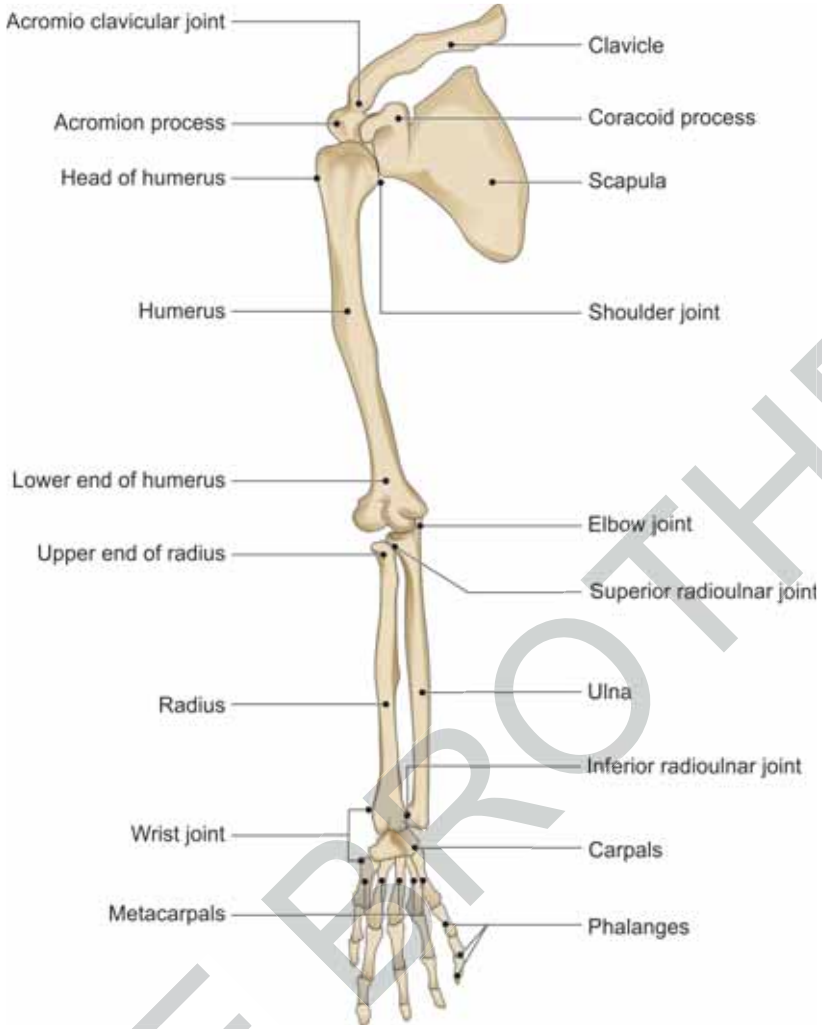

Fig. 2.1: Bones of upper limb.

- Lateral end—it articulates with the acromion process of scapula forming ***acromioclavicular joint***.

❖ ***Functions*:**
- It transmits the weight of upper limb to the axial skeleton.
- It forms one of the boundaries for the ***cervicoaxillary canal*** and protects the neurovascular bundle that traverses through the canal from the neck to the upper limb.

❖ ***Presenting parts*:** It presents a ***shaft*** and two ***ends***. The medial end is expanded and the lateral end is flat (Figs. 2.2 and 2.3).
- ***Shaft*:** It is curved in the shape of letter ***S*** with convexity forward in its medial two-thirds and concavity forward in its lateral one-third.
  - ♦ Medial two-thirds**:** Presents four surfaces the ***anterior***, ***posterior***, ***superior,*** and ***inferior*** that are not clearly demarcated from one another. Hence, the borders separating the surfaces cannot be identified. Middle one-third of inferior surface presents a longitudinal groove (***subclavian groove)***. Inferior surface near the sternal end is marked by a rough oval area for the attachment of a ligament (***costoclavicular ligament***).
  - ♦ Lateral one-third: Presents an upper (***superior***) and a lower (***inferior***) surface. It presents identifiable ***anterior*** and ***posterior borders***. ***Anterior border*** presents a rough elevation the ***deltoid tubercle***. Lower surface presents a rough elevation near the posterior border called ***conoid tubercle*** and a rough ridge ***trapezoid line or ridge*** that gives attachment to conoid and trapezoid parts of ***coracoclavicular ligament,*** respectively.

JAYPEE BROTHERS

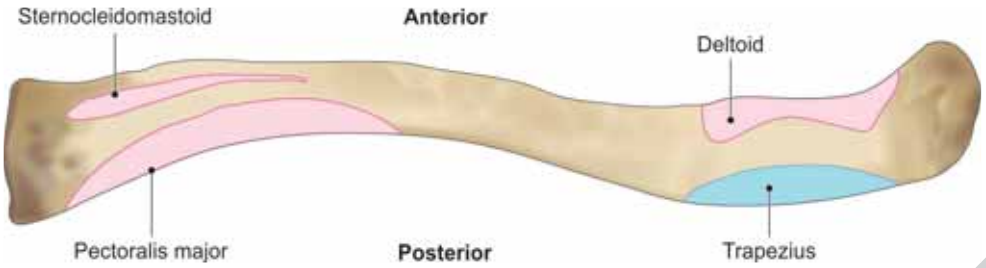

Fig. 2.2: Right clavicle—superior view with muscular attachments.

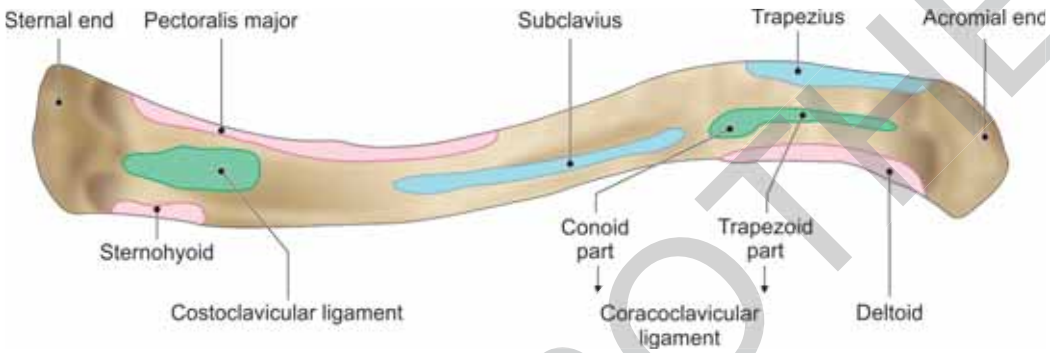

Fig. 2.3: Right clavicle—inferior view with muscular attachments.

Note

Coracoclavicular ligament is the strong structure that suspends the weight of upper limb from the clavicle.

- ***Ends*:** Acromial (lateral) and sternal (medial).
  - **Lateral (*acromial*) end:** It is flat and presents a smooth articular facet that articulates with acromion process to form acromioclavicular joint. It is attached to coracoid process of scapula by coracoclavicular ligament.
  - **Medial (*sternal*) end:** It is quadrilateral and articulates with manubrium of sternum and is also attached to 1st rib by ***costoclavicular ligament*** and takes part in ***sternoclavicular joint***. It is a ***palpable landmark***. The space between the sternal ends of right and left clavicles is known as ***suprasternal notch or space of burns*** (this will be dealt in detail in the head and neck volume).

Determination of Side of the Bone

By placing the curved bone horizontally with the:

- Acromial end—flat facing laterally
- Sternal end—quadrilateral facing medially
- Medial two-thirds of shaft—convexity forward
- Lateral one-third of shaft—concavity forwards
- Inferior surface—longitudinal ***subclavian groove*** in the middle.

Particular Features with Attachments

The attachments to various parts of clavicle are shown in Table 2.1 and Figures 2.2 and 2.3.

Peculiarities of Clavicle

- Though it is a long bone, it is placed horizontally.
- It is a subcutaneous bone.
- First bone to ossify and the last to complete ossification in the body.
- Develops by intramembranous ossification and hence is also called ***dermal bone***.
- It is the only long bone that is ossified from two primary centers.
- It has no medullary cavity.
- The supraclavicular nerves medial, middle, and lateral pass over it and sometimes the intermediate supraclavicular nerve pierces through it.

Ossification (Fig. 2.4)

- First bone to ossify in the body.
- Greater part of bone is formed by intramembranous ossification. The two ends are formed in cartilage.
- Sternal end is the growing end.

JAYPEE BROTHERS

Table 2.1: Muscular and ligamentous attachments of clavicle.

Part of bone	*Origin (O)/Insertion (I) of muscle, attachment of ligament/fascia*	*Articulation*
	Shaft—surfaces	
Medial two-thirds		
• Anterior surface (medial half) • Posterior surface (lower part of medial one-third) • Superior surface (medial two-thirds)	• Pectoralis major (O) • Sternohyoid (O) • Sternocleidomastoid (O)	
Intermediate one-third		
• Inferior surface • Subclavian groove • Margins of subclavian groove	• Nutrient foramen directed laterally • Subclavius (I) • Clavipectoral fascia	
Lateral one-third		
• Superior surface • Inferior surface: ➢ Conoid tubercle ➢ Trapezoid line	• Subcutaneous • Coracoclavicular ligament ➢ Conoid part ➢ Trapezoid part	Coracoid process of scapula
	Shaft—borders	
Lateral one-third		
• Anterior border—deltoid tubercle • Posterior border	Deltoid (O) Trapezius (I)	
	Ends	
Lateral	Acromioclavicular ligament	Acromioclavicular joint —with acromion process of scapula
Medial	***Growing end***	
• Rough area • Rough triangular area on inferior surface • Above rough area for sternoclavicular articulation	• Sternoclavicular ligaments (anterior and posterior) • Costoclavicular ligament • Interclavicular ligament	• Sternoclavicular joint—with manubrium of sternum • 1st rib—costal cartilage • Opposite clavicle

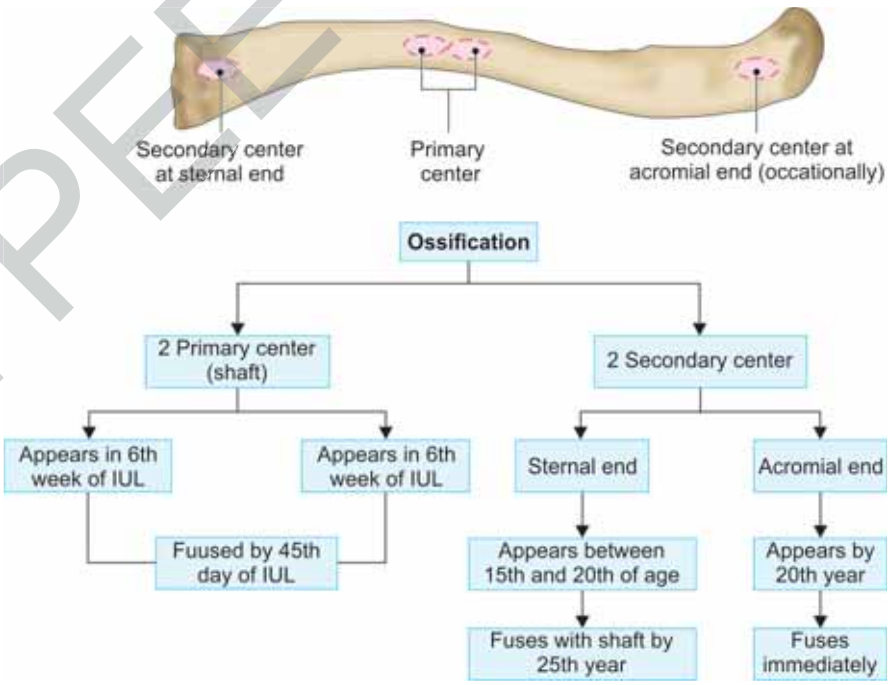

Fig. 2.4: Right clavicle: Time of appearance and fusion of various centers of ossification.

JAYPEE BROTHERS

Clinical Application

CLAVICLE

- **Fracture of clavicle:** The most common bone to be fractured in cases of fall on to the shoulder or on outstretched arm. The most common site of fracture in nearly 85% of cases is at the junction of medial two-thirds with lateral one-third (Fig. 2.5) which is the weakest point.
- **Cleidocranial dysostosis:** It is a developmental disorder with a genetic basis (autosomal dominant inheritance) that affects the membranous bones (skull, clavicle) and teeth. In this condition clavicle may be absent or defective.
- **Greenstick fracture of clavicle:** It is fracture of a tender or young bone (soft and pliable like a green stick) that initially bends and then breaks. Impact on such bone results in this type of fracture. The clavicle is slender and thin. As it completes ossification around 20–25 years fracture of the bone is often incomplete. It is a transverse fracture involving the cortex of one side and the marrow. It will not extend to the cortex on other side of the bone. The bone resembles the bent branch of a tender plant (green stick) which is not disconnected but merely hangs.

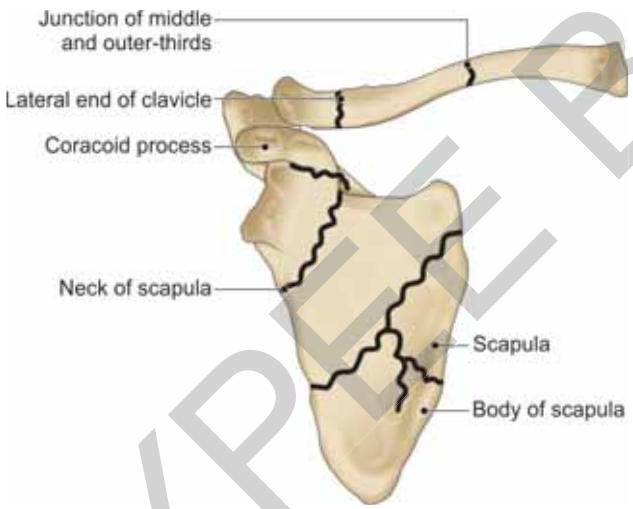

Fig. 2.5: Common sites of fracture: Clavicle and scapula.

Clinical Importance

ANATOMICAL KNOWLEDGE OF CLAVICLE

Case scenario 2.1

A middle aged person comes to the outpatient department (OPD) with severe pain and inability to lift his right arm immediately after a fall from the motor cycle. On examination, a sagging right shoulder downward and forward and a bump (projection) over the collar bone with bruising were observed.

Questions:

- What is the probable diagnosis?
- What investigation is to be advised for diagnosis?
- Explain the anatomical basis for this clinical condition.

Explanation:

- This is a case of fracture of clavicle.
- An X-ray of the region confirms the diagnosis (Fig. 2.6).
- Anatomical explanation: After the fracture, the lateral end of clavicle is displaced downward and forward due to the weight of the arm. This displacement is by the deltoid and pectoralis major muscle producing ***sagging shoulder***. The medial end is pulled upward by the contraction of sternocleidomastoid muscle. This type of fracture rarely requires surgery. A sling or a figure of 8 bandage is applied (Fig. 2.7)



Fig. 2.6: Displaced middle one-third fracture of clavicle with soft tissue interposition.
Courtesy: Dr JVS Vidyasagar, Gleeneagles Global Hospitals, Hyderabad, Telangana, India.

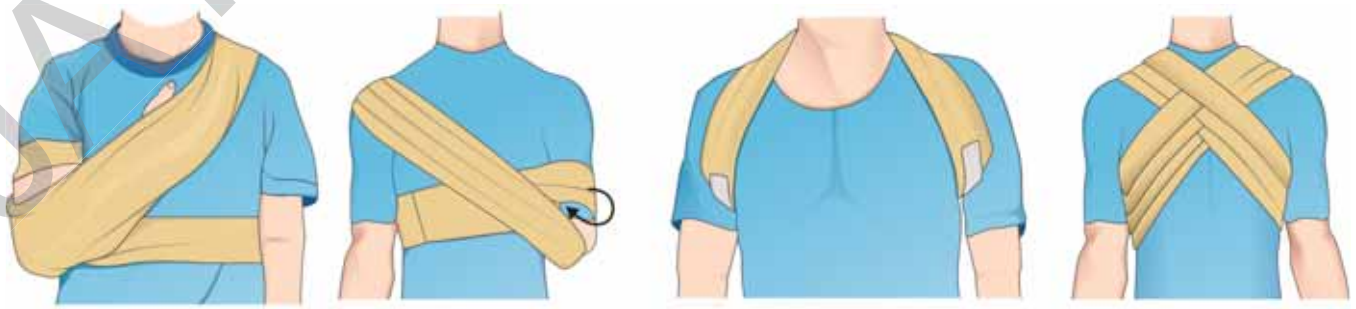

Fig. 2.7: Treatment of clavicular fractures.

JAYPEE BROTHERS

Review or Practice Questions

- In Figure 2.8 identify the side of the bone and the surface. Color the outline origin/insertion/ligamentous/fascial attachment on the clavicle with appropriate colors and label.
- Name the muscles that take origin from the clavicle.
- What are the peculiarities of the clavicle?
- Name the bones with which the clavicle articulates.

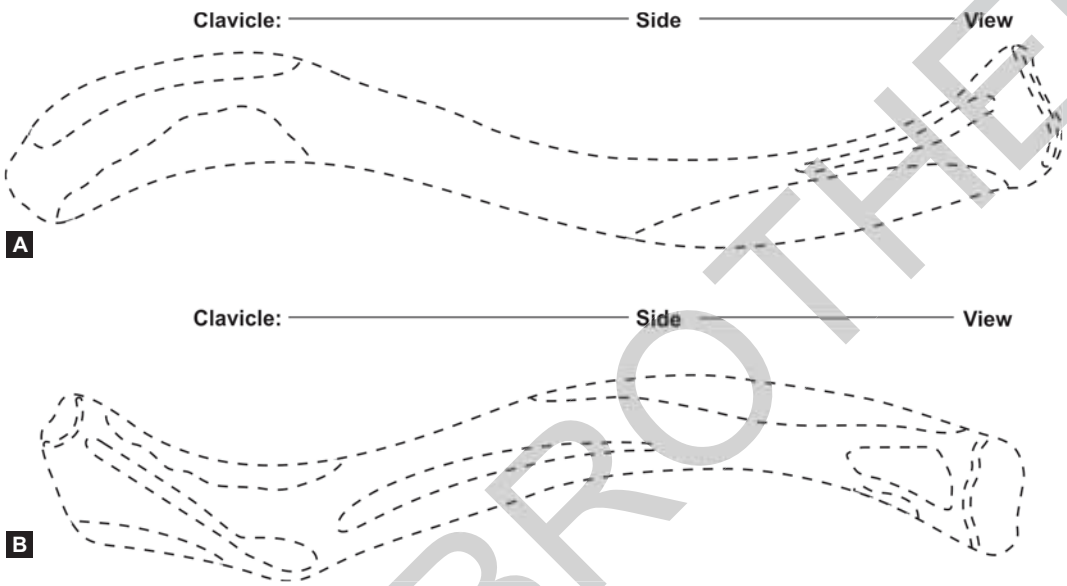

Figs. 2.8A and B: Outline of attachments of both surfaces of clavicle for practice purpose.

SCAPULA

General Description of Scapula (Figs. 2.9 to 2.12)

- ***Meaning, shape, and location*:** It is also called ***shoulder blade***. It is located on the dorsal aspect of rib cage extending from 2nd to 7th ribs.
- ***Type and shape*:** It is a flat bone and is roughly triangular in shape.
- ***Connections and articulations*:** It does not join with the axial skeleton. It forms articulations with clavicle (acromioclavicular and coracoclavicular articulations) and humerus (glenohumeral articulation).
- ***Function*:** It provides attachment for muscles that connect scapula with clavicle, humerus, skull, vertebrae, and ribs. It forms a socket for shoulder joint and enhances movements of upper limb.
- ***Presenting parts*:** Greater part of the scapula consists of flat triangular plate of bone called ***body***. Body presents two ***surfaces***, three ***angles***, three ***borders***, three ***processes***, four ***fossae,*** and two ***notches***.
  - ***Surfaces***—costal and dorsal:
    - Costal (anterior) surface (Fig. 2.9) is concave and contains ***subscapular fossa***. It lies against the posterolateral thoracic wall. It is marked by longitudinal ridges.
    - Dorsal surface (Fig. 2.10) is divided by a projection known as ***spine of scapula*** into a smaller ***supraspinous fossa*** above and a larger ***infraspinous fossa*** below. The two fossae communicate with each other through ***spinoglenoid notch*** that lies on the lateral side of the spine.
  - ***Angles*:** The body presents superior, inferior, and lateral angles (Figs. 2.9 and 2.10):
    - Lateral angle (***glenoid angle***) is enlarged and bears a large shallow oval- or pear-shaped depression called ***glenoid cavity*** (***glene*** = shallow in Greek) which articulates with the head of humerus.
    - Superior angle is at the junction of superior and medial borders.

JAYPEE BROTHERS

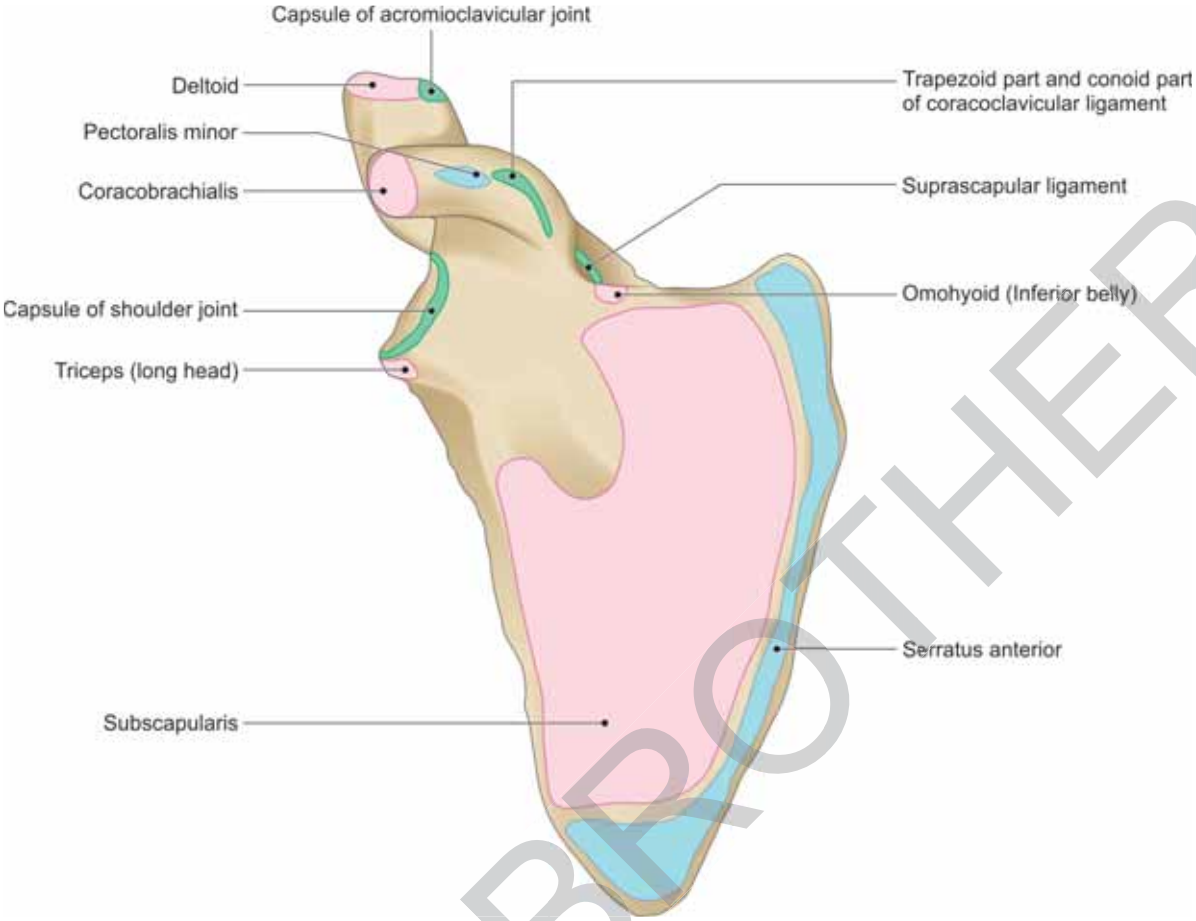

Fig. 2.9: Right scapula—costal surface with muscular attachments (Front view).

- Inferior angle is at the junction of medial and lateral borders. It is thick and rounded.

➢ ***Borders*:** It presents superior, medial (vertebral), and lateral (axillary) borders (Figs. 2.9 to 2.12):

- ***Superior border*** is thin and passes laterally from the superior angle, but is separated from the glenoid cavity (representing lateral angle) by the root of coracoid process. A deep ***suprascapular notch*** is seen at the lateral end of superior border (Figs. 2.9 and 2.12).
- ***Medial (vertebral) border*** is thin and extends from superior angle to inferior angle.
- ***Lateral (axillary) border*** is thick and extends from glenoid cavity to inferior angle. Just below the glenoid cavity the lateral border shows a rough raised area called ***infraglenoid tubercle***. Immediately above the glenoid cavity is a rough area called ***supraglenoid tubercle***.

On the dorsal aspect it is rough for muscular attachments.

➢ ***Processes*:** The scapula presents three processes. They are the ***spine***, ***acromion***, and ***coracoid*** (Figs. 2.9 to 2.12):

- ***Spine of the scapula*:** It is triangular in form with its apex medially and base laterally. It divides the dorsal surface into ***supraspinous and infraspinous fossae***. It presents anterior, posterior, and lateral borders and a root. Its anterior border is attached to the dorsal surface of the body. Its posterior border is free and is greatly thickened and forms the ***crest of the spine of the scapula***. The lateral border of the spine is free and forms the medial boundary of ***spinoglenoid notch***. The medial end of the spine (apex) lies near the medial border of the scapula and is referred to as the ***root of the spine***.

JAYPEE BROTHERS

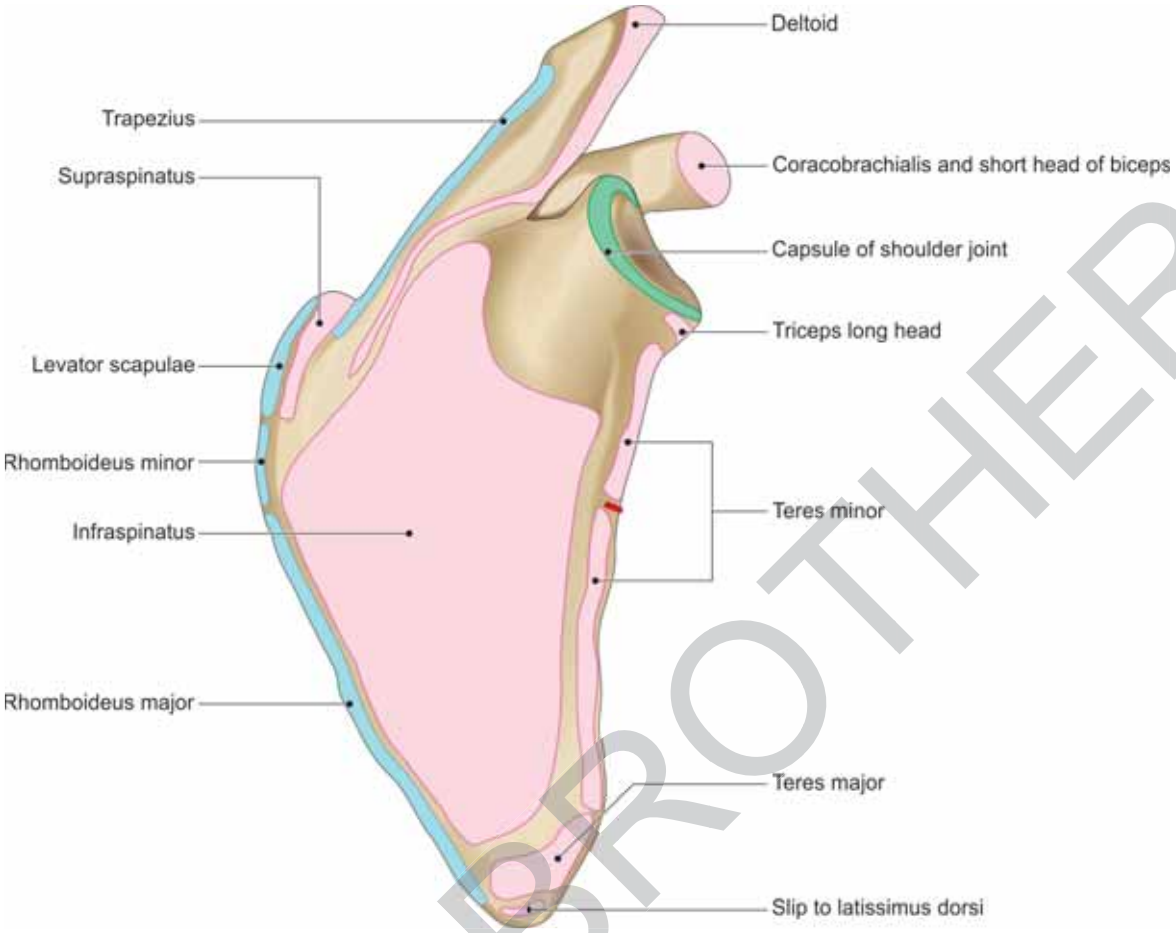

Fig. 2.10: Right scapula—dorsal surface with muscular attachments (Back view).

- ***Acromion*** (***akros*** = point, ***omos*** = shoulder, ***acromios*** = point of the shoulder in Greek)**:** It is continuous with the lateral end of the spine. It forms a projection that is directed forward and partly overhangs the glenoid cavity. It has two borders—the lateral and medial—that meet anteriorly at the ***tip of acromion***. The lateral border meets the crest of the spine of the scapula at a sharp angle termed the ***acromial angle***. The medial border of the acromion shows a small oval facet for articulation with the lateral end of the clavicle. The acromion has upper (subcutaneous) and lower surfaces.
- ***Coracoid process (korax, korone*** = crow in Greek)**:** It is shaped like a bent finger. The root of the process is attached to the body of the scapula just above the glenoid cavity. The lower part of the root is marked by the supraglenoid tubercle. The tip of coracoid process is directed straight forward. At the point where the coracoid process bends forward, its dorsal surface is marked by a ridge.

➢ ***Fossae—***supraspinous, infraspinous, subscapular, and glenoid (Figs. 2.9 to 2.12):

- ***Supraspinous fossa:*** The part above the spine along with the upper surface of spine forms this fossa (Figs. 2.11 and 2.12).
- ***Infraspinous fossa*****:** The area below the spine along with lower surface of spine forms this fossa (Fig. 2.10).
- ***Subscapular fossa*****:** The costal surface forms the subscapular fossa (Fig. 2.9).
- ***Glenoid fossa or cavity*****:** It is oval or pear-shaped depression at the lateral angle of the bone (Figs. 2.10 and 2.11). It forms shoulder joint along with the head of humerus. The region of glenoid cavity is often regarded as the head of the scapula. Immediately medial to it there is a constriction which constitutes the ***neck*** of scapula.

JAYPEE BROTHERS

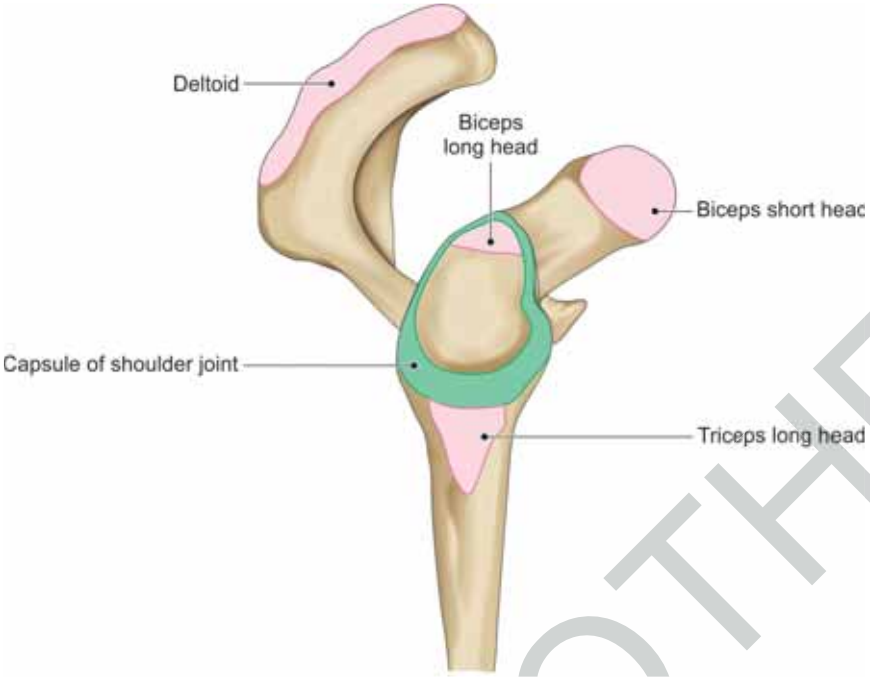

Fig. 2.11: Right scapula—lateral view with muscular attachments.

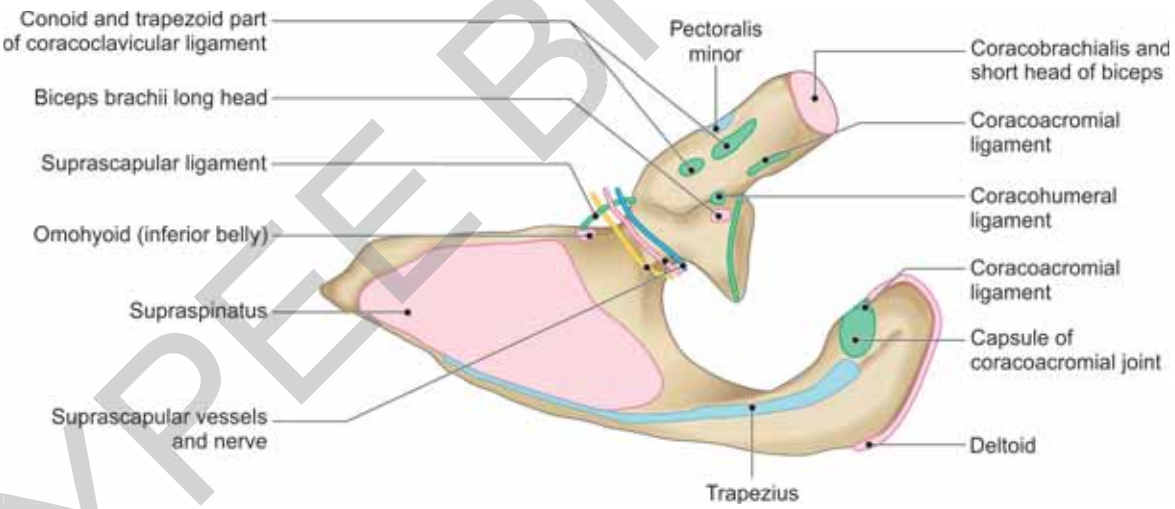

Fig. 2.12: Right scapula—superior view with muscular attachments.

- ***Notches—suprascapular*** and ***spinoglenoid*****:** Suprascapular notch is converted into a foramen by suprascapular ligament that acts as a bridge. Above the ligament pass the suprascapular vessels and below the ligament is the suprascapular nerve. Through the spinoglenoid notch the suprascapular nerve reaches the infraspinous fossa.

JAYPEE BROTHERS

Determination of Side

By placing the triangular bone in position based on the following features:

- Flat triangular body is broad above representing the base of the triangle. Pointed inferior end represents the apex.
- Costal (anterior) surface is concave and smooth. Dorsal surface is divided by a shelf like projection—the spine of the scapula.
- Lateral angle is enlarged and bears the large, shallow, and oval depression—the glenoid cavity that articulates with the head of humerus.

Particular Features with Attachments

The attachments to various parts of scapula are shown in Table 2.2 and Figures 2.9 to 2.12. The scapula gives attachment to 17 muscles that stabilize scapula on thorax, synchronize glenohumeral movement (Glenohumeral rhythm), and provide the power for upper limb movement.

Ossification (Fig. 2.13)

The scapula has one primary center and seven secondary centers. All the secondary centers fuse between 18th and 22nd years of age.

Table 2.2: Muscular and ligamentous attachments of body of scapula.

Part of bone	*Origin (O)/Insertion (I) of muscle, attachment of ligament/fascia*	*Articulation*
Body of scapula—Surfaces and fossae (Figs. 2.9 and 2.10)		
Costal surface • Subscapular fossa	Subscapularis (O)	
Dorsal surface • Medial two-third of supraspinous fossa including upper surface of the spine • Greater part of infraspinous fossa but for a part near the lateral border and a part near neck	Supraspinatus (O) Infraspinatus (O)	
Borders (Figs. 2.9 to 2.12)		
Medial border (Figs. 2.9 and 2.10) • **Along dorsal surface** ➢ Superior angle to root of spine ➢ Opposite root of spine ➢ Root of spine to inferior angle • **Along costal surface** ➢ Superior angle to root of spine ➢ Narrow line along medial border	 • Levator scapulae (I) • Rhomboideus minor (I) • Rhomboideus major (I) • Serratus anterior 1st digitation (I) • Serratus anterior 2nd to–3rd/4th digitations (I)	
Lateral border • **Dorsal aspect** ➢ Upper two-thirds ➢ A gap in the middle ➢ Lower one-third	 • Teres minor (O) • Circumflex scapular vessels • Teres major (O)	
• **Glenoid cavity** ➢ Glenoid fossa ➢ Supraglenoid tubercle ➢ Infraglenoid tubercle ➢ Margins of glenoid cavity	 • Head of humerus • Biceps—long head (O) • Triceps—long head (O) • Capsule of shoulder joint and glenoidal labrum	Shoulder joint—articulation with head of humerus

Contd...

JAYPEE BROTHERS

Contd...

Upper border Near suprascapular notch	• Inferior belly of omohyoid (O) • Suprascapular ligament	
Processes (Figs. 2.9 to 2.12)		
Spine of scapula • Upper border of crest • Lower border of crest	• Trapezius (I) • Deltoid (O)	
Acromion process • Medial border • Lateral border	• Trapezius (I) • Deltoid (O)	• Acromioclavicular joint • Coracoid through coracoacromial ligament
Coracoid process • Tip—lateral part • Tip—medial part • Horizontal part (upper surface)	• Biceps—short head (O) • Coracobrachialis (O) • Pectoralis minor (I) • Coracoclavicular ligament—conoid and trapezoid parts	• Clavicle through coracoclavicular ligament • Acromion through coracoacromial ligament
Angle (Figs. 2.9 and 2.10)		
Inferior angle • Dorsal aspect • Costal aspect	• Latissimus dorsi (O) • Serratus anterior—lower four-fifths digitations (I)	

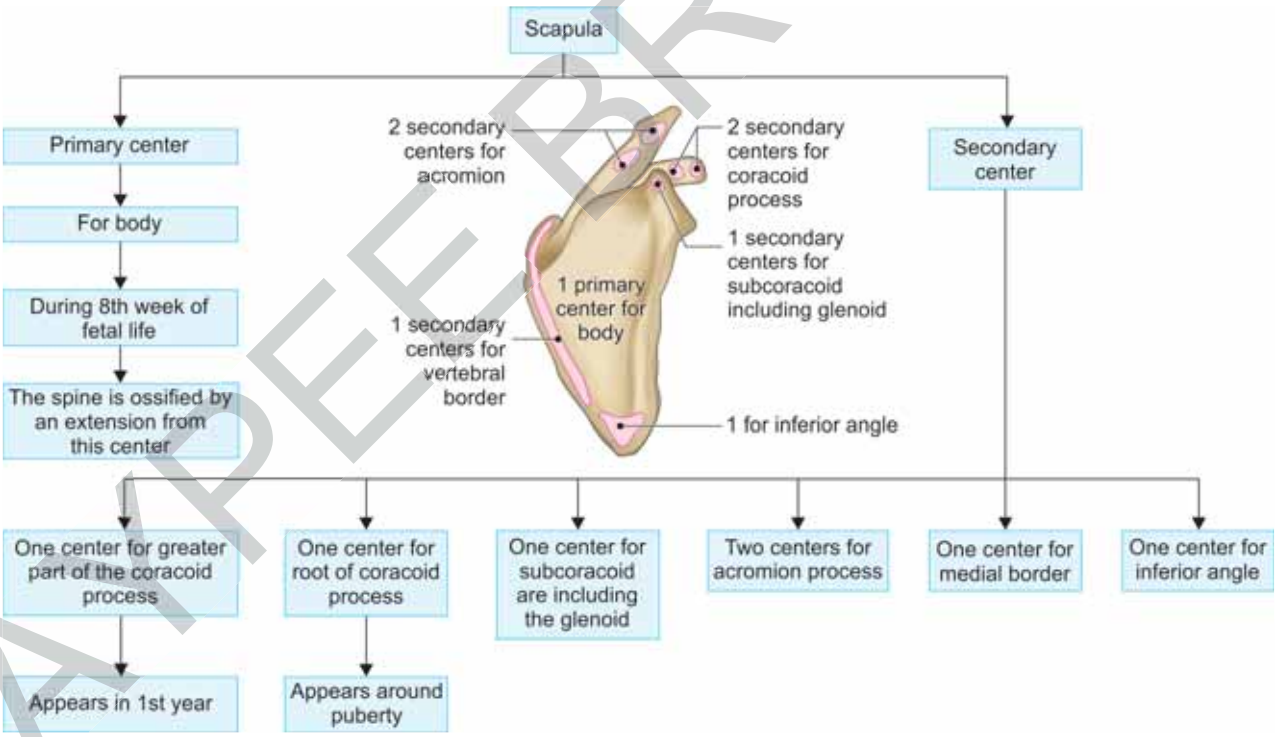

Fig. 2.13: Scapula—ossification

JAYPEE BROTHERS

Clinical Application

SCAPULA

- **Surface marking of parts of scapula with corresponding vertebral levels:**
  - Superior angle—T2 spine
  - Root of spine—T3 spine
  - Inferior angle—T7 spine
- **Neurovascular structures related to various parts of scapula:**
  - Suprascapular nerve and vessels—superior border, suprascapular ligament, and the spinoglenoid notch (Fig. 2.12).
  - Circumflex scapular branch of the subscapular artery—lateral border between the two sets of fibers of teres minor
  - Deep branch of the transverse cervical artery—medial border.
- **Suprascapular nerve entrapment:** At the suprascapular foramen or the spinoglenoid foramen.
- **Fractures of the scapula** (Fig. 2.5) are uncommon. They can occur in automobile accidents. Usual sites of fracture are:
  - Body of the scapula
  - Fracture through the neck
  - Fracture of the acromion process
  - Fracture of the coracoid process.
- **Sprengel's deformity:** It is a condition in which the scapula is placed higher than normal.
- **Winging of the scapula (Fig. 2.14):** It is a condition in which the medial border of the scapula is lifted off the chest wall. It is caused by paralysis of the serratus anterior muscle.



Fig. 2.14: Winging of right scapula.

Clinical Importance

ANATOMICAL KNOWLEDGE OF SCAPULA

Case scenario 2.2

A patient who practices boxing comes to the orthopedic OPD with inability to stretch his right arm forward to pick up an object or to push a table or do the punching movements while practicing sport and pain in the shoulder blade. On examination, the right scapula presented an elevated medial border. When the patient was asked to stand facing the wall and push it with stretched arms he could not perform with his right arm.

Questions:

- What is the probable diagnosis?
- What investigation is to be advised for diagnosis?
- Explain the anatomical basis for this clinical condition.

Knowledge required: To give explanation for the above condition and for planning investigations the knowledge of anatomy of the clavicle and the muscles attached to it and their action and nerve supply are required.

Explanation:

- This is a case of winging of right scapula.
- The investigations that are advised are electromyography (EMG), nerve conduction test for long thoracic nerve of Bell, and MRI scan depending on the severity and based on physical examination.
- ***Anatomical explanation*:**
  - The scapulae are the freely floating bones on the back of rib cage that facilitate a wide range of movement of arms in pushing forward, bracing back, raising above the head, etc.
  - The serratus anterior muscle that is inserted all along the medial border and inferior angle of scapula on its costal surface is the muscle that facilitates pushing and punching movements. It is supplied by long thoracic nerve.
  - Overstretching and strenuous movements of the arm can cause this condition of winging of scapula as in the present case where the patient is practicing the sport of boxing.

JAYPEE BROTHERS

r detailed information on anatomy books, visit our website **www.jaypeebrothers.com,** for detailed information on anatomy books, visit our webs

Inderbir Singh's Textbook of ANATOMY

Salient Features

- Simple language and presentation of material in the form of points for ease of understanding, remembering and reproduction by the students
- Simplified presentation in the form of flowcharts, tables and several images for better perception, comprehension and presentation in the examination
- Simplification and organization of content under several subheadings to motivate the students to read the subject in a sequence
- Organization of book into various chapters with each chapter presenting all the relevant components that has to be followed for continuity at one place like all arteries of that part in one chapter
- Clinical importance of each structure was presented in boxes for greater emphasis on clinical application of anatomical knowledge
- Dissection of the region wherever required is explained in brief in a separate box
- Osteology of individual bones in limbs and thorax are presented in a novel way with description of general features in text form and the muscular attachments in table format for easy reference
- Take home message for each chapter to recap the highlights of that chapter was done
- Greater emphasis on clinical application of anatomical knowledge by providing case scenarios with explanation
- Mnemonics given in respective chapters are close to the students, for easy to remembering and recall
- To motivate the students in this direction almost all chapters are provided with real-time case scenarios and explanations to introduce the anatomical basis for the clinical practice.

V Subhadra Devi MS (Anatomy) is Professor and Head, Department of Anatomy, Sri Padmavathi Medical College for Women (SPMCW); Sri Venkateswara Institute of Medical Sciences (SVIMS) University, Tirupati, Andhra Pradesh, India, and Ex-Vice Principal (Academic), Professor and Head, Department of Anatomy, Sri Venkateswara Medical College, Tirupati. She did her graduation and postgraduation from Sri Venkateswara Medical College, Tirupati. She has a teaching and research experience of over 38 years. Her students are spread all over the globe. She has to her credit 70 publications in national and international journals. She is the author of Textbook of Basic Histology – A Color Atlas and Text, Textbook of General Anatomy and edited the 11th edition of Inderbir Singh's Textbook of Embryology.

She is a recipient of Andhra Pradesh State Meritorious Teacher Award. She is a life member of Anatomical Society of India, Society of Clinical Anatomists, Basic Sciences Association and Indian Society of Human Genetics. She is also Honorary Editor-in-Chief for International Journal of Anatomy and Research and editorial board member in various national and international journals.

Printed in India

Available at all medical bookstores
or buy online at www.jaypeebrothers.com



JAYPEE BROTHERS
Medical Publishers (P) Ltd.
EMCA House, 23/23-B, Ansari Road,
Daryaganj, New Delhi - 110 002, INDIA
www.jaypeebrothers.com

Join us on facebook.com/JaypeeMedicalPublishers

Shelving Recommendation
ANATOMY

