thers.com, for detailed information on anatomy books, visit our website www.jaypeebrothers.com, for detailed information on anatomy books

Complimentary Online Student Resource

diginerve
A Jaypee Initiative
Your Guide at Every Step
Video Lectures | Notes | Self-Assessment
Scan code to check out courses

Inderbir Singh's

Textbook of ANATOMY

As per the Competency Based Medical Education Curriculum (NMC)

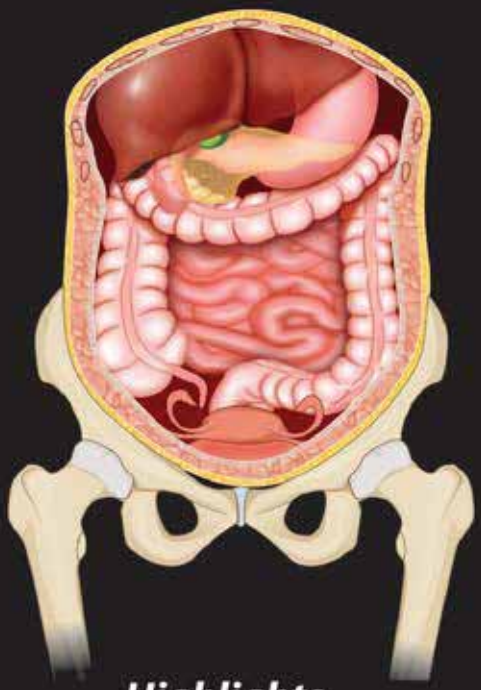

Volume Two

Lower Limb
Abdomen and Pelvis

SEVENTH EDITION

Revised and Edited by

V Subhadra Devi

Highlights

- Thoroughly revised & updated
- Richly illustrated & easily reproducible figures
- Dissection steps and surface anatomy included
- Case scenarios added
- New flowcharts and tables included
- MCQs added
- Interactive Online Student Resource

Revised Reprint

JAYPEE

Contents

Section 1 Lower Limb

1. Introduction to Lower Limb 3
2. Bones of Lower Limb 10
3. Nerves of Lower Limb 62
4. Arteries of Lower Limb 89
5. Venous Drainage of Lower Limb 112
6. Lymphatic Drainage of Lower Limb 122
7. Front and Medial Side of Thigh 128
8. Gluteal Region, Back of Thigh and Popliteal Fossa 158
9. Anterior and Lateral Compartments of Leg and Dorsum of Foot 181
10. Posterior Compartment of Leg and Sole of Foot 198
11. Joints of Lower Limb 226
12. Multiple Choice Questions: Lower Limb 259

Section 2 Abdomen and Pelvis

13. Introduction to the Abdomen 267
14. Bones and Joints of Abdomen 278
15. Anterior Abdominal Wall 289
16. External Genitalia and Perineum 314
17. Peritoneum 338
18. Esophagus, Stomach, Small Intestine, Pancreas and Spleen 358
19. Large Intestine and Liver 391
20. Kidney, Ureter and Suprarenal Glands 429
21. Posterior Abdominal Wall and Some Related Structures 450
22. Walls of Pelvis and Related Structures 491
23. Pelvic Viscera 508
24. Multiple Choice Questions: Abdomen and Pelvis 547

Index *551*

CHAPTER 15

Anterior Abdominal Wall

Learning Objectives

- Layers of anterior abdominal wall and their clinical importance
- Muscles of anterior abdominal wall
- Formation of inguinal canal and its contents
- Inguinal hernia
- Formation and contents of rectus sheath
- Abdominal incisions
- Blood vessels, lymphatics, and nerves of anterior abdominal wall

An introduction to the formation of the walls of the abdomen has been given in Chapter 14. This should be read, and the illustrations referred to therein should be carefully examined, before going on to study the descriptions that follow. The section on regions of the abdomen in Chapter 14 should also be read.

ANTERIOR ABDOMINAL WALL

LAYERS OF ANTERIOR ABDOMINAL WALL

The anterior abdominal wall is composed of the following from outside inward:

1. Skin
2. Superficial fascia
3. Muscles—from superficial to deep are the external oblique abdominis, internal oblique abdominis, and transversus abdominis
4. Fascia transversalis
5. Extraperitoneal fat
6. Parietal peritoneum

Skin

1. ***Langer's cleavage lines (Fig. 15.1):***
   - These are present all over the body.
   - These are due to the parallel arrangement of bundles of collagen fibers of the dermis.
   - In the neck and trunk, these lines are transverse, and in the limbs, they are longitudinal in direction.

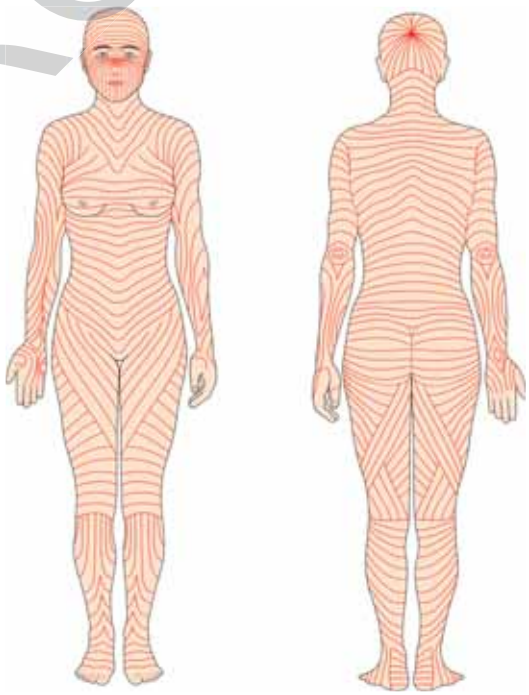

Fig. 15.1: Langer's lines—ventral and dorsal aspects of body. (*Source*: Reproduced from Textbook of General Anatomy by V Subhadra Devi).

JAYPEE BROTHERS

Clinical Application

LANGER'S LINES

Surgical incisions along these lines will unite perfectly after suture because of less stretching. The scar will be linear and hidden and is of cosmetic value.

2. ***Linea albicantes:***
   - In a female after deliveries, linear whitish scars are seen on the lower part of anterior abdominal wall.
   - In the case of males, they are seen in excess obese individuals.
3. ***Sensory/cutaneous innervation of skin of anterior abdominal wall (Fig. 15.2):***
   - It is by anterior rami of T7–T12 spinal nerves that are called thoraco-abdominal nerves, and branches of L1, i.e., iliohypogastric and ilioinguinal nerves.
   - A total of 14 nerves are present on either side of the midline of anterior abdominal wall. They are presented in Table 15.1.
4. ***Umbilicus or ompholos*:**
   - This is the meeting place of four embryonic folds and is represented by a depressed scar in the midline of anterior abdominal wall.
   - It is the site through which the fetus is connected to the mother through umbilical cord.
   - After birth, separation of cord forms the scar. Around the scar due to the accumulation of fat, the skin becomes elevated causing a central depressed area. The four embryonic folds that get fibrosed are as follows:
     - Urachus—obliteration of allantois coming from the hind gut. This becomes the median umbilical ligament that is seen at the apex of the urinary bladder.
     - Right and left umbilical arteries—these get obliterated but their proximal parts remain patent and become superior vesical artery.
     - Umbilical veins—the right vein disappears and the left vein gets obliterated. Ductus venosus (the communication between left umbilical vein and the inferior vena cava) becomes the ligamentum venosum.
   - The level of umbilicus is variable. Usually, it is at the level of junction between L3 and L4 vertebrae.
   - The nerve supply to the region of umbilicus is from anterior rami of T10 spinal nerve that arises from T10 segment of spinal cord. Sympathetic

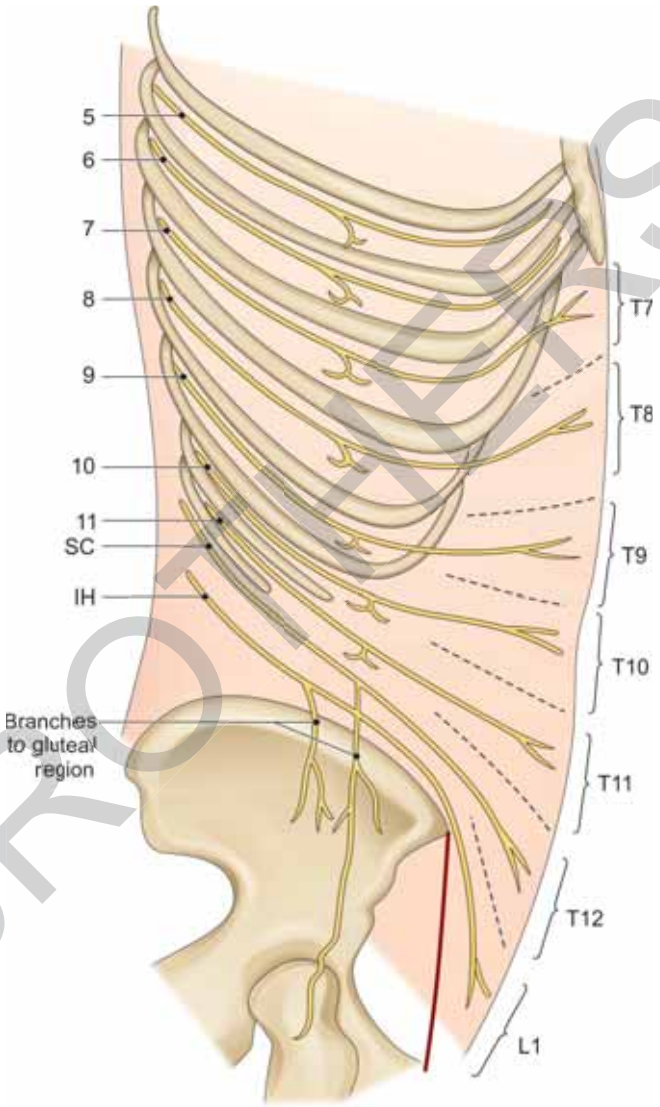

Fig. 15.2: Course of intercostal nerve as seen from the lateral side. (SC: subcostal nerve; IH: Iliohypogastric nerve)

Table 15.1: Region of anterior abdominal wall and cutaneous spinal segment.

Region	*Spinal nerve*
At xiphoid process	T7 nerve
Between xiphoid and umbilicus	T8 and T9 nerves
At the umbilicus	T10 nerve
Between umbilicus and symphysis pubis	T11, T12 (subcostal). Iliohypogastric (L1) and ilioinguinal (L1) nerves

JAYPEE BROTHERS

Clinical Importance

DEVELOPMENTAL CONSIDERATIONS OF UMBILICUS

Early in fetal life, the region of the future umbilicus is marked by a large gap in the future abdominal wall. The gap gradually becomes smaller as the wall grows toward the center (of the gap) from above, from below, and from the sides. At this stage of development, several structures pass through the gap as follows and they get obliterated. Their patency results in certain abnormalities. ***For a detailed description, a textbook of embryology may be referred***.

- ***Vitellointestinal duct***: It connects the embryonic gut to the yolk sac. In the normal course of development, this duct disappears.
  - If the duct remains patent, there is a channel through which intestinal contents flow out at the umbilicus ***(fecal fistula)***.
  - Sometimes, the vitellointestinal duct may not communicate with the exterior but part of it may remain patent as a diverticulum communicating with the gut. This is called ***Meckel's diverticulum***.
  - Remnants of the vitellointestinal duct may also give rise to tumors at the umbilicus.
- ***Allantoic diverticulum***: It is a tube-like structure that is connected, at one end, to the distal part of the embryonic gut (the part called the ***cloaca***) and the other end is blind.
  - In later development, the cloaca is partitioned into a part that forms the rectum and another part that forms the urinary bladder, and after this partition is established the allantoic diverticulum that comes to communicate with the urinary bladder.
  - The other blind end of the allantoic diverticulum passes through the umbilical opening.
    - Normally, the allantoic diverticulum is occluded and forms a fibrous band called the urachus. This band connects the apex of the urinary bladder to the umbilicus.
    - Occasionally, however the urachus remains patent (***patent urachus***) resulting in a communication between the urinary bladder and the umbilicus (***urinary fistula***).
- ***Herniation of gut***:
  - In the early embryo, the abdominal cavity is small. Meanwhile, the gut undergoes rapid growth and the abdomen is unable to accommodate it. As a result, some coils of intestine pass out of the abdomen through the umbilical opening. (This is referred to as ***physiological hernia***). Later, as the abdomen becomes larger in size, the coils return into the abdominal cavity.
  - In some cases, the coils of gut fail to return, and the infant is born with coils of gut protruding out of the abdomen in the region of the umbilicus. This is referred to as ***congenital umbilical hernia*** or ***exomphalos***.
- ***Obliteration of umbilical opening***: The original umbilical opening is obliterated by growth of tissue into it from all sides.
  - In some cases, growth of the wall below the future umbilicus is deficient resulting in a gap in the abdominal wall. Simultaneously, the anterior wall of the urinary bladder is also absent. Hence, we have a condition in which the posterior wall of the urinary bladder can be seen on the surface of the body. The condition is called ***ectopia vesicae***.

nerves from T10 segment (lateral column) of the spinal cord supply testis, ovary, kidney, ureter, and appendix. Hence, pain from any of these viscera is referred to the umbilicus.

5. ***Lymphatic watershed line:***
   - A transverse line drawn at the level of umbilicus demarcates the direction of flow of lymph in superficial lymphatic vessels of anterior abdominal wall.
   - Area of anterior abdominal wall above this line drains into the axillary lymph nodes. Area below this line drains into the inguinal lymph nodes.

Superficial Fascia of Abdomen

The abdominal cavity is required to expand and contract with each respiration. It expands when the stomach is full of ingested food. It is capable of expanding enormously in pregnancy, as a result of accumulation of fluid, or because of the presence of a large tumor within it. It follows that unlike the limbs the abdomen cannot be enclosed in a tight sleeve of deep fascia. In fact, deep fascia is not present over the front and sides of the abdomen.

The superficial fascia over the abdomen shows some special features. Over the lower part of the anterior abdominal wall (and over the perineum), the superficial fascia consists of two layers.

1. Superficial ***fatty layer (fascia of Camper).*** The fatty layer corresponds to superficial fascia elsewhere in the body.
2. Deeper ***membranous layer*** (***fascia of Scarpa)***. In the perineum, it is called the ***fascia of Colles***).

Extension of Fascia of Scarpa

- When traced upward, the membranous layer ends by merging with the fatty layer.
- When traced downward (near the midline), it passes across the pubic symphysis, over the penis, and into the scrotum.

JAYPEE BROTHERS

- When traced laterally, it is firmly adherent to underlying bone or underlying deep fascia (of the thigh) as follows:
  - The membranous layer passes into the upper part of the thigh across the inguinal ligament. However, the layer ends a short distance below the ligament by fusing with deep fascia along a horizontal line extending laterally from the pubic tubercle. The line of fusion is ***Holden's line*** (Fig. 15.3).
  - Near the midline the membranous layer passes downward over the pubic symphysis, but a little lateral to the midline it is fused to the body of the pubis.
  - In the anterior part of the perineum, the membranous layer is attached to the pubic arch.
  - The posterior edge of the fascia reaches the posterior border of the perineal membrane and fuses with it (Fig. 15.4).

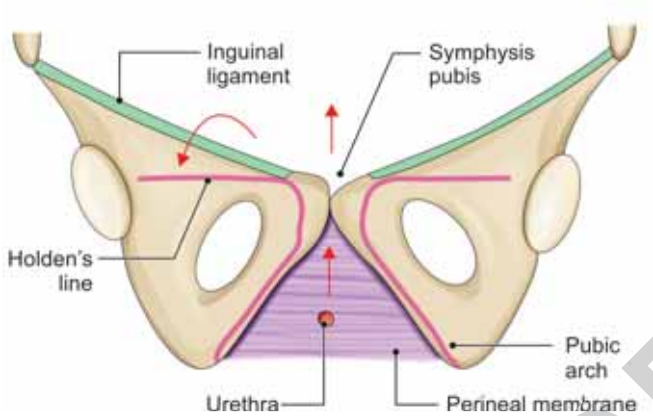

Fig. 15.3: Diagram to show lines along which the membranous layer of superficial fascia is firmly united to underlying structures. Anterior view: Arrows indicate the path that can be taken by extravasated urine if the urethra is ruptured.

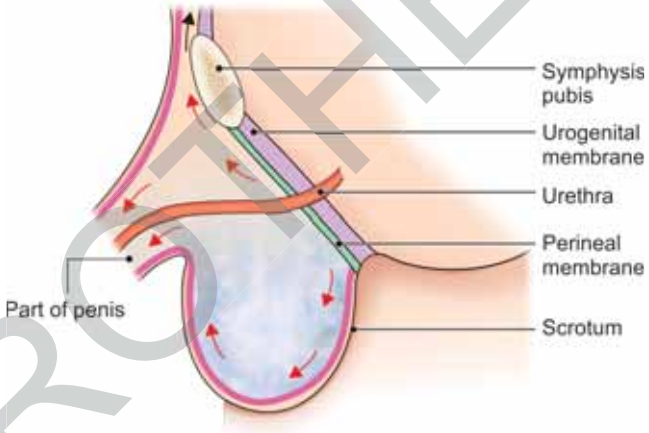

Fig. 15.4: Sagittal section through scrotum and adjoining structures to show arrangement of the membranous layer of superficial fascia. Arrows indicate direction in which extravasated urine can pass when the urethra is ruptured.

Clinical Application

Attachments of Membranous Layer of Deep Fascia of Abdomen

These attachments acquire significance in case of rupture of the urethra in the perineum. In such cases, urine leaking out of the urethra passes into the space between the membranous layer and deeper structures.

- It cannot pass backward beyond the perineal membrane because the membranous layer of fascia is fused to the posterior border of the perineal membrane.
- However, it can pass forward over the scrotum, over the penis, and upward over the pubic symphysis into the lower part of the anterior abdominal wall (Fig. 15.4).
- It cannot spread laterally into the thigh because of the attachment of the membranous layer to the ischiopubic rami.
- However, it can pass laterally over the lower part of the abdominal wall and can then pass downward across the inguinal ligament into the thigh (Fig. 15.3). However, its descent into the thigh is limited by the fusion of the membranous layer of superficial fascia to the deep fascia of the thigh along ***Holden's line***.
- In the clinical practice for palpation of the abdominal viscera the patient is asked to flex his/her thigh and knee on the side of palpation to relax the Scarpa's fascia. Otherwise the Scarpa's fascia is stretched by the attachment to the Holden's line.

JAYPEE BROTHERS

DISSECTION

Anterior Abdominal Wall

Incisions (Fig. 15.5)

- A vertical incision from the xiphoid process to the pubic symphysis in the anterior midline.
- A curved incision, first from the pubic symphysis to the pubic tubercle and then from the pubic tubercle to the anterior superior iliac spine along the fold of groin.
- A transverse incision from the xiphoid process to the midaxillary line.

Carefully reflect the skin flap laterally. Identify the superficial fascia. Try to locate the cutaneous nerves and vessels. Then shift your attention to the muscles. Read the theory of these muscles before you start a dissection. Clean the fascia. Observe the external oblique muscle. See the direction of its fibers. Feel for the inguinal ligament. See if you can insinuate your fingers gently underneath the inguinal ligament. If possible, observe its "rolled back" nature. Detach the external oblique from the ribs and iliac crest and reflect it laterally. Observe the internal oblique muscle. Study its fibers. Similarly expose the transversus abdominis muscle (Fig. 15.6).

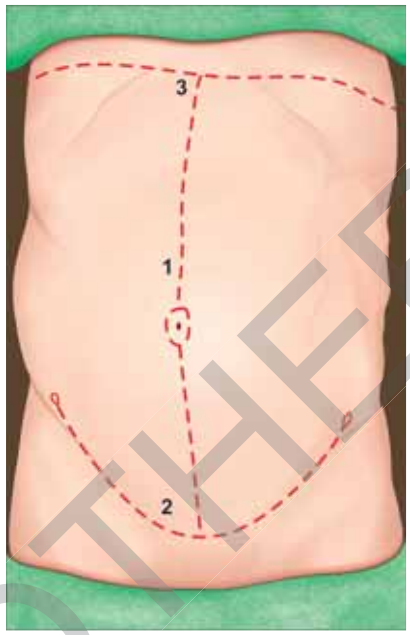

Fig. 15.5: Anterior abdominal wall incisions.

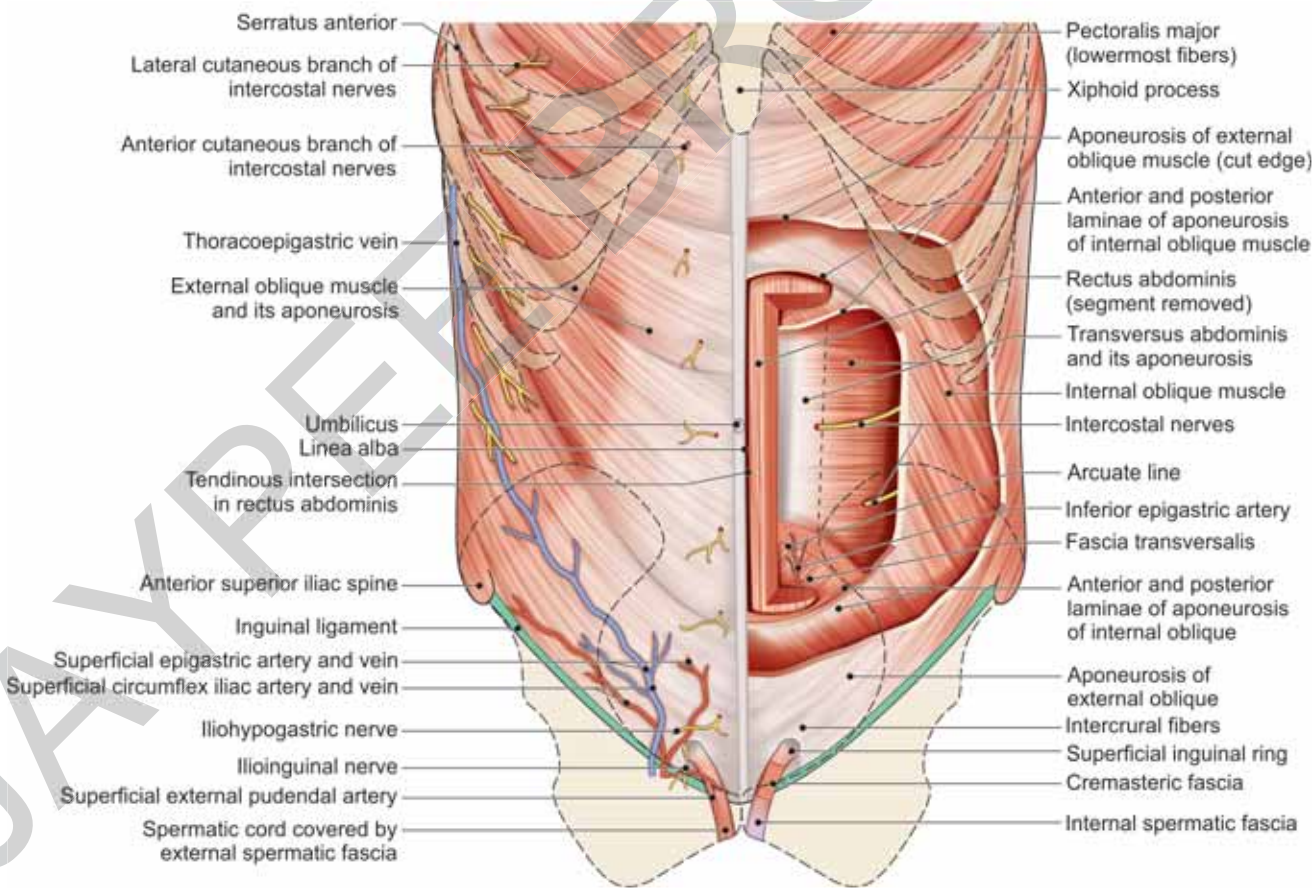

Fig. 15.6: Anterior abdominal wall. In the left half of the figure (representing right half of the body) skin and fasciae have been removed to expose the external oblique muscle and its aponeurosis. In the right half of the figure windows have been cut to display successive layers of the wall.

JAYPEE BROTHERS

Muscles of Anterior Abdominal Wall

Preliminary Considerations

In considering the muscles of the anterior abdominal wall, reference has to be made to a number of structures. Although many of them have been described elsewhere, they are briefly considered here because some of the attachments of the muscles of the abdominal wall cannot be understood unless the student has a clear idea about them.

1. Pubis (Fig. 15.7):

The pubis forms the anterior part of the hip bone. It consists of a ***body***, a ***superior ramus***, and an ***inferior ramus***. The bodies of the two pubic bones meet in the midline to form the ***pubic symphysis***. The upper border of the body is rounded and rough: it forms the ***pubic crest***. At the lateral end of the crest, there is a prominence called the ***pubic tubercle***. The superior ramus passes laterally and backward from the body. It is triangular in cross section, having three surfaces and three borders. The pectineal (anterior) and pelvic (posterior) surfaces are separated by a sharp ridge called the ***pecten pubis*** or the ***pectinate line***. Medially, the pecten pubis reaches the pubic tubercle. The ***pubic symphysis***, ***crest***, ***tubercle***, and ***pecten pubis*** give attachment to some muscles of the abdomen.

2. Iliac crest:

The upper border of the ilium is called the ***iliac crest***. It is a prominent ridge convex upward. It has projecting anterior and posterior extremities called the ***anterior superior*** and ***posterior superior iliac spines***. The crest can be divided into a large ventral segment and a smaller dorsal segment. The ventral segment has prominent medial and lateral lips between which there is a broad intermediate zone. The dorsal segment has two sloping medial and lateral surfaces.

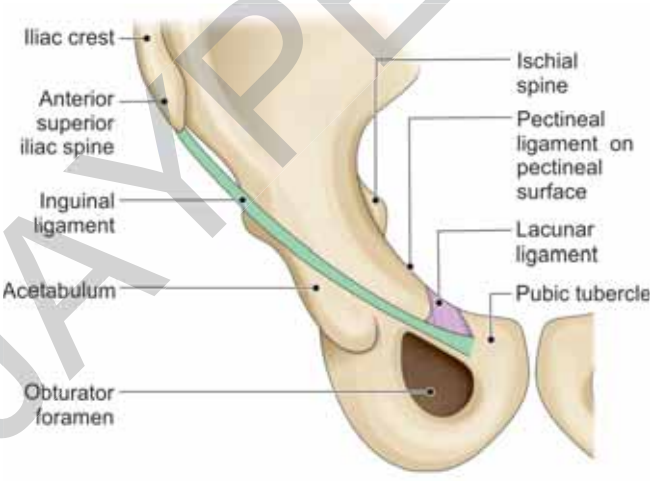

Fig. 15.7: Diagram to show the inguinal ligament and some related structures.

3. Linea alba:

This is a tendinous raphe present in the midline of the anterior abdominal wall (Fig. 15.6). It is attached above to the xiphoid process and below to the symphysis pubis. It is formed by the interlacing of the fibers of the aponeuroses of the external oblique, the internal oblique, and the transversus abdominis muscles. ***Refer below for further details.***

4. Inguinal ligament:

Synonym: **Poupart's ligament**

This is a thick curved band of fibers which lies at the junction of the abdomen and the front of the thigh. It is attached medially to the pubic tubercle and laterally to the anterior superior iliac spine (Fig. 15.7). It represents the lower border of the aponeurosis of the external oblique muscle, which is folded on itself. As a result, the ligament comes to have a grooved upper surface that can be seen if the ligament is viewed from its superior aspect.

5. Lacunar ligament:

Synonym: **Gimbernat's ligament**

This is also called the ***pectineal part of the inguinal ligament***. It is a triangular membrane placed horizontally, behind the medial most part of the inguinal ligament. The apex of the triangle is directed medially and is attached to the pubic tubercle. Its anterior margin is continuous with the inguinal ligament. Its posterior margin is attached to the medial part of the pecten pubis. Its base, directed laterally, is free: it forms the medial boundary of the femoral ring.

6. Pectineal ligament:

Synonym: **Cooper's ligament**

Some fibers (continuous with the lacunar ligament) extend laterally along the pecten pubis beyond the base of the lacunar ligament. They constitute the pectineal ligament, the fibers of which are firmly adherent to the pecten pubis.

7. Superficial inguinal ring:

Just above the medial part of the inguinal ligament, there is an aperture in the aponeurosis of the external oblique muscle called the superficial inguinal ring (Fig. 15.8). The so-called ring is really an obtuse angled triangle. The base of the triangle is formed by the pubic crest. The two sides of the triangle form the lateral (or lower) and the medial (or upper) margins of the opening: these are referred to as crura. The lateral crus is nothing but the medial part of the inguinal ligament: we have seen that it is attached to

JAYPEE BROTHERS

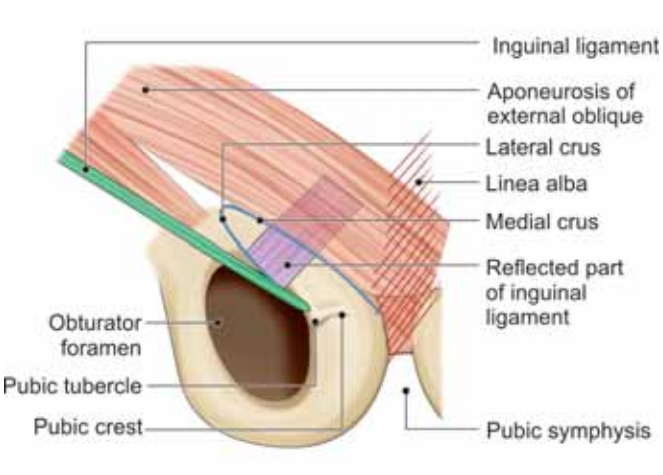

Fig. 15.8: Diagram to show the structure of the superficial inguinal ring.

the pubic tubercle and has a grooved upper surface. The medial crus is attached to the front of the symphysis pubis. The superficial inguinal ring is the external opening of the inguinal canal.

8. Reflected part of the inguinal ligament:

This is made up of fibers that pass upward and medially from the lateral crus of the superficial inguinal ring and disappear under its medial crus (Fig. 15.8). The fibers of the ligaments of the two sides decussate in the linea alba.

9. Inguinal canal:

This is an oblique passage through the anterior abdominal wall placed a little above the medial part of the inguinal ligament (Figs. 15.9 and 15.10). It begins at the deep inguinal ring which is situated in the

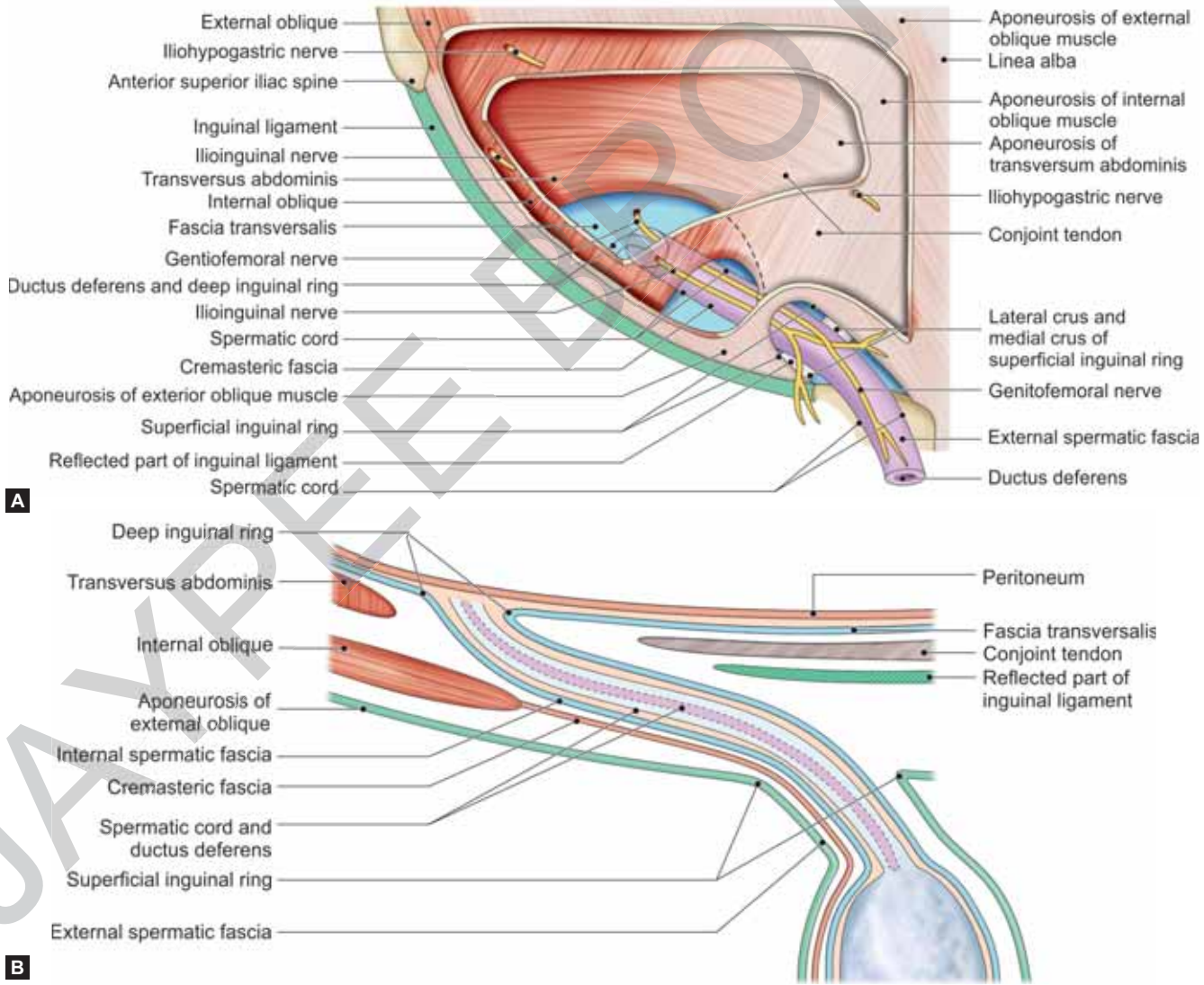

Figs. 15.9A and B: (A) Dissection of lower part of anterior abdominal wall to show the inguinal canal; (B) Scheme to show the coverings of the spermatic cord and of the testis.

JAYPEE BROTHERS

transversalis fascia (see below) midway between the anterior superior iliac spine and the pubic symphysis, half an inch above the inguinal ligament. The canal passes downward and medially to reach the superficial inguinal ring. The canal gives passage to the spermatic cord in the male and the round ligament of the uterus in the female (Fig. 15.9). The ilioinguinal nerve also passes through it. The boundaries of the canal will be considered after the muscles of the anterior abdominal wall have been studied.

10. Transversalis fascia:

This is a thin layer of connective tissue that lines the inner surface of the transversus abdominis muscle. It is separated from the peritoneum by a layer of extraperitoneal tissue rich in fat (Fig. 15.9).

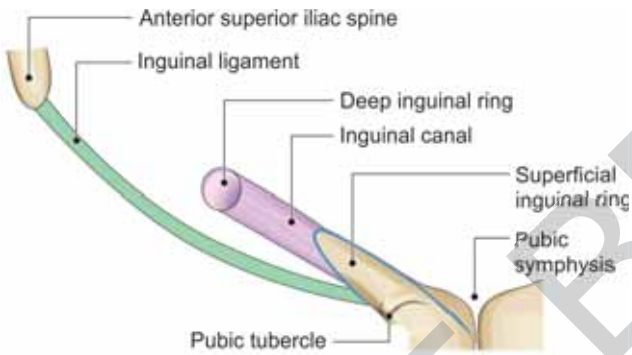

Fig. 15.10: Diagram to show the position of the inguinal canal.

11. Conjoint tendon (falx inguinalis):

This is made up of some fibers of the aponeuroses of the internal oblique and transversus abdominis muscles that join together and descend to be inserted into the pubic crest and the medial part of the pecten pubis (Fig. 15.11). The conjoint tendon lies behind the superficial inguinal ring. Traced medially, the fibers of the tendon become continuous with the rectus sheath. The aponeuroses of the two muscles fuse lateral to the rectus abdominis in the lower part of the abdominal wall. The more lateral fibers run downward forming the conjoint tendon, while the more medial ones form the anterior sheath of the rectus abdominis.

12. Thoracolumbar fascia:

This fascia is present in relation to the posterior abdominal wall. It needs to be mentioned here as some muscles of the anterior abdominal wall arise from it. The thoracolumbar fascia has three layers (anterior, middle, and posterior). The anterior and posterior layers meet at the lateral edge of the quadratus lumborum muscle and the fused layers give attachment to the transversus abdominis and the internal oblique muscles.

The muscles of anterior abdominal wall from superficial to deep are:

1. ***Obliquus externus abdominis*** (external oblique muscle of abdomen) is the most superficial of the anterolateral muscles of the abdomen (Figs. 15.6 and 15.12).

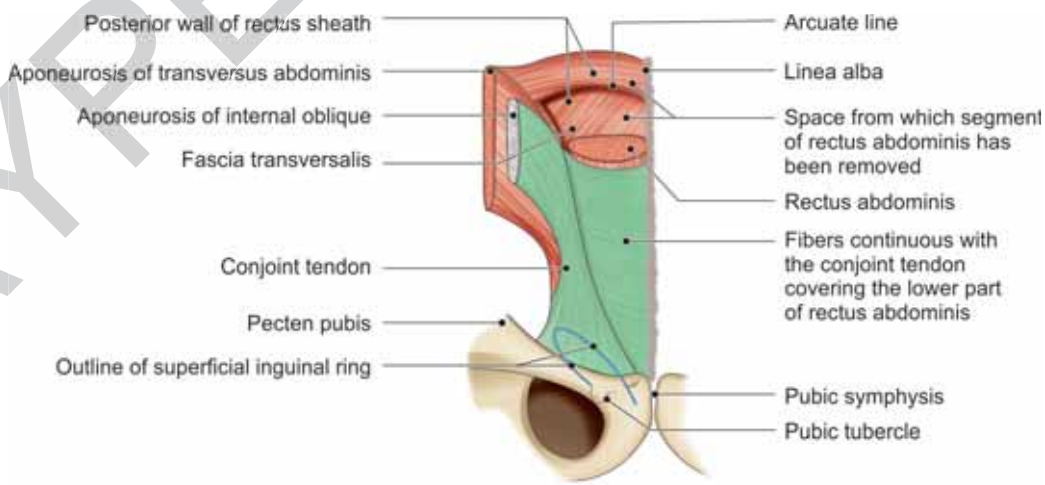

Fig. 15.11: Diagram to show the formation of the conjoint tendon. Some related structures are also shown.

JAYPEE BROTHERS

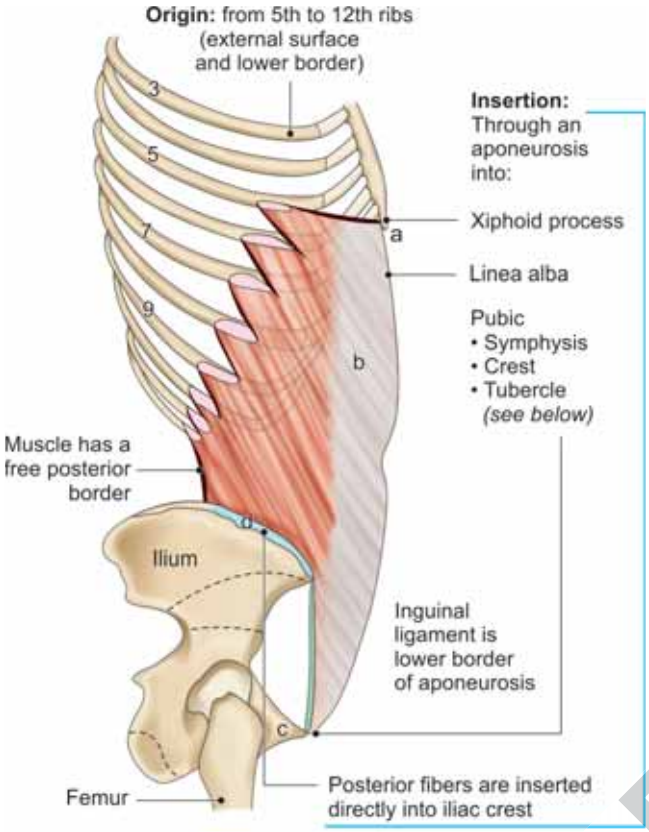

Fig. 15.12: Lateral view of the trunk to show the attachments of the external oblique muscle of the abdomen.

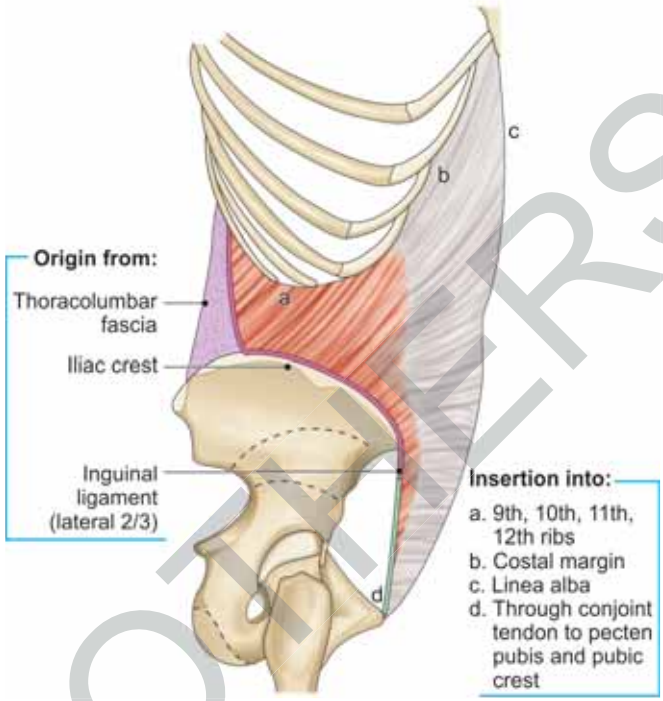

Fig. 15.13: Lateral view of the trunk to show attachments of the internal oblique muscle of the abdomen.

2. ***Obliquus internus abdominis*** (internal oblique muscle of the abdomen) lies between the external oblique and the transversus abdominis muscles (Figs. 15.6, 15.9, 15.13 and 15.14).
3. ***Transversus abdominis*** is the deepest muscle of the anterolateral part of the abdominal wall (Figs. 15.6, 15.9 and 15.15 to 15.17).

The details of these muscles are presented in Table 15.2.

INGUINAL CANAL

- It is an oblique musculo-aponeurotic passage (tunnel) in lower part of anterior abdominal wall
- Length—4 cm
- Direction—downward, forward, and medially
- Situation—lies above and parallel with medial half of inguinal ligament
- Extent—from deep inguinal ring to superficial inguinal ring
- Developmental basis for the formation of inguinal canal—the descent of gonads (testis/ovary) from the posterior abdominal wall to the future scrotal sac in males and labium majus in females during intrauterine life taking the guidance of gubernaculum and processus vaginalis.

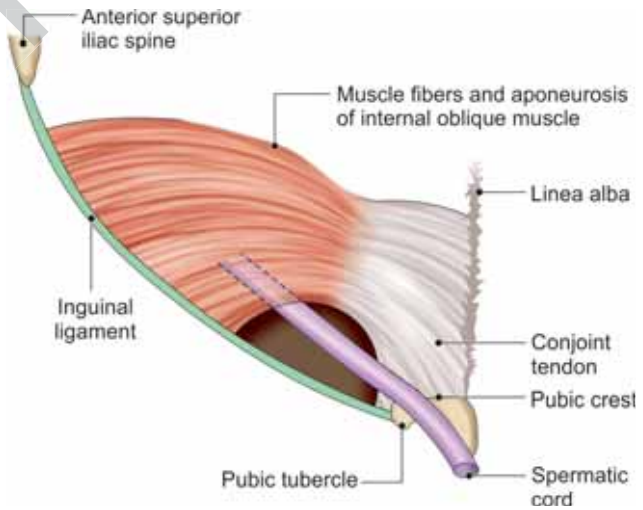

Fig. 15.14: Diagram to show relationship of the internal oblique muscle to the inguinal canal.

The deep and superficial rings are described in Table 15.3.

JAYPEE BROTHERS

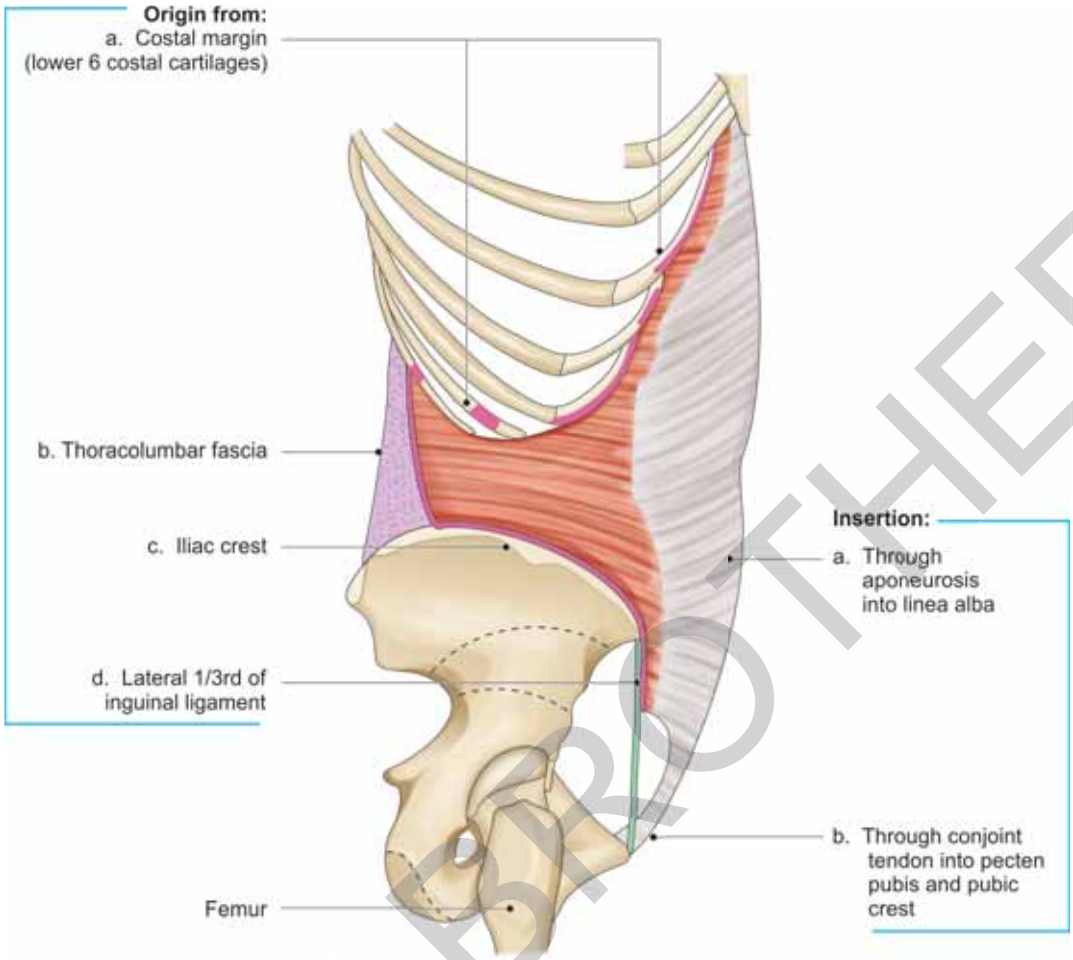

Fig. 15.15: Lateral view of the trunk to show the attachments of the transversus abdominis muscle.

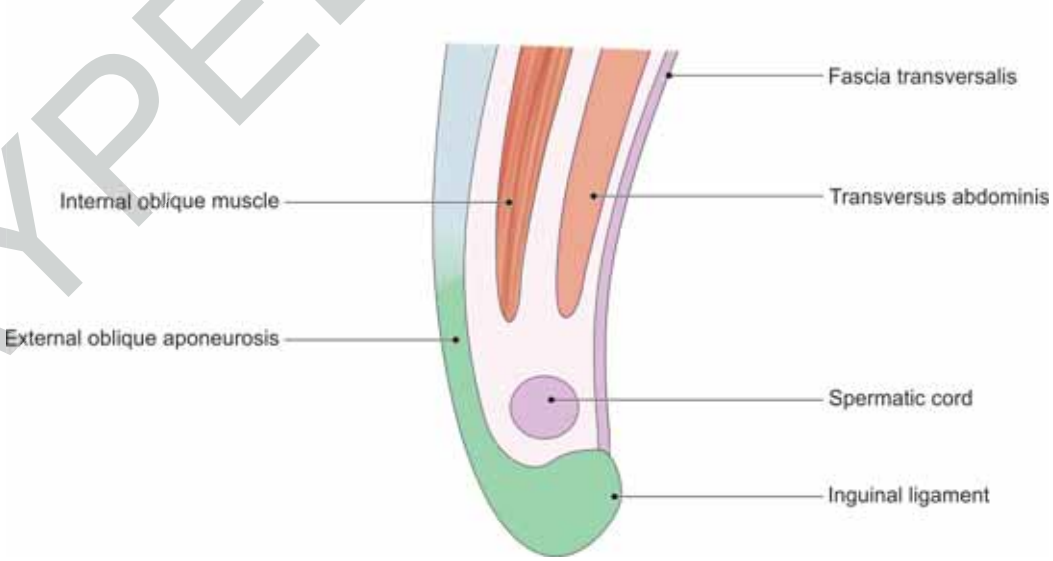

Fig. 15.16: Sagittal section through inguinal canal.

JAYPEE BROTHERS

below the umbilicus are less likely to lead to hernia as this region is protected by the recti which are close to each other.

- ***Paramedian incisions*** are made about 1 inch lateral to the midline. They may be supraumbilical or infraumbilical. The anterior wall of the rectus sheath is incised and the rectus muscle retracted laterally. (Remember that nerves to the rectus abdominis enter it from the lateral side and are safe when the muscle is pulled laterally.) The posterior wall of the sheath, the underlying fascia, and the peritoneum are then incised to gain access to the peritoneal cavity.
- ***Pararectal incision***: A vertical cut is made along the lateral margin of the rectus abdominis, and the muscle is retracted medially. As this is done, the nerves passing into the muscle from the lateral side come into view and have to be carefully preserved by retracting them up and down. The posterior wall of the sheath is now incised. The incision is not favored as access provided is small, and the incision cannot be enlarged without cutting one or more nerves.
- ***Vertical incision through the rectus abdominis (transrectal incision):*** In this incision, the rectus abdominis muscle and its sheath are cut vertically. Such an incision is not to be favored as nerve supply to part of the rectus abdominis medial to the incision is destroyed and this part of the muscle degenerates.
- ***Transverse incisions*** may be made through the abdominal wall, and the incision can include the rectus abdominis. Injury to nerves can be prevented by placing the cut parallel to the course of the nerves. In any case, injury to more than one nerve is unlikely.
- From the point of view of retaining integrity of the abdominal wall, the best incisions are those that split each layer of muscle along the length of its fibers. As the fibers of different layers run in different directions, the area of exposure is small. The best known muscle splitting incision is the ***grid-iron*** (or ***McBurney's***) incision used for operations on the appendix. For giving this incision, the McBurney's point is to be marked.

  McBurney's point: Point A is marked at the anterior superior iliac spine. Point B is marked at the umbilicus. The line joining the two points is called the ***spinoumbilical line***. It is divided into three equal parts. The junction of the medial two-thirds and the lateral one-third represents the McBurney's point on the surface. It is the point of maximum pain during inflammation of the appendix, but it does not correspond to the level of the ileocecal orifice.

  The grid iron incision is made through this point at right angles to the line drawn. The length of the line depends on the degree of exposure desired. As each layer of muscle is exposed, its fibers are split along the line of the fibers and retracted till the fascia transversalis and peritoneum are exposed.
- ***Pfannenstiel's incision*** is a low transverse incision just above the pubis. It is used for surgeries in female reproductive organs—cesarean section, hysterectomy, etc. It has cosmetic value and the exposure is limited to the pelvis.
- ***Rutherford Morrison incision*** is the lateral extension of grid iron incision.

In addition to the incisions described above, various others are used for special purposes. An abdominothoracic incision is used when it is necessary to enter both the abdominal and thoracic cavities.

Clinical Importance

KNOWLEDGE OF ANATOMY OF ANTERIOR ABDOMINAL WALL

Case scenario 15.1

A 64-year-old woman has an umbilical hernia. It is of the acquired variety.

Questions:

- What would you call this hernia, in specific terms?
- Suggest the possible predisposing factors for such a hernia.

Explanation:

- It is a paraumbilical hernia.
- The possible predisposing factors are obesity, weak anterior abdominal wall muscles due to aging, accumulation of fat, reduced muscle tone, and repeated pregnancies.

Contd…

JAYPEE BROTHERS

Contd…

Case scenario 15.2
A 57-year-old man has a direct inguinal hernia.
Questions:
- What would be the position of the neck of hernia with relation to the deep inguinal ring and the inferior epigastric vessels?
- Enumerate the names of some of the herniae that you know of.
- Define hernia.

Explanation:
- The neck of hernial sac is medial to inferior epigastric vessels. The hernia does not pass through the deep inguinal ring but enters the inguinal canal by pushing through its posterior wall.
- Other hernias are femoral hernia, diaphragmatic hernia, umbilical hernia, and indirect inguinal hernia.
- Hernia is an abnormal protrusion of a viscus or structure of a cavity through a normal or abnormal orifice.

Review or Practice Questions

Write essays on:
- Describe the boundaries and contents of inguinal canal.
- Describe the formation and contents of rectus sheath.

Write short notes on:
- Inguinal ligament.
- Superficial fascia of abdomen.
- Linea alba.
- Lacunar ligament.

TAKE HOME MESSAGE

- Umbilicus has anatomical, embryological, and clinical importance.
- Modifications of aponeurosis of external oblique muscle of abdomen are the inguinal ligament, lacunar ligament, and reflected part of inguinal ligament.
- Inguinal canal is the oblique passage in the layers of anterior abdominal wall. It has got developmental basis and has clinical importance, i.e. inguinal hernias. Direct hernias occur through Hesselbach's triangle and are seen in older people. The indirect hernias occur in young individuals and occur through deep ring.
- The inferior epigastric artery relation differentiates direct and indirect hernias. If the neck of hernial sac is medial it is direct hernia. If it is lateral to the artery, it is indirect hernia.
- Spermatic cord has three coverings, three arteries, three nerves, and three other structures (a tube, an embryological remnant, and plexus of veins).
- Aponeuroses of all three muscles of anterior abdominal wall contribute for the anterior wall of rectus sheath. The contents of rectus sheath are two muscles, two arteries and six nerves.

JAYPEE BROTHERS

for detailed information on anatomy books, visit our website **www.jaypeebrothers.com,** for detailed information on anatomy books, visit our web

Inderbir Singh's Textbook of ANATOMY

Salient Features

- Simple language and presentation of material in the form of points for ease of understanding, remembering and reproduction by the students
- Simplified presentation in the form of flowcharts, tables and several images for better perception, comprehension and presentation in the examination
- Simplification and organization of content under several subheadings to motivate the students to read the subject in a sequence
- Organization of book into various chapters with each chapter presenting all the relevant components that has to be followed for continuity at one place like all arteries of that part in one chapter
- Clinical importance of each structure was presented in boxes for greater emphasis on clinical application of anatomical knowledge
- Dissection of the region wherever required is explained in brief in a separate box
- Osteology of individual bones in limbs and thorax are presented in a novel way with description of general features in text form and the muscular attachments in table format for easy reference
- Take home message for each chapter to recap the highlights of that chapter was done
- Greater emphasis on clinical application of anatomical knowledge by providing case scenarios with explanation
- Mnemonics given in respective chapters are close to the students, for easy to remembering and recall
- To motivate the students in this direction almost all chapters are provided with real-time case scenarios and explanations to introduce the anatomical basis for the clinical practice.

V Subhadra Devi MS (Anatomy) is Professor and Head, Department of Anatomy, Sri Padmavathi Medical College for Women (SPMCW); Sri Venkateswara Institute of Medical Sciences (SVIMS) University, Tirupati, Andhra Pradesh, India, and Ex-Vice Principal (Academic), Professor and Head, Department of Anatomy, Sri Venkateswara Medical College, Tirupati. She did her graduation and postgraduation from Sri Venkateswara Medical College, Tirupati. She has a teaching and research experience of over 38 years. Her students are spread all over the globe. She has to her credit 70 publications in national and international journals. She is the author of Textbook of Basic Histology – A Color Atlas and Text, Textbook of General Anatomy and edited the 11th edition of Inderbir Singh's Textbook of Embryology.

She is a recipient of Andhra Pradesh State Meritorious Teacher Award. She is a life member of Anatomical Society of India, Society of Clinical Anatomists, Basic Sciences Association and Indian Society of Human Genetics. She is also Honorary Editor-in-Chief for International Journal of Anatomy and Research and editorial board member in various national and international journals.

Printed in India

Available at all medical bookstores
or buy online at www.jaypeebrothers.com



JAYPEE BROTHERS
Medical Publishers (P) Ltd.
EMCA House, 23/23-B, Ansari Road,
Daryaganj, New Delhi - 110 002, INDIA
www.jaypeebrothers.com

Join us on facebook.com/JaypeeMedicalPublishers

Shelving Recommendation
ANATOMY

