pedic books, visit our website www.jaypeebrothers.com, for detailed information on orthopedic book

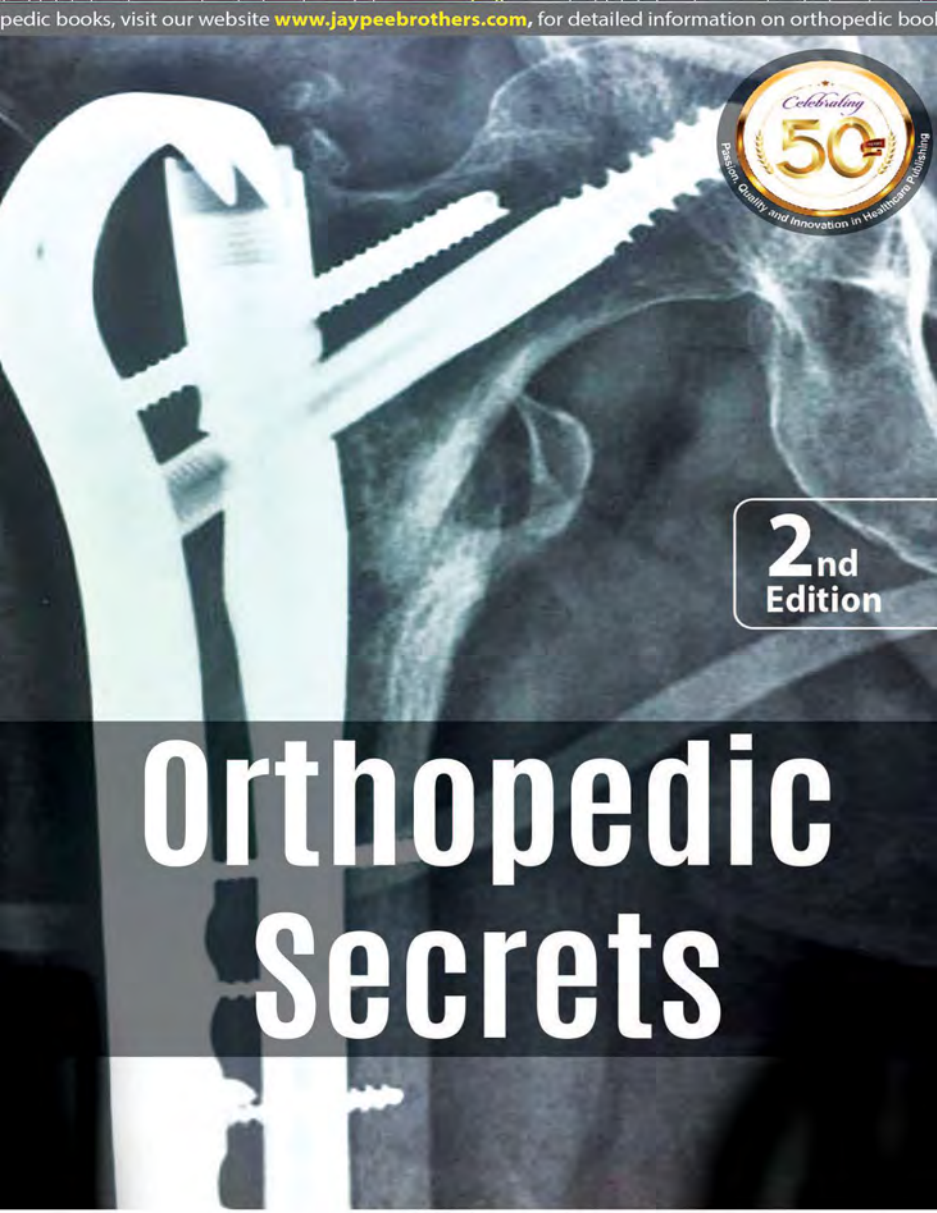

Orthopedic Secrets

DD Tanna

JAYPEE

Contents

1. **Day-to-day Problems 1**
   DD Tanna
   - Exercise Helps.....1
   - Problem.....1
   - Shoulder Mobilizing Exercises 3
   - Gait Correction 4
   - Seroma Collection 6
   - Procedure.....7
   - Cerebrospinal Fluid Leak.....8
2. **Bisphosphonate-induced Fractures 9**
   DD Tanna
3. **Out of Box Surgeries which has Worked in my Hands 20**
   DD Tanna
4. **Coccydynia 33**
   DD Tanna
5. **Comminuted Fracture 41**
   DD Tanna
6. **Distal Transverse Medial Malleolus Fracture 52**
   DD Tanna
7. **Head is Stronger than Machines (Investigations) 58**
   DD Tanna
   - Prolapsed Intervertebral Disc.....58
   - Sternoclavicular Swelling.....59
   - Synovial Herniation Pit of Femoral Neck.....62
   - Acetabular Tuberculosis 67
   - Enchondroma of Femoral Head.....69
   - Pain in Inguinal Area.....73
   - Post-pregnancy Pain in Both Hips 79
   - Pain in Hip Unexplained.....82
   - Infection after 15 years.....82

8. Implant Removal..... 86
DD Tanna
- Austin Moore Removal.....86
- Dynamic Hip Screw Removal.....93
- Humerus Plate Removal.....95
- Broken Nail Removal.....96
- Broken Screw Removal.....102

9. Interesting Cases..... 116
DD Tanna
- Case 1: Undisplaced Femur Neck Fracture.....116
- Case 2: Conservative Treatment of Femur Neck Fracture.....120
- Case 3: Waddling Gait.....124
- Idiopathic Osteoporosis of Head of Femur.....126
- Tip of Ulna Fracture.....128

10. Intramedullary Fibula for Treatment of Nonunion Long Bones..... 136
DD Tanna
- Complications.....162

11. Syndesmotic Injury and Ankle Fracture..... 168
DD Tanna

12. Posterior Malleolus..... 179
DD Tanna

13. Elbow Dislocation with Irreparable Fracture of Head of Radius..... 183
DD Tanna

14. Reamer/Irrigator/Aspirator (RIA) System: Use with induced Membrane to Fill-up Bone Defects..... 192
RM Chandak

15. J Nail Fixation for Surgical Neck Humerus Fractures in Elderly Osteoporotic Bones..... 202
RM Chandak
- Planning J nail Placement.....206

- Case I 209
- Case II 210
- Case III 211

16. Screw Intramedullary Nail in Adult Forearm Fractures: New Concept 213
Wasudeo Gadegone
- The Design of the Screw Intramedullary Nail.....213
- Surgical Technique 214
- Pitfalls and Pearls 219

17. Humerus Nailing in Lateral Position 222
Wasudeo Gadegone
- Operative Technique 222
- Advantages of Lateral Position 228
- Pearls and Pitfalls 229

18. Screw Intramedullary Fixation of Displaced Clavicle Fractures..... 230
Wasudeo Gadegone
- Implant Design 230
- Step-by-step Description of Surgical Technique 231
- Advantages 234
- Pitfalls and Challenges 234

Index 237

Chapter
4

Coccydynia

DD Tanna

Pain in coccyx is very troublesome at times. Soft cushion is the only possible treatment advised, which partially works. Fortunately most often pain in coccyx subsides over a due course of time and needs no further treatment. It is seen more often after delivery and after a fall on stairs and landing on buttocks (Figs. 4.1A and B). One must be careful in diagnosis, as it is presented often as a disguised pilonidal sinus.

- Most of the coccydynia subside with time, all they need is a soft cushion for sitting (Fig. 4.2). They get more pain on leaning backward (Figs. 4.3A to C). There is hypothesis that in flexion, there is abnormal dural tension, which is relieved on extension, probably the reason why transrectal manipulation works (Fig. 4.4). Pain on sitting on hard surface, no pain on standing or sleeping. Local steroid is not

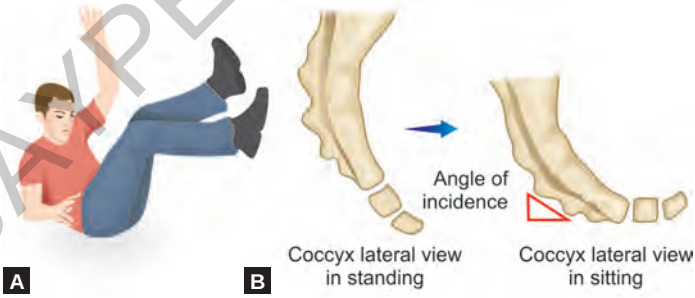

Figs. 4.1A and B: (A) Fall on buttocks gives fracture of coccyx; (B) Angulation of coccyx.

JAYPEE BROTHERS



Fig. 4.2: Use soft cushion while sitting.

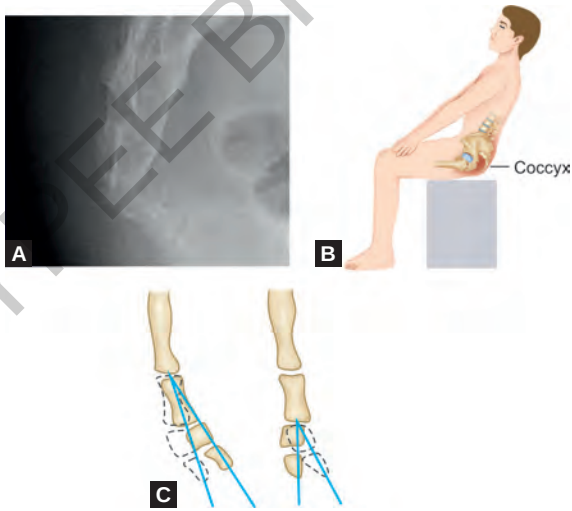

Figs. 4.3A to C: (A) Injury of coccyx; (B) More pain on leaning backward; (C) Movements of coccyx on leaning give pain.

JAYPEE BROTHERS

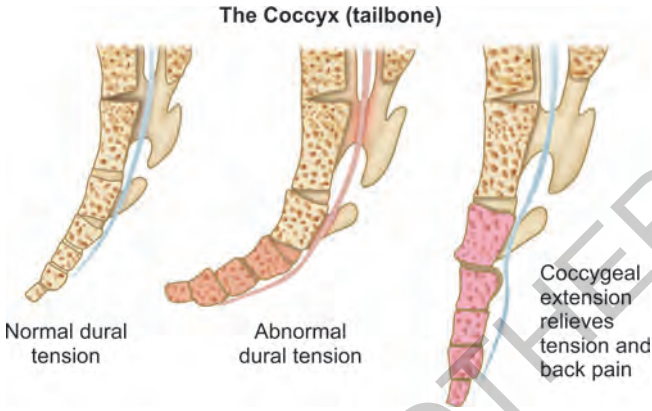

Fig. 4.4: Abnormal dural tension on flexion of coccyx. Probably the reason why transrectal manipulation works.



Fig. 4.5: Some people claim, local injection gives relief, I feel chances of infection are higher in this area, I never do it.

helpful and may give local infection; I never do it (Fig. 4.5). Recalcitrant cases do need excision of coccyx. Before going for surgery, wait for a year, for pain to settle down. Most will

JAYPEE BROTHERS

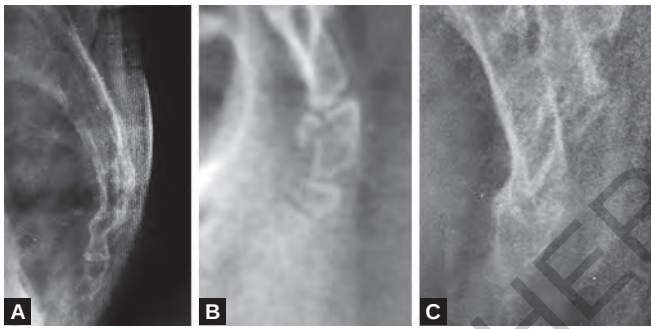

Figs. 4.6A to C: Most will settle down in about 1 year time.

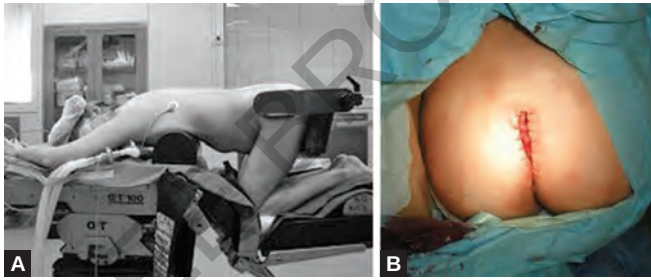

Figs. 4.7A and B: Knee chest position—two views.

be ok in 1 year (Figs. 4.6A to C). If still uncomfortable, excision of coccyx is a possible way forward. Surgery of excision of coccyx is done in knee-chest position (Figs. 4.7A and B). Adrenaline injection is used to improve vision. Remain on bone in center before injection, do not stray on side of bone. Cut the skin and go up to bone, remaining all along on the bone. Remove periosteum and feel the bone. One can see

JAYPEE BROTHERS

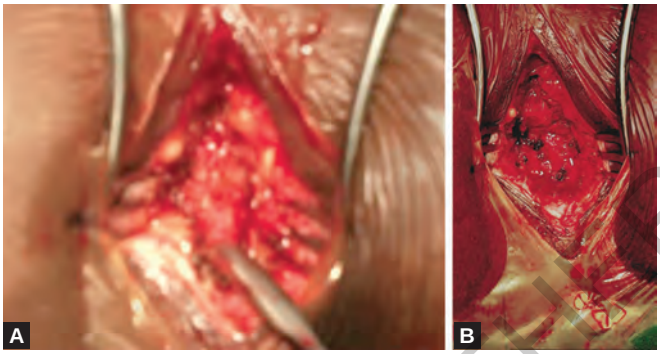

Figs. 4.8A and B: After exposure, movements of the loose piece of coccyx can be felt.

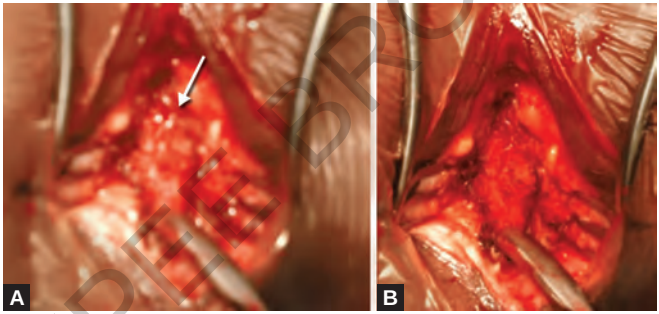

Figs. 4.9A and B: Movements at pseudo-joint, enter from this space (arrow).

the area of movements between two pieces of coccyx (Figs. 4.8A and B). Enter this area from the proximal side, hold the coccyx with towel, clip, and create a space between bone and soft tissue, anterior to the coccyx bone, hugging the bone all the time to avoid injury to rectum (Figs. 4.9 to 4.13).

JAYPEE BROTHERS

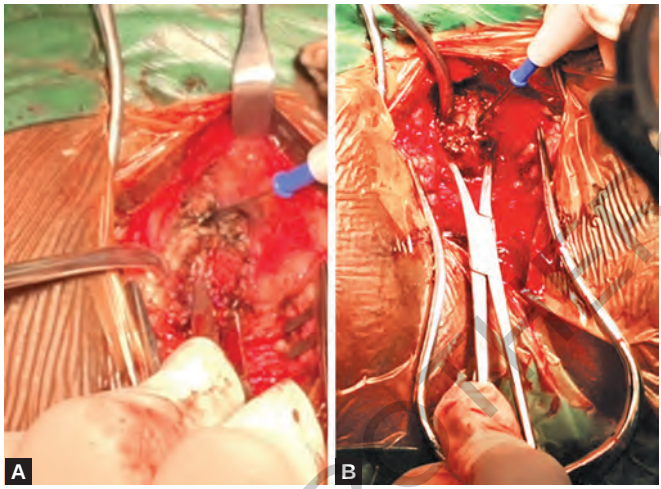

Figs. 4.10A and B: Hold with towel clip and clear this piece all around, hugging the bone to avoid injury to rectum.

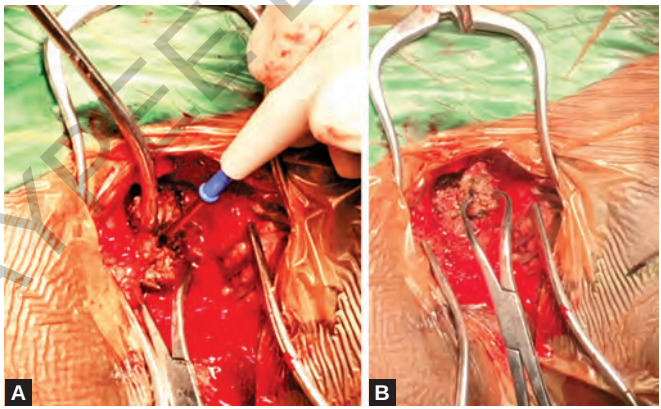

Figs. 4.11A and B: Dissection around bone. Excised coccyx in towel clip.

JAYPEE BROTHERS

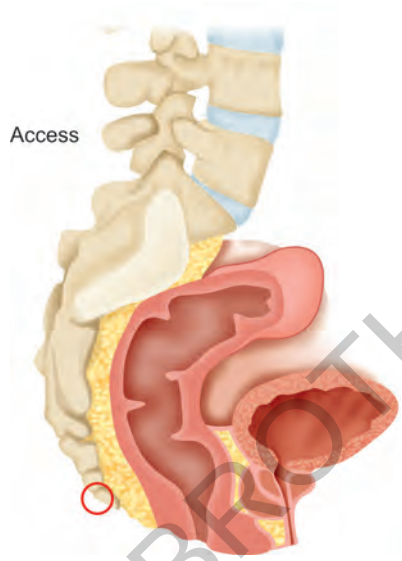

Fig. 4.12: Rectum is nearby.

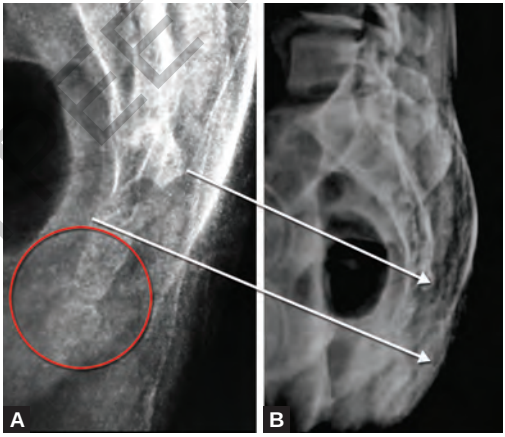

Figs. 4.13A and B: (A) Before surgery loose coccyx piece; (B) After surgery, it is excised.

JAYPEE BROTHERS



Fig. 4.14: Postoperative use cushion while sitting.

Burn every bleeding spot before closure. Subcutaneous tight closure is done, before skin closure. Water-tight dressing done, otherwise skin gets open out when patient is sitting. Use cushion while sitting. Induce constipation for 2 days. Skin closure with sutures, only after subcutaneous closure, so no skin tension. Water-tight dressing, otherwise skin gets open out when patient is sitting of wound. Use cushion while sitting (Fig. 4.14).

JAYPEE BROTHERS

for detailed information on orthopedic books, visit our website www.jaypeebrothers.com, for detailed i

Orthopedic Secrets

Salient Features

- Includes interlocking with lag screw in long oblique fractures—long bone fractures
- Contains alternative to radius head replacement
- Discusses some of the day-to-day problems and their approaches such as tennis elbow, calspur, calcification in soft tissue, meralgia, and unresolved coccyx pain, etc.

DD Tanna MS (Ortho) is an Orthopedic Surgeon who has retired as Professor from BYL Nair Hospital, Mumbai, Maharashtra, India. He is the Honorary Consultant in Jaslok, Bhatia, Saifee and Sir HN Reliance Foundation Hospitals in Mumbai.

He is actively involved in teaching, mainly orthopedic surgeons all over India. He has written two other books on orthopedics: *Interlocking Nailing* (4th edition), which has become the textbook of interlocking nailing in India; and *Proximal Femur Fractures*. He has also contributed chapters in *Textbook of Orthopedics*, which is an official textbook of All India Orthopedic Associations. He has written innumerable articles and given a plenty of orations all over India.

Available at all medical bookstores
or buy online at www.jaypeebrothers.com



JAYPEE BROTHERS
Medical Publishers (P) Ltd.
www.jaypeebrothers.com

Join us on facebook.com/JaypeeMedicalPublishers

Shelving Recommendation
ORTHOPEDICS

