brothers.com, for detailed information on neurology books, visit our website www.jaypeebrothers.com, for detailed information on neurology books

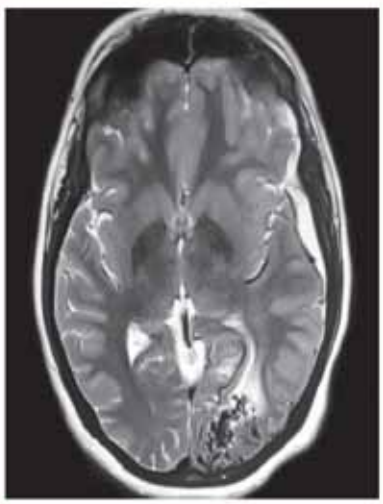

Celebrating 50 Passion, Quality and Innovation in Healthcare Publishing

Series III

Practice Pearls in NEUROLOGY

Bhanu Kesavamurthy • D Vasudevan • AV Srinivasan

Foreword
Padma Shri Professor CU Velmurugendran

JAYPEE

CONTENTS

1. **Neurological Manifestations of Renal Diseases** 1
   Philo Hazeena, Bhanu Kesavamurthy

2. **Approach to Visual Loss** 7
   Chandramouleeswaran Venkatraman, Balasubramanian Samivel, Jawahar Marimuthu

3. **Idiopathic Intracranial Hypertension** 15
   Thangaraj M, Jayasankar VR, Shameer Palliyali

4. **Role of Optical Coherence Tomography in Neurology** 27
   Ambika Selvakumar, Swetha Komma

5. **Trigeminal Neuralgia: An Overview** 51
   S Saravanan

6. **Bell's Palsy: An Update on Etiology, Clinical Features and Multidisciplinary Care** 56
   Bhanu Kesavamurthy, Senthilnathan, AV Srinivasan

7. **Approach to Brachial Plexopathies** 62
   D Vasudevan

8. **Anticoagulation in Neurology: Latest Perspectives and Therapeutic Dilemmas** 67
   Anusha Doraiswamy

9. **Neurogenic Dysphagia: A Comprehensive Approach** 82
   Vinothkanna Selvaraj, Bhanu Kesavamurthy

10. **Early Parkinson's Disease: Essentials of Diagnosis and Management** 90
    Kala Venkiteswaran, Vikram Shivkumar, Thyagarajan Subramanian

11. **Levodopa-induced Dyskinesias** 100
    Pranesh Bheemarao Madakasira, Venkatesan Rajmohan, Ebin Siby

12. **Approach to Falls and Freezing in Parkinson's Disease** 104
    Harish Jayakumar, Bhanu Kesavamurthy, AV Srinivasan

13. **Continuous Dopaminergic Stimulation in Parkinson's Disease** 115
    Anil Venkatachalam

14. **Parkinson-plus Syndromes: Clinical Features and Management** 123
    Vikram Shivkumar, Dipali Nemade, AV Srinivasan

Index 131

JAYPEE BROTHERS

CHAPTER 6

Bell's Palsy: An Update on Etiology, Clinical Features and Multidisciplinary Care

Bhanu Kesavamurthy, Senthilnathan, AV Srinivasan

JAYPEE BROTHERS

INTRODUCTION

Bell's palsy is defined as an acute onset peripheral facial neuropathy with no identifiable cause. It is the most common cause of lower motor neuron type of facial palsy encountered in the clinical setting.[1] It clinically presents as a rapid onset and unilateral lower motor neuron type of facial weakness. Associated symptoms could be postauricular pain, dysgeusia, subjective facial sensory disturbances, and hyperacusis. There can be associated changes in lacrimation and salivation due to involvement of parasympathetic fibers and disturbances of taste sensation due to involvement of special sensory fibers.[2] It progresses rapidly reaching peak of disability in 48–72 hours. Etiopathogenesis of Bell's palsy is still not clear with infection (herpes simplex type I); compression of nerve and autoimmune-mediated inflammation been postulated as some of the causes.

ANATOMY

Facial nerve is the seventh cranial nerve. It is a mixed nerve; it has motor, sensory and parasympathetic functions. All the three nucleus are located at pons. The fibers of motor root wind around the abducent nucleus and exit the brainstem. The course of facial nerve is divided into intracranial and extracranial portion. After exiting from brainstem at pontomedullary junction the nerve enters internal acoustic meatus where it is closely associated with vestibulocochlear nerve. The intratemporal portion of facial nerve gives rise to greater petrosal nerve, nerve to stapedius and chorda tympani branches, and exits the skull through stylomastoid foramen. Extracranially the nerve passes through parotid gland. Facial nerve gives two branches, namely posterior auricular nerve and nerve to posterior belly of digastric before dividing into its terminal branches. The terminal branches are temporal, zygomatic, buccal mandibular and cervical branches. In its entire course facial nerve forms multiple connections among its own branches and also with adjacent cranial nerves like trigeminal, vestibular, glossopharyngeal and vagal nerves. Because of these communications there can be associated features like altered facial sensation, vestibular dysfunction, and pharyngeal dysfunction in Bell's palsy.[3] Motor component of facial nerve predominantly supplies muscles of facial expression, sensory fibers carry taste sensation, and parasympathetic part controls secretions of lachrymal and salivary gland (Fig. 1).

HISTORY

The anatomy and function of facial nerve was first described by Sir Charles Bell in 1800. His initial description of facial palsy was secondary to trauma of peripheral branches, but his description of the condition led to a rapid rise in the number of publication on idiopathic facial palsy that came to be known as Bell's palsy. The

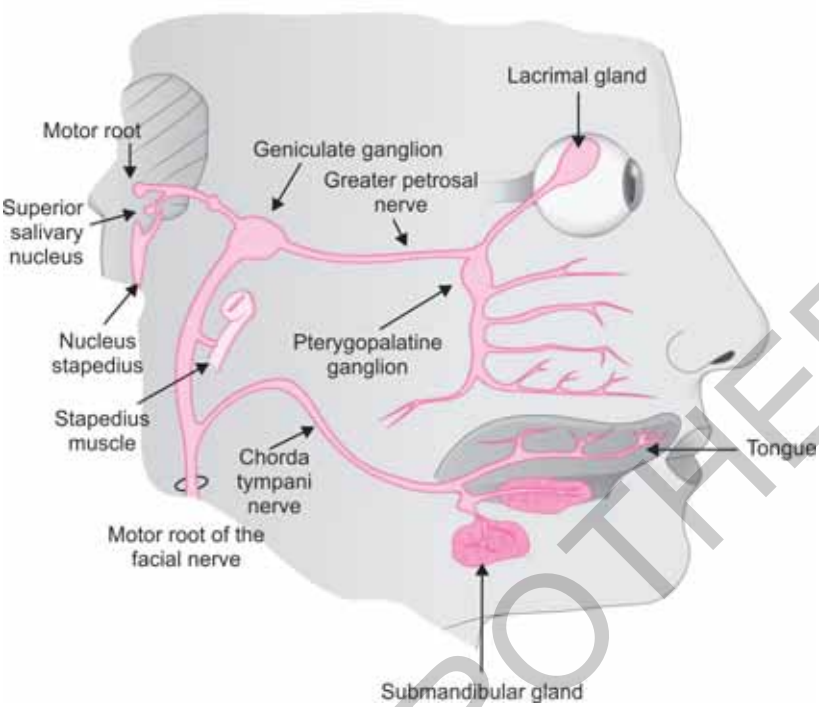

FIG. 1: Anatomy of facial nerve.

description of facial palsy was seen in European medical text as ancient as 5th Century BC.[4] Many famous clinicians also have recognized this condition like Sydenham, Friedrich and Douglas.[5]

EPIDEMIOLOGY

Bell's palsy is the most common isolated cranial mononeuropathy seen in clinical practice with an incidence ranging from 11.5 to 40.2 per 1,00,000 population.[6] It affects males and females equally across all age groups, with a slightly higher incidence seen in mid- and later-life. The incidence of Bell's palsy is common during pregnancy and following viral upper respiratory infection. The incidence is also higher among immune compromised patients and patients with diabetes mellitus and hypertension.

ETIOLOGY

There are extensive works done in identifying the possible cause of this condition. Infection, immune-mediated reaction, and ischemia are implicated in the pathogenesis of this condition. Among infections herpes simplex virus 1 (HSV-I) has been extensively studied and recorded. McCormick first postulated reactivation of HSV-I infection around geniculate ganglion as possible cause.[7] It was also supported by demonstration of HSV-I in endoneural fluid collected from intratemporal facial nerve. But the above claim could not be justified by other studies on cause-effect relationship between the presence of HSV-I and development of Bell's palsy. Other infections implicated in pathogenesis of Bell's palsy include cytomegalovirus, Epstein-Barr virus, rubella, influenza B, adenovirus and coxsackie virus.[8] The role of infection in pathogenesis of Bell's palsy is supported by histopathological study of the nerve that shows inflammation, secondary to infection. The nerve appeared thickened, edematous with inflammatory cells around nerve bundles and intraneural blood vessels. There is extensive degeneration of myelin sheath. The damages are seen in greater

JAYPEE BROTHERS

extent in labyrinthine part of facial nerve which is more prone to compression and ischemia.[9] Another possible mechanism is cell-mediated immune response against myelin which is supported by presence of T and B lymphocytes, elevated chemokine levels, and in vitro reactivity to myelin protein seen in blood samples of Bell's palsy patients.

CLINICAL FEATURES

Bell's palsy usually presents as sudden onset unilateral facial weakness in the form of sagging of eyebrows, inability to close the affected eye lid, and Bell's phenomenon—up-rolling of eye balls seen on attempted closure of eyelids, disappearance of nasolabial fold, and deviation of angle of mouth on unaffected side. Other features like decreased lacrimation, hyperacusis and loss of taste sensation over anterior two-thirds of tongue may be present in severe cases. All the muscles of facial expression are affected unilaterally in peripheral nerve lesion, whereas supranuclear or upper motor neuron type of facial weakness typically spares the upper half of face as it receives supranuclear fibers from both the hemispheres. Symptoms progress over days and reach maximum deficit by 72 hours (Fig. 2).[10]

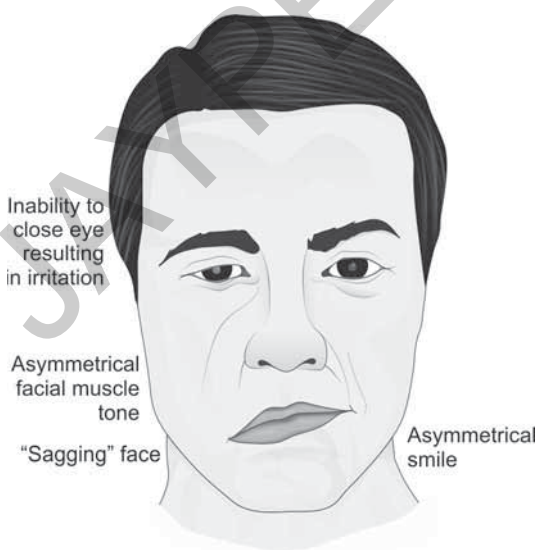

FIG. 2: Clinical features.

INVESTIGATIONS

Electrodiagnostic Tests

Bell's palsy is a clinical diagnosis. Investigations are usually done to rule out other causes and to determine the prognosis. Electrodiagnostic tests help to determine the outcome or prognosis. Motor nerve conduction study of the facial nerve is done by giving supramaximal stimulus near parotid and the CMAP (compound muscle action potential) amplitude obtained correlates with degree of nerve injury. For example, if the CMAP amplitude obtained is 10% of the normal, it indicates that 90% of nerves are affected and hence poor prognosis. Muscles usually studied are orbicularis oculi, nasalis and lower facial muscles. Patients having greater than 90% reduction of CMAP potential compared to normal side in the first 10 days of onset have poor prognosis in the form of prolonged course and incomplete recovery where surgical intervention can be tried.[11]

Another electrophysiological test is blink reflex which is done by stimulation of supra-orbital nerve. It helps to confirm whether the lesion is peripheral and not central and degree of axonal conduction block. Electromyograph is done for clinically complete lesion, to know if the continuity of the nerve still exists, and to prognosticate.[12]

Imaging Studies

As mentioned earlier Bell's palsy is a clinical diagnosis. Imaging can be done if patients present with atypical clinical signs when there is progression beyond 3 weeks or no clinical improvement after 4 months. Preferred imaging techniques are contrast-enhanced high resolution CT or gadolinium-enhanced magnetic resonance imaging (MRI). Apart from brain parenchyma, temporal bone and parotid gland are also to be screened for any tumors. More than two-thirds of patients show pathological enhancement of nerve at the tympanic-mastoid segment within facial canal. Lack of enhancement is considered as a good prognostic sign.[13]

JAYPEE BROTHERS

Differential Diagnosis

Bell's palsy is a diagnosis of exclusion. All lower motor neuron types of facial weakness must be assessed properly to rule out other causes before jumping to the conclusion of Bell's palsy. Some important causes for lower motor neuron type of facial paresis include infection [commonly varicella zoster, Lyme disease, tuberculosis and human immunodeficiency virus (HIV)], traumatic, inflammatory (sarcoidosis, Sjögren's syndrome, vasculitis and other autoimmune disorders), neoplastic (parotid gland tumor, facial nerve schwannoma and acoustic neuroma), and stroke (Table 1).[14]

GRADING

The serenity of facial palsy is graded commonly by House–Brackmann's grading (Table 2).[15] Other widely used grading is Facial Nerve Grading Scale or Sunny Brook System.[16]

Table 1: Differential diagnosis for LMN facial palsy.

Recurrent facial palsy	• Schwannoma, parotid gland tumor, temporal bone or cerebello pontine angle tumors
Bilateral facial palsy	• Guillain-Barre syndrome, lymphoma, malignant pachymeningitis, leptomeningeal carcinomatosis, cryptococcal meningitis/HIV/Lyme disease • Sarcoidosis and Wegener's granulomatosis
Facial palsy syndromes	• Ramsay Hunt syndrome—Peripheral facial palsy with vesicular rashes in ear and mouth caused by varicella zoster • Melkersson–Rosenthal syndrome—recurrent facial palsy with orofacial edema and fissured tongue • Heerfordt–Waldenstrom syndrome—facial palsy with parotid enlargement, anterior uveitis and fever. It is uncommon manifestation of sarcoidosis

TREATMENT

Traditionally Bell's palsy patients were treated with corticosteroids and acyclovir. Oral glucocorticoids are the mainstay of medical management of Bell's palsy. It reduces inflammation. Guidelines of American Academy of Neurology reinforce the role of corticosteroids in treatment of Bell's palsy.[17] However, they argue against the use of antiviral in routine cases. The oral steroids started with 72 hours of onset, has shown better results. A systemic review, published in Cochrane database in 2013, recommends 50 mg of Prednisone for 10 days or 60 mg for first 5 days, then taper it by 10 mg each day for next 5 days.[18] Both the regimens are equally efficacious. The rationale for giving antiviral stems from the studies that showed possible role of HSV-I in pathogenesis of facial palsy, but studies have failed to prove the role of antiviral in recovery of Bell's palsy. In a meta-analysis of 18 trials, glucocorticoid alone was shown to have better results rather than antivirals alone or combination of both. Antivirals that have been tried are acyclovir and valacyclovir. They are especially useful in Ramsay Hunt syndrome. The role of combined corticosteroid with antivirals in the management of severe cases is under study.

Eye Care

Frequent and effective eye blinking is necessary to spread the tears uniformly across conjunctiva. Lacrimation occurs at lateral part and is swept to medial by the blinking and eye closure which occurs by contraction of orbicularis oculi. In the absence of frequent and effective blinking there is dryness of conjunctiva which leads to keratitis and corneal ulceration that may even threaten the eye sight. Effective protection is offered by wrapped sunglasses, lubrication with artificial tear drops or ointments, and closure of eyelids using tapes at night. Early use of eyelid weight is recommended for elderly, diabetic patients, and those under pre-existing eye disease.[19]

JAYPEE BROTHERS

Table 2: House–Brackmann's grading.

1	Normal	• Normal facial function in all areas
2	Mild dysfunction	• Slight weakness noticeable only on close inspection • At rest—normal symmetry of forehead, ability to close eye with minimal effort and slight asymmetry, ability to move corners of mouth with maximal effort and slight asymmetry • No synkinesis, contracture or hemifacial spasm
3	Moderate dysfunction	• Obvious, but not disfiguring difference between two sides, no functional impairment • At rest—normal symmetry and tone • Motion—slight-to-no movement of forehead, ability to close eye with maximal effort and obvious asymmetry, ability to move corners of mouth with maximal effort and obvious asymmetry • Patients who have obvious but no disfiguring synkinesis, contracture and/or hemifacial spasm are grade III regardless of degree of motor activity
4	Moderately severe dysfunction	• Obvious weakness and/or disfiguring asymmetry • At rest—normal symmetry and tone • Motion–no movement of forehead; inability to close eye completely with maximal effort • Patients with synkinesis, mass action and/or hemifacial spasm severe enough to interfere with function are grade IV regardless of motor activity
5	Severe dysfunction	• Only barely perceptible motion • At rest—possible asymmetry with droop of corner of mouth and decreased or absence of nasal labial fold • Motion—no movement of forehead, incomplete closure of eye and only slight movement of lid with maximal effort, slight movement of corner of mouth • Synkinesis, contracture and hemifacial spasm usually absent
6	Total paralysis	• Loss of tone; asymmetry; no motion; no synkinesis, contracture, or hemifacial spasm

Oral Care

Loss of sphincter function due to weakness of orbicularis oris leads to oral incontinence and predisposes to lip and inner cheek abrasion and later to ulceration. Use of straw for liquids and strategic eating and avoiding hard food substances along with physiotherapy help the patients to overcome this difficulty.

Physiotherapy

Physiotherapy helps in motor recovery, especially those with hypotonia, hyperkinesia or synkinesis, and patients with incomplete recovery. Modalities include heat therapy, massage, electrostimulation, mime therapy and biofeedback.[20]

Prognosis

Prognosis is usually good with approximately 85% of patients having good recovery in just 3 weeks. Some of the predictors of poor recovery are severe deficit at onset, duration between start of palsy to onset of recovery and persistent pain. Patient with complete facial palsy (grade 5–6) in whom there is no marked recovery in first 3–4 months is more likely to have incomplete recovery. When steroid is given early improved outcome is noted in over 90% of patients.[21]

Synkinesis

It is an abnormal facial contraction that occurs during vocational facial movements post-recovery. It occurs due to aberrant reinnervations

JAYPEE BROTHERS

of facial musculature post-nerve injury. There is an involuntary eye closure during movements like eating or smiling (oro-ocular synkinesis). Other synkinesis like occulo-oral synkinesis (lip movement on eye closure) or chin dumpling during facial movements are also noted following nerve injury. Management includes physiotherapy, biofeedback exercises, and chemodenervation by injecting botulinum toxin to the problem areas.[22]

Facial Reanimation

Role of surgical correction of deformities has been studied widely. In the case of incomplete recovery various techniques can be tried like nerve to nerve transfer and regional or free tissue transfer. These techniques help to restore facial movements and add to cosmetic effect too. In regional tendon transfer, temporalis muscle tendon is relocated to oral commissure to give esthetic look. Other technique is to use the gracilis muscle with nerve coaptation from contralateral facial nerve or ipsilateral trigeminal nerve (mandibular branch). Nerve to nerve transfer technique is used with preserved facial musculature but a frozen oral commissure. Donor nerves, which are harvested from trigeminal nerve (masseteric branch) and facial nerve from opposite side are also being tried. These reconstructive procedures, though complex, help in smile reanimation and subsequent benefits in social functioning and quality of life.[23]

REFERENCES

1. Peitersen E. Bell's palsy: the spontaneous course of 2,500 peripheral facial nerve palsies of different etiologies. Acta Otolaryngol Suppl. 2002;(549):4-30.
2. Adour KK, Byl FM, Hilsinger RL Jr, et al. The true nature of Bell's palsy: analysis of 1,000 consecutive patients. Laryngoscope. 1978;88(5)787-801.
3. Diamond M, Wartmann CT, Tubbs RS, et al. Peripheral facial nerve communications and their clinical implications. Clin Anat. 2011;24(1):10-8.
4. Canalis RF, Cino L. Ceramic representations of facial paralysis in ancient Peru. Otol Neurotol. 2003;24(5): 828-31.
5. Sajadi MM, Sajadi MR, Tabatabaie SM. The history of facial palsy and spasm: hippocrates to Razi. Neurology. 2011;77:174-8.
6. De Diego JI, Prim MP, Madero R, et al. Seasonal patterns of idiopathic facial paralysis: a 16-year study. Otolaryngol Head Neck Surg. 1999;120(2): 269-71.
7. McCormick DP. Herpes-simplex virus as cause of Bell's palsy. Lancet. 1972;1(7757):937-9.
8. Morgan M, Nathwani D. Facial palsy and infection: The unfolding story. Clin Infect Dis. 1992;14(1):263-71.
9. Liston SL, Kleid MS. Histopathology of Bell's palsy. Laryngoscope. 1989;99(1):23-6.
10. Croxson GR. The assessment of facial nerve dysfunction. J Otolaryng Soc Austral. 1990;4:252-63.
11. Valls-Solé J. Electrodiagnostic studies of the facial nerve in peripheral facial palsy and hemifacial spasm. Muscle Nerve. 2007;36(1):14-20.
12. Somia NN, Rash GS, Epstein EE, et al. A computer analysis of reflex eyelid motion in normal subjects and in facial neuropathy. Clin Biomech (Bristol, Avon). 2000;15(10)766-71.
13. Martin-Duverneuil N, Sola-Martínez MT, Miaux Y, et al. Contrast enhancement of the facial nerve on MRI: normal or pathological? Neuroradiology. 1997;39(3):207-12.
14. Croxson G, Coulson SE, Mukherjee P. Mistaken diagnoses in Facial Nerve Disorders [Conference Presentation]. 12th International Facial Nerve Symposium. Boston: 2013.
15. House JW, Brackmann DE. Facial nerve grading system. Otolaryngol Head Neck Surg. 1985;93(2):146-7.
16. Ross BG, Fradet G, Nedzelski JM. Development of a sensitive clinical facial grading system. Otolaryngol Head Neck Surg. 1996;114(3):380-6.
17. Gronseth GS, Paduga R; American Academy of Neurology. Evidence-based guideline update: steroids and antivirals for Bell palsy: report of the Guideline Development Subcommittee of the American Academy of Neurology. Neurology. 2012;79(22):2209-13.
18. Salinas RA, Alvarez G, Daly F, et al. Corticosteroids for Bell's palsy (idiopathic facial paralysis). Cochrane Database Syst Rev. 2010;(3):CD001942.
19. Hohman MH, Hadlock TA. Etiology, diagnosis, and management of facial palsy: 2000 patients at a facial nerve center. Laryngoscope. 2014;124(7):E283-93.
20. Lindsay RW, Robinson M, Hadlock TA. Comprehensive facial rehabilitation improves function in people with facial paralysis: a 5-year experience at the Massachusetts Eye and Ear Infirmary. Phys Ther. 2010;90(3):391-7.
21. Sullivan FM, Swan IR, Donnan PT, et al. Early treatment with prednisolone or acyclovir in Bell's palsy. N Engl J Med. 2007;357(16):1598-607.
22. Hohman MH, Lee LN, Hadlock TA. Two-step highly selective neurectomy for refractory periocular synkinesis. Laryngoscope. 2013;123(6):1385-8.
23. Labbé D, Bénateau H, Bardot J. Surgical procedures for labial reanimation in facial paralysis. Ann Chir Plast Esthet. 2002;47(5):580-91.

JAYPEE BROTHERS

for detailed information on neurology books, visit our website www.jaypeebrothers.com, for detailed information on neurology books, visit our web

Practice Pearls in NEUROLOGY

Key Features

- The book presents with a concise yet comprehensive clinical approach to common neurological disorders
- Focuses on key aspects of clinical diagnosis, investigations and treatment which make a significant impact on the management of the patient
- Dedicated chapters on Trigeminal Neuralgia, Approach to Brachial Plexopathies, and Bell's Palsy have been discussed in detail
- Text is enriched with relevant tables, algorithms and figures
- Written by experts with vast knowledge and experience in this field
- A must-read book for practicing neurologists, physicians and postgraduate students.

Bhanu Kesavamurthy DNB DM FMMC FRCP
Director of Neurosciences, Mehta's Hospital Pvt. Ltd.
Chennai, Tamil Nadu, India
Former Director, Institute of Neurology, Madras Medical College and
Government General Hospital
Chennai, Tamil Nadu, India

D Vasudevan MD DM
Professor and Head, Department of Neurology
Saveetha Medical College
Chennai, Tamil Nadu, India
Senior Consultant Neurologist
The Brain, Spine and Nerve Centre
Chennai, Tamil Nadu, India

AV Srinivasan MD DM PhD FAAN FIAN DSc (Hon) FRCP (Lon)
Emeritus Professor, The Tamil Nadu Dr MGR Medical University
Former Head and Professor of Neurology
Institute of Neurology, Madras Medical College
Chennai, Tamil Nadu, India

Available at all medical bookstores
or buy online at www.jaypeebrothers.com



JAYPEE BROTHERS
Medical Publishers (P) Ltd.
www.jaypeebrothers.com

Join us on facebook.com/JaypeeMedicalPublishers

Shelving Recommendation
NEUROLOGY

