www.jaypeebrothers.com, for detailed information on ophthalmology books, visit our website www.jaypeebrothers.com

OPHTHALMOLOGY



OPHTHALMOLOGY

Solved Question Papers

Fourth Edition

Singi Yatiraj

Foreword
Santosh Patil



Contents

1. MBBS Phase III Examination – December 2007 (Revised Scheme 2) 1
2. MBBS Phase III Examination – June 2008 (Revised Scheme 2) 18
3. MBBS Phase III Examination – December 2008 (Revised Scheme 2) 44
4. MBBS Phase III Examination – June 2009 (Revised Scheme 2) 59
5. MBBS Phase III Examination – December 2009 (Revised Scheme 2) 77
6. MBBS Phase III Examination – June 2010 (Revised Scheme 2) 113
7. MBBS Phase III Examination – December 2010 (Revised Scheme 2) 139
8. MBBS Phase III Examination – June 2011 (Revised Scheme 2) 164
9. MBBS Phase III Examination – December 2011 (Revised Scheme 2) 193
10. MBBS Phase III Examination – June 2012 (Revised Scheme 2) 203
11. MBBS Phase III Examination – December 2012 (Revised Scheme 2) 214
12. MBBS Phase III Examination – June 2013 (Revised Scheme 2) 226
13. MBBS Phase III Examination – December 2013 (Revised Scheme 2) 241
14. MBBS Phase III Examination – June 2014 (Revised Scheme 2) 247
15. MBBS Phase III Examination – December 2014 (Revised Scheme 2) 264
16. MBBS Phase III Examination – June 2015 (Revised Scheme 2) 269
17. MBBS Phase III Examination – December 2015 (Revised Scheme 2) 277
18. MBBS Phase III Examination – June 2016 (Revised Scheme 2) 291
19. MBBS Phase III Examination – December 2016 (Revised Scheme 2) 293
20. MBBS Phase III Examination – June 2017 (Revised Scheme 2) 304
21. MBBS Phase III Examination – December 2017 (Revised Scheme 2) 310
22. MBBS Phase III Examination – June 2018 (Revised Scheme 2) 312
23. MBBS Phase III Examination – December 2018 (Revised Scheme 2) 321
24. MBBS Phase III Examination – June 2019 (Revised Scheme 2) 332

Sample Paper 1 347

Sample Paper 2 370

Sample Paper 3 392

Index *407*

MBBS PHASE III EXAMINATION

DECEMBER 2008

(Revised Scheme 2)

JAYPEE BROTHERS

LONG ESSAYS

1. Discuss the differential diagnosis of acute conjunctivitis and how you manage a case of acute conjunctivitis.

Refer Question No. 2 Dec. 2010 (RS2).

2. Describe the etiology, signs, symptoms and management of chronic dacryocystitis.

- Chronic dacryocystitis is a chronic inflammation of the lacrimal sac that usually results from obstruction of the nasolacrimal duct
- More common than acute dacryocystitis.

Etiology

Causative organisms	*Source of infection*
◆ Staphylococci ◆ Pneumococci ◆ Streptococci ◆ *Pseudomonas pyocyanea* ◆ Enterobacter ◆ *E. coli* ◆ Rarely chronic granulomatous inflammations like tuberculosis, syphilis, leprosy and occasionally rhinosporidiosis	◆ Conjunctivitis ◆ Nasal infection ◆ Paranasal sinus abscess

i. Predisposing factors
   - Age: More common between 40–60 years of age
   - Sex: Predominant in females (80%) due to narrow bony canal lumen
   - Race: Rare in Negroes due to shorter, wider and less sinuous
   - Heredity: Affects indirectly by determining the facial configuration, length and width of bony canal
   - Socioeconomic status: Common in low socioeconomic strata
   - Personal hygiene: Poor personal hygiene predisposes

ii. Factors responsible for tear stasis in lacrimal sac
   - Anatomical factors like comparatively narrow bony canal, partial canalization of membranous nasolacrimal duct and excessive membranous folds in nasolacrimal duct
   - Foreign bodies in sac blocking opening of nasolacrimal duct
   - Excessive lacrimation
   - Mild grade inflammation of lacrimal sac may block nasolacrimal duct with epithelial debris and mucus plug
   - Obstruction of lower end of the nasolacrimal duct by nasal diseases like polyps, hypertrophied inferior concha, marked deviated nasal septum (DNS), tumor, atrophic rhinitis, etc.

Pathogenesis

- Blockage of nasolacrimal duct → stasis if tear in lacrimal sac → infection by pyogenic bacteria → dacryocystitis

Clinical Features

- Usually affects females over 40 years of age.

Symptoms	*Signs*
◆ Usually unilateral but may be bilateral ◆ Constant passive overflow of tears (epiphora) over the lid margin ◆ Aggravation of epiphora on exposure to wind ◆ Swelling, pain and redness at the site of sac	◆ Pooling of tears near the inner canthus ◆ Persistent congestion of neighboring conjunctiva, caruncle and skin ◆ Regurgitation of mucopurulent fluid by pressure over the sac ◆ Nontender swelling at the site of sac

Stages

Stage	*Chronic catarrhal dacryocystitis*	*Lacrimal mucocele*[Q]	*Chronic suppurative dacryocystitis*	*Chronic fibrotic sac*
Characteristics	Mild inflammation of the lacrimal sac associated with blockage of nasolacrimal duct	Follows chronic stagnation causing distension of lacrimal sac	Due to pyogenic infection, mucocele is converted into pyocele	Low grade repeated infection for a prolonged period leads to small fibrotic sac due to thickening of mucosa
Manifestation	**Watering eye**[Q] and mild redness in the inner canthus	Constant epiphora and swelling just below the inner canthus	Epiphora and recurrent conjunctivitis and swelling at inner canthus with mild erythema of overlying skin	Persistent epiphora and discharge
Syringing	Regurgitation of clear fluid of few fibrinous mucoid flakes	Regurgitation of milky or gelatinous mucoid fluid	Regurgitation of frank purulent discharge	
Dacryocystography	Block in nasolacrimal duct, normal sized lacrimal sac with healthy mucosa	Distended sac with blockage somewhere in nasolacrimal duct	Distended sac with blockage somewhere in nasolacrimal duct	Very small sac with irregular fold in mucosa

Investigations

- Nasal examination to exclude DNS, abnormal growth and atrophic rhinitis
- Syringing to confirm nasolacrimal duct obstruction and determine stage of disease
- Dacryocystography is a radiological procedure using radiopaque dye like lipiodol, urografin, conray, etc. to outline the lacrimal excretory passage helps find the size of the sac and site of obstruction
- Subtraction macrodacryocystography with canalicular catheterization
- Radioactive tracer containing sulfur instilled into conjunctival sac and its excretion visualized by gamma camera.

Treatment

Conservative

a. Repeated syringing of the nasolacrimal duct and frequent instillation of antibiotic drops
   Principle
   - Reduces swelling of the inflamed mucosa
   - Restores patency of lacrimal excretory passage by clearing epithelial debris

   Indications
   - To confirm nasolacrimal duct obstruction
   - Treatment of recent cases
   - To control infection before any operative procedure

   Procedure
   - Topical local anesthesia of the conjunctival sac with topical 4% xylocaine
   - Dilate the punctum with Nettleship's punctum dilator
   - Using a 5cc syringe with 24–26 gauge cannula, syringe out lacrimal sac 2–3 times with normal saline
   - Instill the antibiotic drops.

JAYPEE BROTHERS

Duration
- Twice daily initially and later twice weekly.

Operative

a. Dacryocystorhinostomy (DCR)
- **Operation of choice[Q] (Gold standard[Q])**

Principle
- A nasal drainage operation which re-establishes the lacrimal drainage by creating a alternative to nasolacrimal duct by **making a connection between lacrimal sac and middle meatus of nose[Q]**

Techniques
- External DCR
- Endolaser DCR
  - Ostium made endoscopically with holmium YAG or KTP laser
  - Has low success rate (~70%)

Indications	*Contraindication*
◆ Chronic dacryocystitis in young and middle aged persons ◆ Mucocele of lacrimal sac	◆ Absolute – Atrophic rhinitis – Tumor of lacrimal sac ◆ Relative – Comorbid conditions (hypertension, diabetes mellitus, bleeding diathesis) – Acute dacryocystitis (cannot be done immediately) – Young children (<4 years) or elderly (dacryocystectomy is preferred)

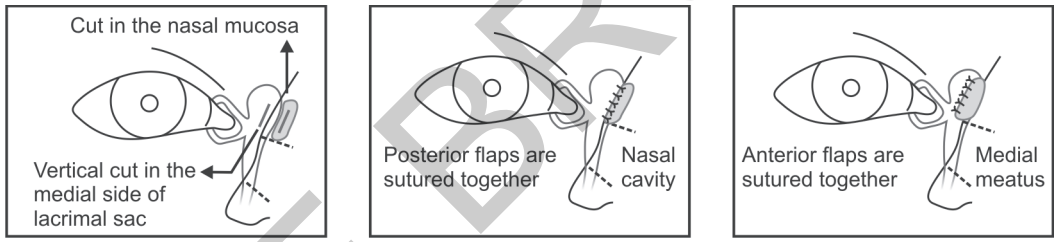

Fig. 1: Dacryocystorhinostomy.

Anesthesia
- Local anesthesia by packing nasal fossa of same side with cocaine or xylocaine and adrenaline.

Incision
- Curved incision 2 mm above the medial palpebral ligament, 3 mm to the nasal side of inner canthus and 4 mm downwards and outwards (coincides with surface marking of anterior lacrimal crest).

Steps
- Dilate the canaliculi and irrigate the lacrimal sac with warm saline
- Make the incision
- Split orbicularis muscle along the incision line
- Cut the medial palpebral ligament at its attachments to the anterior lacrimal crest
- Expose and incise lacrimal fascia along the anterior lacrimal crest
- Incise the periosteum over the lacrimal crest and expose the lacrimal bone
- Make a bony ostium of 15 mm × 10 mm by cutting the lacrimal bone, part of adjacent nasal bone and frontal process of the maxilla thus exposing the nasal mucosa of middle meatus
- Give two horizontal H-shaped incision on the nasal mucosa and the medial wall of the lacrimal sac thus creating two anterior flaps and two posterior flaps
- Suture the corresponding flaps with catgut or vicryl thus anastomosing nasal mucosa of the middle meatus with the medial wall of the lacrimal sac
- Reposit and suture the divided ends of medial palpebral ligament
- Suture the orbicularis muscle with catgut and skin with silk in continuous subcuticular fashion

JAYPEE BROTHERS

Postoperative care
- Nasal pack removed on 2nd day
- Patency of the passage tested by syringing on 3rd day
- Stitches are removed on 7th day

Advantages
- No postoperative epiphora

Complications
- Hemorrhage from nasal mucosa, injury to angular vein requiring nasal packing for 24 hours
- Failed DCR due to small bony openings, improper suturing, postoperative infection, nasal polyps, etc

b. Dacryocystectomy (DCT)
- Completely excises the lacrimal sac
- Performed only when DCR is contraindicated

Indications (Contraindication to DCR)
- Too young (less than 4 years) or too old (more than 60 years)
- Markedly shrunken and fibrosed sac
- Tuberculosis, syphilis, leprosy or mycotic infections of the sac
- Osteomyelitis of lacrimal fossa
- Tumors of the sac
- Gross nasal diseases like atrophic rhinitis
- Unskilled surgeon

Anesthesia
- Local anesthesia of lacrimal sac with 4% xylocaine drops and surrounding area with 2% xylocaine and adrenaline

Incision
- Curved incision 2 mm above the medial palpebral ligament, 3 mm to the nasal side of inner canthus and 4 mm downwards and outwards (coincides with surface marking of anterior lacrimal crest)

Steps
- Dilate the canaliculi and irrigate the lacrimal sac with warm saline
- Make the incision
- Split orbicularis muscle along the incision line
- Cut the medial palpebral ligament at its attachments to the anterior lacrimal crest
- Expose and incise lacrimal fascia along the anterior lacrimal crest
- Free the lacrimal sac by blunt dissection and draw it forward
- Twist the sac 2–3 times and tear it away from the nasal duct
- Curette the upper end of nasal duct and cauterize with carbolic acid
- Reposit and suture the divided ends of medial palpebral ligament
- Suture the orbicularis muscle with catgut and skin with silk in continuous subcuticular fashion

Postoperative care
- Stitches are removed on 7th day

Complications
- Hemorrhage from injury to angular vein
- Epiphora persists for sometimes and gradually wears off

c. Conjunctivodacryocystorhinostomy (CDCR)
- Performed in presence of blocked canaliculi

d. Insertion of special tubes
- Special tubes like Lester Jones tube, Pawar's cannula inserted into lacrimal sac to facilitate the drainage.

Complications
- Atonic sac
- Lacrimal abscess following probing or spontaneously
- Lacrimal fistula if abscess bust open repeatedly
- Chronic intractable conjunctivitis
- Acute on chronic dacryocystitis
- Ectropion of lower lid
- Maceration and eczema of lower lid skin due to prolonged watering

JAYPEE BROTHERS

- Nonhealing corneal ulcer or hypopyon ulcer
- Panophthalmitis following intraocular surgery
- Orbital cellulitis, facial cellulitis and rarely cavernous sinus thrombosis.

SHORT ESSAYS

3. Buphthalmos.

- Congenital glaucoma is a group of diverse disorders with abnormal high intraocular pressure due to developmental abnormalities of angle of anterior chamber obstructing drainage of aqueous humor
- Also called buphthalmos due to enlarged eyeballs (bull-like eyes) or hydrophthalmos.

Types

True congenital glaucoma (40%)	*Infantile glaucoma (50%)*	*Juvenile glaucoma (10%)*
◆ ↑ IOP during intrauterine life ◆ Child born with ocular enlargement	◆ Disease manifests before 3 years	◆ ↑ IOP between 3–16 years of age

Etiology

Primary congenital glaucoma (due to failure or abnormal development of trabecular meshwork)	*Secondary congenital glaucoma (associated with ocular anomalies)*
◆ Presence of Barkan's membrane ◆ Abnormal cleavage of anterior chamber ◆ Persistent embryonic mesodermal tissue at angle ◆ Absence of canal of Schlemm	◆ Aniridia (50%) ◆ Iridocorneal dysgenesis ◆ Ectopia lentis syndrome (Marfan's syndrome/homocystinuria) ◆ Phakomatosis (VRH syndrome) ◆ Neurofibromatosis ◆ Sturge-Weber syndrome ◆ Congenital rubella ◆ Lowe's syndrome ◆ Mesodermal dysgenesis

Incidence

- Mostly sporadic
- **Autosomal recessive inheritance**[Q] (10%)
  - Chromosomal abnormality at 1p36 and 2q21
- Affects 1 child in 10,000 births

Pathogenesis

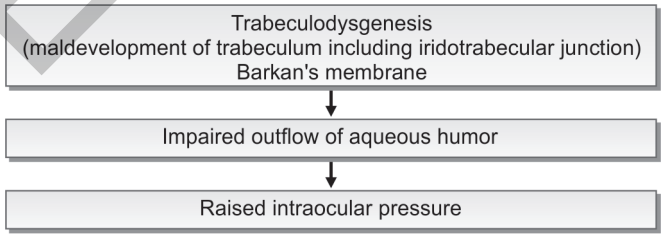

Pathology

- Trabeculodysgenesis (maldevelopment of trabeculum including iridotrabecular junction) is characterized by:
  i. Flat iris insertion (common)
     - Flat and abrupt insertion of iris into thickened trabeculum either at or anterior sclear spur (often) or posterior to sclera spur
  ii. Concave iris insertion
     - Superficial iris tissue sweeps over iridotrabecular junction and trabeculum

Clinical Features

- **2/3 of cases in boys**[Q]
- **Mostly bilateral**[Q] (75%) but may be asymmetric.

JAYPEE BROTHERS

Symptoms

- **Photophobia**[Q], **blepharospasm**[Q], eye rubbing due to irritation of corneal nerves because of ↑ IOP
- **Lacrimation**[Q] due to corneal edema and erosion
- Defective vision due to corneal edema leading to hazy cornea
- **Enlargement of cornea and eye**[Q] as a whole
- Irritable child.

Signs

- Corneal edema (**hazy frosted glass cornea**[Q])
  - First sign to arouse suspicion
  - At first epithelial, lateral stromal
  - Result in permanent opacities
- Corneal enlargement
  - Along with enlargement of eyeball
  - Cornea more than 13 mm (normal 10.5 mm in infants)
- Tears and break in Descemet's membrane (Haab's striae)
  - Because of less elasticity
  - Located along periphery and concentric with limbus
  - **Haab's striae**[Q] appear as horizontal curvilinear lines representing healed breaks of Descemet's membrane
- Thin and **blue sclara**[Q] (due to stretching and underlying uveal tissue)
- Diminished corneal sensation[Q]
- **Deep anterior chamber**[Q] (due to stretching of corneoscleral junction)
- Iridodonesis (due to backward displacement of lens) and atrophic patches on iris
- **Flattening of lens and backward displacement**[Q] (due to stretching of zonules of Zinn) and even subluxation of lens
- Cupping and atrophy of optic disc especially after 3rd year
- Raised IOP (but neither marked nor acute)
- Axial myopia (due to increase in axial length) → anisometropic amblyopia.

Evaluation (under General Anesthesia)

- Measurement of IOP with Pearkin's applanation tonometer
  - IOP not markedly raised due to extensibility or stretching of sclera and uveoscleral outflow
  - IOP above 20 mm Hg (normal 9–10 mm Hg in children)
- Measurement of corneal diameter with calipers
  - Corneal diameter more than 13 mm confirms corneal enlargement (normal 10.5 mm in infants)
- Ophthalmoscopy
  - Wide and deep cupping of optic disc due to stretching of lamina cribrosa and raised tension
  - Nasal shifting of vessels
  - Optic atrophy after 3rd year
- Gonioscopic examination of angle of anterior chamber
  - Presence of open angle
  - Barkan's membrane
  - Abnormally high insertion of iris
  - Poorly developed and posteriorly placed scleral spur
  - Collapsed Schlemm's canal.

Differential Diagnosis

Keratoglobus	*Megalocornea*	*Very high myopia*
◆ Bilateral ◆ Impaired vision ◆ Corneal stromal haze due to fragmentation of Bowman's membrane ◆ Normal IOP ◆ Normal angle of anterior chamber ◆ No cupping of optic disc	◆ Almost always bilateral ◆ Mostly males ◆ Vision not impaired ◆ Transparent cornea ◆ Normal IOP ◆ Normal angle of anterior chamber ◆ No cupping of optic disc	

JAYPEE BROTHERS

Syndromes associated with Infantile Glaucoma

- Von Recklinghausen's disease
- Sturge-Weber syndrome.

Treatment

Conservative (**not very effective**[Q])

- Hyperosmotic agents
  - To lower IOP till surgery
  - Acetazolamide (5–10 mg/kg), beta-blockers, mannitol.

Operative

a. Goniotomy
   Indications
   - Blockage of corneoiridic angle by persistant embryonic tissue.

   Procedure

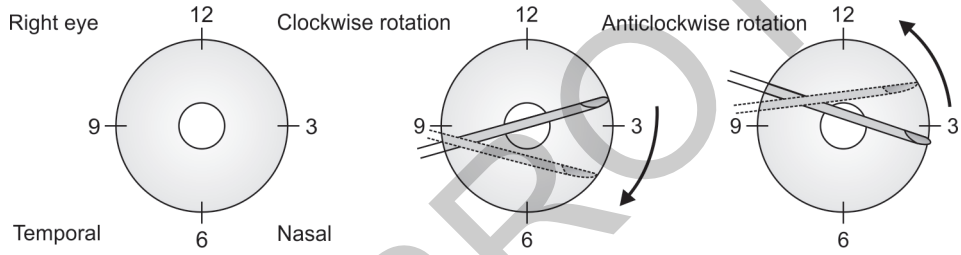

Fig. 2: Technique of goniotomy in right eye.

   - Pass Barkan's goniotomy knife through limbus on temporal side
   - Sweep the knife across the anterior chamber to the nasal side under gonioscopic control
   - Make an incision in the angle midway between root of iris and Schwalbe's ring through approximately 75°
   - Withdraw the knife.

b. **Trabeculotomy**[Q] ab externo
   Indications
   - In presence of corneal clouding
   - Failed goniotomy

   Procedure
   - Make conjunctival and partial thickness sclera flaps at upper limbus
   - Make a vertical scleral incision to expose canal Schlemm at 12 O'clock position
   - Pass lower prong of Harm's trabeculotome along the Schlemm's canal on one side using the upper prong as guide
   - Rotate the trabeculotome so as to break inner wall over one quarter of canal
   - Repeat the procedure on the other side

c. Trabeculectomy
   - A type of filtering operation

   Indications
   - Failed trabeculectomy

d. **Combined trabeculotomy and trabeculectomy**[Q]
   - Offers best surgical results.

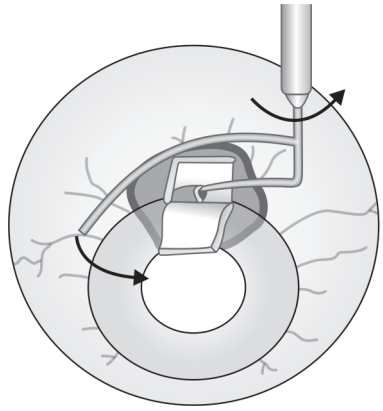

Fig. 3: Harm's trabeculotome.

Complications

- Corneal scarring

JAYPEE BROTHERS

- Amblyopia
- Cataract

4. Hypertensive retinopathy.

- Hypertensive retinopathy refers to fundus changes in systemic hypertension patients.

Predisposing factors	*Pathogenesis*
◆ Severity of hypertension ◆ Duration of hypertension ◆ Age of patient: – In young: Narrowing of retinal arterioles due to spasm – In elderly: Depends upon amount of involutional sclerosis or replacement fiborsis	◆ Essential hypertension with sustained elevation of blood pressure results in: – Thickening of arteriolar wall – Fibrinoid necrosis of smooth muscles and endothelium of vessels – Leakage of plasma and blood

Pathology

- Pathological fundus changes in hypertensive retinopathy results due to:

Vasoconstriction	*Arteriosclerotic changes*	*Increased vascular permeability*
◆ Primary response of retinal arterioles to raised blood pressure and is **related to the severity of hypertension**[Q] ◆ Occurs in pure form in young individuals but in elderly is affected by pre-existing involutional sclerosis ◆ May be focal or generalized	◆ Due to thickening of vessel wall, there occurs changes in arteriolar reflex and AV crossing and **reflects duration of hypertension**[Q] ◆ In elderly, it may pre-exist due to involutional sclerosis	◆ Caused due to hypoxia, resulting in hemorrhages, exudates (soft and hard) and focal retinal edema

Classification

A. Keith, Wegner and Barker (1939)
   – Traditional and widely accepted

   Principle
   – Based on fundus changes
   – Correlates directly with degree of hypertension and inversely with prognosis for patient survival
   – Helps in assessing hypertensive damage to heart, brain and kidneys

   a. Grade I (mild hypertension)
      - Mild to moderate generalized arteriolar attenuation or sclerosis (particularly of small branches)
      - Broadening of anterior light reflex

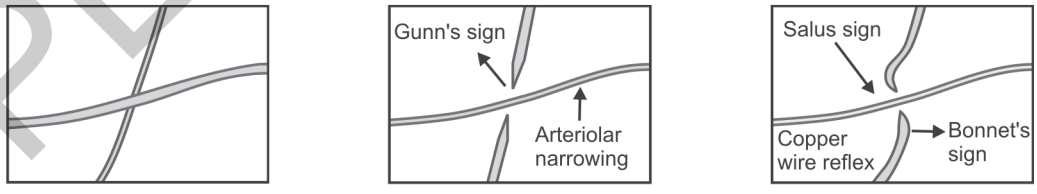

Fig. 4: Mild hypertension.

   b. Grade II (moderate hypertension)
      - Moderate to marked generalized narrowing and **focal attenuation of arterioles**[Q]
      - Copper wiring of arterioles (transparent arterial wall becomes thick and reflects wider burnish copper colored light)—**exaggeration of light reflex**[Q]
      - Changes at AV crossings
        * 'S' shaped deflection of veins at AV crossings (Salus' sign)
        * Banking of veins distal to AV crossings (Bonnet sign)
        * Tapering of veins (due to constriction) on either side of AV crossings (Gunn sign)

JAYPEE BROTHERS

c. Grade III (high and sustained hypertension)
   - Grade II changes
   - **Silver wiring of arterioles**[Q] (marked thickening of arterial walls causes all light to reflect and artery look brilliant white)—highly exaggerated light reflex
   - Flamed-shaped hemorrhages in nerve fiber layer
   - Retinal edema due to extravasation of fluid
   - **Cotton wool spots**[Q] (soft exudates) consisting of fibrin and protein scattered all over the fundus (gray-white patches of 0.5 disc diameters)

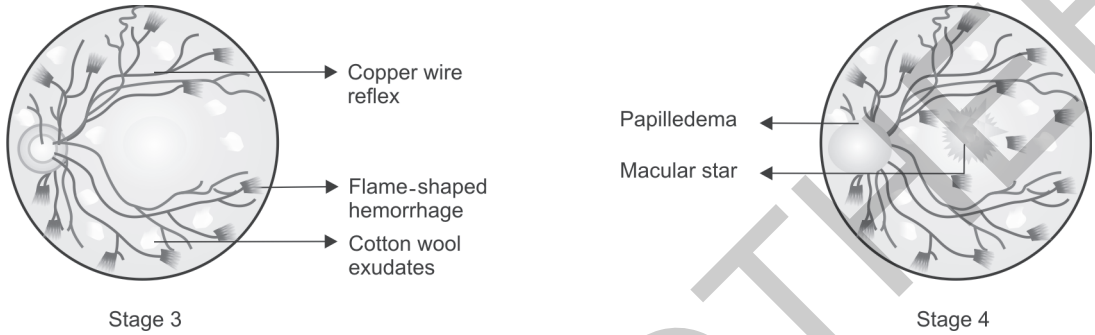

Fig. 5: Hypertensive retinopathy.

d. Grade IV (malignant hypertension)
   - Grade III changes
   - Hard exudates around fovea in outer plexiform layer arranged radially to form **macular star**[Q]
   - **Papilledema**[Q] (pathognomonic)

B. Scheie's classification

Grade	*Hypertensive feature*	*Arteriosclerotic feature*
0	Normal fundus	Normal fundus
1	Narrowing of smaller retinal arterioles No focal constriction	Widening of arteriolar light reflex with simple venous concealment
2	Severe narrowing of localized irregular constriction of arterioles	Grade 1 changes ◆ Salus sign
3	Narrowing and focal irregularities of arterioles, retinal hemorrhages and exudates	Grade 2 changes ◆ Copper wire arterioles ◆ Bonnet sign ◆ Gunn sign
4	Neuroretinal edema and/or papilledema	Grade 3 changes ◆ Silver wire arterioles ◆ Marked AV crossing changes

Clinical Forms

a. Hypertension without sclerosis
   – Occurs in young
   – Elastic retinal arterioles exposed to raised blood pressure for short duration
   – Few retinal signs
   – **Constricted, pale and straight arterioles**[Q] with acute angle branching (due to generalized constriction)
   – Minimal signs of AV crossing
   – **Superficial, flame shaped hemorrhages**[Q]
   – **Cotton wool spots**[Q]
   – No hard exudates and papilledema

b. Hypertension with involutionary (senile) sclerosis
   – Seen after 50 years of age
   – Presence of senile sclerosis

JAYPEE BROTHERS

- Fundus changes comprise augmented arteriosclerotic retinopathy, i.e. localized constriction and dilatation of vessels, thickening of vessel wall and deposition of hard exudates and sometimes hemorrhages without any edema
- Diagnostic AV crossing changes like Gunn sign

c. Hypertension with compensatory arteriolar sclerosis
- Seen in young
- Retinal arterioles subjected to prolonged benign hypertension respond by proliferative and fibrous changes in media
- Advanced fundus changes (albuminuric or renal retinopathy) comprise narrow and tortuous vessels with nicking at AV crossings, multiple hemorrhages and soft exudates in early stages and edema and hard exudates in late stages

d. Malignant hypertension
- Rapid progression of hypertension to a serious degree in a patient with relatively young arterioles
- Fundus picture (hypertensive neuroretinopathy) shows marked arteriolar narrowing, papilledema (essential feature), retinal edema over posterior pole, cluster of superficial flame-shaped hemorrhages and abundance of cotton wool patches.

Treatment

- Antihypertensive drugs.

5. Pseudophakia.

- Pseudophakia is condition where aphakia is corrected with an intraocular lens implant
- Also called artephakia.

Signs

- Surgical scar (linear semicircular corneoscleral scar) at limbus
- Deep anterior chamber
- Mild iridodonesis (tremulousness of iris)
- Purkinje image test shows four images
- Blackish pupil but shining reflex when examined under light
- Demonstration of IOL after dilating pupil
- Visual status and refraction depends upon power of IOL implanted
  - Emmetropia: Implantation of exact power IOL
  - Myopia: Implantation of overcorrecting IOL
  - Hypermetropia: Implantation of undercorrecting IOL

Treatment

Conservative (Optical)

a. Spectacles
- Depending upon refractive status
  - Emmetropia: Plus glasses for near vision only
  - Myopia: Glasses to correct myopia and may or may not need glasses for near vision
  - Hypermetropia: Plus glasses for distance vision and +2D to +3D for near vision.

6. Zonular cataract.

Refer Question No. 2 Dec. 2009 (RS2).

7. Episcleritis.

- Episcleritis is benign recurrent inflammation of episclera (deep subconjunctival connective tissue) including the superficial scleral lamellae and the overlying Tenon's capsule.

Etiology

- Unknown
- Considered allergic reaction to an endogenous toxin or protein of streptococcal or tuberculous nature
- May be collagen disorder due to associated history of rheumatoid arthritis
- Usually associated with herpes zoster, gout, rosacea and psoriasis.

JAYPEE BROTHERS

Pathology

- Localized lymphocytic infiltration of epsicleral tissue
- Edema and congestion of overlying Tenon's capsule and conjunctiva.

Types

i. Simple diffuse episcleritis
ii. Nodular episcleritis.



Fig. 6: Episcleritis.

Clinical Features

- Common in women
- Seen in young adults with peak age in 4th decade
- Usually bilateral involvement.

Symptoms	*Signs*	
	Diffuse episcleritis	*Nodular episcleritis*
◆ Localized redness ◆ Mild ocular discomfort in form of gritty, burning or foreign body sensation ◆ Mild photophobia and lacrimation	◆ Involves whole eye to some extent ◆ Maximum inflammation limited to 1–2 quadrants ◆ Tenderness	◆ Pink or purple flat nodule of size of lentil surrounded by injection, located 2–3 mm from limbus often on temporal side ◆ Firm, immovable and tender nodule ◆ Overlying conjunctiva moves freely ◆ Episclera bright red or pink due to vascular congestion

Differential Diagnosis

- Phlycten
- Foreign body granuloma
- Limbal type of spring catarrh
- Inflamed pinguecula
- Ophthalmia nodosa.

Fate

- Limited course of 10–21 days and resolve spontaneously
- Recurrences common and occur in bouts
- May become chronic but never ulcerates
- If attacks are fleeting (lasts for shorter duration) but frequently repeated—episcleritis periodica fugax.

Treatment

Conservative

- Topical corticosteroid eyedrops or ointments 2–3 hourly—for rapid resolution
- Cold compress to closed eyes—offer soothing relief
- NSAIDs in recurrent cases—to control inflammation and relieve pain.

Complications

- Severe neuralgia due to nerve involvement
- Scleritis from deeper tissue involvement
- Slate colored scarring with adherent conjunctiva
- Uveitis.

8. Exposure keratitis.

- Exposure keratitis develops due to insufficient covering of eye by the lids and loss of protective blinking mechanism
- Also called keratitis lagophthalmos.

REVISED SCHEME 2

JAYPEE BROTHERS

Etiology

- Symblepharon
- Physiological lagophthalmos (during sleep)
- Extreme proptosis
- Ectropion of severe degree
- Deep coma
- Bell's palsy.

Pathogenesis

- Insufficient covering of eye by the lids and/or loss of protective blinking mechanism → exposure of cornea → drying of corneal epithelium → desiccation of corneal epithelium → casting off of epithelium → invasion or raw area by microorganisms → keratitis.

Clinical Features

Symptoms	*Signs (usually seen in lower 1/3rd cornea)*
◆ Inability to close eyelids completely ◆ Absence of blinking	◆ Desiccation in interpalpebral area ◆ Fine punctate epithelial keratitis → necrosis → frank ulceration ◆ Corneal vascularization ◆ Bacterial superinfection → deep suppurative ulceration → perforation

Treatment

Supportive	*Specific*
◆ Frequent instillation of artificial tears ◆ Instillation of ointment and closure of lids by tape or bandage during sleep ◆ Soft bandage contact lens	◆ Treat underlying cause ◆ Treat corneal ulcer (topical antibiotics and 1% atropine) ◆ Tarsorrhaphy as last resort

9. Papilledema.

Refer Question No. 1 Dec. 2007 (RS2).

10. Legal blindness.

- Blindness is the visual acuity of less than 3/60 (Snellen) or its equivalent or inability to count fingers in daylight at distance of 3 meters (WHO).

Legal (Manifest) Blindness

- Visual acuity in better eye is less than 1/60 by finger counting to perception of light and/or visual filed constricted to less than 10°.

Exposure keratitis—etiology "SPEED Boat"

- **S**ymblepharon
- **P**hysiological lagophthalmos (during sleep)
- **E**xtreme proptosis
- **E**ctropion of severe degree
- **D**eep coma
- **B**ell's palsy

11. Panophthalmitis.

- Panophthalmitis is intense, purulent inflammation of whole eyeball (**all three coats**[Q]) including Tenon's capsule.

Etiology

Causative organisms	*Mode of infection*
◆ *Staphylococcus epidermidis* ◆ *Staphylococcus aureus* ◆ *Streptococci* ◆ *Pseudomonas* ◆ *Pneumococci* ◆ *Clostridium welchii* ◆ *Corynebacterium* ◆ *Bacillus subtilis* ◆ *E. coli* ◆ *Propionibacterium acnes* ◆ *Actinomyces*	i. Exogenous – Following perforating injuries – Perforation of infected corneal ulcers – Postoperative infections following intraocular operations ii. Endogenous – Metastatic spread from infected foci like infective embolus in retinal or choroidal vessels, caries teeth, generalized septicemia or puerperal sepsis iii. Secondary infection from surrounding structures (rare) – Orbital cellulitis – Thrombophlebitis – Infected corneal ulcer

JAYPEE BROTHERS

r detailed information on ophthalmology books, visit our website www.jaypeebrothers.com, for detailed information on opht

OPHTHALMOLOGY

Solved Question Papers

Salient Features

- Includes 24 solved question papers of Revised Scheme 2 & 3 of Rajiv Gandhi University of Health Sciences, Karnataka, India
- Important and most commonly repeated questions of Revised Scheme & Old Scheme are compiled in 3 Sample Papers for benefit of students
- Important PG Entrance points are marked as **'Q'** in superscript in text provided as answer
- Chapterwise Page References for making it chapterwise thus useful for regular reading and for college internals
- Revised Course Contents (Revised Scheme 3) prescribed by the university also included
- Format similar to other books by the author to make it user friendly
- All the questions are answered to reduce the workload on the students
- Also included are figures that are essential and sufficient for the question
- Answers are selected from the books commonly referred by the students to avoid confusion during revision for university examination
- A complete comprehensive manual for aspirants of 3rd MBBS examinations.

Available at all medical bookstores
or buy online at www.jaypeebrothers.com



JAYPEE BROTHERS
Medical Publishers (P) Ltd.
www.jaypeebrothers.com

Join us on facebook.com/JaypeeMedicalPublishers

https://www.facebook.com/singiyatiraj

Shelving Recommendation
OPHTHALMOLOGY

