rs.com, for detailed information on anatomy books, visit our website www.jaypeebrothers.com, for detailed information on anatomy books

Celebrating 50

Passion, Quality and Innovation in Healthcare Publishing

Exam Oriented ANATOMY

Regional and Applied

Volume ONE

Upper Limb

Lower Limb

Abdomen and Pelvis

ANATOMY

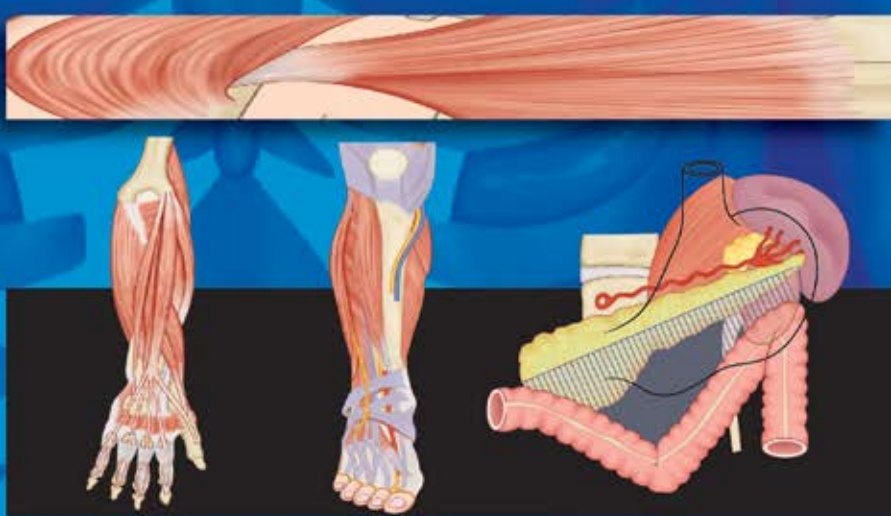

Highlights

- Ready-made and easy-going answers for examination
- Useful for theory, oral and practical examination
- Easy presentation for self-learning
- Precise and to the point
- All sections enriched with a chapter of clinical anatomy
- Richly illustrated with 418 diagrams

Samar Deb

JAYPEE

CONTENTS

Section 1: Upper Limb

1. Pectoral Region and Breast 1
Pectoralis Major Muscle 1
Deltopectoral Groove 1
Pectoralis Minor 1
Clavipectoral Fascia 3
Axillary Tail of Spence 4
Breast 4
Soft Tissue Architecture of Breast 5
Blood Supply of Breast 6
Lymphatic Drainage of Breast 7

2. Axilla and Scapular Region 11
Axilla 11
Serratus Anterior Muscle 13
Axillary Artery 14
Axillary Lymph Nodes 16
Brachial Plexus 18
Deltoid Muscle 23
Triangular and Quadrangular Spaces 24

3. Anterior Compartment of Arm and Cubital Fossa 26
Muscles of Anterior Compartment of the Arm 26
Nerve Supply of the Muscles 27
Action of the Muscles 28
Brachial Artery 28
Cubital Fossa 30

4. Posterior Compartment of Arm 32
Triceps Brachii Muscle 32
Anconeus 33
Profunda Brachii Artery 34

5. Shoulder Girdle and Shoulder Joint 35
Shoulder Girdle 35
Sternoclavicular Joint 36
Acromioclavicular Joint 37
Shoulder (Glenohumeral) Joint 40

6. Anterior Compartment of Forearm 48
Muscles of the Front of Forearm 48
Anterior Interosseous Nerve 54
Radial Artery 55
Arterial Anastomosis Around Elbow Joint 56

7. Posterior Compartment of Forearm 58
Muscles of the Posterior Compartment of Forearm 58
Posterior Interosseous Nerve 65

8. Elbow Joint and Radioulnar Joints 67
Elbow Joint 67
Proximal (Superior) Radioulnar Joint 71
Interosseous Membrane 72
Pronation and Supination 73

9. Hand 75
Flexor Retinaculum of Hand 75
Palmar Aponeurosis 77
Fibrous Flexor Sheath of Fingers 78
Intrinsic Muscles of the Hand 79
Synovial Sheath of Flexor Tendons 81
Lumbrical Muscles 82
Superficial Palmar Arch 84
Interossei Muscles of Hand 85
Median Nerve in the Palm 86
Ulnar Nerve in the Palm 87
Fascial Spaces of Hand 89
Cutaneous Nerves of Dorsum of Hand 94
Extensor Retinaculum of Hand 95
Dorsal Digital Expansion (Extensor Expansion) 96
Anatomical Snuff Box 98

10. Joints of the Wrist and Hand 99
Radiocarpal (Wrist) Joint 99
First Carpometacarpal Joint 102

11. Major Nerves of the Upper Limb 105
Axillary Nerve 105
Musculocutaneous Nerve 107

Median Nerve 108
Carpal Tunnel Syndrome 111
Ulnar Nerve 111
Radial Nerve 115

12. Explanatory Notes (Clinical/ Embryological/Morphological) 119
Radial Nerve Injury at the Axilla 123
Radial Nerve Injury at the Spiral Groove 123
Full Claw Hand 124
Ulnar Claw Hand 124

Section 2: Lower Limb

13. Front of Thigh 131
Inguinal Lymph Nodes 131
Saphenous Opening 132
Iliotibial Tract 133
Femoral Triangle 134
Femoral Sheath 136
Sartorius 138
Pectineus 139
Quadriceps Femoris 140
Articularis Genu 142
Adductor Canal 142
Femoral Artery 144
Femoral Nerve 146

14. Medial Side of the Thigh 149
Muscles of Medial Compartment of Thigh 149
Obturator Nerve 152
Profunda Femoris Artery 153

15. Gluteal Region, Back of Thigh and Popliteal Fossa 155
Sacrotuberous Ligament 155
Sacrospinous Ligament 155
Gluteus Medius and Gluteus Minimus 155
Tensor Fasciae Latae 156
Structures Under Gluteus Maximus 157
Hamstring Muscles 160
Arteries of Back of Thigh 162
Boundaries of Popliteal Fossa 164
Muscles of the Popliteal Fossa 165
Neurovascular Structures of Popliteal Fossa 165
Genicular Anastomosis 168
Popliteus 169

16. Anterolateral Compartment of Leg and Dorsum of Foot 171
Muscles of Anterior Compartment of Leg 171
Cutaneous Nerve Supply of Dorsum of Foot 174
Extensor Retinacula of the Foot 175
Extensor Digitorum Brevis 176
Deep Fibular (Deep Peroneal) Nerve 177
Anterior Tibial Artery 178
Muscles of Lateral (Peroneal) Compartment 179
Fibular (Peroneal) Retinacula 181
Superficial Fibular (Peroneal) Nerve 182

17. Back of the Leg and Sole of the Foot 183
Flexor Retinaculum of Ankle 183
Soleus Muscle 184
Posterior Tibial Artery 184
Second Layer 186
Interosseous Muscles 187
Blood Vessels and Nerves of Sole of Foot 188

18. Joints of Lower Limb 190
Hip Joint 190
Knee Joint 196
Ankle (Talocrural) Joint 209
Tarsal Joints 214
Inversion and Eversion of the Foot 216

19. Miscellaneous Topics 218
Arches of Foot 218
Venous Drainage of Lower Limb 223
Great Saphenous Vein 224
Short Saphenous Vein 225
Deep Veins 227

20. Explanatory Notes (Clinical/ Embryological/Morphological) 229
Flat Foot (Pes Planus) 237
Clubfoot (Talipes) 237

Section 3: Abdomen and Pelvis

21. Anterior Abdominal Wall 239
Umbilicus 239
External Oblique Abdominis 240
Linea Alba
Rectus Abdominis Muscle 243
Pyramidalis Muscle 244
Rectus Sheath 244
Inguinal Canal 246

22. Peritoneum 255
Primitive Ventral and Dorsal Mesenteries of Gut 255
Functions of Peritoneum 257
Changes in the Foregut Making Peritoneal Cavity Complex 257
Disposition of Peritoneal Membrane in Abdominal Cavity 261
Important Peritoneal Spaces 265

23. Stomach and Small Intestine 268
Stomach 268
Arterial Supply of Stomach 273
Venous Drainage of Stomach 273
Lymphatic Drainage of Stomach 274
Duodenum 274
First Part of Duodenum 276
Second Part of Duodenum 277
Suspensory Muscle of Duodenum (Ligament of Treitz) 279
Jejunum and Ileum 280
Arterial Supply of Jejunum and Ileum 282
The Mesentery (Mesentery of Small Intestine) 283
Differences Between Jejunum and Ileum 284
Meckel's Diverticulum 285

24. Liver and Biliary Apparatus 287
Liver 287
Basic Architecture of Liver 297
Biliary Apparatus 299

25. Pancreas, Spleen and Celiac Trunk 306
Pancreas 306
Spleen 315
Splenic Circulation 319
Celiac Trunk 320
Branches 321

26. Abdominal Part of Large Gut, Mesenteric Arteries and Portal Vein 323
Large Intestine 323
Cecum 324
Vermiform Appendix 329
Transverse Colon 332
Superior Mesenteric Artery 335
Inferior Mesenteric Artery 337
Portal Vein 338

27. Posterior Abdominal Wall 342
Cisterna Chyli 342
Psoas Major Muscle 342
Iliacus Muscle 343
Psoas Minor Muscle 343
Quadratus Lumborum Muscle 344
Psoas Sheath 345
Thoracolumbar Fascia 345
Abdominal Aorta 347
Inferior Vena Cava 350
Lumbar Plexus of Nerves 352
Autonomic Nervous System in Posterior Abdominal Wall 354

28. Thoracoabdominal Diaphragm 358
Thoracoabdominal Diaphragm 358
Lymphatic Drainage 363

29. Kidney and Suprarenal Gland 367
Kidney 367
Suprarenal Gland 374
Chromaffin System 378

30. Pelvis 379
Bony Pelvis 379
False Pelvis 379
True Pelvis 380
Pelvic Inlet (Pelvic Brim) 380
Pelvic Outlet 380
Pelvic Cavity 380
Axis of the Pelvis 380
Pelvic Parameters 381
Sex Differences of Pelvis 381
Types of Female Pelvis 382
Clinical Anatomy 382
Piriformis 382
Obturator Internus 383
Pelvic Diaphragm 384
Internal Iliac Artery 389
Sacral Plexus 391
Autonomic Nerves of the Pelvis 393

31. Pelvic Part of the Large Gut 395
Rectum 395
Anal Canal 399

32. Urinary Bladder and Ureter 407
Urinary Bladder 407
Pelvic Part of Ureter 416

33. Organs of Male Reproductive System 417
Prostate Gland 417
Microstructure 422
Vas Deferens 426
Scrotum 427
Testis 429
Structure of the Testis 431
Arterial Supply 431
Venous Drainage 432
Lymphatic Drainage 432
Nerve Supply 432
Descent of Testis 432

34. Organs of Female Reproductive System 435
Uterus 435
Uterine (Fallopian) Tubes 446
Ovaries 449

35. Perineum and Urethra 453
Perineal Body 453
Ischiorectal Fossa 454
Pudendal Canal 455
Superficial Perineal Pouch 457
Deep Perineal Pouch 459
Urogenital Diaphragm 460
Male Urethra 461

36. Explanatory Notes (Clinical/ Embryological/Morphological) 466

Index *479*

Chapter

4 Posterior Compartment of Arm

JAYPEE BROTHERS

SA 4.1 Write a note on triceps brachii muscle.

TRICEPS BRACHII MUSCLE (FIG. 4.1)

Triceps brachii muscle takes its name from its three head of origin—long, lateral and medial.

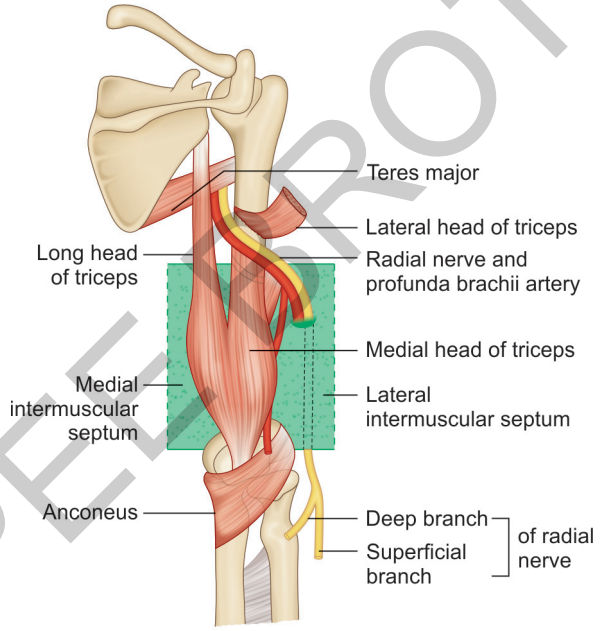

Fig. 4.1: Triceps brachii muscle.

Origin

Long head of the muscle arises by a flattened tendon from the *infraglenoid tuberosity of scapula*. The fibers fuse above with the fibers of capsular ligament of shoulder joint. The fleshy fibers of long head descend medial to lateral head and superficial to medial head of the muscle.

Lateral head take origin through a more expanded flattened tendon from:

- An oblique ridge on posterior surface of shaft of humerus above and parallel to the spiral groove.
- The lateral border of shaft of humerus above spiral groove as high as the surgical neck of the bone.
- Lateral intermuscular septum.

The fibers meet in a common tendon which overlaps the structures in the spiral groove and fuse with medial head.

Medial head is overlapped posteriorly by lateral and long heads. It arises from:
- *Entire posterior surface* of shaft of humerus *below the spiral groove*
- *Medial border* of shaft of humerus from the lower end of insertion of teres major up to 2.5 cm above trochlea
- *Medial intermuscular septum*
- *Lower part of lateral intermuscular septum.*

Insertion

The tendon of triceps brachii is found to appear near the middle of the muscle differentiated in the form of *superficial and deep laminae*.

After receiving the muscle fibers, the two layers unite above the elbow. Most of the fibers of single tendon so formed are attached to *superior surface of olecranon process. A band from the tendon* extends downwards and laterally *over anconeus muscle* **to fuse with deep fascia of forearm.**

Nerve Supply

Three heads of triceps are supplied by separate branches of *radial nerve (C_6, C_7 and C_8)* as follows:
- **Above the spiral groove:** To long and medial heads of triceps
- **In the spiral groove:** To medial and lateral heads of the muscle.

Action

- In general, triceps is *the major extensor of* the elbow joint
- Medial head is active in all forms of extension of the joint
- Lateral and long heads come into the action mostly in extension against resistance
- In addition, long head supports lower part of capsule of shoulder joint when the arm is hyperabducted.

SN 4.2 Write a short note on anconeus muscle.

ANCONEUS (FIG. 4.1)

Origin

Anconeus is a small triangular muscle on the back of elbow. In one side it blends with fibers of triceps and distally it fuses with the surface of capsule of elbow joint. It arises through a tendon from the *posterior aspect of lateral epicondyle of humerus*.

Insertion

Fibers of anconeus fan out downwards and medially towards ulna across the back of elbow. Spiraled fibers of the muscle are inserted on the *lateral surface of olecranon process and upper one fourth of posterior surface of ulna*. The muscle gives an *expansion to posterior aspect of capsule of elbow joint.*

Nerve Supply

Nerve to anconeus is a long slender nerve arising from radial nerve (C_6, C_7 and C_8) in the spiral groove. The nerve passes through the substance of medial head of triceps to reach anconeus.

Actions

It is not clearly known which action of anconeus is more important. But following are its actions.
- *Anconeus helps triceps* to extend the forearm on elbow joint.

JAYPEE BROTHERS

- It *prevents abduction of ulna* (its widening from radius) *during pronation of forearm.*
- It increases tension of capsule of elbow joint, so that *capsular fibers are not pinched within the joint.*

SN 4.3 Write a short note on profunda brachii artery.

PROFUNDA BRACHII ARTERY (FIG. 4.2)

Introduction

Profunda brachii artery is the artery of the posterior compartment of arm and it forms a neurovascular bundle along with the radial nerve in the spiral groove.

Origin

Profunda brachii artery springs out from posteromedial aspect of brachial artery beyond the teres major muscle. It runs downwards, backwards and laterally along the spiral groove, where it lies deep to the lateral head of triceps.

Termination

At the inferolateral end of spiral groove, it divides into two terminal branches—radial collateral and middle collateral arteries.

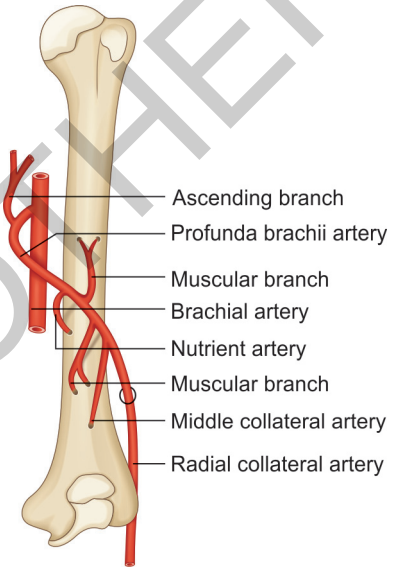

Fig. 4.2: Profunda brachii artery.

Branches

In the spiral groove:

- Muscular branches for triceps
- Nutrient branch for humerus

Terminal Branches

- Radial collateral artery is one of the terminal branches which pierces the lateral intermuscular septum along with radial nerve and runs downwards in front of lateral epicondyle to take part in arterial anastomosis in front of lateral side of elbow joint.
- Middle collateral artery runs downwards in the posterior compartment of arm. It takes part in anastomosis around elbow joint passing behind lateral epicondyle of humerus.

Note: The radial nerve has been described in Chapter 11: Major Nerves of the Upper Limb.

JAYPEE BROTHERS

or detailed information on anatomy books, visit our website www.jaypeebrothers.com, for detailed information on anatomy books, visit

Exam Oriented
ANATOMY
Regional and Applied

Salient Features

- All the areas of gross anatomy have been covered in such a fashion that, this book can be used as an ideal textbook for undergraduate course
- Though the text material has been placed in the question-answer form, it has been sequentially arranged to create clear concept on the subject
- The text material is compact to incorporate within 2 volumes instead of conventional 3 volumes
- The presentation is student friendly with neat diagrams to make the book easy for self-learning
- The style of presentation is unique to be helpful for a teacher to prepare for the classes
- All the topics have been enriched in such a fashion that the book will also be very useful for the postgraduate students as well as the readers of other disciplines.

Samar Deb MS is Academic Director and Emeritus Professor, Department of Anatomy, MGM Medical College, Kishanganj, Bihar, India, where he worked as Principal and Professor, Department of Anatomy till August 2017. He obtained his MBBS degree from NRS Medical College, Kolkata, West Bengal, India. He was awarded postgraduate degree (MS in Anatomy) by the Institute of Medical Sciences, Banaras Hindu University, Varanasi, Uttar Pradesh, India. He joined the medical teaching profession in 1972 in North Bengal Medical College, Darjeeling, West Bengal where he worked as Professor, Department of Anatomy since 1992. Following his retirement from the government institute in 2008, he worked as Academic Director as well as Principal and Professor, Department of Anatomy, Katihar Medical College, Katihar, Bihar and as Principal, College of Medicine & JNM Hospital, Kalyani, West Bengal.

Dr Samar Deb is a life member of Anatomical Society of India. He was the member of Medical Council of India for about a decade. He served as postgraduate teacher for many years, guided a good number of PhD students and published many research papers. He possesses the experience of being Medical Council of India (MCI) inspector and undergraduate as well as postgraduate examiner of many universities. He was awarded the Fellowship of National Academy of Anatomical Society of India in the year 2013. With 47 years of teaching experience in anatomy, he has established himself as a popular and successful teacher for his unique style of teaching.

Available at all medical bookstores
or buy online at www.jaypeebrothers.com



JAYPEE BROTHERS
Medical Publishers (P) Ltd.
www.jaypeebrothers.com

Join us on f facebook.com/JaypeeMedicalPublishers

Shelving Recommendation
ANATOMY

