eebrothers.com, for detailed information on pathology books, visit our website www.jaypeebrothers.com, for detailed information on pathology books

Celebrating 50
Passion, Quality and Innovation in Healthcare Publishing

# AUTOPSY PRACTICES

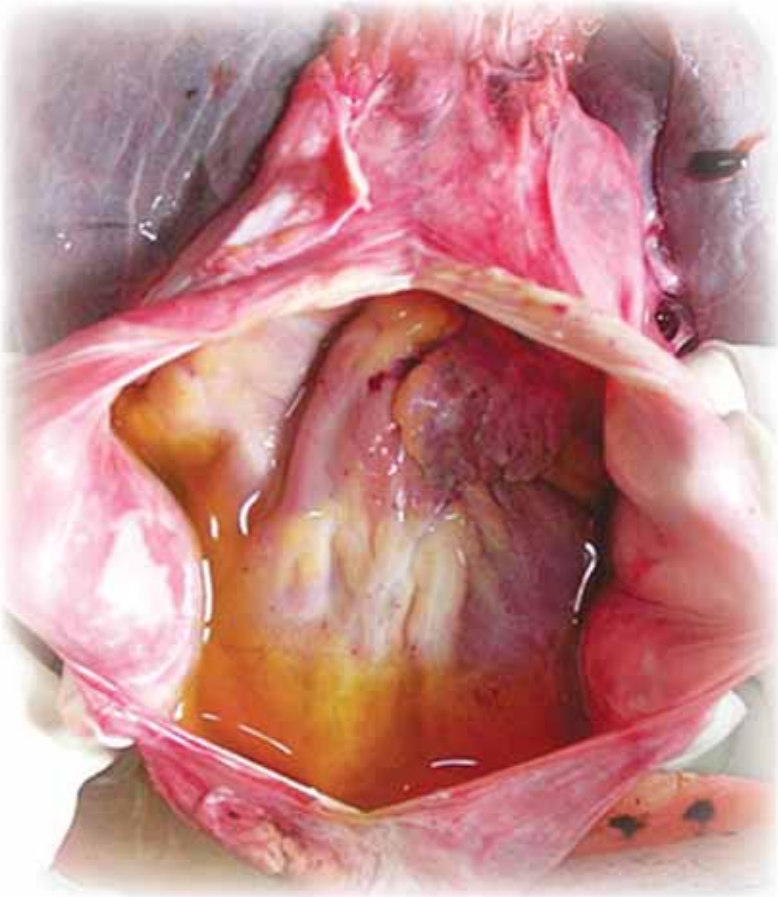

SECOND EDITION

*Editors*
**Dhaneshwar Lanjewar**
**Pradeep Vaideeswar**

JAYPEE

# Contents


**1. Autopsy: Introduction and History** 1
*Dhaneshwar Lanjewar*
Types of Autopsies 1; History of Autopsy 2; History of Autopsy in India 5

**2. External Examination at Autopsy** 10
*Arvind Valand, Dhaneshwar Lanjewar*

**3. Utility and Techniques of Autopsy** 15
*Jaya Deshpande*
Preliminary Skin Incisions 17; Opening of the Thoracic and Abdominal Cavities 18; Techniques of Evisceration 19

**4. In situ Examination** 22
*Dhaneshwar Lanjewar*
Examination of Cranial Cavity 22; Pericardial Cavity 23; Pleural Cavity and Lungs 24; Abdominal Cavity 24

**5. Systemic Examination** 27
*Bishan Radotra, Pradeep Vaideeswar, Gayathri Amonkar, Anjali D Amarapurkar, Ashim Das, Vinaya Shah, Daksha Prabhat, Shubhangi Agale, Subhash Yadav*

**5A: Central Nervous System 27**
*Bishan Radotra*
Brain Removal Procedure 28; Examination of the Brain Before Fixation 31; Fixation of the Brain 32; Removal of the Spinal Cord 32; Examination of brain After Fixation 33; Sampling for Histology 35; Spinal Cord Examination and Sampling 36

**5B: Cardiovascular System 38**
*Pradeep Vaideeswar*
Separation and Fixation of the Heart 38; External Examination of the Heart 41; Opening the Heart and Heart Weight 47; Internal Examination of the Heart 48; Alterations in Dissection 53; Sampling for Histopathology 53


JAYPEE BROTHERS

**5C: Examination of the Respiratory System 55**
*Gayathri Amonkar*
Importance of External and In Situ 55; Lung Dissection, Fixation and Cutting 57; Examination of the Lungs 59

**5D: Gastrointestinal Tract at Autopsy 62**
*Anjali D Amarapurkar*
In Situ Examination 63; Systemic Examination 63

**5E: Approach in Autopsy of Patients with Liver-related Problems 69**
*Ashim Das*
External Examination 69; Internal Examination 70

**5F: Urogenital Tract at Autopsy 76**
*Vinaya Shah*
External Examination of the Kidneys 76; Examination of Cut Surface of the Kidneys 79; Examination of the Ureters 83; Examination of the Urinary Bladder 84; Examination of the Testes 85; Examination of the Prostate 86; Examination of the Seminal Vesicles 86 Examination of the Female Genital Tract 86

**5G: Examination of the Lymphoreticular System 88**
*Daksha Prabhat, Shubhangi Agale, Subhash Yadav*
Spleen 88; Thymus 96

**6. Autopsies in Special Situations 99**
*Bhuvaneshwari Kandalkar, Pragati Sathe, Late Ratnaprabha Ghodke, Kusum Jashnani*

**6A: Pediatric Autopsies 99**
*Bhuvaneshwari Kandalkar, Pragati Sathe, Late Ratnaprabha Ghodke*
External Examination 100; Incisions and In Situ Examination 101; Systemic Examination 102; Postmortem Investigations 105; Sampling for Histopathology 105

**6B: Autopsy in Maternal Deaths 107**
*Kusum Jashnani*
Role of Autopsy in Maternal Deaths 108; Importance of Clinical Records 108; External Examination 108; In Situ Examination 109; Internal Systemic Examination 110

**7. Autopsy and Law 118**
*Shailesh Mohite*
Indian Law Related to Medicolegal Postmortem 122

**8. Design of Autopsy Room 130**
*Smita Divate, Dhaneshwar Lanjewar*
Basic Functional Areas 130

JAYPEE BROTHERS

**9. Autopsy Safety Precautions** **136**
*Smita Divate*
General Rules for Autopsy Biosafety 137; Isolation Room for Specific Types of High-Risk Autopsies 138; Safe Use of Sharp Instruments 138; Limiting the Generation of Aerosols 138; Personal Protective Attire/Equipment for Autopsies 139 Handwashing 139; Cleaning and Decontamination 139; Handling of Cadavers 140; Storage and Transport of Tissues 140; Demonstration of Organs At Meetings 141; Biowaste Disposal 141; Photography 141; Employee Health 141; Appendix 1 143; Appendix 2 144

**10. Autopsy Audit** **145**
*Jaya Deshpande*
Preanalytical Phase 145; Analytical Phase 146; Postanalytical Phase 146; Autopsy Clinical Audit Monitors 147

**11. Embalming** **148**
*Deepak S Joshi*
History 148; Modern Embalming 148; Principle of Embalming 149; Pre-Embalming Steps and Their Legal Aspects 150; Equipment Required for Embalming 150; Methods of Embalming 151; Packing and Transportation 152; Plastination 152

**12. Autopsy Guidelines in COVID-2019** **154**
*Dhaneshwar Lanjewar*
Guidelines and Precautions for Performing Autopsy 154; Recommendations for Gross Contamination and Liquids 156

**Appendices** **159**

**Case 1: Central Nervous System 159**
*Bishan Radotra*

**Case 2: Central Nervous System 162**
*Bishan Radotra*

**Case 3: Cardiovascular System 163**
*Pradeep Vaideeswar*

**Case 4: Cardiovascular System 166**
*Pradeep Vaideeswar*

**Case 5: Gastrointestinal Tract 169**
*Anjali D Amarapurkar*

**Case 6: Urinary Tract 171**
*Vinaya Shah*

**Case 7: Autopsy In Infectious Disease 173**
*Dhaneshwar Lanjewar*

JAYPEE BROTHERS

**Case 8: Maternal Mortality 176**
*Kusum Jashnani*

**Case 9: Pediatric Autopsy 179**
*Pragati Sathe*

**Case 10: Urinary System and Gastrointestinal Tract 181**
*Dhaneshwar Lanjewar*

**Case 11: Respiratory System 184**
*Pradeep Vaideeswar, Saranya Singaravel*

**Case 12: Central Nervous, Cardiovascular and Respiratory Systems 187**
*Bishan Radotra*

**Case 13: Multi-System Involvement 193**
*Bishan Radotra*

**Case 14: Gastrointestinal Tract 200**
*Dhaneshwar Lanjewar, Saroj Bolde*

***Index*** ***207***

JAYPEE BROTHERS

6
CHAPTER

# Autopsies in Special Situations

*Bhuvaneshwari Kandalkar, Pragati Sathe, Ratnaprabha Ghodke, Kusum Jashnani*

JAYPEE BROTHERS

## 6A: Pediatric Autopsies

*Bhuvaneshwari Kandalkar, Pragati Sathe, Ratnaprabha Ghodke*

### INTRODUCTION

A pediatric autopsy is of great value to the clinicians and to the kith and kin of the child who has died. Maximum information should be garnered from each and every autopsy so as to reduce mortality and morbidity in other children. Pediatric autopsies include autopsies of the fetus, neonate (age from birth up to 1 month), infant (age up to 1 year), and child, which in many centers is up to the age 12 years, although this limit can be extended to 18 years. In general, like autopsies in adults, autopsies performed in the pediatric age group also help to judge the accuracy of diagnosis, to rule out the differential diagnosis, to document surprise findings and confirm the cause of death. In addition, it provides feedback regarding therapeutic outcomes, diagnostic technologies, and tests. In some cases, it may help study new diseases and their courses, and may also alleviate guilt feelings in parents following the death of their children.

Maternal medical disorders like eclampsia, diabetes mellitus, coagulopathies, and infections contribute significantly to fetal growth and outcome. Likewise, common placental abnormalities like twinning, umbilical cord related lesions, vasculopathies, and abruption can also affect fetal outcome. Fetal autopsy reveals confirms gestational age, maternal/placental problems, and genetic abnormalities which are useful for future counseling for hereditary disorders. Perinatal and neonatal deaths are often due to infections, congenital anomalies, and respiratory complications, whereas in infants and children, infections, inborn errors of metabolism, and tumors contribute to death. There, however can be overlapping or common problems in all of them.

Before commencing a pediatric autopsy, the case history should be thoroughly evaluated and documented for the maternal history and birth history, immunization

schedule, and milestones. Particular attention should be paid to all investigations, particularly radiological images. After a careful record of the history, a systematic autopsy has to be performed commencing with a good external examination followed by in situ and internal organ system examination.

## EXTERNAL EXAMINATION

Apart from the usual observations performed in an adult autopsy, in a pediatric autopsy, weights, measurements, and photographs are of great importance. The gestational age-wise weights can be compared with the standard charts to decide appropriate or small for gestational age babies, especially in the perinatal period. The important measurements include crown-heel length, crown-rump length, head circumference, abdominal circumference, chest circumference, foot length, distance between nipples, and mid-arm circumference. All measurements can be accurately performed with a measuring tape at various levels. The value should be reported to the nearest 0.01 cm and plotted on a standardized growth chart. Out of these measurements, foot length correlates well with gestational age. It is helpful in disrupted fetuses as well. These measurements also have an internal control, e.g., crown-rump length is equal to two-thirds of crown-heel length and head circumference is approximately equal to crown-rump length. Head circumference is measured in children up to age three, as this is the time of greatest brain growth. Abnormal measurements tell us about abnormality in the growth of the brain inside the skull cavity. These measurements also give us information about the nutritional status, overall skeletal development, and the chronicity of the illness. As per World Health Organization (WHO) guidelines, a mid-upper arm circumference <115 mm is considered to be a significant indicator of malnutrition in children 6–60 months of age. At the extremes of malnourishment, thickness of subcutaneous fat on the chest midway between the nipples and on the abdomen midway between the xiphoid process and the umbilicus serve as rough indicators of nutritional status (<3 mm fat at abdominal level and <2 mm fat at the chest level indicates severe wasting whereas >25 mm at the abdominal level and >12 mm at the chest level are indicative of obesity).

Photographs are important for documentation of external abnormalities and can also serve as material for future reference. The important planes include full image of the front and the back of the body and a close-up view of the face from front and profile. Signs of maceration vary with the time spent intrauterine after death and thus help in deciding the time since death (**Table 6.1**). Signs of prematurity are important to investigate the gestational age of the fetus (**Box 6.1**). Abnormal facial appearance and maldevelopment of ears, hands (**Fig. 6.1A**), feet, rib cage, vertebral column, and genitalia (**Fig. 6.1B**) may suggest a syndromic association and hence should be carefully documented. The skin color should be examined. Meconium staining may be seen in cases of asphyxia.

Bruising, fractures, and hemorrhages may suggest birth injuries that could have directly or indirectly contributed to death. Position of umbilicus and the cord structures should be noted as vascular anomalies like single umbilical artery may indicate internal anomalies.

JAYPEE BROTHERS

**TABLE 6.1 Grades of maceration in relation to time since death.**

| Time since death | Grades of maceration |
|---|---|
| Intrapartum death | None |
| Less than 12 hours between death and delivery | *Slight:* Skin slippage (on rubbing of skin the epidermis is detached from the underlying tissues), rare bullae (blisters), little (e.g., scrotum only or single spots of skin loss elsewhere) or no denudation (due to rupture of bullae) |
| About 12–24 hours between death and delivery | *Mild:* Focal denudation of multiple regions without other changes |
| One to a few days between death and delivery | *Moderate:* Generalized skin maceration/denudation but without significant compressive changes |
| More than a few days between death and delivery | *Advanced:* Compression and/or mummification and/or internal liquefaction |

**BOX 6.1 Common signs of prematurity.**

- Lanugo hair
- Maldeveloped ear cartilage
- Absent breast bud
- Undescended testes
- Length of finger nails (the nails are identifiable after 17 weeks and reach the finger tips by 32 weeks)
- Rugose scrotum
- Poorly developed palmar/plantar creases

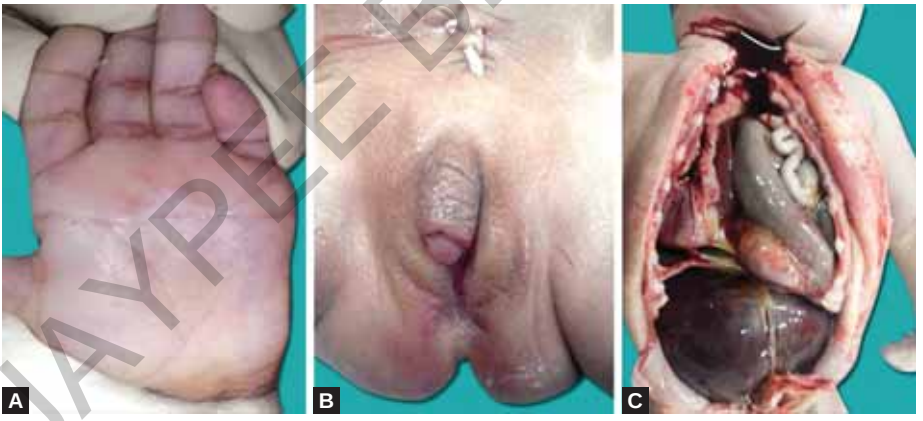


**FIGS. 6.1A TO C:** (A) Simian crease in a baby of Down's syndrome; (B) Ambiguous genitalia. Micropenis is seen along with labia majora; (C) Congenital diaphragmatic hernia. Note the intestinal loops in left thoracic cavity.

## INCISIONS AND IN SITU EXAMINATION

In contrast to opening of the cranium in adults and older children, Beneke suture-splitting technique is used to open the cranium of fetuses and infants. This is possible as the sutures are not closed and cranial bones are still soft. One has to look for cephalohematomas and hemorrhages in subgaleal, subdural subarachnoid or

JAYPEE BROTHERS

intracerebral locations as they may be related to birth trauma. Record of hemorrhages especially extradural in location is also important in cases of battered baby syndrome.

The thoracic cavity is best examined before the peritoneal cavity is opened so as to avoid possible contamination by intestinal organisms when lung tissue has to be sampled for culture. The chest should be opened after aspirating the pleural cavities for air to identify a possible pneumothorax that may have occurred during attempted resuscitation. One has to look for effusions, positions, and shapes of organs namely the heart, lungs, great vessels, thymus, and for any abnormal presence of abdominal organs within the thoracic cavity like in cases of diaphragmatic hernia (**Fig. 6.1C**). After removing the thymus and pericardial sac, the external configuration and vascular connections of the heart are checked while the heart is still in situ. Procedure of dissection is similar to adults except that the venous and arterial connections of the heart must be determined before removal of heart-lung en bloc. When the abdominal cavity is opened, one should check for situs, organomegaly (**Fig. 6.2A**), masses, and the nature of ascitic fluid, if present. Marked dilatation of a loop of intestine may suggest atresia in the segment distal to it.

## SYSTEMIC EXAMINATION

All major organs need to be weighed and compared to published data. However, there are variations in individual as well as racial and pathological conditions. Hence, weight ratios are more reliable.

For example, lung: heart = 3:1, brain: liver = 3:1, liver: heart = 6:1, and thymus: spleen: adrenals = 1:1:1.

The gyral and sulcal patterns of development of the cerebral hemispheres should be compared with published diagrams that indicate increasing complexity with advancing gestational age, as this is a relatively reliable tool fordetermining gestational age in preterm neonatal deaths. The pituitary could be in a defective position in cases of anencephaly. Various anomalies like absent corpus callosum, holoprosencephaly, etc., may be incompatible with life and have to be documented. The brain would be edematous in cases of perinatal hypoxia. As a consequence of ischemia or hypoxia, hemorrhages most often occur in the germinal matrix of the ventricles (**Fig. 6.2B**), cerebellum, and around small blood vessels (ring hemorrhages).

Periventricular leukomalacia is a form of coagulative necrosis with tissue lysis, edema, cyst formation, and gliosis, indicating an intrauterine ischemic event most commonly seen in prematurity. When present, kernicterus is usually recognizable on the cut surfaces of the peduncles as deep yellow staining. A single midcoronal cut through the hemisphere will also show yellowish discoloration of the basal ganglia (**Fig. 6.2B**).

The heart and lungs should be eviscerated together with the tongue, pharynx, submandibular salivary glands, esophagus, larynx, and trachea. Usually the thoracic and abdominal block can be dissected after separation. However, the blocks need to be dissected in continuity in congenital heart diseases when there is pulmonary arterial or particularly venous malformations (where one might severe the connections due to lack of awareness) and in the heterotaxy syndromes. The esophageal hiatus should be examined in situ. The esophagus should be opened from posterior aspect

JAYPEE BROTHERS

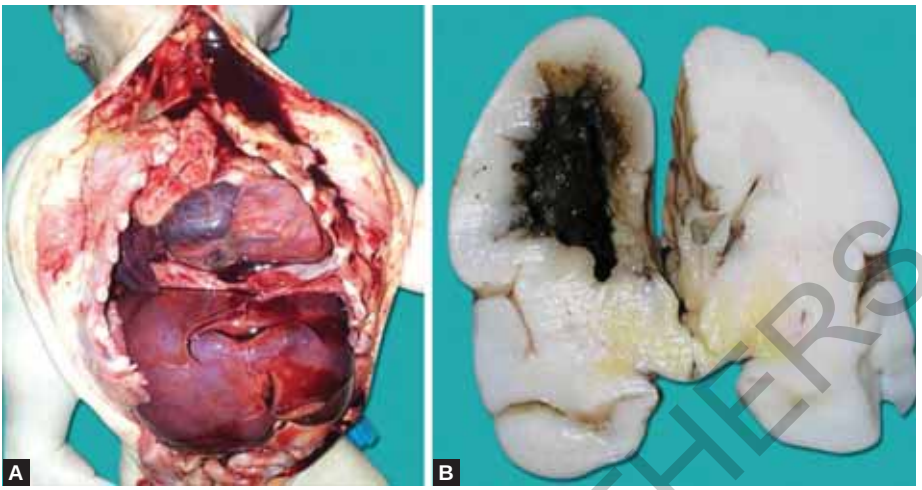


**FIGS. 6.2A AND B:** (A) Enlarged liver is seen to occupy almost the entire abdominal cavity; (B) Yellowish discoloration of thalami in a case of kernicterus. There is a large periventricular hemorrhage as well.

JAYPEE BROTHERS

so that esophageal atresia or tracheoesophageal fistula may be detected. Gross examination and sampling of the larynx and vocal cords in young infants should be done particularly when dealing with sudden unexpected death in infancy. The intact larynx, trachea, and main bronchi should be opened along their posterior surface. Also check for plugging by mucus, meconium, or aspirated material. The heart has to be checked for position, size, external appearance, and relation to great vessels. The opening of heart is along the flow of blood as done in adults. Complex congenital cardiac anomalies are likely to manifest early and should be looked for in all neonatal hearts. The lungs have to be checked for their size and shape, number of lobes and position, abnormalities in the form of hypoplasia, atelectasis/collapse, congestion and hemorrhage pneumonia/abscesses, and bullae/cystic lesions.

The mesentery has to be kept intact till intestinal atresia or stenosis examined. There can be incomplete mesenteric fixation, which renders the cecum excessively mobile, with displacement of the vermiform appendix to the right upper quadrant.

One has to look for intussusceptions, atresia, bands, and volvulus, besides the usual inflammations, infections (**Fig. 6.3A**), and infestations. Frequently mucosal polyps like Peutz-Jeghers polyp are found at the tip of the intussusception. The liver is frequently slightly enlarged in preterm babies as it is a site for extramedullary hematopoiesis. Hepatomegaly in neonates, infants, and young children commonly occurs due to cholestatic and metabolic diseases; it may be greenish in cholestatic disorders, cirrhotic in diseases like Wilson disease, slate gray as in malaria, nodular (**Fig. 6.3B**) or even focally cystic at times (**Fig. 6.3C**). The patency of the extrahepatic biliary tree has to be checked by confirming the flow of bile at the ampulla of Vater. The gallbladder in these cases is shrunken, atretic, and does not contain bile. The bile

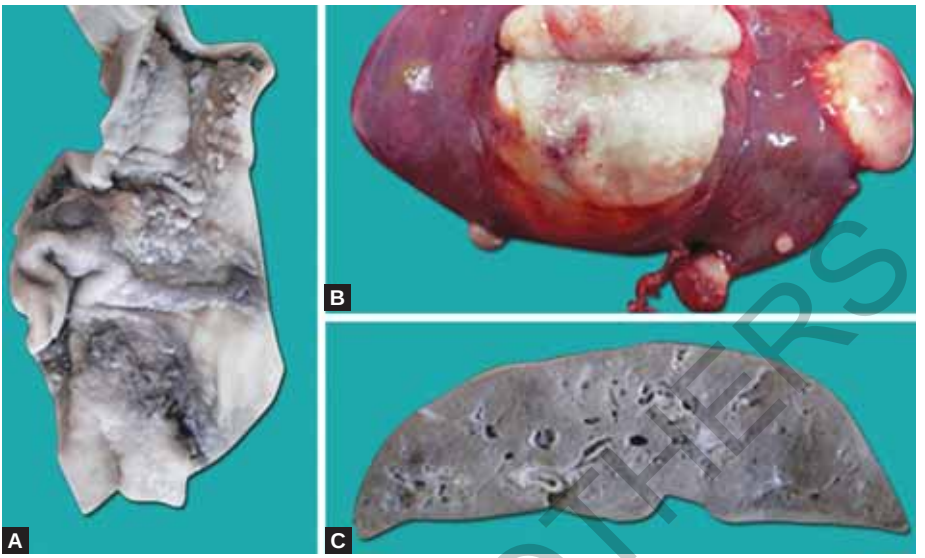


**FIGS. 6.3A TO C:** (A) Transverse ulcers of ileal tuberculosis; (B) Multiple gray white lesions of metastasis of Wilms tumor in the liver; (C) Multiple tiny cysts distributed throughout the liver parenchyma. The patient also had autosomal recessive polycystic kidney disease.

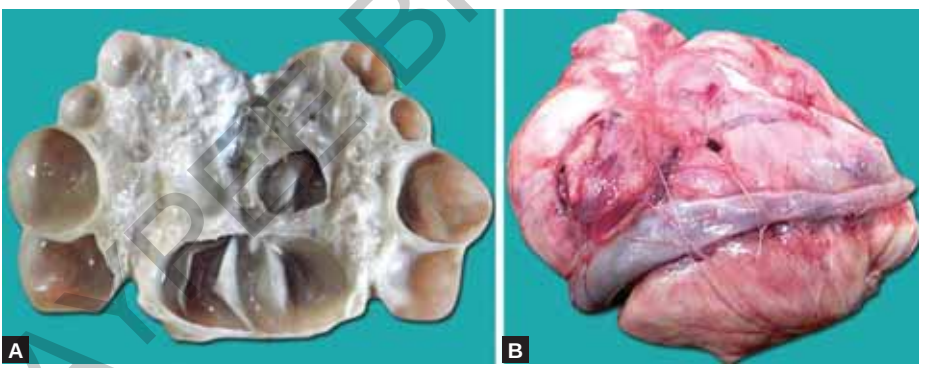


**FIGS. 6.4A AND B:** (A) Multicystic renal dysplasia in a newborn; (B) A large Wilms tumor with intestinal loop stretched over it.

JAYPEE BROTHERS

duct may be reduced to just a fibrous tract. It is advisable to perform a hepatobiliary dissection for better demonstration of the biliary tract. The other causes of obstructive biliary disease like choledochal cysts are common in older children.

Anomalies of urinary tract such as renal agenesis/hypoplasia, horse-shoe shape, cystic anomalies (**Fig. 6.4A**), ureteral, bladder and urethral abnormalities, and tumors (**Fig. 6.4B**) should be looked for. Presence of undescended testis and observation of internal genital organ development are important in cases of ambiguous genitalia. It is important to remember that adrenal glands are large in children and are usually one-third the weight of the kidneys. They can be decreased in size in anencephaly

and growth retardation and can be enlarged in Rh isoimmunization, hemorrhage, hypoxia, necrosis, abscess, and congenital infections. In stillborn babies with complex congenital anomalies, asplenia is common. Spleen may be enlarged in infants and young children due to infections, metabolic disorders, and hemolytic anemias. Mildly enlarged reactive mesenteric lymph nodes are frequently seen in pediatric population and may not be of diagnostic significance.

## POSTMORTEM INVESTIGATIONS

Routine microbiology cultures should be taken from turbid peritoneal fluid, abscesses, cerebrospinal fluid, and rectal stools in cases with diarrheal disease. Cerebrospinal fluid should be collected by cisternal puncture. Blood culture is performed from blood collected from the heart after searing the right ventricular surface in cases of sepsis. Swabs should be collected from bronchial secretions after opening the trachea with flamed scissors to avoid contamination.

Hematological and histochemical investigations should be ideally performed within 12 hours after death for reliable results. Immunological tests [e.g., toxoplasma, syphilis, rubella, cytomegalovirus, and herpes simplex (TORCH) titers, human immunodeficiency virus (HIV) antibody] should be completed by 24 hours after death. A blood spot on a Guthrie card can be useful for potential future deoxyribonucleic acid (DNA) analysis. When there is suspicion of an inborn error of metabolism, and in forensic cases, samples of blood, urine, bile, gastric content, and vitreous humor should be taken for biochemical or toxicologic analysis. Portions of liver and kidney may also be kept in a freezer until histology is complete. Presence of zonal necrosis in the liver may suggest poisoning and in such cases toxicologic analysis can be performed further. Material for viral culture (suspected organ of involvement like lung, kidney, and liver) has to be collected in virus transport medium. For chromosome assays, if leukocytes of blood are used for culture then it has to be performed within 12 hours of death. If skin or amnion fibroblasts are used for culture, then the test has to be performed within 3 days of death. For electron microscopy, especially in cases of inborn errors of metabolism, remove representative portions of the organ (cortex and medulla for kidney, parenchyma, and peribronchial/perivascular tissue for lung) and place in glutaraldehyde. The optimum tissue size is 1 $mm^3$.

## SAMPLING FOR HISTOPATHOLOGY

Microscopic examination of tissues helps to assess maturation, may help to observe changes occurring during the period immediately preceding death, and of course determining the pathologic process that led to death. Thus, routine sampling of the following tissues should be regularly undertaken. Following tissues should be sampled in addition to routine sections:

- Thymus to evaluate for small hemorrhages (as stress reaction), and involutionary changes.
- Rib costochondral junction to assess the duration of terminal stress and possible underlying rickets and/or scurvy.

JAYPEE BROTHERS

- Adrenal glands to evaluate the cortical lipid content, pseudoacinus formations, necrosis, hemorrhages, and retention of fetal cortex. Midportion of adrenal should be sampled.
- Kidney should be sectioned at right angles to capsule to count glomerular generation. Do not strip the capsule.
- Lungs should be sampled midway between the hilum and the most distant periphery of each lobe to discern whether or not patchy pathologic findings are sufficient to explain death. Hilar and pleural surface also has to be sampled.
- The paraventricular area of the brain below the corpus callosum should be sampled for demonstration of germinal matrix hemorrhages.
- Sections from both papillary muscles of the heart should be taken for demonstration of vacuolated myocardial fibers in perinatal asphyxia.
- Any abnormal finding should be sampled for histopathology for confirmation.

When all the tissues have been examined and the results of laboratory investigations are available, a final autopsy diagnosis is given. An opinion should be given whether the microbiological test findings are of clinical significance keeping in mind the interval between time of death and autopsy. The final diagnosis should list all the abnormal gross and microscopic findings, and ancillary abnormalities that contributed to the death of the patient in order of their importance. In addition, the pathologist should provide a clinicopathologic correlation of the sequence of events leading to death. If any special requests or queries were made by the concerned party wanting the autopsy it should be especially mentioned. There are occasions when the pathologist should recommend that particular corrective action be taken to avoid recurrences of harmful events, such as inborn errors of metabolism. The final report should indicate the number of paraffin blocks that have been processed and their organ of origin. The report should be dated and signed by the concerned pathologist.

## FURTHER READING

1. Newton D, Coffin CM, Clark EB, Lowichik A. How the pediatric autopsy yields valuable information in a vertically integrated health care system. Arch Pathol Lab Med. 2004;128:1239-46.
2. Siebert JR. Perinatal, fetal and embryonic autopsy. In: Gilbert-Barness E (Ed). Potter's Pathology of the Fetus, Infant and Child, 2nd edition. Philadelphia: Elsevier; 2007. pp. 695-739.
3. Stocker JT, Macpherson TA. The pediatric autopsy. In: Stocker JT, Dehner LP (Ed). Pediatric Pathology, 2nd edition. Philadelphia: Lippincott Williams & Wilkins; 2001.pp. 5-17.
4. Wainright HC. My approach to performing a perinatal or neonatal autopsy. J Clin Pathol. 2006;59:673-80.

JAYPEE BROTHERS

# 6B: Autopsy in Maternal Deaths

*Kusum Jashnani*

## INTRODUCTION

Maternal mortality is an important event to assess the quality of healthcare system, as it is not only a health issue but also a matter of social injustice. Maternal deaths are defined as "deaths occurring during pregnancy or within 42 days of childbirth or of an abortion from any cause related to or aggravated by pregnancy or its management". Maternal deaths are subdivided into direct, indirect, and coincidental. Direct causes are related to obstetric complications occurring during pregnancy, labor, delivery, and the postpartum periods. Indirect causes are related to preexisting or newly developed medical conditions that may be aggravated by the physiologic demands of pregnancy. Coincidental causes include deaths due to homicide, accidents, illicit drug toxicity, and suicides. A list of the causes of maternal death is available in comprehensive review of this subject (**Tables 6.2** and **6.3**). The medicolegal aspects of autopsies in maternal death will not be dealt here.

**TABLE 6.2** **List of common causes of maternal death.**

| Direct causes | Indirect causes | Coincidental causes |
|---|---|---|
| Hypertensive diseases of pregnancy | Venous thromboembolism | Homicide/suicide (particularly burns) |
| Obstetric hemorrhage | Hepatitis/hepatic necrosis | Road/railway accident |
| Peripartum dilated cardiomyopathy and some cases of acute aortic dissections | Preexisting congenital or acquired heart diseases | Illicit drug toxicity |
| Amniotic fluid embolism | Tuberculosis, malaria, and HIV/AIDS | |
| Puerperal sepsis | Anemia | |
| Ruptured ectopic pregnancy | Stroke | |
| Acute fatty liver of pregnancy | Cancer | |

(AIDS: acquired immunodeficiency syndrome; HIV: human immunodeficiency virus)

**TABLE 6.3** **Causes of obstetric hemorrhage.**

| Early pregnancy bleeding | Antepartum hemorrhage | Postpartum hemorrhage |
|---|---|---|
| Abortion | Placenta previa | Tone: Atony |
| Ectopic pregnancy | Abruptio placentae | Tissue: Retained, accreta |
| Gestational trophoblastic tumor | Uterine rupture | • Trauma: Rupture, laceration<br>• Thrombosis: DIC, sepsis, HELLP |

(DIC: disseminated intravascular coagulation; HELLP: hemolysis, elevated liver enzymes, and low platelet count)

JAYPEE BROTHERS

Delay in deciding to seek care may be one of the reasons for maternal death. It is common in developing countries, to see women die at home from maternal complications, not knowing where and when to ask for health care. Also women who do ask for care may not receive effective treatment. Studies have shown that half of the deceased women were taken to at least two facilities, causing fatal delays in receiving appropriate care. Maternal Death Review is a tool used to analyze the reasons for maternal deaths for appropriate local intervention. The Government of India introduced Maternal Death Review guidelines in 2010 and hence it is important for all administrative staff (medical and nonmedical) to implement and follow the guidelines. For example, since then, each and every maternal death in the city of Mumbai is reviewed by a committee of members appointed by the Municipal Corporation of Greater Mumbai (MCGM). Maternal mortality ratio (MMR) is the number of women who die from obstetric complications in a given year per 100,000 live births in that year. Maternal mortality rate is defined as the number of maternal deaths to women in the ages 15–49 per lakh of women in the same age group.

## ROLE OF AUTOPSY IN MATERNAL DEATHS

Autopsy still plays an important role in healthcare and educational programs, in spite of declining autopsy rates. Despite advances in imaging and laboratory diagnostic services, an autopsy remains the most accurate way to identify the cause of death. Maternal autopsy is not different from any other adult autopsy, provided that one remembers that certain lethal complications of pregnancy are either unique [amniotic fluid embolism (AFE) and eclampsia) or unusual in nonmaternal autopsies (air embolism and pituitary necrosis) for which one must positively identify their presence or absence. Also, maternal death autopsies assume greater significance than most other deaths as recommendations for improving the obstetric practice can be based on these reports.

## IMPORTANCE OF CLINICAL RECORDS

The first step in performing an autopsy is the thorough review of the medical records. The pathologist must obtain a clear understanding of the mother's present and past medical history, place and type of delivery process or abortion, transfer/s from one healthcare center to the other, therapeutic interventions if any, and the terminal events leading to death.

Fetal/neonatal information is also relevant, e.g., infected peripartum, small-for-dates, etc. It would be preferable if the pathologist can get in touch with the obstetrician/physician to discuss the case before beginning the prosection. The clinical team should be invited to visit the autopsy room during or after the autopsy (if no negligence is suspected).

## EXTERNAL EXAMINATION

Look for signs of pallor, icterus, edema feet, anasarca, and any injuries. External signs of disease should be sought, e.g., vaginal discharge (genital tract infection and

JAYPEE BROTHERS

for detailed information on pathology books, visit our website www.jaypeebrothers.com, for detailed information on pathology books, visit our websi

# AUTOPSY PRACTICES

*Autopsy Practices* emphasizes the practical procedures of dissecting and describing various organ systems, which will help in identification of lesions, their interpretations and final clinical correlation. This book will be useful to residents and faculty members in pathology and forensic medicine and toxicology.

**Dhaneshwar Lanjewar** completed MBBS, DCP and MD from the Government Medical College (affiliated to Dr Babasaheb Ambedkar Marathwada University), Aurangabad, Maharashtra, India. He joined the Grant Government Medical College and Sir Jamshedjee Jeejeebhoy Group of Hospitals, Mumbai, initially as an Associate Professor and, with his dedication and zeal, he ascended to the post of Professor and the Head, Department of Pathology. His teaching experience spans over 41 years, and nearly 20 years of his tenure at the Grant Medical College, Mumbai, were related to clinical autopsies. He is recognized as a pioneer to describe the pathology of HIV/AIDS in Mumbai, India. His contributions in the field of pathology are manifold with more than 60 papers published in national and international journals and participation as a faculty in international conferences. In addition, he was an administrator of Maharashtra Medical Council and Maharashtra Nursing Council, and the Director of AIDS Research and Control Center, Mumbai, and the President of Indian Association of Pathologists and Microbiologists (2009), and currently he is the Overseas Advisor to the Indian College of Pathologists.

**Pradeep Vaideeswar** is Professor (Additional), Department of Pathology, Seth Gordhandas Sunderdas Medical College, Mumbai, Maharashtra, India. He has 31 years of teaching experience in pathology, and his special interests are cardiovascular and pulmonary pathology, pathology of infections and autopsy pathology. He was Honorary Joint Secretary (2011–2013), Honorary Secretary (2014–2016), Honorary Vice-President (2018) and Honorary President (2019) of Indian Association of Pathologists and Microbiologists.

*Printed in India*

**Available at all medical bookstores**
**or buy online at www.jaypeebrothers.com**



**JAYPEE BROTHERS**
**Medical Publishers (P) Ltd.**
EMCA House, 23/23-B, Ansari Road,
Daryaganj, New Delhi - 110 002, INDIA
www.jaypeebrothers.com

Join us on facebook.com/JaypeeMedicalPublishers

Shelving Recommendation
**PATHOLOGY, MICROBIOLOGY**

