s.com, for detailed information on anatomy books, visit our website www.jaypeebrothers.com, for detailed information on anatomy book

Celebrating 50

Passion, Quality and Innovation in Healthcare Publishing

# Exam Oriented ANATOMY

## Regional and Applied

**Volume TWO**

Thorax
Neuroanatomy
Head and Neck

ANATOMY

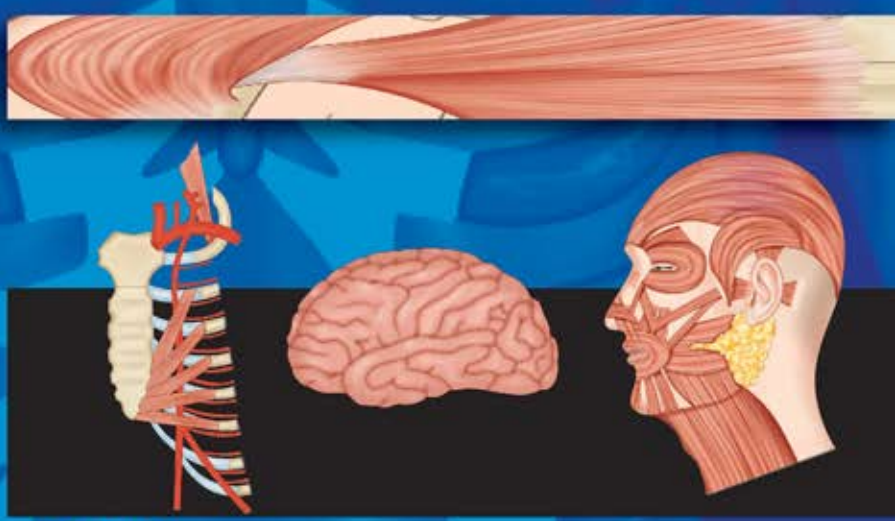

**Highlights**

- Ready-made and easy-going answers for examination
- Useful for theory, oral and practical examination
- Easy presentation for self-learning
- Precise and to the point
- All sections enriched with a chapter of clinical anatomy
- Richly illustrated with 504 diagrams

**Samar Deb**

JAYPEE

# CONTENTS

## Section 1: Thorax


**1. Thoracic Wall 1**
Inlet of Thorax 1
Outlet of Thorax 3
Intercostal Spaces 4
Intercostal Nerves 7
Atypical Intercostal Nerves 10
Intercostal Arteries 10
Internal Thoracic Artery 12

**2. Pleura 14**
Introduction to Thoracic Cavity 14
The Pleura 15

**3. The Lungs with Tracheobronchial Tree 22**
Introduction to the Respiratory Tract 22
Lungs 22

**4. Mediastinum of Thorax 37**
Mediastinum of Thorax 37

**5. Pericardium and Heart 42**
Pericardium 42
Fibrous Pericardium 42
Serous (Serosal) Pericardium 43
Heart 46
External Features 47
Interior of Right Atrium 50
Interatrial Septum 51
Interior of Right Ventricle 53
Interior of Left Atrium 54
Interior of Left Ventricle 54
Interventricular Septum 55
Valves of the Heart 55
Fibrous Skeleton of the Heart 57
Conducting System of the Heart 58
Arterial Supply of the Heart 60
Venous Drainage of Heart 63
Coronary Sinus 63
Nerve Supply of the Heart 64

**6. Great Vessels of Mediastinum 67**
Ascending Aorta 67
Arch of Aorta 68
Superior Vena Cava 71

**7. Structures of Posterior Thoracic Wall 73**
Trachea 73
Principal Bronchi 75
Esophagus 76
Azygos Venous System 80
Azygos Vein 80
Hemiazygos Vein 81
Accessory Hemiazygos Vein 82
Thoracic Duct 82
Thoracic Part of the Sympathetic Nervous System 85

**8. Joints of the Thorax and Respiratory Movements 88**
Joints of the Thorax 88
Costovertebral Joints 88
Costotransverse Joint 89
Costochondral Joints 90
Interchondral Joint 90
Sternocostal Joints 90
Joints of the Sternum 91
Intervertebral Joints 91
Respiratory Movements (Mechanics of Respiration) 92

**9. Explanatory Notes (Clinical/Embryological/Morphological) 96**


## Section 2: Neuroanatomy


**10. Introduction to Human Neuroanatomy 105**
Principles of Functions of Nervous System 105
Subdivisions of Nervous System 106
Centers of Nervous System 108
Composition of Nervous System 108
Neurons 109

Structure of a Typical Neuron 109
Neuronal (Axonal) Transport 110
Classification of Neurons 110
Neuronal Junction (Synapse) 112
Neuroglia 115
Ependymal Cells 115
Astrocytes 115
Oligodendrocytes 116
Microglia 117
Schwann Cells 117
Satellite Cells 117
Developmental Sources of Neuroglial Cells 118
Clinical Anatomy 118
Myelin Sheath 118

**11. Spinal Cord 120**
Spinal Cord 120
Internal Structure of Gray Matter 125
Rexed's Lamination of Spinal Gray Matter 129
Ascending Tracts 130
Descending Tracts 133
Corticospinal and Corticobulbar Tracts 133
Noncorticospinal Tract 134
Clinical Anatomy of Spinal Cord 137

**12. Brainstem 143**
Brainstem 143
Fundamental Points on Cranial Nerve Nuclei in the Brainstem 149
Locations and Functions of Cranial Nerve Nuclei in Different Level of Brainstem 150
Internal Structure of Midbrain 155
Clinical Anatomy of Brainstem 161

**13. Cerebellum and Fourth Ventricle 164**
Cerebellum 164
Fourth Ventricle of Brain 176

**14. Cerebrum: Cortical Gray Matter 181**
Cerebral Hemispheres 181
Types of Neurons in Cerebral Cortex 190
Functional Areas of Cerebral Cortex 191

**15. Cerebrum: Deep Structures 198**
Fibers of the Brain 198
Commissural Fibers 199
Anterior Commissure 202
Internal Capsule 202
Basal Ganglia 206
Other Terminologies 206
Lateral Ventricle of Brain 213

**16. Diencephalon and Third Ventricle 219**
Thalamus 219
Metathalamus 223
Epithalamus 224
Subthalamus 226
Hypothalamus 227
Third Ventricle of Brain 233

**17. Meninges of Brain and Cerebrospinal Fluid 238**
Dura Mater 238
Arachnoid Mater 240
Pia Mater 242
Cerebrospinal Fluid 243

**18. Blood Supply of Brain and Spinal Cord 248**
Arterial Supply of Brain 248
Venous Drainage of Brain 254
Arterial Supply of Spinal Cord 256
Venous Drainage of Spinal Cord 258
Blood-Brain Barrier 258
Clinical Anatomy 259

**19. Reticular Formation 263**
Reticular Formation 263

**20. Limbic System 269**
Limbic System 269

**21. Explanatory Notes (Clinical/Embryological/Morphological) 275**

**Section 3: Head and Neck**

**22. Scalp, Temple and Face 283**
Scalp 283
Muscles of Face 287
Arteries of Face 289
Veins of Face 290
Sensory Nerves of Face 292
Motor Nerves of Face 292

**23. Deep Cervical Fascia and Posterior Triangle of Neck 294**
Sternocleidomastoid Muscle 294
External Jugular Vein 296
Platysma Muscle 297
Deep Cervical Fascia 297
Posterior Triangle of Neck 303

**24. Anterior Triangle of Neck 306**
Anterior Triangle of Neck 306
Common Carotid Artery 311
External Carotid Artery 312

**25. Parotid Region and Infratemporal Fossa 315**
Parotid Gland 315
Muscles of Mastication 321
Pterygoid Venous Plexus 324
Temporomandibular Joint 325
Maxillary Artery 330

**26. Pterygopalatine Fossa and Submandibular Region 332**
Pterygopalatine Fossa 332
Third Part of Maxillary Artery 333
Pterygopalatine Ganglion 335
Digastric Triangle 337
Mylohyoid Muscle 339
Hyoglossus Muscle 340
Submandibular Salivary Gland 341

**27. Deep Structures of the Neck 345**
Thyroid Gland 345
Parathyroid Gland 352
Internal Jugular Vein 354
Cervical Lymph Nodes 356
Thymus 359

**28. Nose and Paranasal Air Sinuses 362**
External Nose 362
Nasal Cavity 363
Lateral Wall of Nasal Cavity 364
Nasal Septum 367
Paranasal Air Sinuses 370

**29. Larynx 375**
Larynx 375
Cartilages of Larynx 376
Important Joints of Larynx 378
Ligaments and Membranes of Larynx 379
Fibroelastic Lamina of Larynx 379
Cavity and Mucosa of Larynx 380
Intrinsic Muscles of Larynx 382
Arterial Supply of Larynx 386
Venous Drainage of Larynx 387
Lymphatic Drainage of Larynx 387
Nerve Supply of Larynx 387
Clinical Anatomy of Larynx 387

**30. Mouth, Tongue and Palate 389**
Teeth 389
Tongue 392
Muscular Architecture of Tongue 395
Arterial Supply of Tongue 397
Venous Drainage of Tongue 398
Lymphatic Drainage of Tongue 398
Nerve Supply of Tongue 398
Soft Palate 399

**31. Pharynx, Tonsil and Pharyngotympanic Tube 406**
Pharynx 406
Layers of Pharyngeal Wall 409
Constrictor Muscles of Pharynx 411
Nerve Supply of Pharynx 413
Mechanism of Deglutition (Swallowing) 413
Palatine Tonsil 415
Pharyngotympanic Tube 418

**32. Prevertebral Region and Back of the Neck 421**
Scalenus Anterior 421
Cervical Plexus 422
Ansa Cervicalis 424
Phrenic Nerve in the Neck 425
Accessory Phrenic Nerve 425
Cervical Part of Sympathetic Trunk 426
Subclavian Artery 428
Suboccipital Triangle 432

**33. Cranial Cavity and Orbit 436**
Dura Mater 436
Nerve Supply of Dura Mater 439
Venous Sinuses of Dura Mater 439
Cavernous Sinus 441

Pituitary Gland 444
Lacrimal Apparatus 448
Muscles of the Orbit 450
Ophthalmic Artery 453

**34. The Eyeball 455**
The Eyeball 455

**35. The Ear 463**
External Acoustic Meatus 463
Tympanic Membrane 464
Middle Ear 466
Ossicles of the Middle Ear 471
Muscles of the Middle Ear 473
Mastoid Antrum and Air Cells 473
Organ of Corti 474

**36. Cranial Nerves 476**
Fundamental Points on Cranial Nerves 476
Olfactory Nerve and Olfactory Pathway 477
Optic Nerve and Visual Pathway 479
Visual Reflexes 483
Oculomotor Nerve 488
Trochlear Nerve 492
Trigeminal Nerve 494
Ophthalmic Nerve 496
Maxillary Nerve 499
Mandibular Nerve 501
Clinical Anatomy of Trigeminal Nerve 505
Abducent Nerve 506
Facial Nerve 508
Vestibulocochlear Nerve 515
Vestibular Pathway 515
Cochlear Pathway 517
Last Four Cranial Nerves 521
Glossopharyngeal Nerve 522
Vagus Nerve 525
Accessory Nerve 531
Hypoglossal Nerve 535

**37. Explanatory Notes (Clinical/Embryological/Morphological) 538**

*Index* *549*

Chapter

# 4

# Mediastinum of Thorax

**LA 4.1 Define mediastinum of thorax. Mention its subdivisions with their boundaries and contents. Add a note on its clinical anatomy.**

## MEDIASTINUM OF THORAX

### Introduction

The word 'mediastinum' means a partition. The mediastinum of thorax is a **movable thick partition** in the midline of thorax extending anteroposteriorly from the anterior to the posterior chest wall. It is mainly formed by heart with pericardium, great blood vessels connected to it, trachea with esophagus, nerves and lymphatic duct embedded in loose connective tissue.

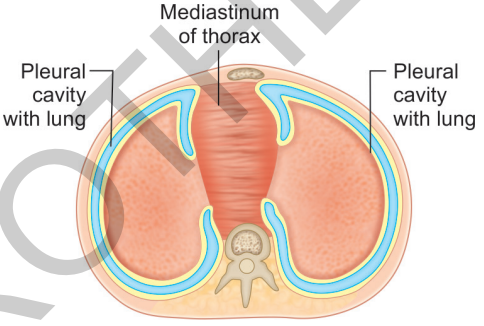


**Fig. 4.1:** Mediastinum is a broad septum lying between pleurae and lungs of two sides.

The mediastinum divides the thoracic cavity into right and left halves containing the pleural sac invaginated by the lung of the corresponding side **(Fig. 4.1)**.

### Extent

- **Anteriorly:** Posterior surface of the sternum
- **Posteriorly:** Bodies of thoracic vertebrae and intervertebral disks
- **Superiorly:** Inlet of thorax
- **Inferiorly:** The diaphragm
- **Laterally:** Mediastinal pleura.

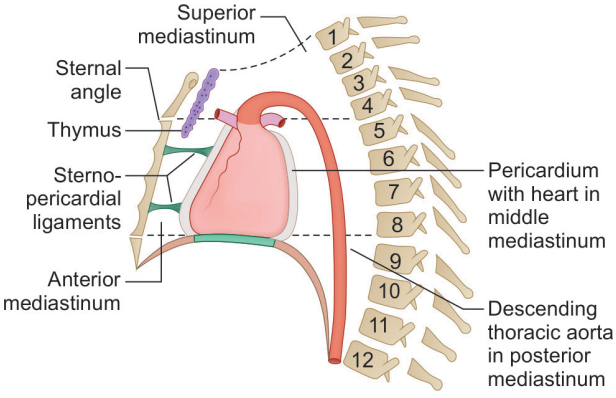


**Fig. 4.2:** Subdivision of mediastinum of thorax.

### Importance of Knowledge of Mediastinum

Mediastinum of thorax is formed by a large number of structures which are very closely related to each other. Acquirement of the knowledge of their relationship is important because its pathological change of any structure leading to its enlargement may give rise to pressure effect on another structure. It will result in a clinical condition called **mediastinal syndrome**.

### Subdivisions (Fig. 4.2)

Primarily, the mediastinum of thorax is subdivided into **superior mediastinum** and **inferior mediastinum** by an imaginary line passing anteriorly through the **sternal angle** and posteriorly through the level of lower border of body of **4th thoracic vertebra**.

JAYPEE BROTHERS

**Further subdivision of inferior mediastinum:** Heart enclosed by pericardium divides inferior mediastinum as follows.

- **Anterior mediastinum:** In front of the heart with pericardium
- **Middle mediastinum:** Occupied by the heart with pericardium
- **Posterior mediastinum:** Behind the heart with pericardium.

## Summary of the Subdivision

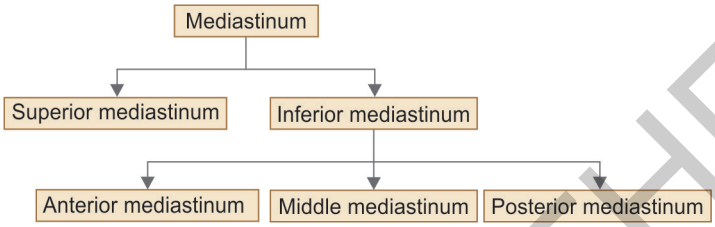


### *Superior Mediastinum*

#### Boundaries

- **Anterior:** Manubrium sterni
- **Posterior:** Bodies of upper four thoracic vertebrae and intervertebral disks
- **Superior:** Plane of inlet of thorax
- **Inferior:** Transverse thoracic plane passing through the level of sternal angle ($T_4$ vertebra)
- **Laterally:** Mediastinal pleura.

#### Contents (Fig. 4.3)

Contents of superior mediastinum is divided anteroposteriorly in 3 sets which are as follows:

- **Anterior** (behind manubrium):
  - Origin of **sternohyoid** and **sternothyroid** muscles from the back of manubrium.
  - Remnant of **thymus**.
- **Middle** (opposite the plane of heart):
  - **Arch of aorta** with its three major branches—**brachiocephalic, left common carotid** and **left subclavian arteries**
  - **Left brachiocephalic vein** crossing obliquely the midline from left to right in front of the three major branches of arch of aorta
  - **Upper half of superior vena cava** with **right brachiocephalic vein**
  - Right and left phrenic nerves.

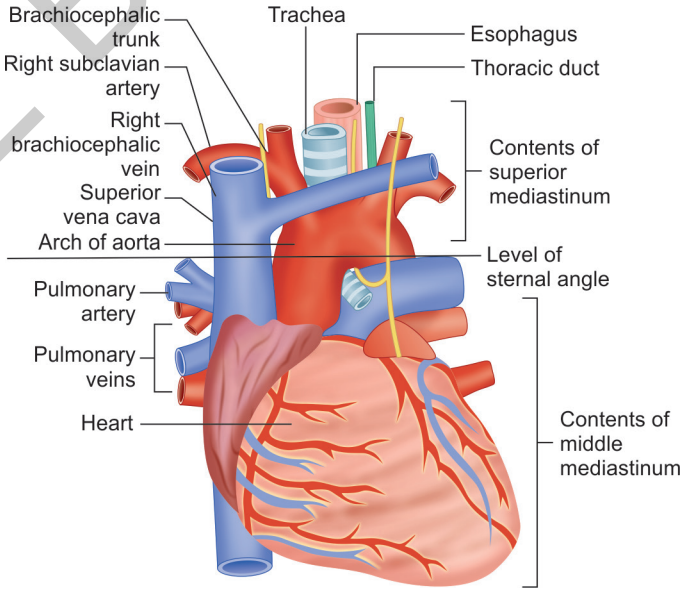


**Fig. 4.3:** Structures of superior and middle mediastinum.

JAYPEE BROTHERS

- **Posterior**
  - Trachea
  - Esophagus with thoracic duct
  - Right and left vagus nerve with left recurrent laryngeal nerve
  - Longus colli muscle
  - Sympathetic trunk.

#### Summary of the structures of the superior mediastinum from before backwards

- Thymus
- Major (large) veins
- Major (large) arteries
- Trachea
- Esophagus with thoracic duct
- Sympathetic trunk.

### *Inferior Mediastinum*

#### Anterior mediastinum (*see* Fig. 4.2)

***Boundaries***

- **Anterior:** Body of the sternum
- **Posterior:** Heart enclosed by pericardium
- **Superior:** Transverse thoracic plane at the level of sternal angle ($T_4$ vertebra)
- **Inferior:** The diaphragm
- **Lateral:** Mediastinal pleura.

***Contents***

- **Thymus** in children (may remain in adults)
- Superior and inferior **sternopericardial ligaments** connecting body of sternum with fibrous pericardium
- Sternopericardial group of **lymph nodes**
- **Mediastinal arteries**—branches of internal thoracic artery
- **Loose areolar tissue**.

#### Middle mediastinum

***Boundaries***

- **Anterior:** Structures of anterior mediastinum
- **Posterior:** Anterior structures of posterior mediastinum, e.g. bifurcation of trachea and esophagus
- **Superior:** Transverse thoracic plane passing through the level of sternal angle ($T_4$ vertebra)
- **Inferior:** The diaphragm
- **Lateral:** Mediastinal pleura.

***Contents (see Fig. 4.3)***

- **Heart** enclosed by **pericardium** is the main content
- **Arteries: Ascending aorta, pulmonary trunk** and **pericardiophrenic artery**
- **Veins:** Lower half of **superior vena cava, pulmonary veins** and **terminal part (arch) of azygos vein**
- **Nerve: Phrenic nerve** and **cardiac plexus**
- **Tubes: Bifurcation of trachea** into right and left **primary bronchi**
- **Lymph nodes: Tracheobronchial lymph nodes**.

JAYPEE BROTHERS

### Posterior mediastinum

***Boundaries***

- **Anterior:** Pericardium covering the posterior surface or base of the heart
- **Posterior:** Bodies of $T_5$ to $T_{12}$ vertebrae with intervening intervertebral disks
- **Superior:** Transverse thoracic plane passing through the lower border of body of $T_4$ vertebra (sternal angle)
- **Inferior:** The diaphragm which truly forms the *anteroinferior boundary* as it slopes downwards and backwards
- **Lateral:** Mediastinal pleura.

***Contents (Fig. 4.4)***

- **Tube: Esophagus**
- **Arteries: Descending thoracic aorta** with its branches
- **Veins: Azygos and hemiazygos veins**
- **Lymph vessel: Thoracic duct**
- **Lymph nodes: Posterior mediastinal lymph nodes**
- **Nerves: Sympathetic trunk** and thoracic **splanchnic nerves**.

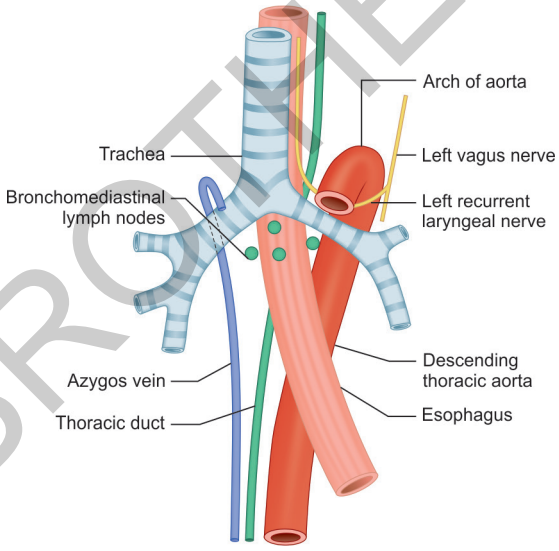


**Fig. 4.4:** Structures of posterior mediastinum of thorax.

## Clinical Anatomy

### *Mediastinitis*

It is the clinical condition due to inflammation of loose connective tissue of the mediastinum. Loose connective tissue embedding the mediastinal structures is continuous with that of the root of neck. So, the deep infection in the root of the neck can easily spread into the chest causing mediastinitis.

### *Dead Space in Superior Mediastinum*

On the right side of superior mediastinum, there is adequate dead space occupied by loose connective tissue around the large veins, namely the superior vena cava and brachiocephalic vein. This dead space has physiological as well as pathological importance. During increased venous return, dilated veins are accommodated in this space. Again, any mediastinal tumor is also accommodated here.

### *Subcutaneous Emphysema of Mediastinum*

This is the complication which results from a penetrating wound in esophagus. Air swallowed in esophagus leaks and get accumulated in the loose tissue space of mediastinum. It finally spreads upwards through the fascial space in the root of neck.

### *Neck Infection Spreading into Anterior Mediastinum*

Pretracheal layer of deep cervical fascia extends below to blend with adventitious (outer fibrous) coat of great vessels of superior mediastinum. Infection from the root of neck may spread downwards to the anterior mediastinum in front of root of great vessels.

JAYPEE BROTHERS

*Mediastinal Syndrome*

It is a clinical condition which occurs due to pressure effect on any of the structures which are crowded together within the mediastinum. It results due to any enlarging tumor or cyst in the mediastinum.

For example, a tumor (cancer) of the left lung spreading rapidly may cause enlargement of the mediastinal lymph nodes which will press the left recurrent laryngeal nerve resulting paralysis of vocal cord of larynx.

**Common causes** of mediastinal syndrome are:

- **Bronchogenic carcinoma** of lung
- **Aneurysm (ballooning) of aorta**
- Enlarged mediastinal lymph nodes in **Hodgkin's lymphoma**.

**Pressure effect** in mediastinal syndrome are as follows:

- Difficulty in breathing **(dyspnea)** due to compression on trachea
- Difficulty in swallowing **(dysphagia)** due to compression on esophagus
- **Venous stasis and venous engorgement** in upper half of the body due to pressure on superior vena cava
- Hoarseness of voice **(dysphonia)** due to pressure on left recurrent laryngeal nerve.

**Deflection of mediastinum (mediastinal shift):** In the living body, the mediastinum of thorax is mobile. The heart, the great vessels and the lungs are in rhythmic pulsation. The esophagus becomes distended when the food bolus passes through it. Though mobile, midline position of the mediastinum is maintained by the intrapleural pressure of both sides. Shifting of the mediastinum takes place due to decrease or increase of intrapleural pressure in one side. When any disease of the lung causes its collapse, it will cause **reduction of intrapleural pressure** on that side. It results in **shifting of mediastinum to the diseased side**. Again, in case of **pneumothorax, abnormal rise of intrapleural pressure** will cause deflection or **shifting of the mediastinum to the opposite (normal) side**.

JAYPEE BROTHERS

for detailed information on anatomy books, visit our website www.jaypeebrothers.com, for detailed information on anatomy books, visit

# Exam Oriented
# ANATOMY
# Regional and Applied

***Salient Features***

- All the areas of gross anatomy have been covered in such a fashion that, this book can be used as an ideal textbook for undergraduate course
- Though the text material has been placed in the question-answer form, it has been sequentially arranged to create clear concept on the subject
- The text material is compact to incorporate within 2 volumes instead of conventional 3 volumes
- The presentation is student friendly with neat diagrams to make the book easy for self-learning
- The style of presentation is unique to be helpful for a teacher to prepare for the classes
- All the topics have been enriched in such a fashion that the book will also be very useful for the postgraduate students as well as the readers of other disciplines.

**Samar Deb** MS is Academic Director and Emeritus Professor, Department of Anatomy, MGM Medical College, Kishanganj, Bihar, India, where he worked as Principal and Professor, Department of Anatomy till August 2017. He obtained his MBBS degree from NRS Medical College, Kolkata, West Bengal, India. He was awarded postgraduate degree (MS in Anatomy) by the Institute of Medical Sciences, Banaras Hindu University, Varanasi, Uttar Pradesh, India. He joined the medical teaching profession in 1972 in North Bengal Medical College, Darjeeling, West Bengal where he worked as Professor, Department of Anatomy since 1992. Following his retirement from the government institute in 2008, he worked as Academic Director as well as Principal and Professor, Department of Anatomy, Katihar Medical College, Katihar, Bihar and as Principal, College of Medicine & JNM Hospital, Kalyani, West Bengal.

Dr Samar Deb is a life member of Anatomical Society of India. He was the member of Medical Council of India for about a decade. He served as postgraduate teacher for many years, guided a good number of PhD students and published many research papers. He possesses the experience of being Medical Council of India (MCI) inspector and undergraduate as well as postgraduate examiner of many universities. He was awarded the Fellowship of National Academy of Anatomical Society of India in the year 2013. With 47 years of teaching experience in anatomy, he has established himself as a popular and successful teacher for his unique style of teaching.

**Available at all medical bookstores**
**or buy online at www.jaypeebrothers.com**



**JAYPEE BROTHERS**
**Medical Publishers (P) Ltd.**
**www.jaypeebrothers.com**

Join us on f facebook.com/JaypeeMedicalPublishers

Shelving Recommendation
**ANATOMY**

